Atlas of Human Anatomy

Third Edition

Frank H. Netter, M.D.

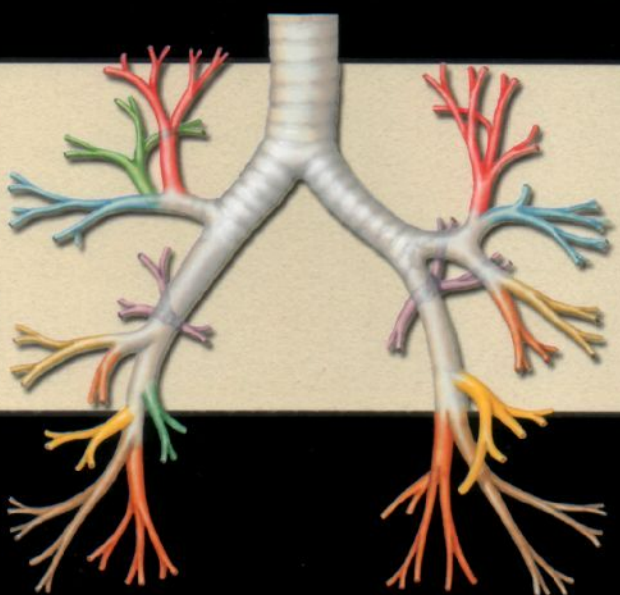

Atlas of Human Anatomy

Atlas Human

of

Anatomy

Third Edition

by Frank H. Netter, M.D.

John T. Hansen, Ph.D., *Consulting Editor*
University of Rochester School of Medicine and Dentistry
Rochester, New York

Icon Learning Systems · Teterboro, New Jersey

Copyright © 2003, 1997, 1989, ICON Learning Systems, LLC, a subsidiary of MediMedia USA, Inc.

First Edition, 1989
Second Edition, 1997
Third Edition, 2003

All rights reserved. No part of this book may be reproduced in any form or by any electronic or mechanical means, including information storage and retrieval systems, without permission in writing from the publisher. Requests for permission should be addressed to Permissions Editor, Icon Learning Systems, 295 North Street, Teterboro NJ 07608; or may be made at www.netterart.com/request_start.asp

NOTICE

Every effort has been taken to confirm the accuracy of the information presented. Neither the publisher nor the authors can be held responsible for errors or for any consequences arising from the use of the information contained herein, and make no warranty, expressed or implied, with respect to the contents of the publication.

Executive Editor: Paul Kelly
Editorial Director: Greg Otis
Managing Editor: Jennifer Surich
Art Director: Erika Gehringer
Print Production Manager: Mary Ellen Curry

10 9 8 7 6 5 4 3 2

ISBN 1-929007-11-6 (paperback)
ISBN 1-929007-15-9 (paperback/CD Combo)
ISBN 1-929007-21-3 (case bound/CD Combo)
Library of Congress Control No: 2002110663

Printed and bound in USA by RR Donnelley

100M-0703-RRD

To my dear wife, Vera

PREFACE TO THE FIRST EDITION

I have often said that my career as a medical artist for almost 50 years has been a sort of "command performance" in the sense that it has grown in response to the desires and requests of the medical profession. Over these many years, I have produced almost 4,000 illustrations, mostly for *The CIBA (now Netter) Collection of Medical Illustrations* but also for *Clinical Symposia*. These pictures have been concerned with the varied subdivisions of medical knowledge such as gross anatomy, histology, embryology, physiology, pathology, diagnostic modalities, surgical and therapeutic techniques and clinical manifestations of a multitude of diseases. As the years went by, however, there were more and more requests from physicians and students for me to produce an atlas purely of gross anatomy. Thus, this atlas has come about, not through any inspiration on my part but rather, like most of my previous works, as a fulfillment of the desires of the medical profession.

It involved going back over all the illustrations I had made over so many years, selecting those pertinent to gross anatomy, classifying them and organizing them by system and region, adapting them to page size and space and arranging them in logical sequence. Anatomy of course does not change, but our understanding of anatomy and its clinical significance does change, as do anatomical terminology and nomenclature. This therefore required much updating of many of the older pictures and even revision of a number of them in order to make them more pertinent to today's ever-expanding scope of medical and surgical practice. In addition, I found that there were gaps in the portrayal of medical knowledge as pictorialized in the illustrations I had previously done, and this necessitated my making a number of new pictures that are included in this volume.

In creating an atlas such as this, it is important to achieve a happy medium between complexity and simplification. If the pictures are too complex, they may be difficult and confusing to read; if oversimplified, they may not be adequately definitive or may even be misleading. I have therefore striven for a middle course of realism without the clutter of confusing minutiae. I hope that the students and members of the medical and allied professions will find the illustrations readily understandable, yet instructive and useful.

At one point, the publisher and I thought it might be nice to include a foreword by a truly outstanding and renowned anatomist, but there are so many in that category that we could not make a choice. We did think of men like Vesalius, Leonardo da Vinci, William Hunter and Henry Gray, who of course are unfortunately unavailable, but I do wonder what their comments might have been about this atlas.

Frank H. Netter, M.D.
(1906–1991)

PHOTOGRAPH BY JAMES L. CLAYTON

FRANK H. NETTER, M.D.

FOREWORD

"The release in 1989 of the first edition of Dr. Frank Netter's 'personal Sistine Chapel'—the Atlas of Human Anatomy—was a major event in the history of the teaching and learning of anatomy. Almost instantly, the Atlas of Human Anatomy became the top-selling anatomical atlas in the world and clearly became the students' choice universally." This quotation from the second edition of the *Atlas of Human Anatomy* still resonates today as the beautifully conceived and rendered artwork of Dr. Netter continues to capture the admiration of students and healthcare professionals.

The skillful editing and publishing teamwork of Novartis Medical Education, in consultation with many of the 20th century's outstanding anatomists and physicians, have made the first and second editions of the *Atlas* the standard against which all other atlases are compared. This third edition owes much to the Consulting Editors of the earlier editions, Drs. Sharon Colacino (Oberg) (first edition) and Arthur F. Dalley II (second edition), who shepherded their editions with great skill and uncompromising professionalism and thus made my task significantly easier. I am honored to serve as the Consulting Editor of the third edition and to continue the Netter tradition in partnership with Icon Learning Systems as the *Atlas of Human Anatomy* enters the new century.

Perceptive student and faculty response to the earlier editions prompted greater attention to several concepts that are critical to the anatomical basis of clinical practice. Notably, each regional section now begins with a surface anatomy plate, skillfully drawn by Carlos A.G. Machado, M.D. These surface anatomy plates remind us of the value of careful observation in clinical medicine and draw attention to surface features that portend the underlying anatomy.

We also have included a significant number of normal radiographic images in this edition, reflecting the importance of diagnostic imaging in clinical anatomy and medicine. These new images are not meant to be comprehensive of the radiographic knowledge available to today's clinicians, but rather are starting points for further exploration into the richness of anatomical detail that imaging can provide. I am grateful to Matthew Cham, M.D., and John Wandtke, M.D., of our Department of Radiology for selecting these images and permitting us to use them in this edition.

We balanced the addition of new surface and radiographic anatomy plates largely by eliminating several plates that contributed little to the quality of the *Atlas*. Several plates from *The Netter* (formerly *CIBA*) *Collection of Medical Illustrations* were added and several plates were altered slightly to correct anatomical errors consistent with our current knowledge. In sum, the third edition has grown by 30 images. Finally, the References and the Index have been updated.

The anatomical terminology is consistent throughout the *Atlas* and conforms to the International Anatomical Terminology (*Terminologia Anatomica*) approved in 1998 by the International Federation of Associations of Anatomists. Common eponyms are retained parenthetically, and the leader lines and labels have been checked and, where necessary, corrected to ensure their accuracy. For reviewing this material I thank Wojciech Pawlina, M.D., Leonard J. Cleary, Ph.D., Daniel O. Graney, Ph.D., and Brian R. MacPherson, Ph.D. Their meticulous examination of each plate has greatly enhanced the accuracy of this atlas.

For the proofreading, editing and designing, I am indebted to Jennifer Surich, Erika Gehringer and Greg Otis at Icon Learning Systems; their keen eyesight, dedication and professionalism buoyed me when I began to drift. A special thank you is reserved for Paul Kelly, Executive Editor, who continues to listen patiently and is a true believer in the power of the visual image to teach.

To all students, past, present and future, the legacy of Dr. Netter's artwork lives in you; his unique ability to "clarify rather than intimidate" is his gift to you. I am both privileged and humbled to have the opportunity to carry forward this tradition of excellence and to contribute to your understanding of human anatomy.

Finally, to my wife, Paula, thank you for giving me the freedom to write and the support to sustain me—in those respects, this book was co-edited.

John T. Hansen, Ph.D.
Professor of Neurobiology and Anatomy
University of Rochester School of Medicine and Dentistry
Rochester, New York

CONTENTS

Section I HEAD AND NECK

SURFACE ANATOMY	*Plate 1*
BONES AND LIGAMENTS	*Plates 2–18*
SUPERFICIAL FACE	*Plates 19–22*
NECK	*Plates 23–31*
NASAL REGION	*Plates 32–46*
ORAL REGION	*Plates 47–58*
PHARYNX	*Plates 59–69*
THYROID GLAND AND LARYNX	*Plates 70–76*
ORBIT AND CONTENTS	*Plates 77–86*
EAR	*Plates 87–93*
MENINGES AND BRAIN	*Plates 94–109*
CRANIAL AND CERVICAL NERVES	*Plates 110–129*
CEREBRAL VASCULATURE	*Plates 130–141*
REGIONAL SCANS	*Plates 142–144*

Section II BACK AND SPINAL CORD

SURFACE ANATOMY	*Plate 145*
BONES AND LIGAMENTS	*Plates 146–152*
SPINAL CORD	*Plates 153–166*
MUSCLES AND NERVES	*Plates 167–173*

Section III THORAX

SURFACE ANATOMY	*Plate 174*
MAMMARY GLAND	*Plates 175–177*
BODY WALL	*Plates 178–191*
LUNGS	*Plates 192–206*
HEART	*Plates 207–225*
MEDIASTINUM	*Plates 226–237*
REGIONAL SCANS	*Plate 238*

Section IV ABDOMEN

SURFACE ANATOMY	*Plate 239*
BODY WALL	*Plates 240–259*
PERITONEAL CAVITY	*Plates 260–266*
VISCERA (GUT)	*Plates 267–277*
VISCERA (ACCESSORY ORGANS)	*Plates 278–289*
VISCERAL VASCULATURE	*Plates 290–307*
INNERVATION	*Plates 308–318*
KIDNEYS AND SUPRARENAL GLANDS	*Plates 319–334*
ABDOMINAL SECTIONS	*Plates 335–337*
REGIONAL SCANS	*Plate 338*

Section V PELVIS AND PERINEUM

SURFACE ANATOMY	*Plate 339*
BONES AND LIGAMENTS	*Plates 340–342*
PELVIC FLOOR AND CONTENTS	*Plates 343–353*
FEMALE STRUCTURES	*Plates 354–362*
MALE STRUCTURES	*Plates 363–371*
RECTUM	*Plates 372–377*
VASCULATURE	*Plates 378–388*
INNERVATION	*Plates 389–397*
HOMOLOGUES OF GENITALIA	*Plates 398–399*
REGIONAL SCANS	*Plate 400*

Section VI UPPER LIMB

SURFACE ANATOMY	*Plate 401*
SHOULDER AND AXILLA	*Plates 402–413*
ARM	*Plates 414–418*
ELBOW AND FOREARM	*Plates 419–434*
WRIST AND HAND	*Plates 435–454*
NEUROVASCULATURE	*Plates 455–466*

Section VII LOWER LIMB

SURFACE ANATOMY	*Plate 467*
HIP AND THIGH	*Plates 468–487*
KNEE	*Plates 488–494*
LEG	*Plates 495–504*
ANKLE AND FOOT	*Plates 505–519*
NEUROVASCULATURE	*Plates 520–528*

Section VIII CROSS-SECTIONAL ANATOMY

CROSS-SECTION OVERVIEW	*Plate 529*
THORAX	*Plates 530–533*
ABDOMEN	*Plates 534–539*
MALE PELVIS	*Plate 540*
THORAX	*Plates 541–542*

REFERENCES
INDEX

Section I
HEAD AND NECK

SURFACE ANATOMY
Plate 1

1. Head and Neck

BONES AND LIGAMENTS
Plates 2–18

2. Skull: Anterior View
3. Skull: Anteroposterior Radiograph
4. Skull: Lateral View
5. Skull: Lateral Radiograph
6. Skull: Midsagittal Section
7. Calvaria
8. Cranial Base: Inferior View
9. Bones of Cranial Base: Superior View
10. Foramina of Cranial Base: Superior View
11. Skull of Newborn
12. Bony Framework of Head and Neck
13. Mandible
14. Temporomandibular Joint
15. Cervical Vertebrae: Atlas and Axis
16. Cervical Vertebrae (*continued*)
17. External Craniocervical Ligaments
18. Internal Craniocervical Ligaments

SUPERFICIAL FACE
Plates 19–22

19. Superficial Arteries and Veins of Face and Scalp
20. Cutaneous Nerves of Head and Neck
21. Facial Nerve Branches and Parotid Gland
22. Muscles of Facial Expression: Lateral View

NECK
Plates 23–31
23. Muscles of Neck: Lateral View
24. Muscles of Neck: Anterior View
25. Infrahyoid and Suprahyoid Muscles
26. Scalene and Prevertebral Muscles
27. Superficial Veins and Cutaneous Nerves of Neck
28. Cervical Plexus In Situ
29. Subclavian Artery
30. Carotid Arteries
31. Fascial Layers of Neck

NASAL REGION
Plates 32–46
32. Nose
33. Lateral Wall of Nasal Cavity
34. Lateral Wall of Nasal Cavity (*continued*)
35. Medial Wall of Nasal Cavity (Nasal Septum)
36. Maxillary Artery
37. Arteries of Nasal Cavity: Nasal Septum Turned Up
38. Nerves of Nasal Cavity: Nasal Septum Turned Up
39. Nerves of Nasal Cavity (*continued*)
40. Autonomic Innervation of Nasal Cavity
41. Ophthalmic (V_1) and Maxillary (V_2) Nerves
42. Mandibular Nerve (V_3)
43. Nose and Paranasal Sinuses: Cross Section
44. Paranasal Sinuses
45. Paranasal Sinuses (*continued*)
46. Paranasal Sinuses: Changes With Age

ORAL REGION
Plates 47–58
47. Inspection of Oral Cavity
48. Roof of Mouth
49. Floor of Mouth
50. Muscles Involved in Mastication
51. Muscles Involved in Mastication (*continued*)
52. Teeth
53. Teeth (*continued*)
54. Tongue
55. Tongue (*continued*)
56. Tongue and Salivary Glands: Sections
57. Salivary Glands
58. Afferent Innervation of Mouth and Pharynx

PHARYNX
Plates 59–69
59. Pharynx: Median Section
60. Fauces
61. Muscles of Pharynx: Median (Sagittal) Section
62. Pharynx: Opened Posterior View
63. Muscles of Pharynx: Partially Opened Posterior View
64. Muscles of Pharynx: Lateral View
65. Arteries of Oral and Pharyngeal Regions
66. Veins of Oral and Pharyngeal Regions
67. Nerves of Oral and Pharyngeal Regions

68. Lymph Vessels and Nodes of Head and Neck
69. Lymph Vessels and Nodes of Pharynx and Tongue

THYROID GLAND AND LARYNX
Plates 70–76

70. Thyroid Gland: Anterior View
71. Thyroid Gland and Pharynx: Posterior View
72. Parathyroid Glands
73. Cartilages of Larynx
74. Intrinsic Muscles of Larynx
75. Action of Intrinsic Muscles of Larynx
76. Nerves of Larynx

ORBIT AND CONTENTS
Plates 77–86

77. Eyelids
78. Lacrimal Apparatus
79. Fascia of Orbit and Eyeball
80. Extrinsic Eye Muscles
81. Arteries and Veins of Orbit and Eyelids
82. Nerves of Orbit
83. Eyeball
84. Anterior and Posterior Chambers of Eye
85. Lens and Supporting Structures
86. Intrinsic Arteries and Veins of Eye

EAR
Plates 87–93

87. Pathway of Sound Reception
88. External Ear and Tympanic Cavity
89. Tympanic Cavity
90. Bony and Membranous Labyrinths
91. Bony and Membranous Labyrinths (*continued*)
92. Orientation of Labyrinth in Skull
93. Pharyngotympanic (Auditory) Tube

MENINGES AND BRAIN
Plates 94–109

94. Meninges and Diploic Veins
95. Meningeal Arteries
96. Meninges and Superficial Cerebral Veins
97. Dural Venous Sinuses
98. Dural Venous Sinuses (*continued*)
99. Cerebrum: Lateral Views
100. Cerebrum: Medial Views
101. Cerebrum: Inferior View
102. Ventricles of Brain
103. Circulation of Cerebrospinal Fluid
104. Basal Nuclei (Ganglia)
105. Thalamus
106. Hippocampus and Fornix
107. Cerebellum
108. Brainstem
109. Fourth Ventricle and Cerebellum

CRANIAL AND CERVICAL NERVES
Plates 110–129

110. Cranial Nerve Nuclei in Brainstem: Schema
111. Cranial Nerve Nuclei in Brainstem: Schema (*continued*)
112. Cranial Nerves (Motor and Sensory Distribution): Schema
113. Olfactory Nerve (I): Schema

114. Optic Nerve (II) (Visual Pathway): Schema
115. Oculomotor (III), Trochlear (IV) and Abducent (VI) Nerves : Schema
116. Trigeminal Nerve (V): Schema
117. Facial Nerve (VII): Schema
118. Vestibulocochlear Nerve (VIII): Schema
119. Glossopharyngeal Nerve (IX): Schema
120. Vagus Nerve (X): Schema
121. Accessory Nerve (XI): Schema
122. Hypoglossal Nerve (XII): Schema
123. Cervical Plexus: Schema
124. Autonomic Nerves in Neck
125. Autonomic Nerves in Head
126. Ciliary Ganglion: Schema
127. Pterygopalatine and Submandibular Ganglia: Schema
128. Otic Ganglion: Schema
129. Taste Pathways: Schema

CEREBRAL VASCULATURE
Plates 130–141

130. Arteries to Brain and Meninges
131. Arteries to Brain: Schema
132. Arteries of Brain: Inferior Views
133. Cerebral Arterial Circle (Willis)
134. Arteries of Brain: Frontal View and Section
135. Arteries of Brain: Lateral and Medial Views
136. Arteries of Posterior Cranial Fossa
137. Veins of Posterior Cranial Fossa
138. Deep Veins of Brain
139. Subependymal Veins of Brain
140. Hypothalamus and Hypophysis
141. Arteries and Veins of Hypothalamus and Hypophysis

REGIONAL SCANS
Plates 142–144

142. Head Scans: Sagittal MR Images
143. Head Scans: Axial CT Images
144. Head Scans: Coronal CT Images

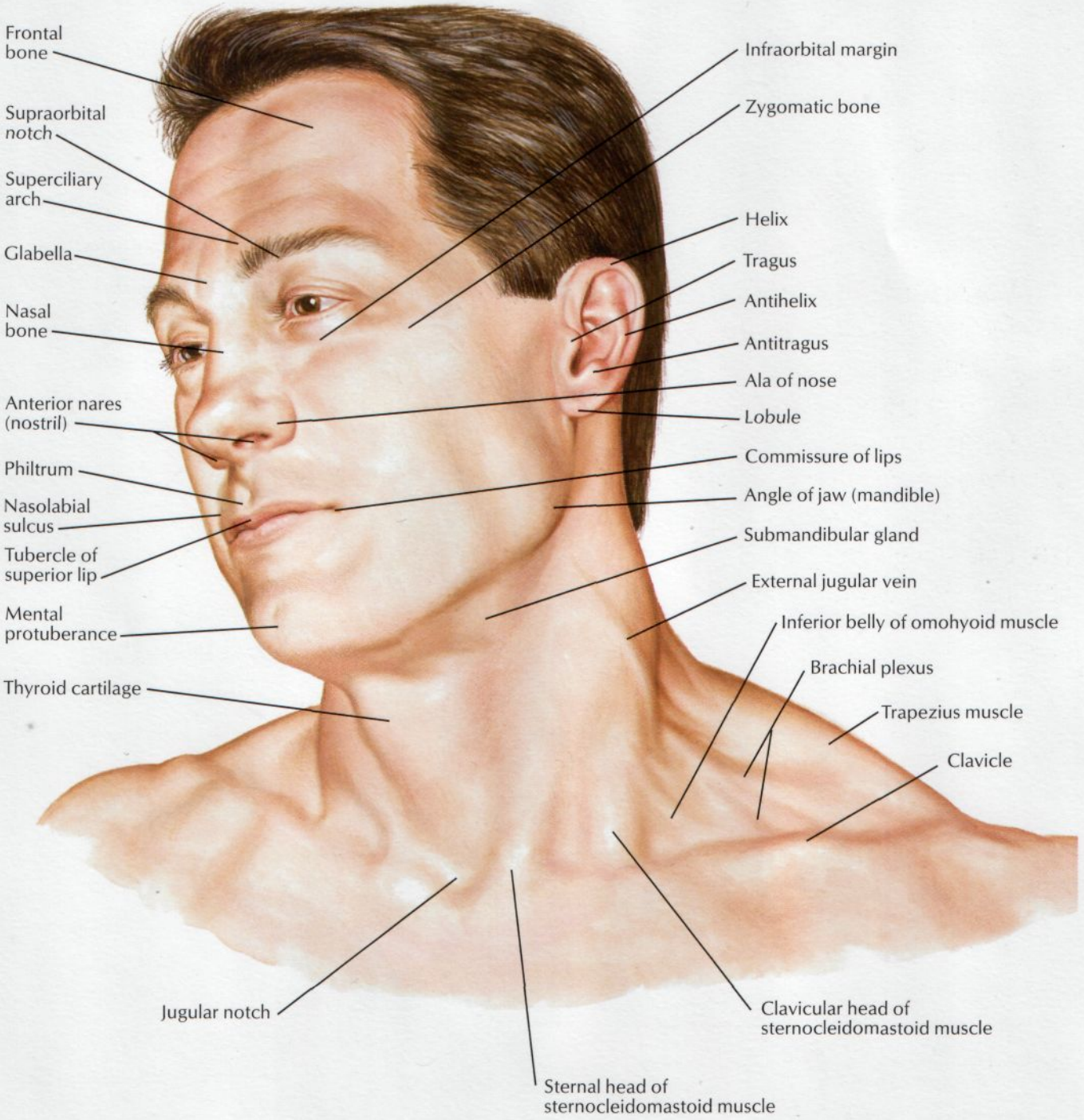

C. Machado M.D.
©ICON LEARNING SYSTEMS

Skull: Anterior View

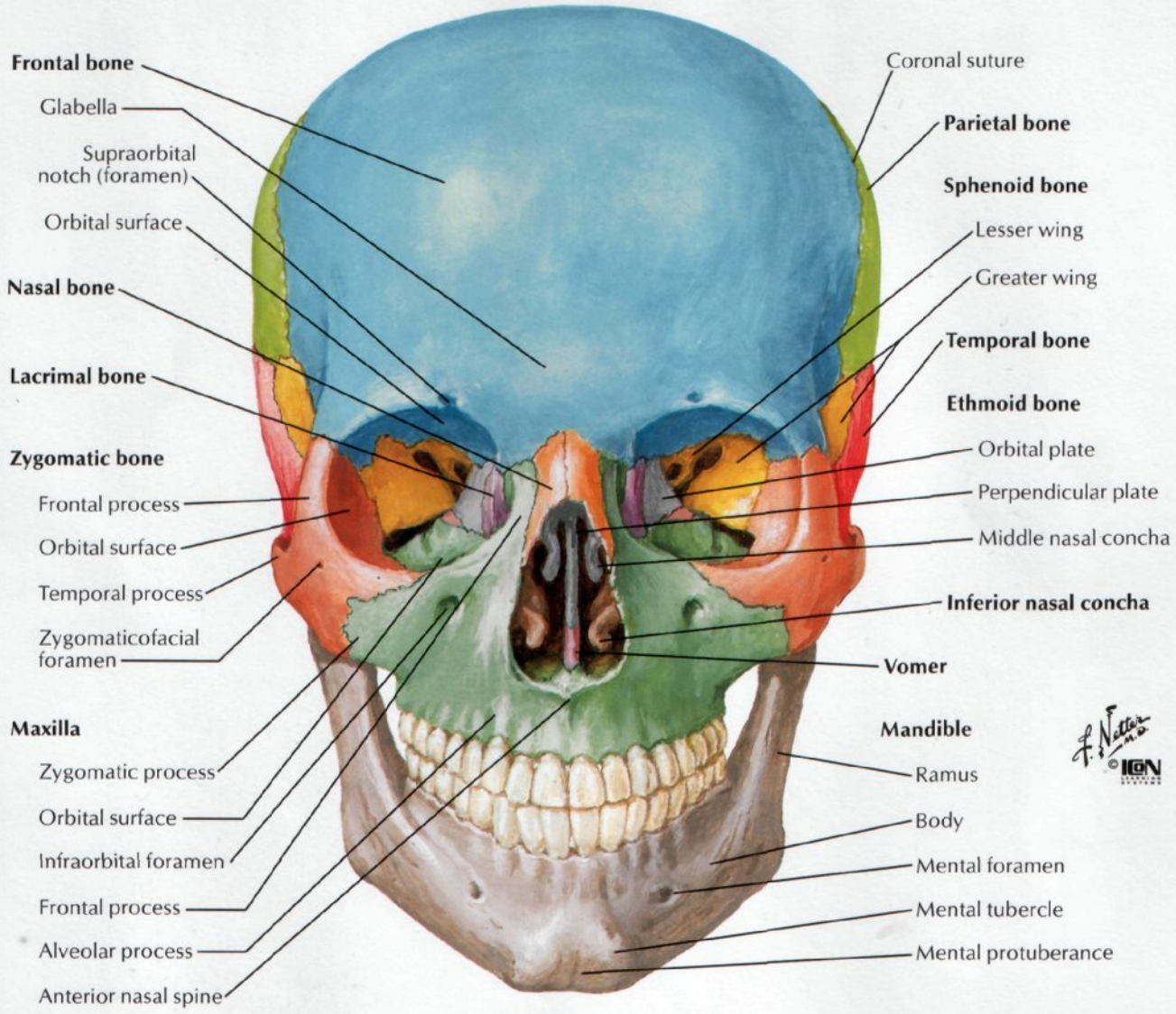

Right orbit: frontal and slightly lateral view

Skull: Anteroposterior Radiograph

SEE ALSO PLATE 2

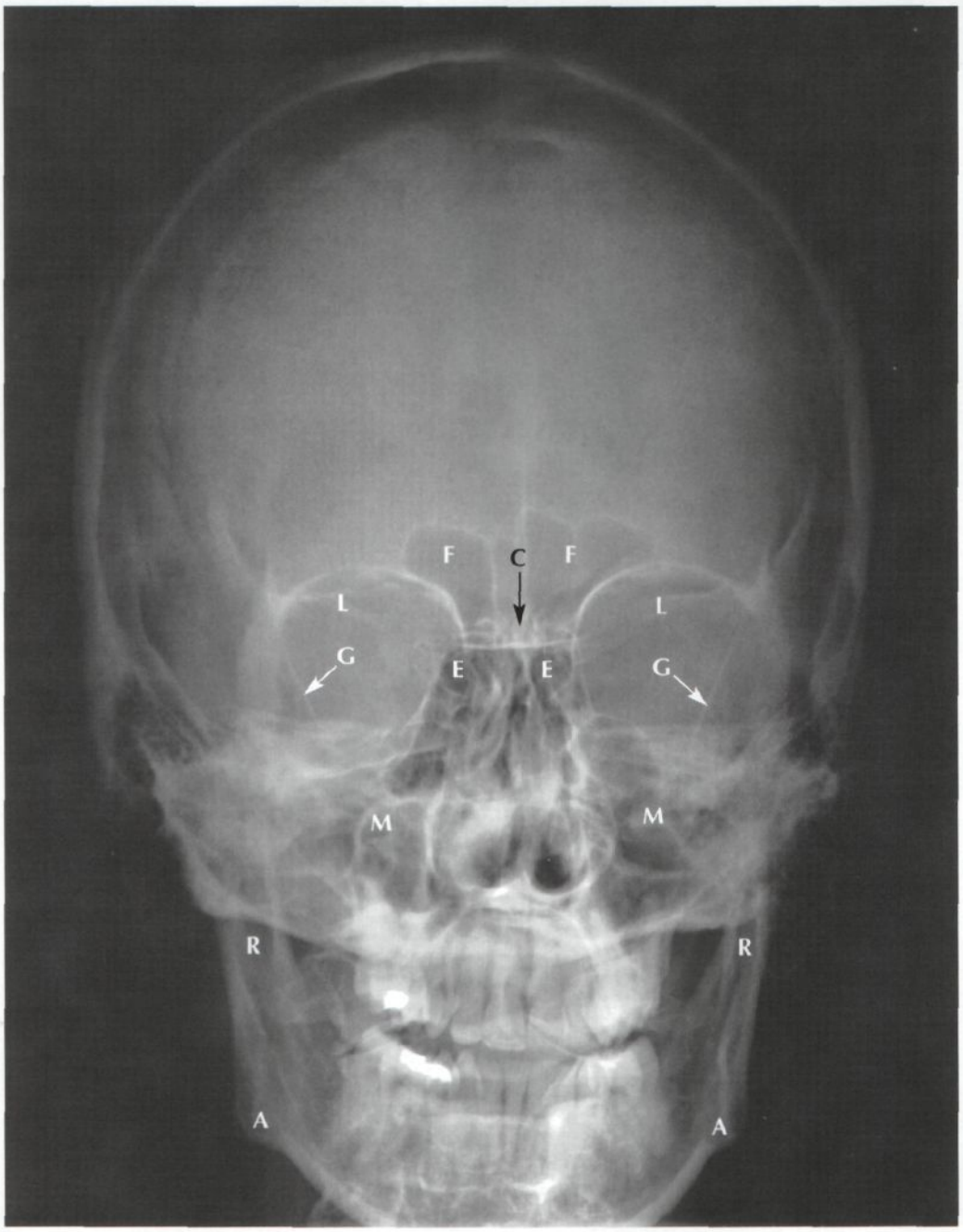

A Angle of mandible
C *Crista galli*
E Ethmoid sinus
F Frontal sinus
G Greater wing of sphenoid
L Lesser wing of sphenoid
M Maxillary sinus
R Ramus of mandible

Skull: Lateral View

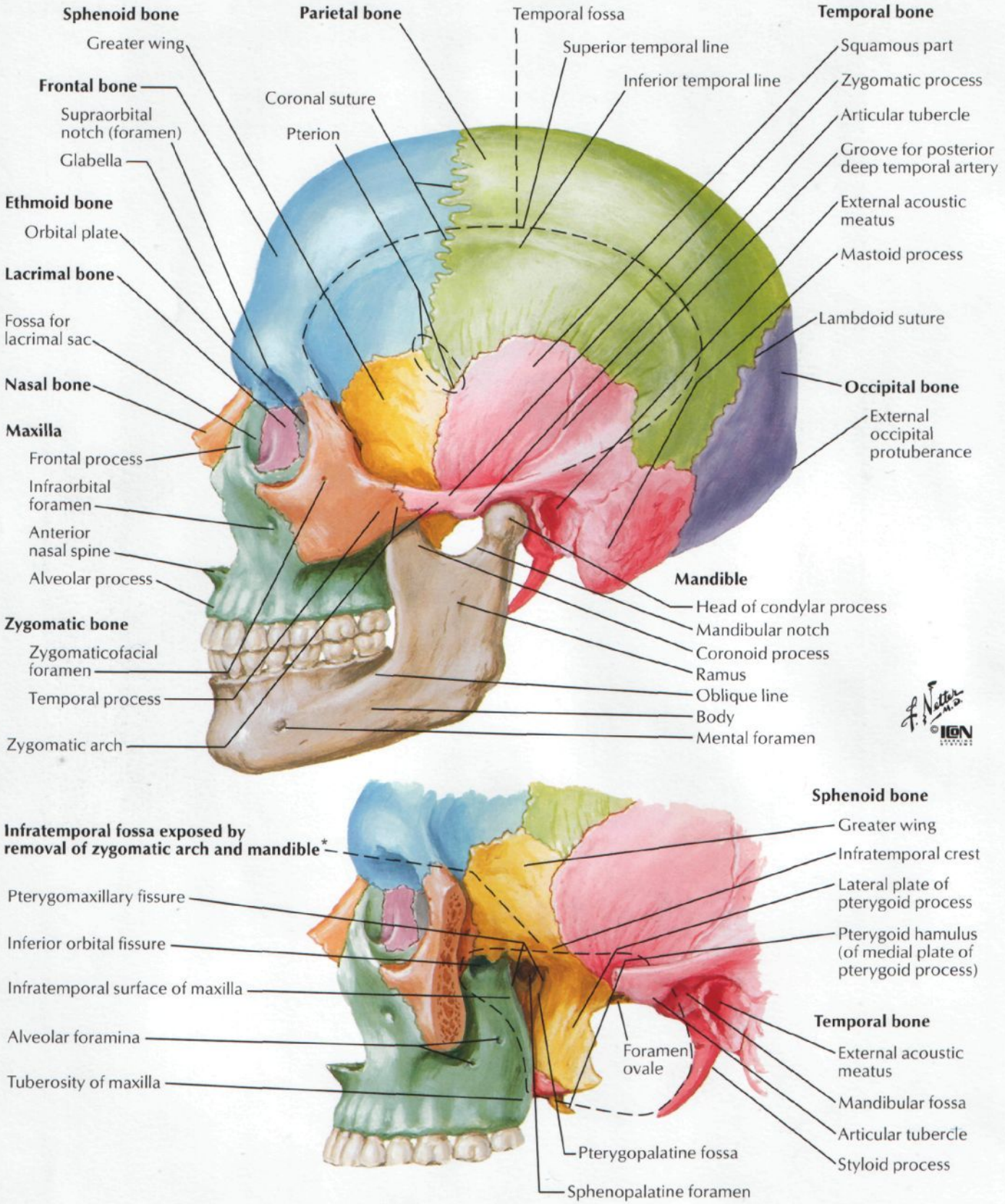

*Superficially, mastoid process forms posterior boundary

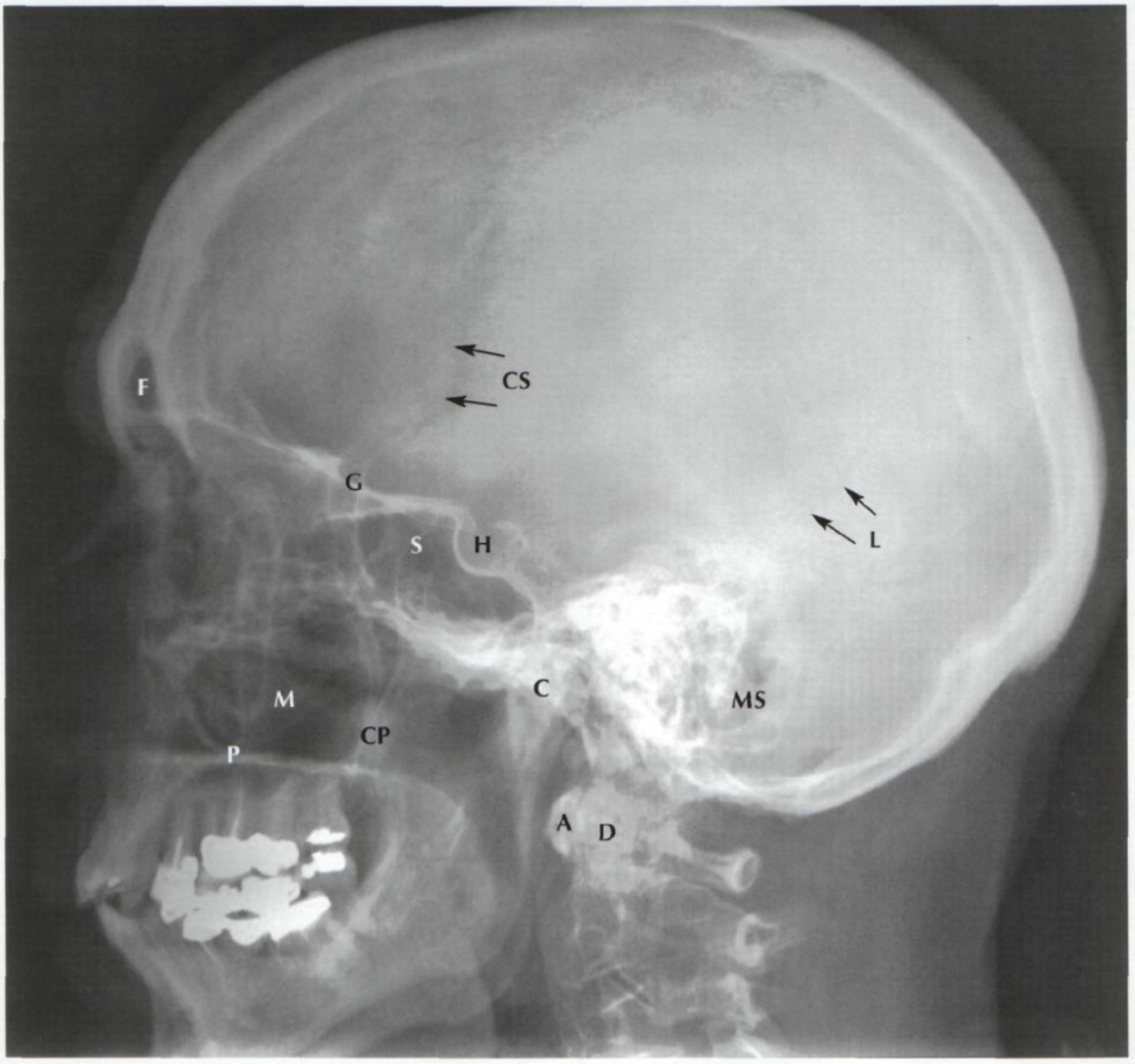

A Anterior arch of atlas (CI vertebra)
C Condyle of mandible
CP Coronoid process of mandible
CS Coronal suture
D Dens of axis (C2 vertebra)
F Frontal sinus
G Greater wing of sphenoid
H Hypophyseal fossa
L Lambdoid suture
M Maxillary sinus
MS Mastoid air cells
P Palatine process of maxilla
S Sphenoid sinus

Skull: Midsagittal Section

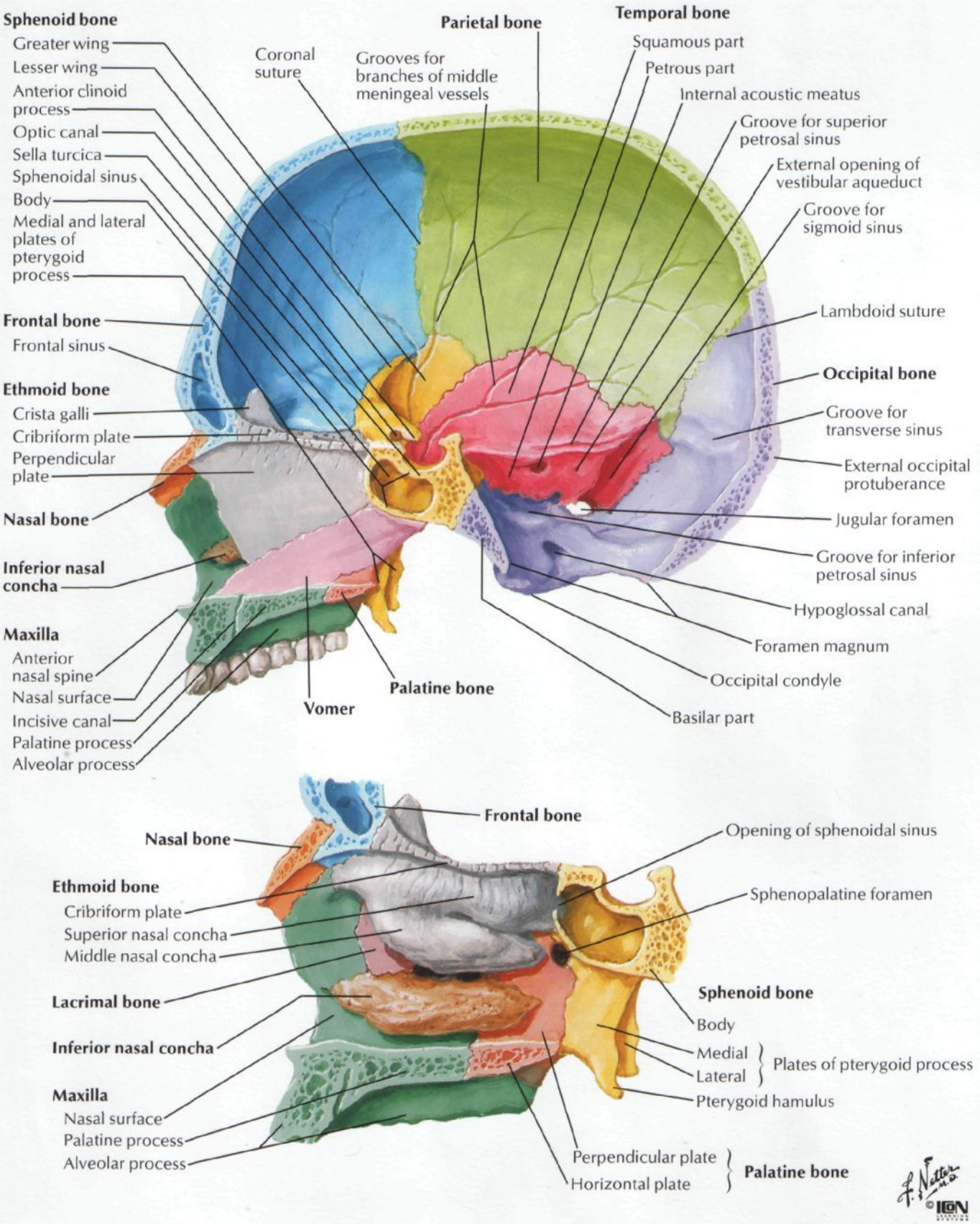

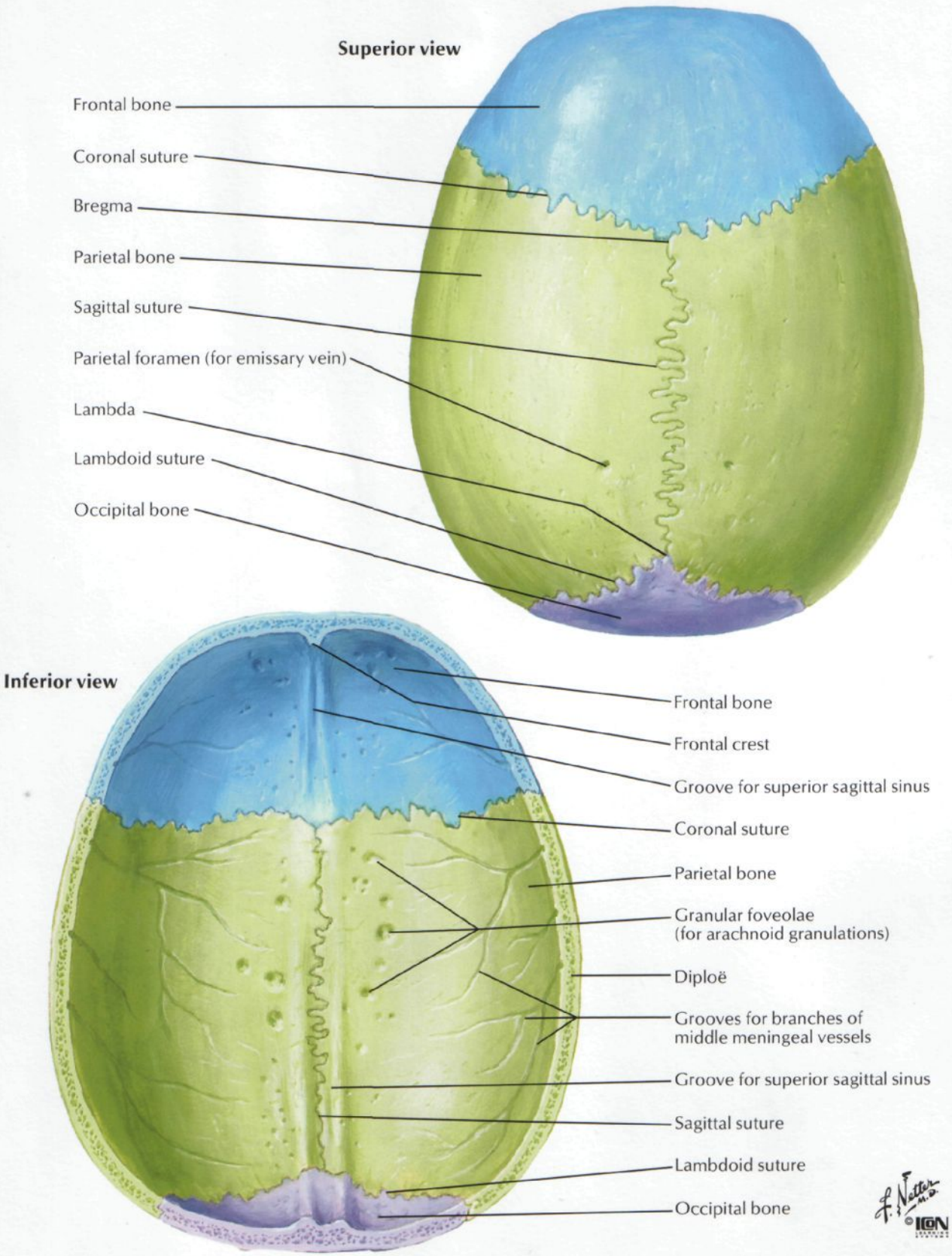
Superior view
Frontal bone
Coronal suture
Bregma
Parietal bone
Sagittal suture
Parietal foramen (for emissary vein)
Lambda
Lambdoid suture
Occipital bone
Inferior view
Frontal bone
Frontal crest
Groove for superior sagittal sinus
Coronal suture
Parietal bone
Granular foveolae
(for arachnoid granulations)
Diploë
Grooves for branches of
middle meningeal vessels
Groove for superior sagittal sinus
Sagittal suture
Lambdoid suture
Occipital bone

Cranial Base: Inferior View

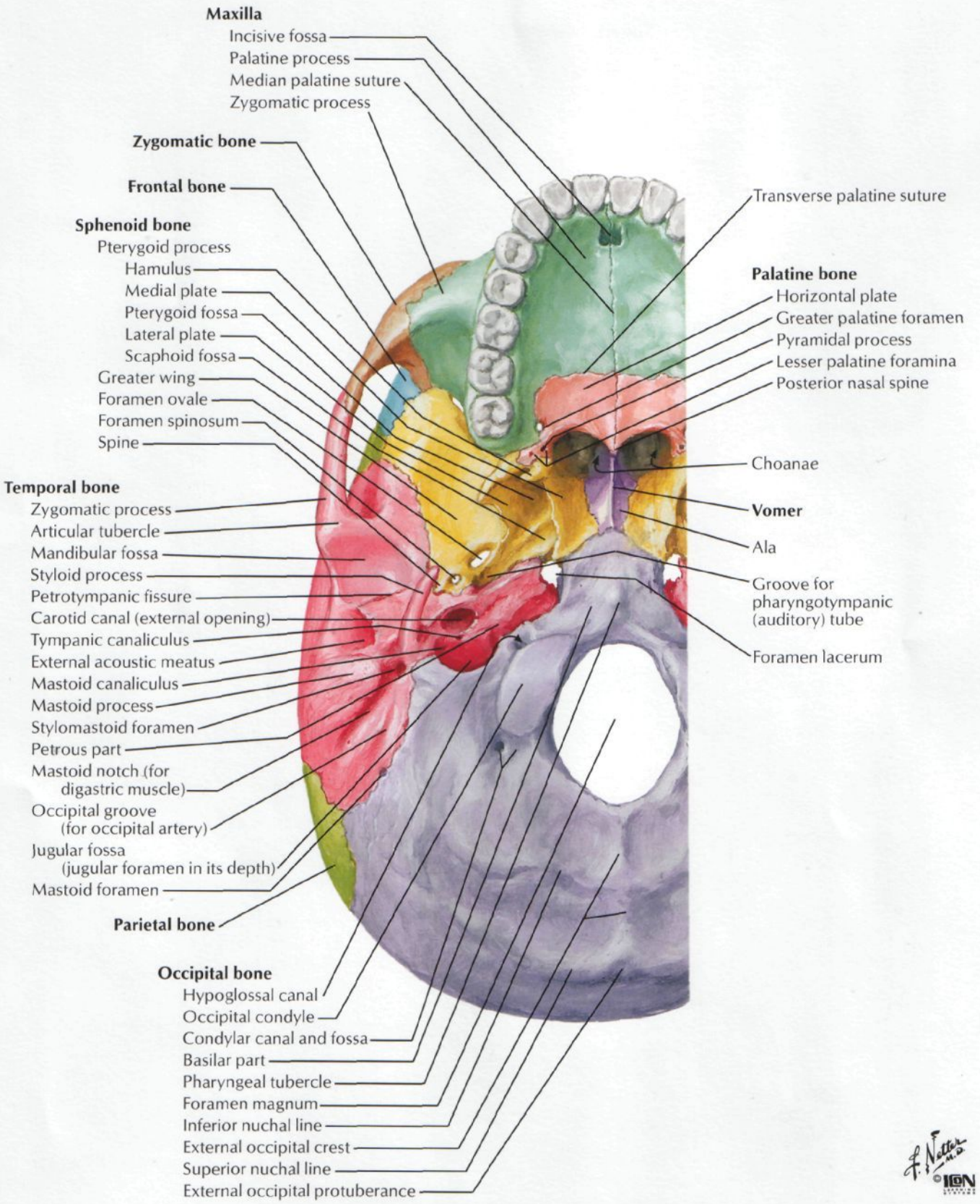

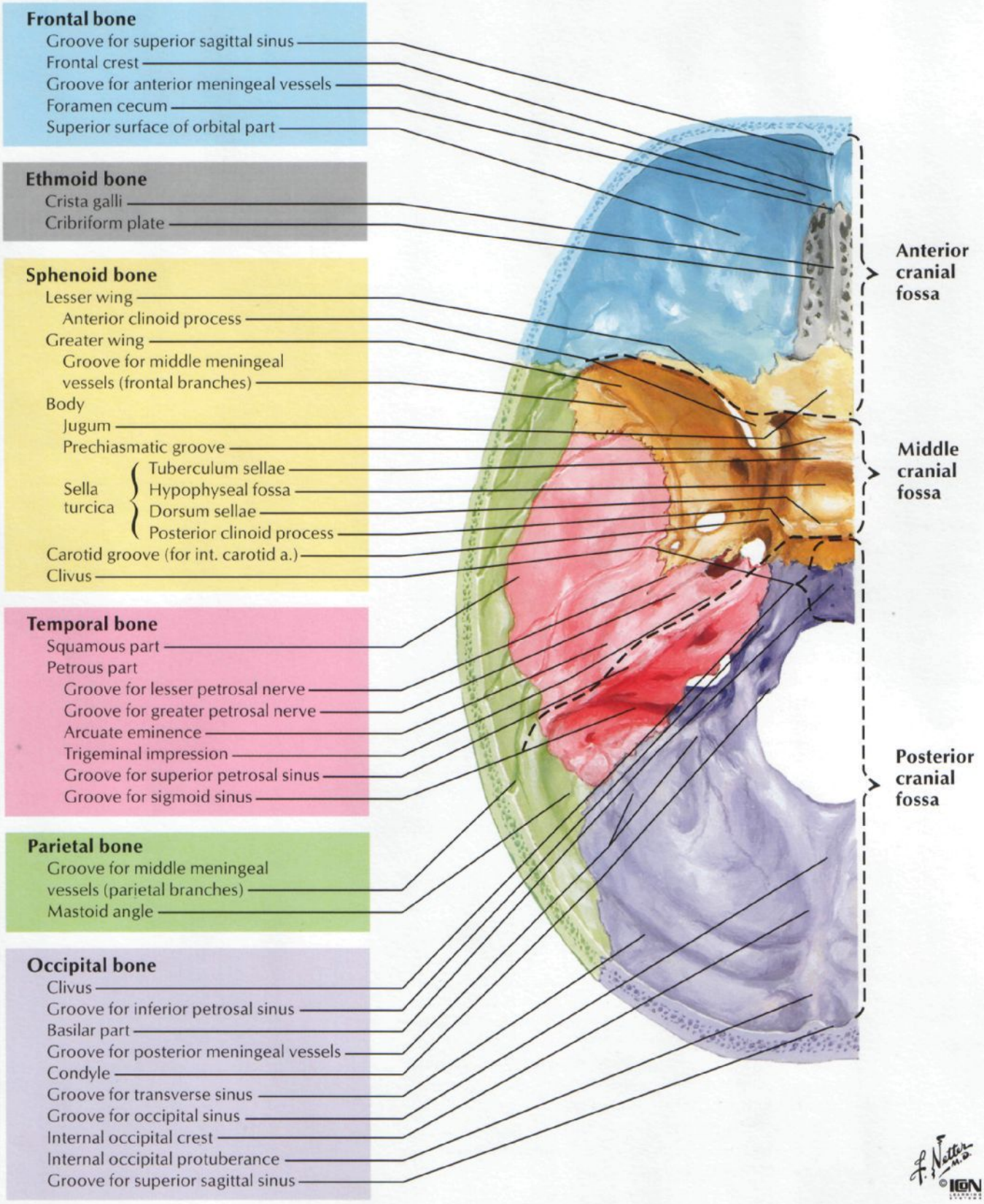
Frontal bone
Groove for superior sagittal sinus
Frontal crest
Groove for anterior meningeal vessels
Foramen cecum
Superior surface of orbital part
Ethmoid bone
Crista galli
Cribriform plate
Sphenoid bone
Lesser wing
Anterior clinoid process
Greater wing
Groove for middle meningeal vessels (frontal branches)
Body
Jugum
Prechiasmatic groove
Sella turcica
Tuberculum sellae
Hypophyseal fossa
Dorsum sellae
Posterior clinoid process
Carotid groove (for int. carotid a.)
Clivus
Temporal bone
Squamous part
Petrous part
Groove for lesser petrosal nerve
Groove for greater petrosal nerve
Arcuate eminence
Trigeminal impression
Groove for superior petrosal sinus
Groove for sigmoid sinus
Parietal bone
Groove for middle meningeal vessels (parietal branches)
Mastoid angle
Occipital bone
Clivus
Groove for inferior petrosal sinus
Basilar part
Groove for posterior meningeal vessels
Condyle
Groove for transverse sinus
Groove for occipital sinus
Internal occipital crest
Internal occipital protuberance
Groove for superior sagittal sinus
Anterior cranial fossa
Middle cranial fossa
Posterior cranial fossa

Foramina of Cranial Base: Superior View

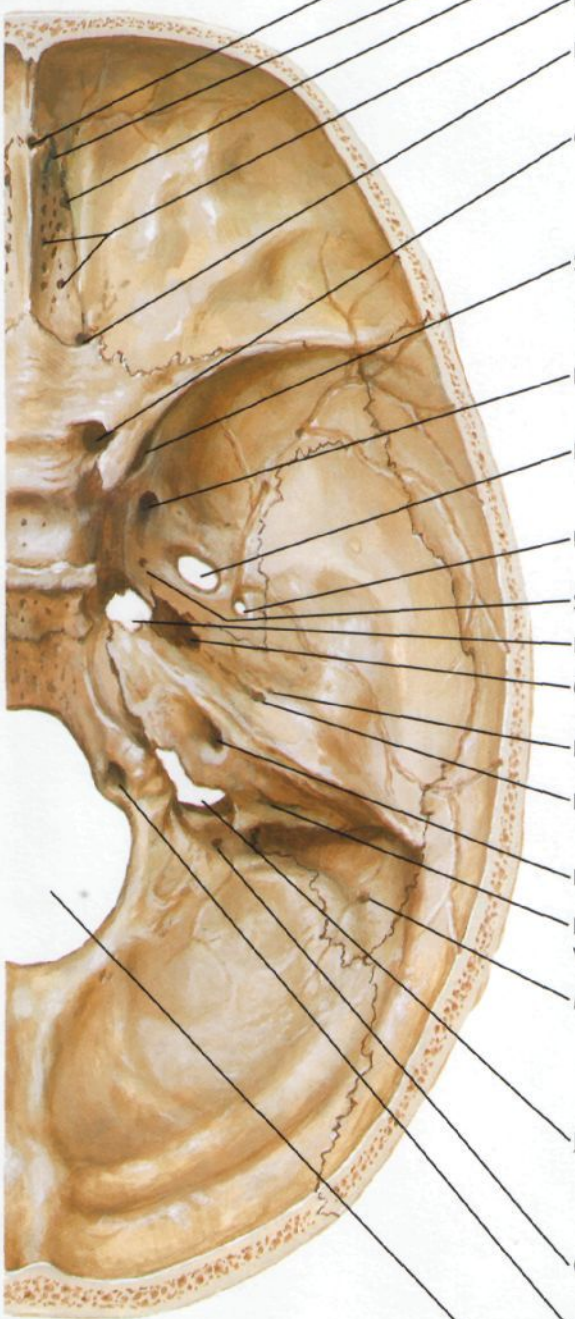

- Foramen cecum — Emissary vein to superior sagittal sinus
- Nasal slit, Anterior ethmoidal foramen — Anterior ethmoidal artery, vein and nerve
- Foramina of cribriform plate — Olfactory nerve bundles
- Posterior ethmoidal foramen — Posterior ethmoidal artery, vein and nerve
- Optic canal — Optic nerve (II), Ophthalmic artery
- Superior orbital fissure — Oculomotor nerve (III), Trochlear nerve (IV), Lacrimal, frontal and nasociliary branches of ophthalmic nerve (V_1), Abducent nerve (VI), Superior ophthalmic vein
- Foramen rotundum — Maxillary nerve (V_2)
- Foramen ovale — Mandibular nerve (V_3), Accessory meningeal artery, Lesser petrosal nerve (occasionally)
- Foramen spinosum — Middle meningeal artery and vein, Meningeal branch of mandibular nerve
- Sphenoid emissary foramen (Vesalius) (inconstant)
- Foramen lacerum
- Carotid canal for — Internal carotid artery, Internal carotid nerve plexus
- Hiatus for — Lesser petrosal nerve
- Hiatus for — Greater petrosal nerve
- Internal acoustic meatus — Facial nerve (VII), Vestibulocochlear nerve (VIII), Labyrinthine artery
- External opening of vestibular aqueduct — Endolymphatic duct
- Mastoid foramen (inconstant) — Emissary vein (and occasional branch of occipital artery)
- Jugular foramen — Inferior petrosal sinus, Glossopharyngeal nerve (IX), Vagus nerve (X), Accessory nerve (XI), Sigmoid sinus, Posterior meningeal artery
- Condylar canal (inconstant) — Emissary vein and meningeal branch of ascending pharyngeal artery
- Hypoglossal canal — Hypoglossal nerve (XII)
- Foramen magum — Medulla oblongata, Meninges, Vertebral arteries, Meningeal branches of vertebral arteries, Spinal roots of accessory nerves

F. Netter, M.D. © IGN

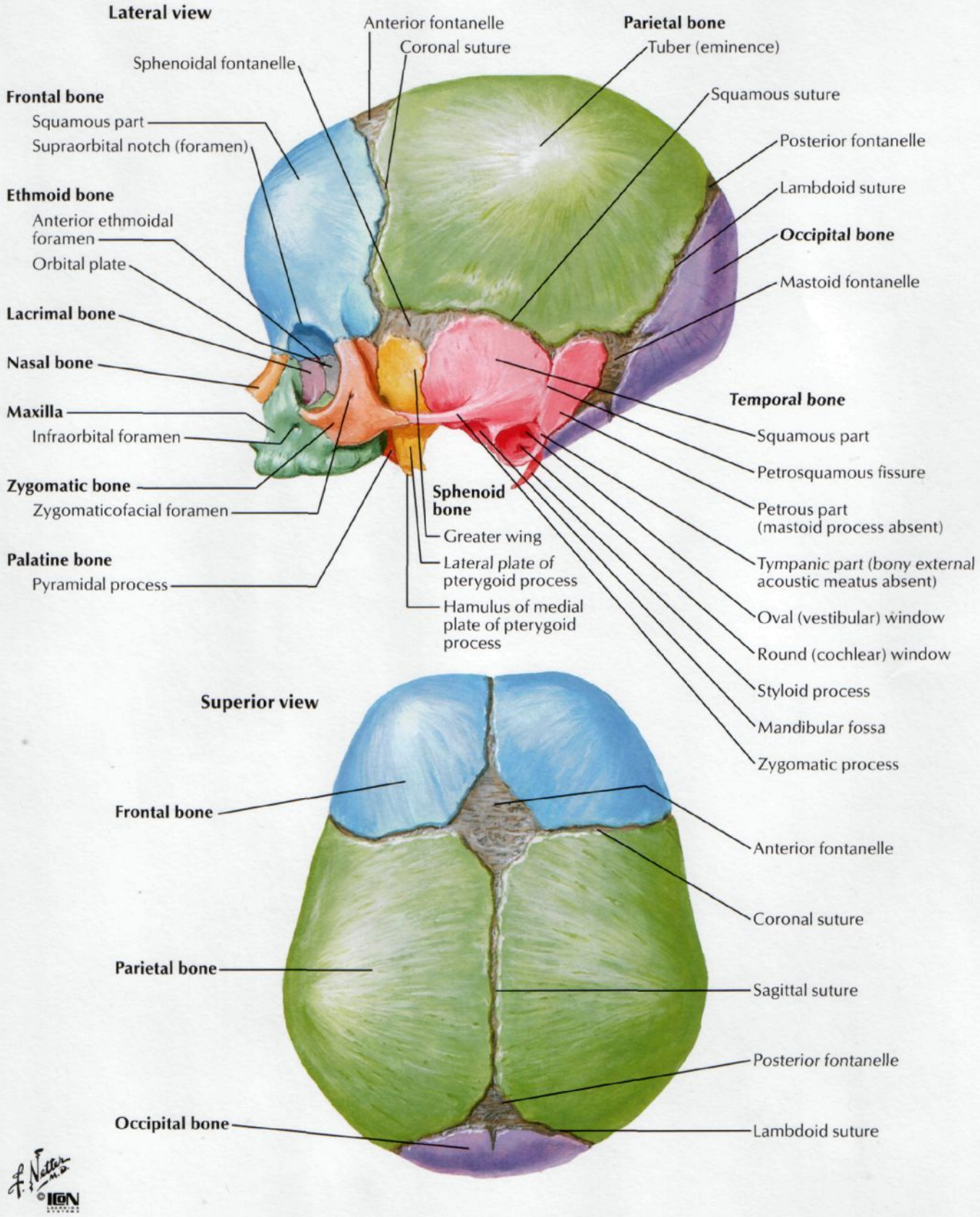
Lateral view
Anterior fontanelle
Coronal suture
Parietal bone
Tuber (eminence)
Sphenoidal fontanelle
Squamous suture
Frontal bone
Squamous part
Supraorbital notch (foramen)
Posterior fontanelle
Lambdoid suture
Ethmoid bone
Anterior ethmoidal foramen
Occipital bone
Orbital plate
Mastoid fontanelle
Lacrimal bone
Nasal bone
Temporal bone
Squamous part
Maxilla
Infraorbital foramen
Petrosquamous fissure
Petrous part (mastoid process absent)
Zygomatic bone
Zygomaticofacial foramen
Sphenoid bone
Tympanic part (bony external acoustic meatus absent)
Greater wing
Palatine bone
Lateral plate of pterygoid process
Pyramidal process
Oval (vestibular) window
Hamulus of medial plate of pterygoid process
Round (cochlear) window
Styloid process
Mandibular fossa
Zygomatic process
Superior view
Frontal bone
Anterior fontanelle
Coronal suture
Parietal bone
Sagittal suture
Posterior fontanelle
Occipital bone
Lambdoid suture

Bony Framework of Head and Neck

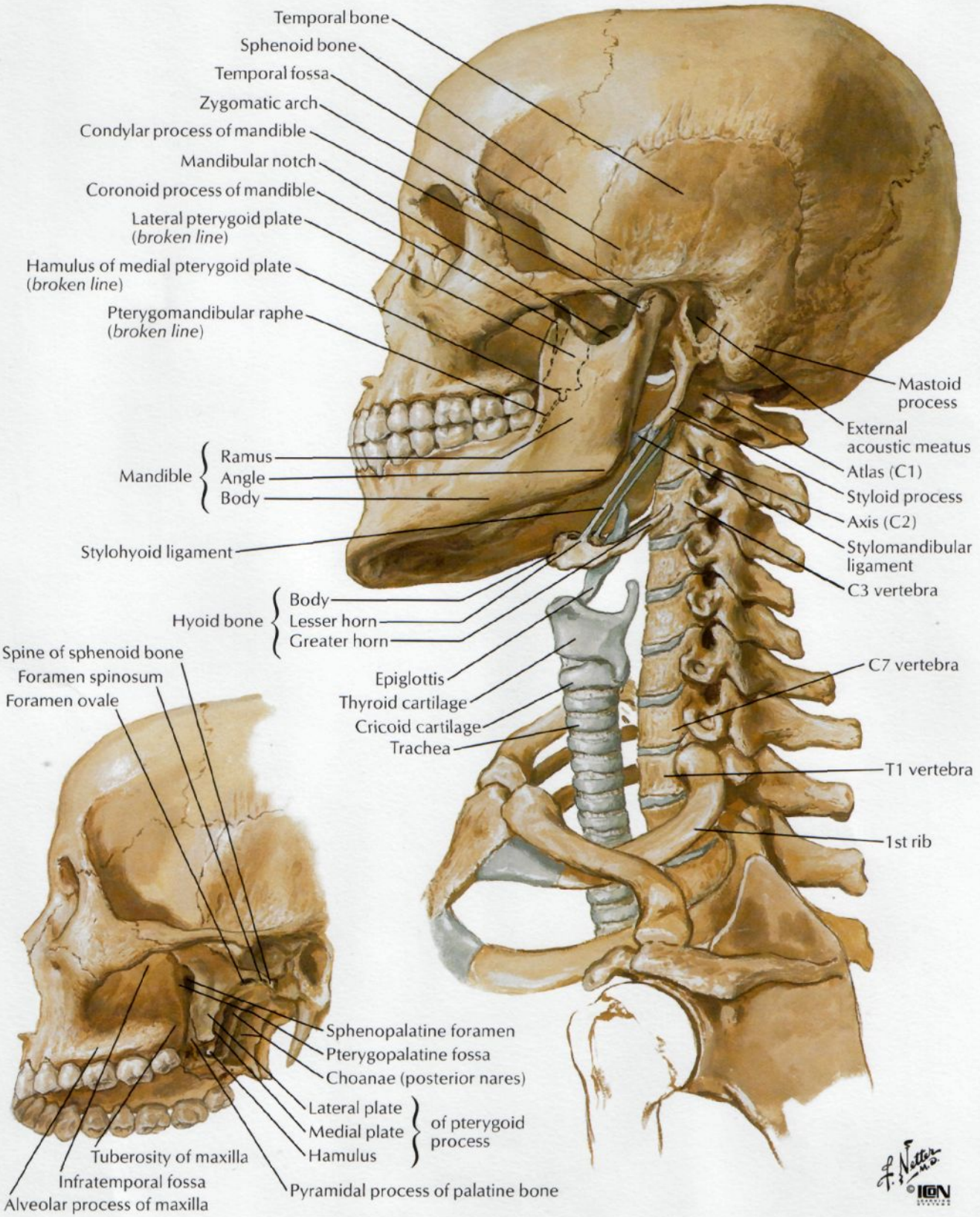

Mandible of infant

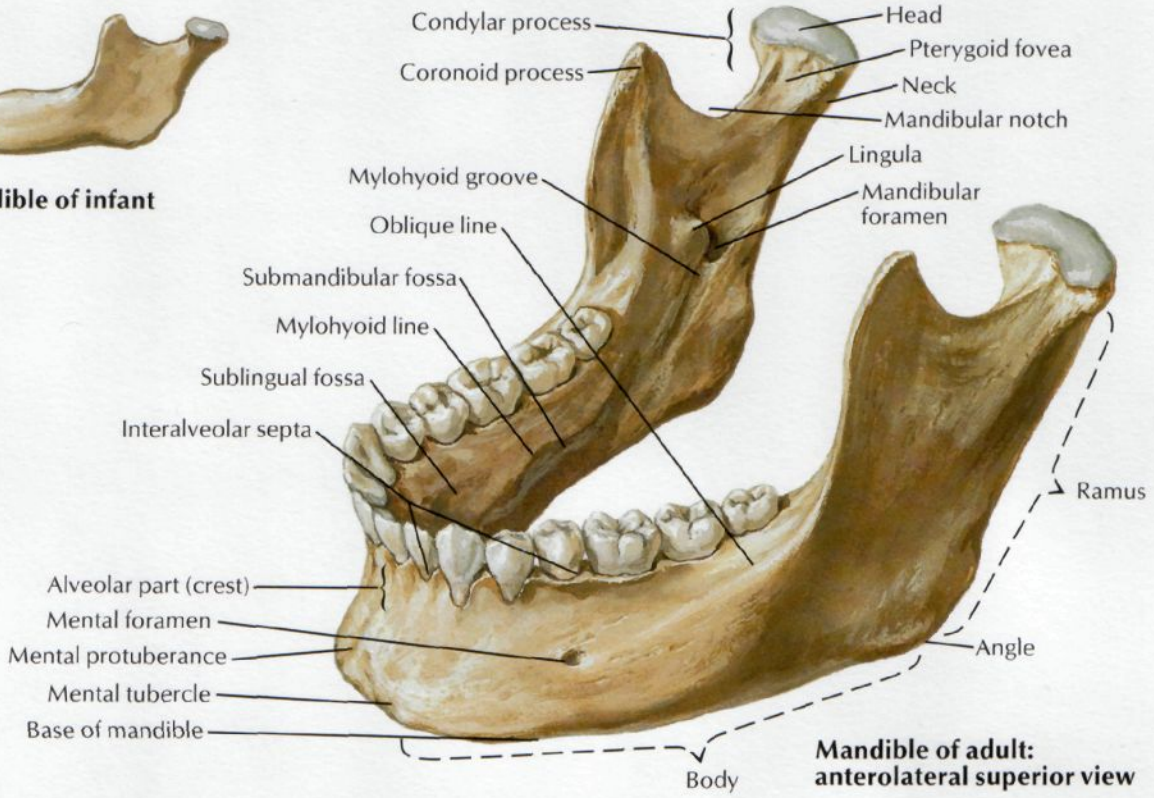

Mandible of adult: anterolateral superior view

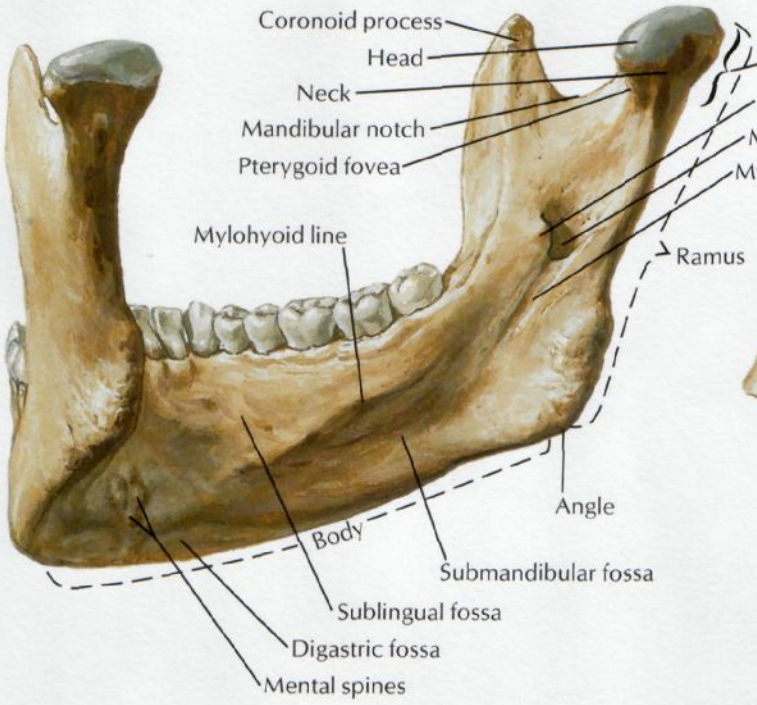

Mandible of adult: left posterior view

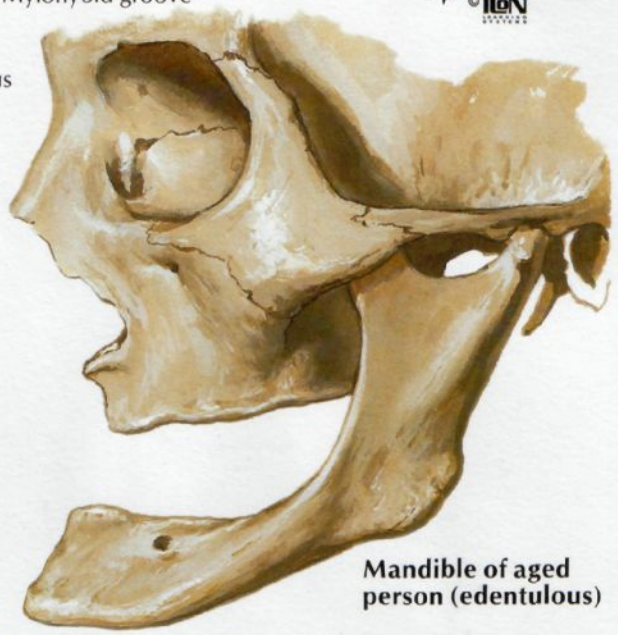

Mandible of aged person (edentulous)

Temporomandibular Joint

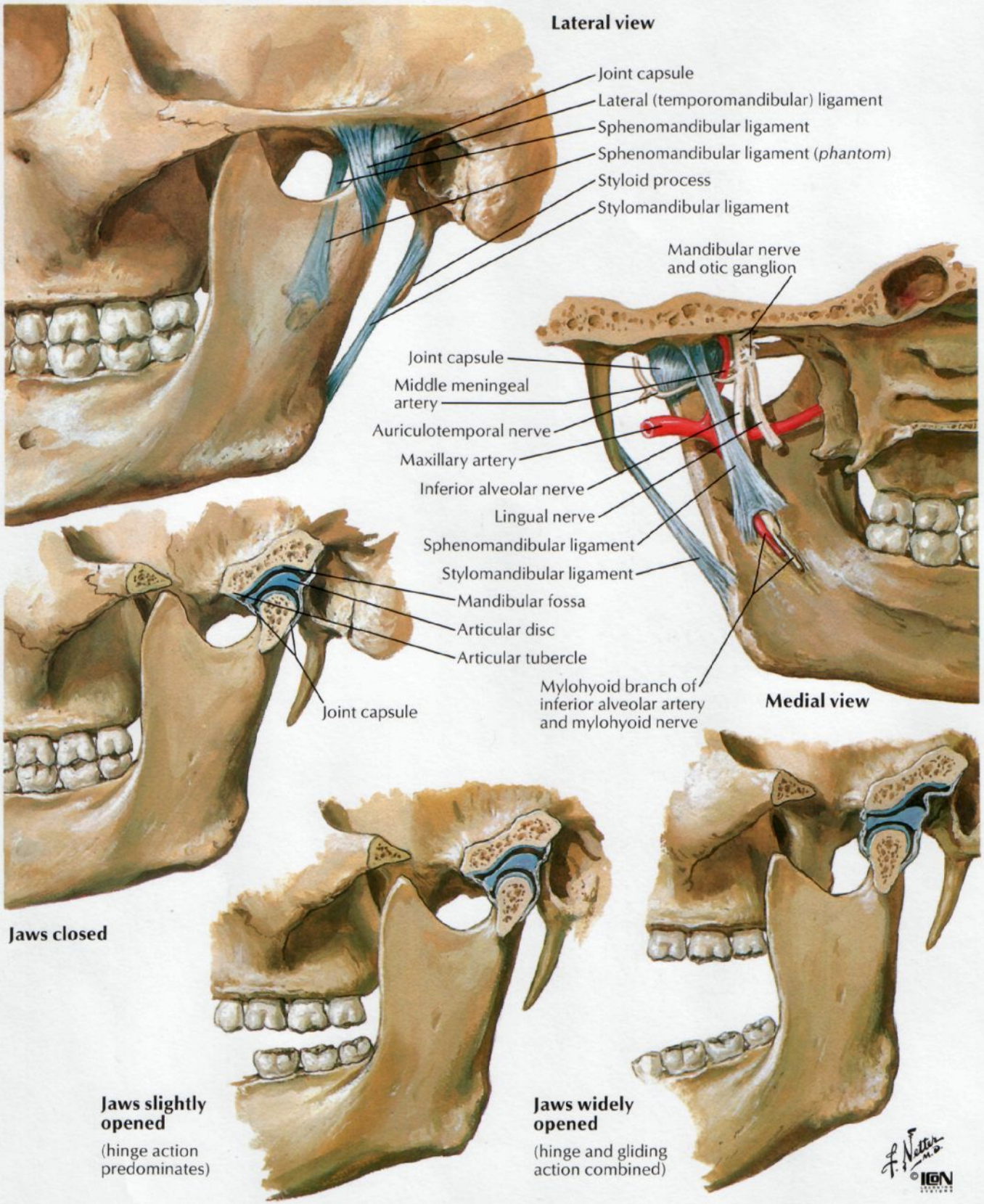

SEE ALSO PLATES 12, 146

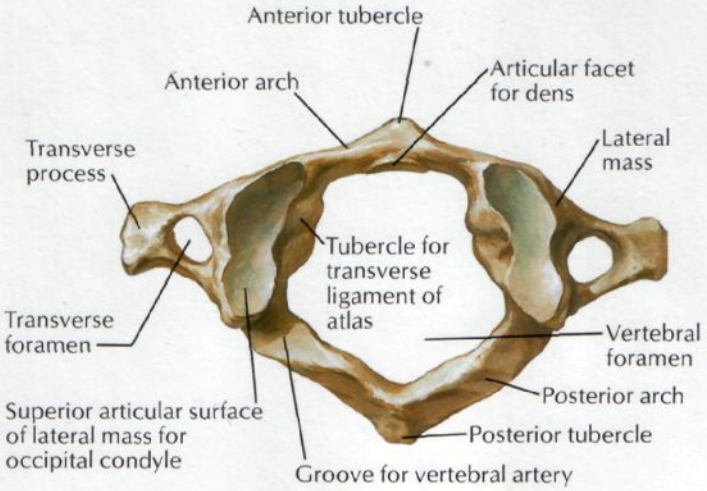

Atlas (C1): superior view

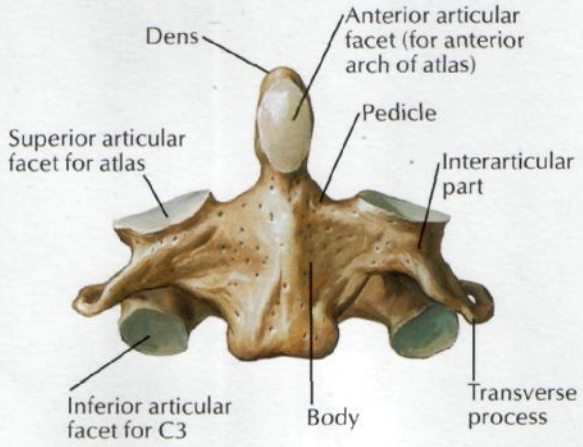

Axis (C2): anterior view

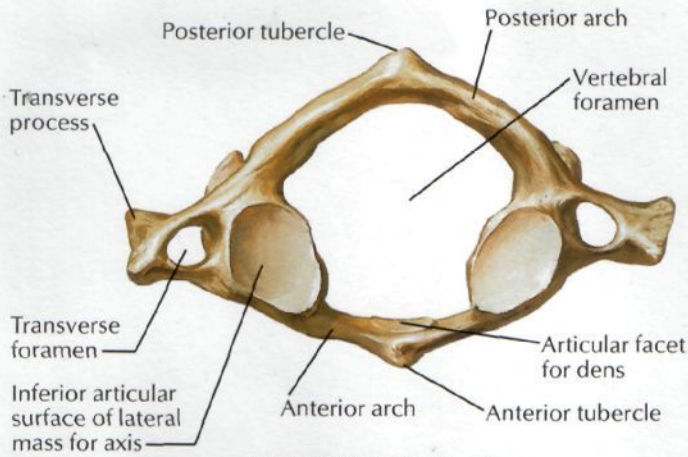

Atlas (C1): inferior view

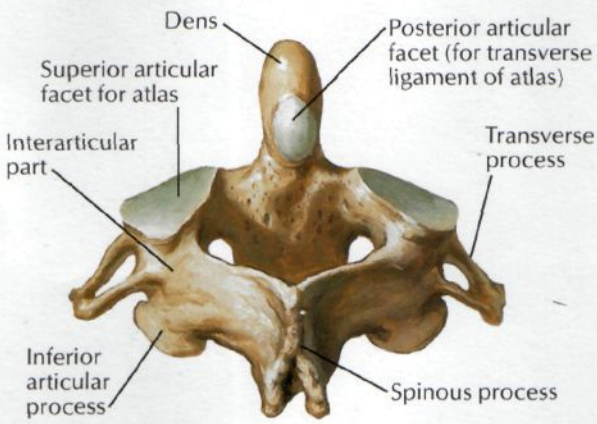

Axis (C2): posterosuperior view

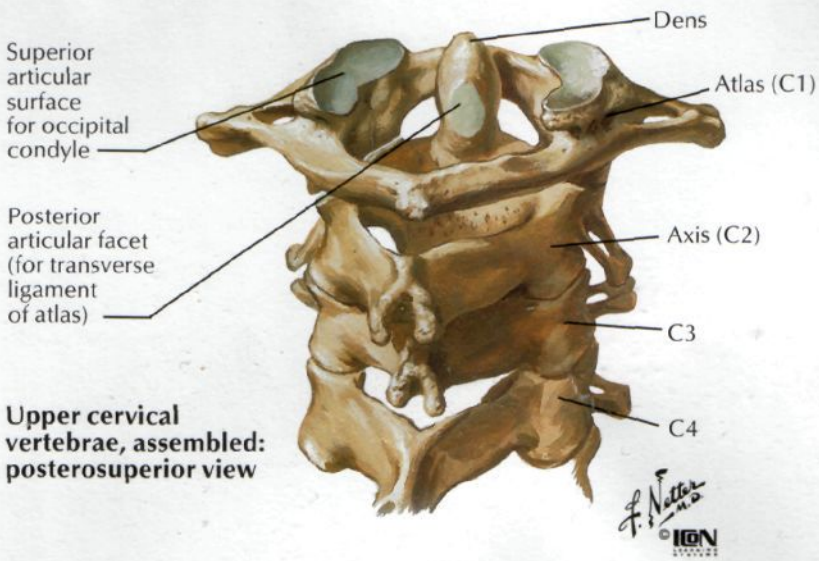

Upper cervical vertebrae, assembled: posterosuperior view

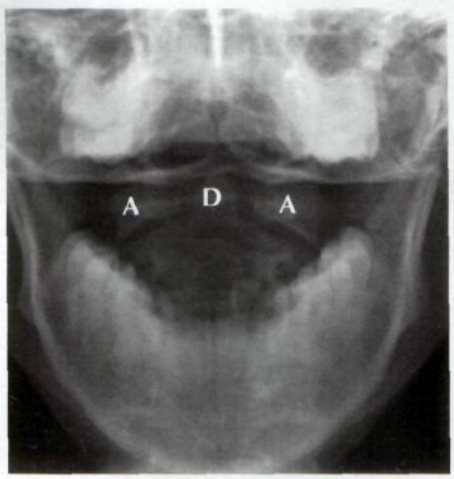

Radiograph of atlantoaxial joint

A Lateral masses of atlas (CI vertebra)
D Dens of axis (C2 vertebra)

Cervical Vertebrae (continued)

SEE ALSO PLATES 12, 146

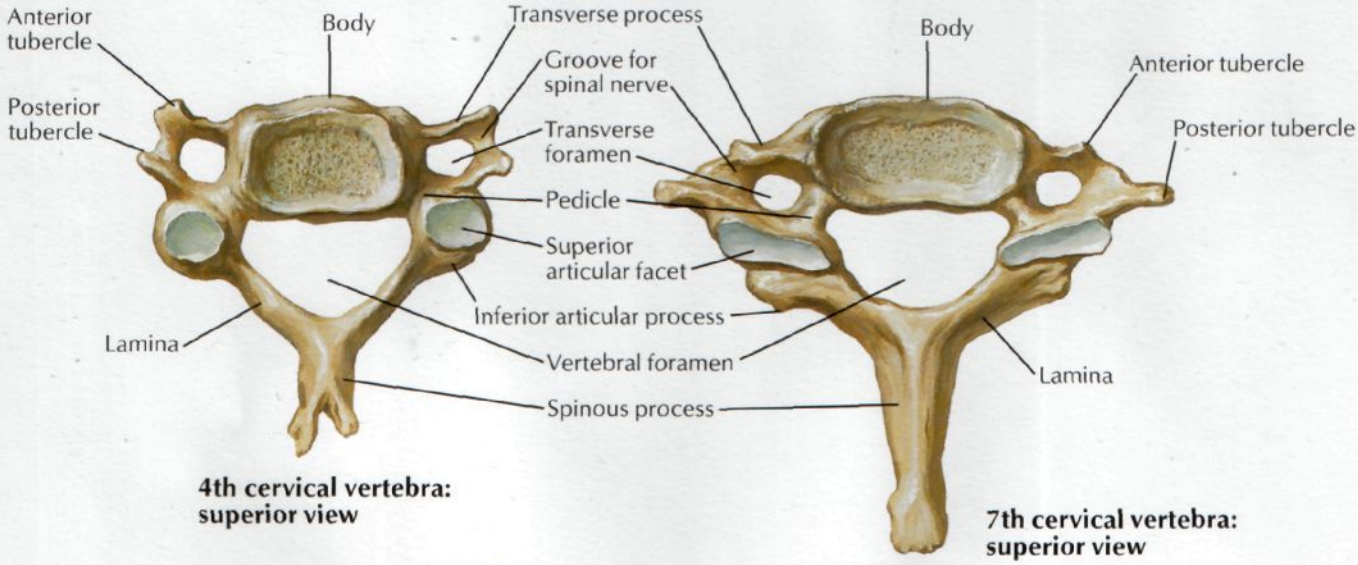

4th cervical vertebra: superior view

7th cervical vertebra: superior view

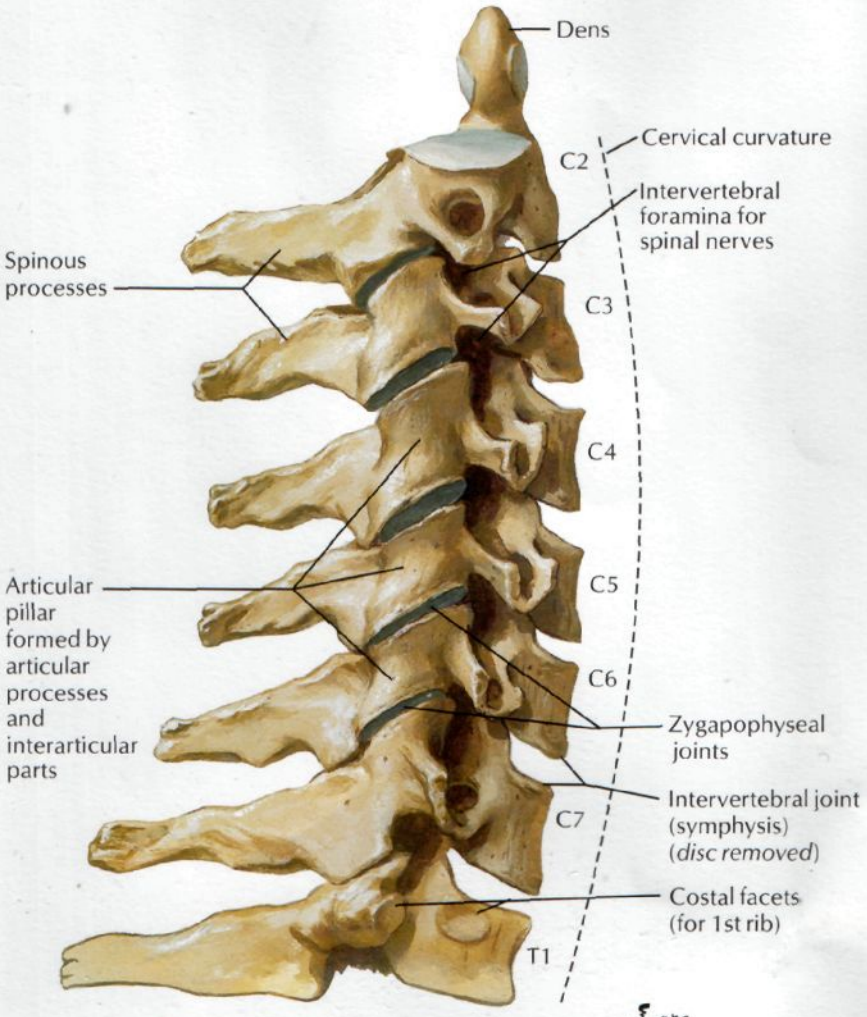

2nd cervical to 1st thoracic vertebrae: right lateral view

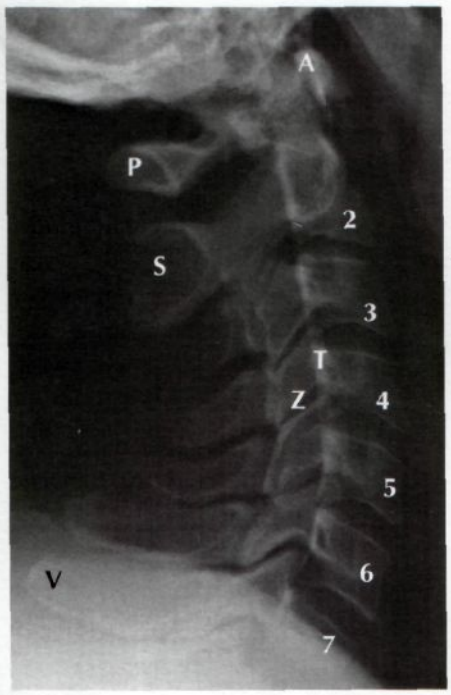

Cervical vertebrae: lateral radiograph

- **A** Anterior arch of atlas
- **P** Posterior arch of atlas
- **S** Spinous process
- **T** Transverse process
- **V** Vertebra prominens (spinous process of C7)
- **Z** Zygapophyseal joint

Bodies of 2–7 cervical vertebrae are numbered

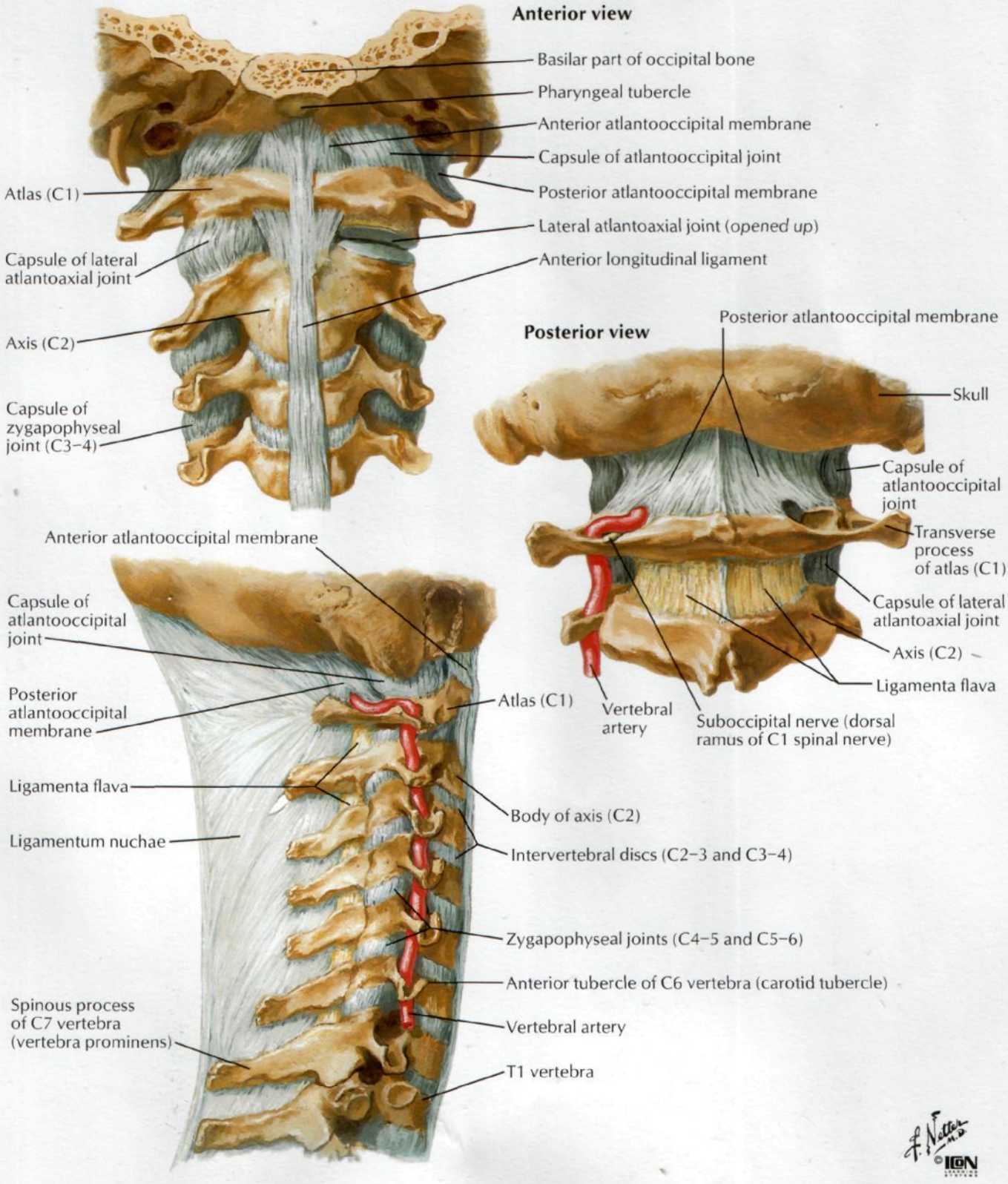
Anterior view
Basilar part of occipital bone
Pharyngeal tubercle
Anterior atlantooccipital membrane
Capsule of atlantooccipital joint
Posterior atlantooccipital membrane
Lateral atlantoaxial joint (opened up)
Anterior longitudinal ligament
Atlas (C1)
Capsule of lateral atlantoaxial joint
Axis (C2)
Capsule of zygapophyseal joint (C3–4)
Posterior view
Posterior atlantooccipital membrane
Skull
Capsule of atlantooccipital joint
Transverse process of atlas (C1)
Capsule of lateral atlantoaxial joint
Axis (C2)
Ligamenta flava
Vertebral artery
Suboccipital nerve (dorsal ramus of C1 spinal nerve)
Anterior atlantooccipital membrane
Capsule of atlantooccipital joint
Posterior atlantooccipital membrane
Atlas (C1)
Ligamenta flava
Ligamentum nuchae
Body of axis (C2)
Intervertebral discs (C2–3 and C3–4)
Zygapophyseal joints (C4–5 and C5–6)
Anterior tubercle of C6 vertebra (carotid tubercle)
Spinous process of C7 vertebra (vertebra prominens)
Vertebral artery
T1 vertebra
Right lateral view

Internal Craniocervical Ligaments

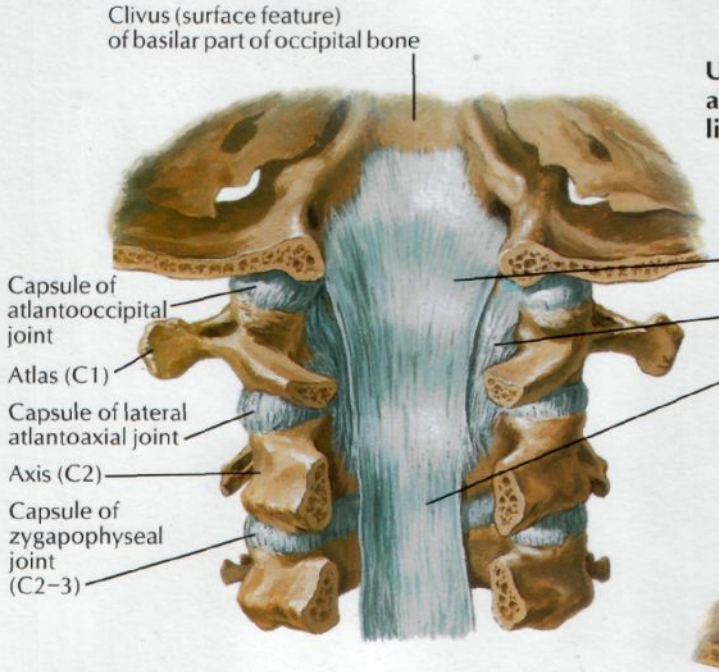

Upper part of vertebral canal with spinous processes and parts of vertebral arches removed to expose ligaments on posterior vertebral bodies: posterior view

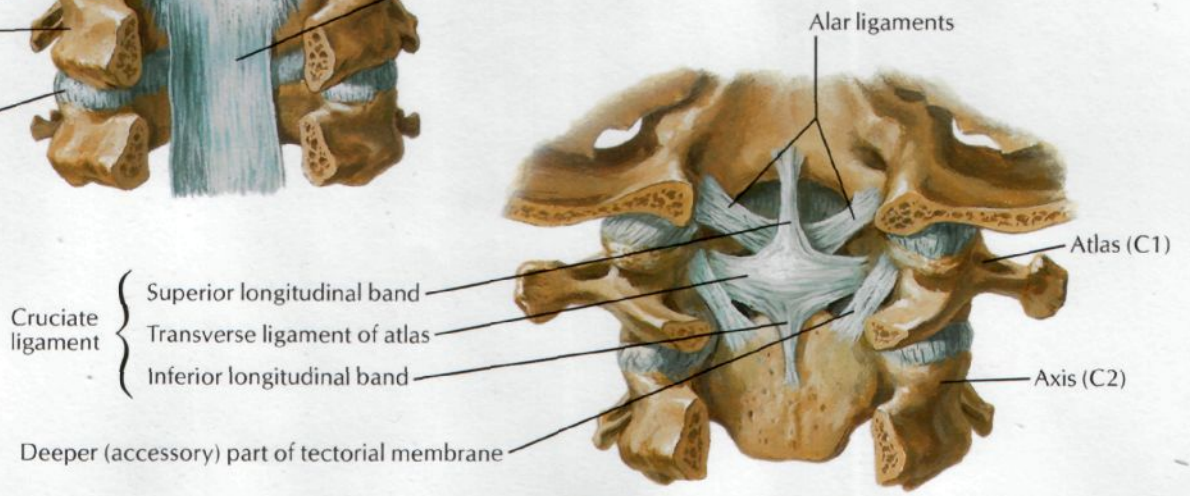

Principal part of tectorial membrane removed to expose deeper ligaments: posterior view

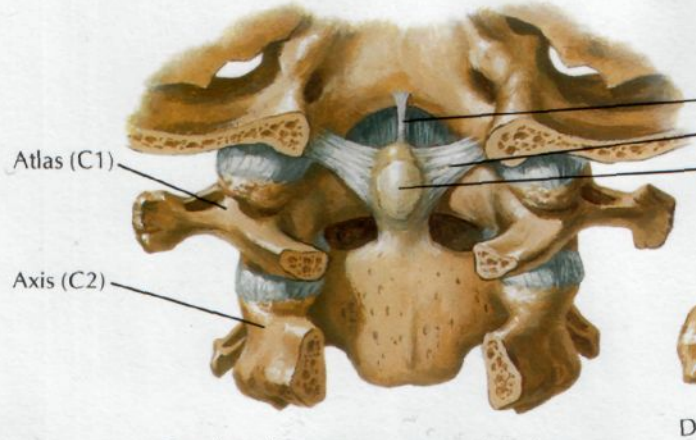

Cruciate ligament removed to show deepest ligaments: posterior view

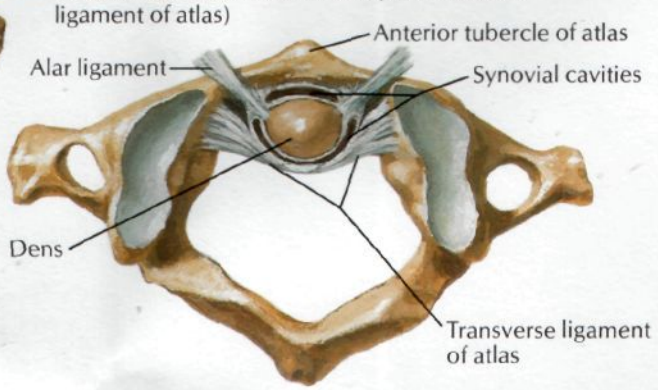

Median atlantoaxial joint: superior view

F. Netter M.D. ©ICON

Superficial Arteries and Veins of Face and Scalp

SEE ALSO PLATES 30, 36, 65, 66, 81, 98

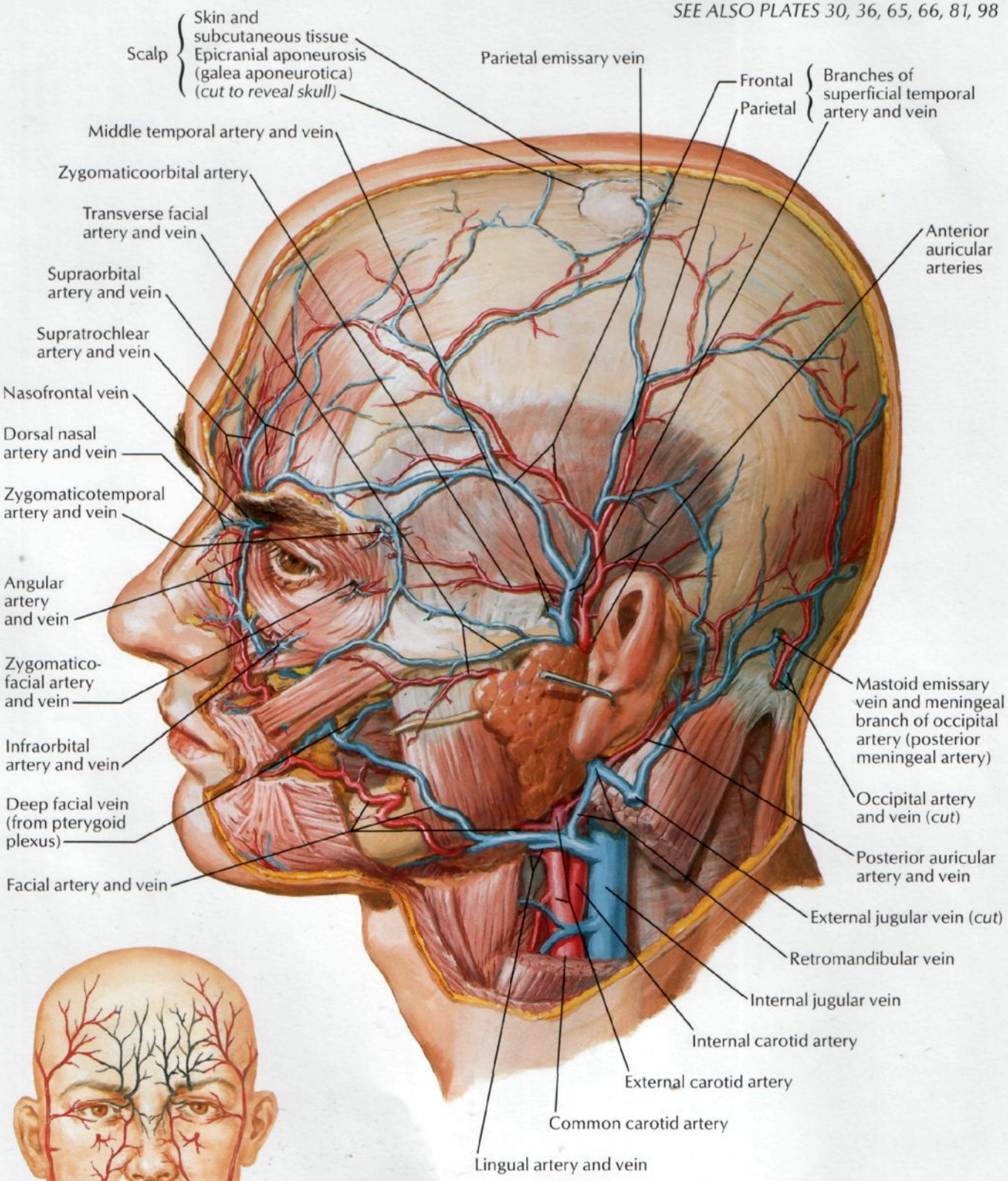

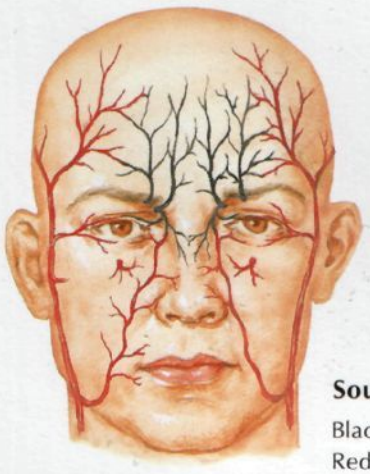

Sources of arterial supply of face

Black: from internal carotid artery (via ophthalmic artery)
Red: from external carotid artery

F. Netter M.D. ©IGN

Cutaneous Nerves of Head and Neck

SEE ALSO PLATES 28, 32, 41, 42, 116

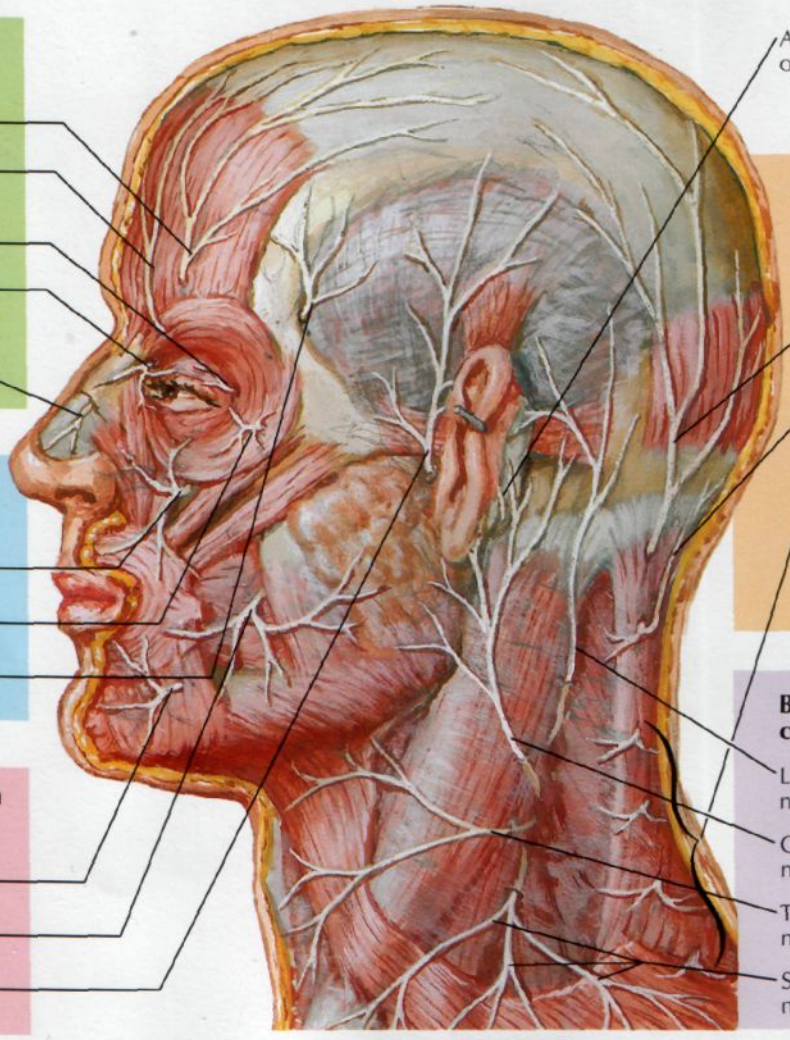

From ophthalmic division of trigeminal nerve (V_1)

- Supraorbital nerve
- Supratrochlear nerve
- Palpebral branch of lacrimal nerve
- Infratrochlear nerve
- External nasal branch of anterior ethmoidal nerve

From maxillary division of trigeminal nerve (V_2)

- Infraorbital nerve
- Zygomaticofacial nerve
- Zygomaticotemporal nerve

From mandibular division of trigeminal nerve (V_3)

- Mental nerve
- Buccal nerve
- Auriculotemporal nerve

- Auricular branch of vagus nerve (X)

Medial branches of dorsal rami of cervical spinal nerves

- Greater occipital nerve (C2)
- 3rd occipital nerve (C3)
- From 4th, 5th, 6th and 7th nerves in succession below

Branches from cervical plexus

- Lesser occipital nerve (C2, 3)
- Great auricular nerve (C2, 3)
- Transverse cervical nerve (C2, 3)
- Supraclavicular nerves (C3, 4)

Trigeminal nerve (V)

- **Ophthalmic nerve (V_1)**
- **Maxillary nerve (V_2)**
- **Mandibular nerve (V_3)**

- **Dorsal rami of cervical spinal nerves**
- Note: Auricular branch of vagus nerve to external acoustic meatus and small area on posteromedial surface of auricle
- **Branches from cervical plexus**

F. Netter M.D.
©ICON

Facial Nerve Branches and Parotid Gland

SEE ALSO PLATE 117

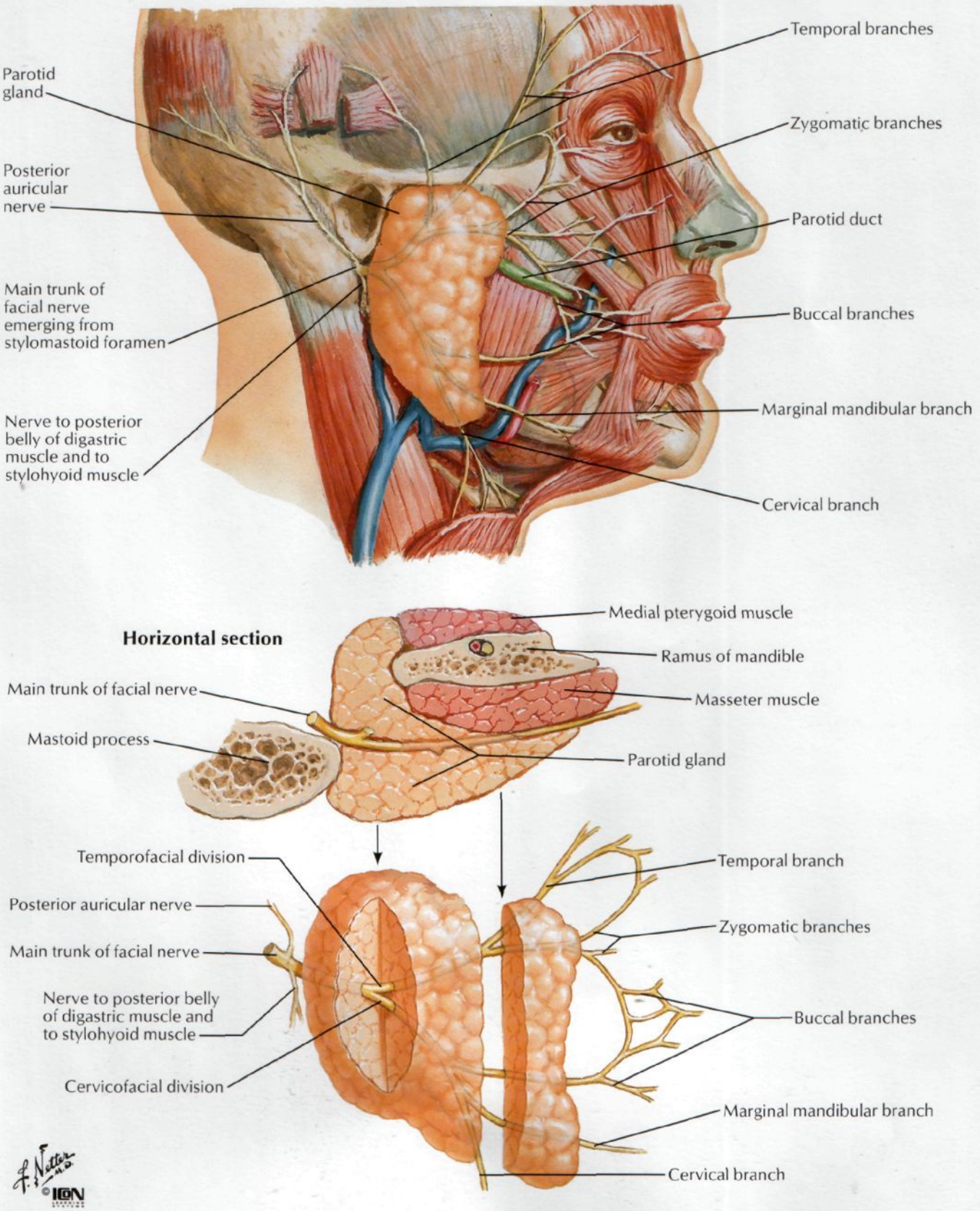

Muscles of Facial Expression: Lateral View

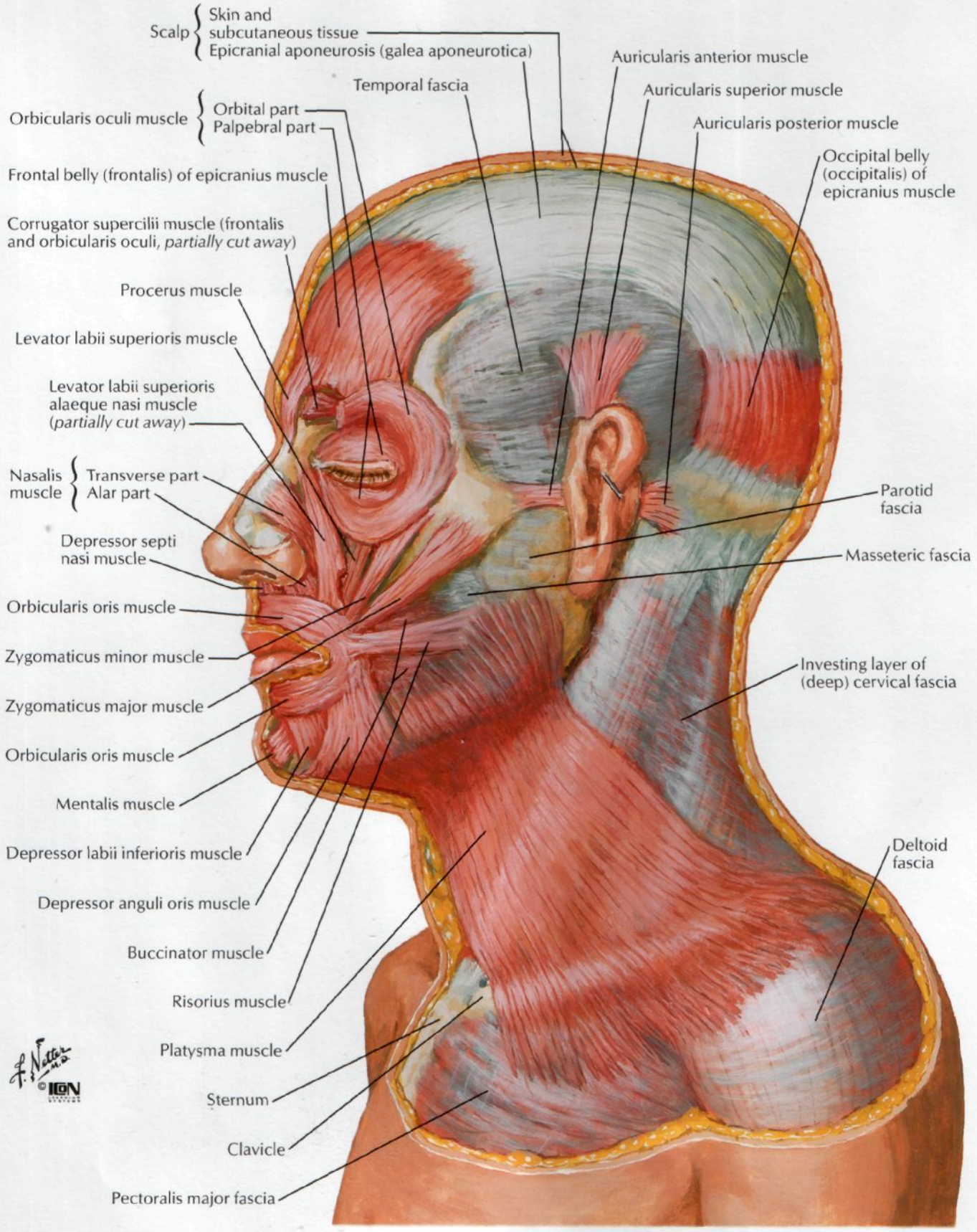

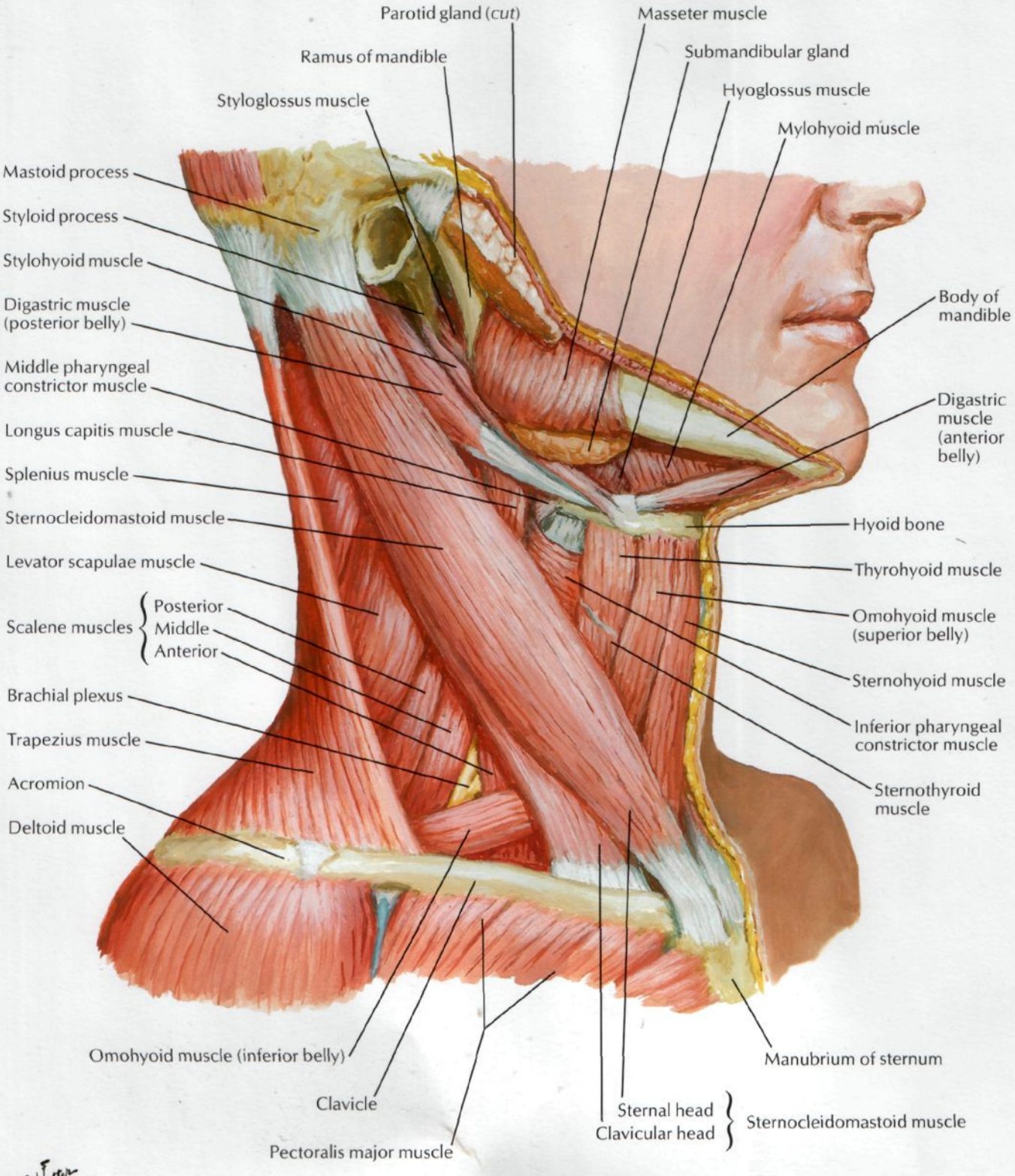
Parotid gland (*cut*)
Masseter muscle
Ramus of mandible
Submandibular gland
Styloglossus muscle
Hyoglossus muscle
Mylohyoid muscle
Mastoid process
Styloid process
Stylohyoid muscle
Digastric muscle (posterior belly)
Middle pharyngeal constrictor muscle
Longus capitis muscle
Splenius muscle
Sternocleidomastoid muscle
Levator scapulae muscle
Scalene muscles
Posterior
Middle
Anterior
Brachial plexus
Trapezius muscle
Acromion
Deltoid muscle
Body of mandible
Digastric muscle (anterior belly)
Hyoid bone
Thyrohyoid muscle
Omohyoid muscle (superior belly)
Sternohyoid muscle
Inferior pharyngeal constrictor muscle
Sternothyroid muscle
Omohyoid muscle (inferior belly)
Clavicle
Pectoralis major muscle
Manubrium of sternum
Sternal head
Clavicular head
Sternocleidomastoid muscle

Muscles of Neck: Anterior View

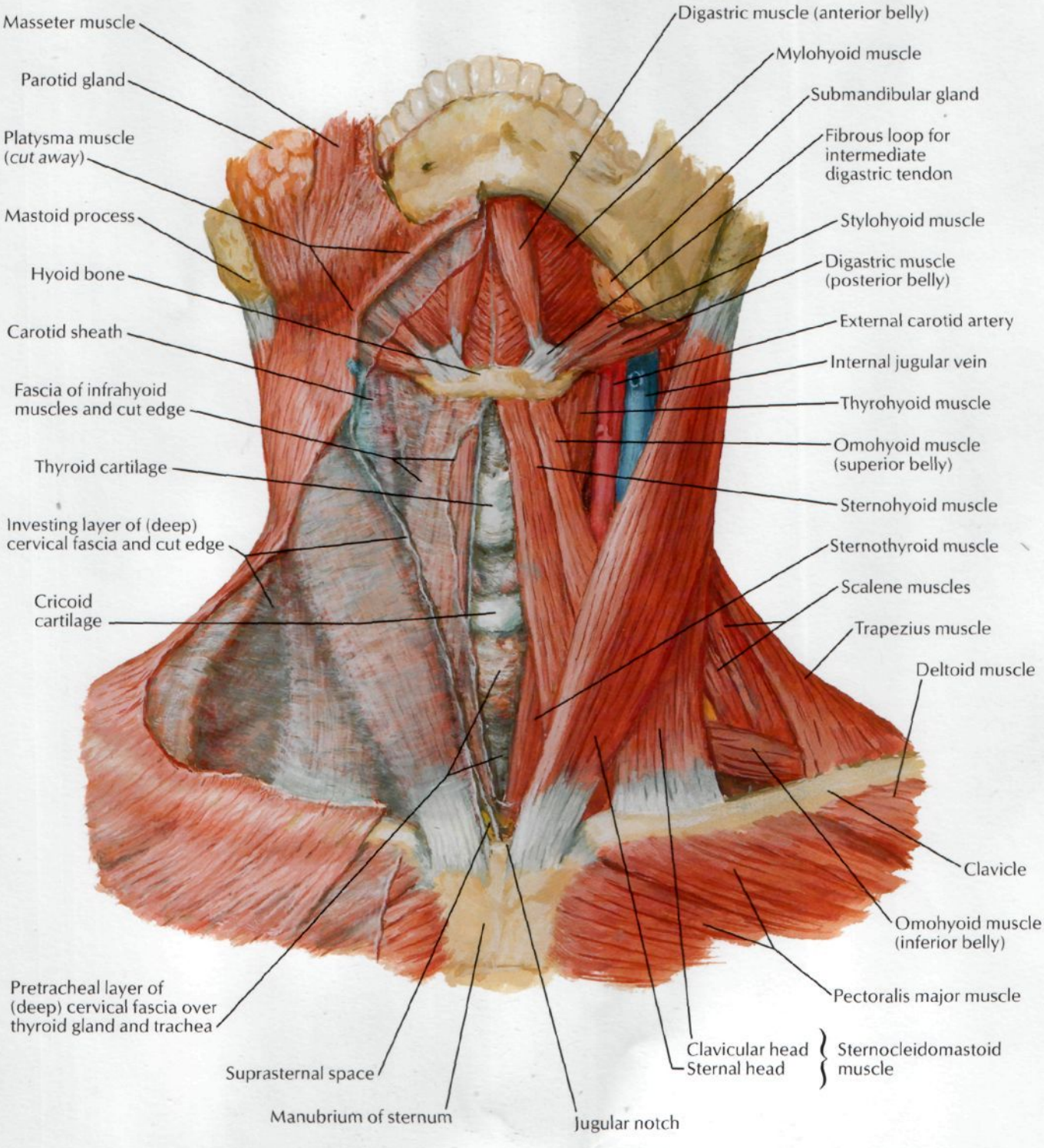

SEE ALSO PLATE 49

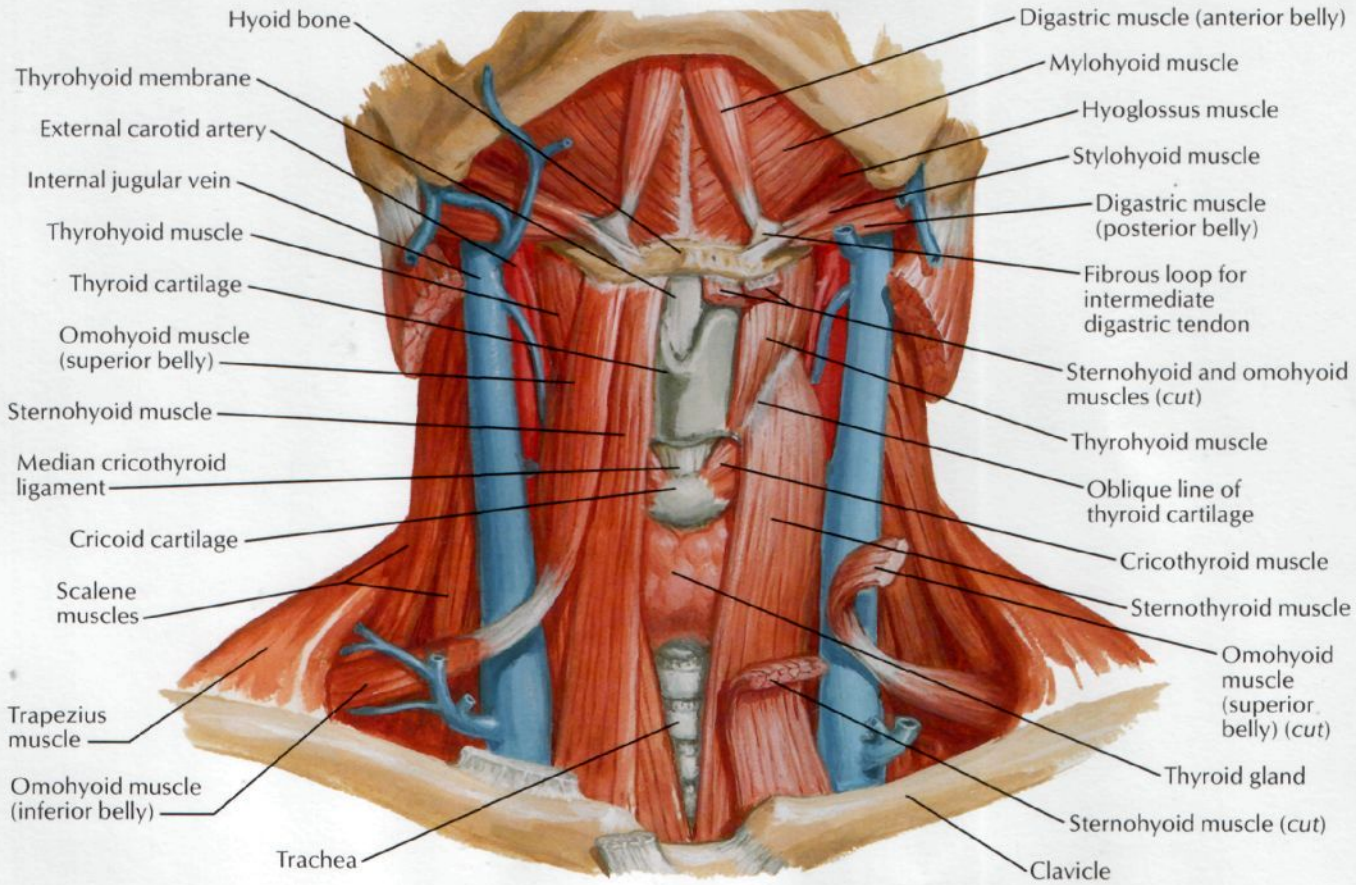

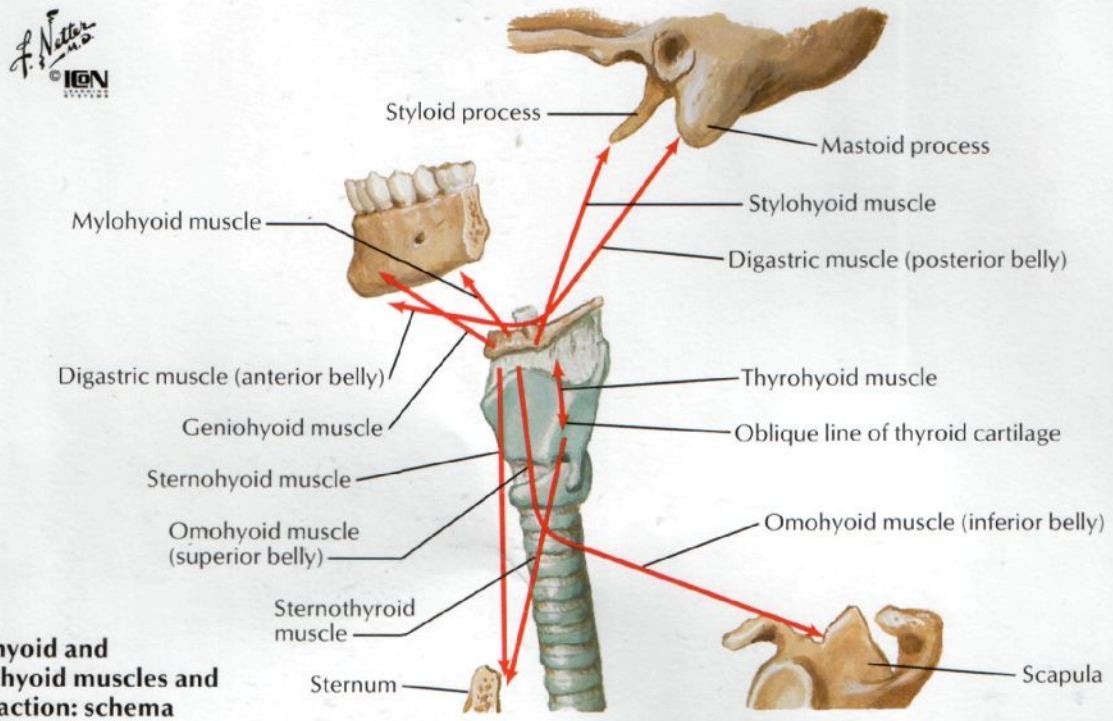

Infrahyoid and suprahyoid muscles and their action: schema

Scalene and Prevertebral Muscles

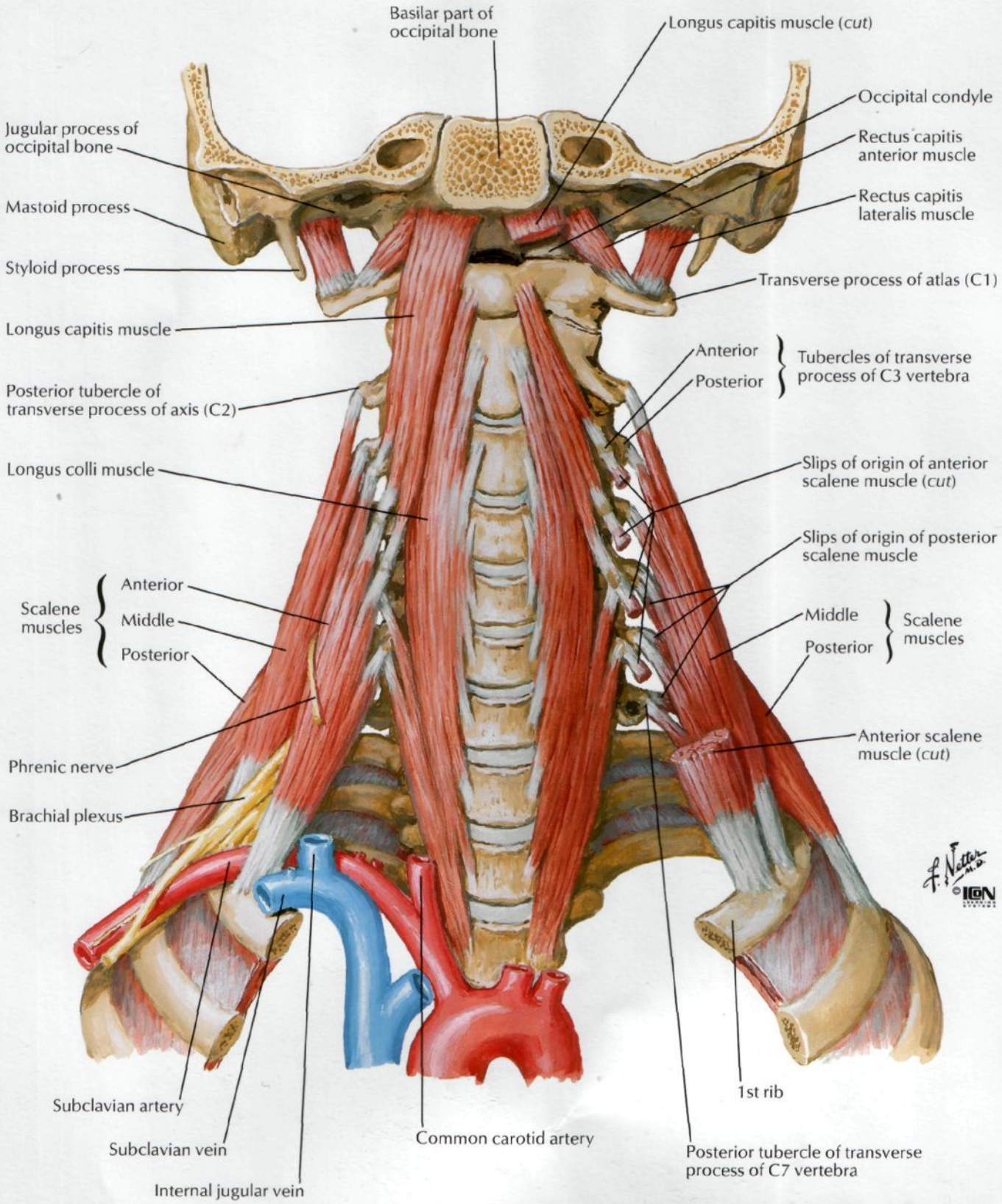

Superficial Veins and Cutaneous Nerves of Neck

FOR DEEP VEINS OF NECK SEE PLATE 66

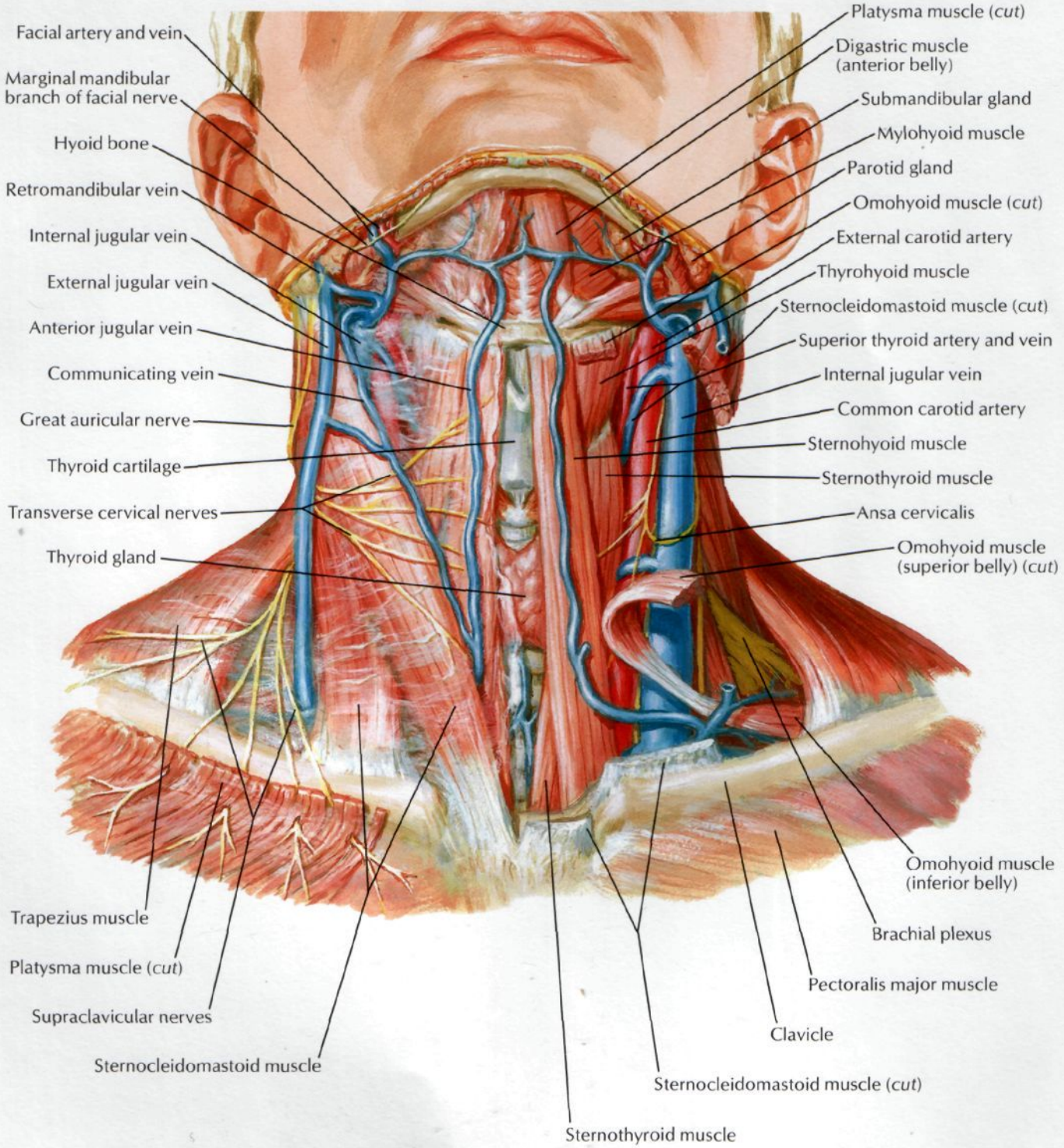

Cervical Plexus In Situ

SEE ALSO PLATES 121–123, 190

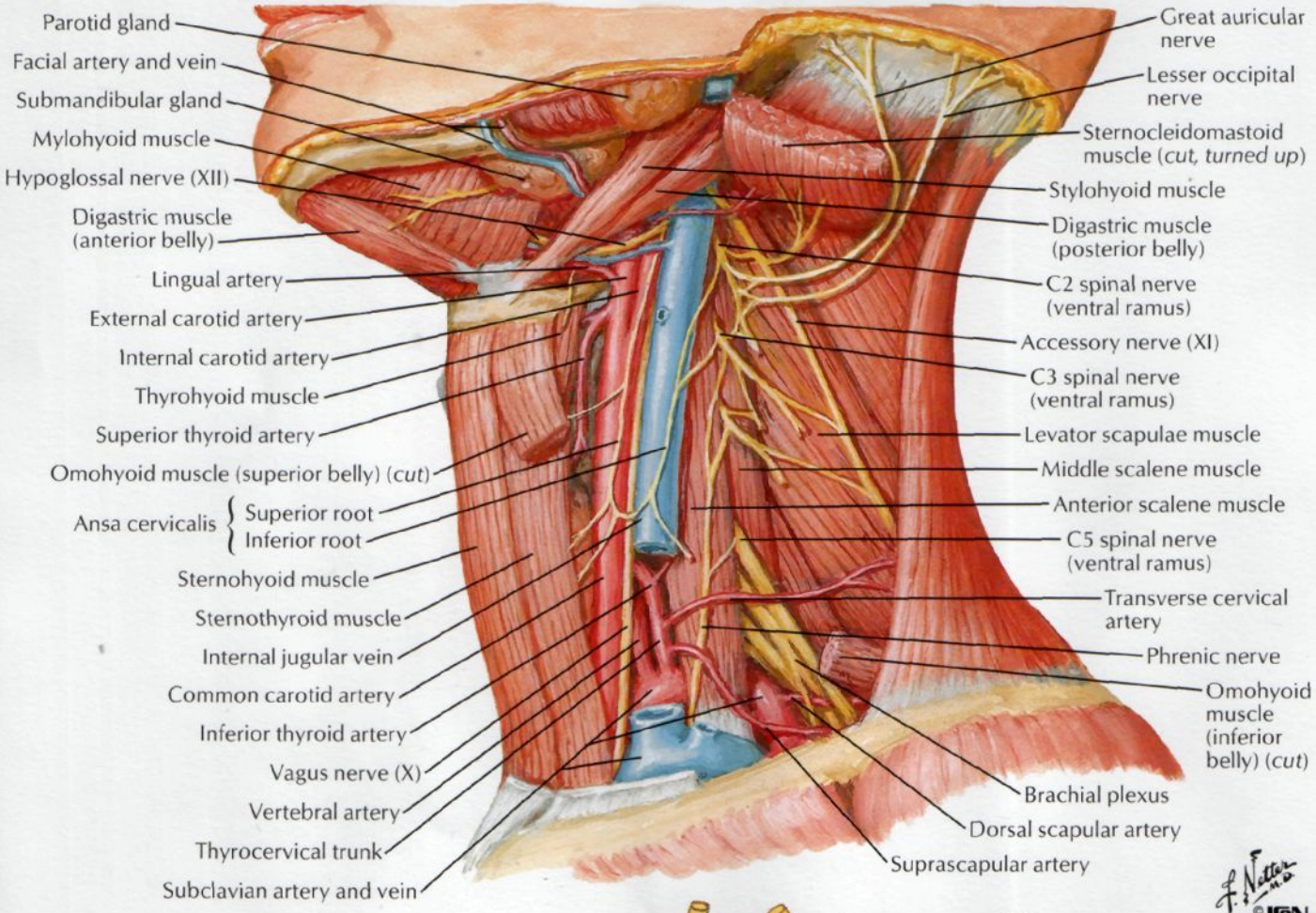

Cervical plexus: schema
(S = gray ramus from superior cervical sympathetic ganglion)

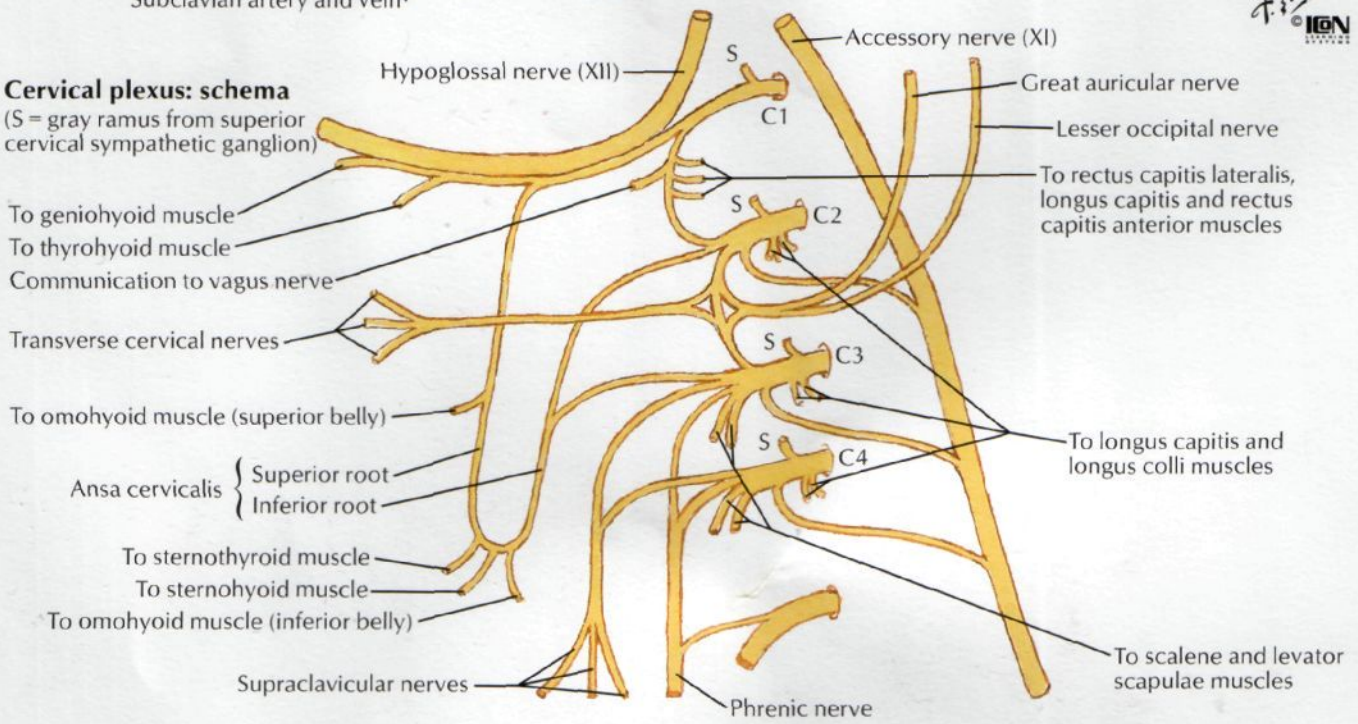

SEE ALSO PLATE 410

Right anterior dissection

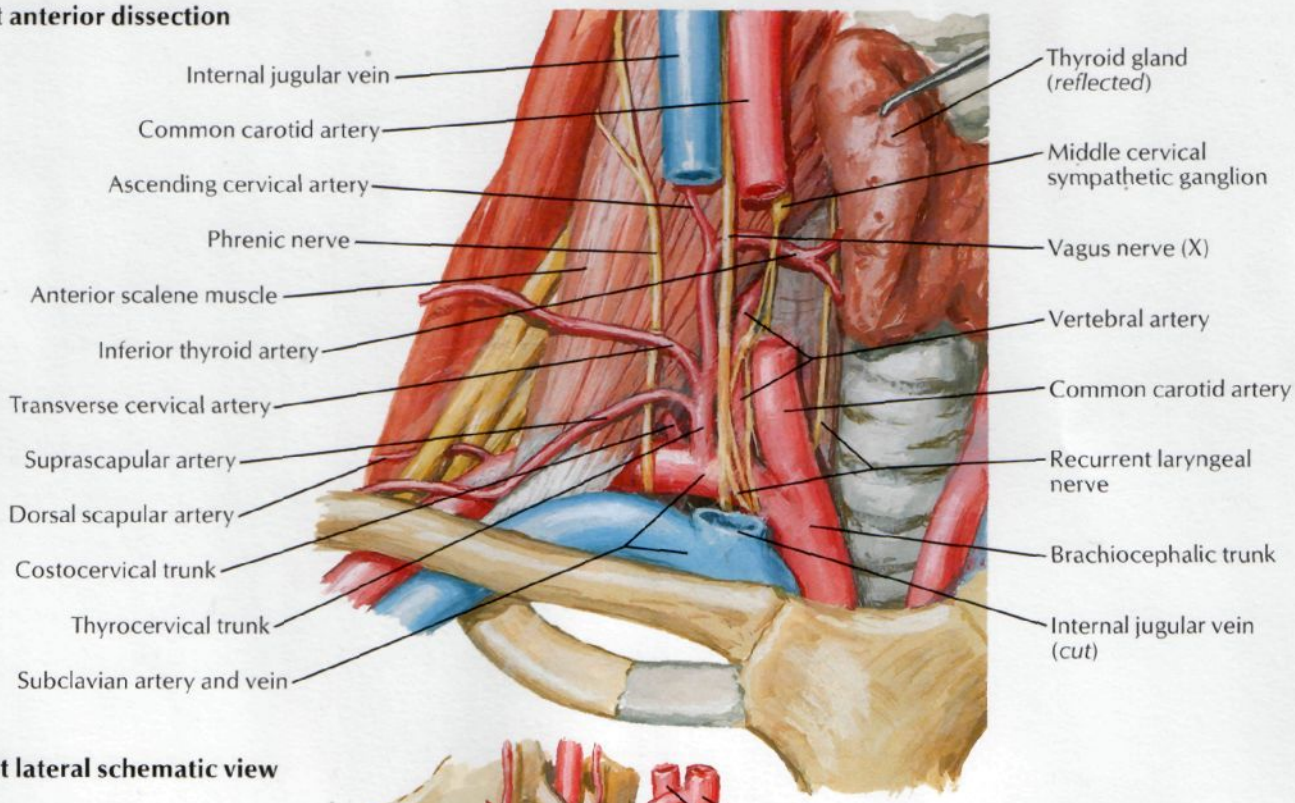

Right lateral schematic view

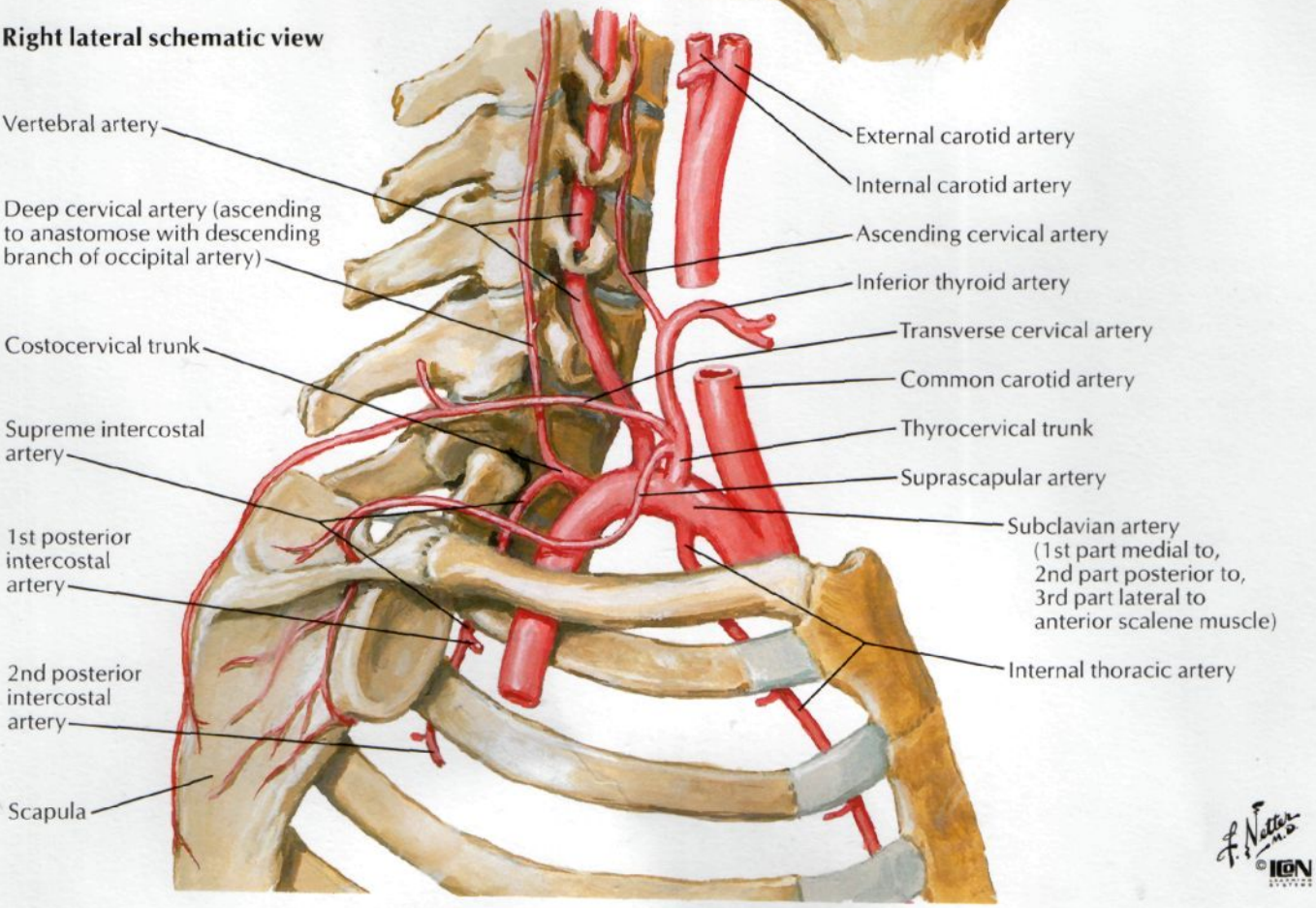

Carotid Arteries

SEE ALSO PLATES 130, 131

Parotid space (bed): right lateral dissection

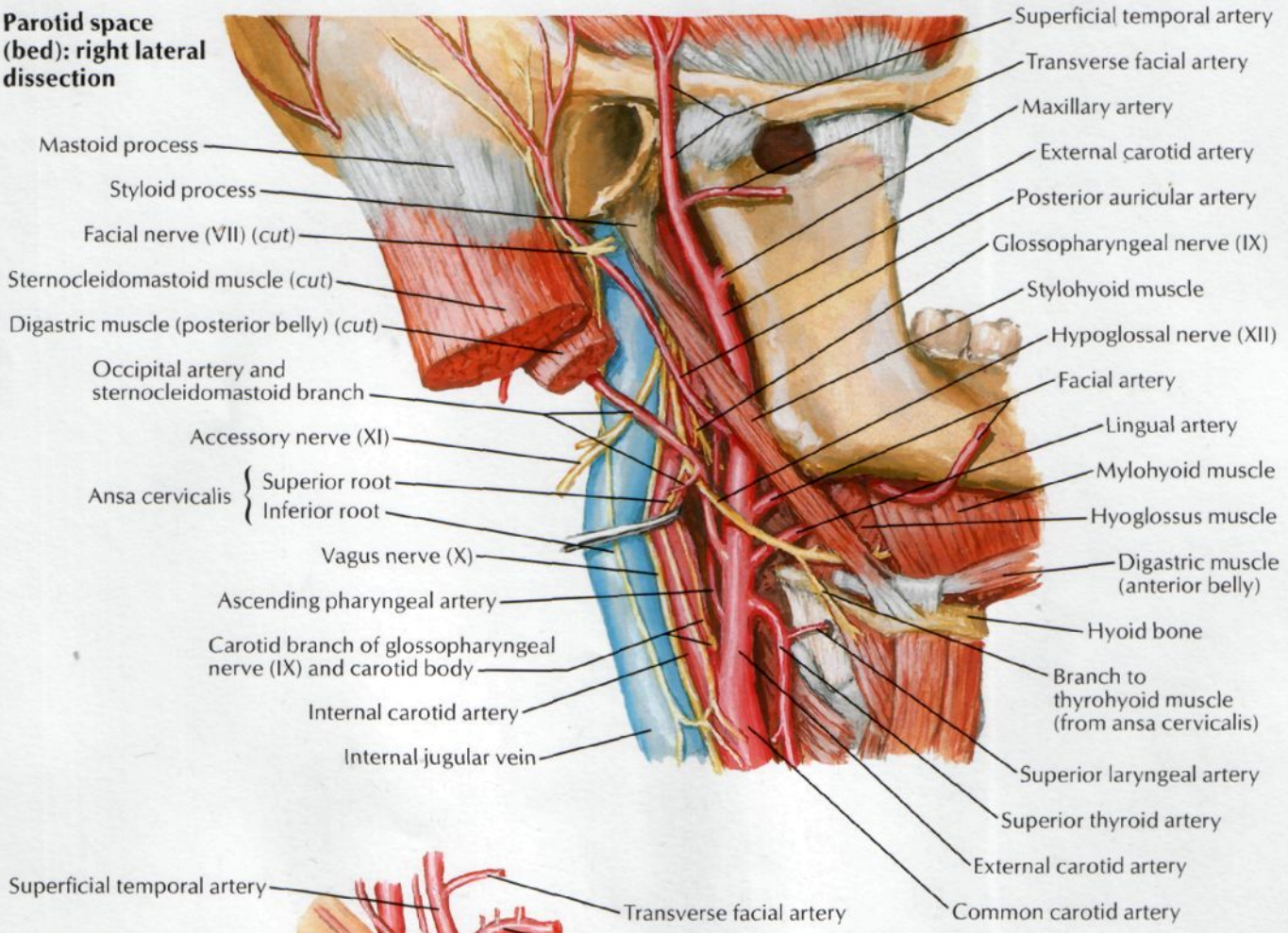

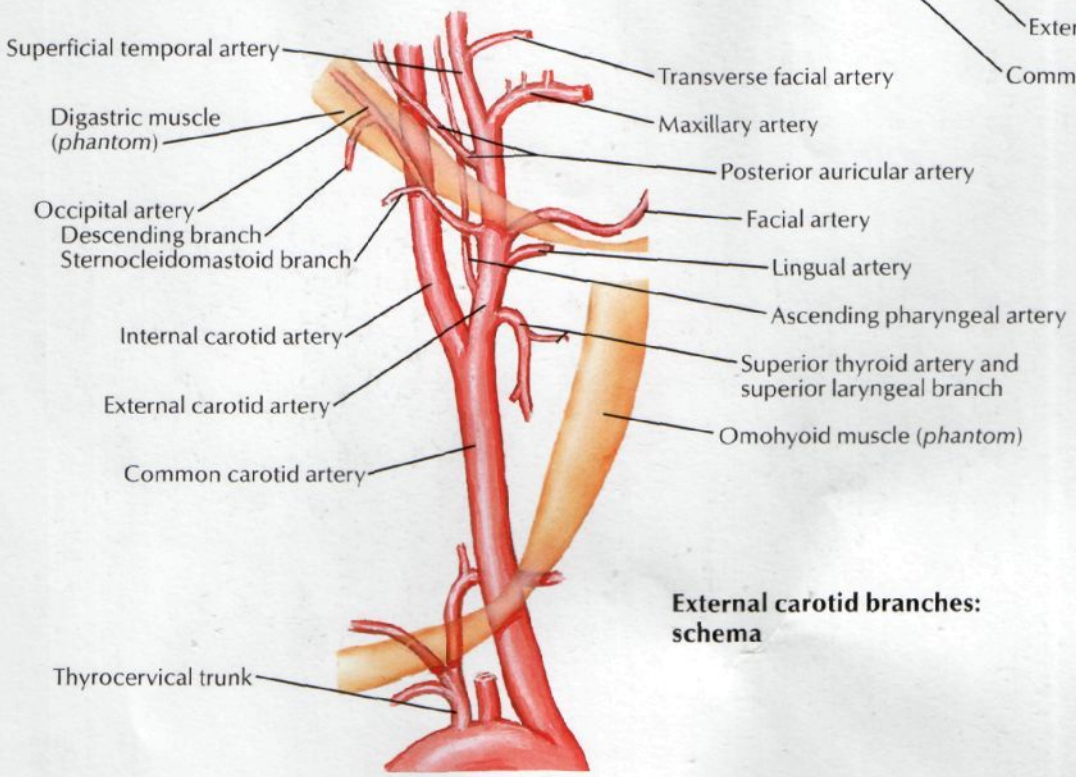

External carotid branches: schema

F. Netter M.D.
©IGN

Fascial Layers of Neck

FOR CONTENTS OF CAROTID SHEATH SEE PLATES 65–67

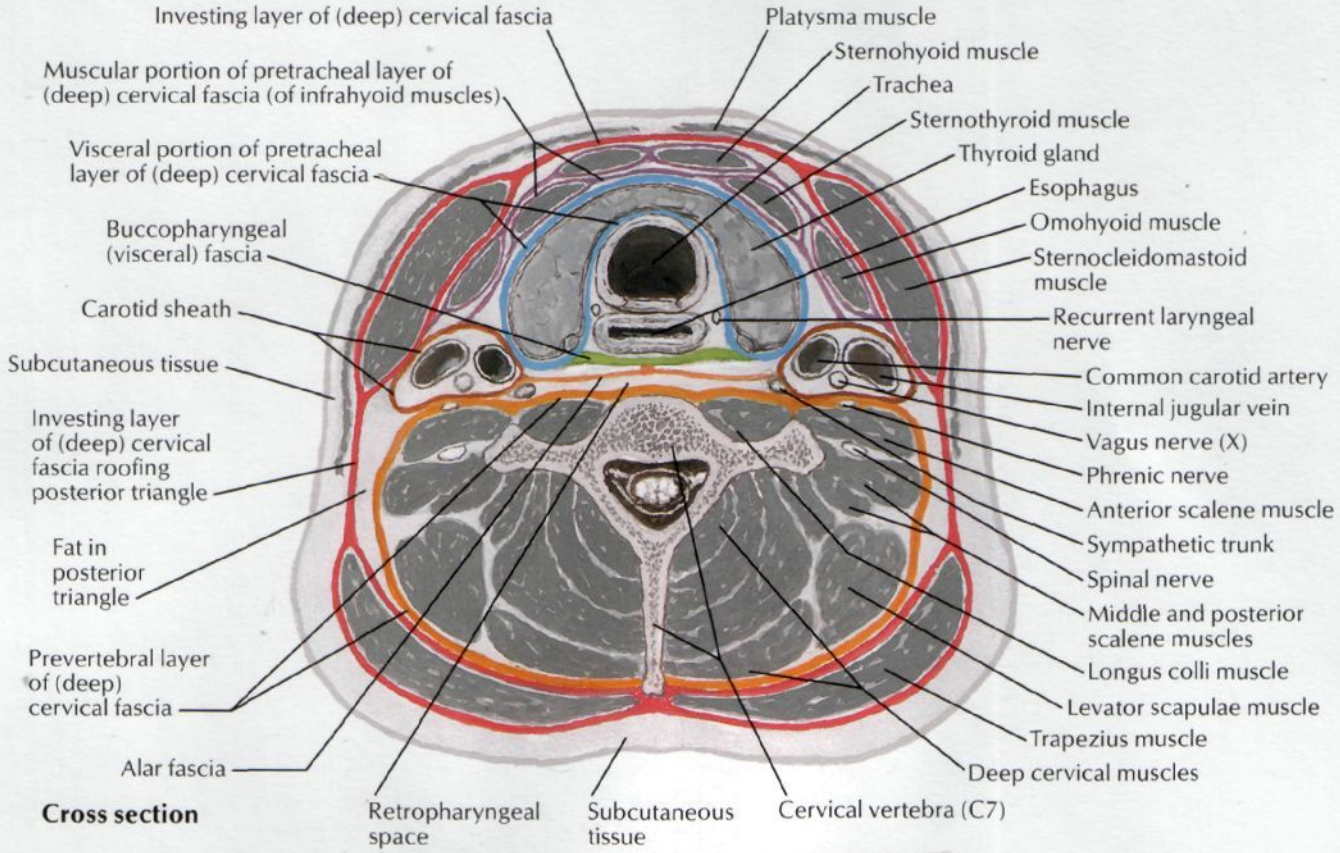

Cross section

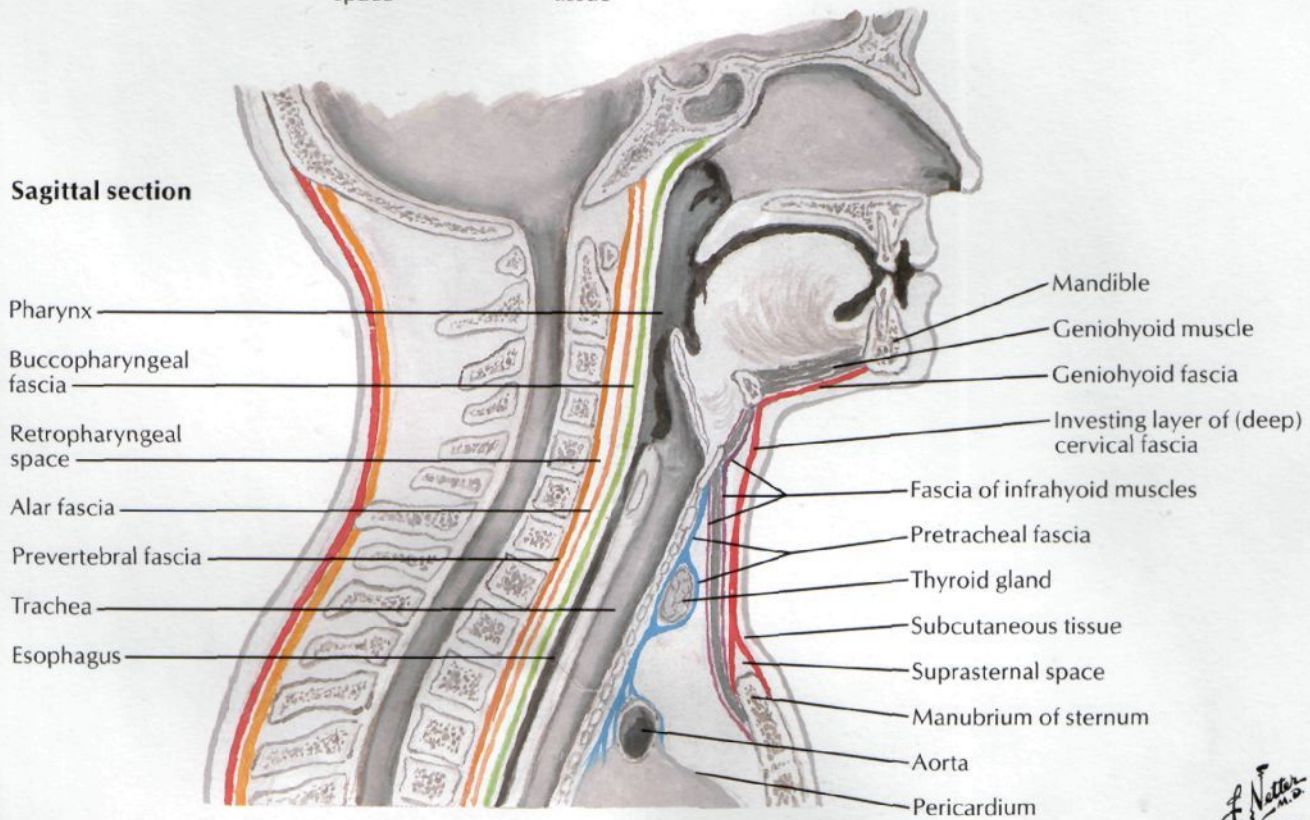

Sagittal section

F. Netter M.D. ©IGN

Nose

Anterolateral view

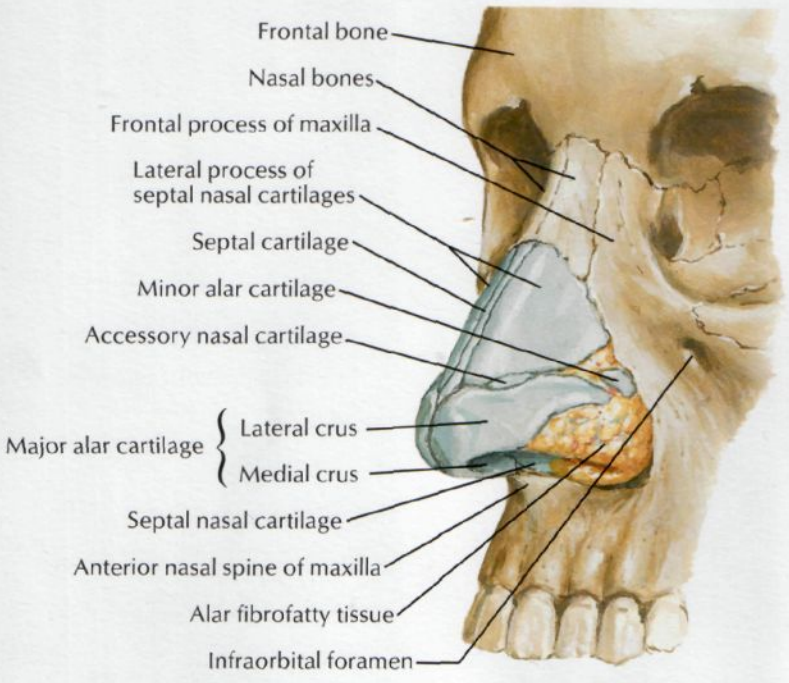

Inferior view

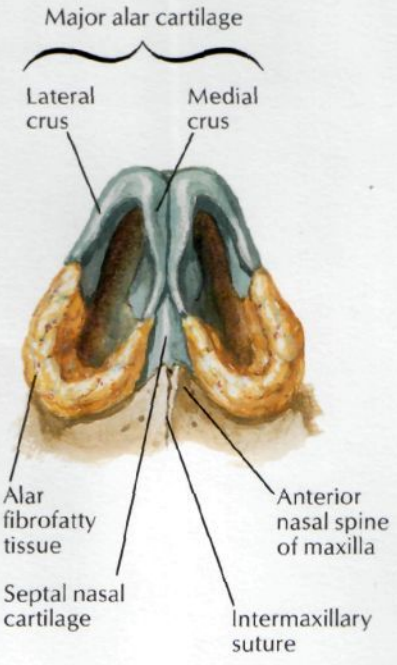

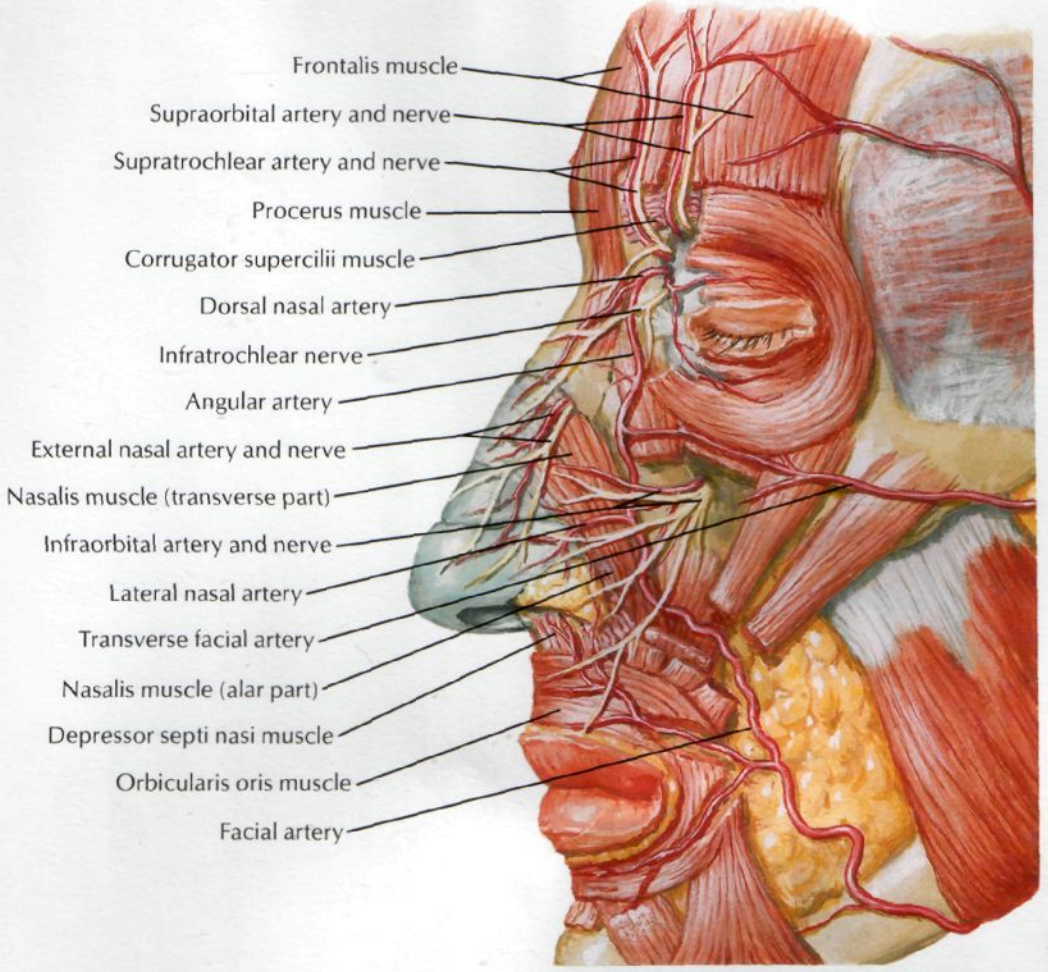

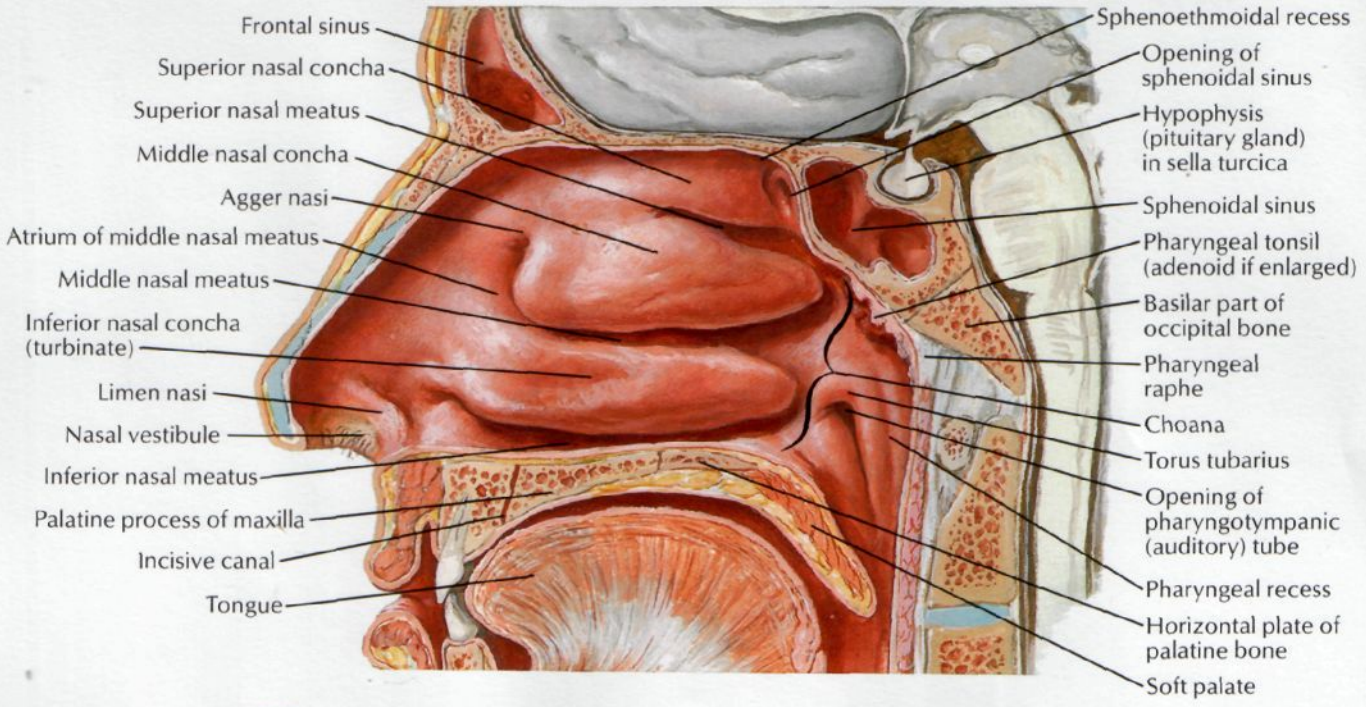

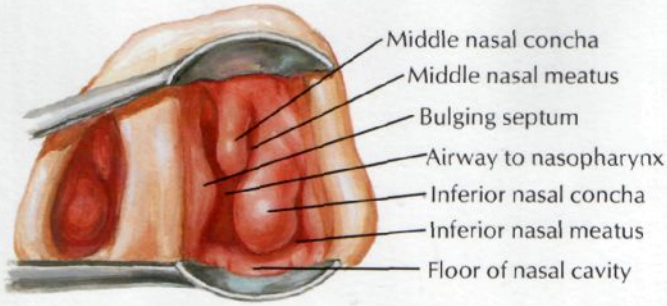

Speculum view

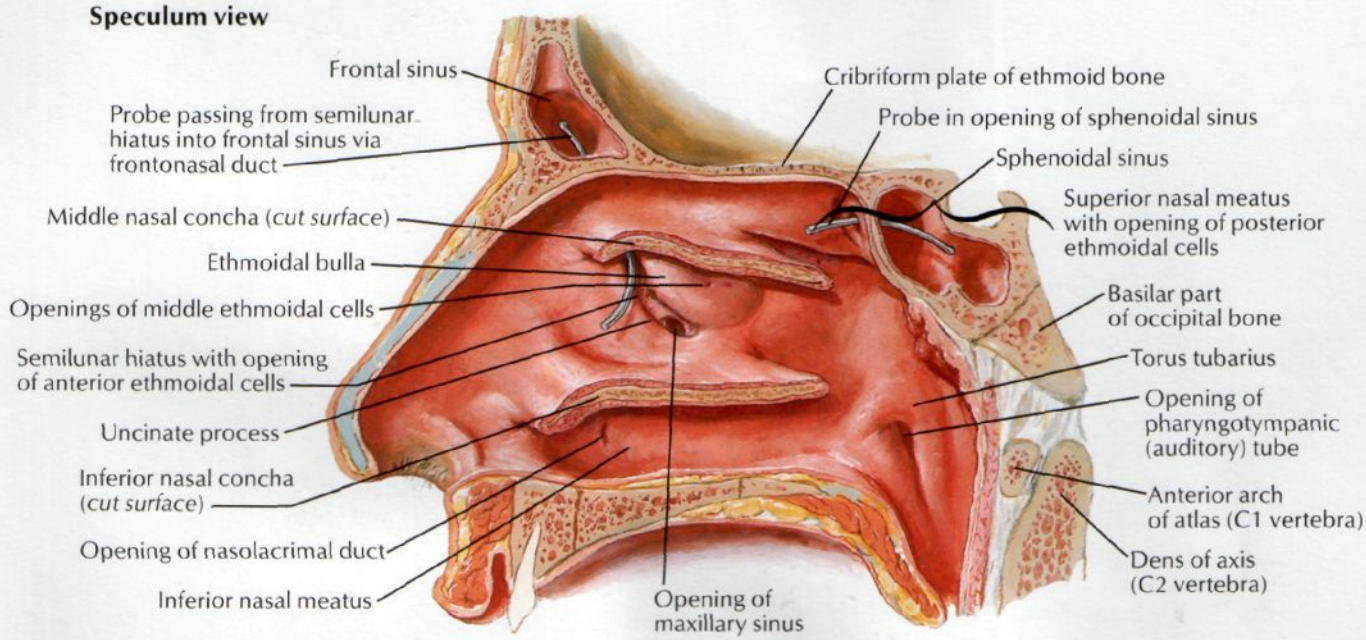

Lateral Wall of Nasal Cavity (continued)

SEE ALSO PLATE 6

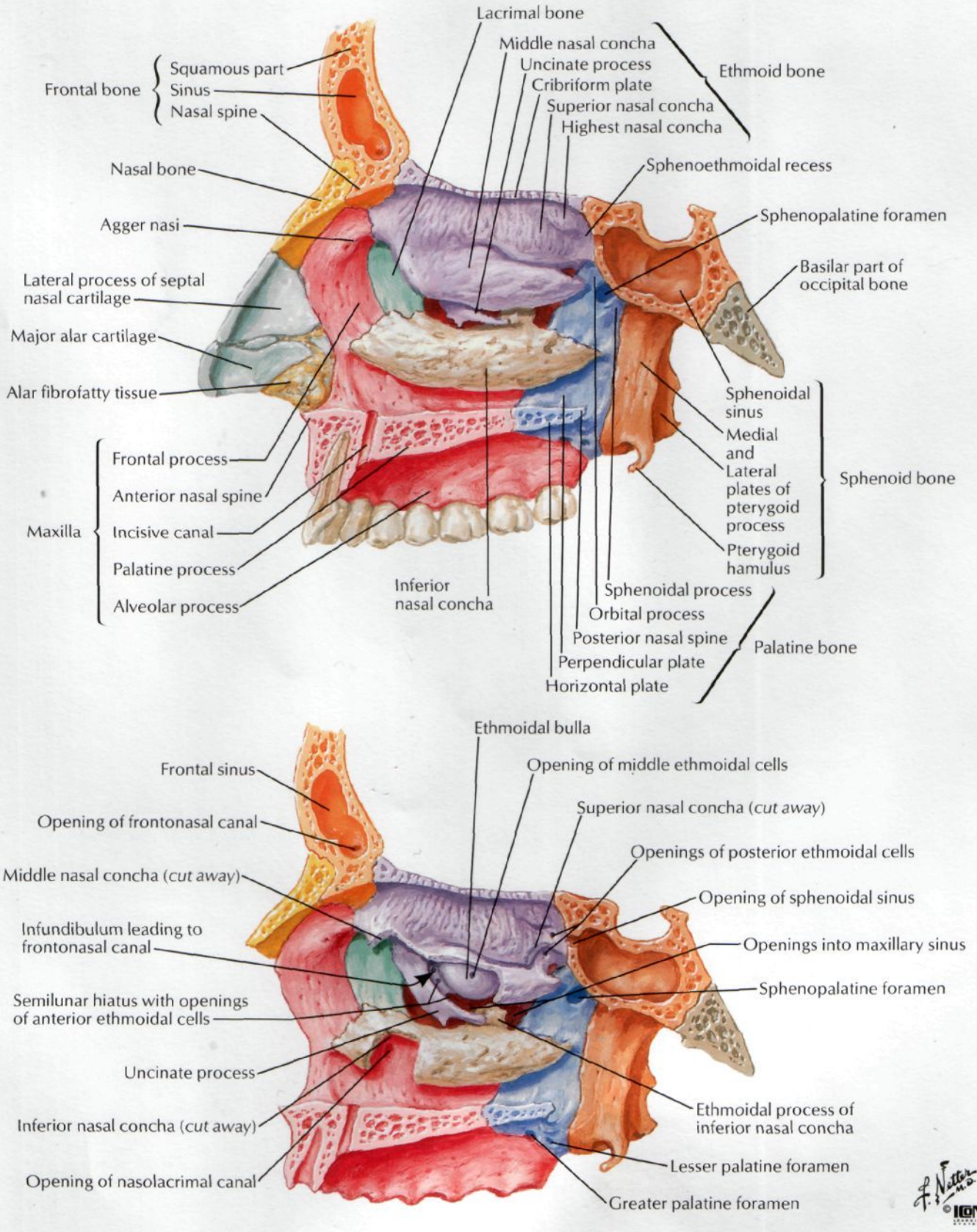

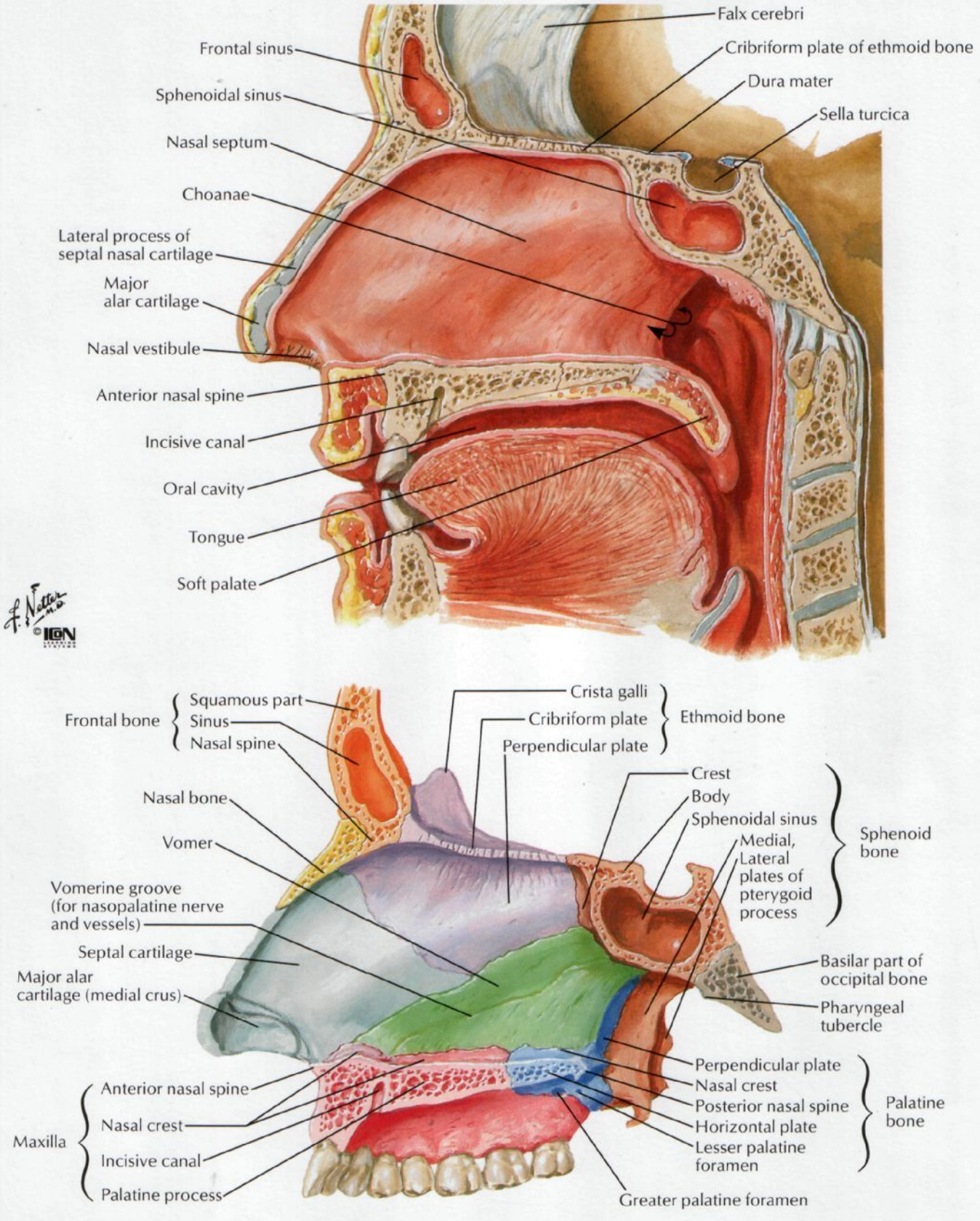
Falx cerebri
Frontal sinus
Cribriform plate of ethmoid bone
Sphenoidal sinus
Dura mater
Sella turcica
Nasal septum
Choanae
Lateral process of septal nasal cartilage
Major alar cartilage
Nasal vestibule
Anterior nasal spine
Incisive canal
Oral cavity
Tongue
Soft palate
F. Netter M.D.
©IGN
Frontal bone
Squamous part
Sinus
Nasal spine
Crista galli
Cribriform plate
Perpendicular plate
Ethmoid bone
Nasal bone
Vomer
Crest
Body
Sphenoidal sinus
Medial, Lateral plates of pterygoid process
Sphenoid bone
Vomerine groove (for nasopalatine nerve and vessels)
Septal cartilage
Major alar cartilage (medial crus)
Basilar part of occipital bone
Pharyngeal tubercle
Maxilla
Anterior nasal spine
Nasal crest
Incisive canal
Palatine process
Perpendicular plate
Nasal crest
Posterior nasal spine
Horizontal plate
Lesser palatine foramen
Palatine bone
Greater palatine foramen

Maxillary Artery

SEE ALSO PLATE 30

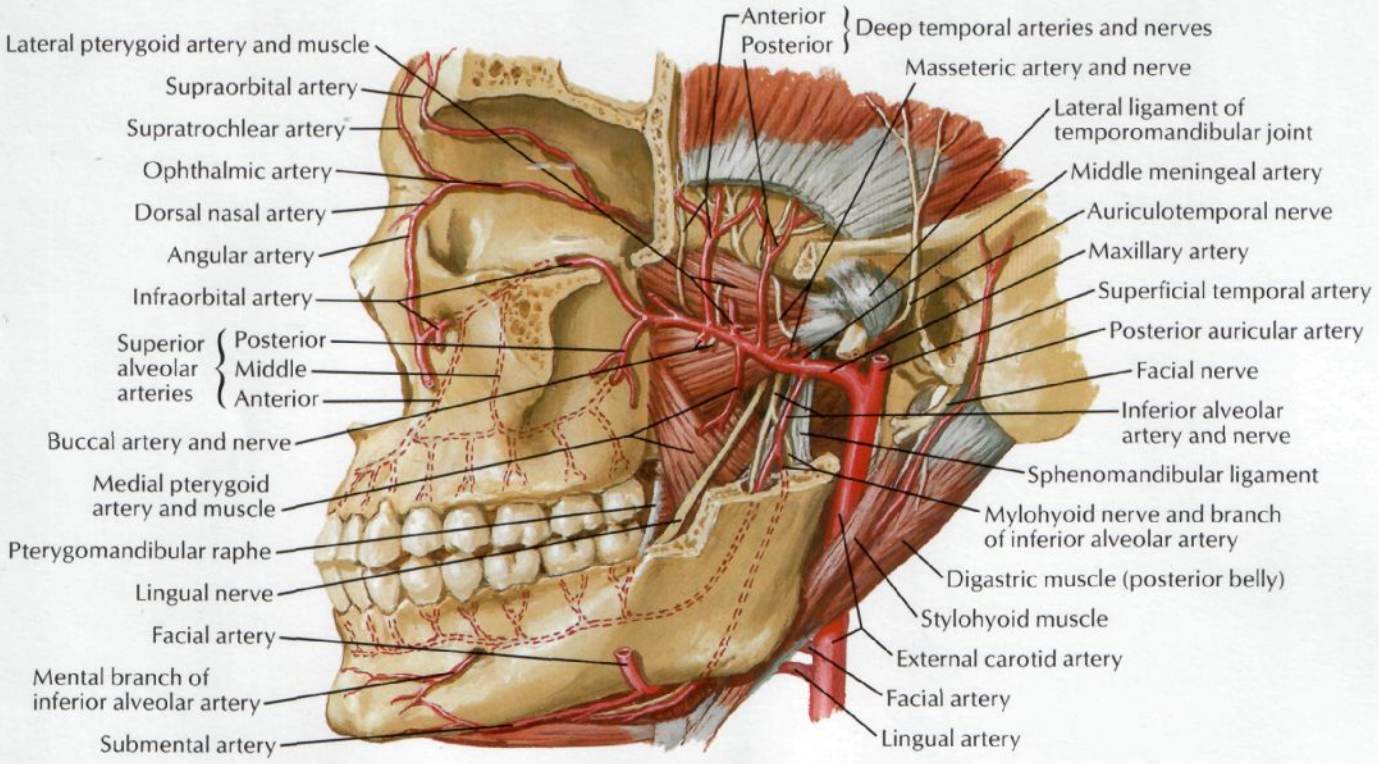

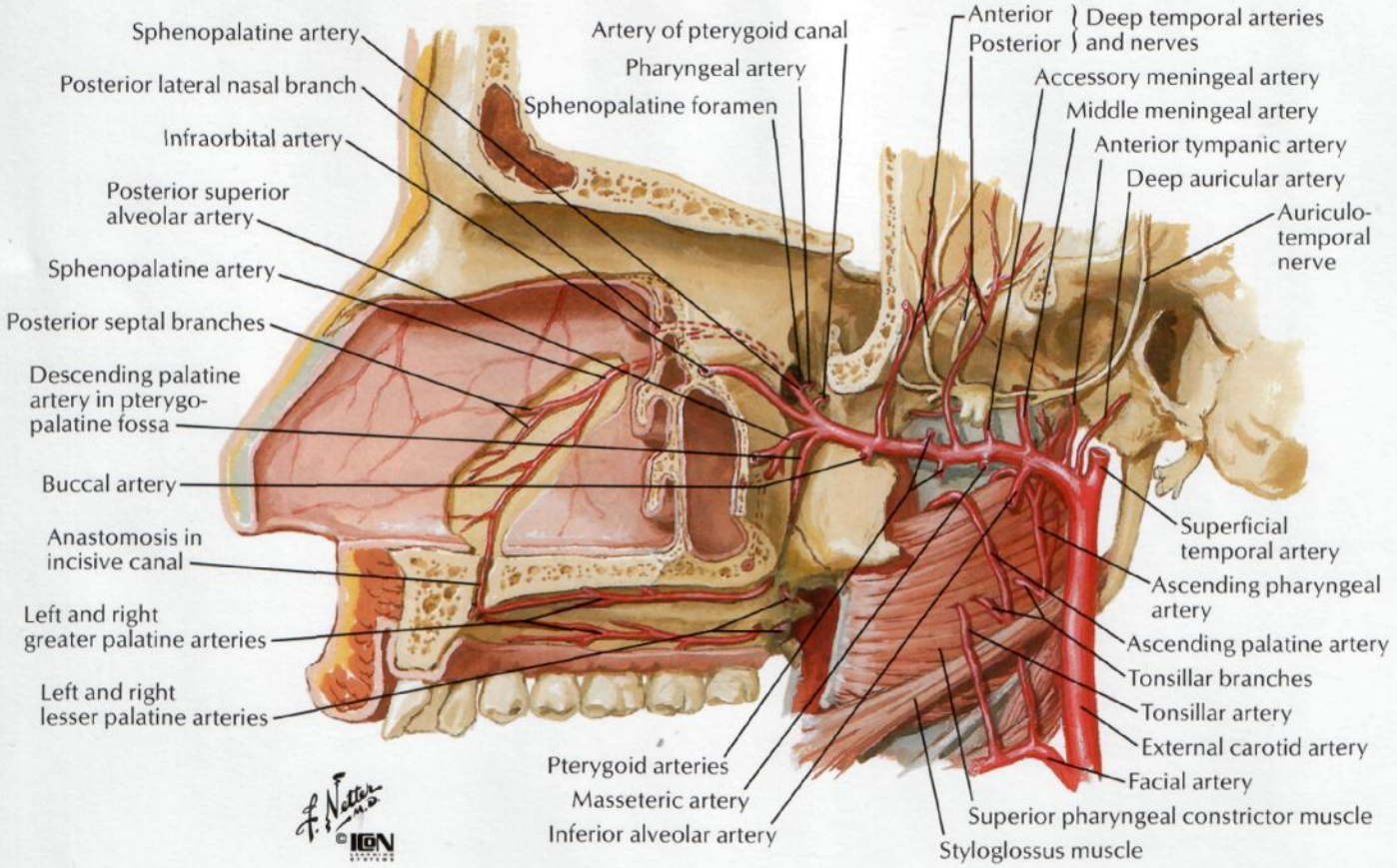

Arteries of Nasal Cavity: Nasal Septum Turned Up

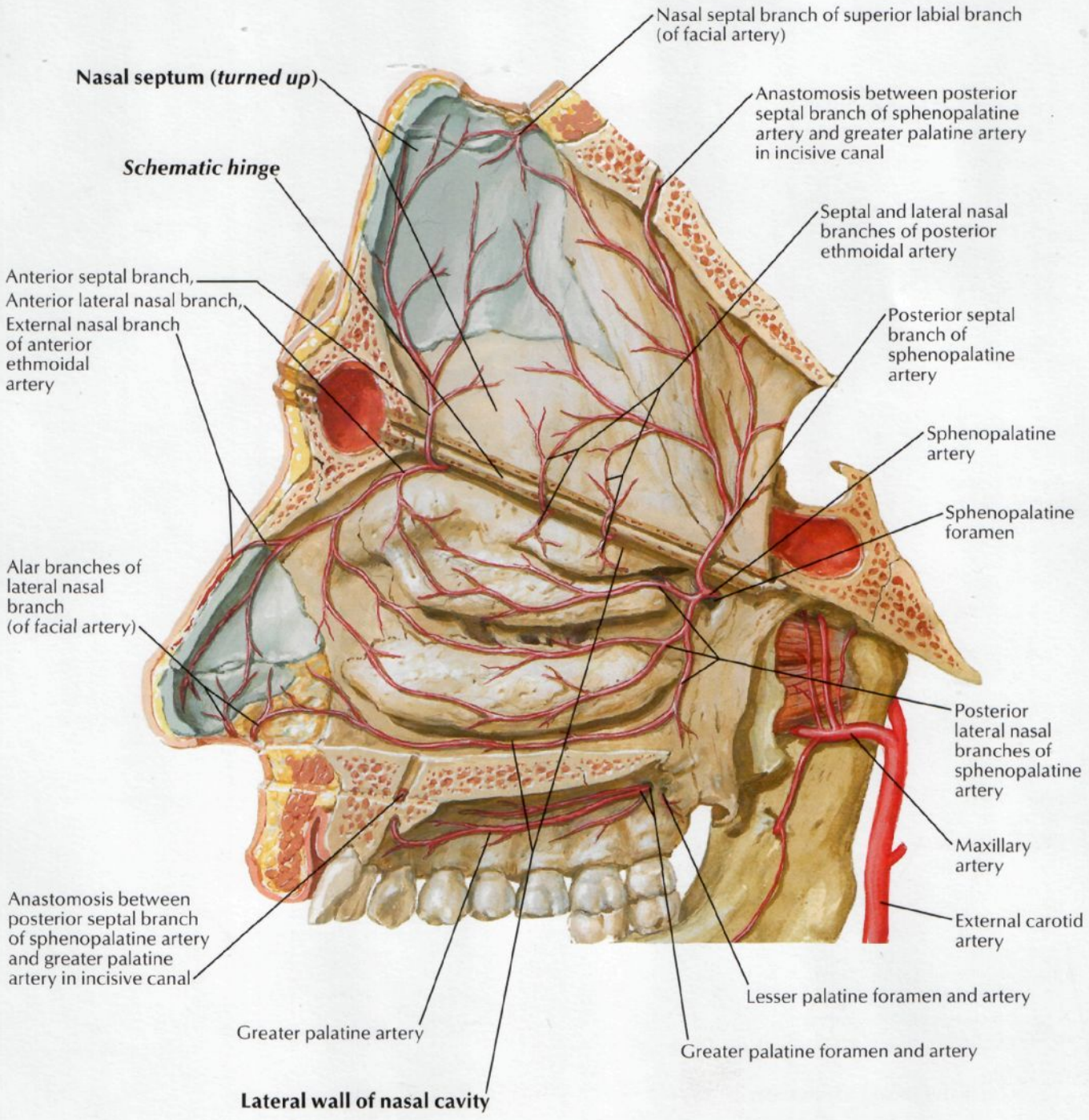

©IGN

Nerves of Nasal Cavity: Nasal Septum Turned Up

SEE ALSO PLATES 40, 41, 113

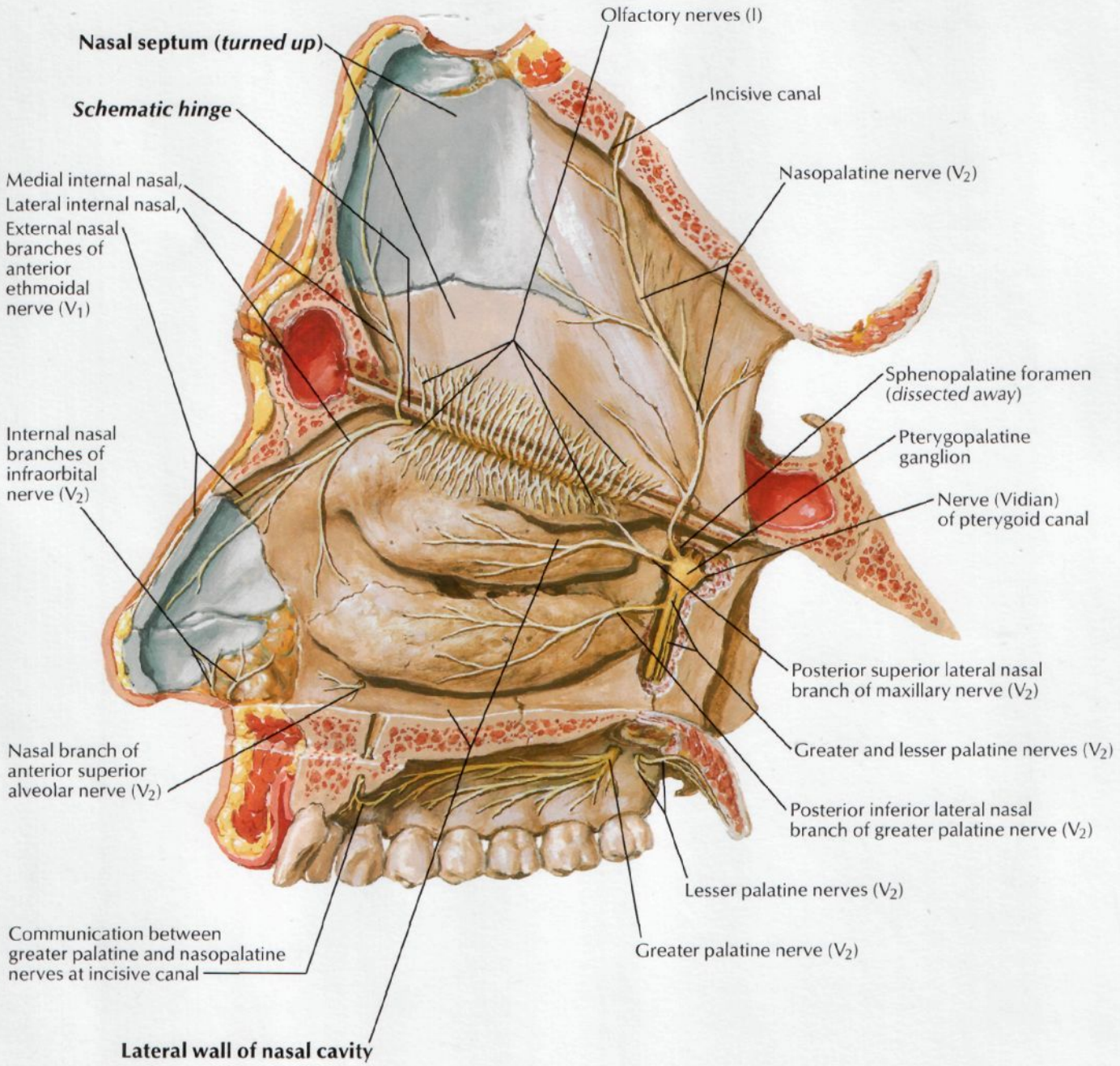

F. Netter M.D. ©IGN

SEE ALSO PLATE 113

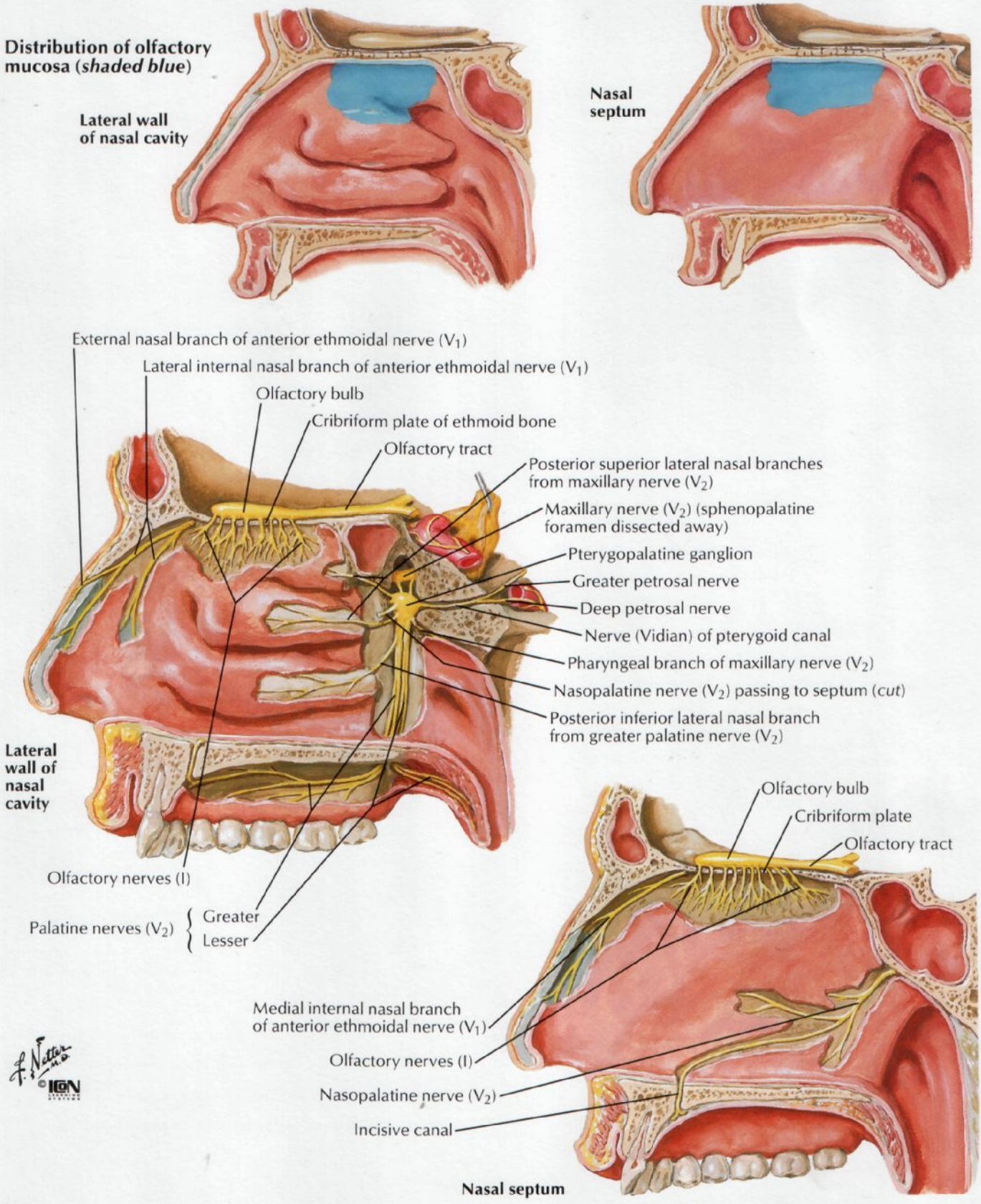

Autonomic Innervation of Nasal Cavity

SEE ALSO PLATES 116, 125, 127

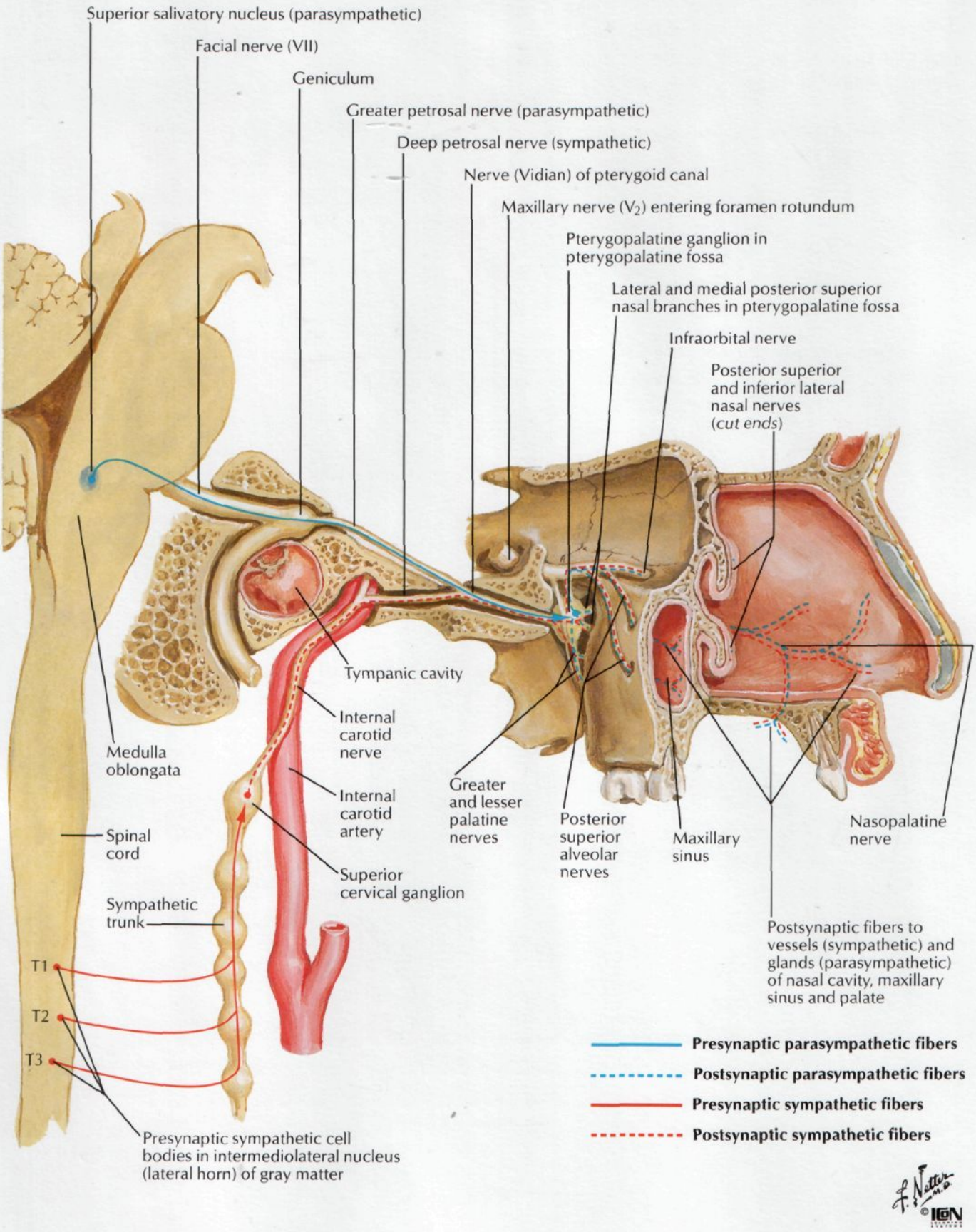

F. Netter M.D.
©IGN

Ophthalmic (V_1) and Maxillary (V_2) Nerves

SEE ALSO PLATE 116

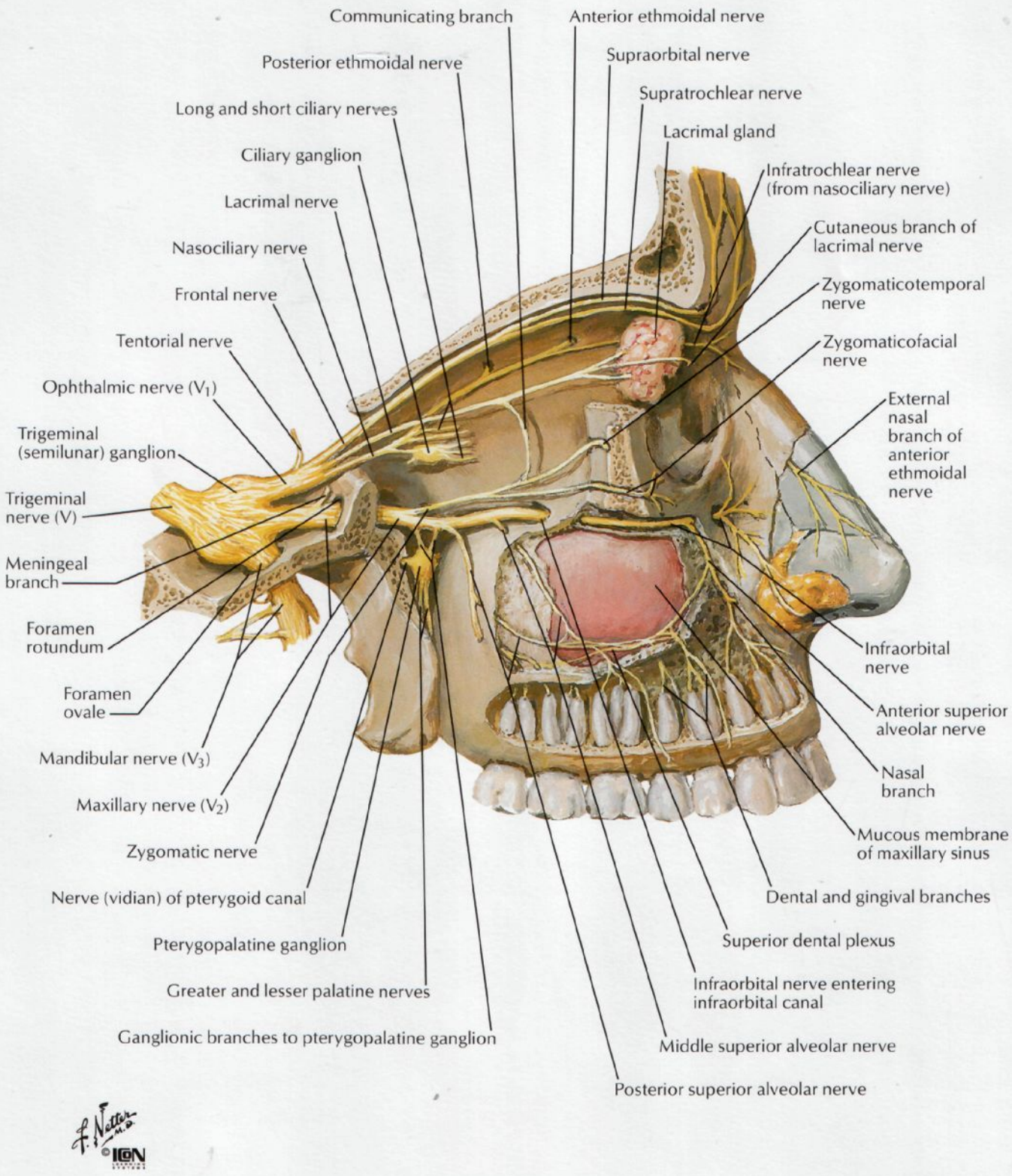

Mandibular Nerve (V_3)

SEE ALSO PLATES 67, 116

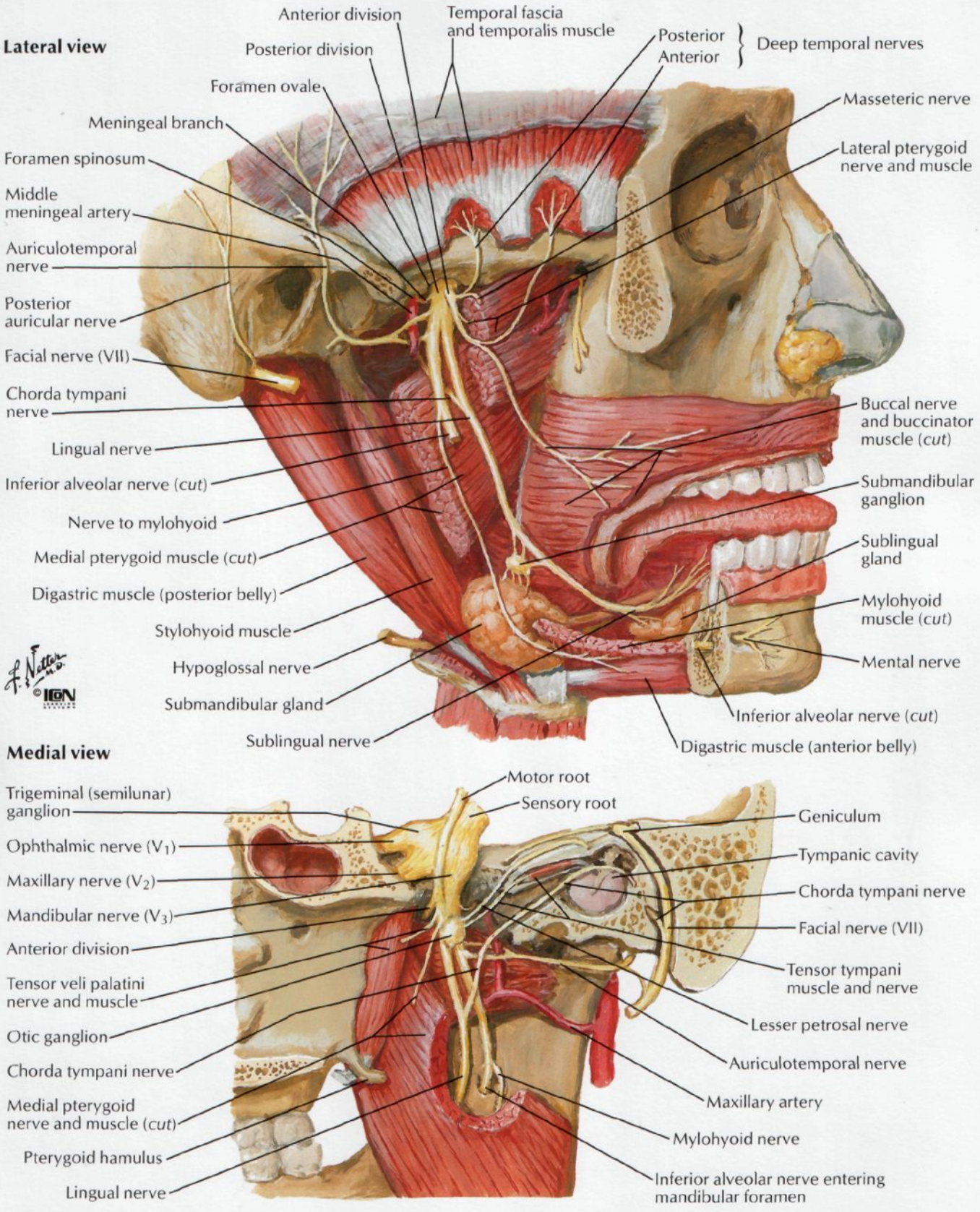

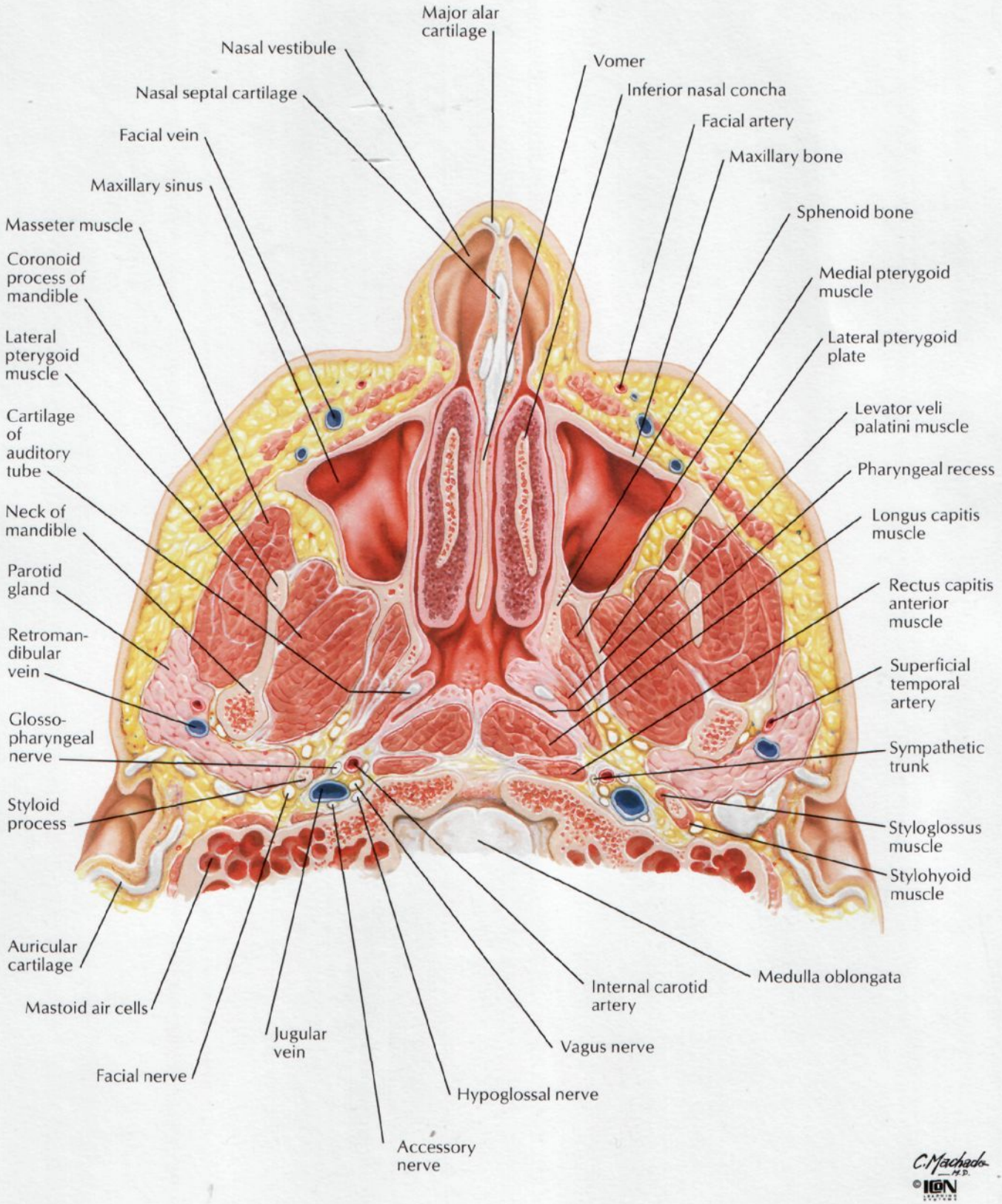
Major alar cartilage
Nasal vestibule
Vomer
Nasal septal cartilage
Inferior nasal concha
Facial vein
Facial artery
Maxillary bone
Maxillary sinus
Sphenoid bone
Masseter muscle
Coronoid process of mandible
Medial pterygoid muscle
Lateral pterygoid muscle
Lateral pterygoid plate
Cartilage of auditory tube
Levator veli palatini muscle
Pharyngeal recess
Neck of mandible
Longus capitis muscle
Parotid gland
Rectus capitis anterior muscle
Retromandibular vein
Superficial temporal artery
Glossopharyngeal nerve
Sympathetic trunk
Styloid process
Styloglossus muscle
Stylohyoid muscle
Auricular cartilage
Medulla oblongata
Internal carotid artery
Mastoid air cells
Jugular vein
Vagus nerve
Facial nerve
Hypoglossal nerve
Accessory nerve
C. Machado M.D.
©IGN

Paranasal Sinuses

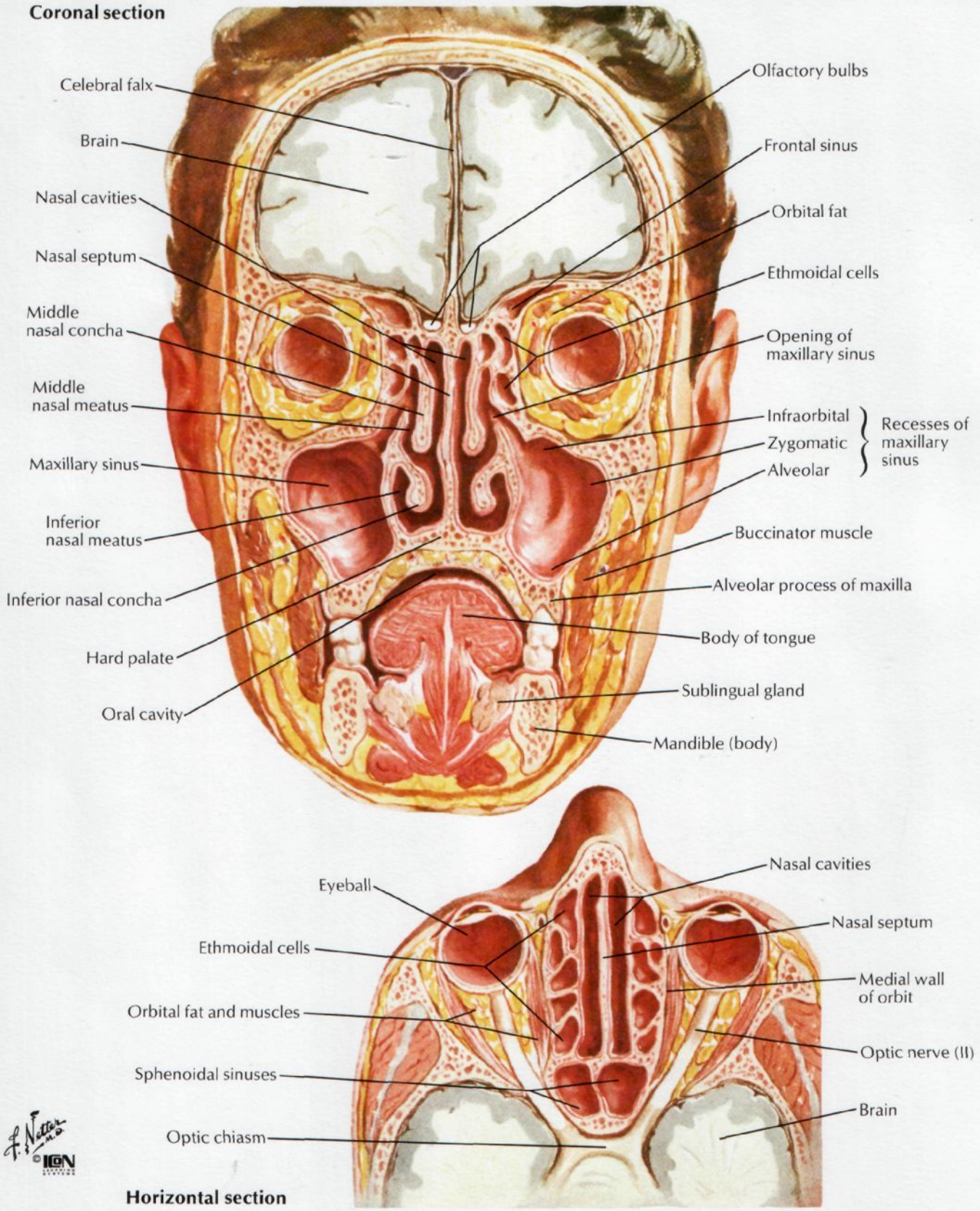

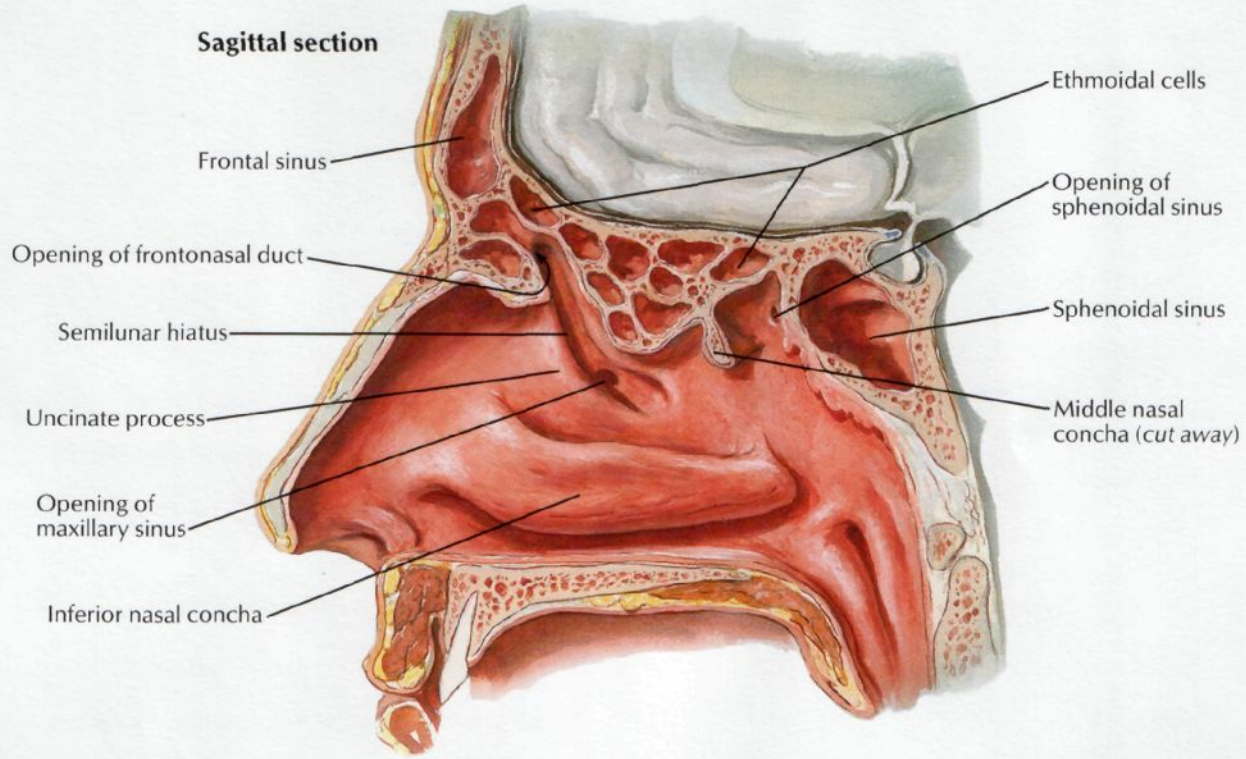
Sagittal section
Ethmoidal cells
Frontal sinus
Opening of sphenoidal sinus
Opening of frontonasal duct
Sphenoidal sinus
Semilunar hiatus
Middle nasal concha (cut away)
Uncinate process
Opening of maxillary sinus
Inferior nasal concha

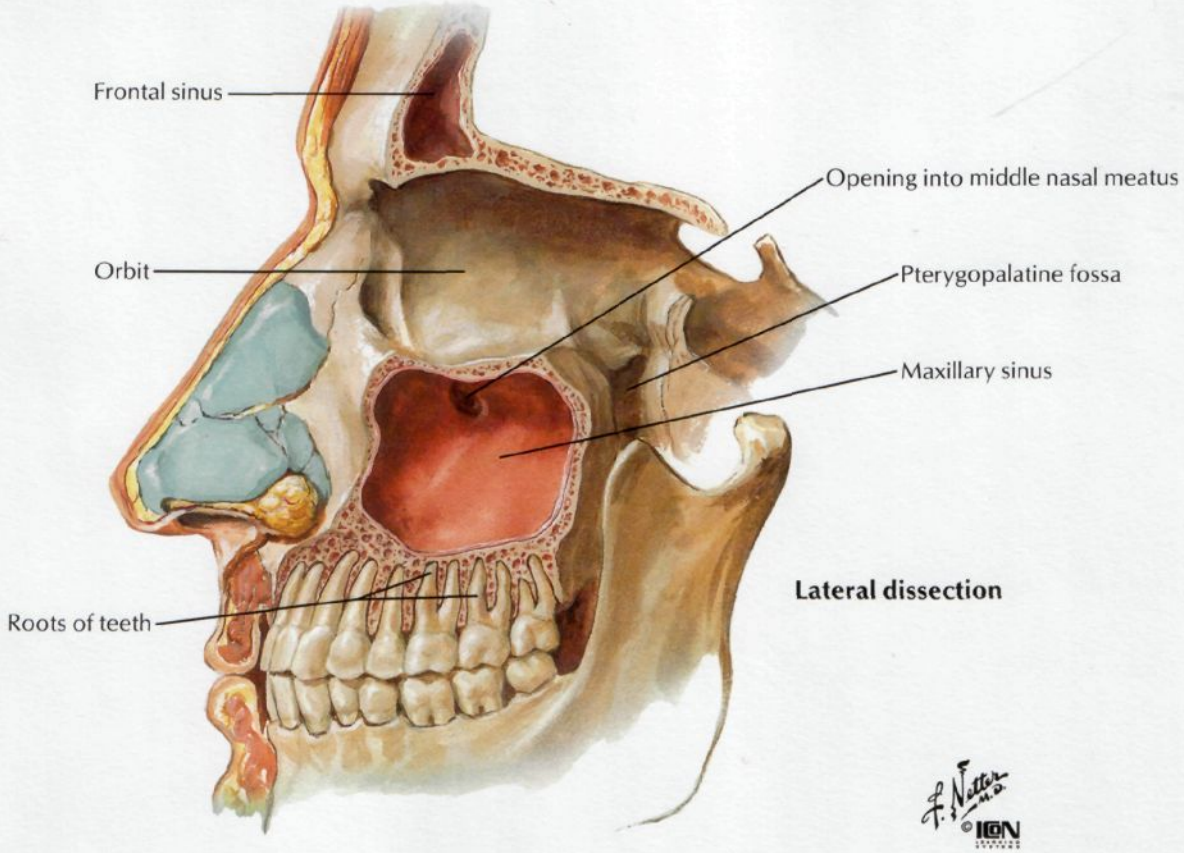
Frontal sinus
Opening into middle nasal meatus
Orbit
Pterygopalatine fossa
Maxillary sinus
Roots of teeth
Lateral dissection
F. Netter M.D.
©IGN

Paranasal Sinuses: Changes With Age

Bones of nasal cavity and paranasal sinuses at birth

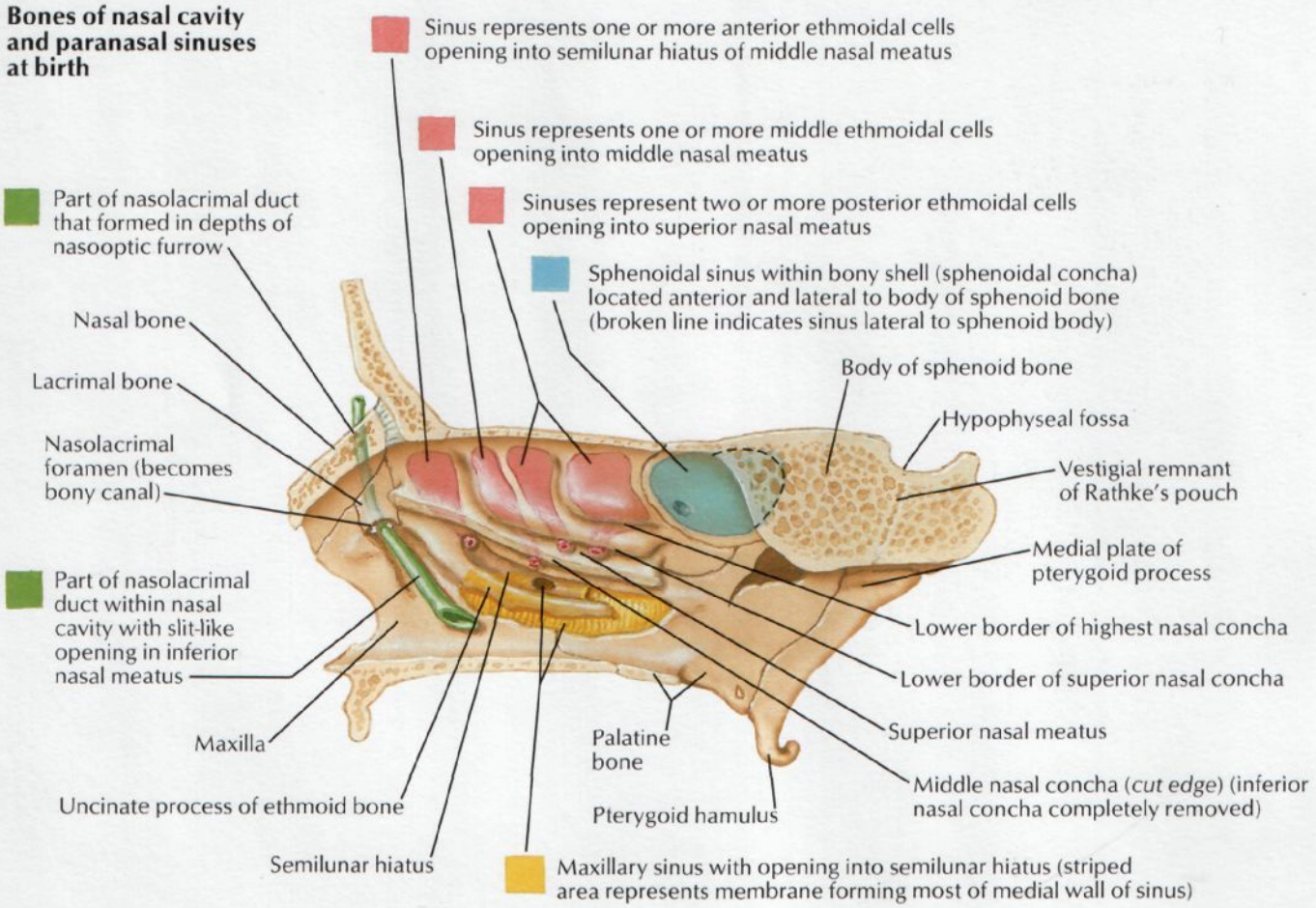

Growth of frontal and maxillary sinuses throughout life

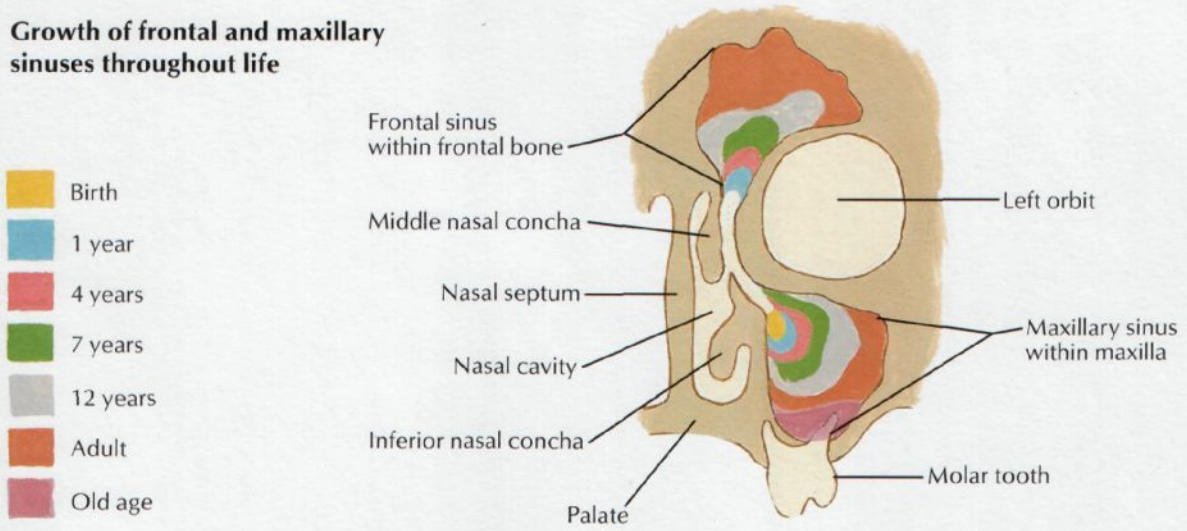

F. Netter M.D. ©IGN

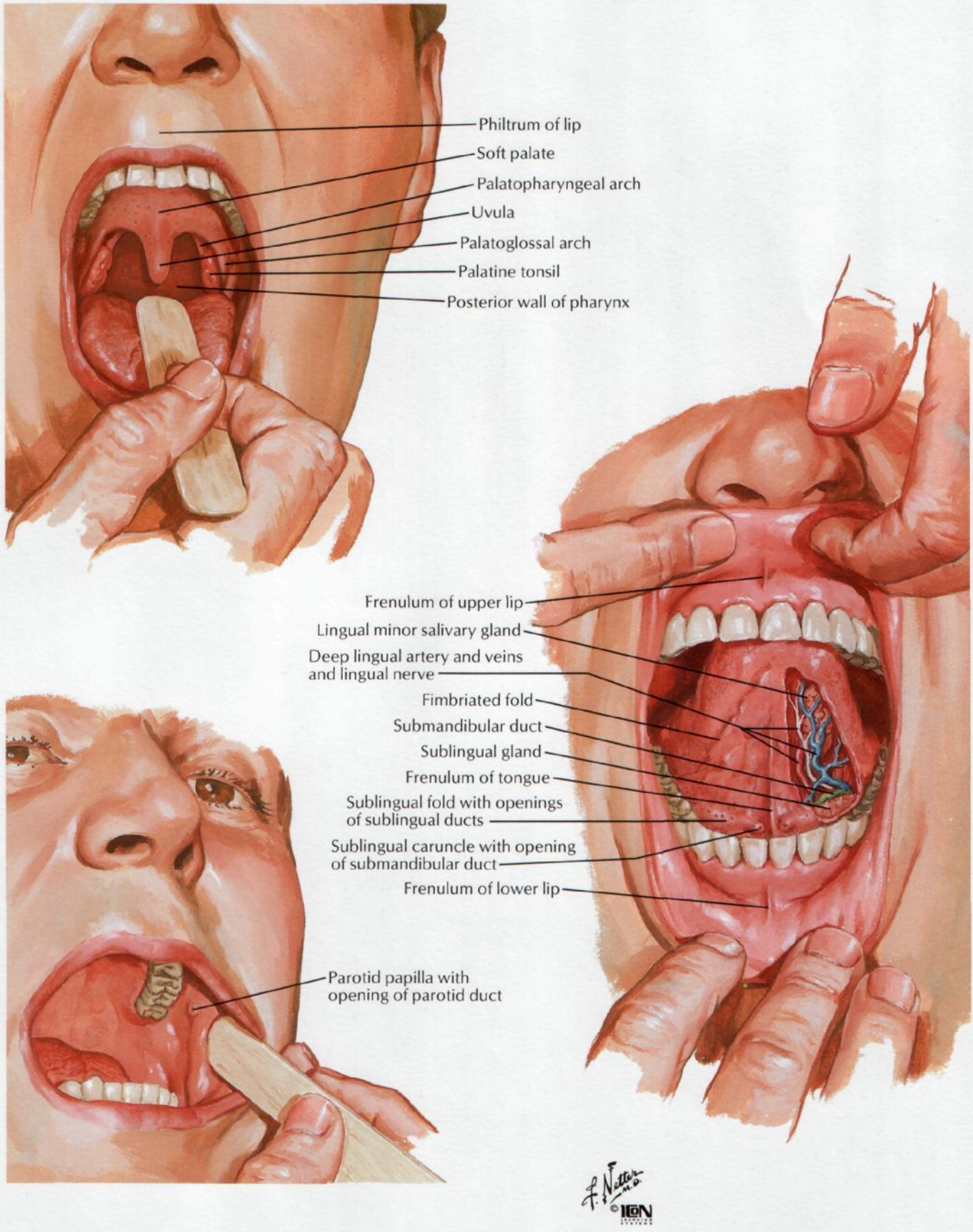
Philtrum of lip
Soft palate
Palatopharyngeal arch
Uvula
Palatoglossal arch
Palatine tonsil
Posterior wall of pharynx
Frenulum of upper lip
Lingual minor salivary gland
Deep lingual artery and veins and lingual nerve
Fimbriated fold
Submandibular duct
Sublingual gland
Frenulum of tongue
Sublingual fold with openings of sublingual ducts
Sublingual caruncle with opening of submandibular duct
Frenulum of lower lip
Parotid papilla with opening of parotid duct
F. Netter M.D.
©ICON

Roof of Mouth

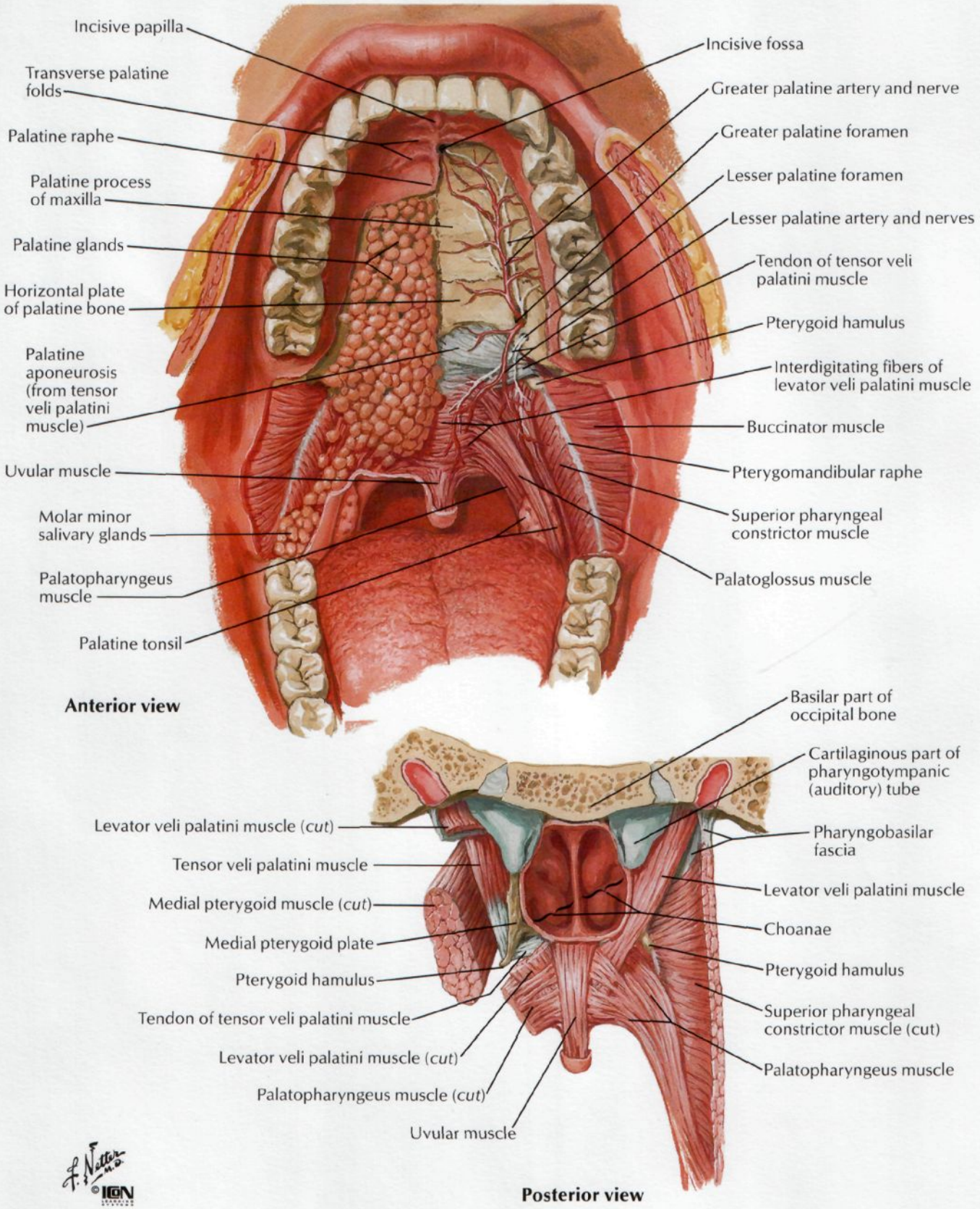

Floor of Mouth

SEE ALSO PLATE 25

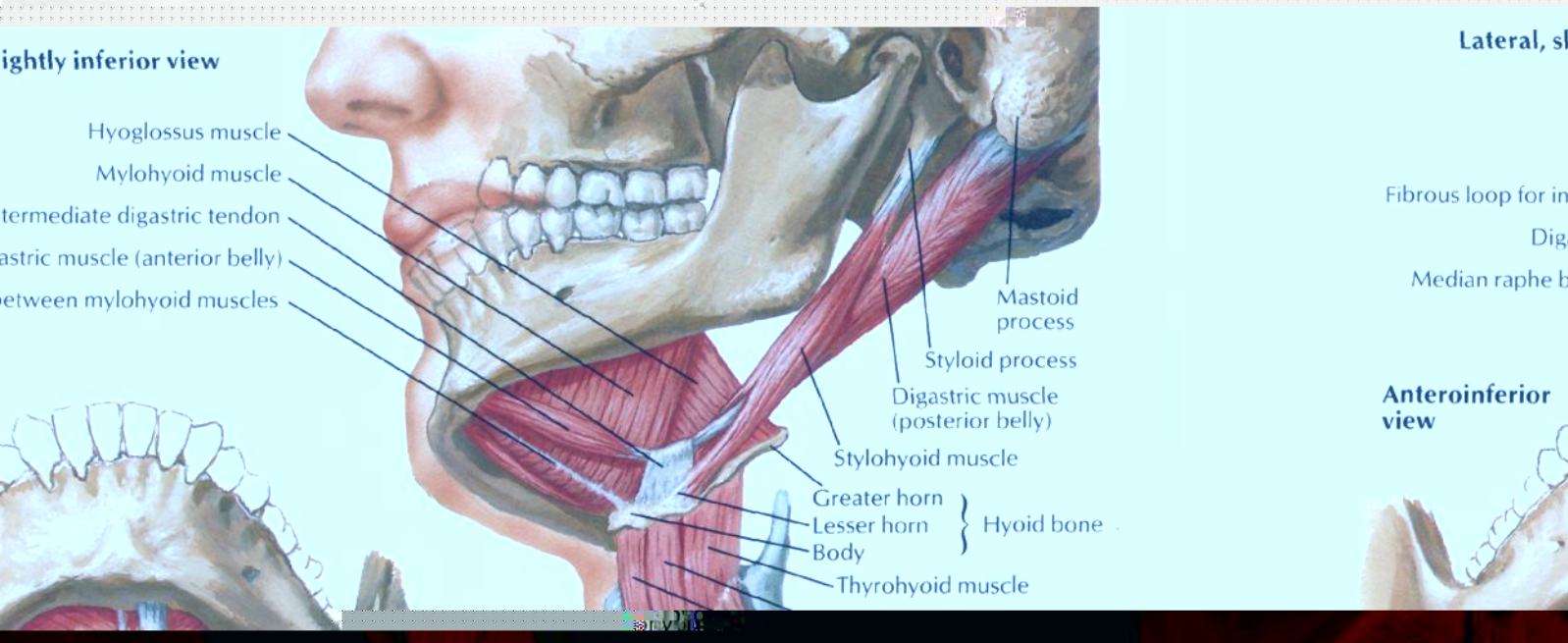

Muscles Involved in Mastication

FOR FACIAL MUSCLES SEE PLATE 22

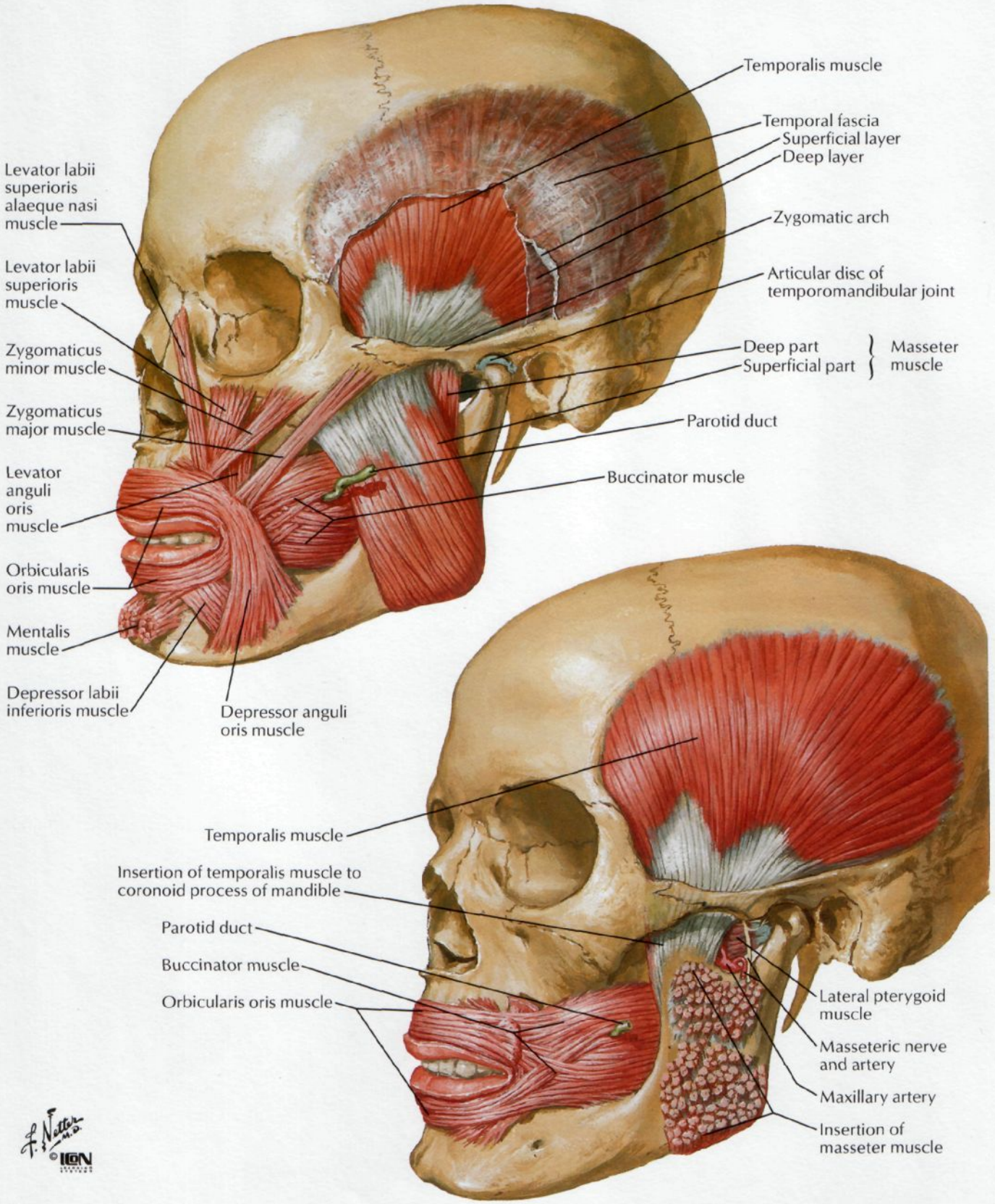

F. Netter M.D. ©IGN

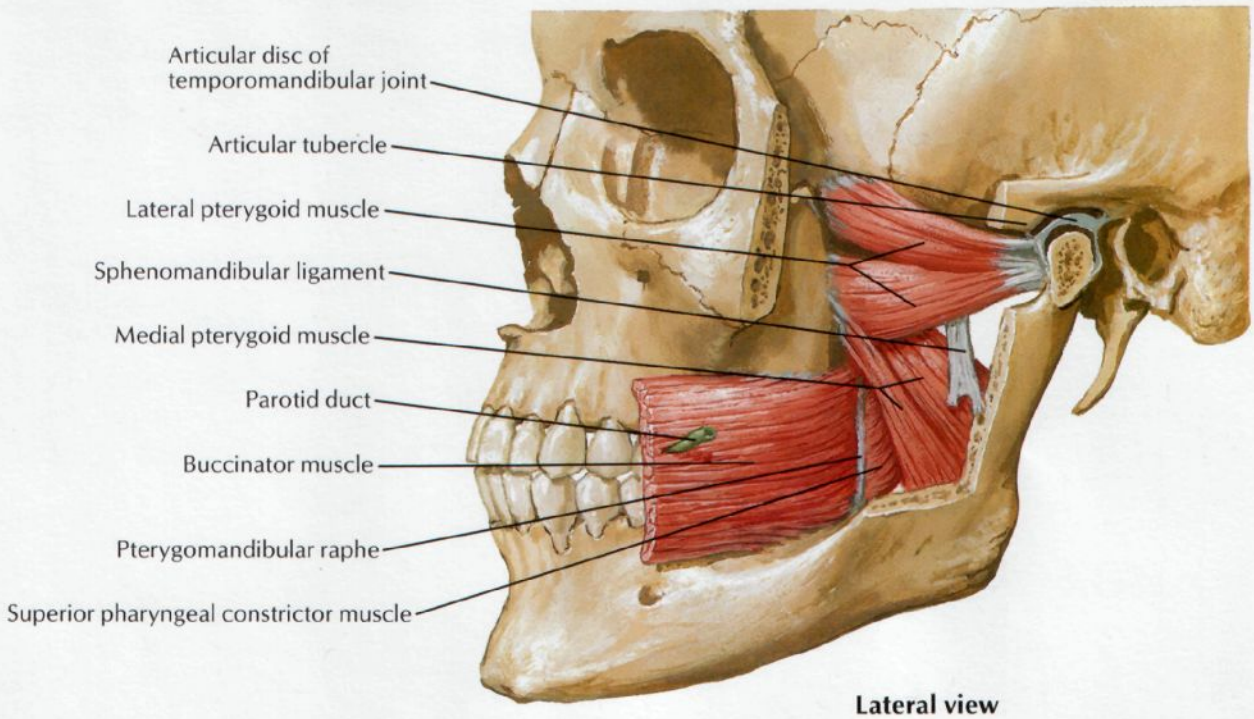

Lateral view

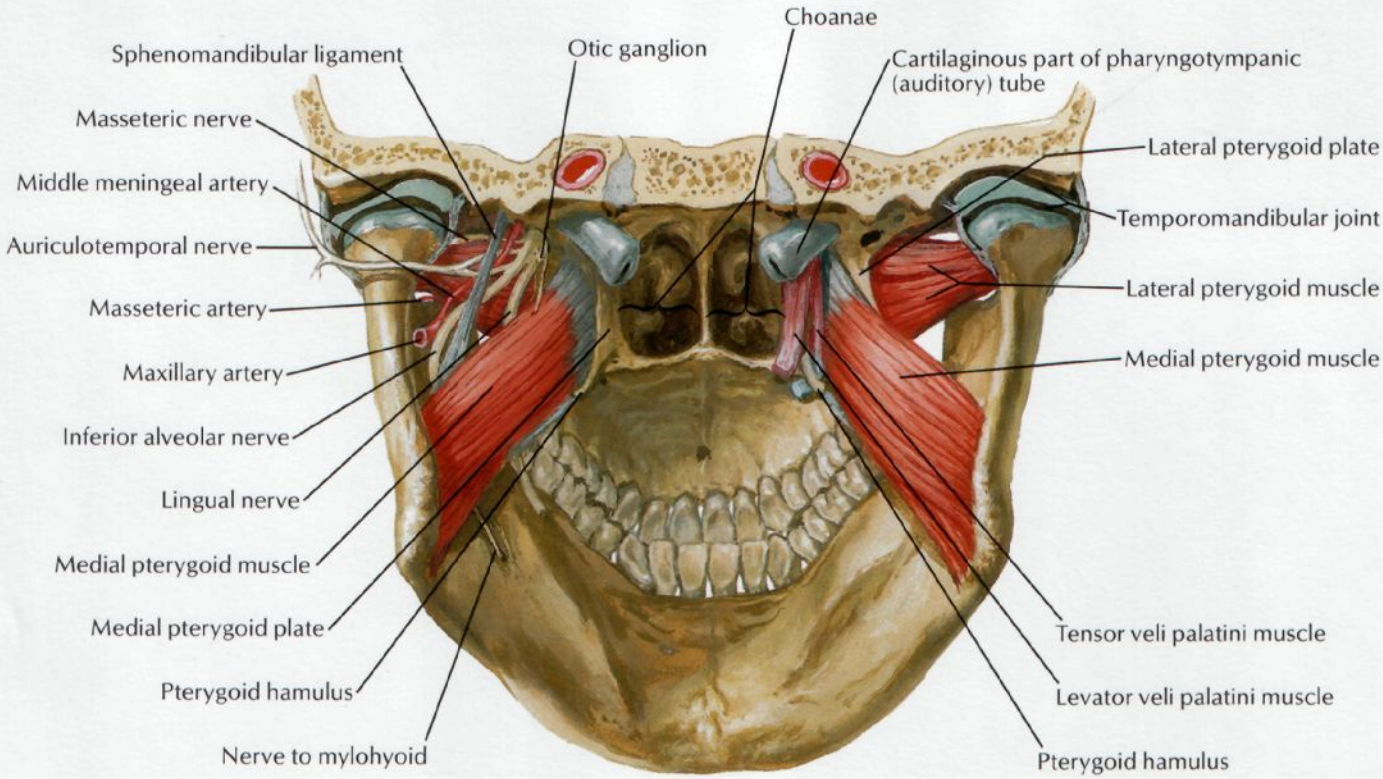

Posterior view

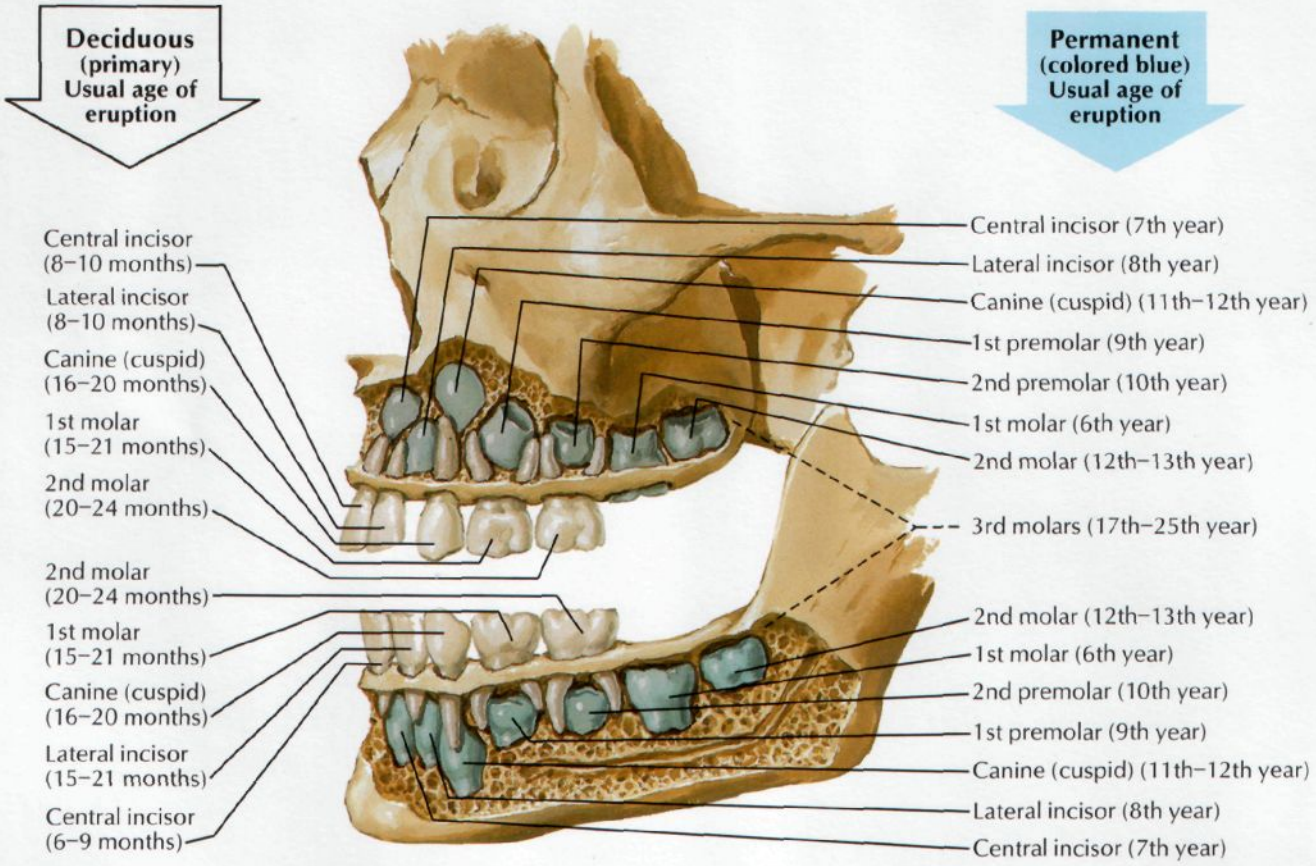

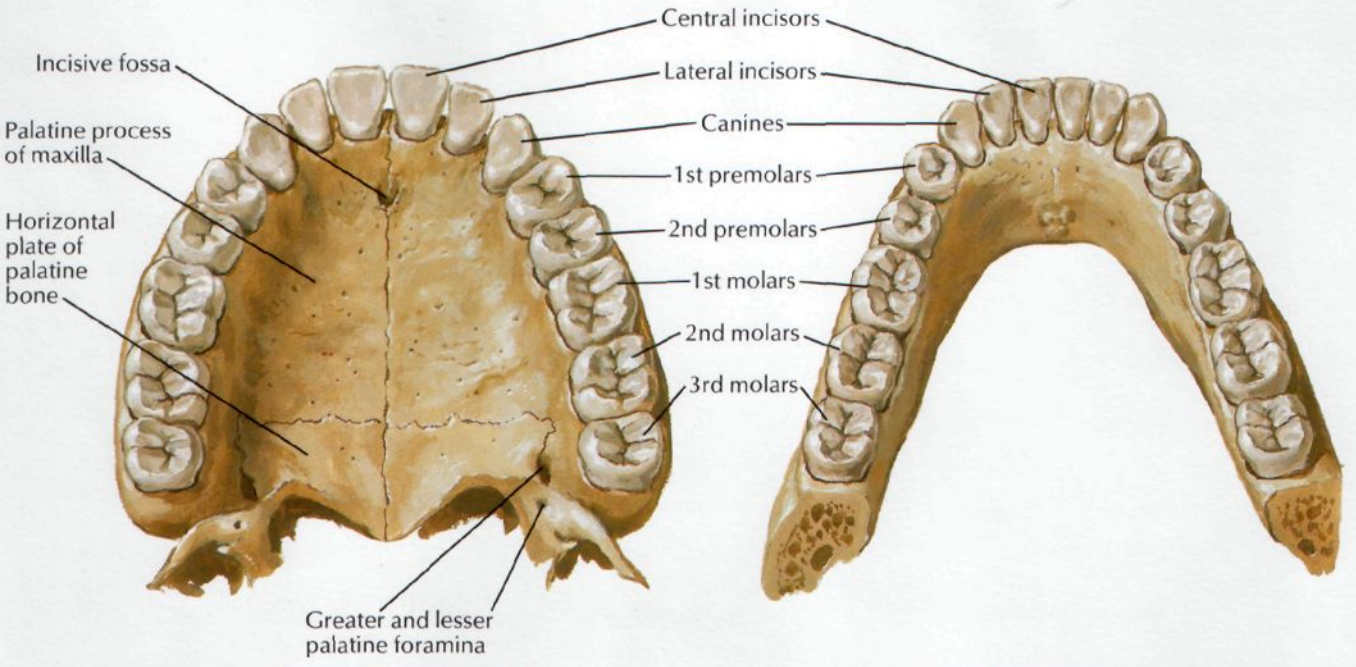

Upper permanent teeth **Lower permanent teeth**

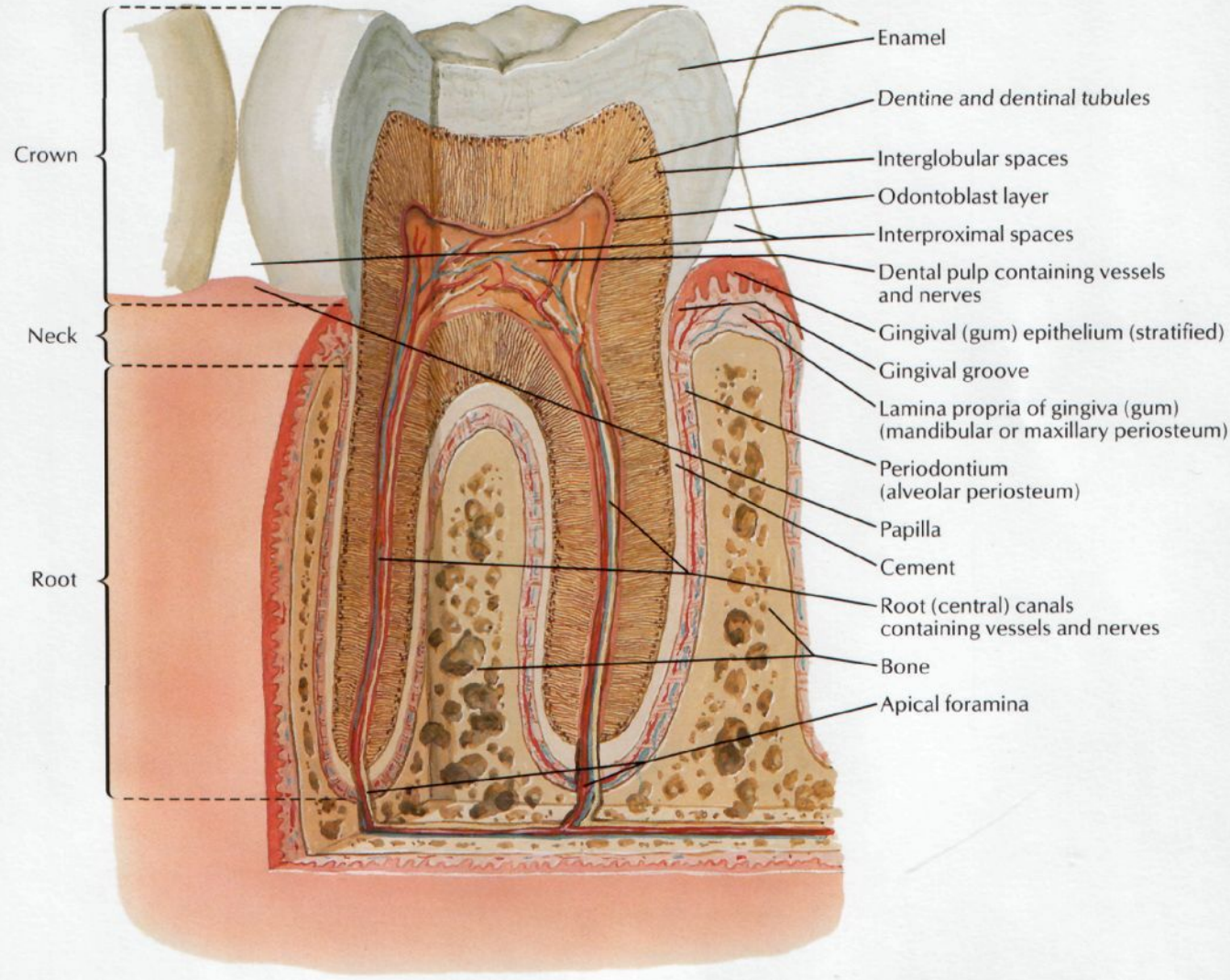
Crown
Neck
Root
Enamel
Dentine and dentinal tubules
Interglobular spaces
Odontoblast layer
Interproximal spaces
Dental pulp containing vessels and nerves
Gingival (gum) epithelium (stratified)
Gingival groove
Lamina propria of gingiva (gum) (mandibular or maxillary periosteum)
Periodontium (alveolar periosteum)
Papilla
Cement
Root (central) canals containing vessels and nerves
Bone
Apical foramina

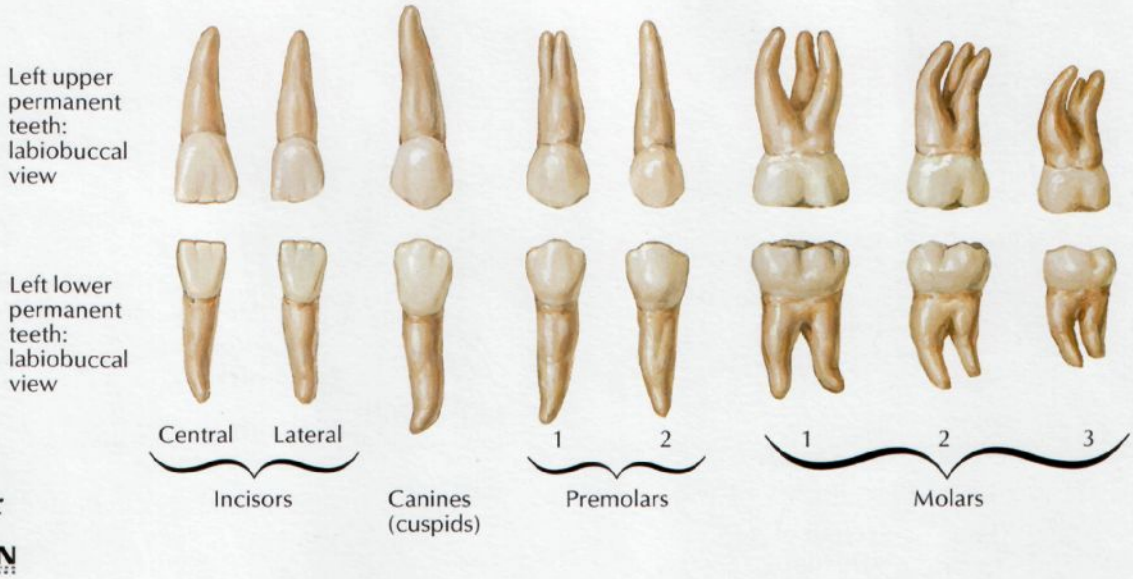
Left upper permanent teeth: labiobuccal view
Left lower permanent teeth: labiobuccal view
Central
Lateral
Incisors
Canines (cuspids)
1
2
Premolars
1
2
3
Molars

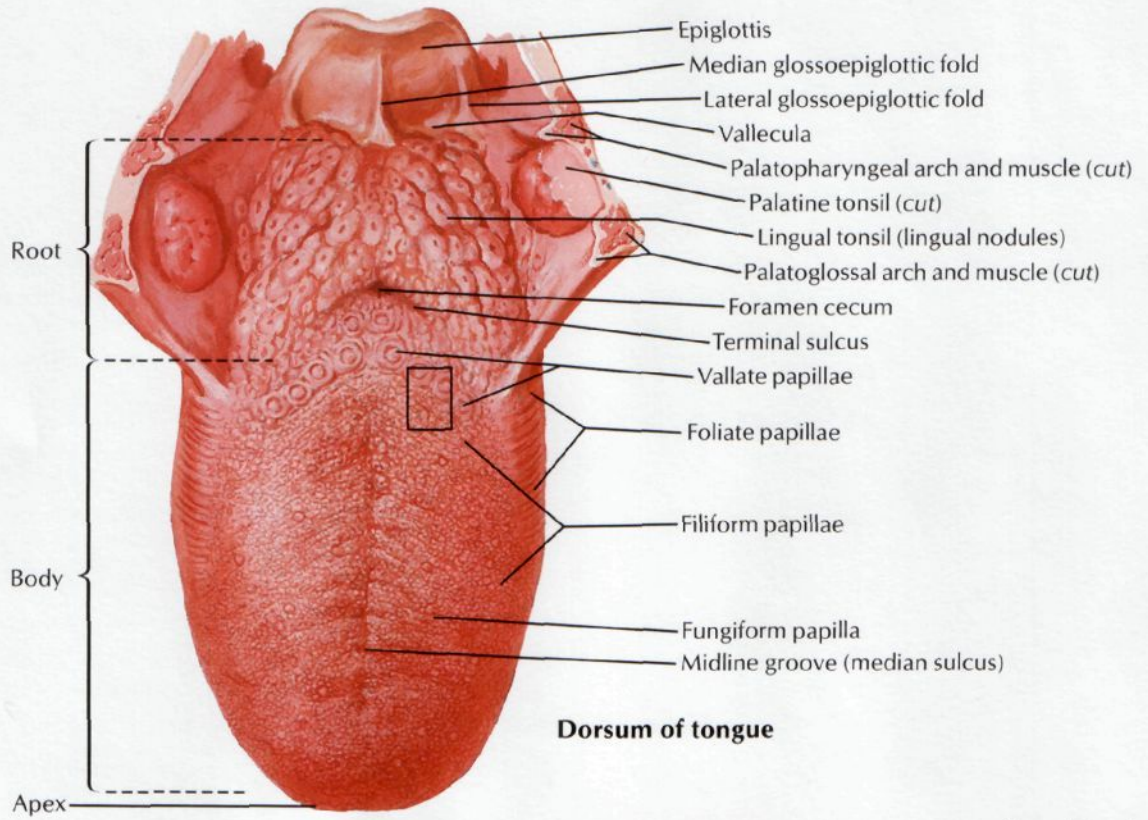

Dorsum of tongue

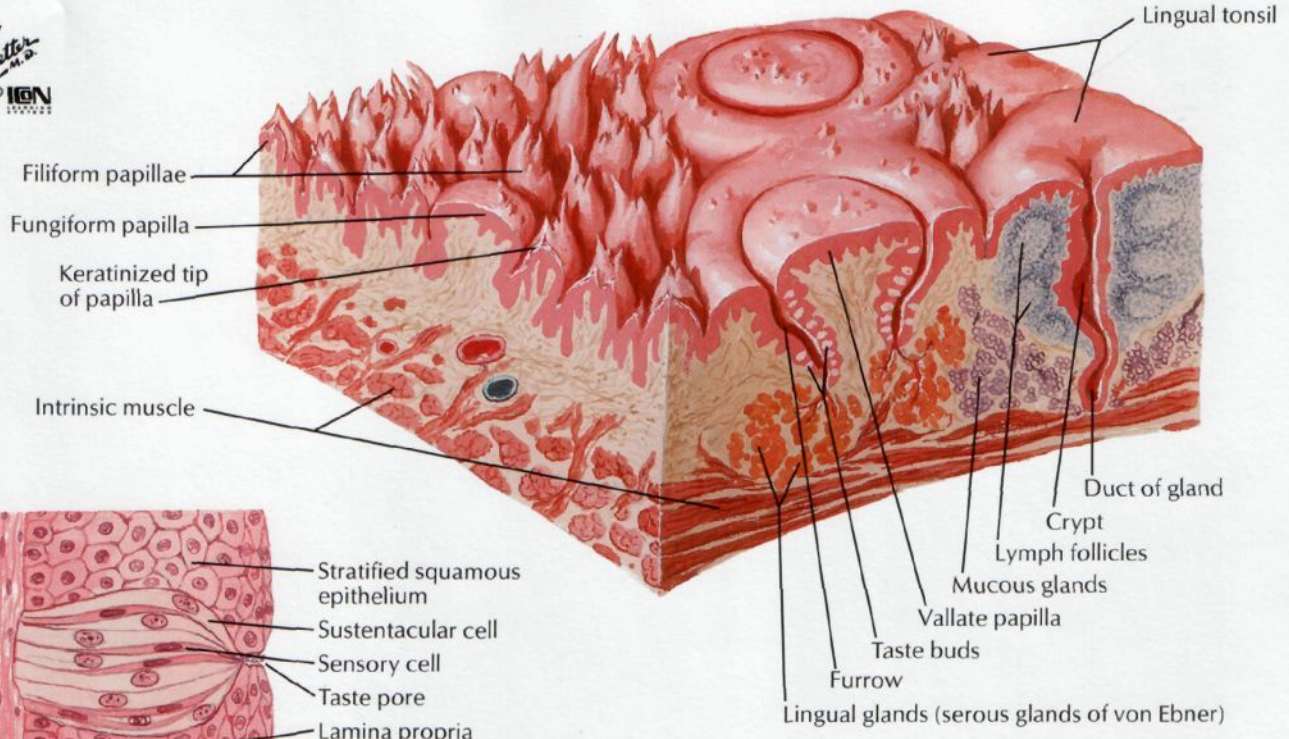

Schematic stereogram: area indicated above

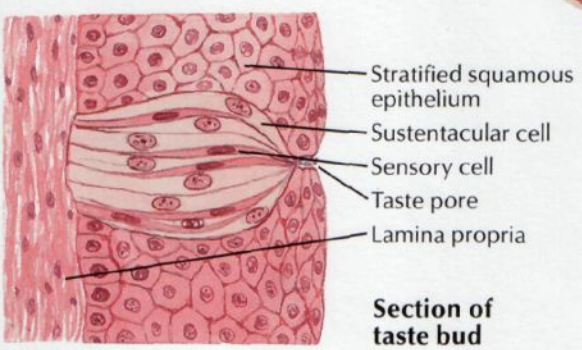

Section of taste bud

SEE ALSO PLATES 30, 42, 49, 122

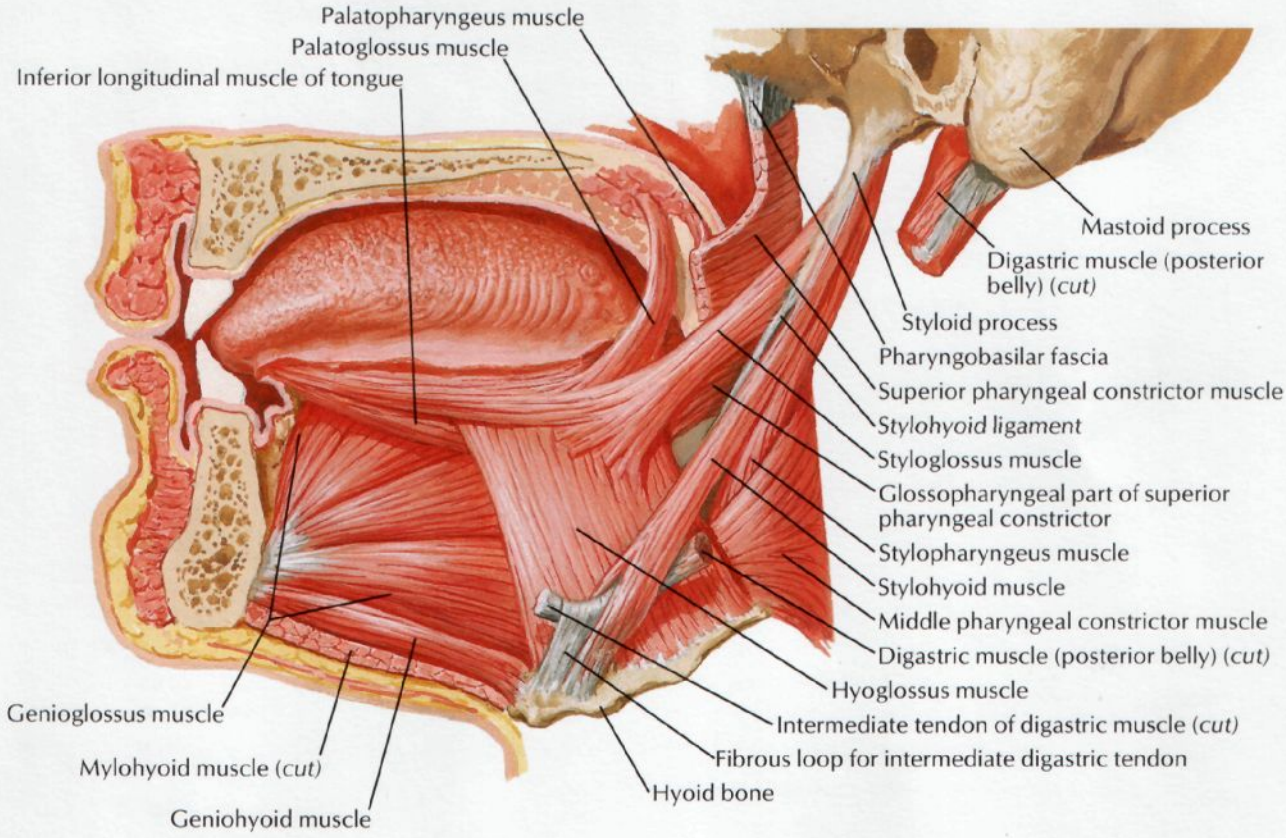

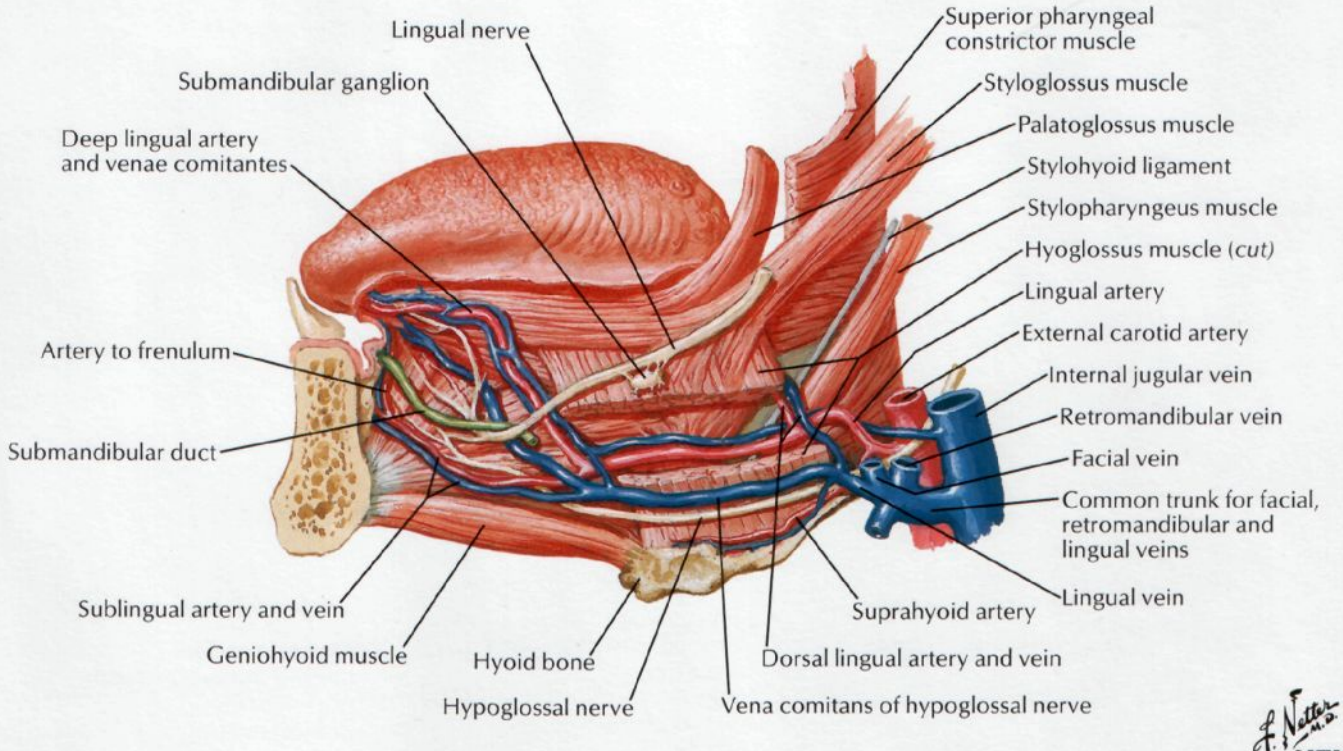

Tongue and Salivary Glands: Sections

Horizontal section below lingula of mandible (superior view) demonstrating bed of parotid gland

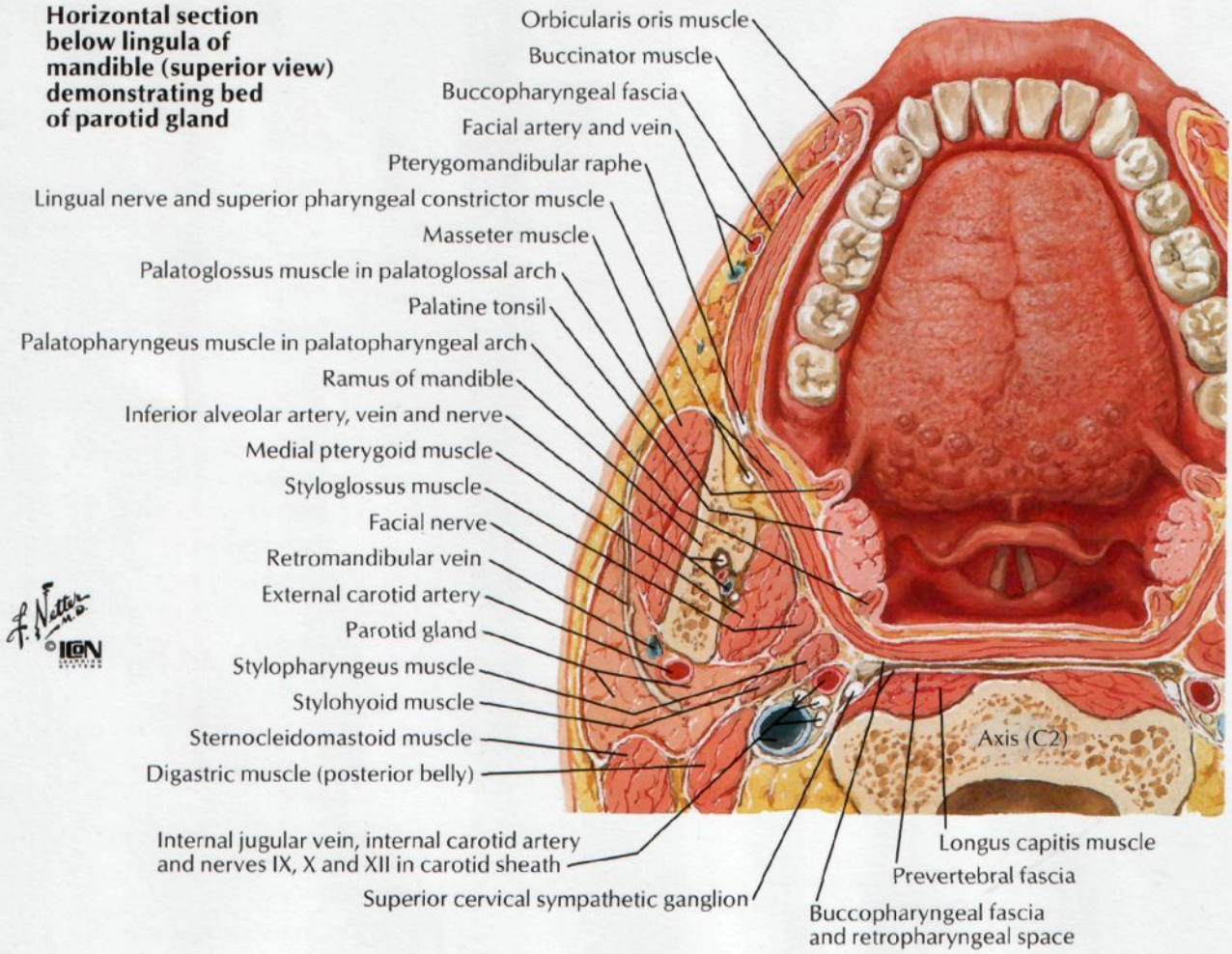

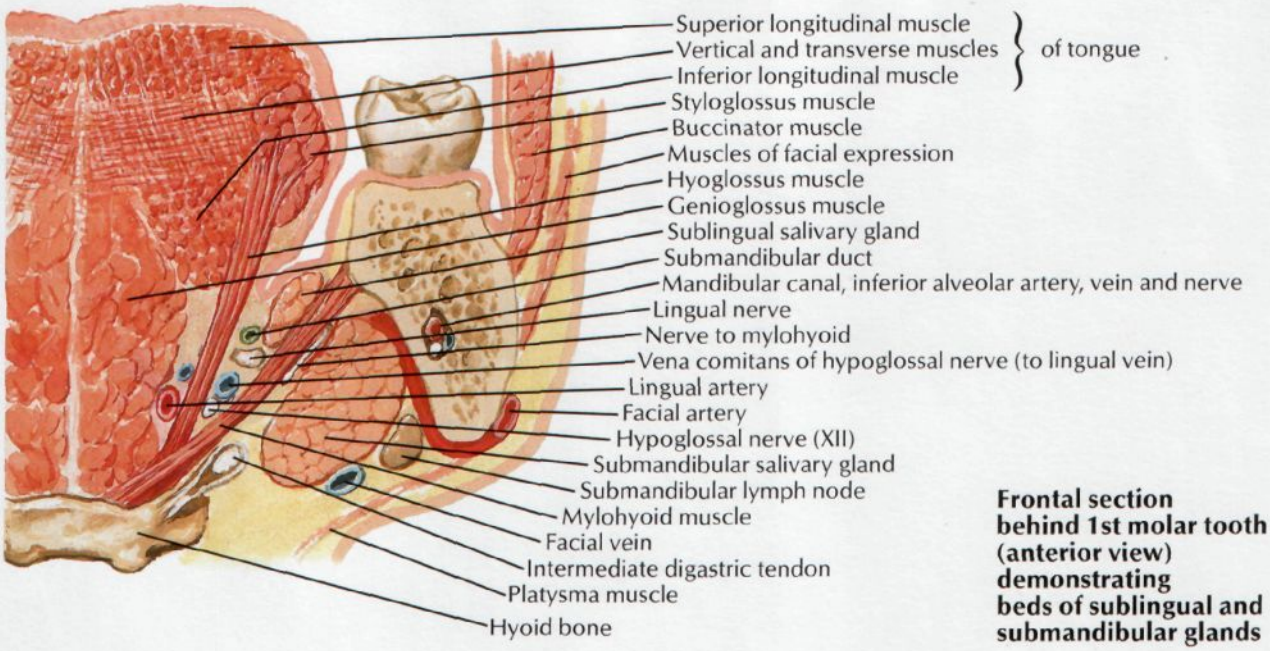

Frontal section behind 1st molar tooth (anterior view) demonstrating beds of sublingual and submandibular glands

SEE ALSO PLATES 21, 49, 127, 128, 160

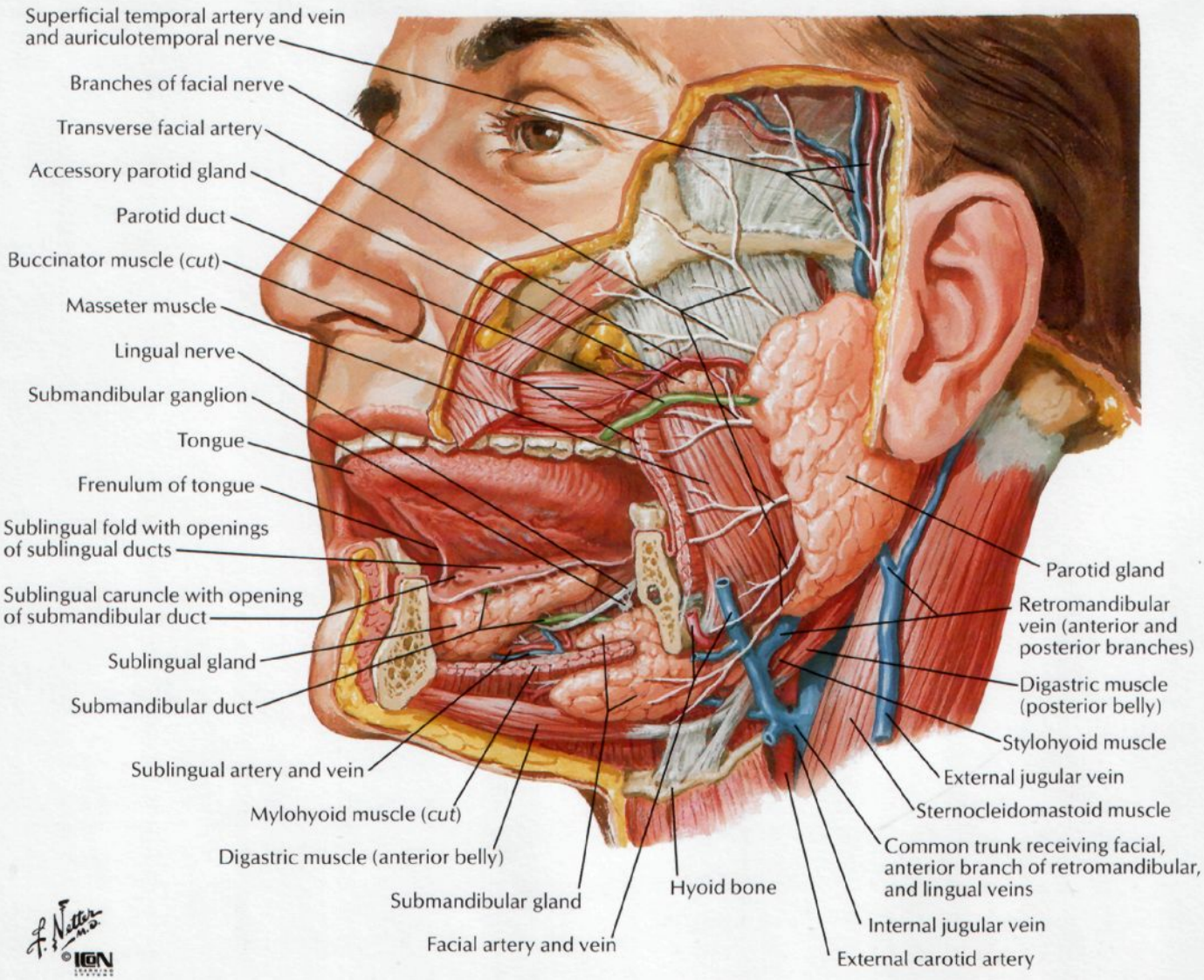

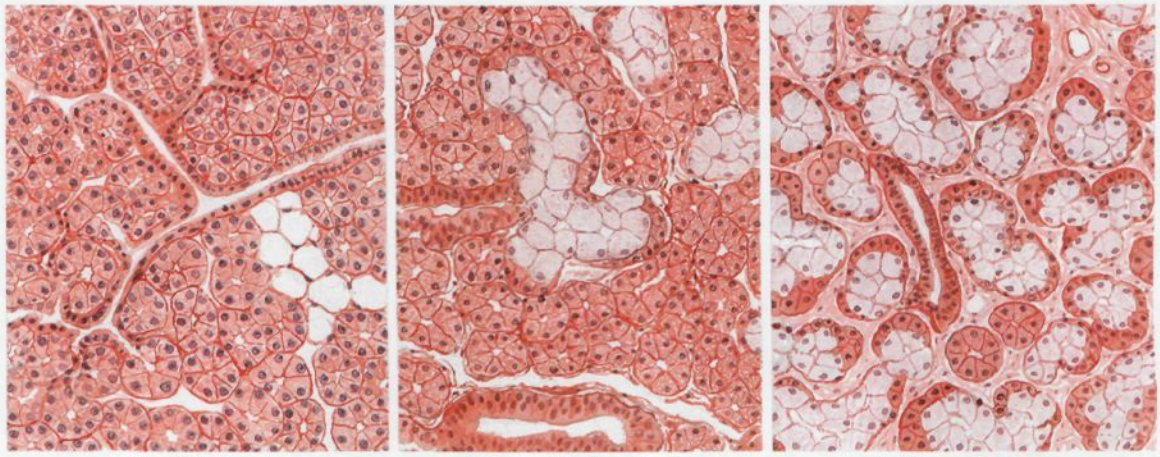

Parotid gland: totally serous

Submandibular gland: mostly serous, partially mucous

Sublingual gland: almost completely mucous

Afferent Innervation of Mouth and Pharynx

SEE ALSO PLATES 42, 48, 55, 60, 116, 117, 119, 127, 129

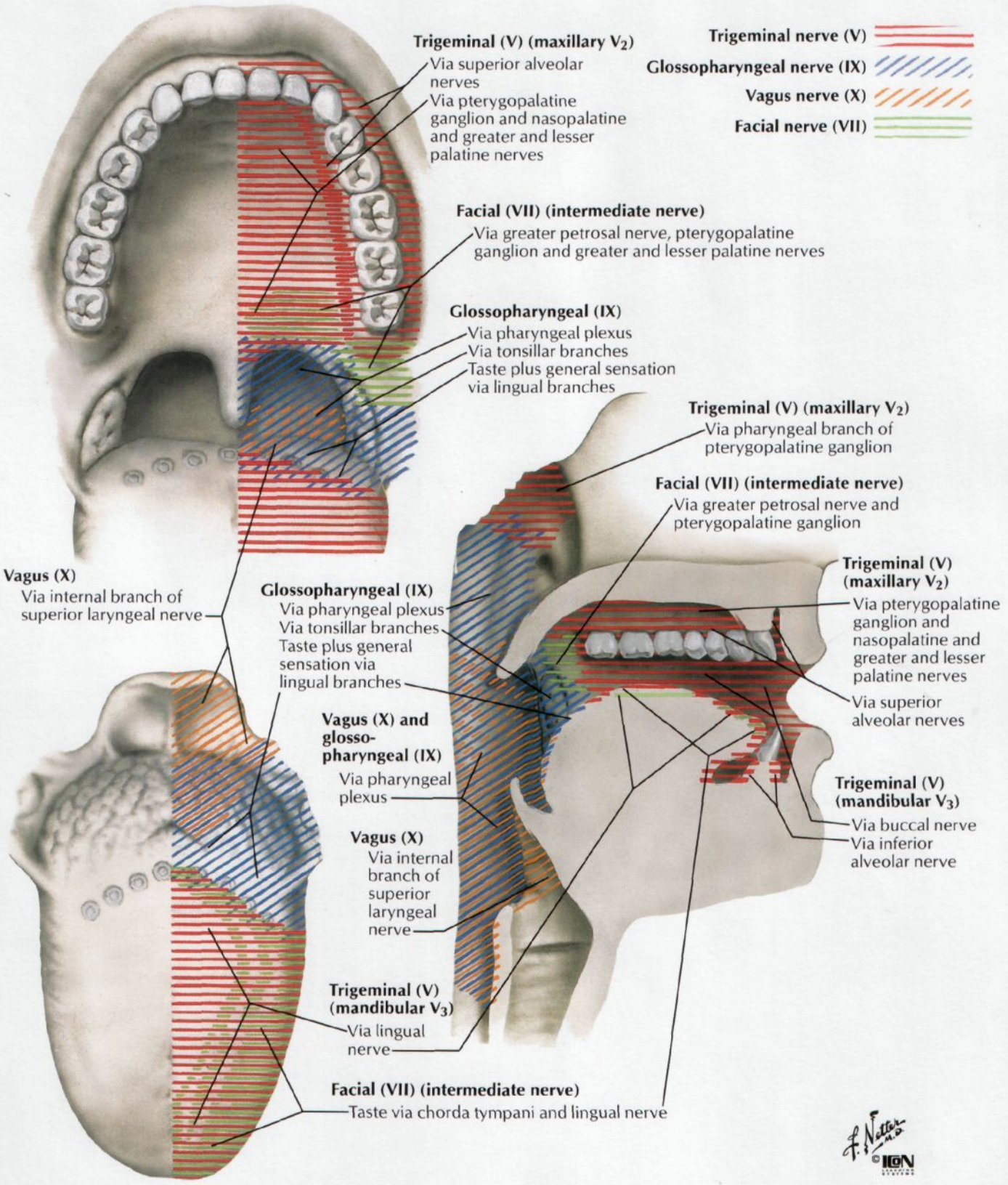

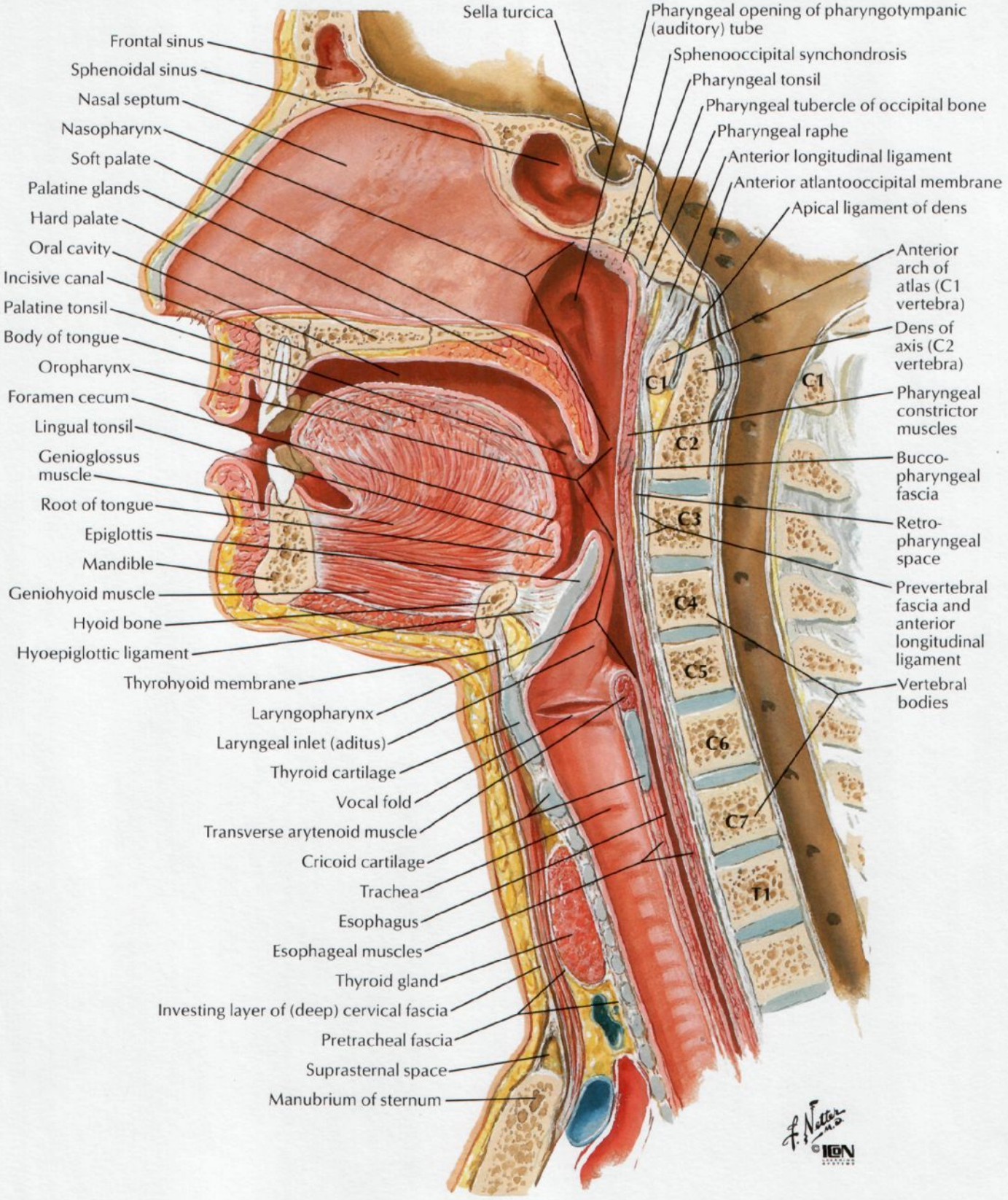
Sella turcica
Pharyngeal opening of pharyngotympanic (auditory) tube
Sphenooccipital synchondrosis
Pharyngeal tonsil
Pharyngeal tubercle of occipital bone
Pharyngeal raphe
Anterior longitudinal ligament
Anterior atlantooccipital membrane
Apical ligament of dens
Frontal sinus
Sphenoidal sinus
Nasal septum
Nasopharynx
Soft palate
Palatine glands
Hard palate
Oral cavity
Incisive canal
Palatine tonsil
Body of tongue
Oropharynx
Foramen cecum
Lingual tonsil
Genioglossus muscle
Root of tongue
Epiglottis
Mandible
Geniohyoid muscle
Hyoid bone
Hyoepiglottic ligament
Thyrohyoid membrane
Laryngopharynx
Laryngeal inlet (aditus)
Thyroid cartilage
Vocal fold
Transverse arytenoid muscle
Cricoid cartilage
Trachea
Esophagus
Esophageal muscles
Thyroid gland
Investing layer of (deep) cervical fascia
Pretracheal fascia
Suprasternal space
Manubrium of sternum
Anterior arch of atlas (C1 vertebra)
Dens of axis (C2 vertebra)
Pharyngeal constrictor muscles
Buccopharyngeal fascia
Retropharyngeal space
Prevertebral fascia and anterior longitudinal ligament
Vertebral bodies
C1
C1
C2
C3
C4
C5
C6
C7
T1
F. Netter M.D.
©IGN

Fauces

Medial view
Median (sagittal) section

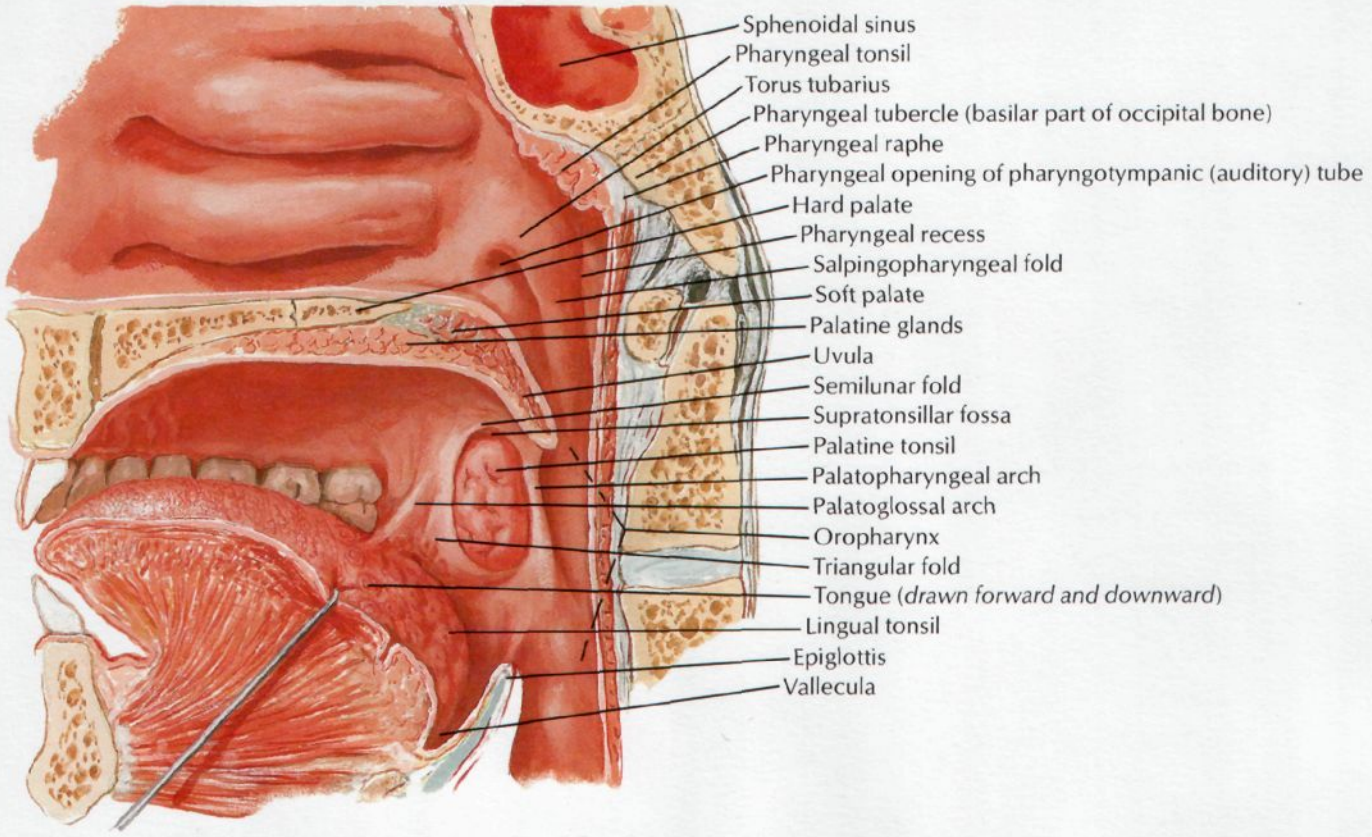

Pharyngeal mucosa removed

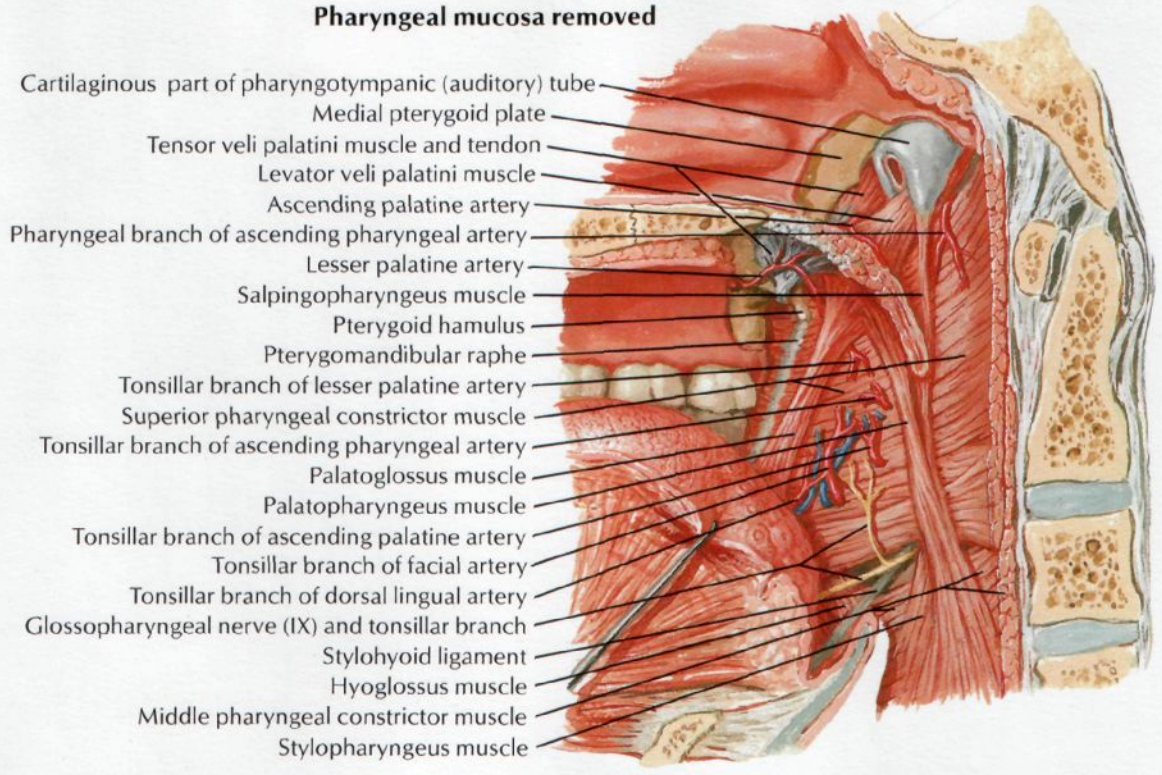

F. Netter M.D. ©IGN

Muscles of Pharynx: Median (Sagittal) Section

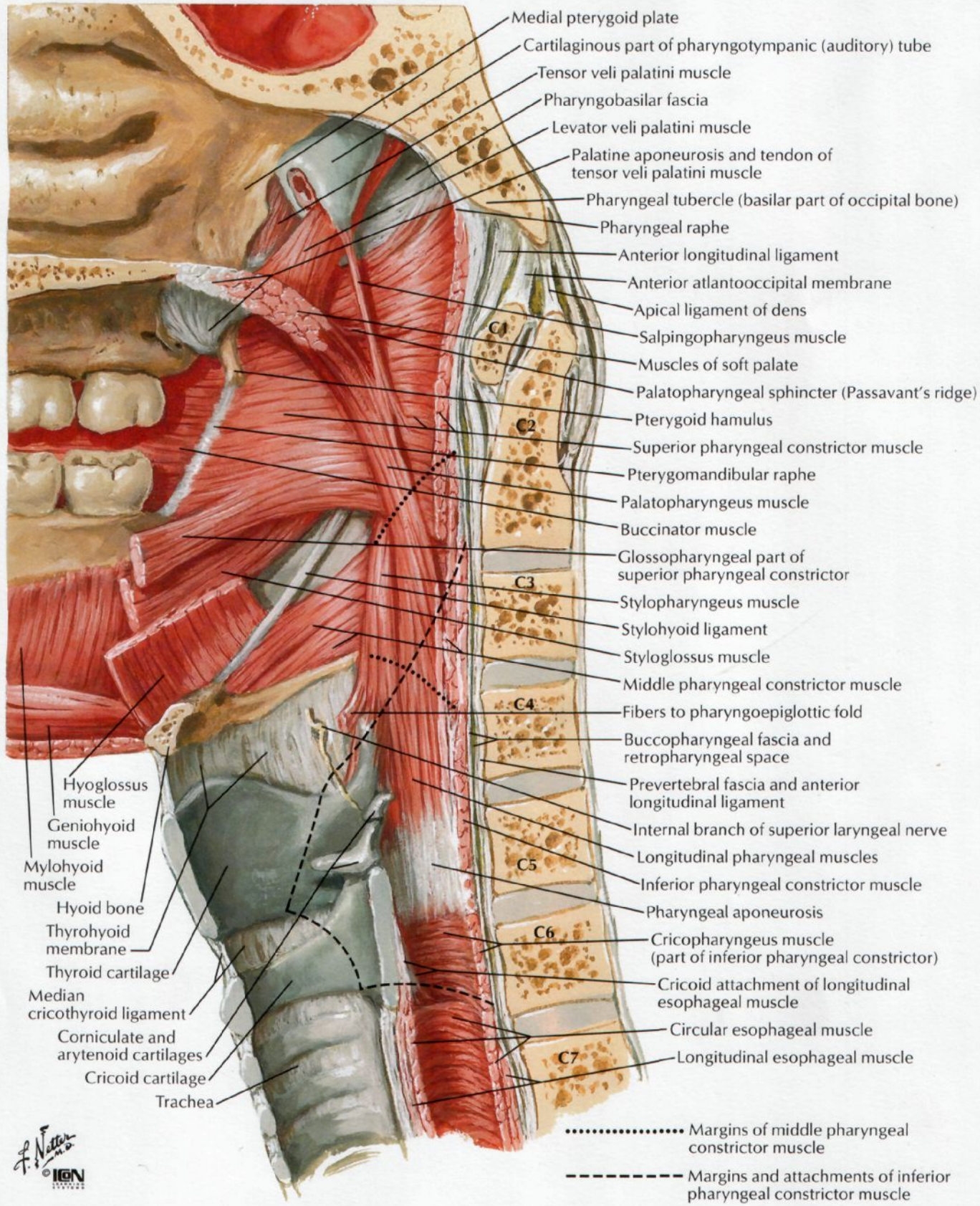

F. Netter M.D.
©IGN

Pharynx: Opened Posterior View

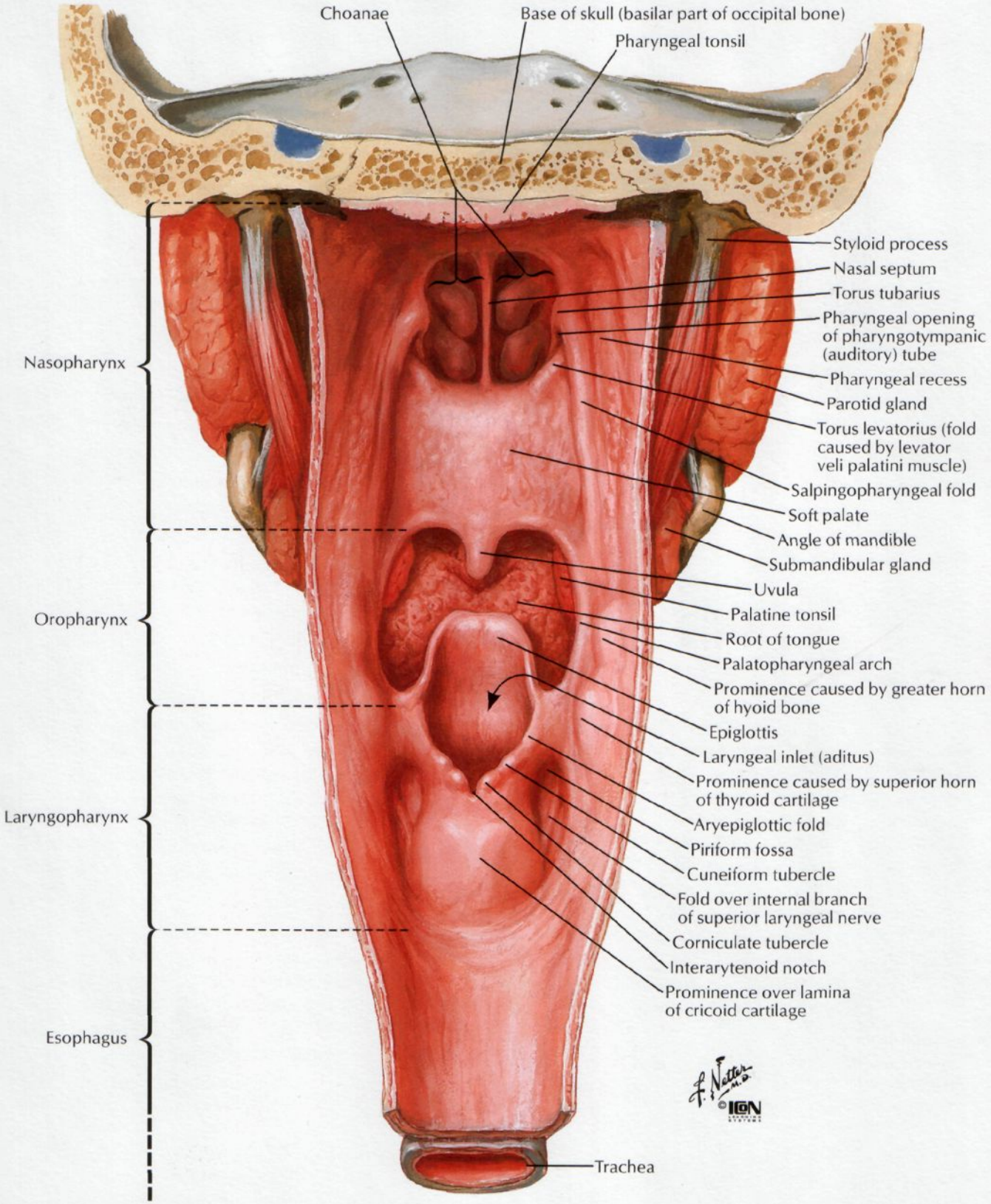

Muscles of Pharynx: Partially Opened Posterior View

SEE ALSO PLATE 231

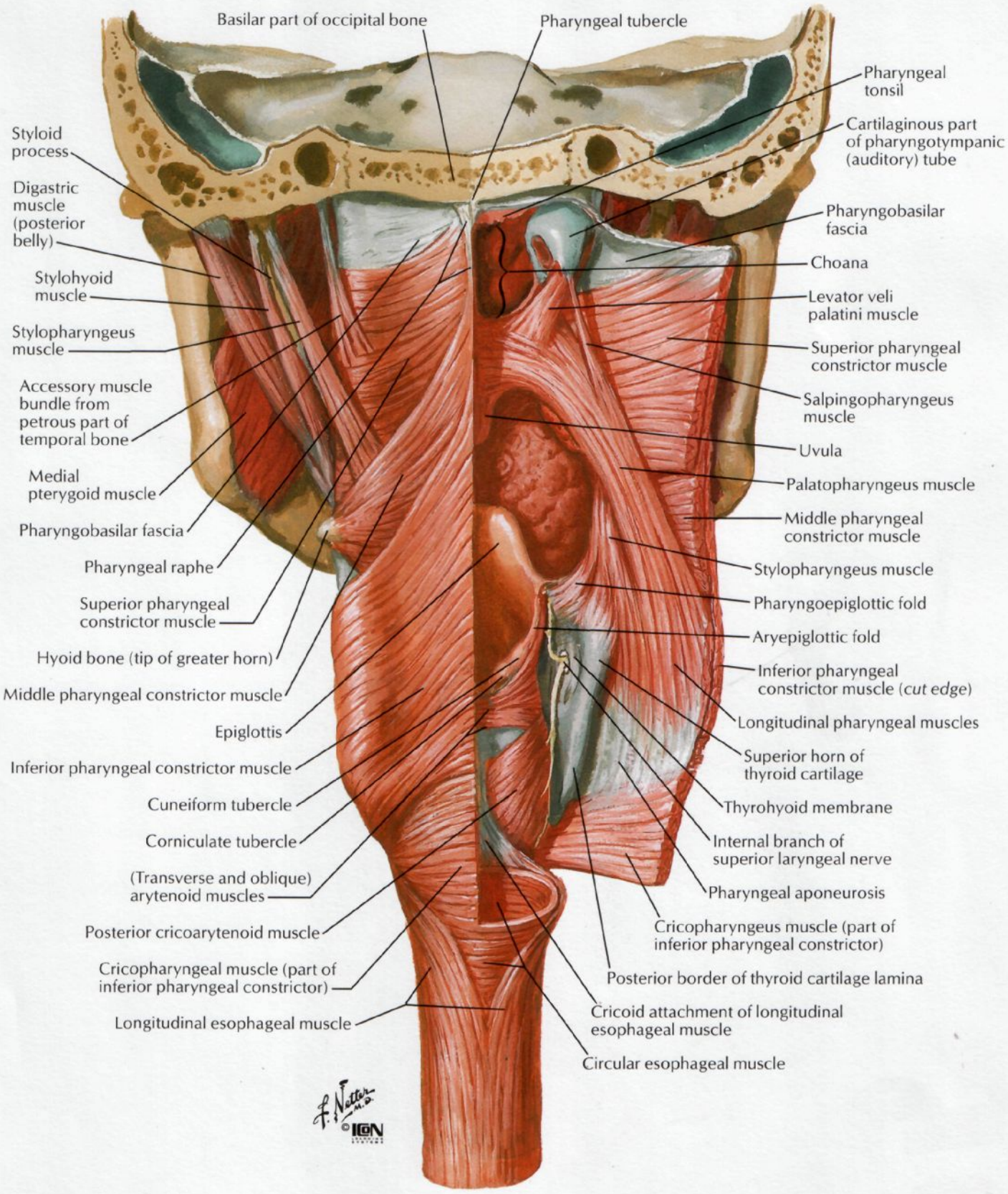

Pharynx: Opened Posterior View

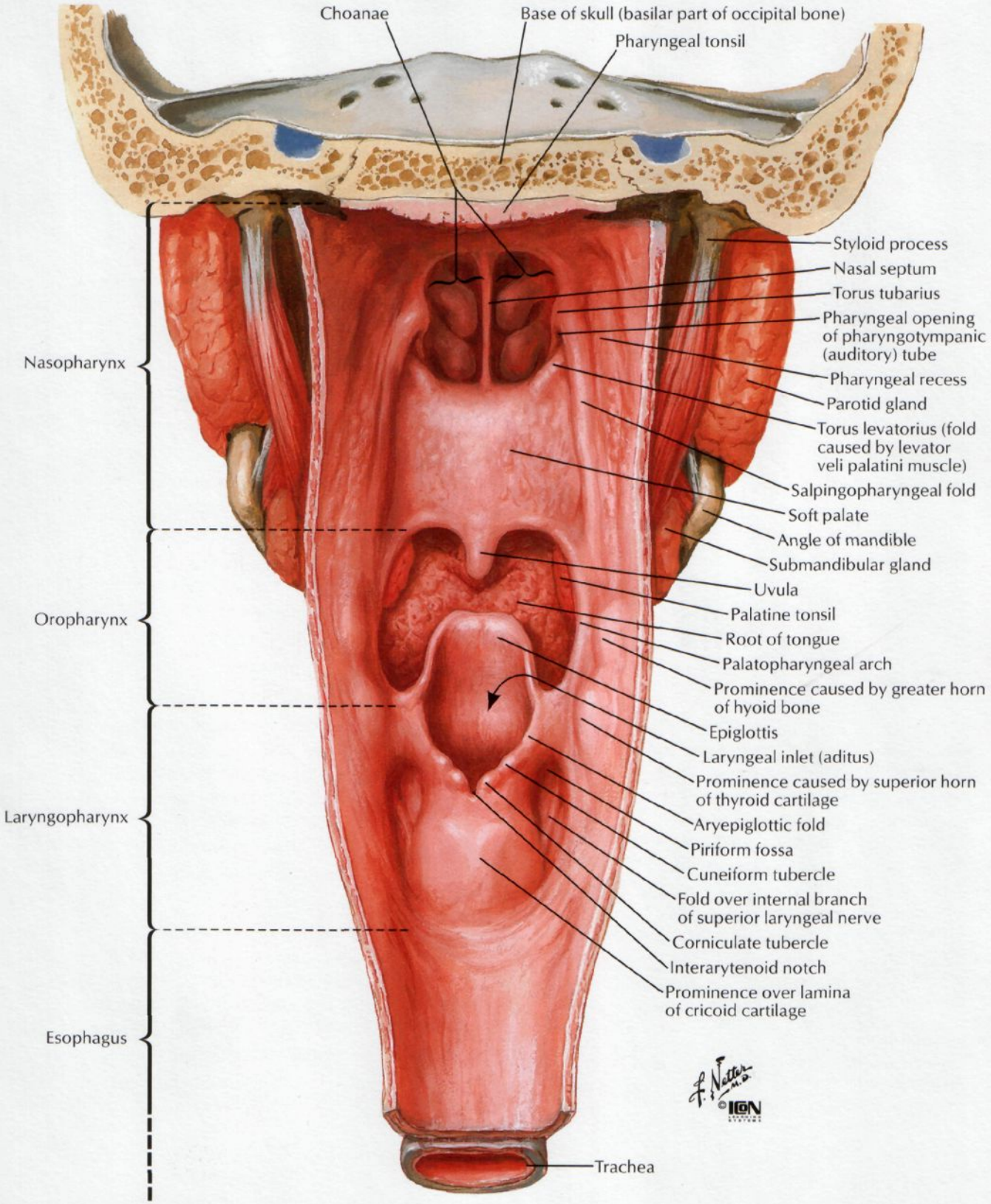

Muscles of Pharynx: Partially Opened Posterior View

SEE ALSO PLATE 231

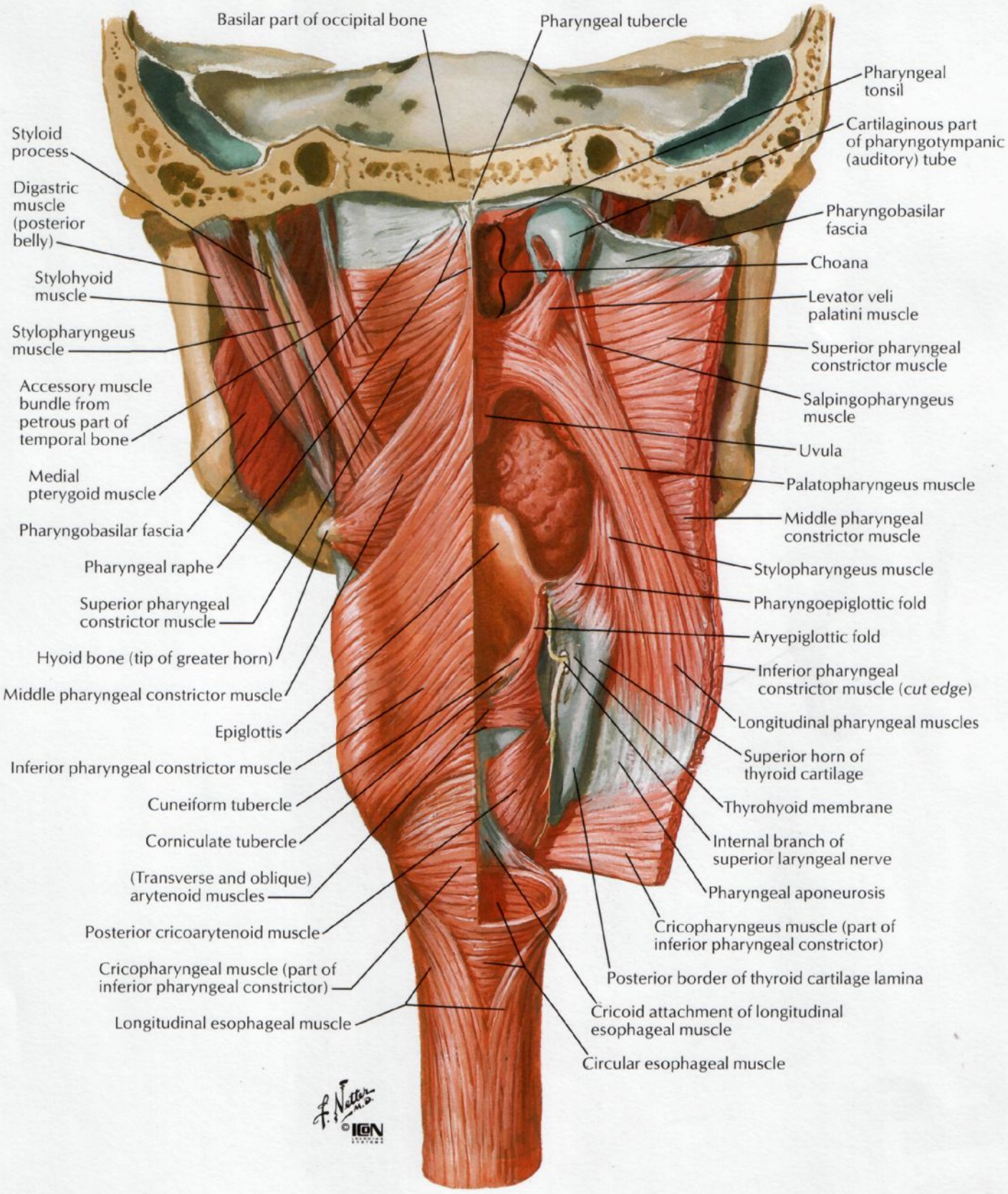

Muscles of Pharynx: Lateral View

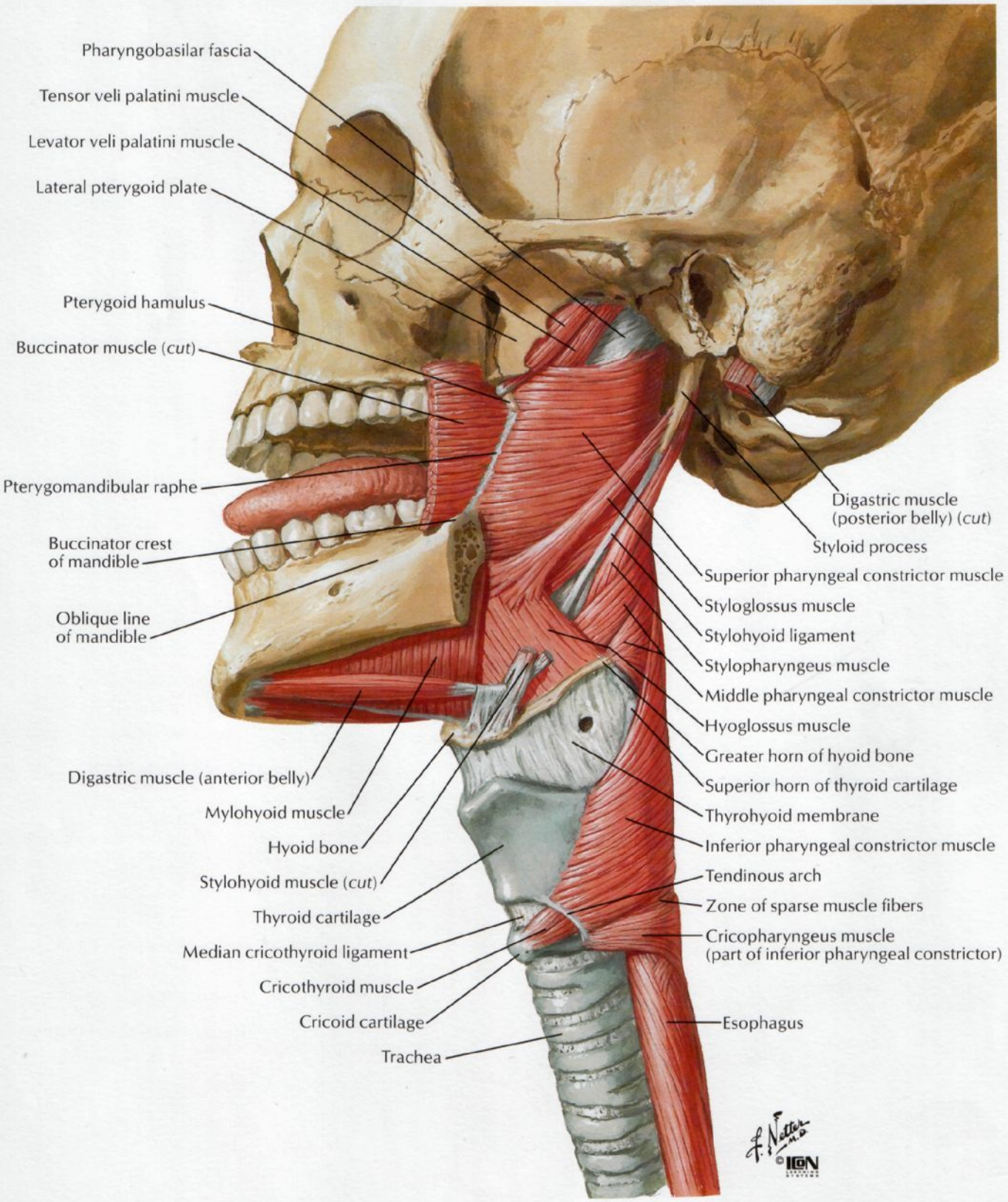

Arteries of Oral and Pharyngeal Regions

SEE ALSO PLATES 30, 36

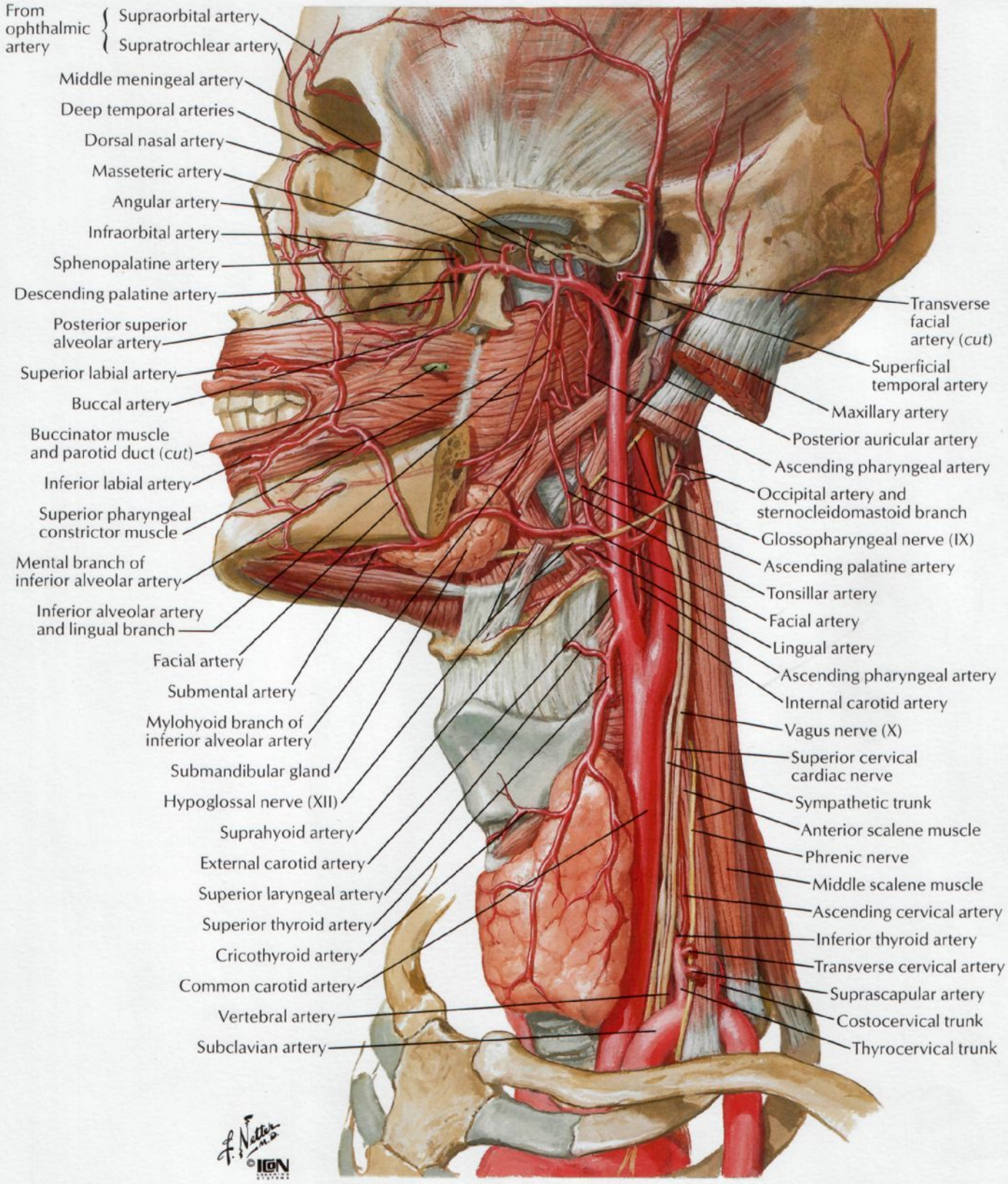

Veins of Oral and Pharyngeal Regions

SEE ALSO PLATES 19, 27, 98

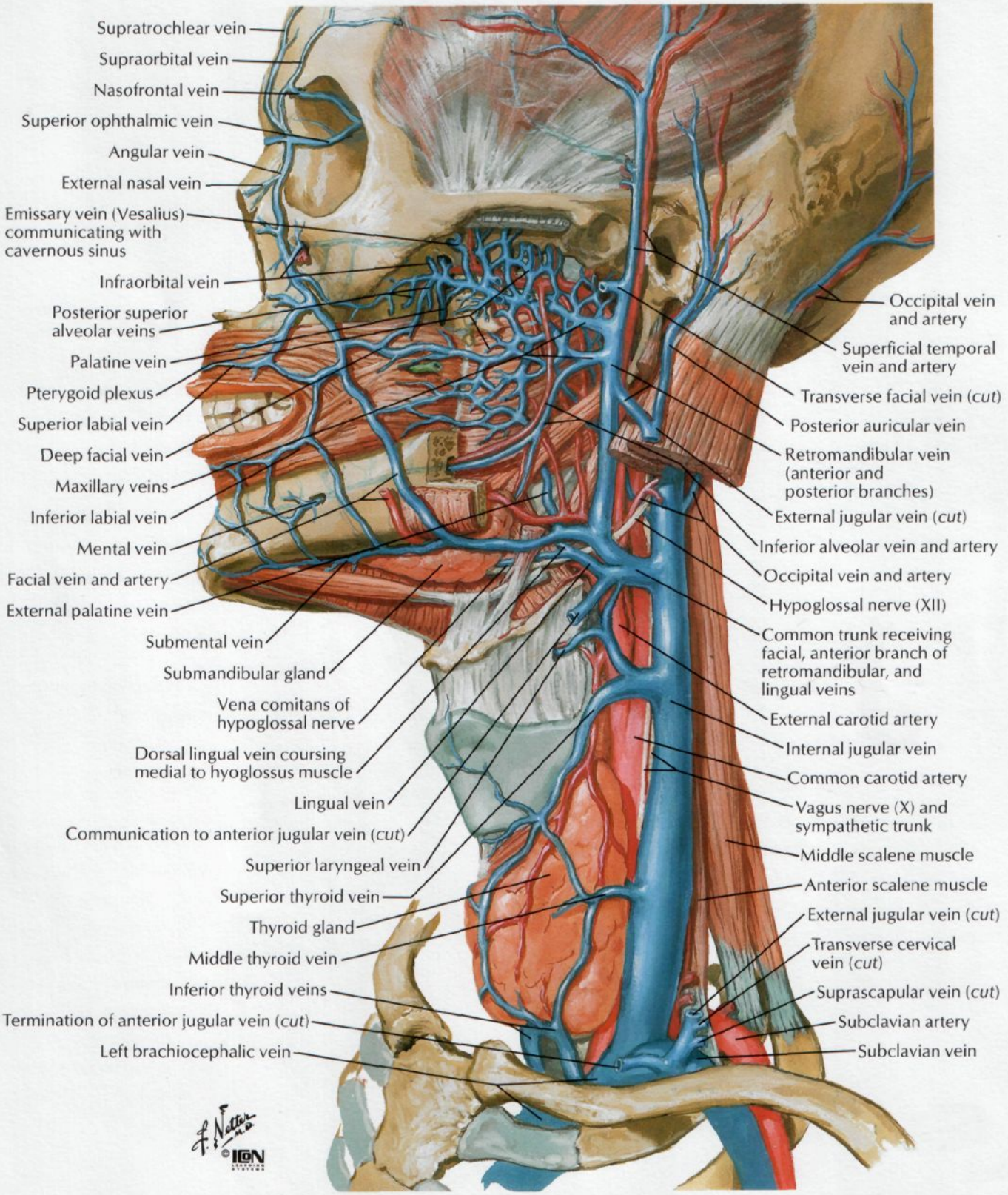

SEE ALSO PLATES 21, 41, 42, 116, 119, 120

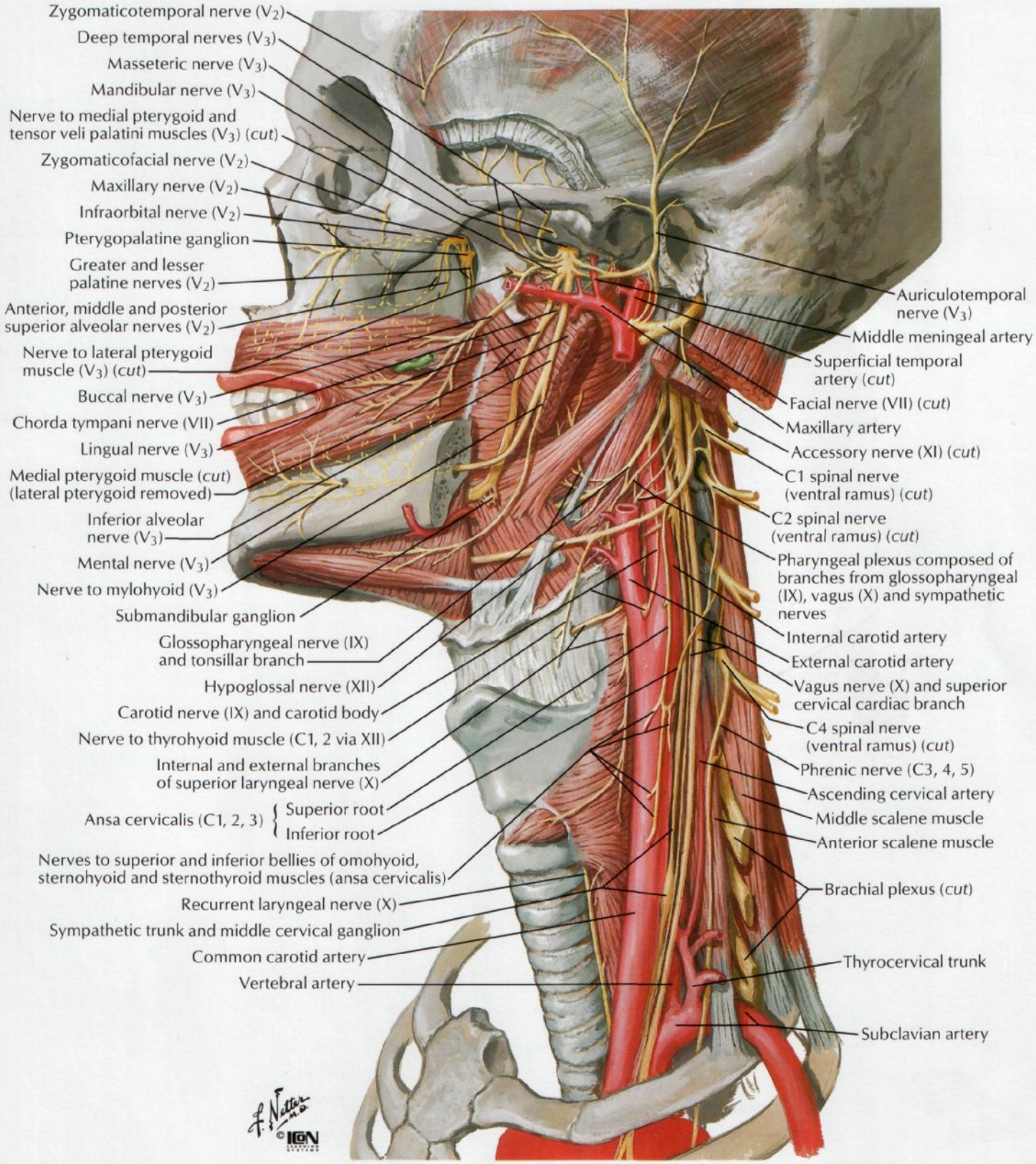

Lymph Vessels and Nodes of Head and Neck

SEE ALSO PLATE 204

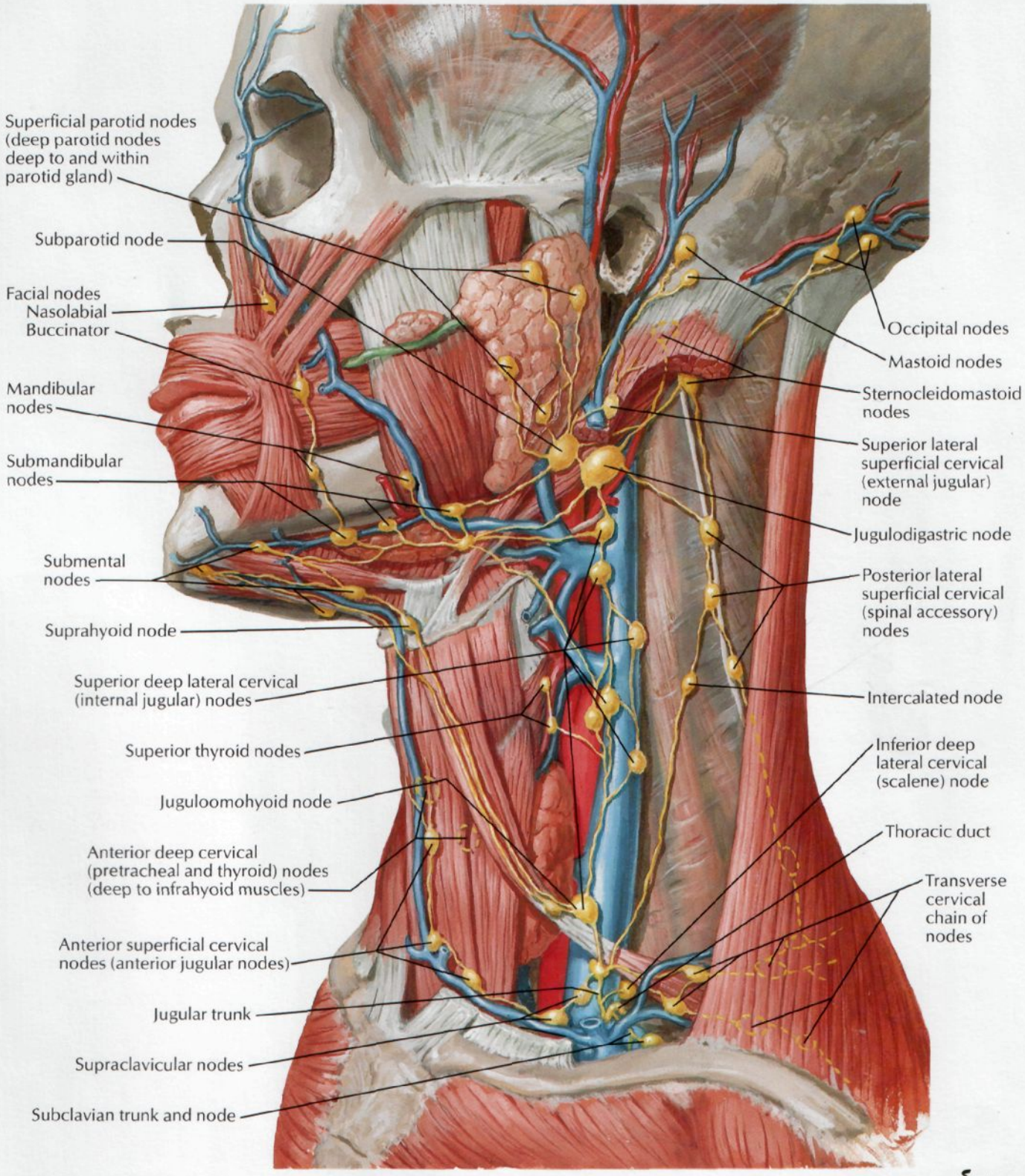

Lymph Vessels and Nodes of Pharynx and Tongue

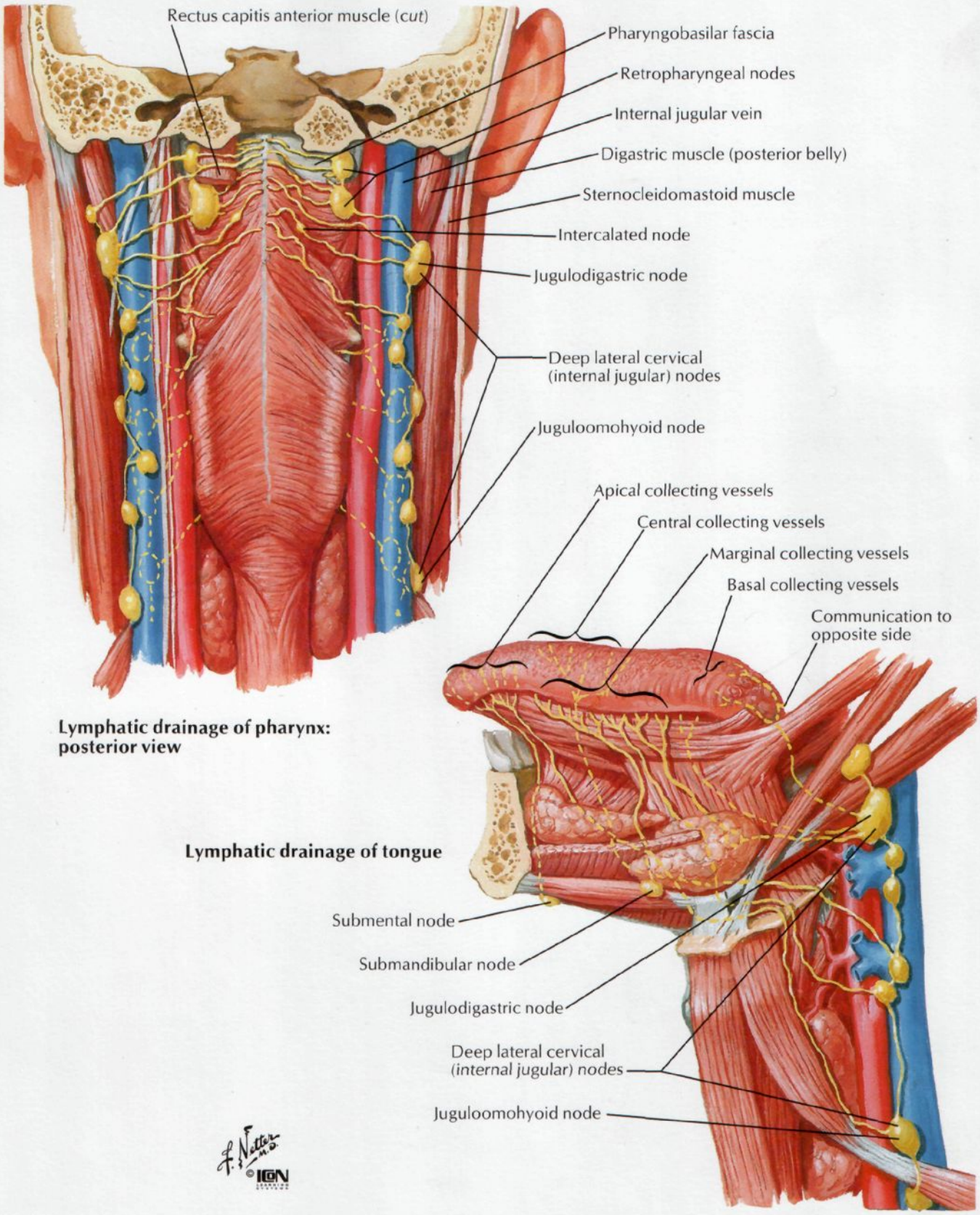

Lymphatic drainage of pharynx: posterior view

Lymphatic drainage of tongue

Thyroid Gland: Anterior View

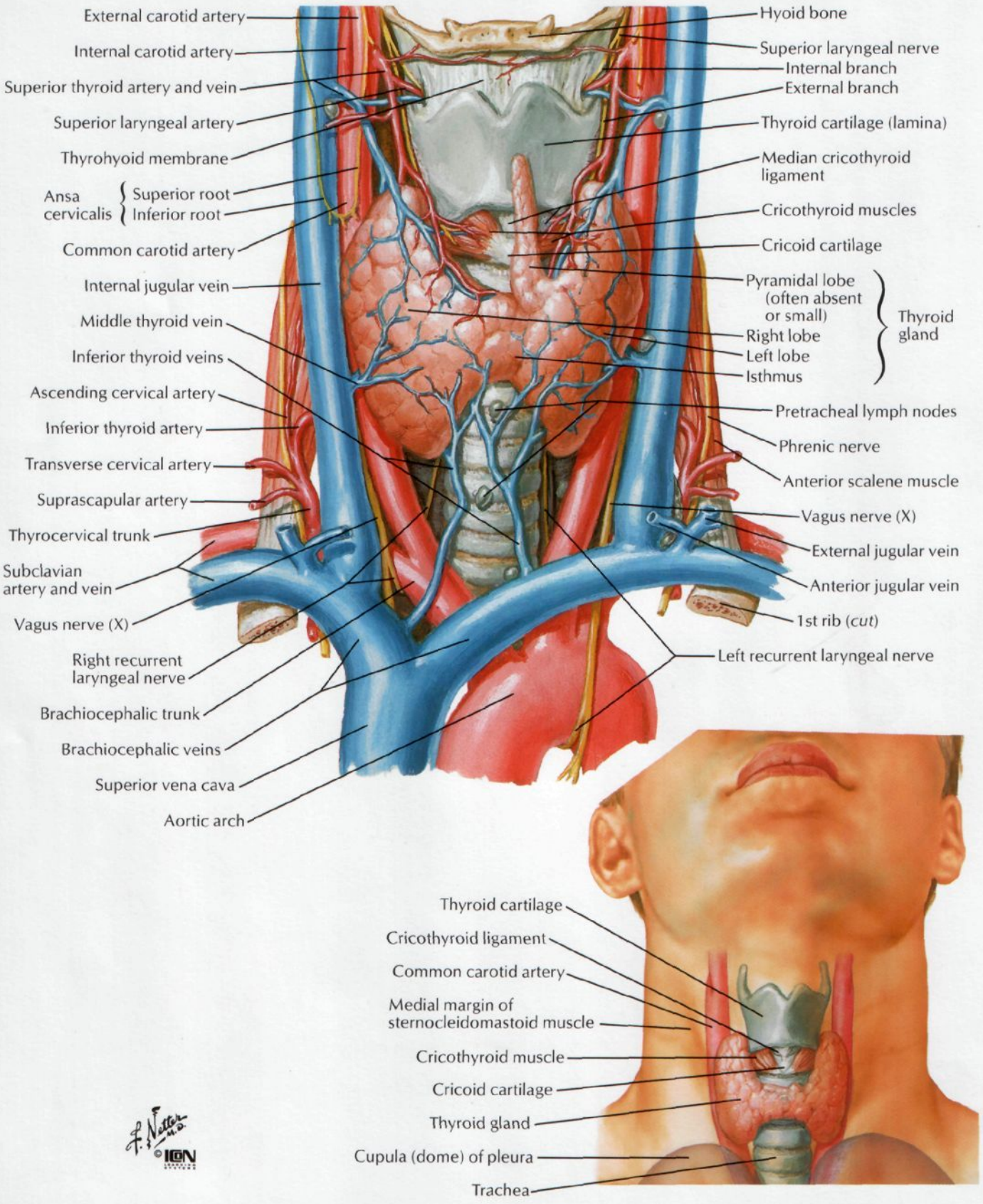

F. Netter M.D.
©

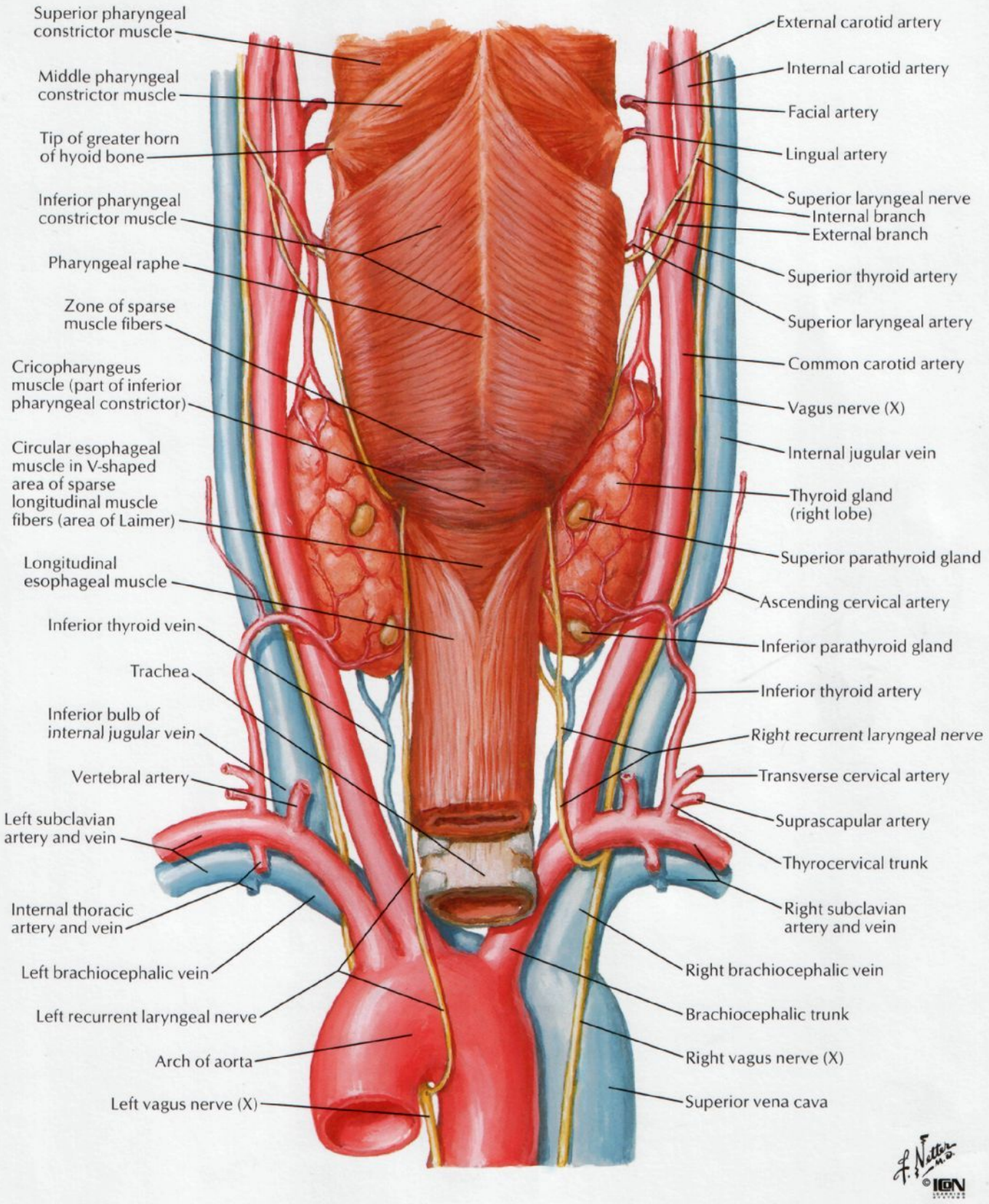
Superior pharyngeal constrictor muscle
Middle pharyngeal constrictor muscle
Tip of greater horn of hyoid bone
Inferior pharyngeal constrictor muscle
Pharyngeal raphe
Zone of sparse muscle fibers
Cricopharyngeus muscle (part of inferior pharyngeal constrictor)
Circular esophageal muscle in V-shaped area of sparse longitudinal muscle fibers (area of Laimer)
Longitudinal esophageal muscle
Inferior thyroid vein
Trachea
Inferior bulb of internal jugular vein
Vertebral artery
Left subclavian artery and vein
Internal thoracic artery and vein
Left brachiocephalic vein
Left recurrent laryngeal nerve
Arch of aorta
Left vagus nerve (X)
External carotid artery
Internal carotid artery
Facial artery
Lingual artery
Superior laryngeal nerve
Internal branch
External branch
Superior thyroid artery
Superior laryngeal artery
Common carotid artery
Vagus nerve (X)
Internal jugular vein
Thyroid gland (right lobe)
Superior parathyroid gland
Ascending cervical artery
Inferior parathyroid gland
Inferior thyroid artery
Right recurrent laryngeal nerve
Transverse cervical artery
Suprascapular artery
Thyrocervical trunk
Right subclavian artery and vein
Right brachiocephalic vein
Brachiocephalic trunk
Right vagus nerve (X)
Superior vena cava

Parathyroid Glands

SEE ALSO PLATE 76

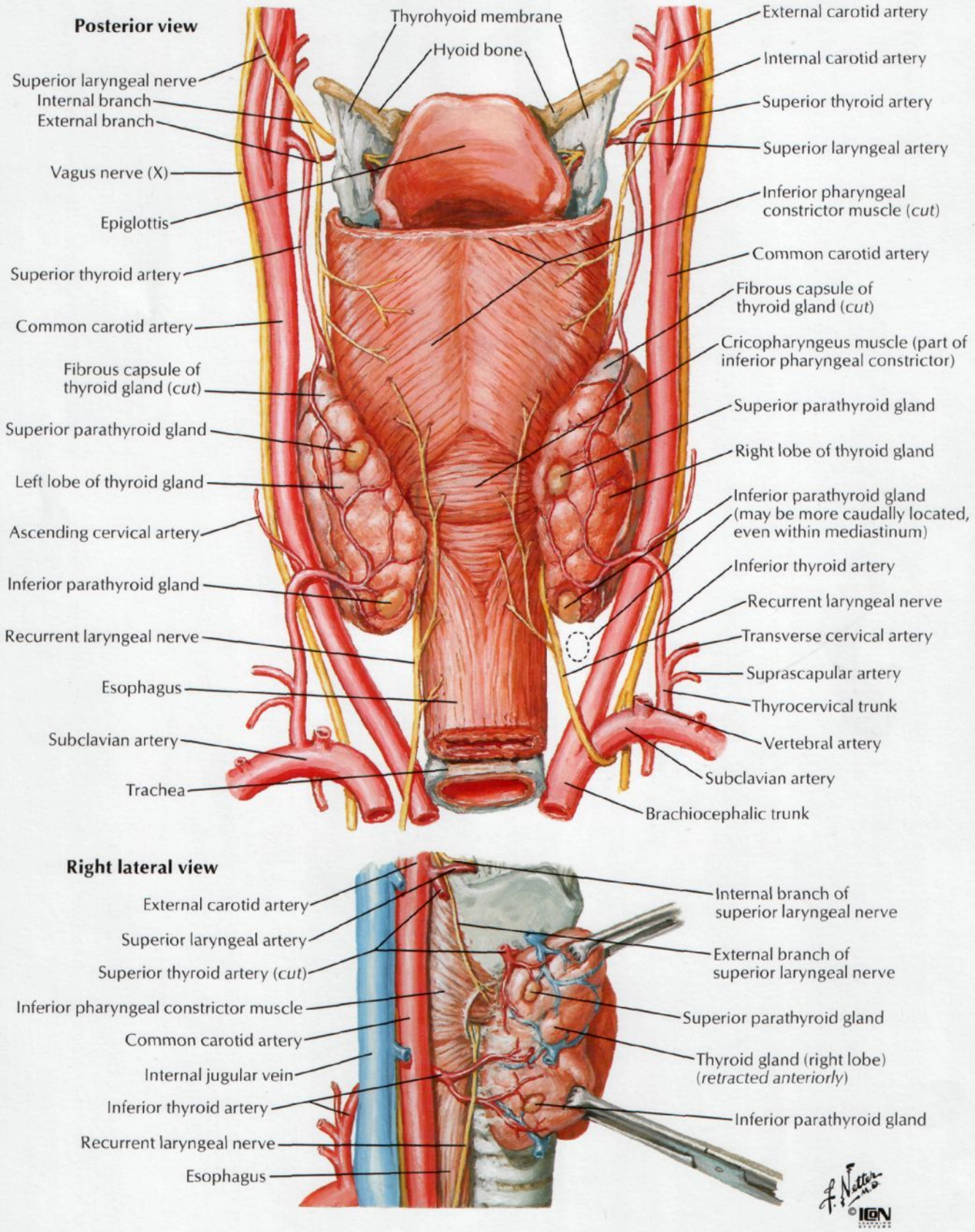

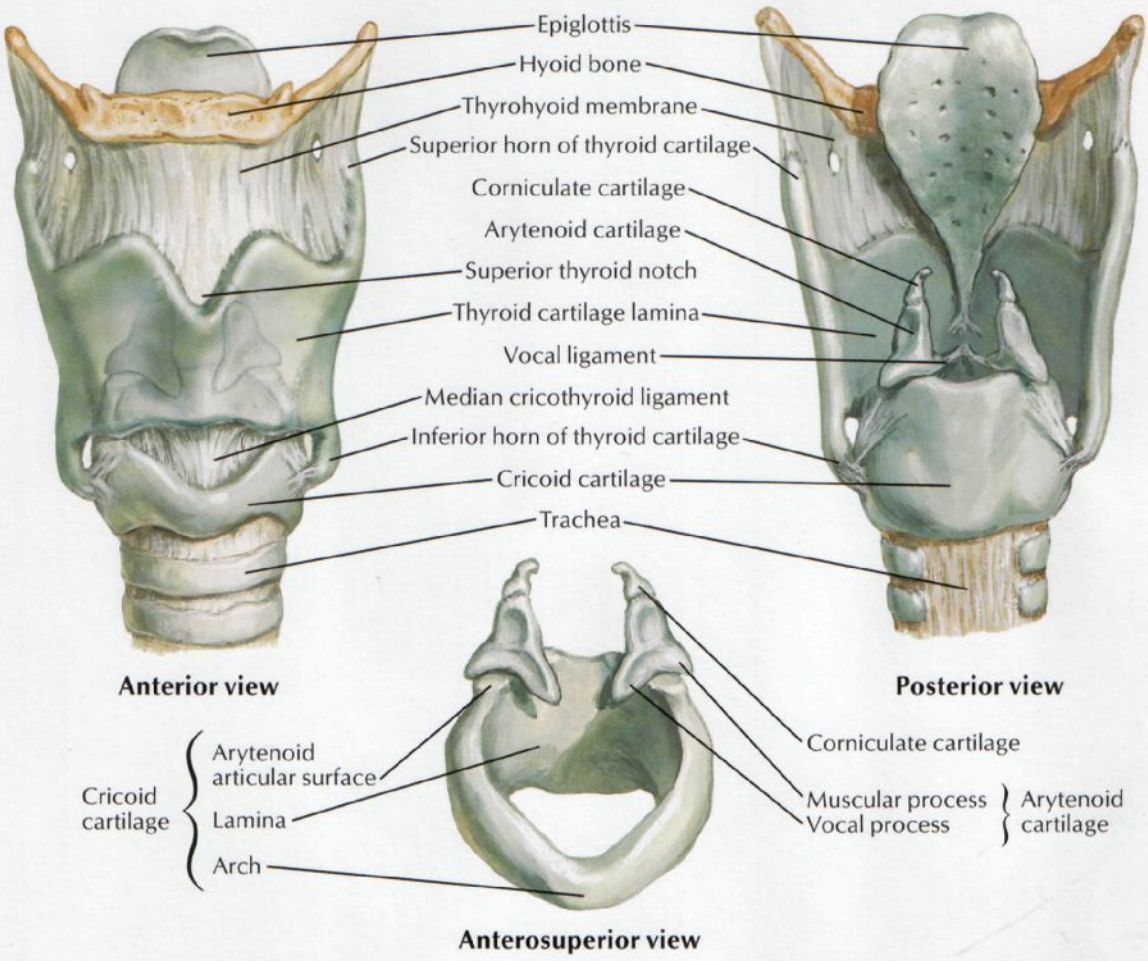
Epiglottis
Hyoid bone
Thyrohyoid membrane
Superior horn of thyroid cartilage
Corniculate cartilage
Arytenoid cartilage
Superior thyroid notch
Thyroid cartilage lamina
Vocal ligament
Median cricothyroid ligament
Inferior horn of thyroid cartilage
Cricoid cartilage
Trachea
Anterior view
Posterior view
Cricoid cartilage
Arytenoid articular surface
Lamina
Arch
Corniculate cartilage
Muscular process
Vocal process
Arytenoid cartilage
Anterosuperior view

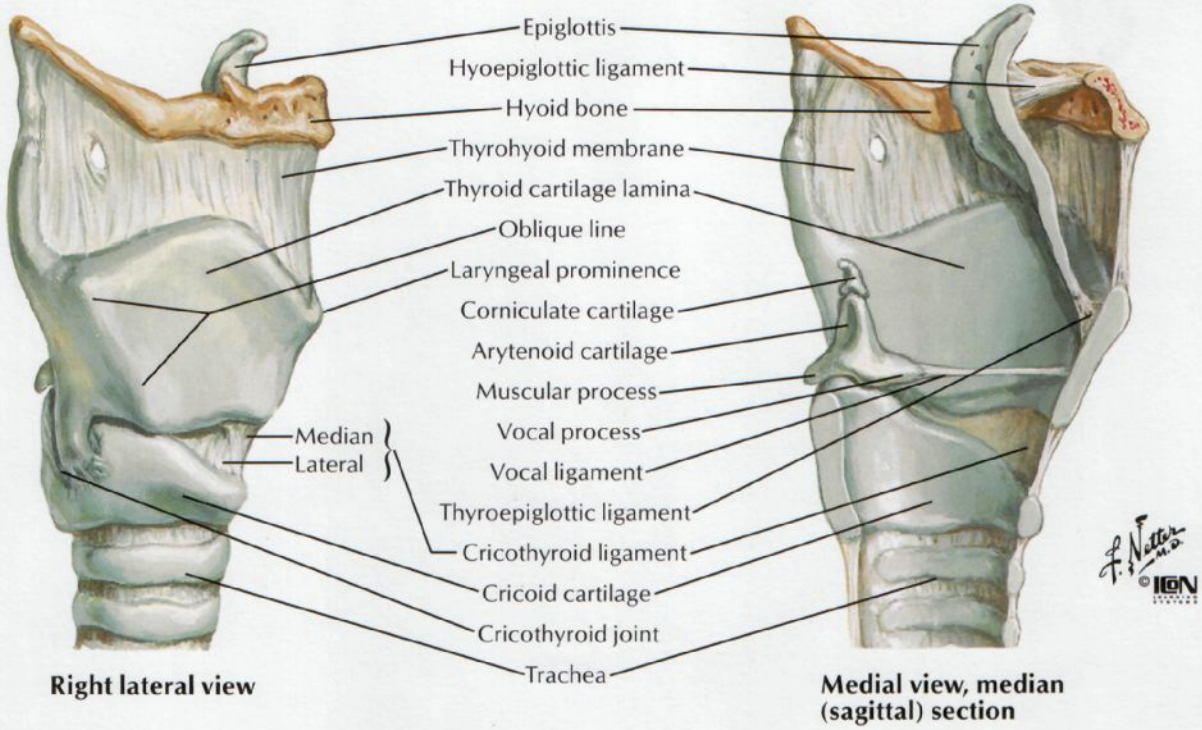
Epiglottis
Hyoepiglottic ligament
Hyoid bone
Thyrohyoid membrane
Thyroid cartilage lamina
Oblique line
Laryngeal prominence
Corniculate cartilage
Arytenoid cartilage
Muscular process
Vocal process
Vocal ligament
Thyroepiglottic ligament
Cricothyroid ligament
Cricoid cartilage
Cricothyroid joint
Trachea
Median
Lateral
Right lateral view
Medial view, median (sagittal) section

Intrinsic Muscles of Larynx

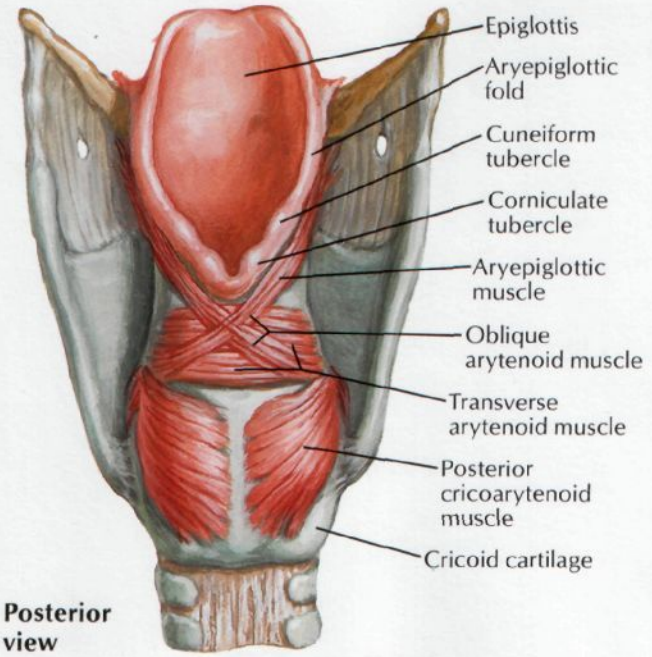

Posterior view

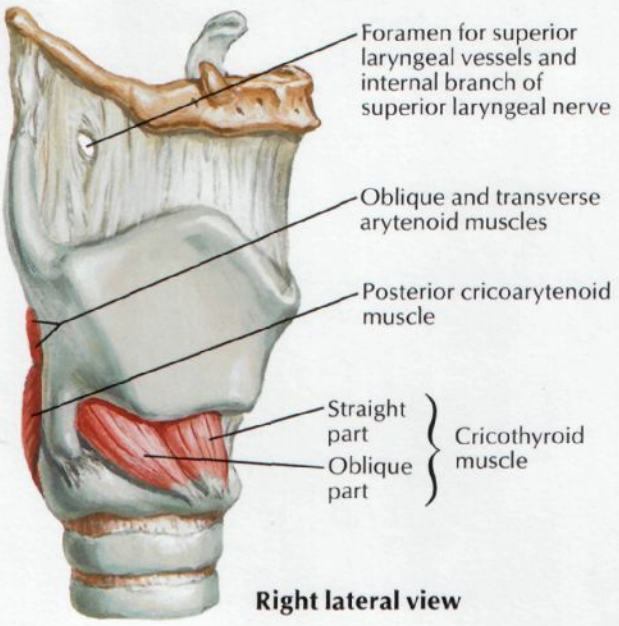

Right lateral view

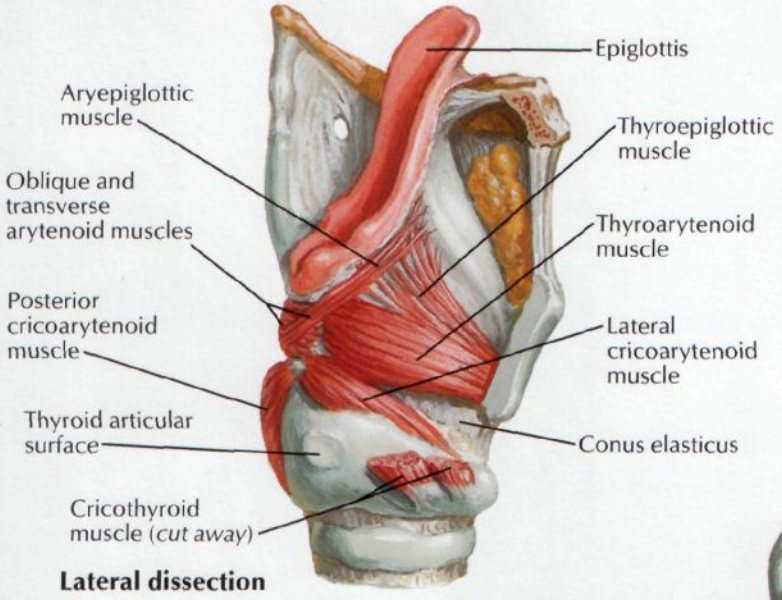

Lateral dissection

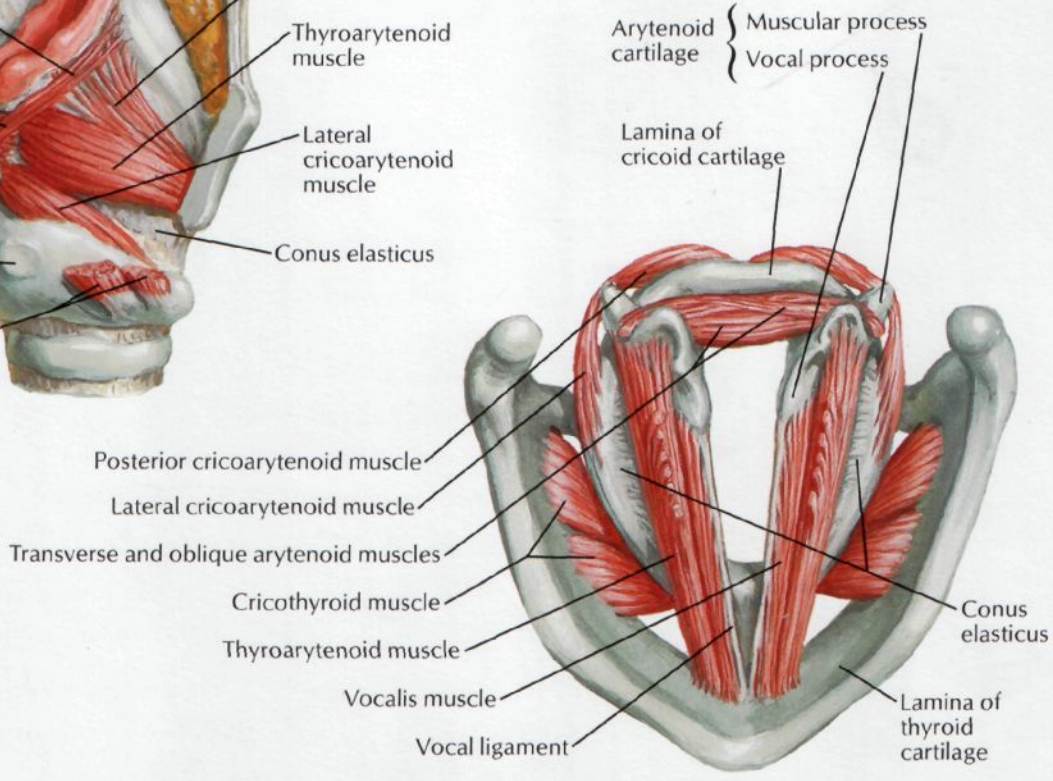

Superior view

F. Netter M.D. ©IGN

Intrinsic Muscles of Larynx

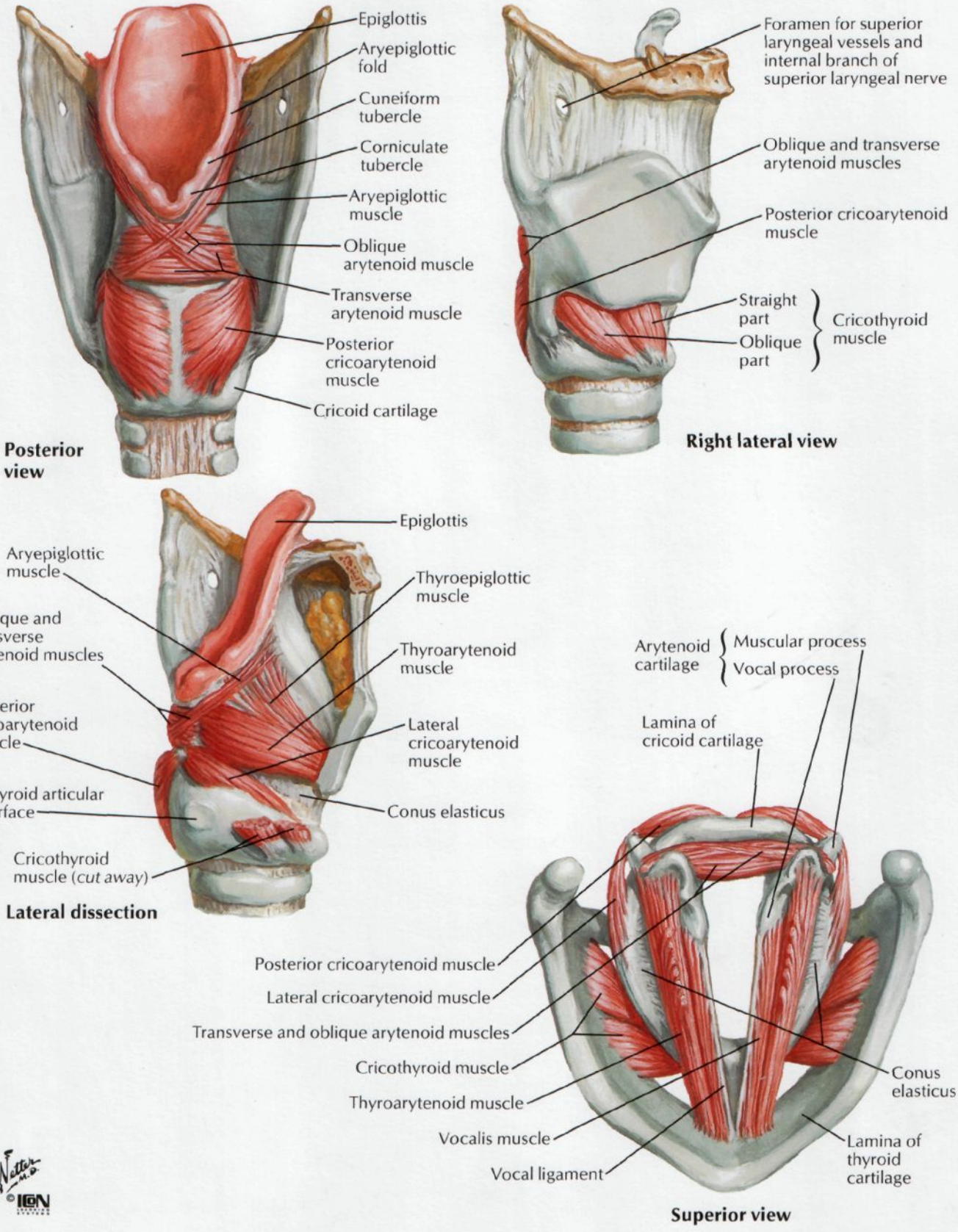

F. Netter M.D.
©IGN

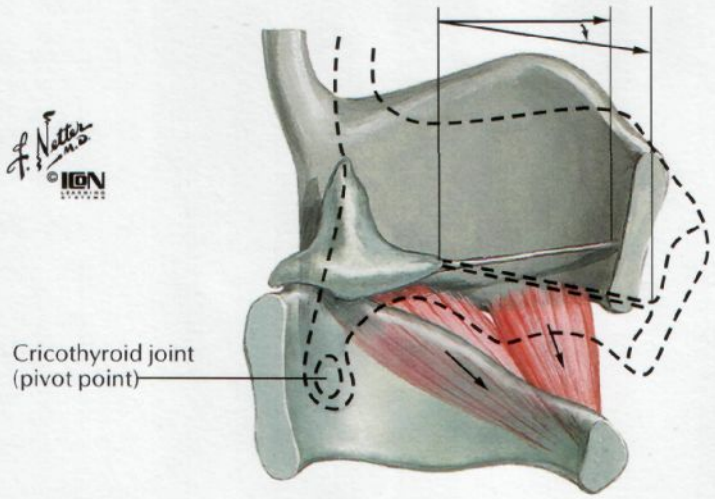

Action of cricothyroid muscles
Lengthening (increasing tension) of vocal ligaments

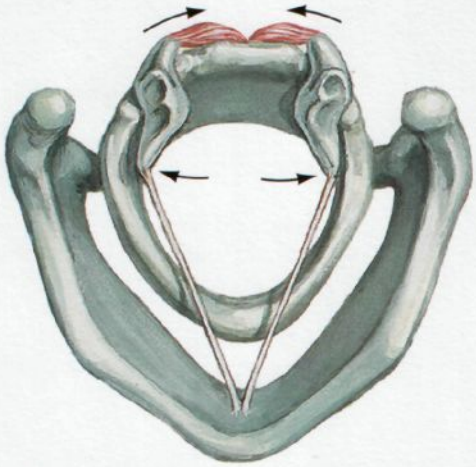

Action of posterior cricoarytenoid muscles
Abduction of vocal ligaments

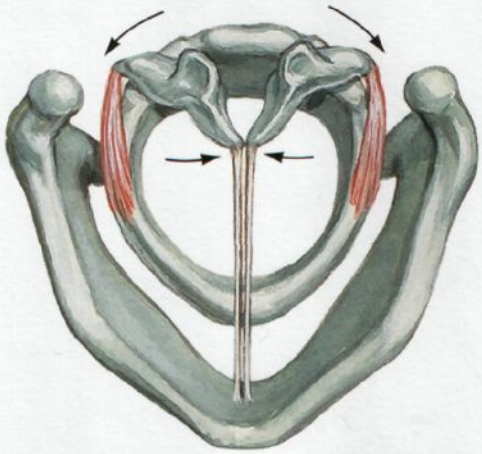

Action of lateral cricoarytenoid muscles
Adduction of vocal ligaments

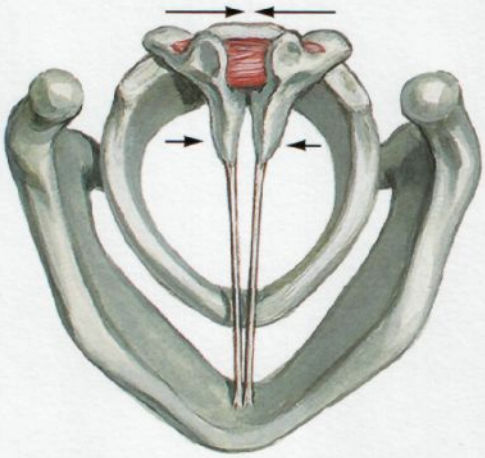

Action of transverse arytenoid muscle
Adduction of vocal ligaments

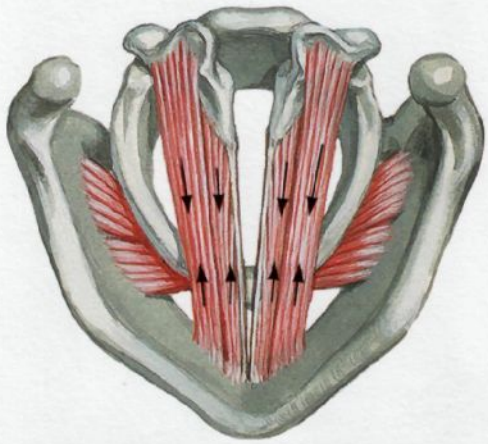

Action of vocalis and thyroarytenoid muscles
Shortening (relaxation) of vocal ligaments

Nerves of Larynx

SEE ALSO PLATES 70–72, 231

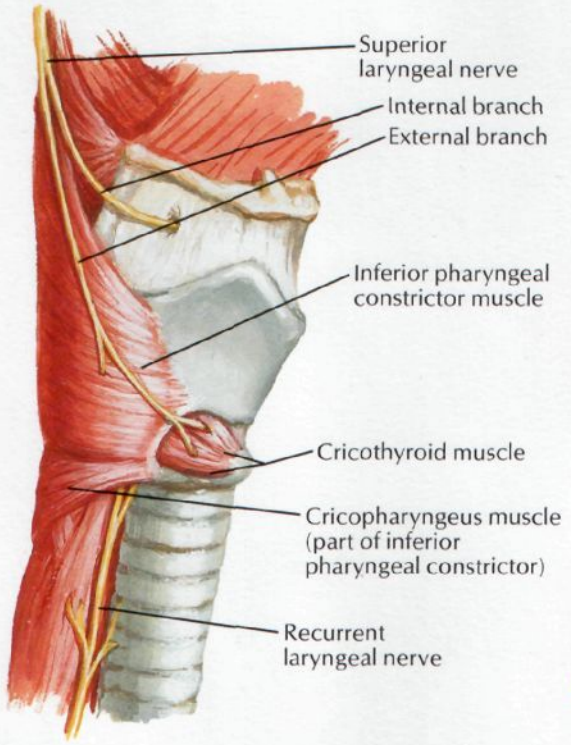

Right lateral view

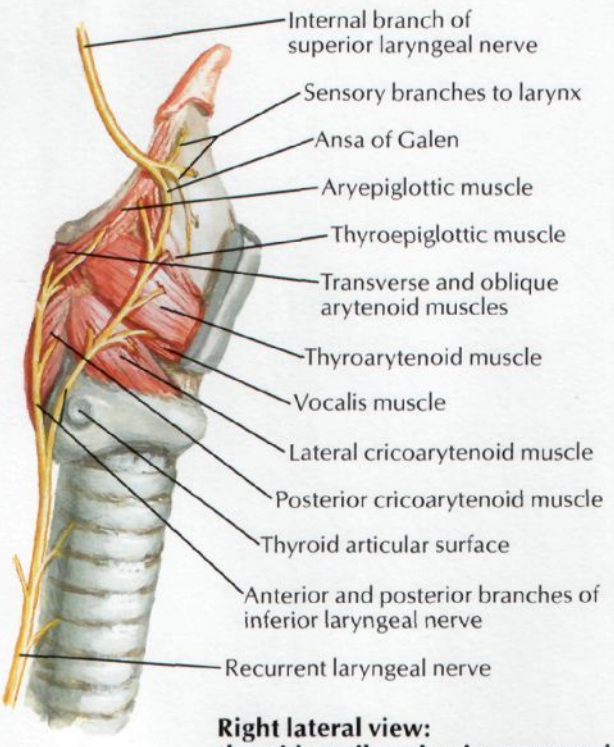

Right lateral view: thyroid cartilage lamina removed

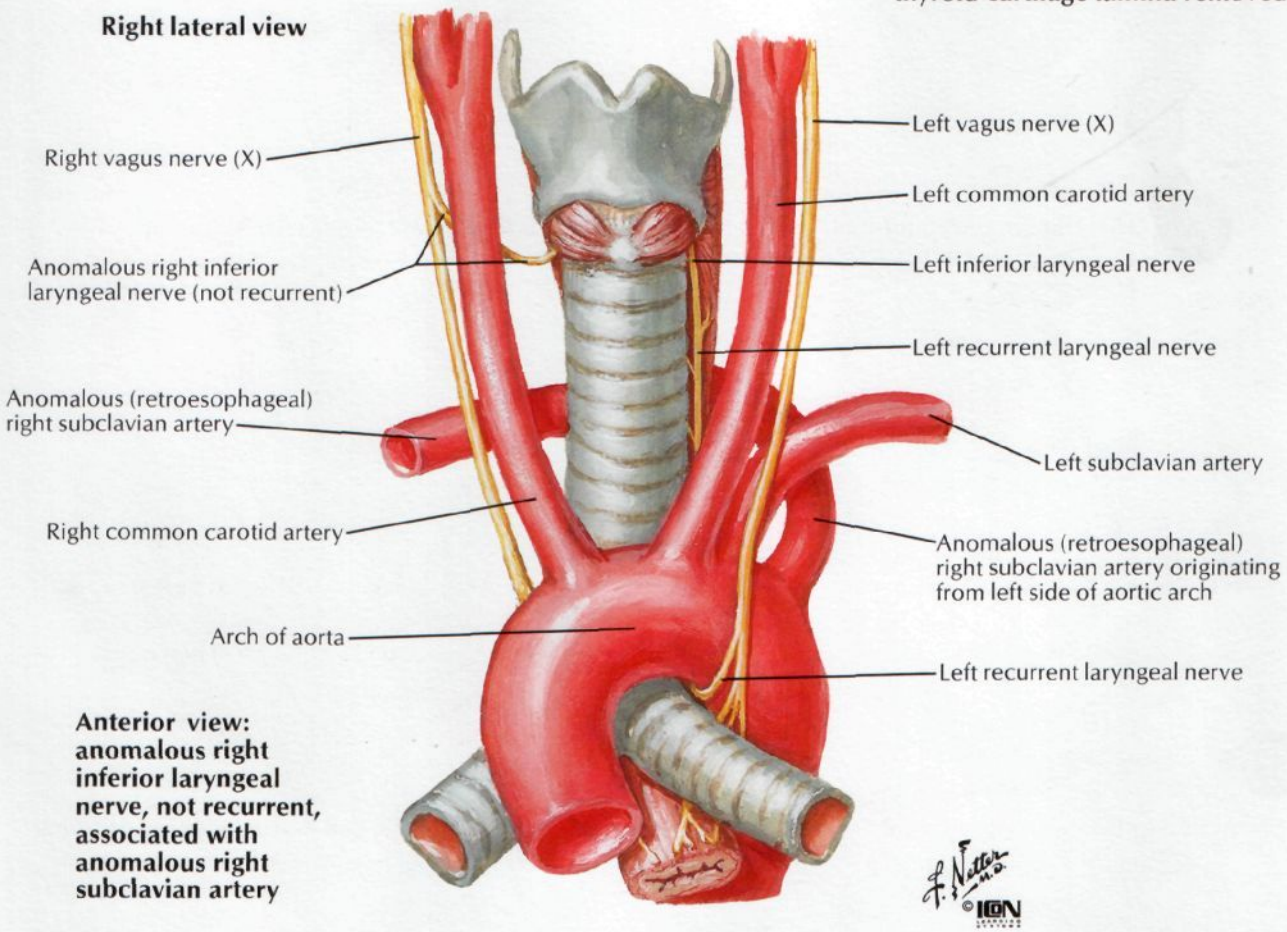

Anterior view: anomalous right inferior laryngeal nerve, not recurrent, associated with anomalous right subclavian artery

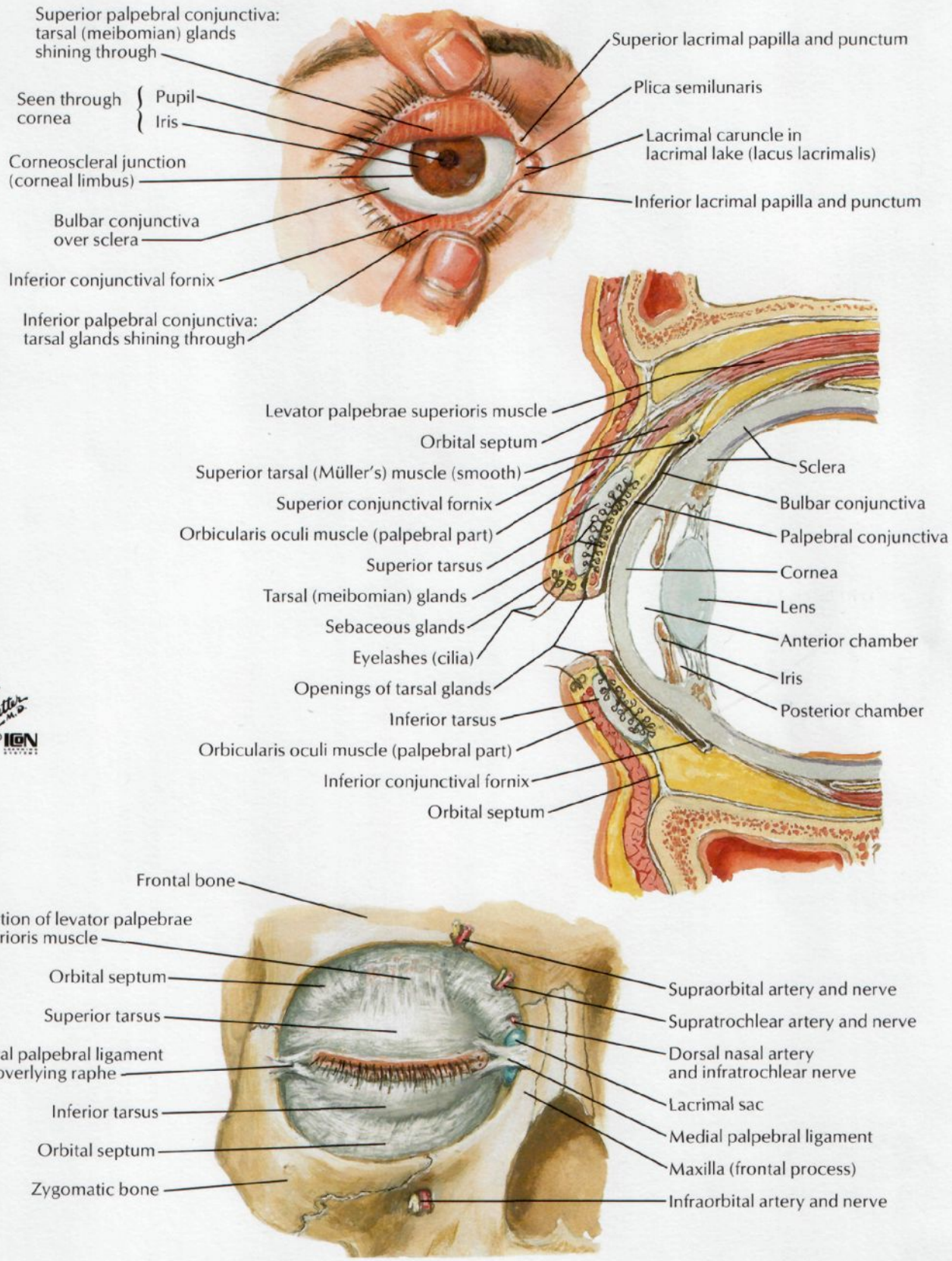
Superior palpebral conjunctiva: tarsal (meibomian) glands shining through
Seen through cornea
Pupil
Iris
Corneoscleral junction (corneal limbus)
Bulbar conjunctiva over sclera
Inferior conjunctival fornix
Inferior palpebral conjunctiva: tarsal glands shining through
Superior lacrimal papilla and punctum
Plica semilunaris
Lacrimal caruncle in lacrimal lake (lacus lacrimalis)
Inferior lacrimal papilla and punctum
Levator palpebrae superioris muscle
Orbital septum
Superior tarsal (Müller's) muscle (smooth)
Superior conjunctival fornix
Orbicularis oculi muscle (palpebral part)
Superior tarsus
Tarsal (meibomian) glands
Sebaceous glands
Eyelashes (cilia)
Openings of tarsal glands
Inferior tarsus
Orbicularis oculi muscle (palpebral part)
Inferior conjunctival fornix
Orbital septum
Sclera
Bulbar conjunctiva
Palpebral conjunctiva
Cornea
Lens
Anterior chamber
Iris
Posterior chamber
Frontal bone
Insertion of levator palpebrae superioris muscle
Orbital septum
Superior tarsus
Lateral palpebral ligament and overlying raphe
Inferior tarsus
Orbital septum
Zygomatic bone
Supraorbital artery and nerve
Supratrochlear artery and nerve
Dorsal nasal artery and infratrochlear nerve
Lacrimal sac
Medial palpebral ligament
Maxilla (frontal process)
Infraorbital artery and nerve

Lacrimal Apparatus

SEE ALSO PLATES 41, 127

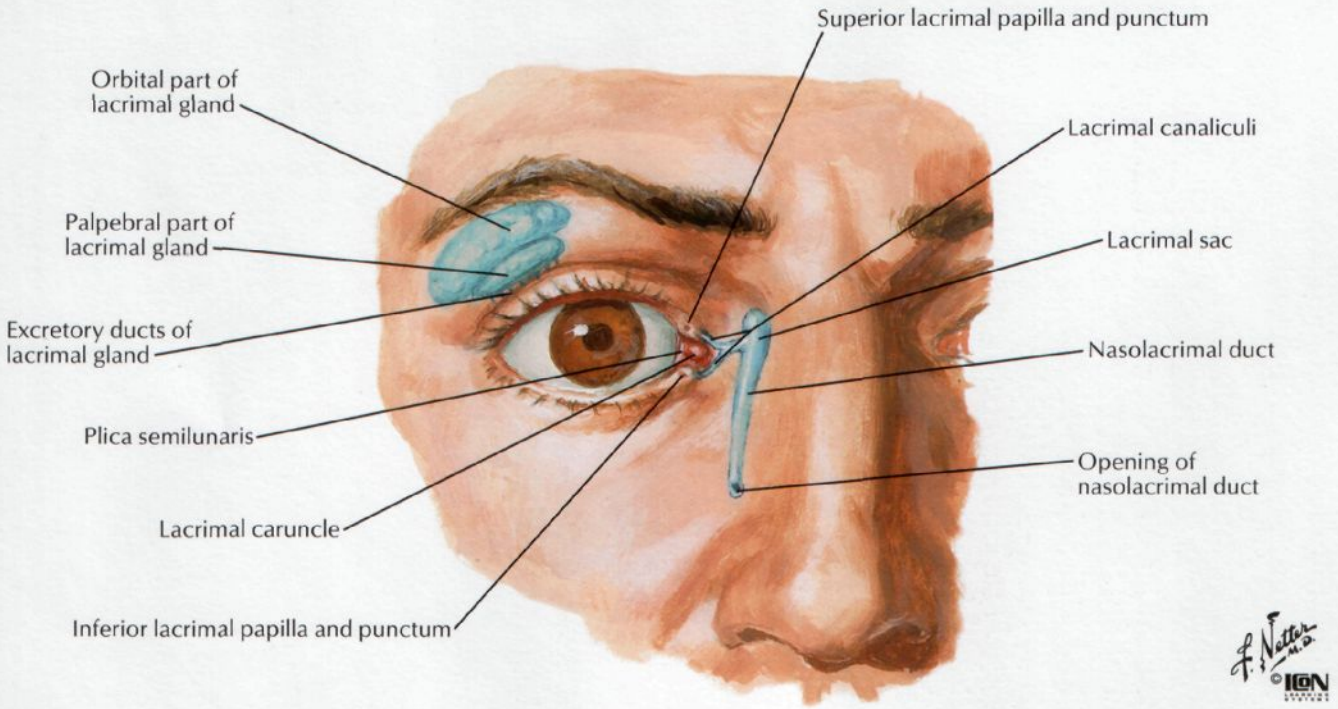

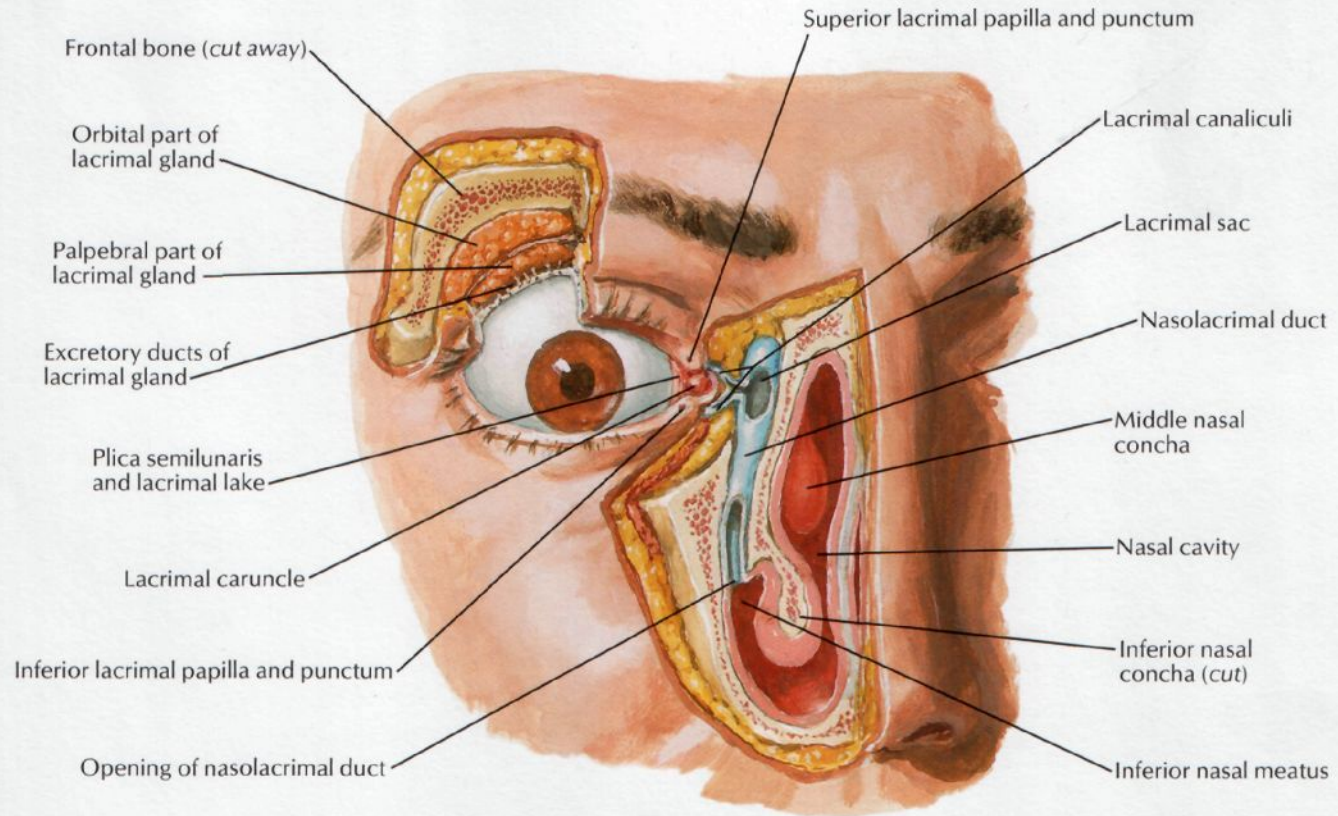

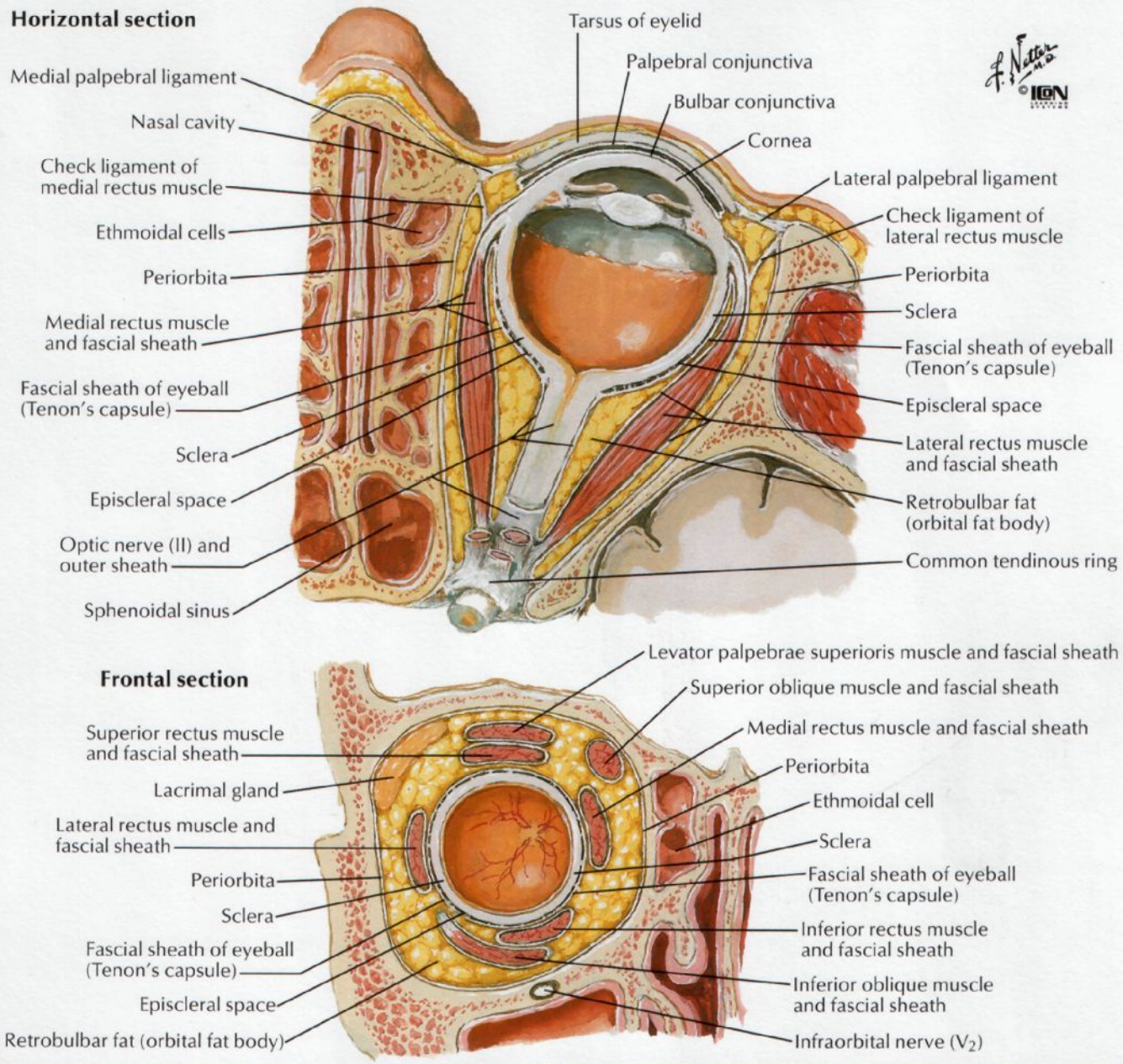

Muscle attachments and nerves and vessels entering orbit

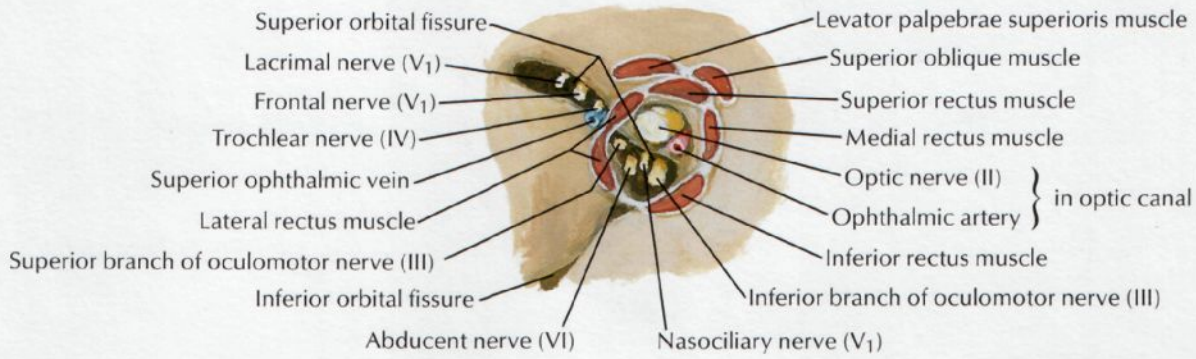

Extrinsic Eye Muscles

Right lateral view

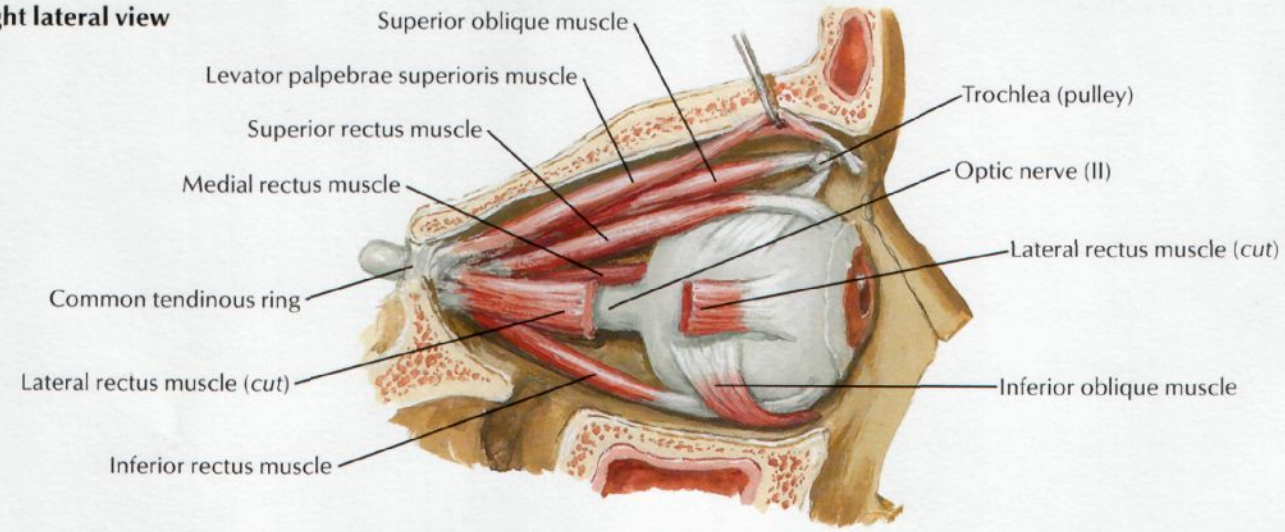

Superior view

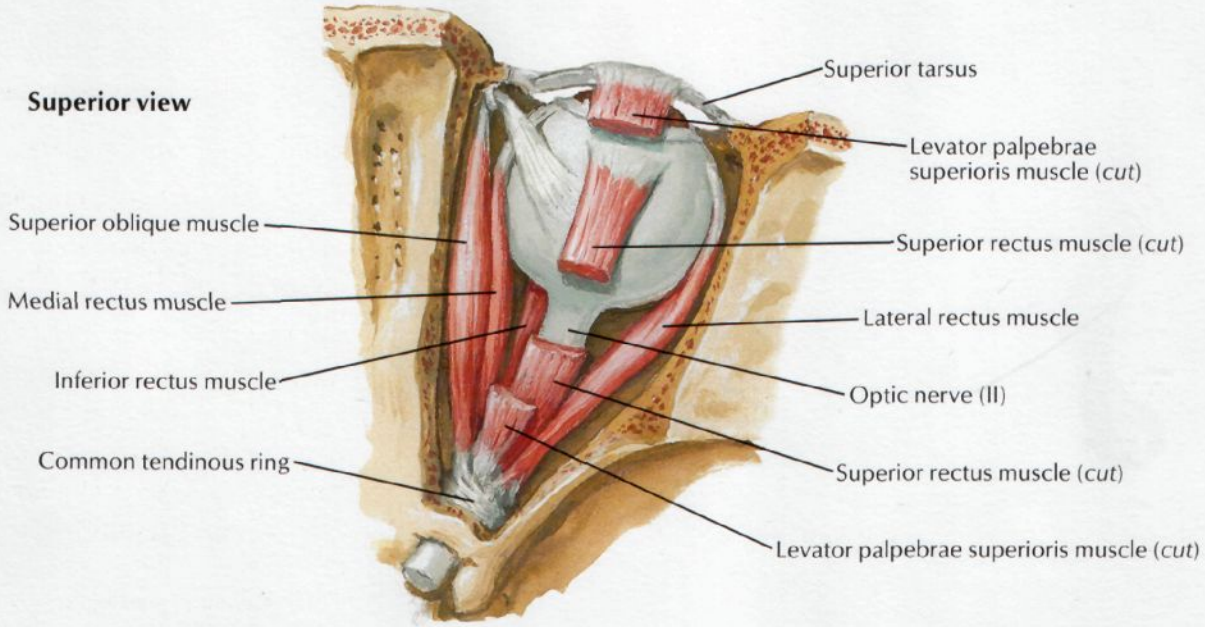

Innervation and action of extrinsic eye muscles: anterior view

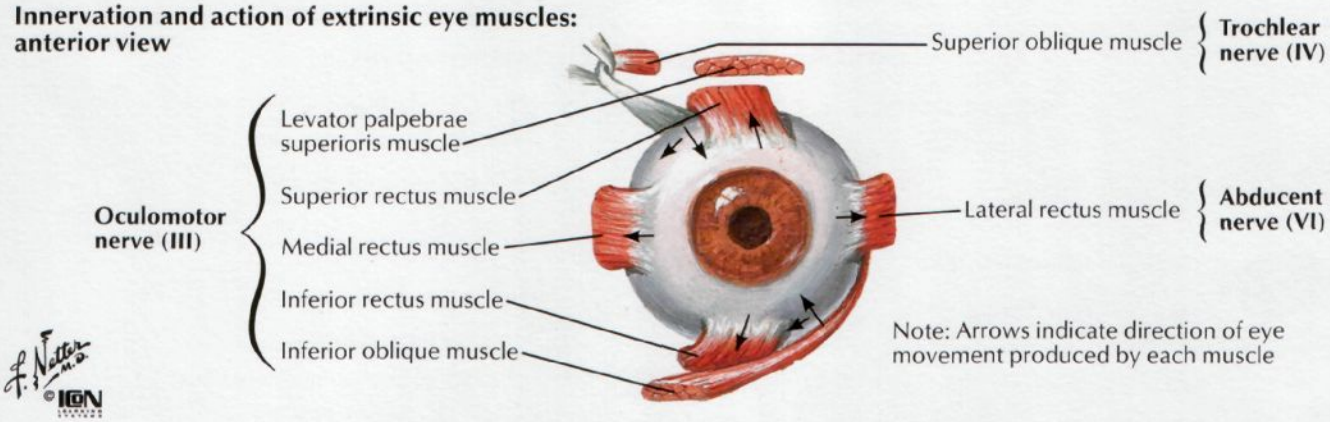

F. Netter M.D.
©IGN

SEE ALSO PLATES 19, 98

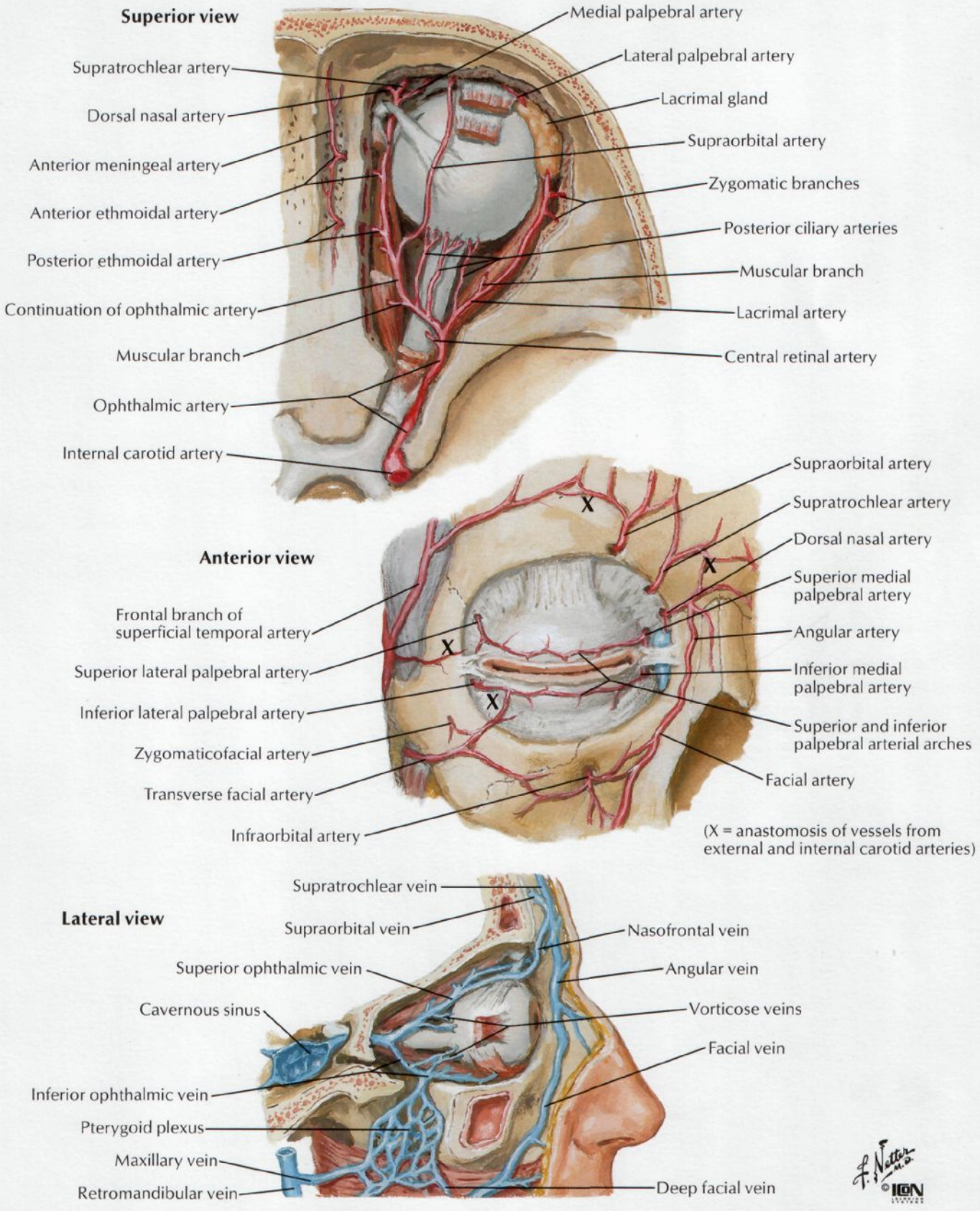

Nerves of Orbit

SEE ALSO PLATES 41, 115, 126

Superior view

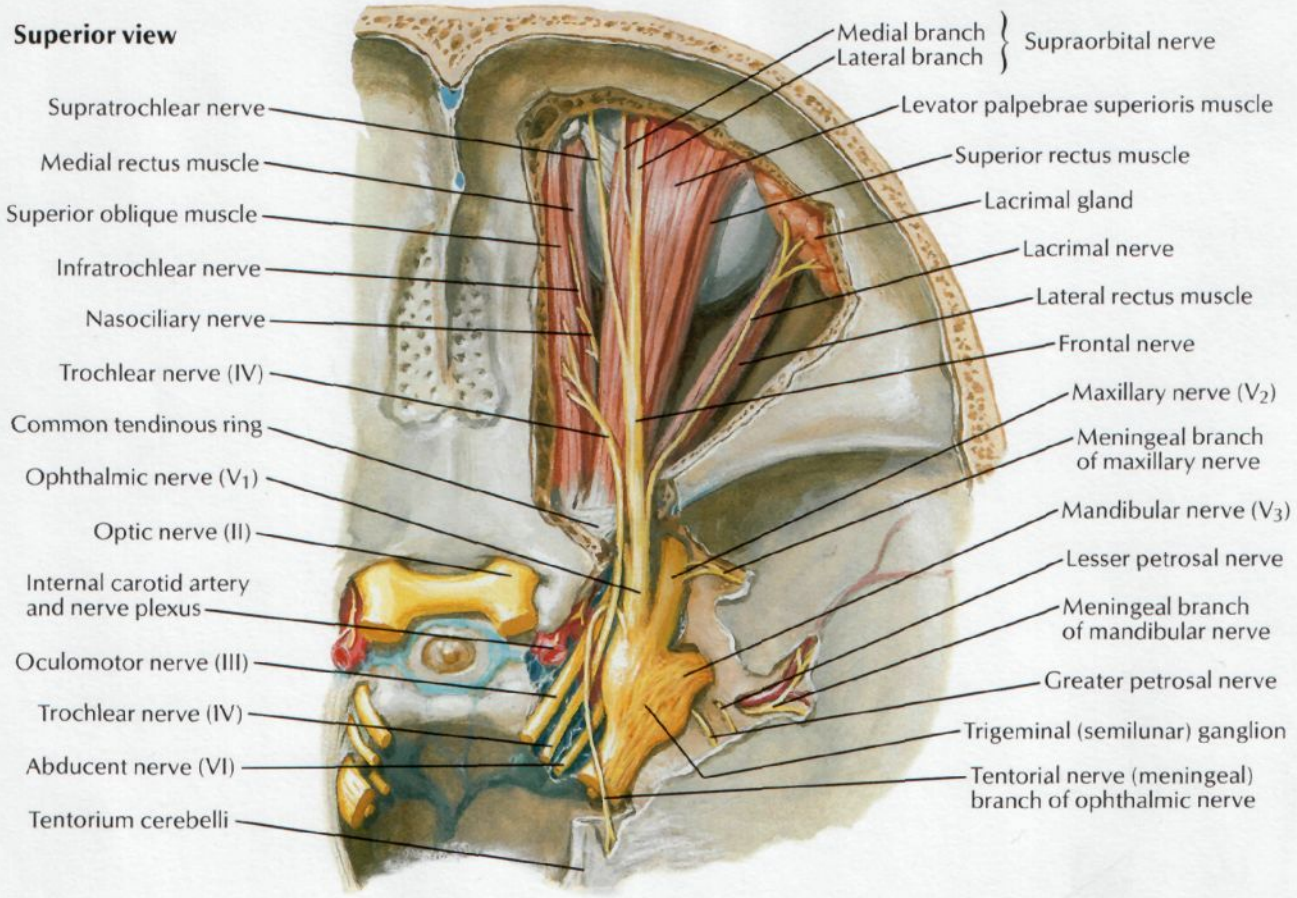

Superior view:
levator palpebrae superioris, superior rectus and superior oblique muscles partially cut away

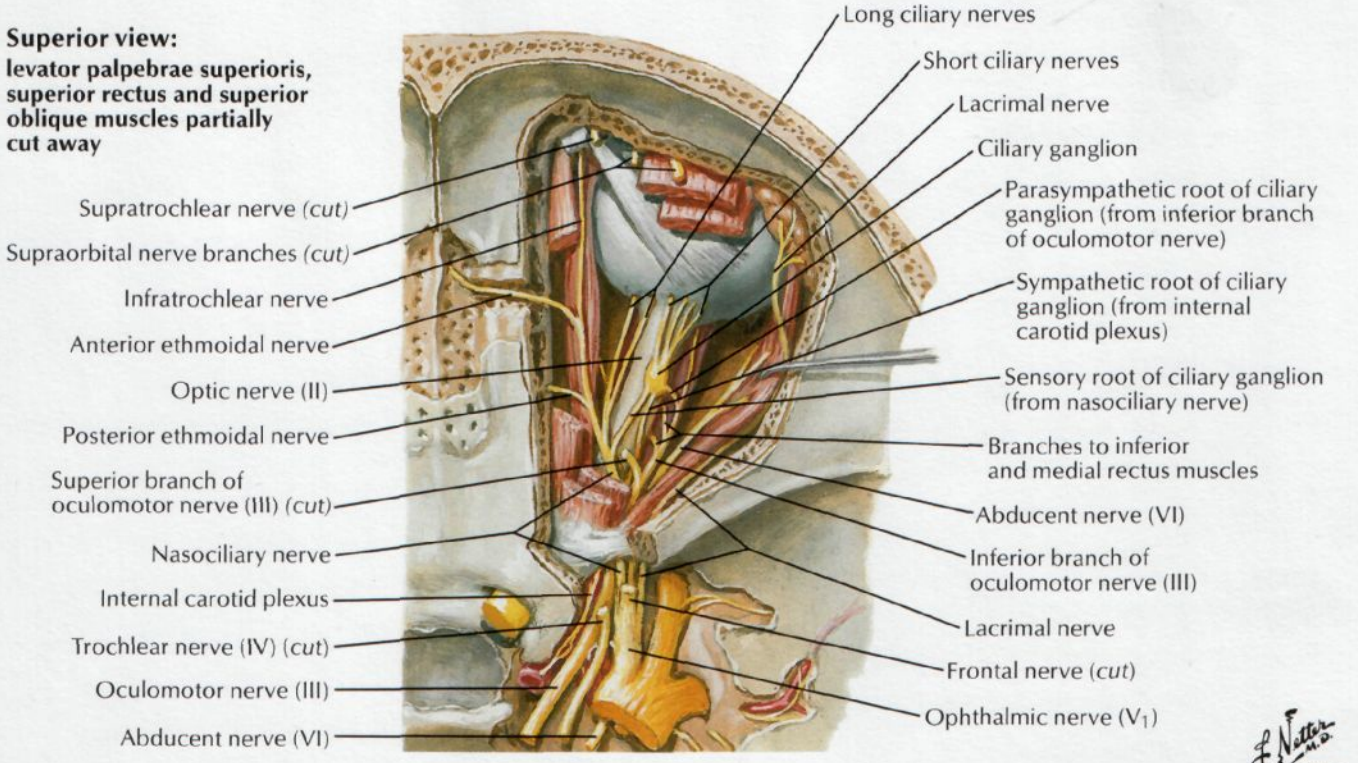

F. Netter M.D.
©IGN

Horizontal section

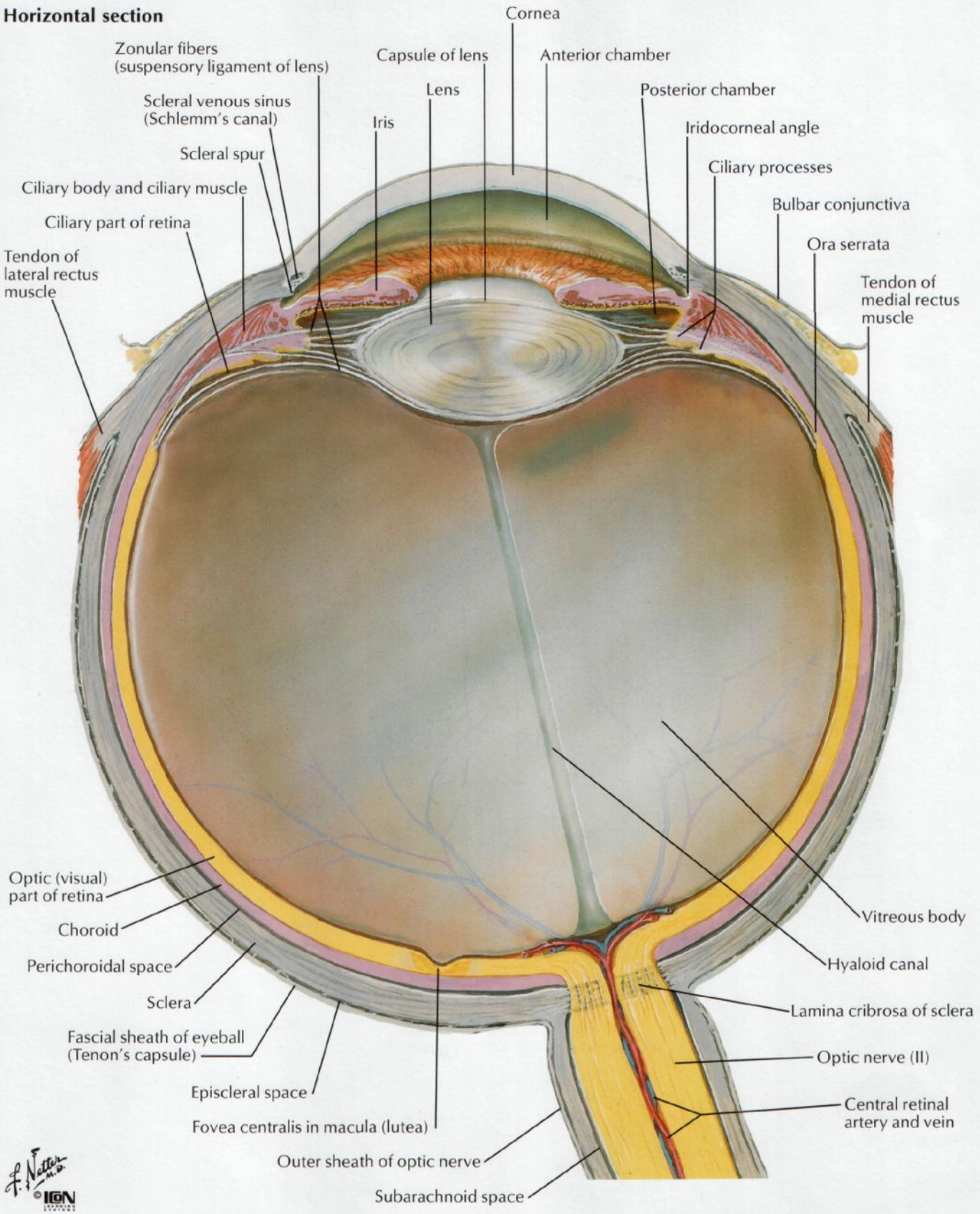

Anterior and Posterior Chambers of Eye

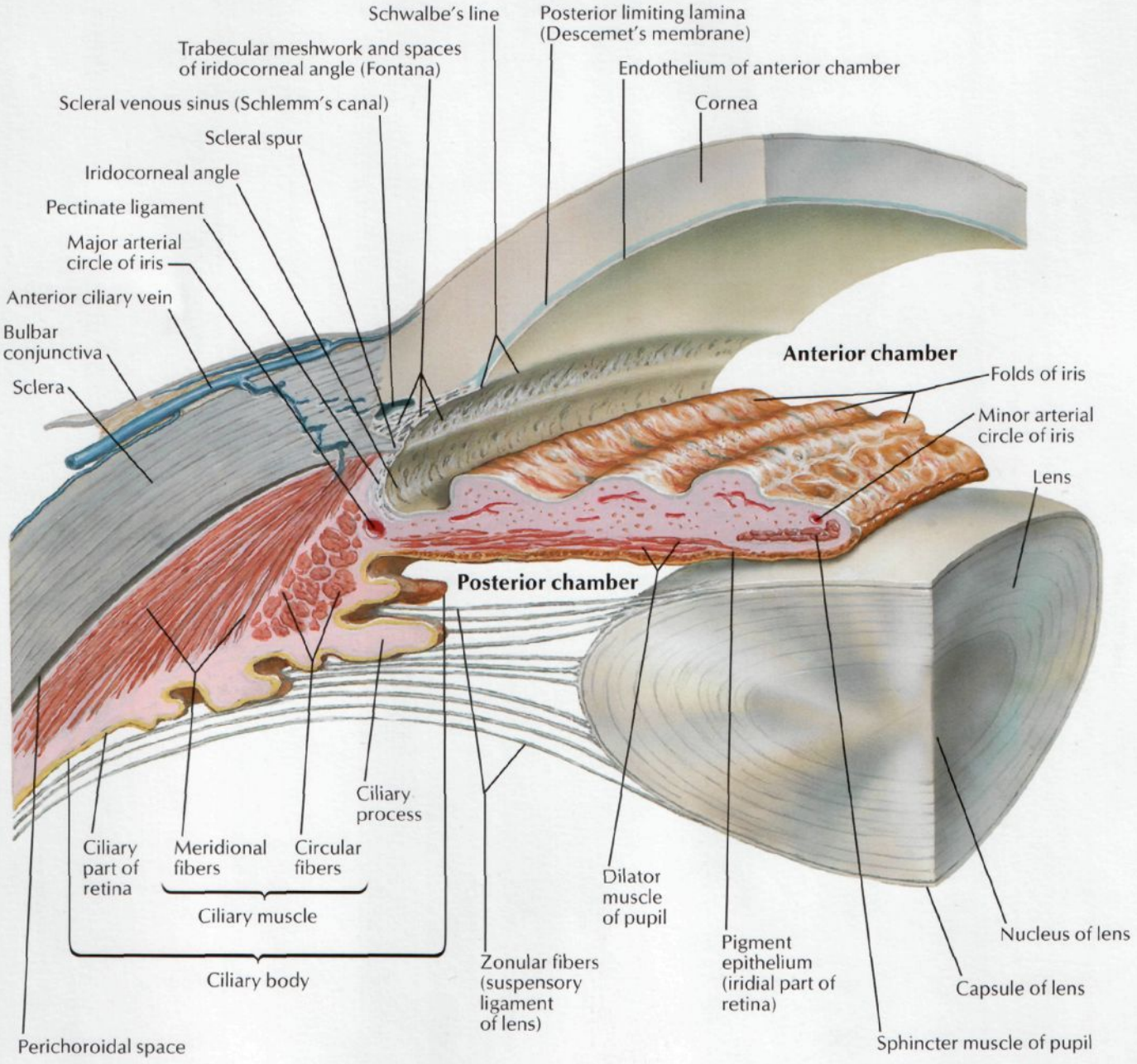

Note: For clarity, only single plane of zonular fibers shown; actually, fibers surround entire circumference of lens

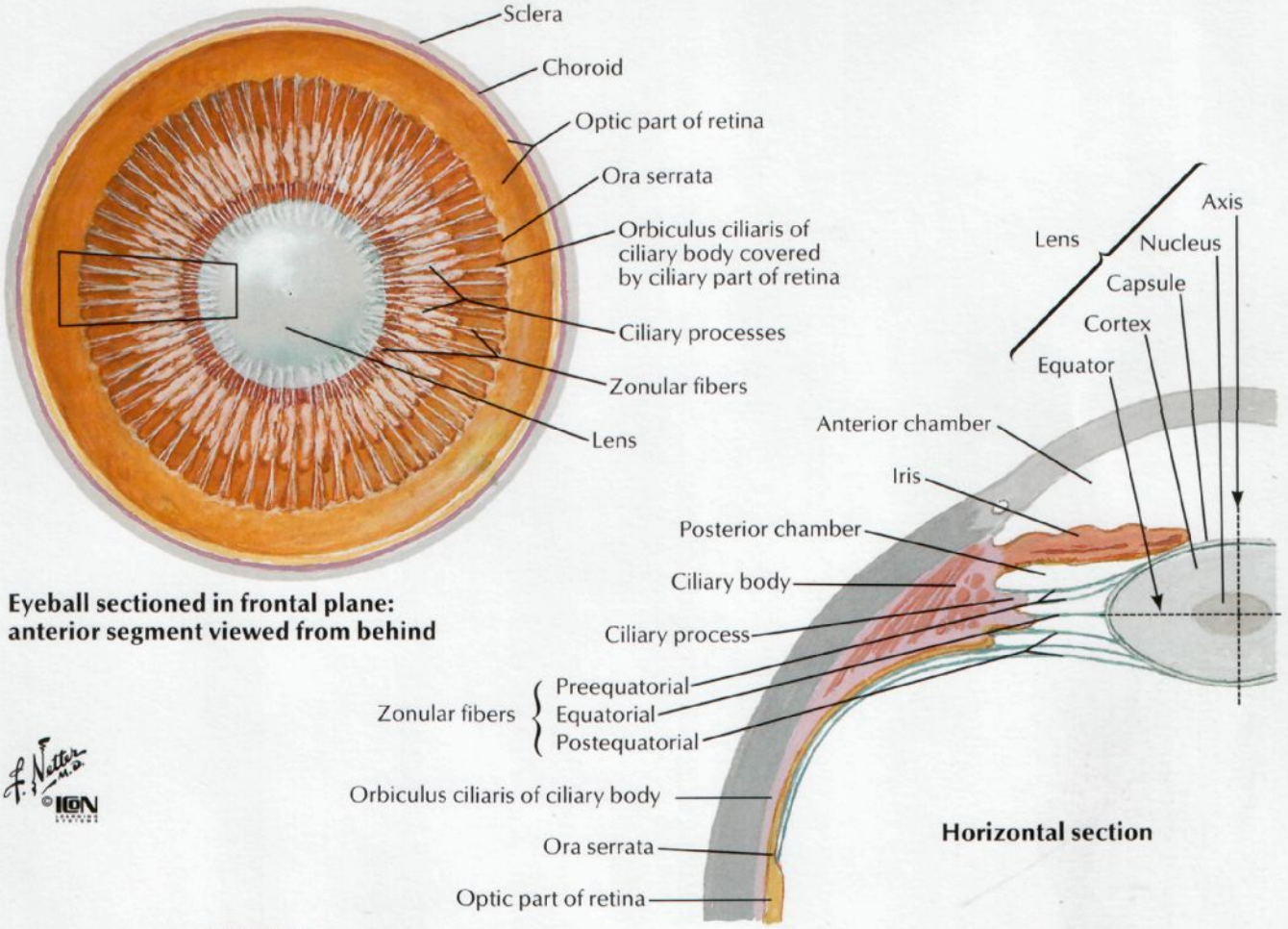

Eyeball sectioned in frontal plane: anterior segment viewed from behind

Horizontal section

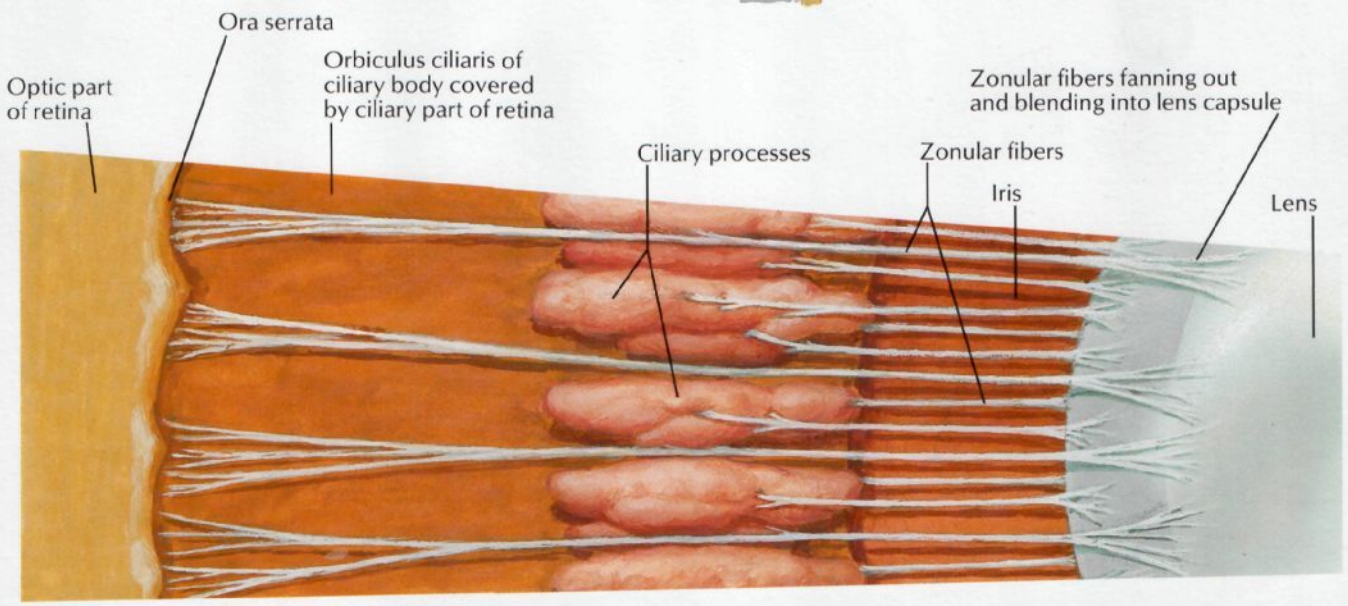

Enlargement of segment outlined in top illustration (semischematic)

Intrinsic Arteries and Veins of Eye

SEE ALSO PLATE 81

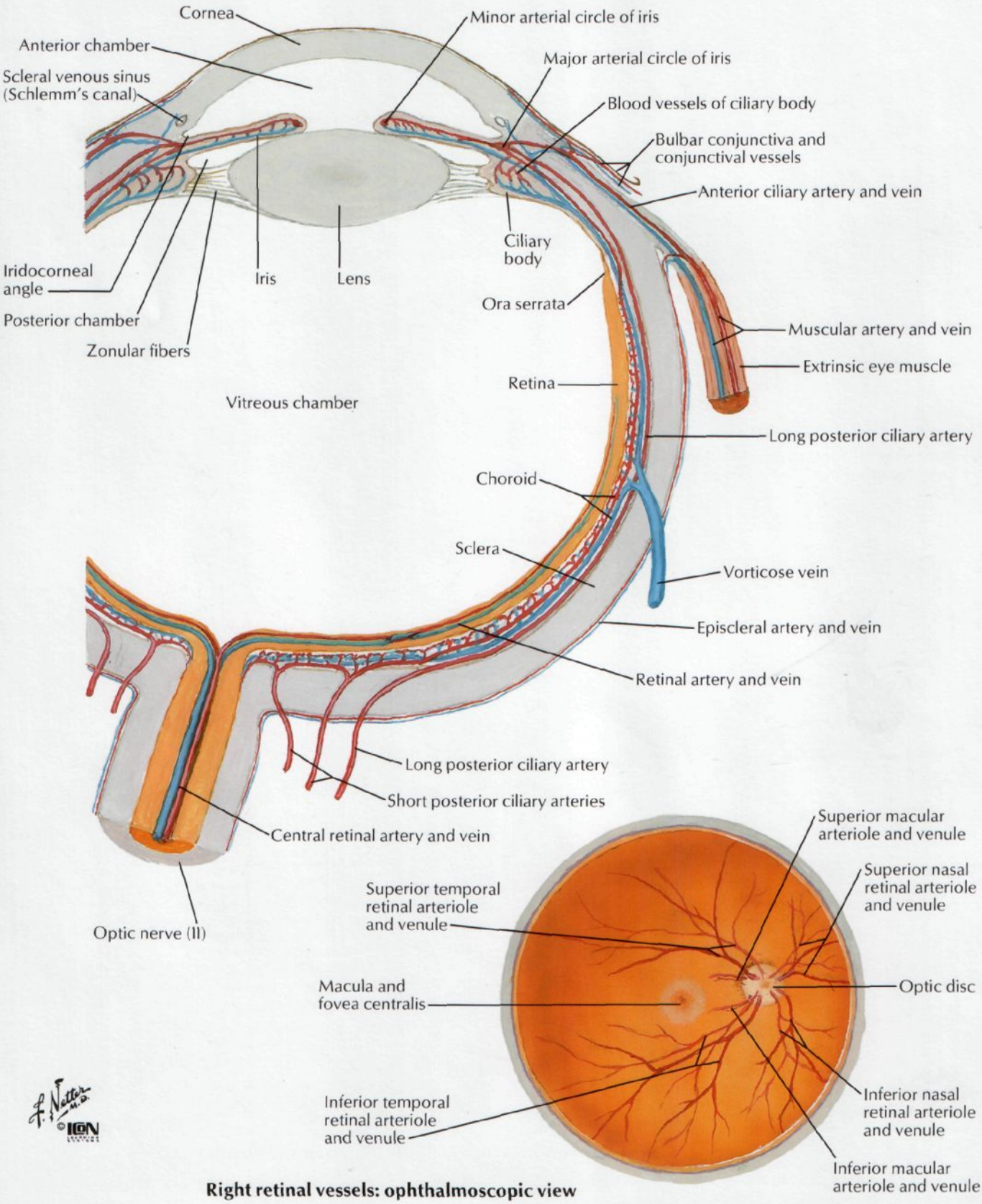

Right retinal vessels: ophthalmoscopic view

Frontal section

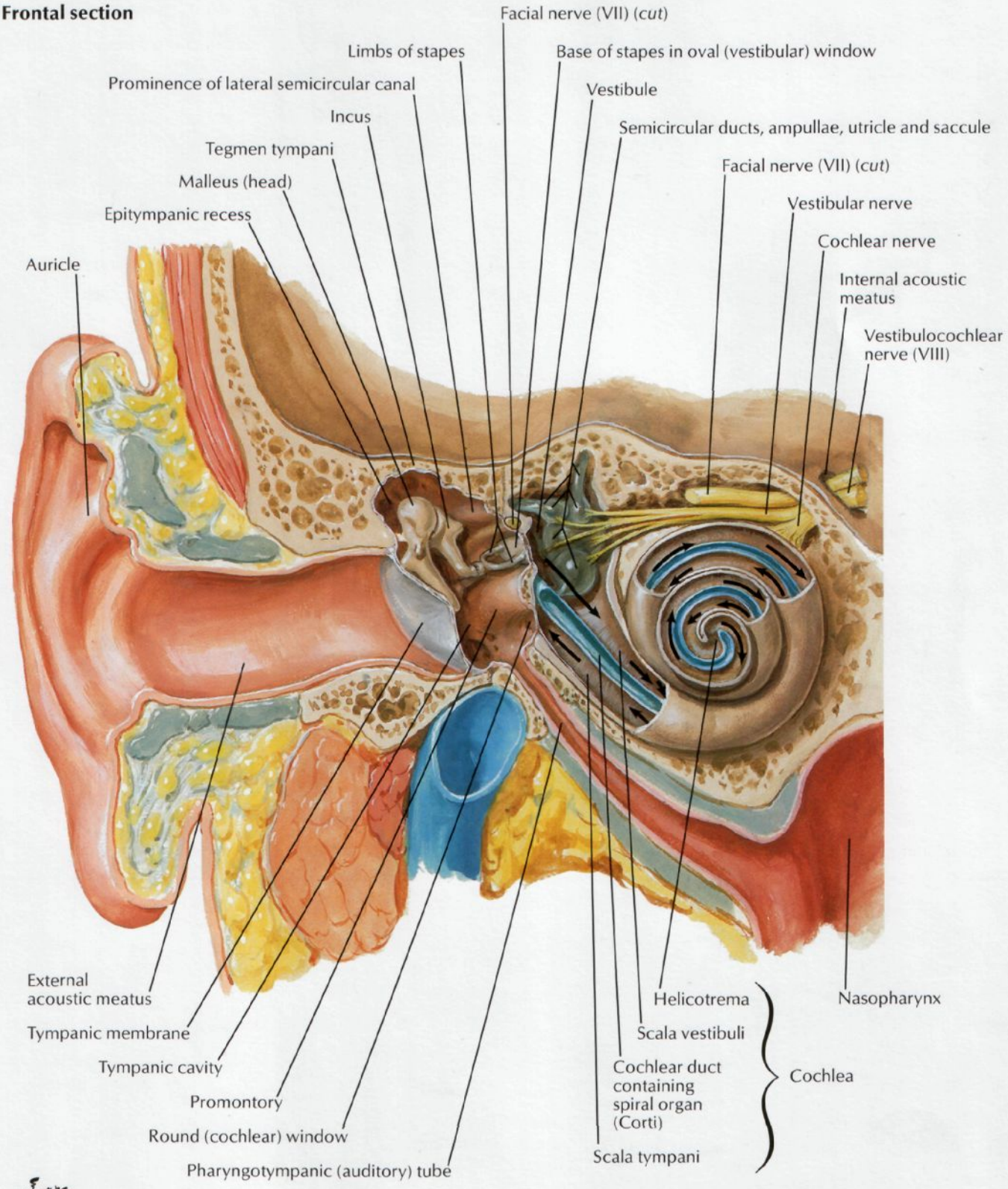

Note: Arrows indicate course of sound waves

External Ear and Tympanic Cavity

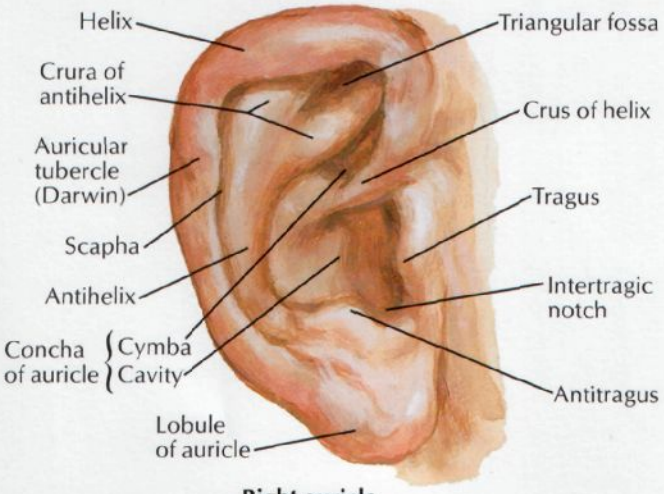

Right auricle

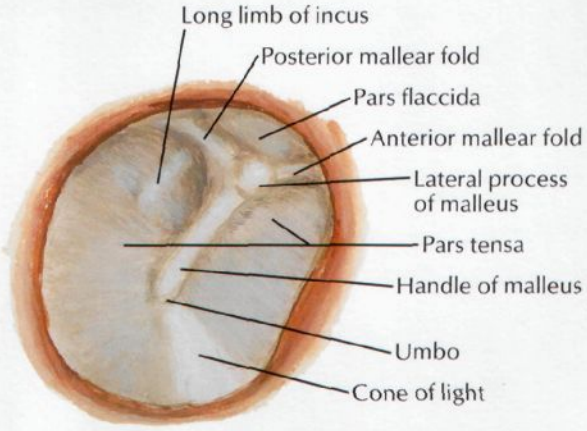

Right tympanic membrane (eardrum) viewed through speculum

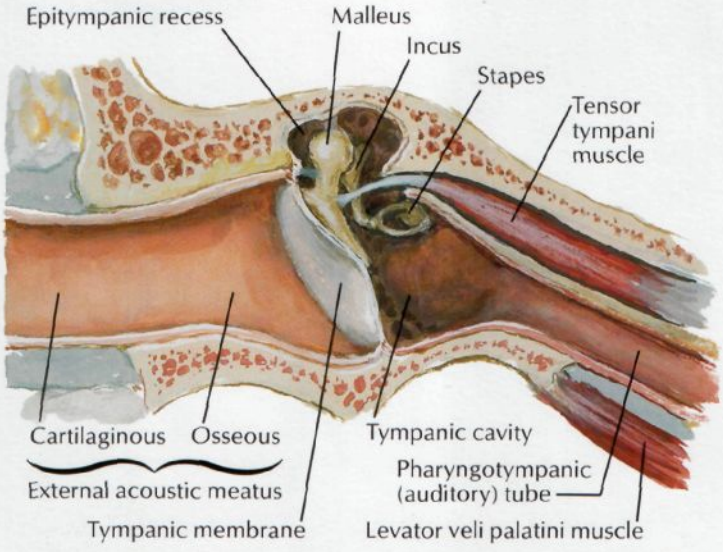

Coronal oblique section of external acoustic meatus and middle ear

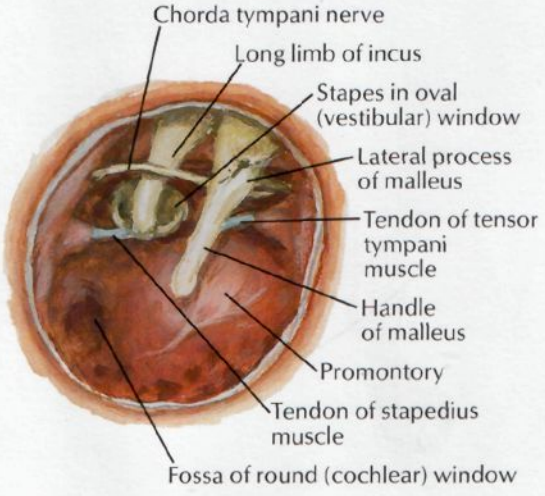

View into tympanic cavity after removal of tympanic membrane

Auditory ossicles

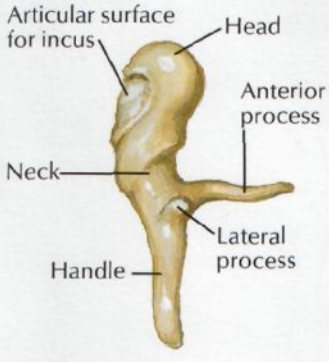

Malleus: lateral view

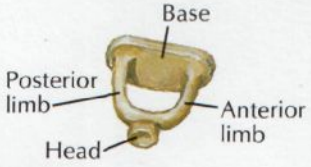

Stapes: superolateral view

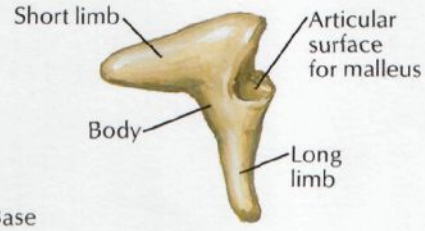

Incus: lateral view

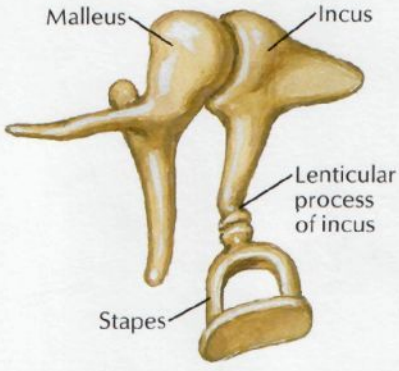

Ossicles articulated: medial view

SEE ALSO PLATES 42, 117, 118, 129

Lateral wall of tympanic cavity: medial (internal) view

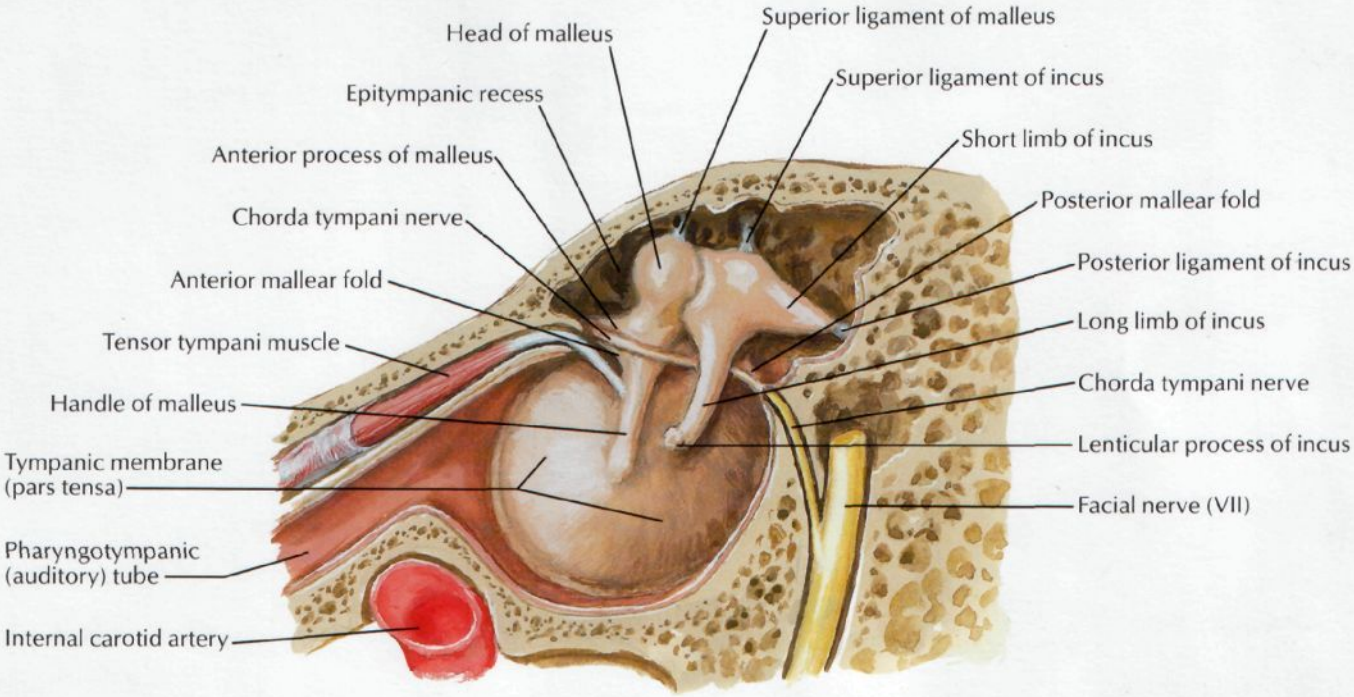

Medial wall of tympanic cavity: lateral view

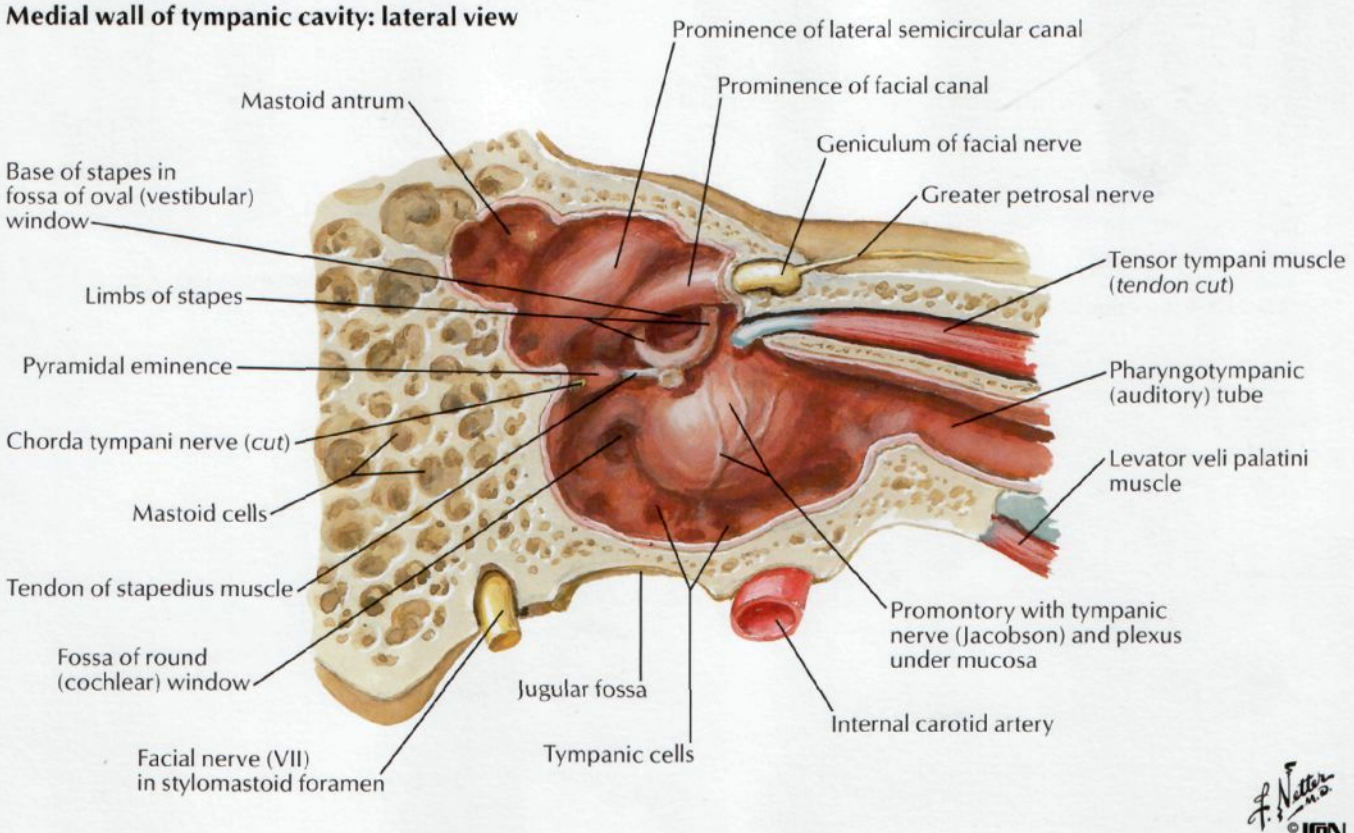

Bony and Membranous Labyrinths

SEE ALSO PLATE 118

Right bony labyrinth (otic capsule), anterolateral view: surrounding cancellous bone removed

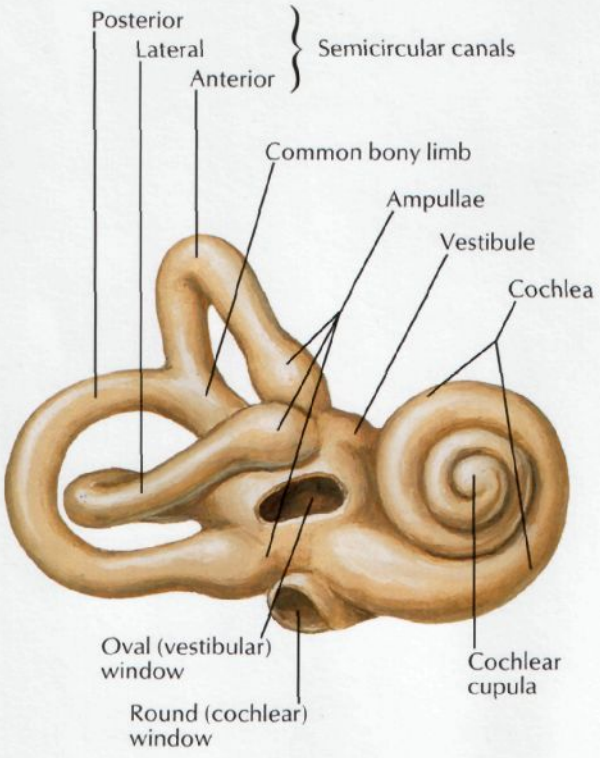

Dissected right bony labyrinth (otic capsule): membranous labyrinth removed

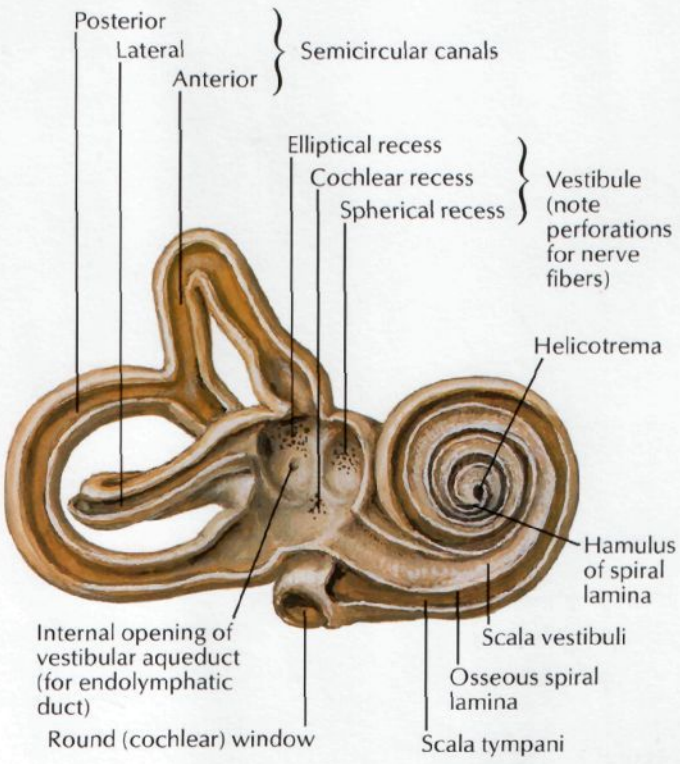

Right membranous labyrinth with nerves: posteromedial view

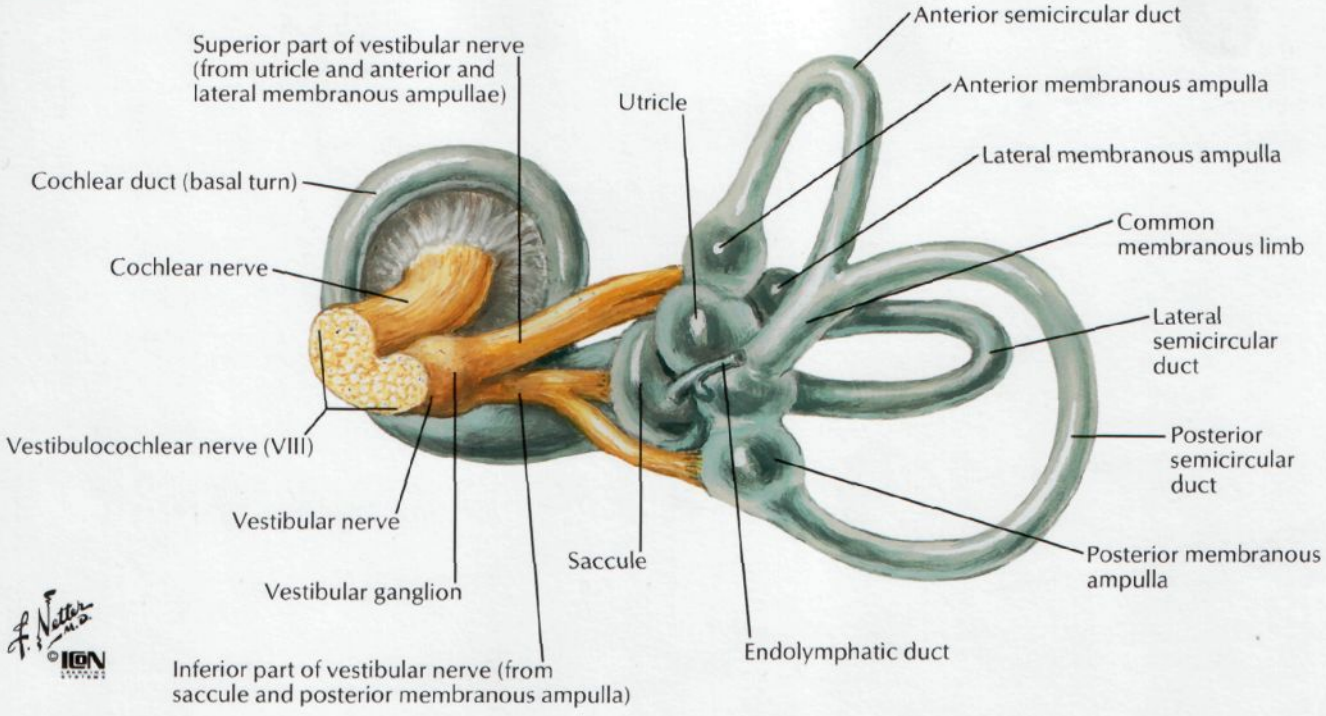

F. Netter M.D.
©ICON

Bony and membranous labyrinths: schema

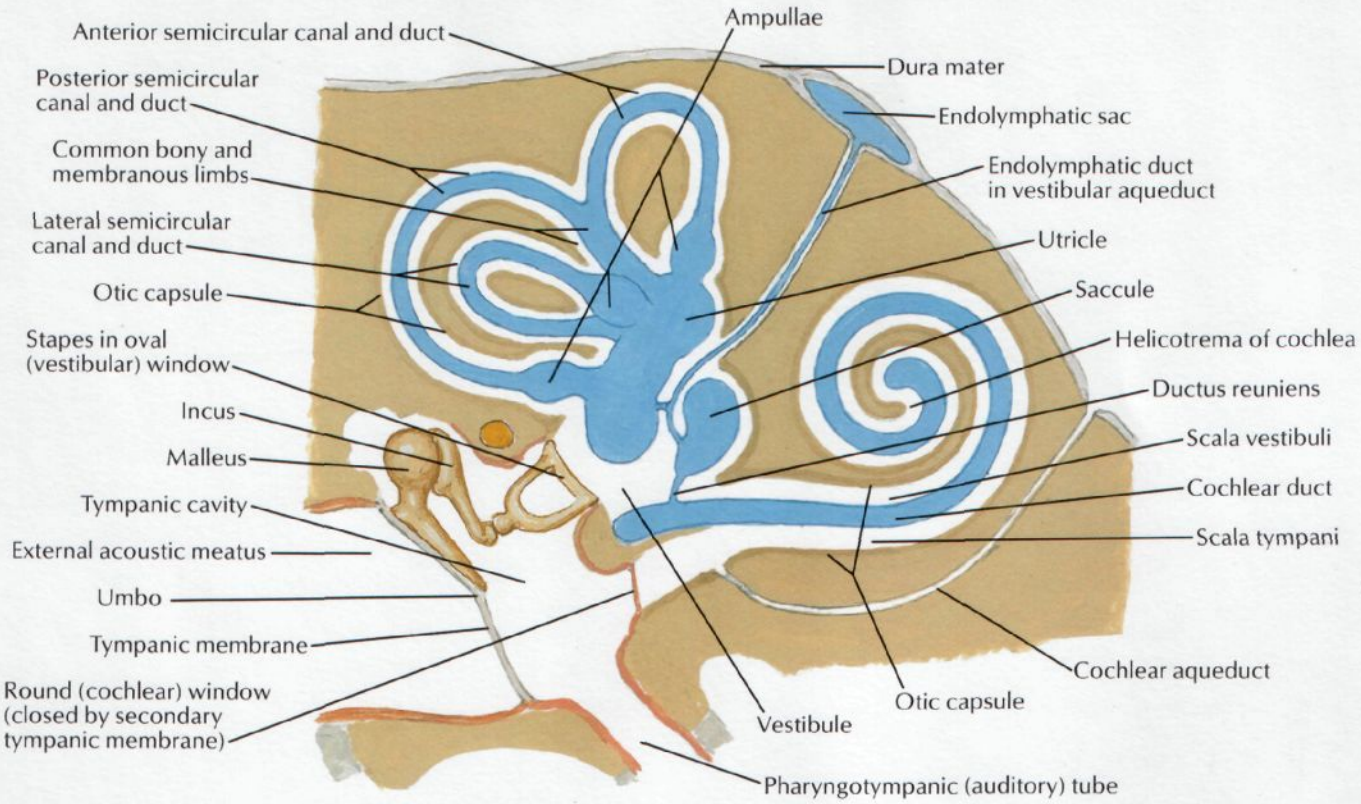

Section through turn of cochlea

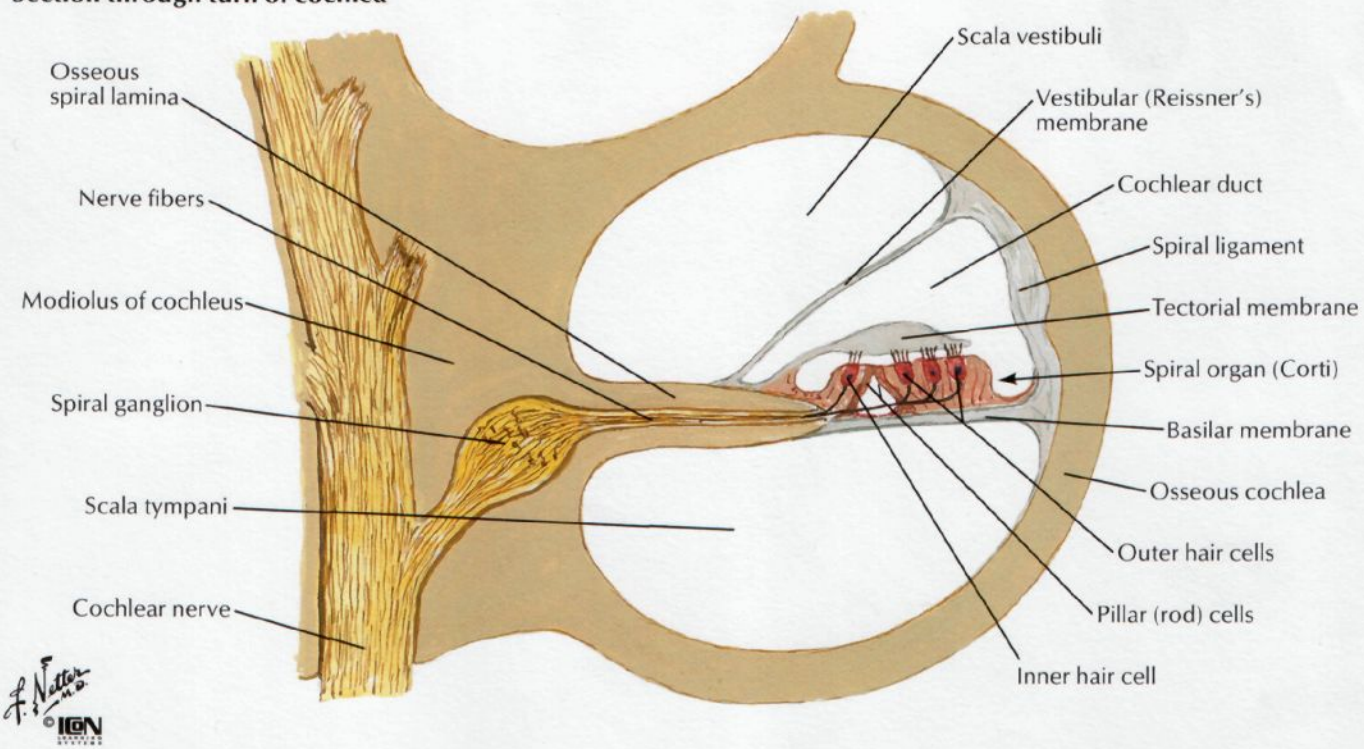

Orientation of Labyrinth in Skull

Superior projection of right bony labyrinth on floor of skull

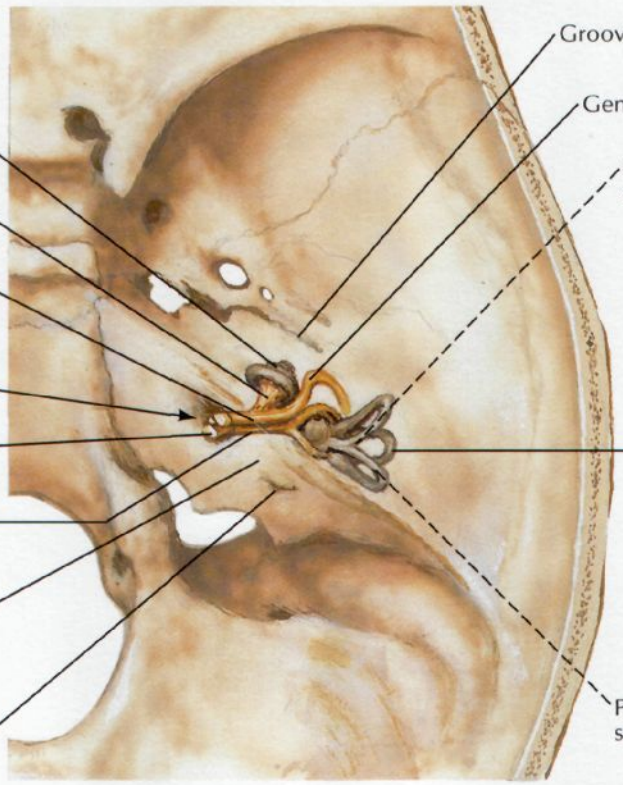

Lateral projection of right membranous labyrinth

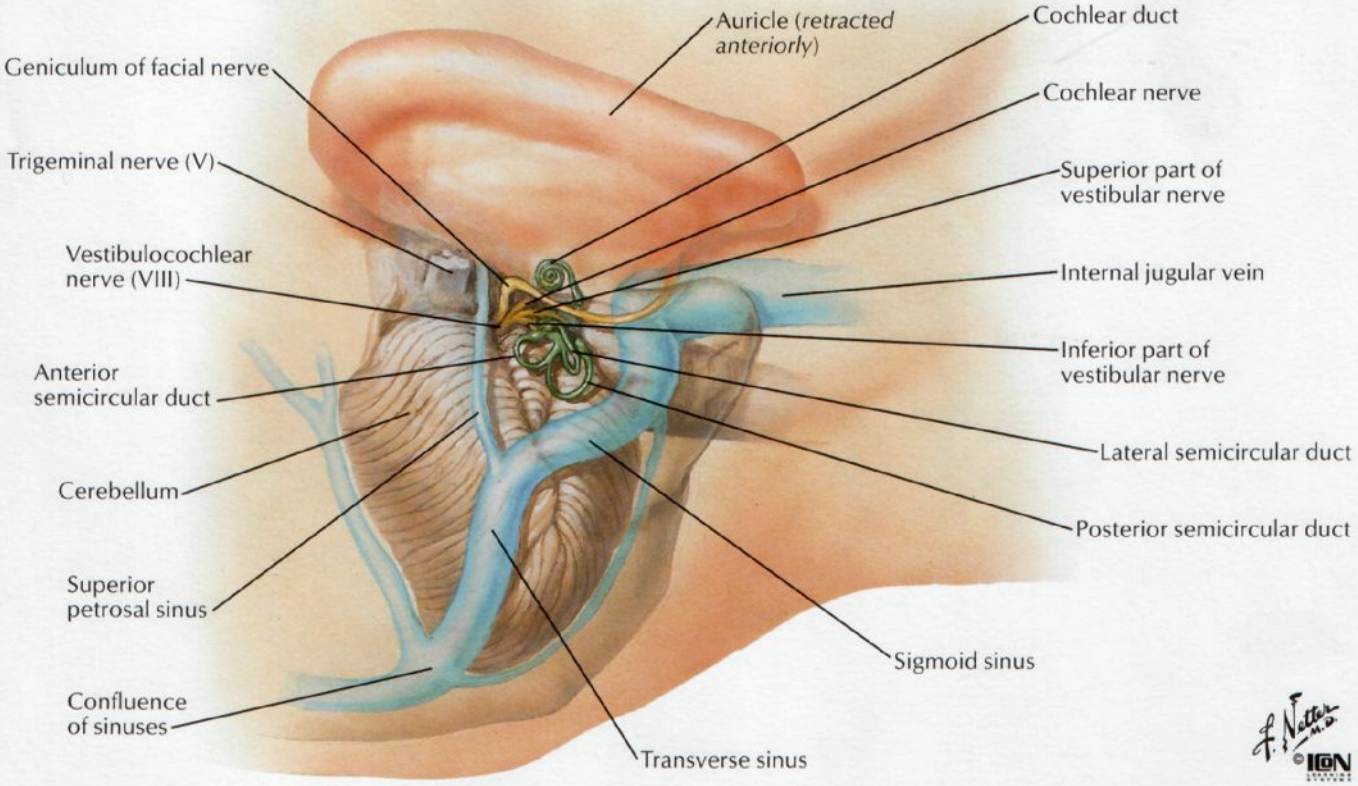

SEE ALSO PLATES 48, 51, 61

Cartilaginous part of pharyngotympanic (auditory) tube at base of skull: inferior view

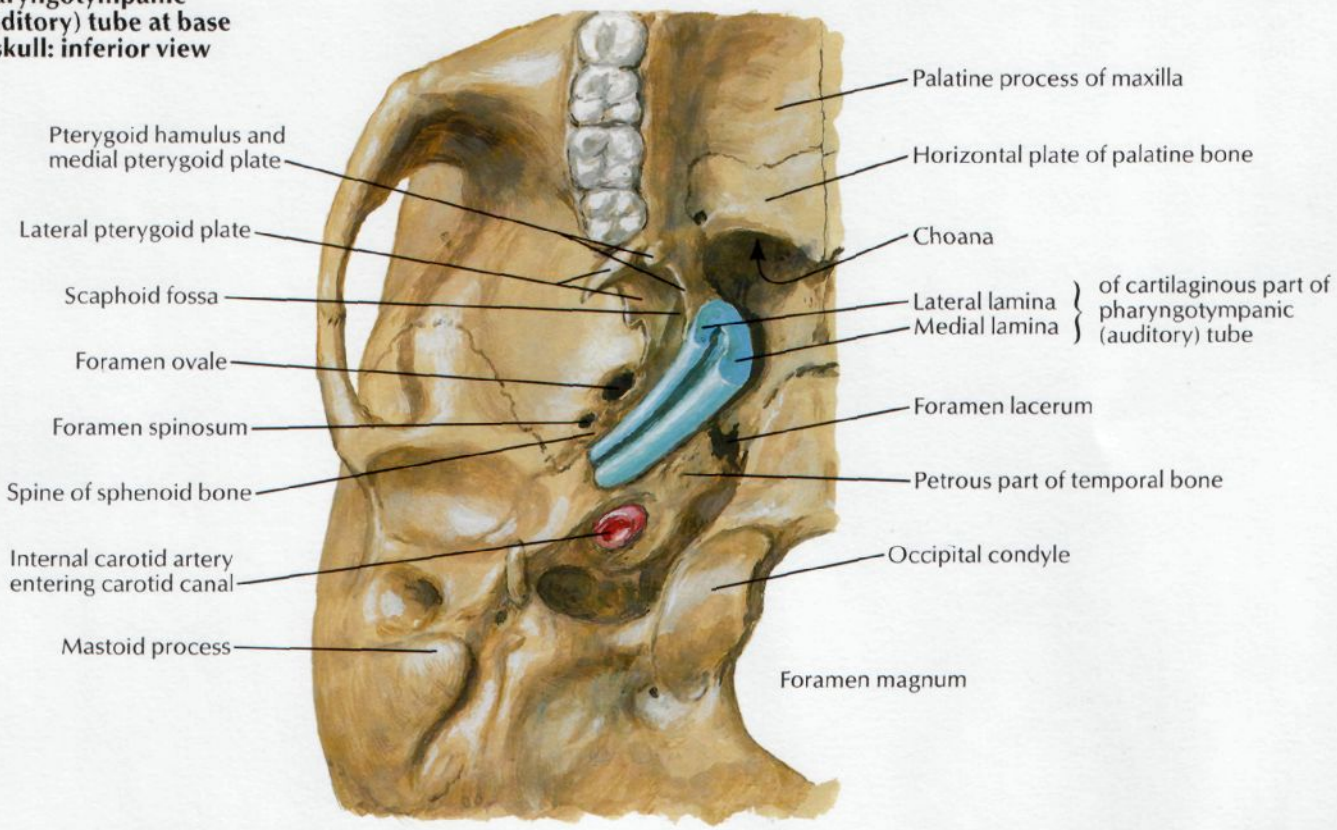

Section through cartilaginous part of pharyngotympanic (auditory) tube, with tube closed

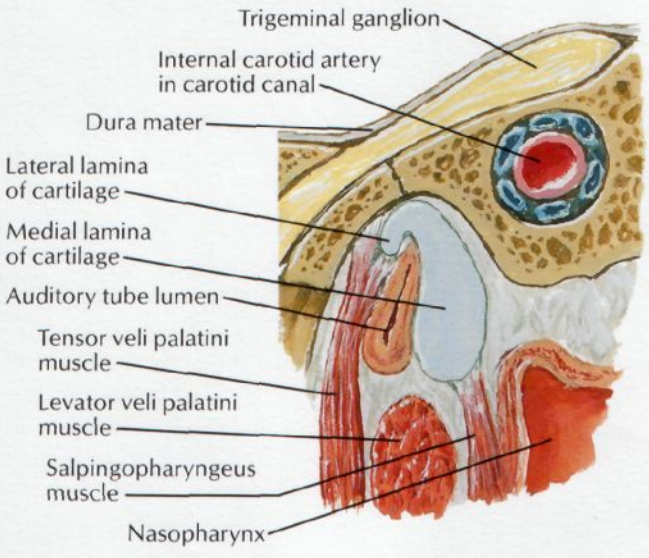

Pharyngotympanic (auditory) tube closed by elastic recoil of cartilage, tissue turgidity and tension of salpingopharyngeus muscles

Section through cartilaginous part of pharyngotympanic (auditory) tube, with tube open

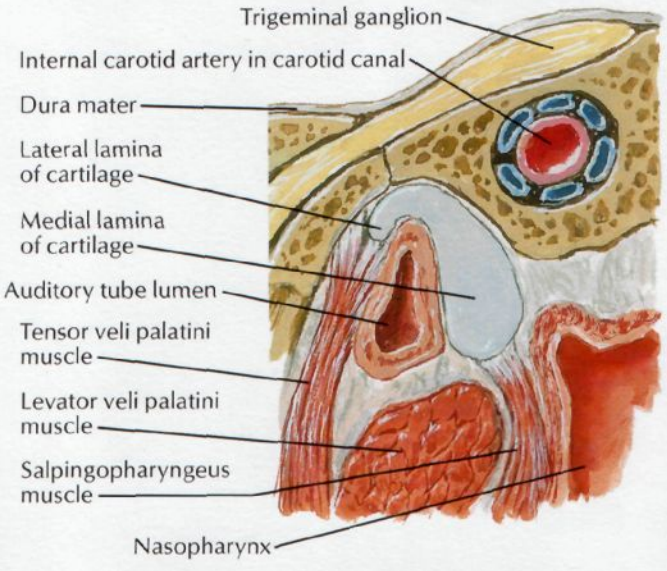

Lumen opened chiefly when attachment of tensor veli palatini muscle pulls wall of tube laterally during swallowing

F. Netter M.D. ©IGN

Meninges and Diploic Veins

SEE ALSO PLATE 19

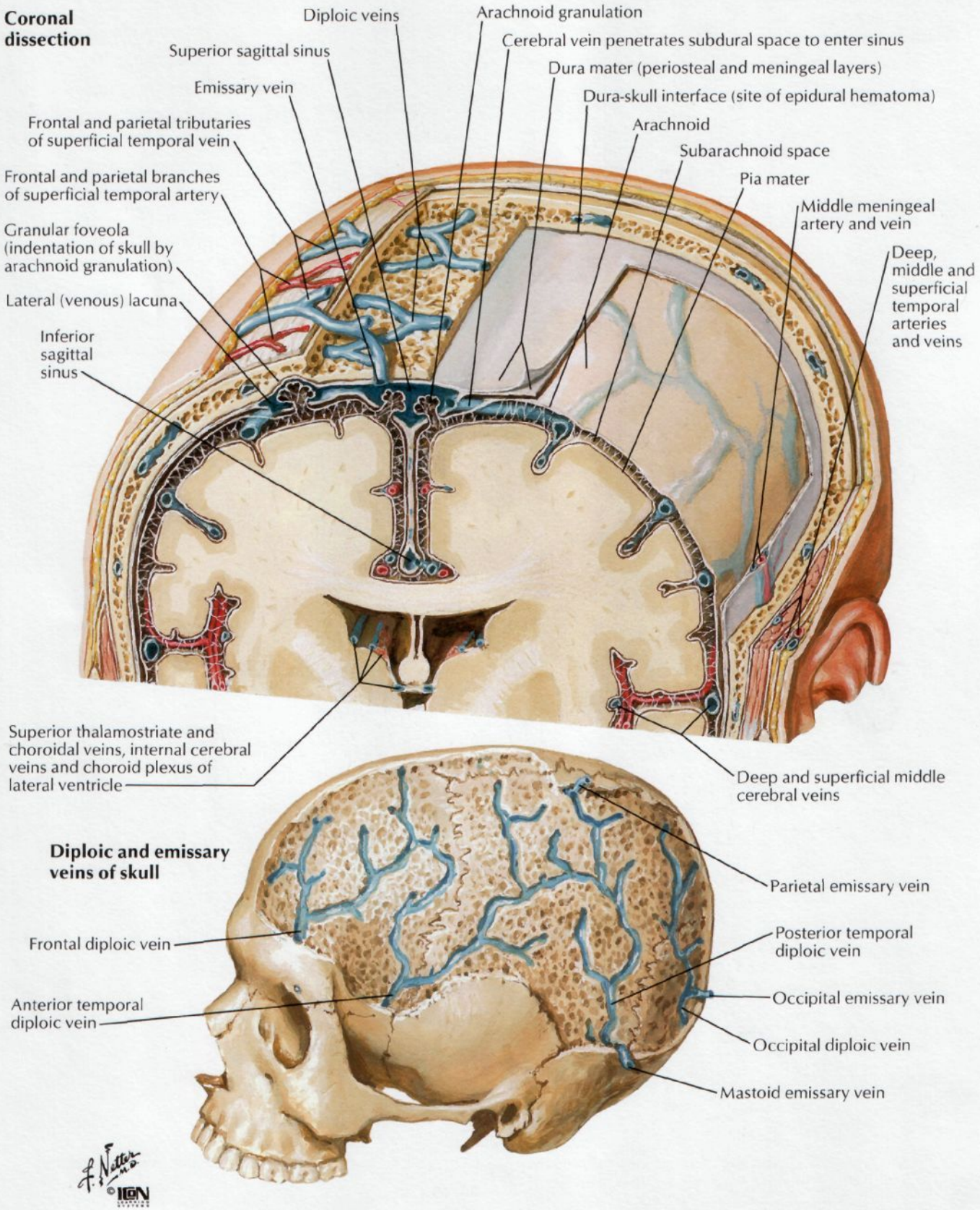

SEE ALSO PLATES 36, 130

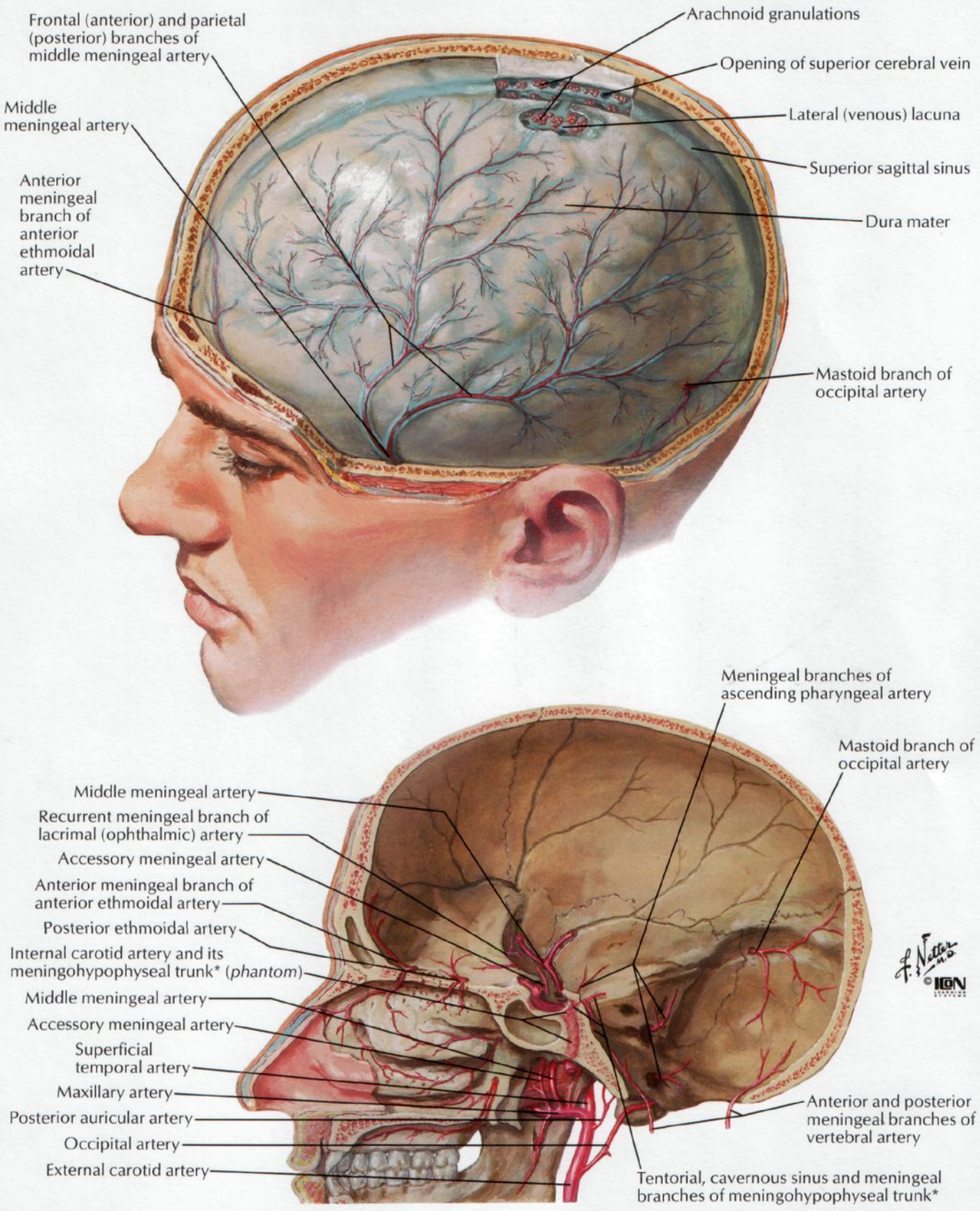

*Variant; most commonly, these branches arise directly from internal carotid artery

Meninges and Superficial Cerebral Veins

FOR DEEP VEINS OF BRAIN SEE PLATE 138

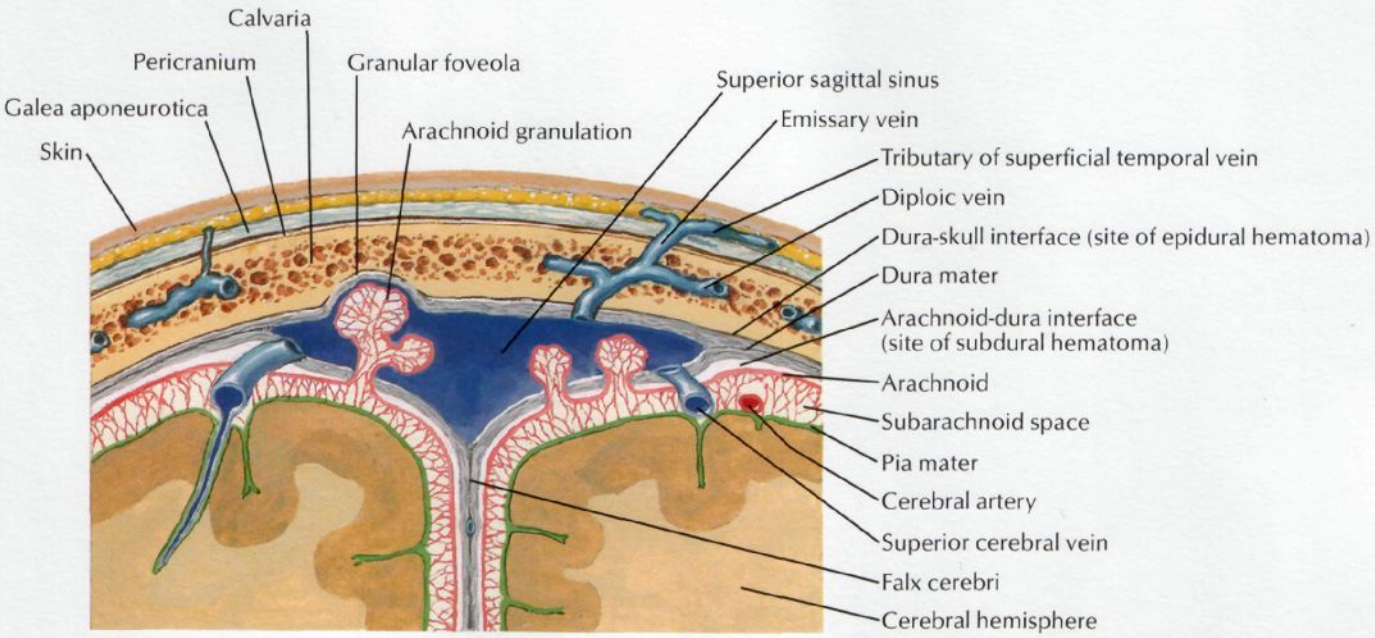

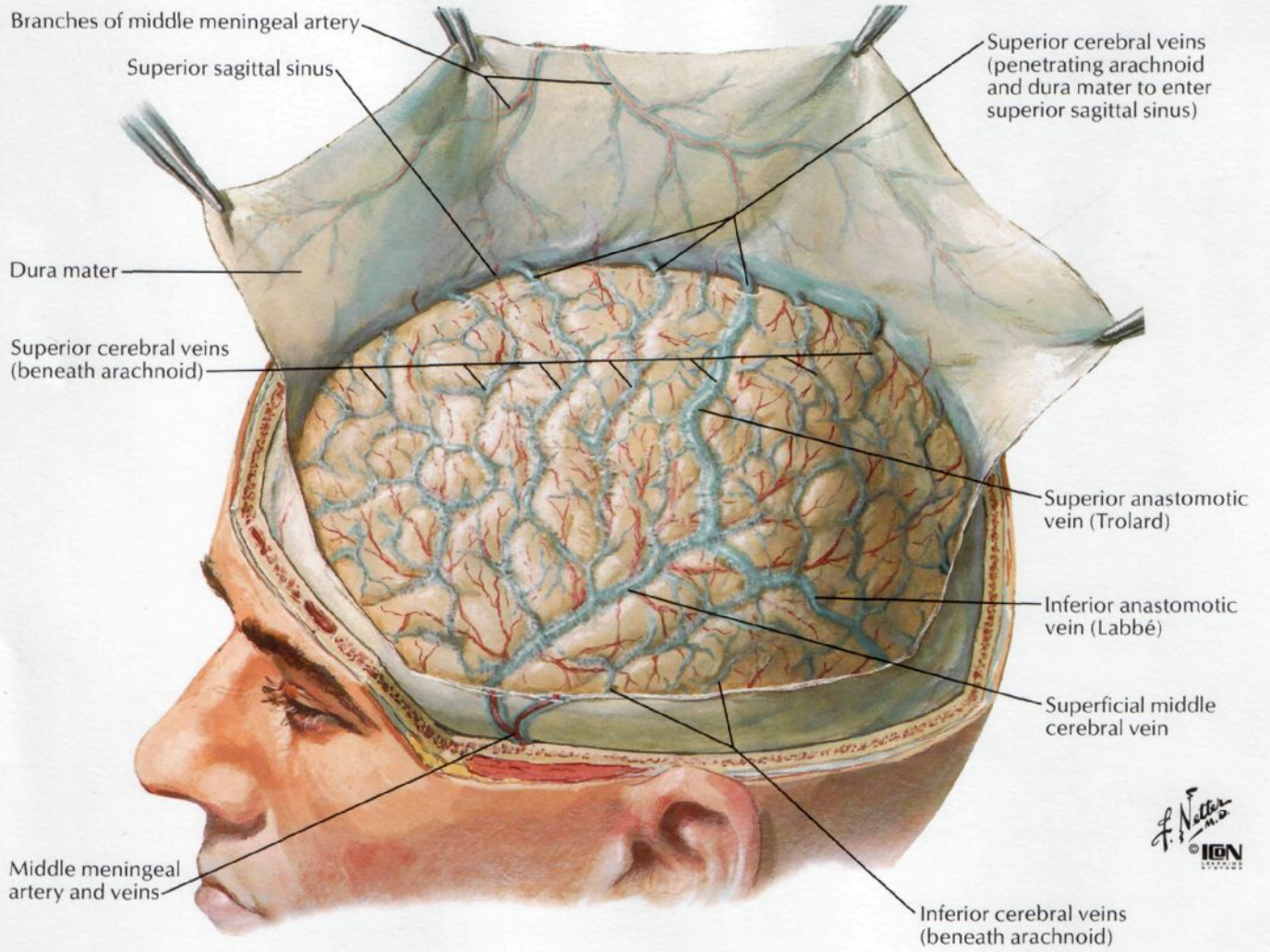

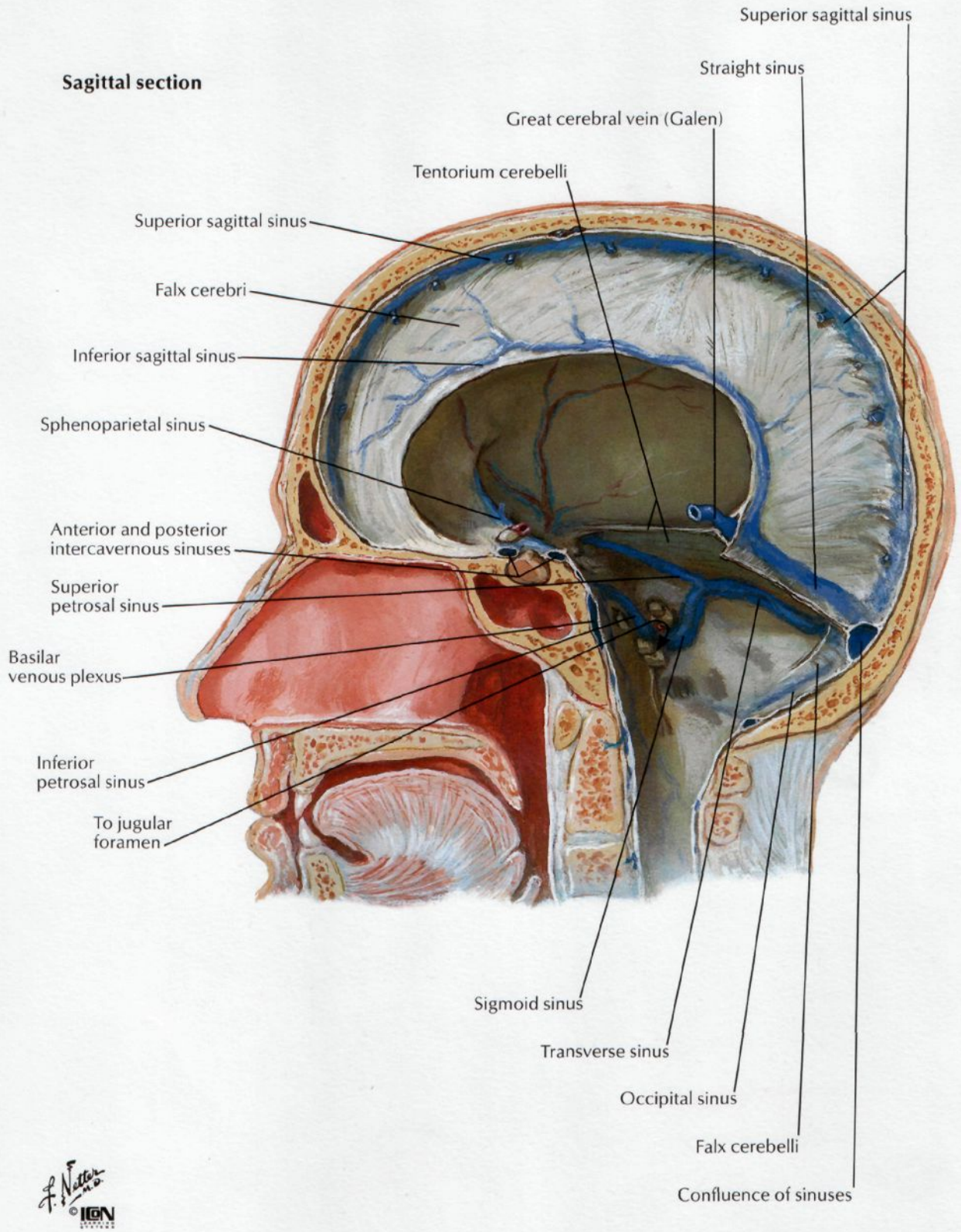
Sagittal section
Superior sagittal sinus
Straight sinus
Great cerebral vein (Galen)
Tentorium cerebelli
Superior sagittal sinus
Falx cerebri
Inferior sagittal sinus
Sphenoparietal sinus
Anterior and posterior intercavernous sinuses
Superior petrosal sinus
Basilar venous plexus
Inferior petrosal sinus
To jugular foramen
Sigmoid sinus
Transverse sinus
Occipital sinus
Falx cerebelli
Confluence of sinuses
F. Netter M.D.
©

Dural Venous Sinuses (continued)

SEE ALSO PLATE 81

Skull sectioned horizontally: superior view

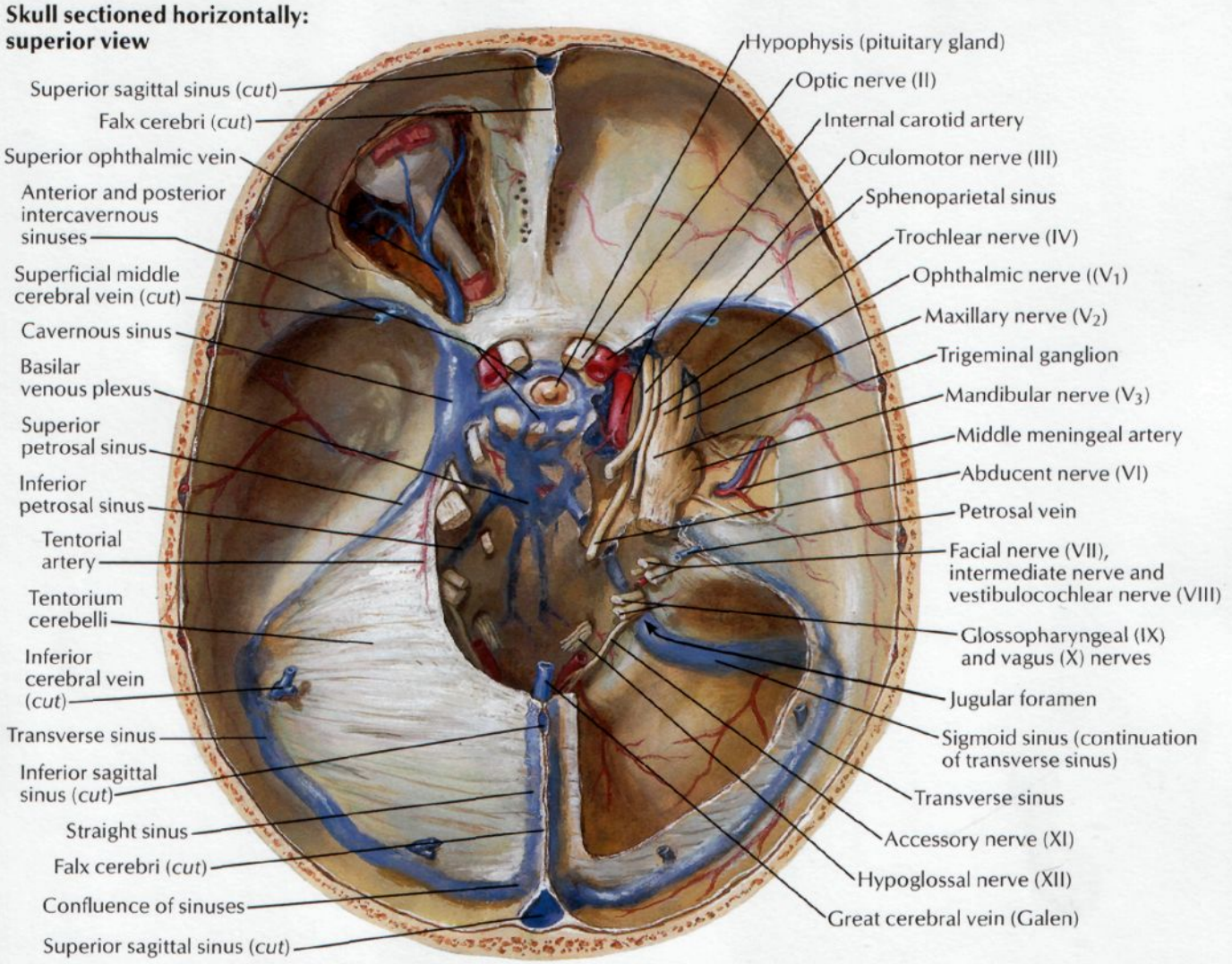

Coronal section through cavernous sinus

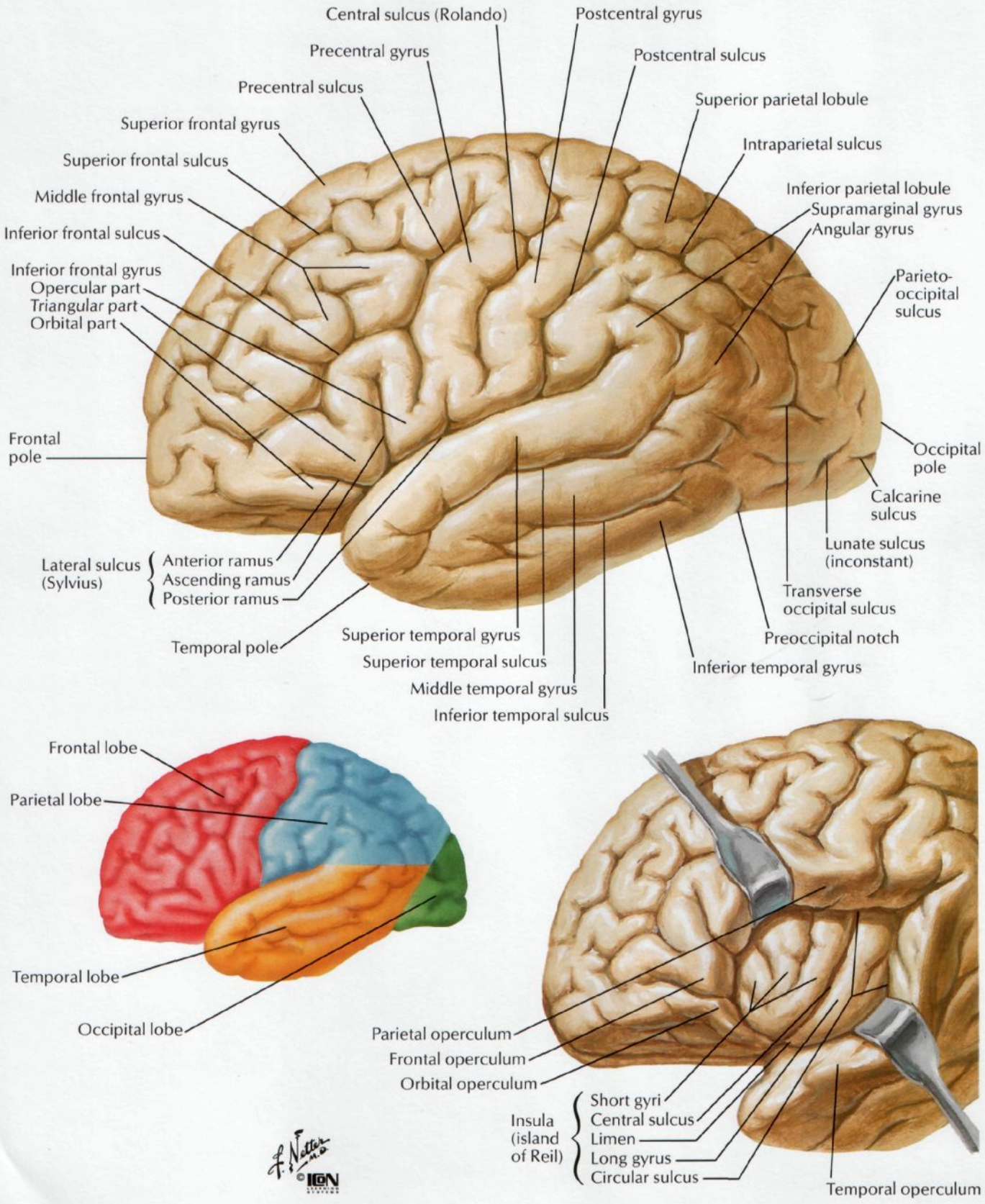
Central sulcus (Rolando)
Postcentral gyrus
Precentral gyrus
Postcentral sulcus
Precentral sulcus
Superior parietal lobule
Superior frontal gyrus
Intraparietal sulcus
Superior frontal sulcus
Inferior parietal lobule
Middle frontal gyrus
Supramarginal gyrus
Inferior frontal sulcus
Angular gyrus
Inferior frontal gyrus
Parieto-occipital sulcus
Opercular part
Triangular part
Orbital part
Frontal pole
Occipital pole
Calcarine sulcus
Lateral sulcus (Sylvius)
Anterior ramus
Ascending ramus
Posterior ramus
Lunate sulcus (inconstant)
Transverse occipital sulcus
Temporal pole
Preoccipital notch
Superior temporal gyrus
Superior temporal sulcus
Inferior temporal gyrus
Middle temporal gyrus
Inferior temporal sulcus
Frontal lobe
Parietal lobe
Temporal lobe
Occipital lobe
Parietal operculum
Frontal operculum
Orbital operculum
Insula (island of Reil)
Short gyri
Central sulcus
Limen
Long gyrus
Circular sulcus
Temporal operculum

Cerebrum: Medial Views

FOR HYPOPHYSIS SEE PLATE 140

Sagittal section of brain in situ

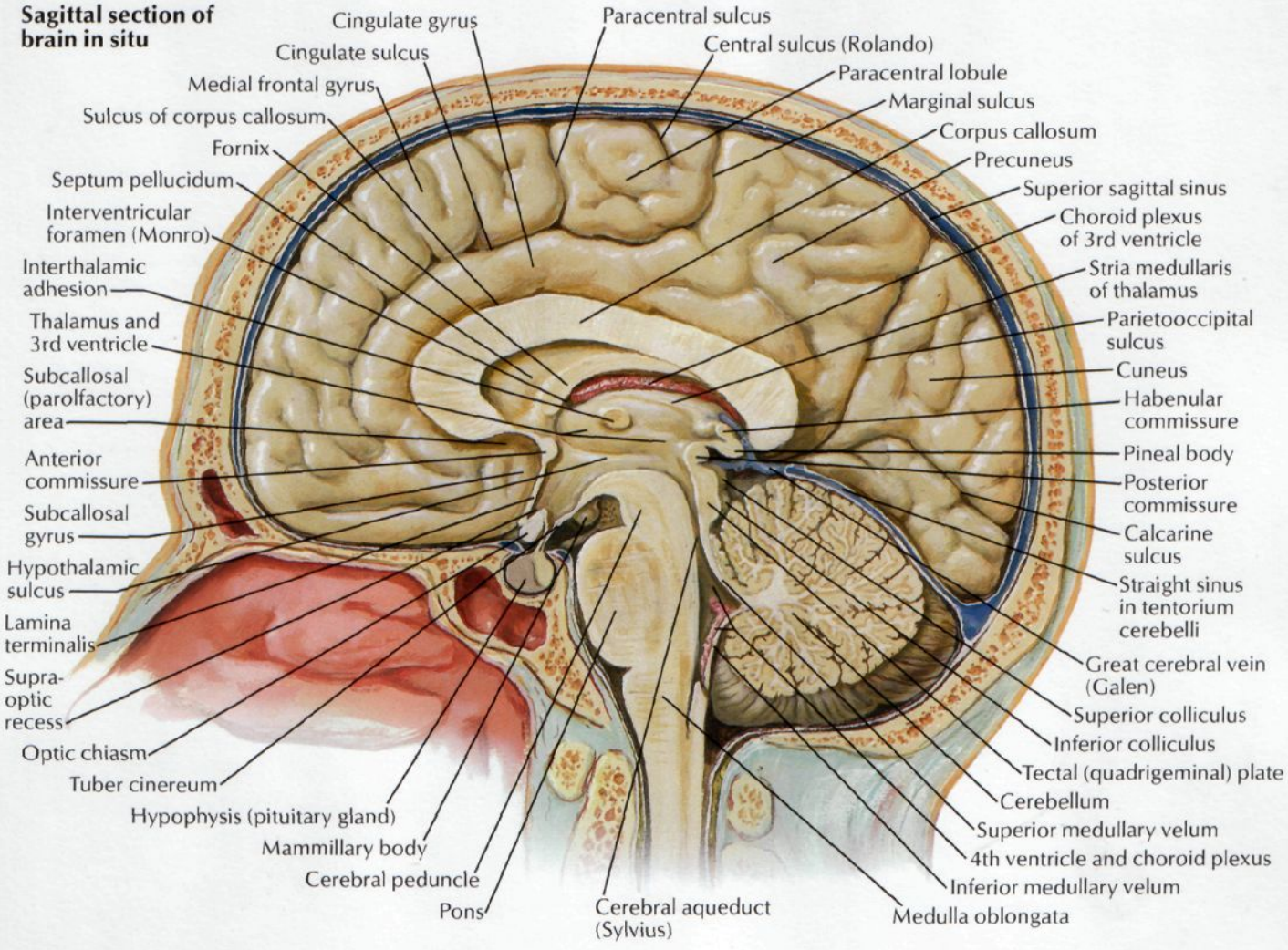

Medial surface of cerebral hemisphere: brainstem excised

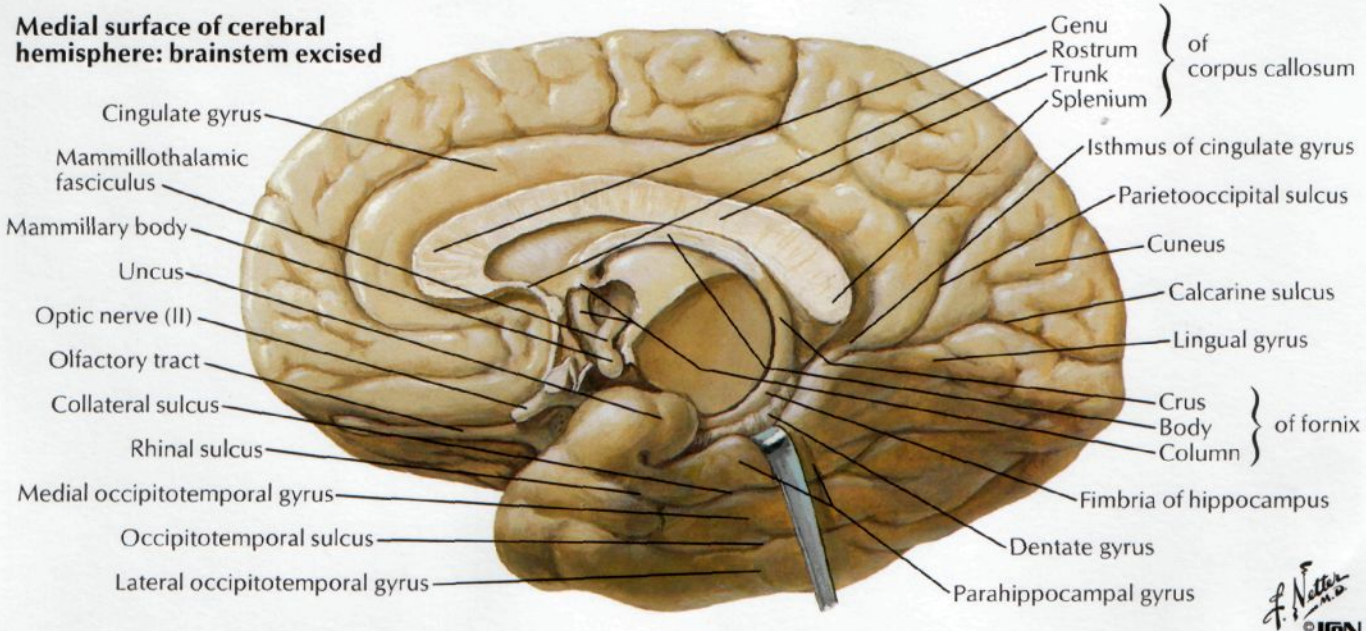

F. Netter, M.D.
©IGN

Cerebrum: Inferior View

FOR HYPOPHYSIS SEE PLATE 140

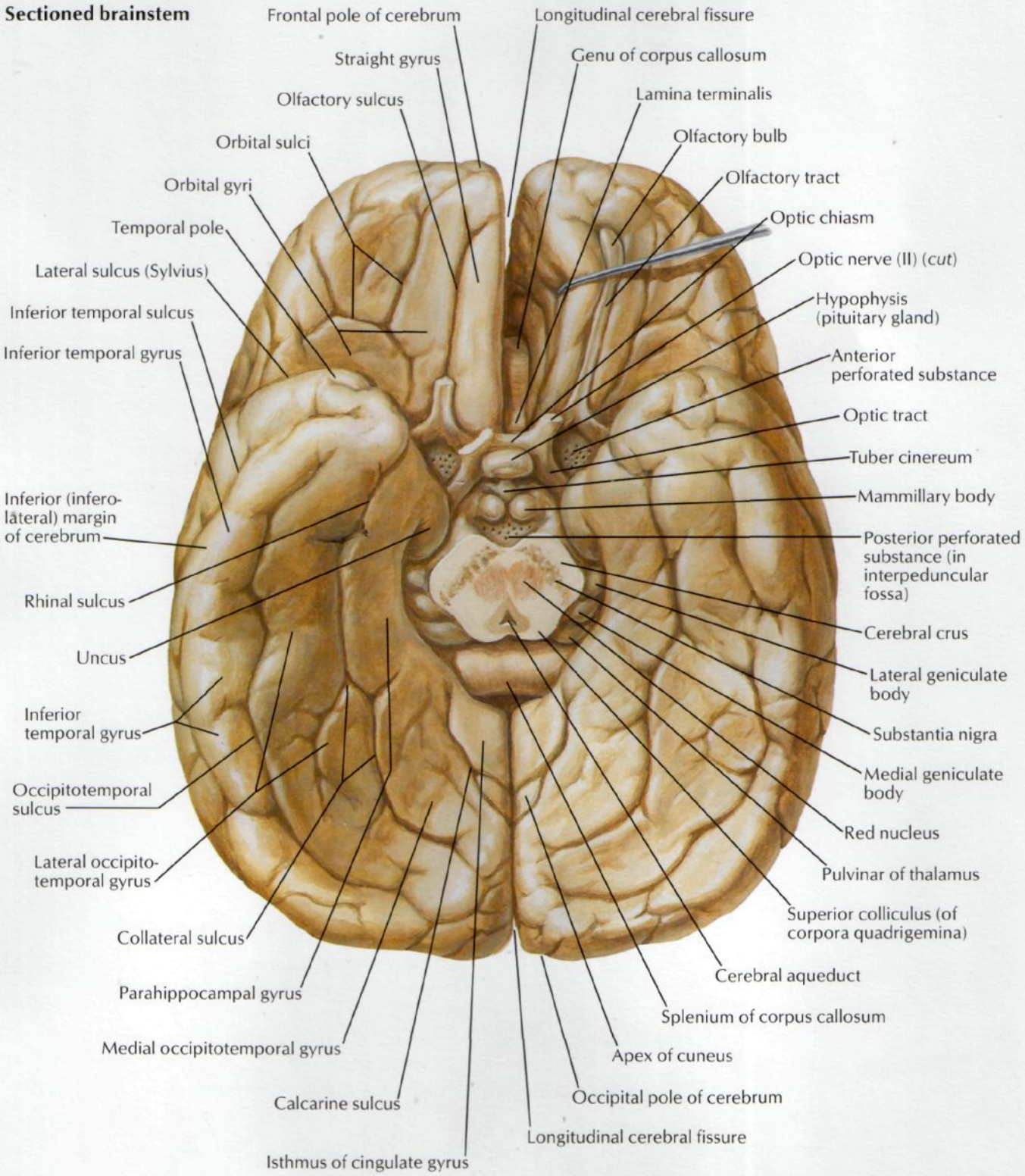

F. Netter M.D.
© ICON

Ventricles of Brain

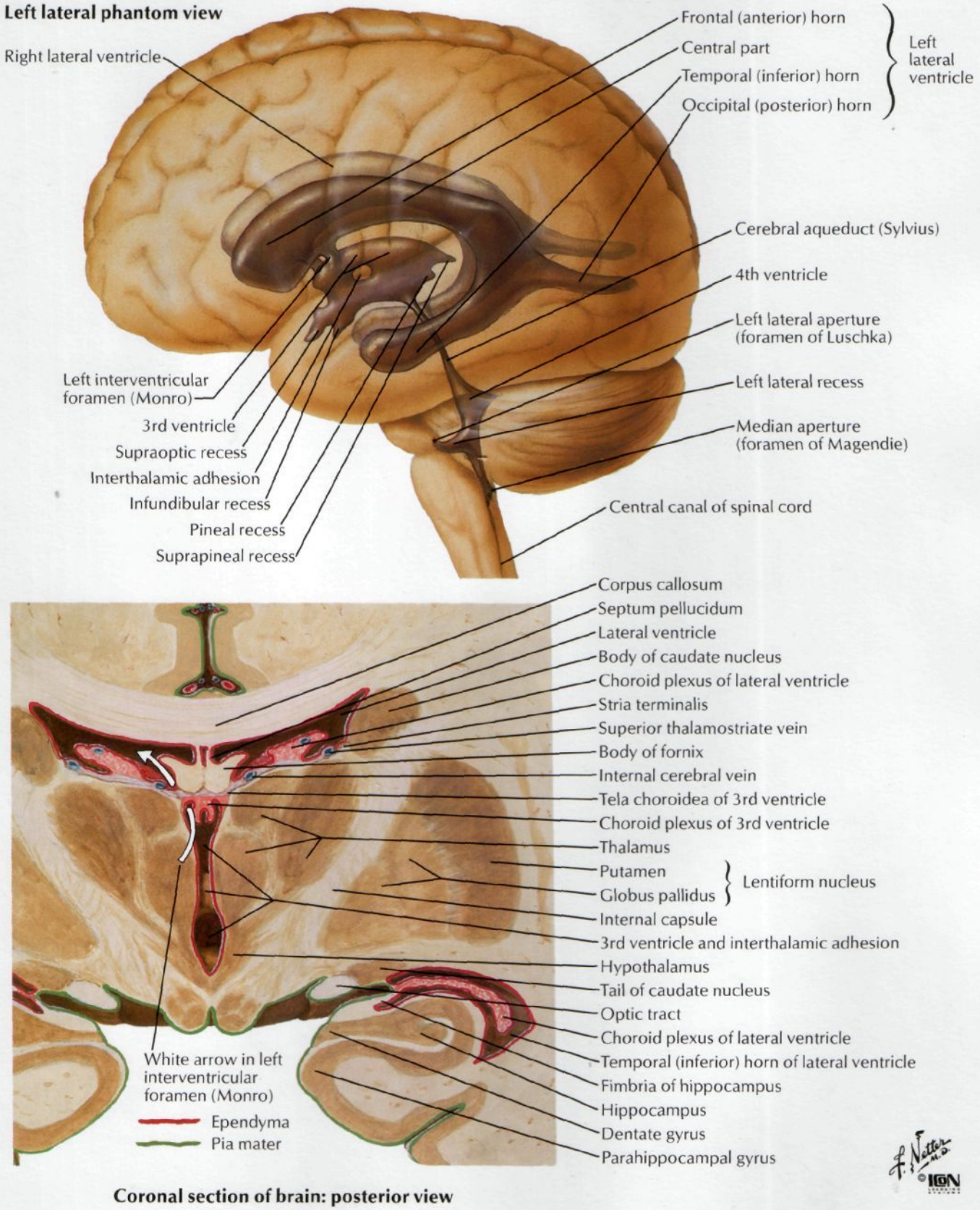

Coronal section of brain: posterior view

Circulation of Cerebrospinal Fluid

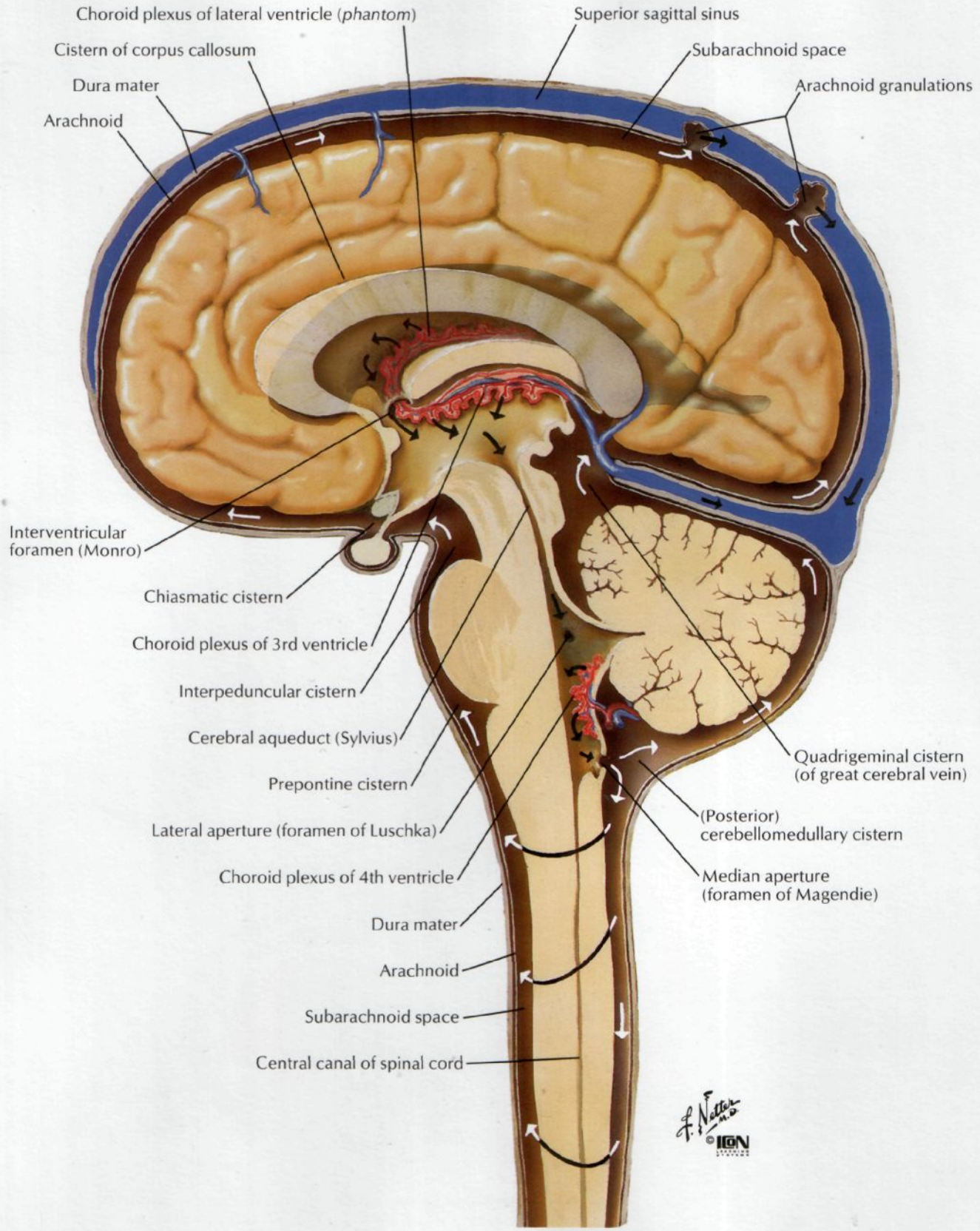

Basal Nuclei (Ganglia)

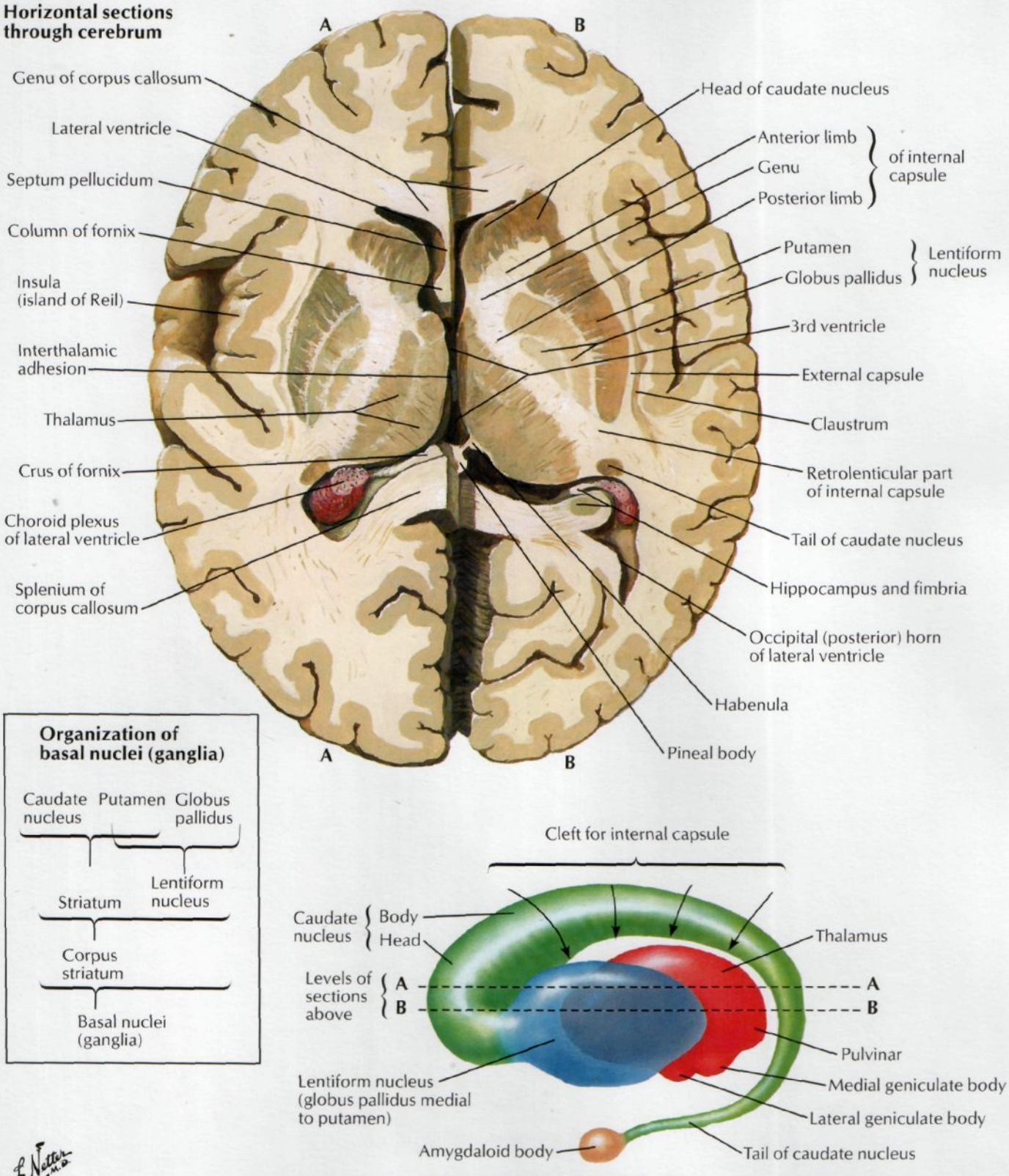

Interrelationship of thalamus, lentiform nucleus, caudate nucleus and amygdaloid body (schema): left lateral view

F. Netter M.D.
©IGN

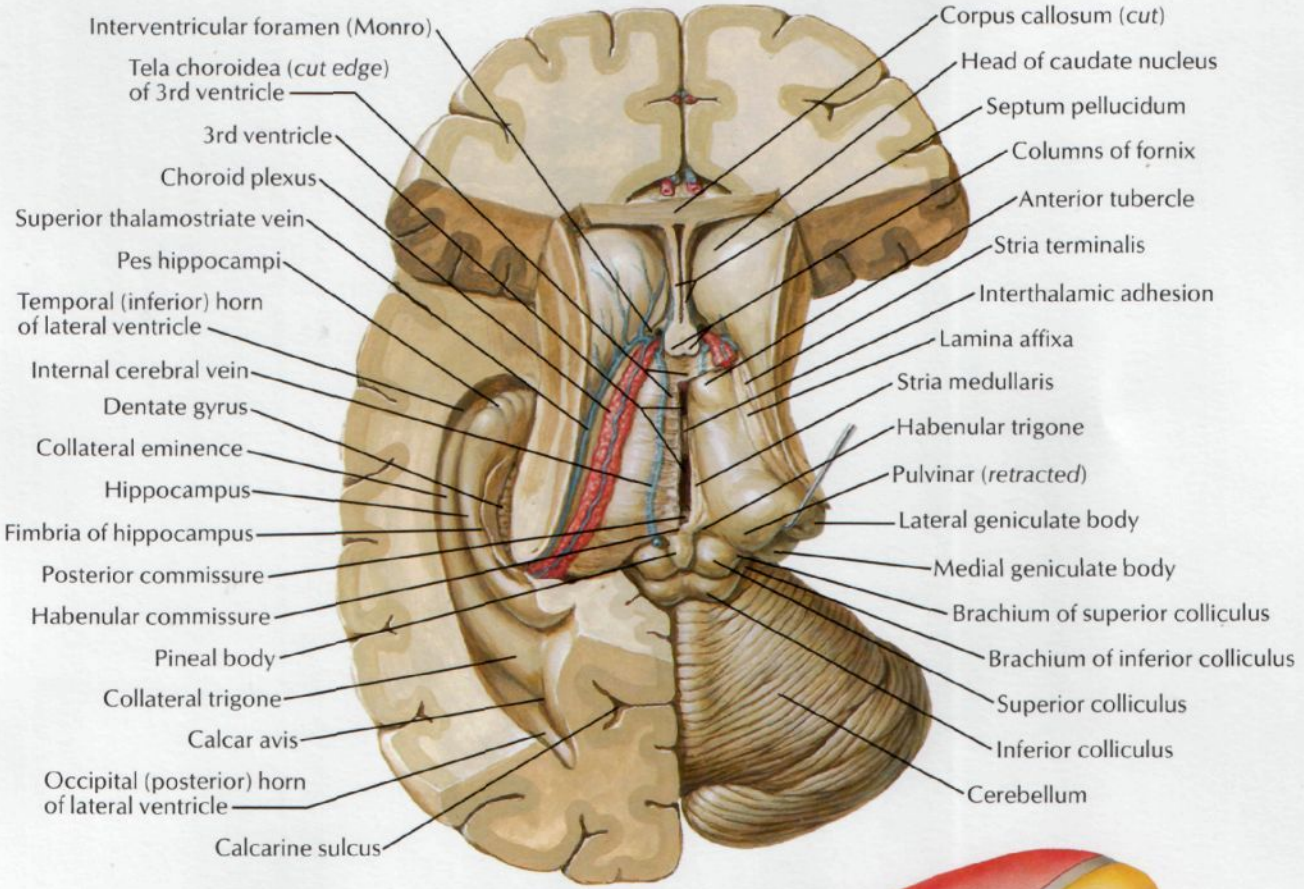

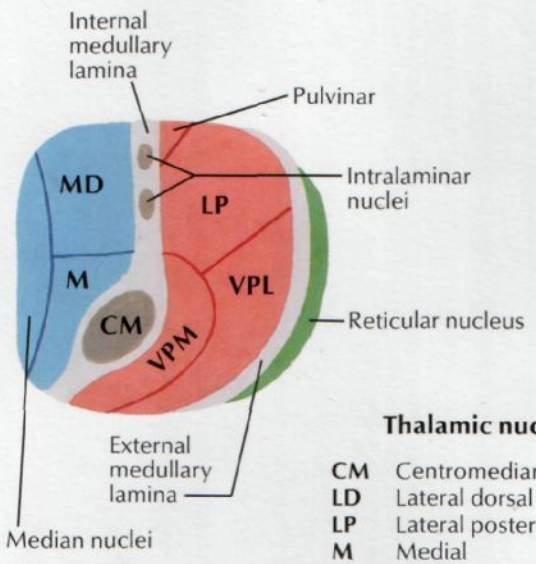

Schematic section through thalamus
(at level of broken line shown in figure at right)

Thalamic nuclei

CM	Centromedian
LD	Lateral dorsal
LP	Lateral posterior
M	Medial
MD	Medial dorsal
VA	Ventral anterior
VI	Ventral intermedial
VL	Ventral lateral
VP	Ventral posterior
VPL	Ventral posterolateral
VPM	Ventral posteromedial

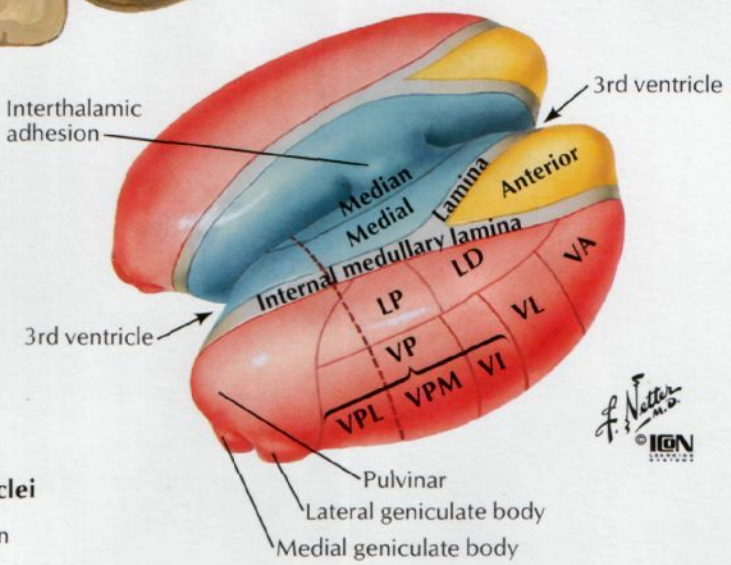

Schematic representation of thalamus
(external medullary lamina and reticular nuclei removed)

Lateral nuclei
Medial nuclei
Anterior nuclei

Hippocampus and Fornix

Superior dissection

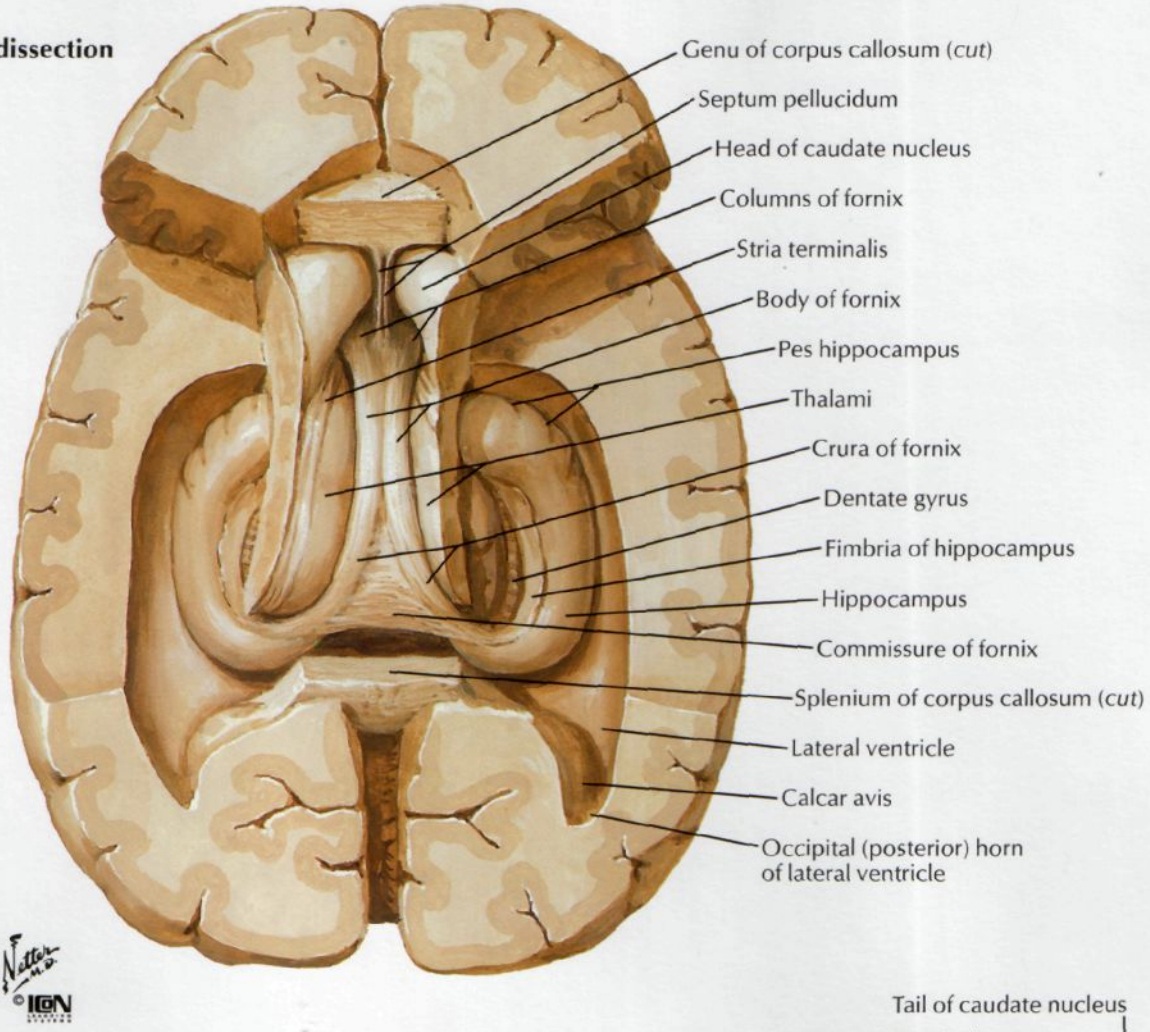

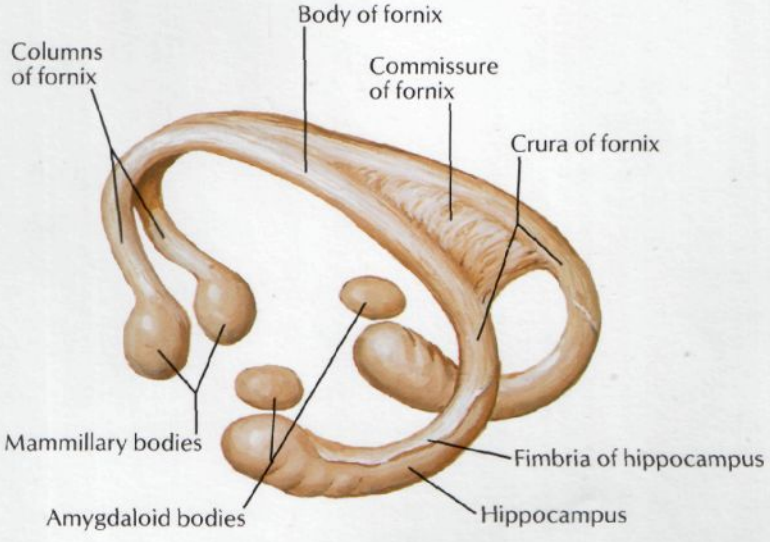

Fornix: schema

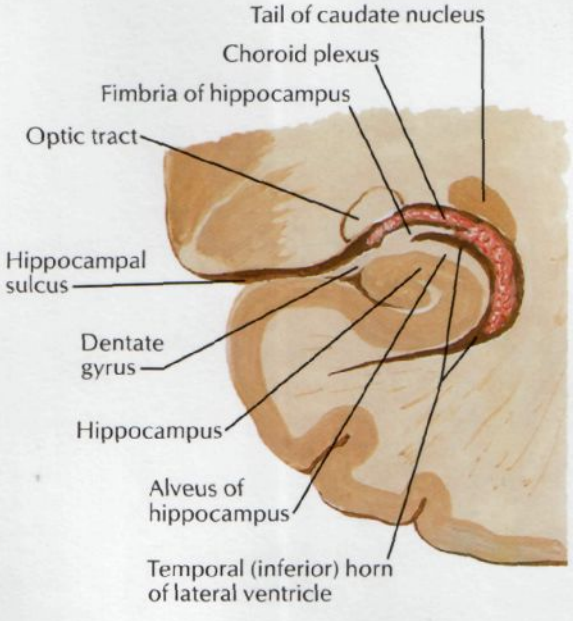

Coronal section: posterior view

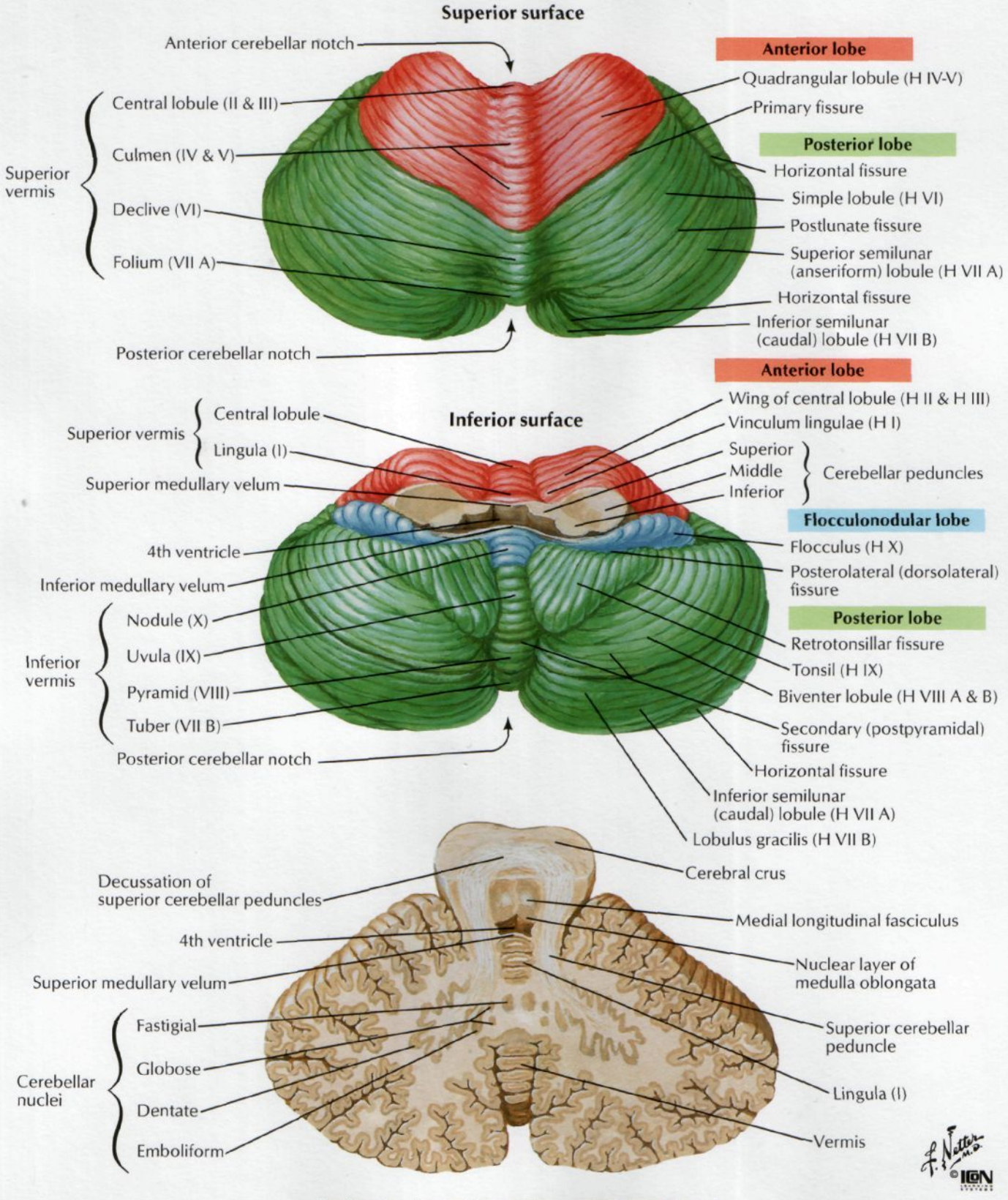

Section in plane of superior cerebellar peduncle

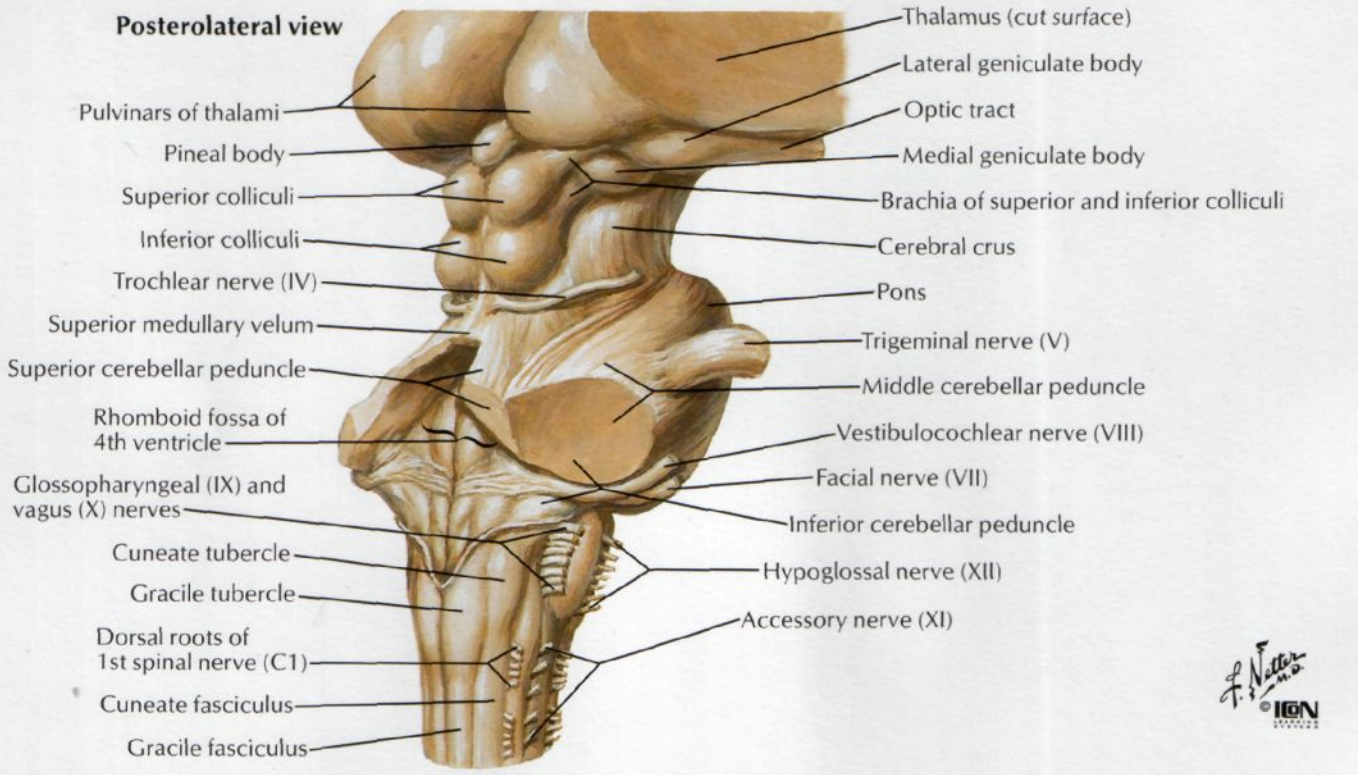
Posterolateral view
Thalamus (cut surface)
Lateral geniculate body
Optic tract
Medial geniculate body
Brachia of superior and inferior colliculi
Cerebral crus
Pons
Trigeminal nerve (V)
Middle cerebellar peduncle
Vestibulocochlear nerve (VIII)
Facial nerve (VII)
Inferior cerebellar peduncle
Hypoglossal nerve (XII)
Accessory nerve (XI)
Pulvinars of thalami
Pineal body
Superior colliculi
Inferior colliculi
Trochlear nerve (IV)
Superior medullary velum
Superior cerebellar peduncle
Rhomboid fossa of 4th ventricle
Glossopharyngeal (IX) and vagus (X) nerves
Cuneate tubercle
Gracile tubercle
Dorsal roots of 1st spinal nerve (C1)
Cuneate fasciculus
Gracile fasciculus
F. Netter, M.D.
IGN

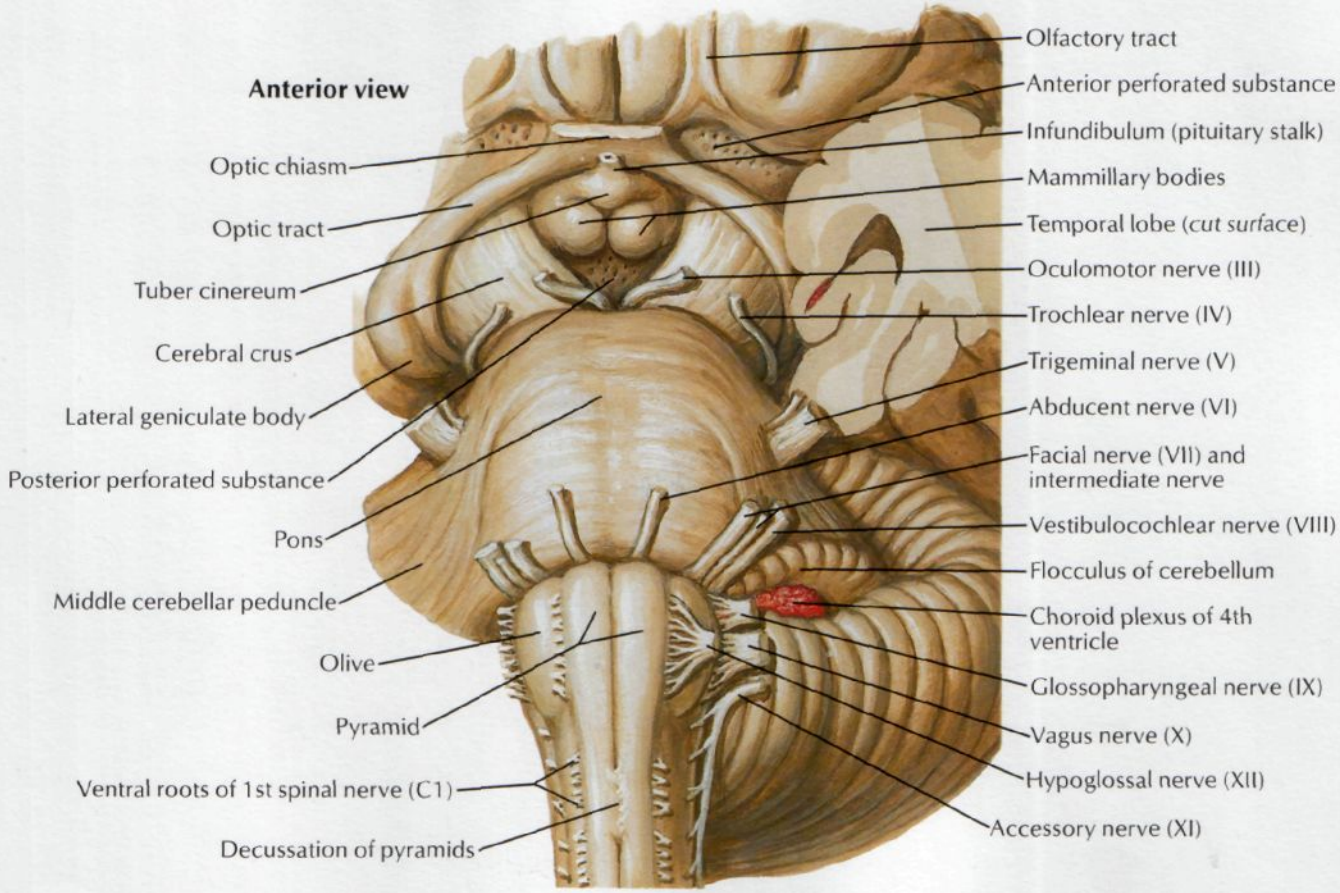
Anterior view
Olfactory tract
Anterior perforated substance
Infundibulum (pituitary stalk)
Mammillary bodies
Temporal lobe (cut surface)
Oculomotor nerve (III)
Trochlear nerve (IV)
Trigeminal nerve (V)
Abducent nerve (VI)
Facial nerve (VII) and intermediate nerve
Vestibulocochlear nerve (VIII)
Flocculus of cerebellum
Choroid plexus of 4th ventricle
Glossopharyngeal nerve (IX)
Vagus nerve (X)
Hypoglossal nerve (XII)
Accessory nerve (XI)
Optic chiasm
Optic tract
Tuber cinereum
Cerebral crus
Lateral geniculate body
Posterior perforated substance
Pons
Middle cerebellar peduncle
Olive
Pyramid
Ventral roots of 1st spinal nerve (C1)
Decussation of pyramids

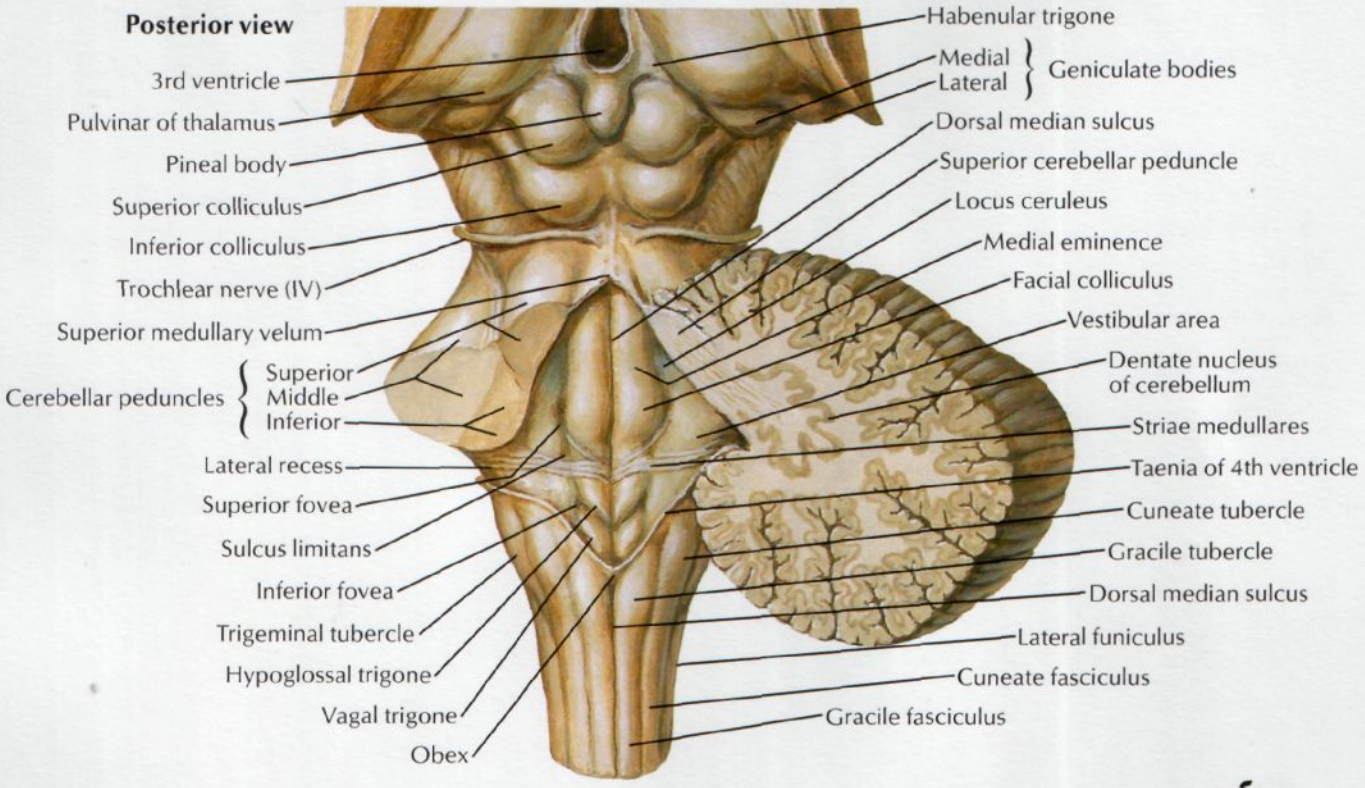
Posterior view
3rd ventricle
Pulvinar of thalamus
Pineal body
Superior colliculus
Inferior colliculus
Trochlear nerve (IV)
Superior medullary velum
Cerebellar peduncles
Superior
Middle
Inferior
Lateral recess
Superior fovea
Sulcus limitans
Inferior fovea
Trigeminal tubercle
Hypoglossal trigone
Vagal trigone
Obex
Habenular trigone
Medial
Lateral
Geniculate bodies
Dorsal median sulcus
Superior cerebellar peduncle
Locus ceruleus
Medial eminence
Facial colliculus
Vestibular area
Dentate nucleus of cerebellum
Striae medullares
Taenia of 4th ventricle
Cuneate tubercle
Gracile tubercle
Dorsal median sulcus
Lateral funiculus
Cuneate fasciculus
Gracile fasciculus

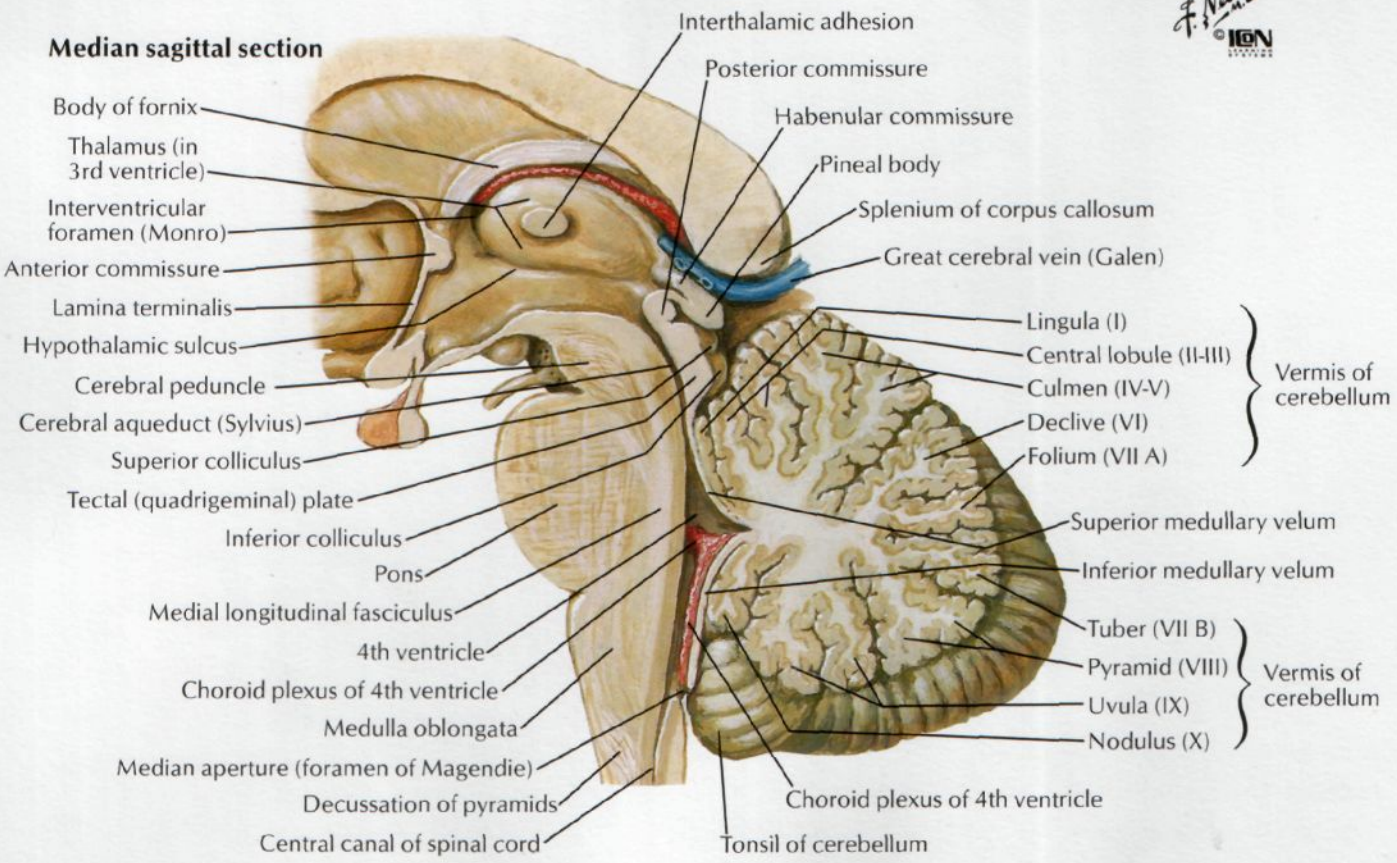
Median sagittal section
Body of fornix
Thalamus (in 3rd ventricle)
Interventricular foramen (Monro)
Anterior commissure
Lamina terminalis
Hypothalamic sulcus
Cerebral peduncle
Cerebral aqueduct (Sylvius)
Superior colliculus
Tectal (quadrigeminal) plate
Inferior colliculus
Pons
Medial longitudinal fasciculus
4th ventricle
Choroid plexus of 4th ventricle
Medulla oblongata
Median aperture (foramen of Magendie)
Decussation of pyramids
Central canal of spinal cord
Interthalamic adhesion
Posterior commissure
Habenular commissure
Pineal body
Splenium of corpus callosum
Great cerebral vein (Galen)
Lingula (I)
Central lobule (II-III)
Culmen (IV-V)
Declive (VI)
Folium (VII A)
Vermis of cerebellum
Superior medullary velum
Inferior medullary velum
Tuber (VII B)
Pyramid (VIII)
Uvula (IX)
Nodulus (X)
Vermis of cerebellum
Choroid plexus of 4th ventricle
Tonsil of cerebellum

Cranial Nerve Nuclei in Brainstem: Schema

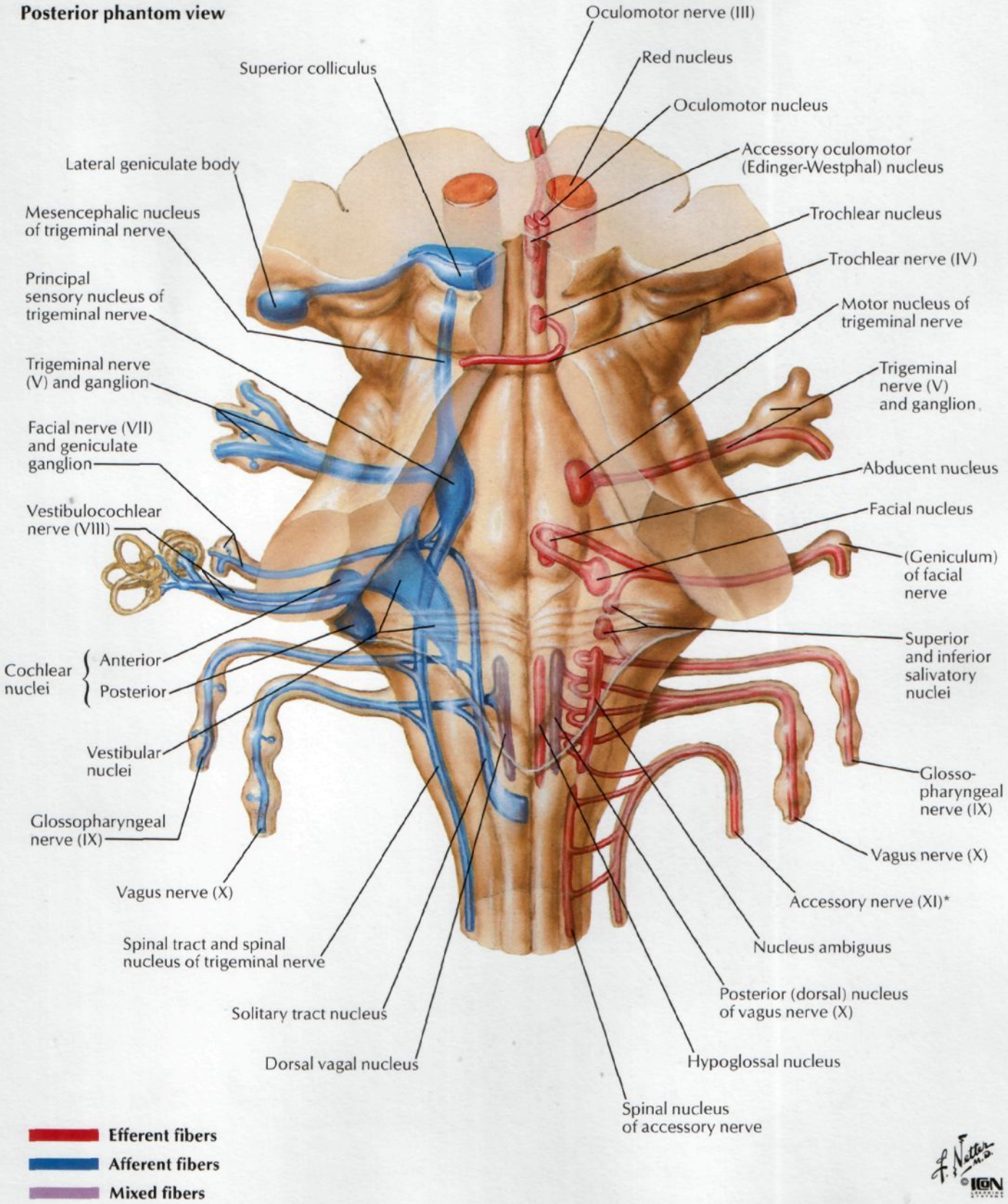

*Recent evidence suggests that the accessory nerve lacks a cranial root and has no connection to the vagus nerve. Verification of this finding awaits further investigation

Medial dissection

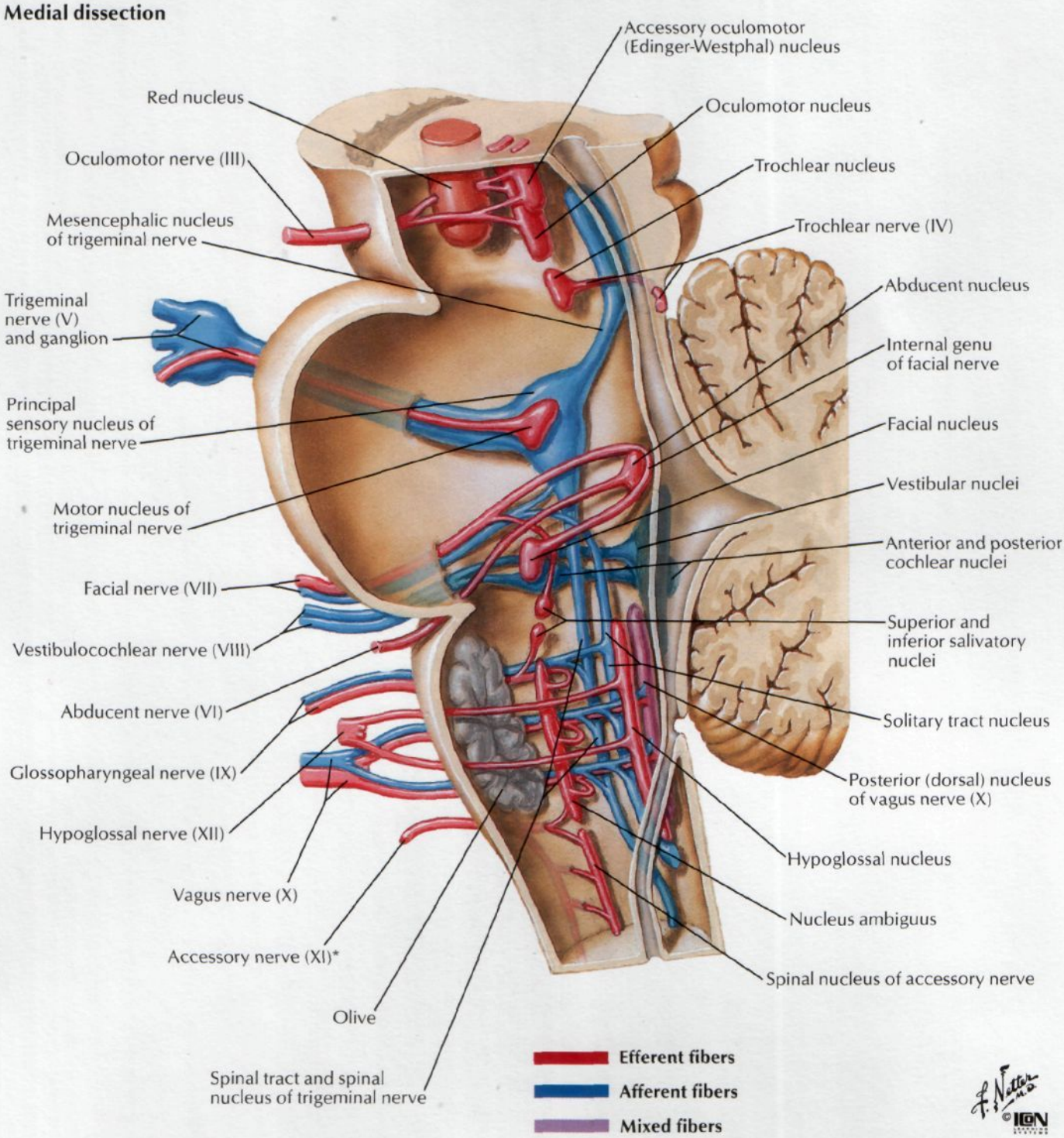

*Recent evidence suggests that the accessory nerve lacks a cranial root and has no connection to the vagus nerve. Verification of this finding awaits further investigation

Cranial Nerves (Motor and Sensory Distribution): Schema

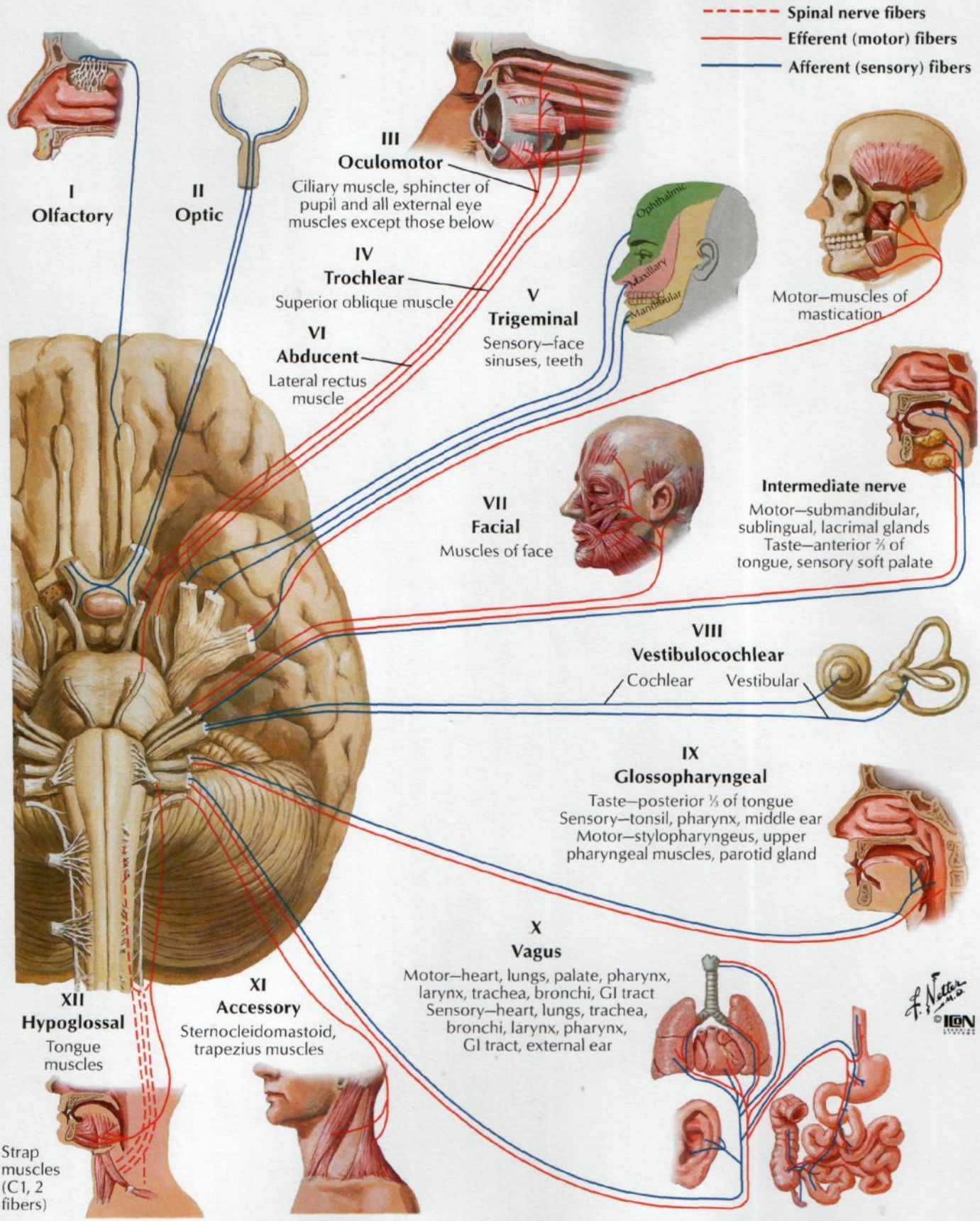

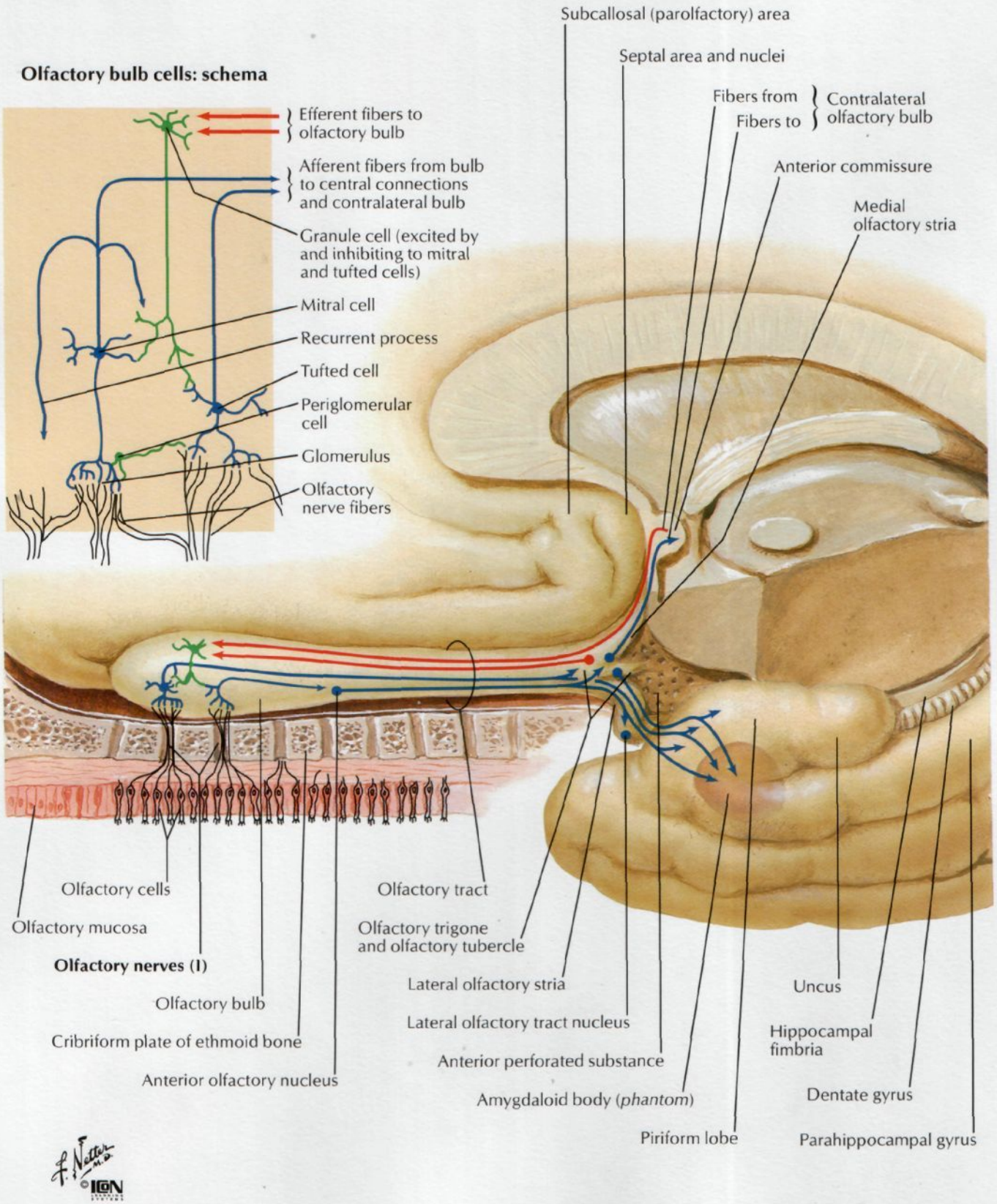
Olfactory bulb cells: schema
Efferent fibers to olfactory bulb
Afferent fibers from bulb to central connections and contralateral bulb
Granule cell (excited by and inhibiting to mitral and tufted cells)
Mitral cell
Recurrent process
Tufted cell
Periglomerular cell
Glomerulus
Olfactory nerve fibers
Subcallosal (parolfactory) area
Septal area and nuclei
Fibers from
Fibers to
Contralateral olfactory bulb
Anterior commissure
Medial olfactory stria
Olfactory cells
Olfactory mucosa
Olfactory nerves (I)
Olfactory bulb
Cribriform plate of ethmoid bone
Anterior olfactory nucleus
Olfactory tract
Olfactory trigone and olfactory tubercle
Lateral olfactory stria
Lateral olfactory tract nucleus
Anterior perforated substance
Amygdaloid body (phantom)
Piriform lobe
Uncus
Hippocampal fimbria
Dentate gyrus
Parahippocampal gyrus
F. Netter M.D.
©ICON

Optic Nerve (II) (Visual Pathway): Schema

Structure of retina: schema

- **A** Amacrine cells
- **B** Bipolar cells
- **C** Cones
- **G** Ganglion cells
- **H** Horizontal cells
- **P** Pigment cells
- **R** Rods

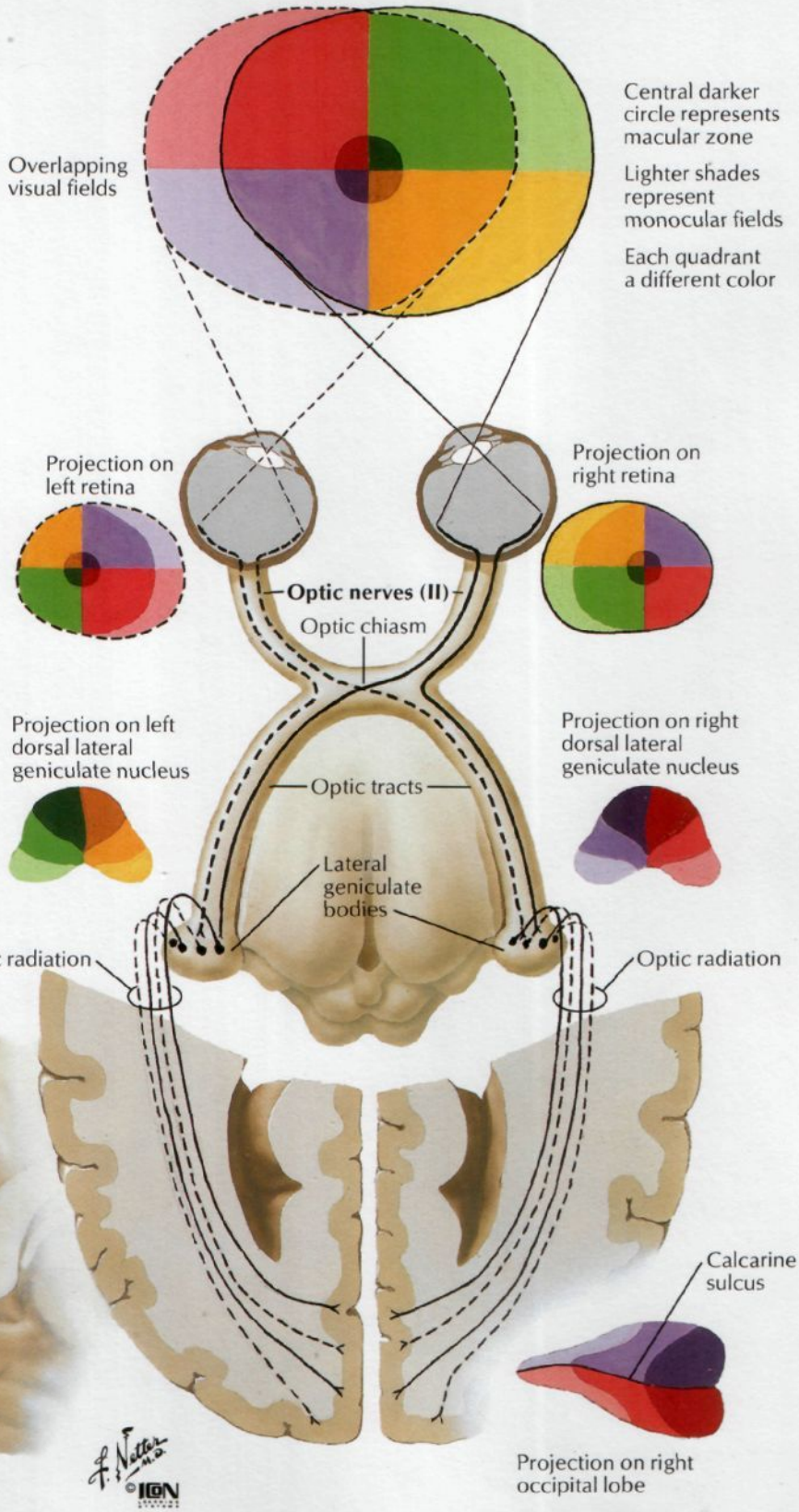

Oculomotor (III), Trochlear (IV) and Abducent (VI) Nerves: Schema

SEE ALSO PLATES 82, 126, 160

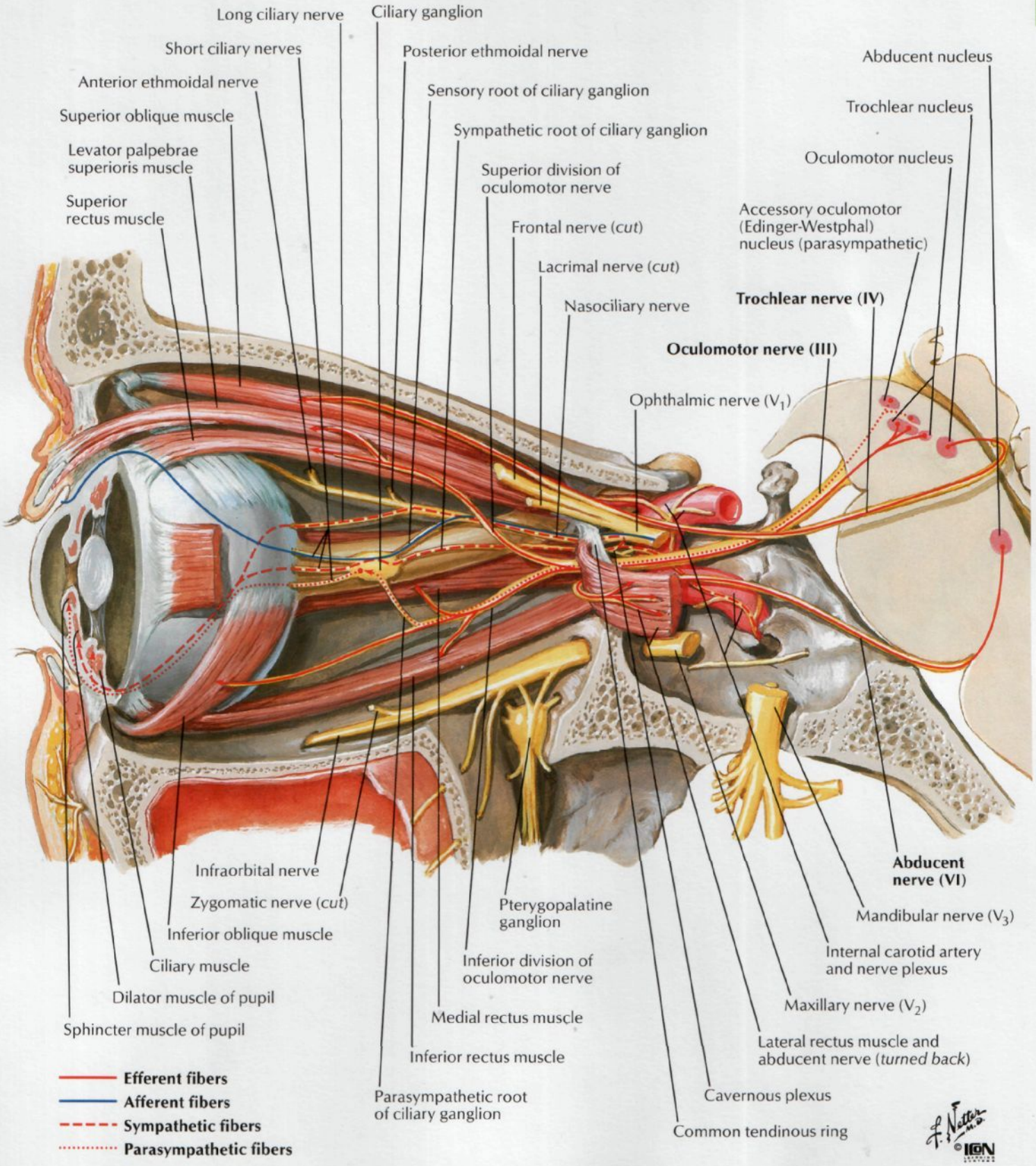

Trigeminal Nerve (V): Schema

SEE ALSO PLATES 20, 38, 39, 41, 42, 160

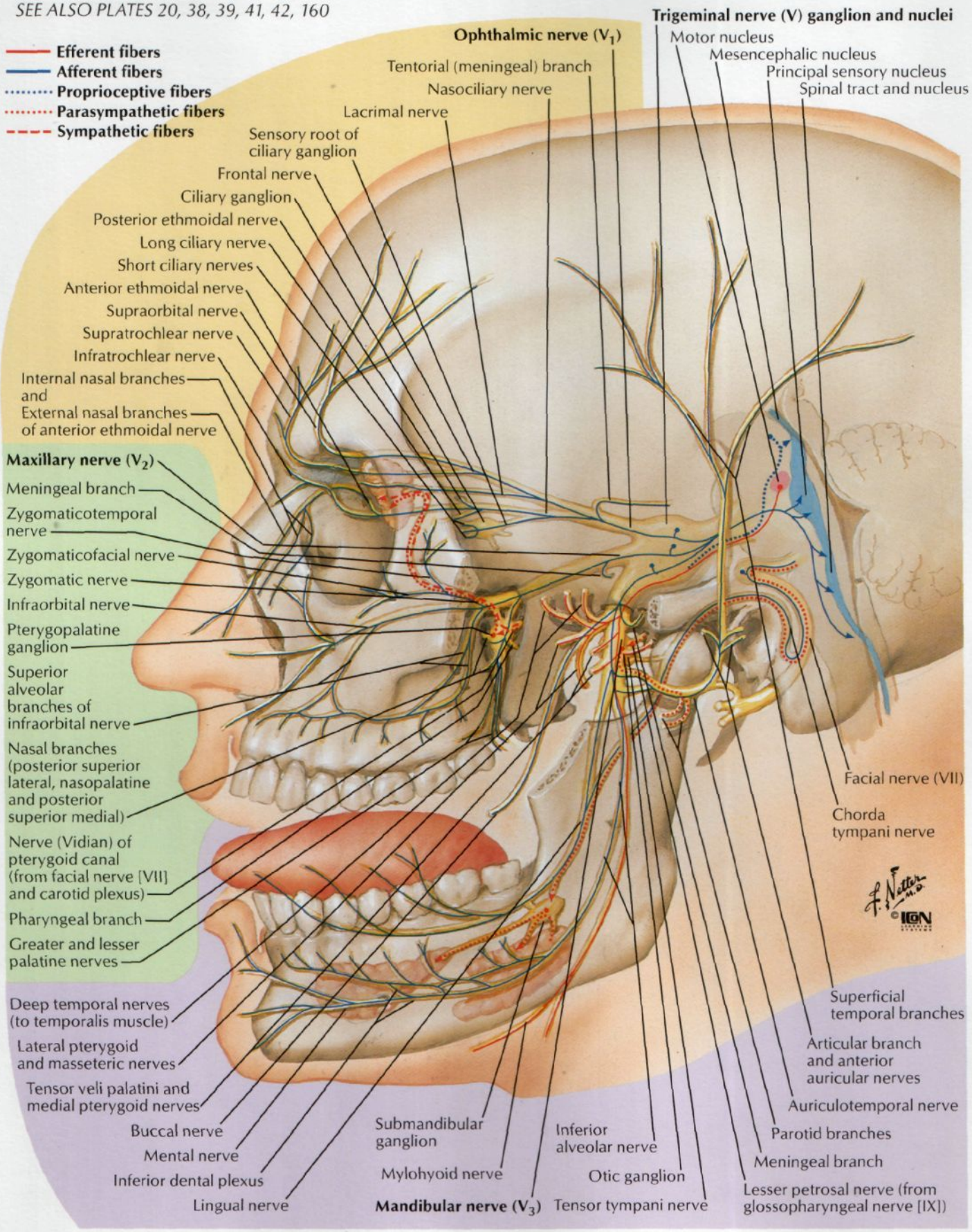

SEE ALSO PLATES 21, 160

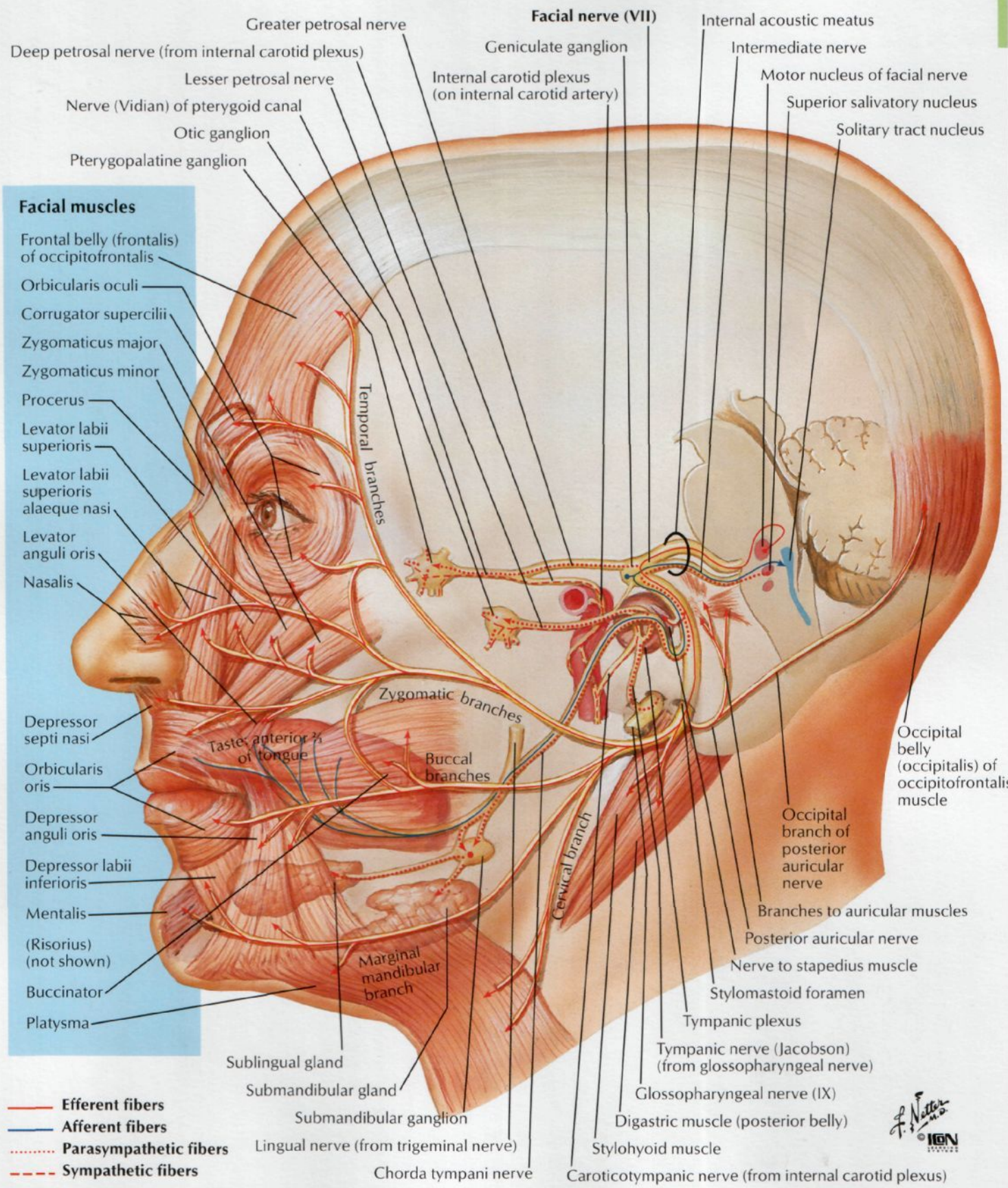

Vestibulocochlear Nerve (VIII): Schema

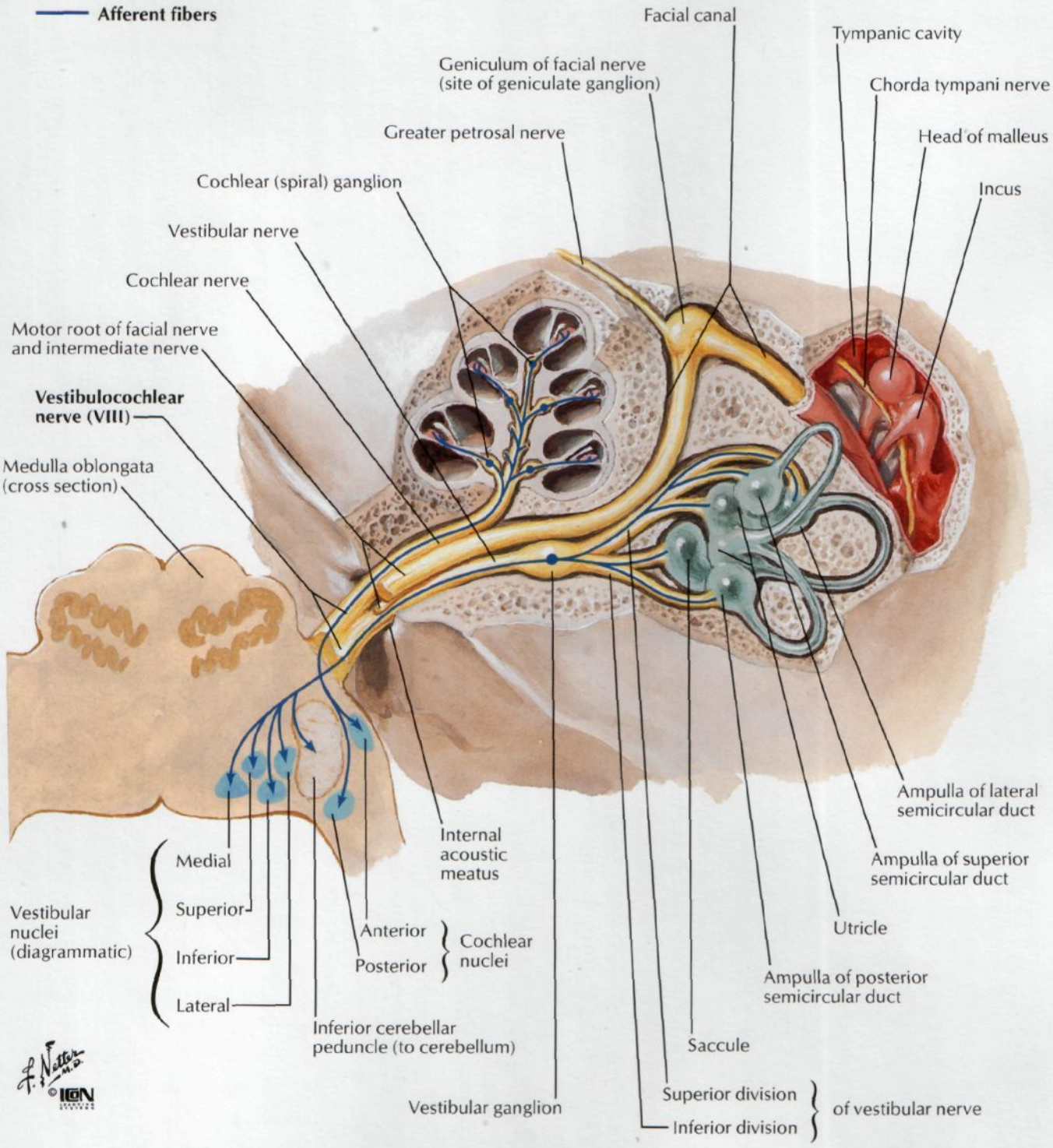

Glossopharyngeal Nerve (IX): Schema

SEE ALSO PLATE 160

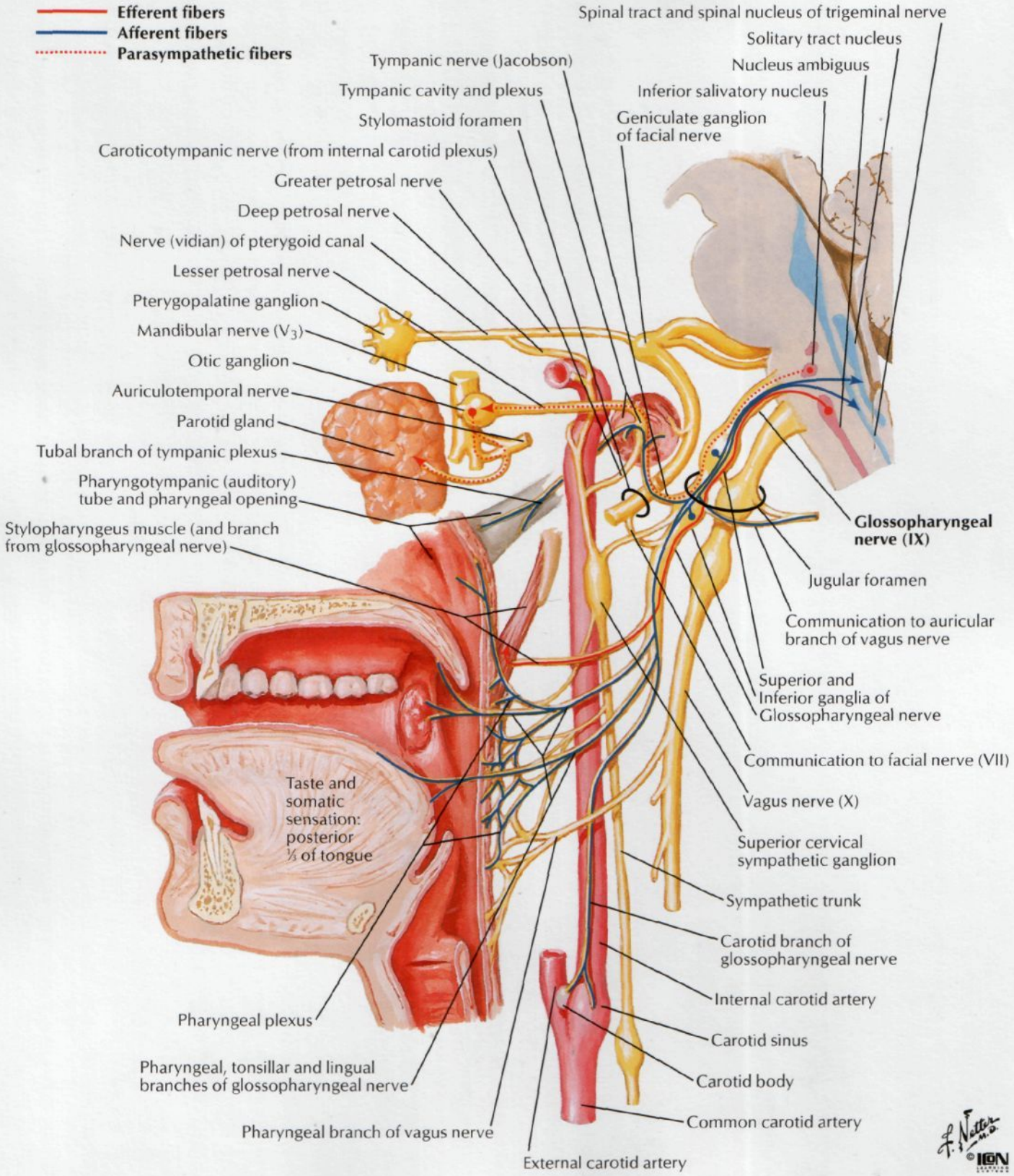

Vagus Nerve (X): Schema

SEE ALSO PLATE 160

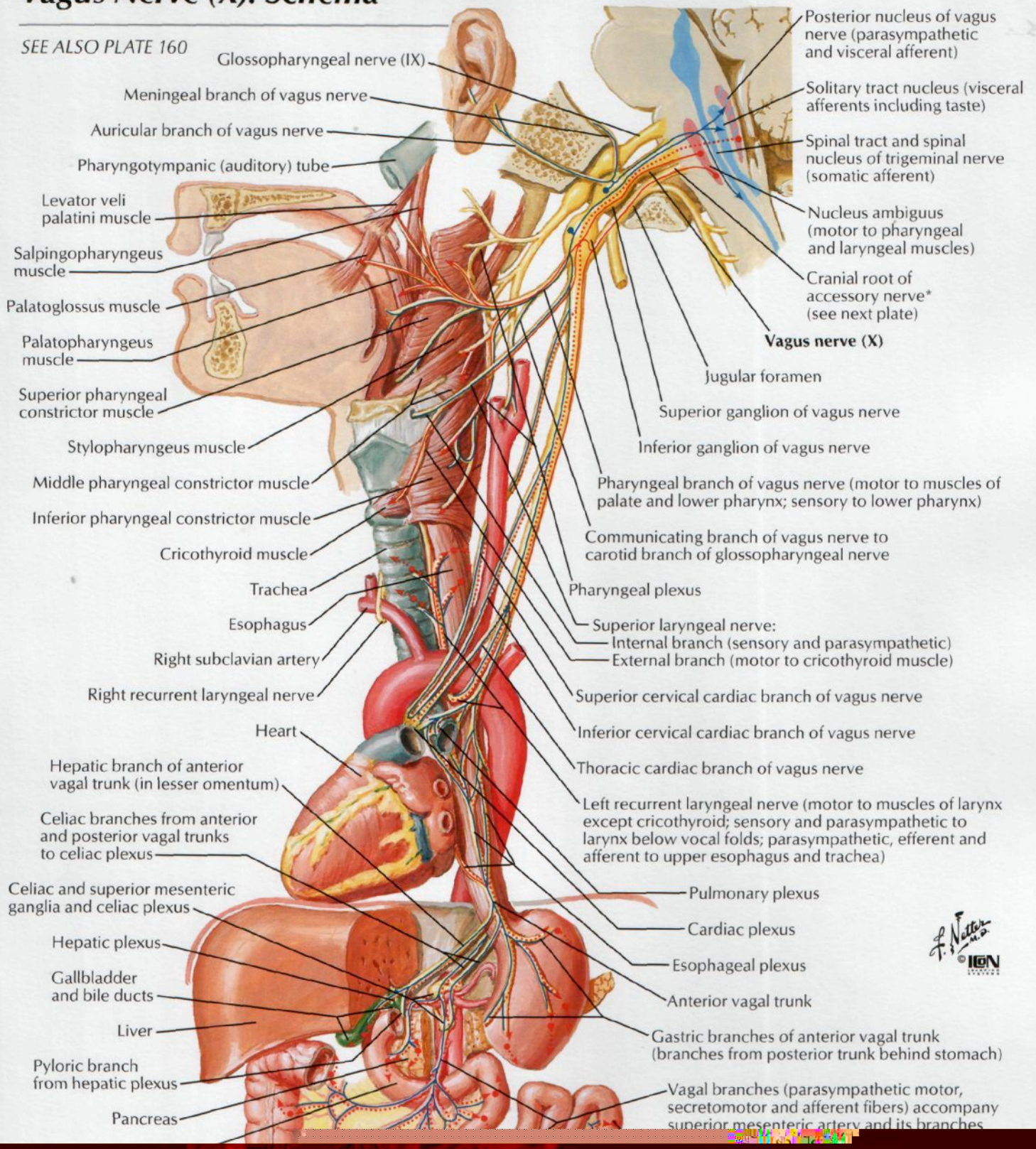

Accessory Nerve (XI): Schema

SEE ALSO PLATE 28

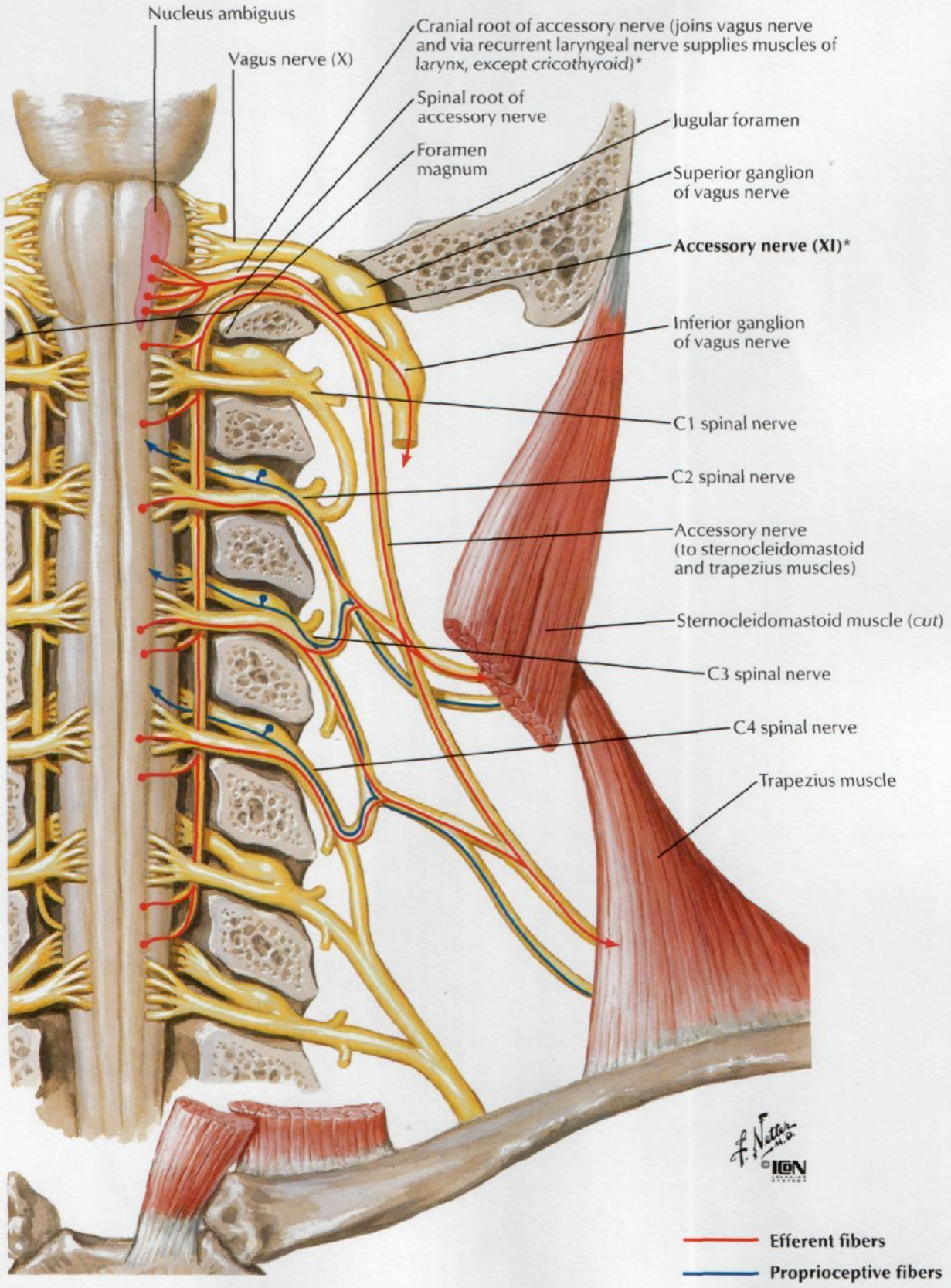

*Recent evidence suggests that the accessory nerve lacks a cranial root and has no connection to the vagus nerve. Verification of this finding awaits further investigation.

Hypoglossal Nerve (XII): Schema

SEE ALSO PLATE 28

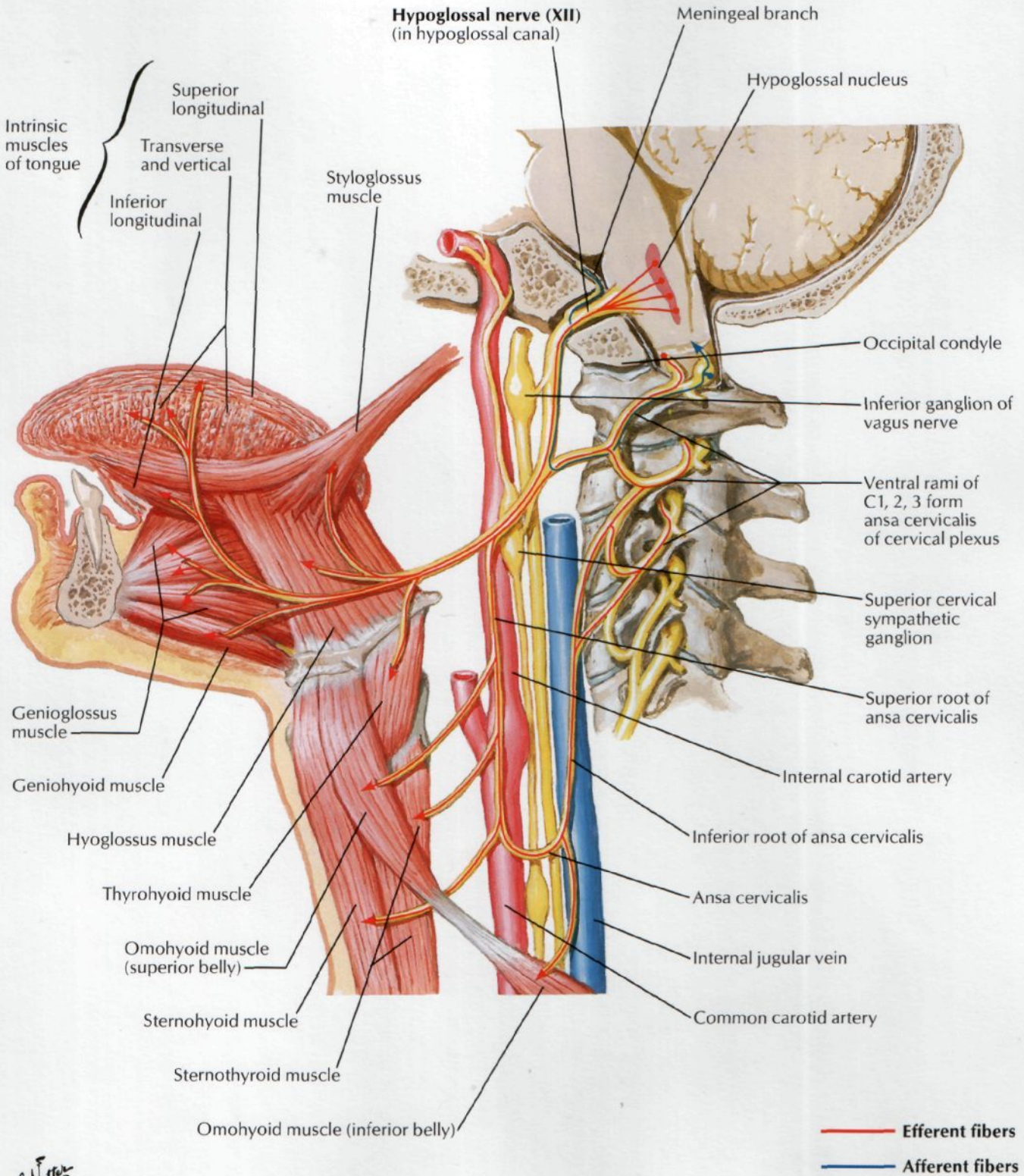

F. Netter M.D.
©IGN

Cervical Plexus: Schema

SEE ALSO PLATE 28

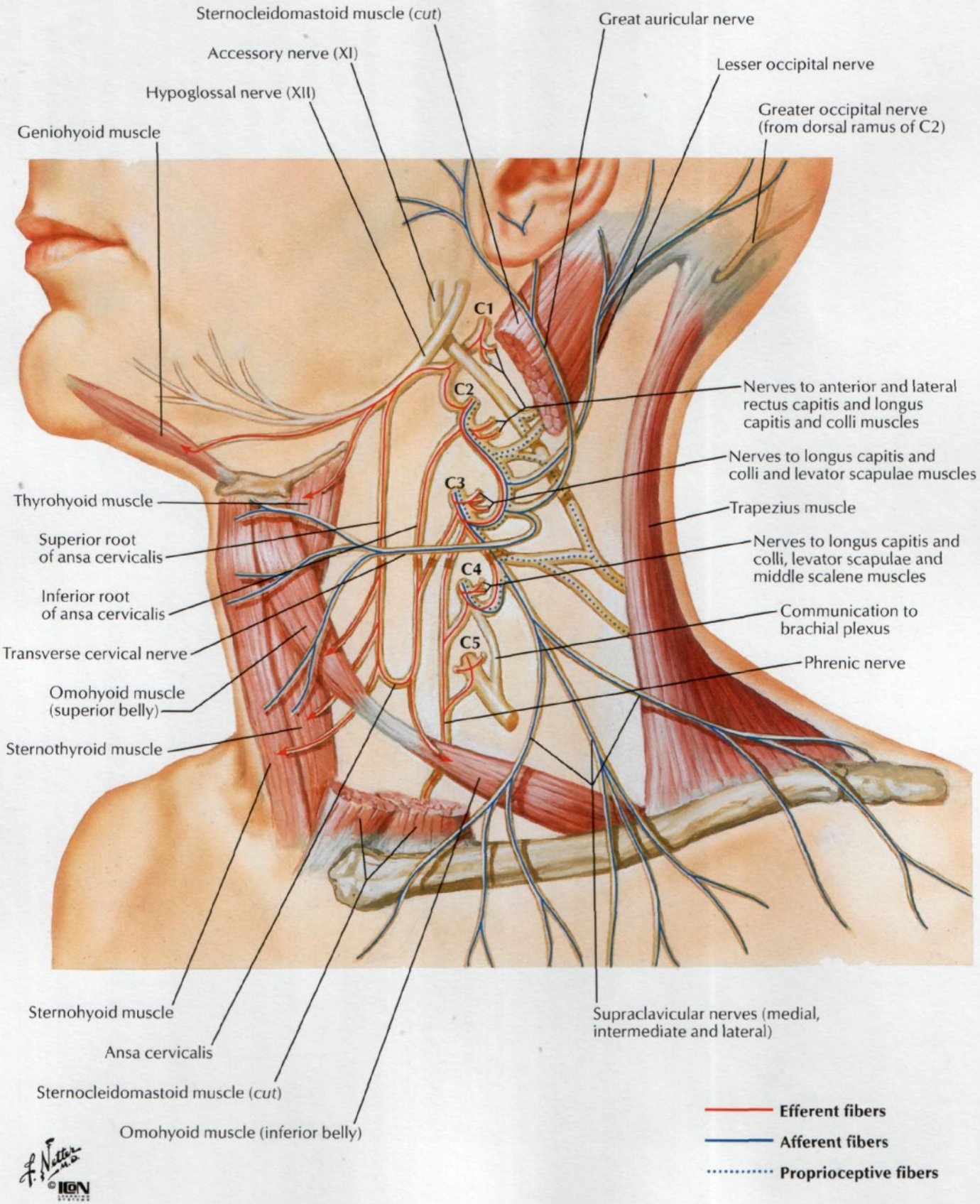

F. Netter M.D.
©IGN

Autonomic Nerves in Neck

SEE ALSO PLATES 67, 119, 120, 159, 205, 222, 236, 308

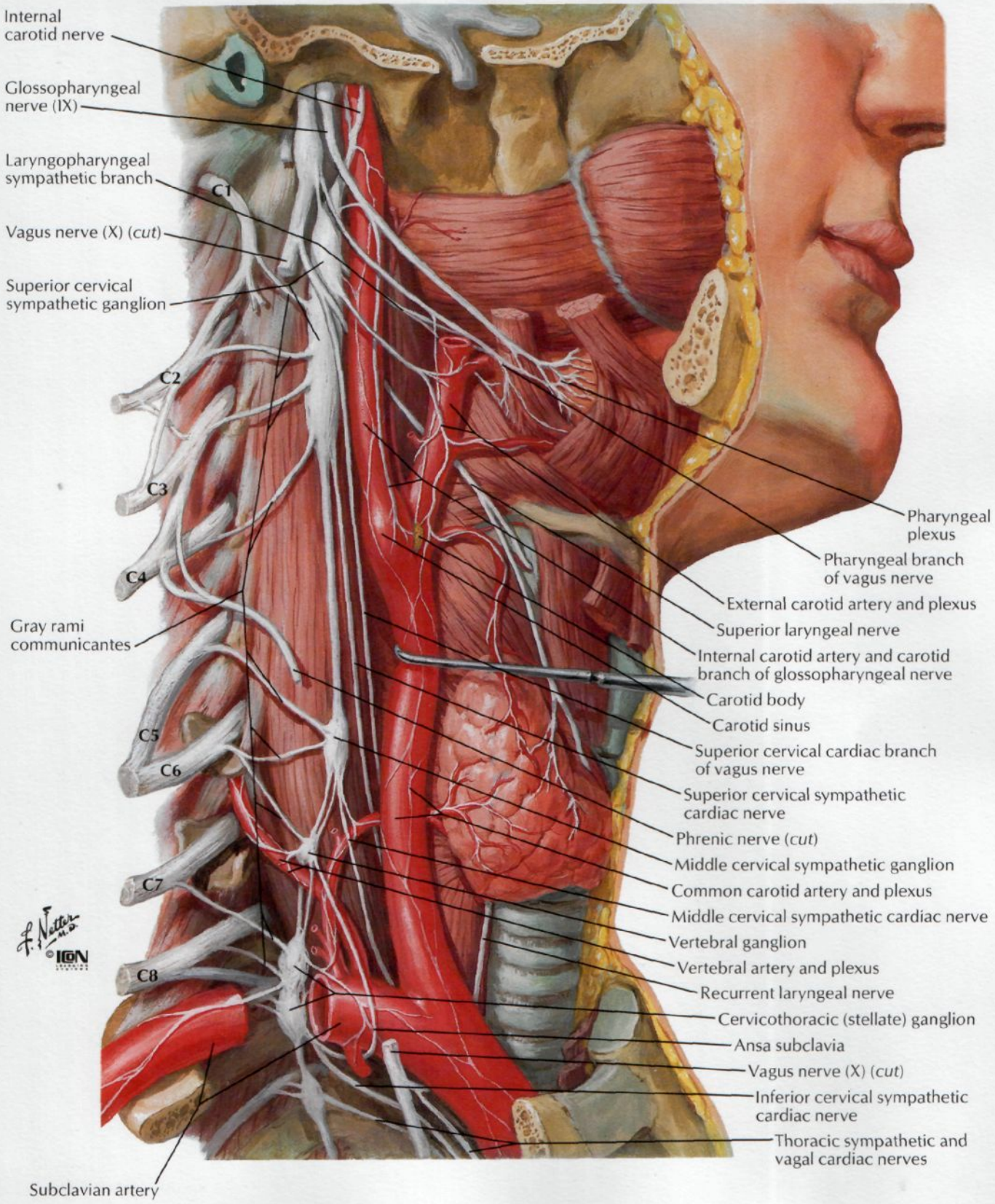

SEE ALSO PLATES 40–42, 82, 115, 126–128, 159

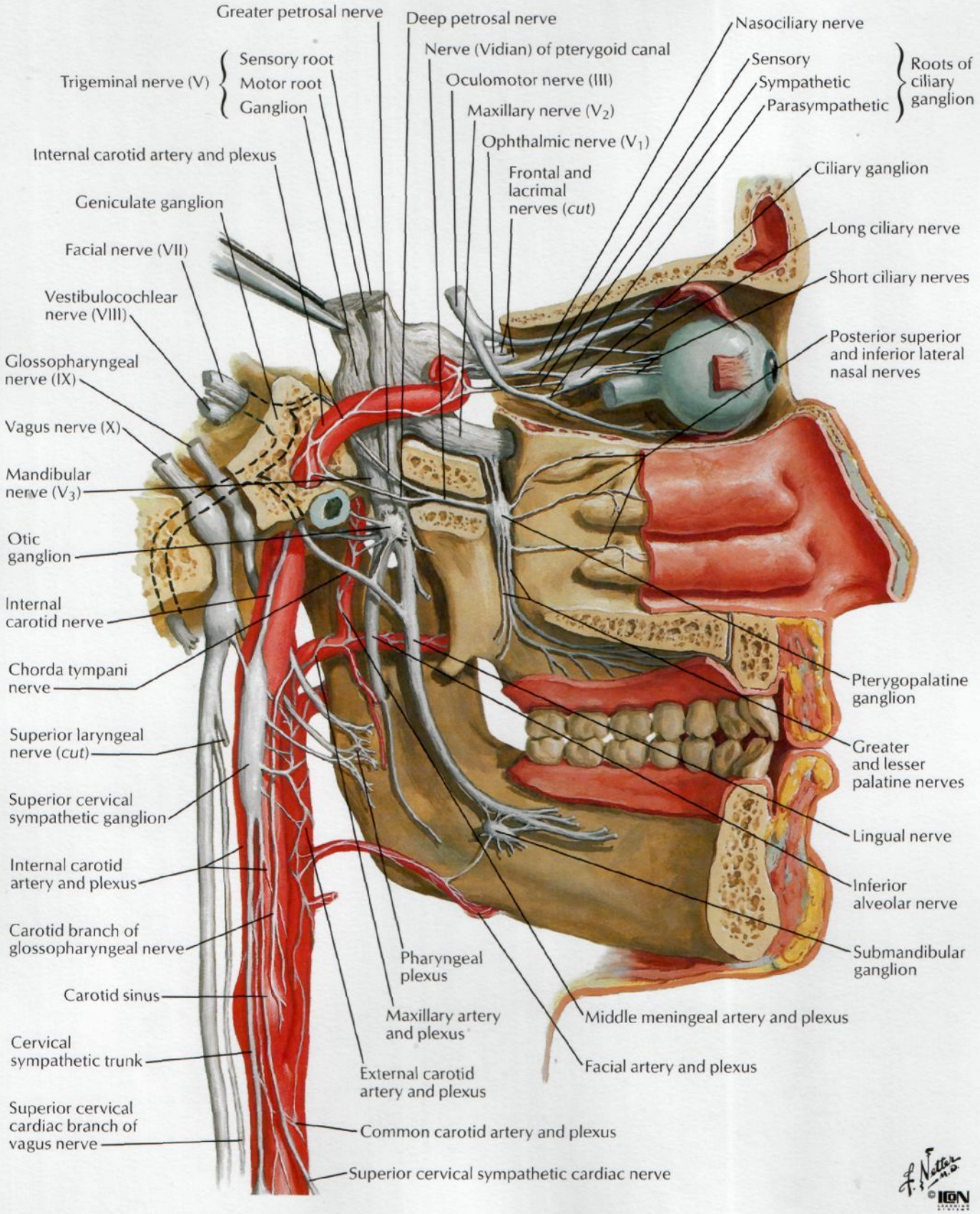

Ciliary Ganglion: Schema

SEE ALSO PLATE 160

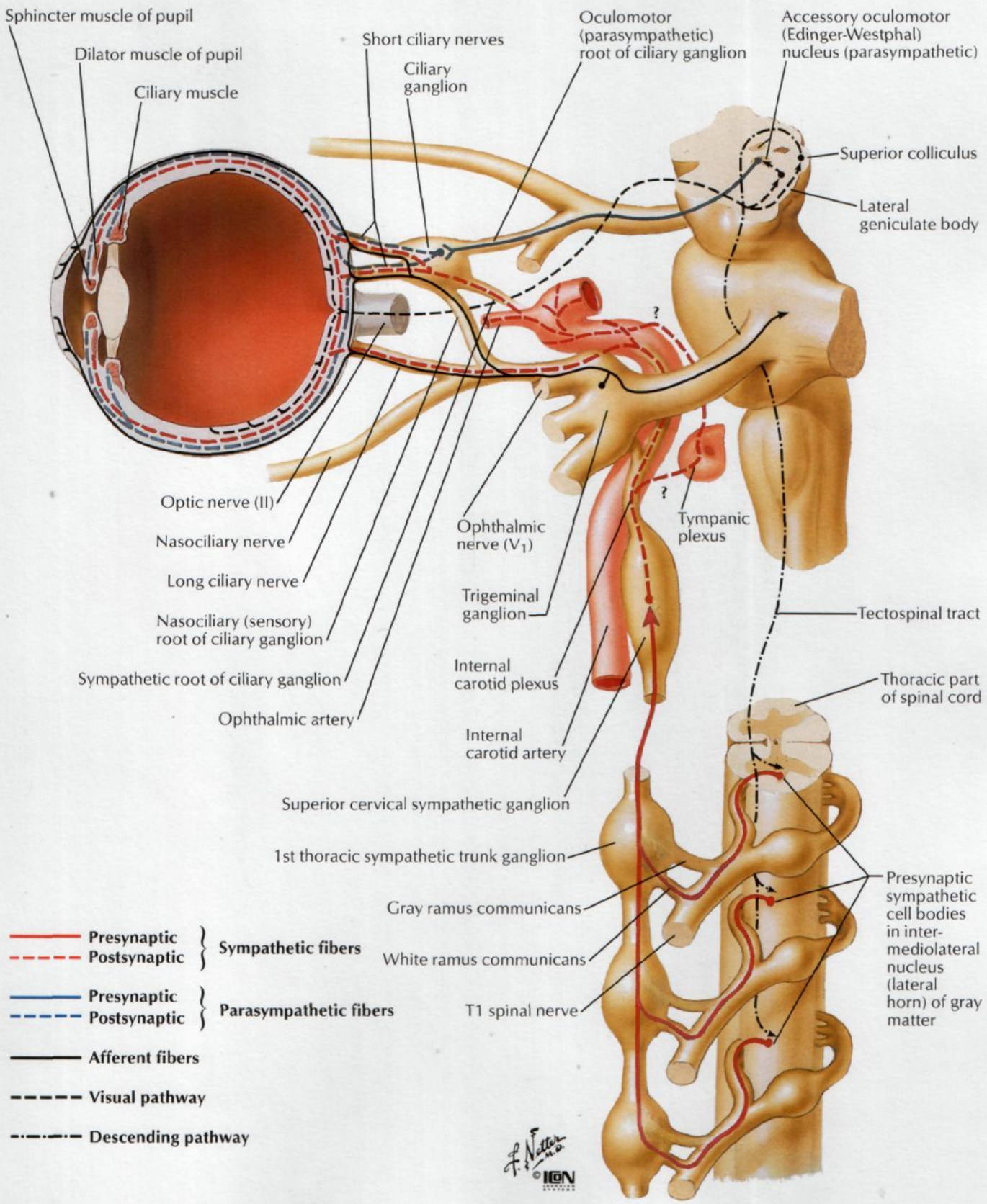

Pterygopalatine and Submandibular Ganglia: Schema

SEE ALSO PLATE 160

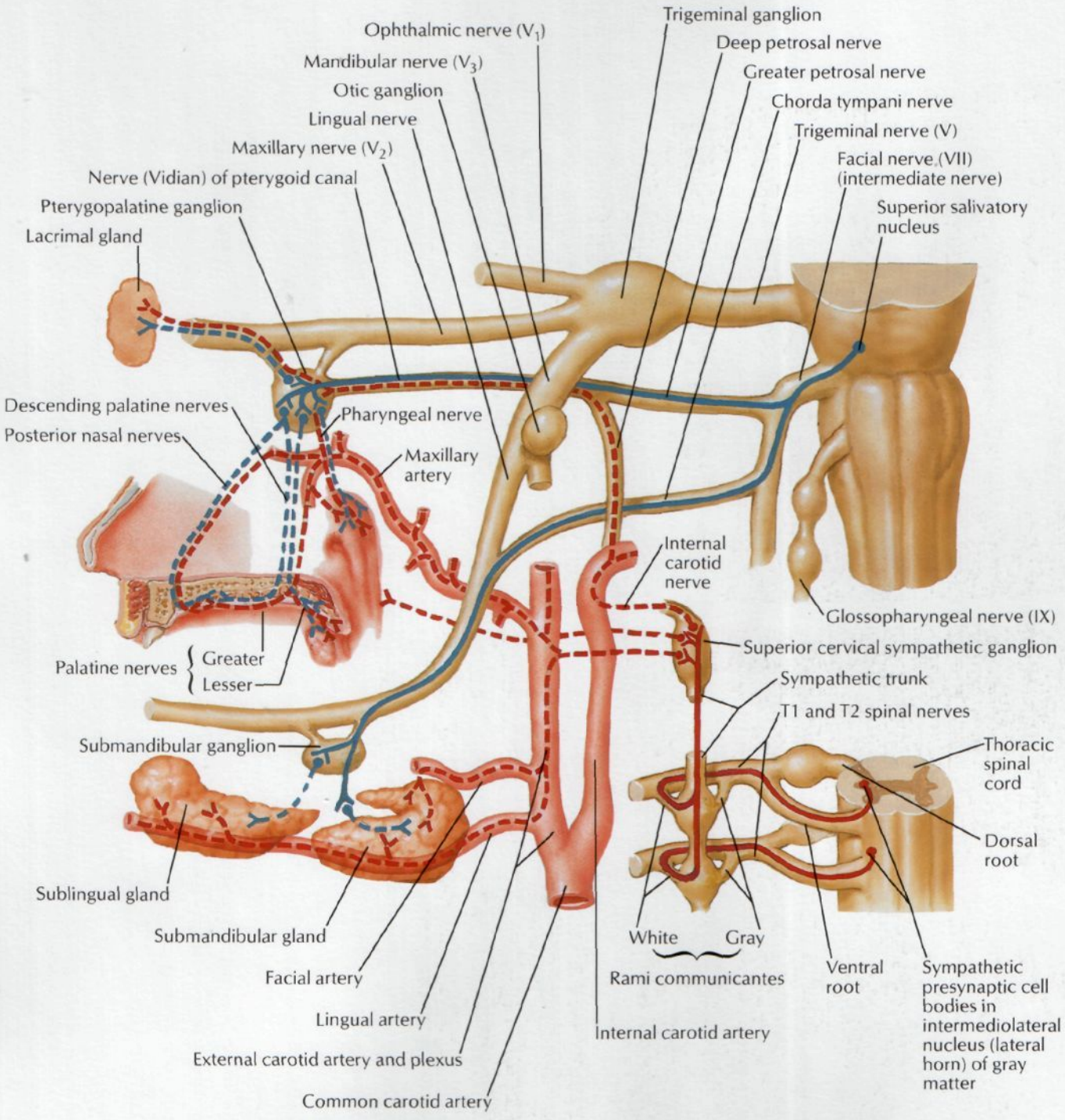

F. Netter M.D.
©IGN

Sympathetic presynaptic fibers
Sympathetic postsynaptic fibers
Parasympathetic presynaptic fibers
Parasympathetic postsynaptic fibers

Otic Ganglion: Schema

SEE ALSO PLATE 160

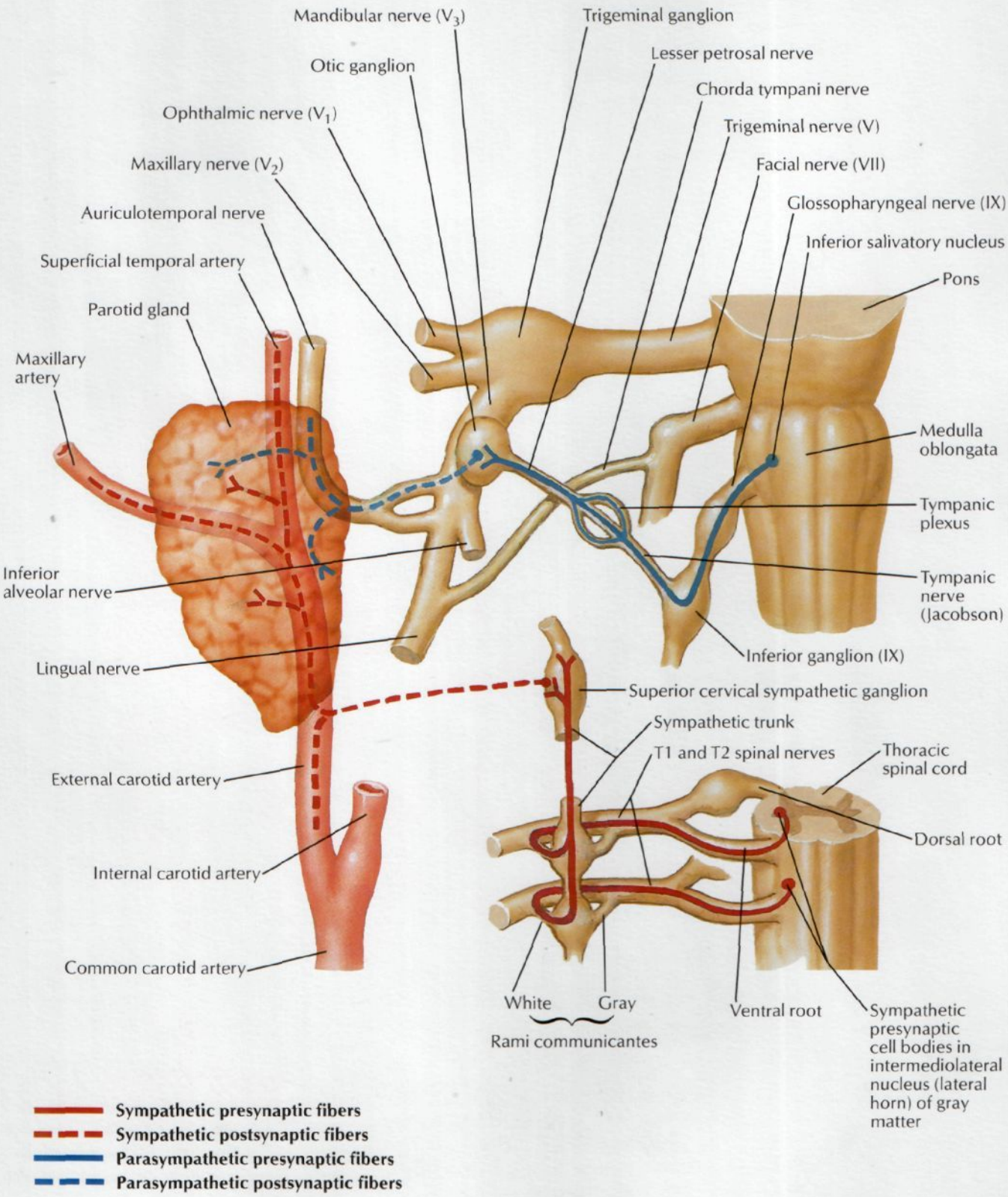

F. Netter M.D.
©ICN

Taste Pathways: Schema

SEE ALSO PLATES 42, 89, 117, 119, 120

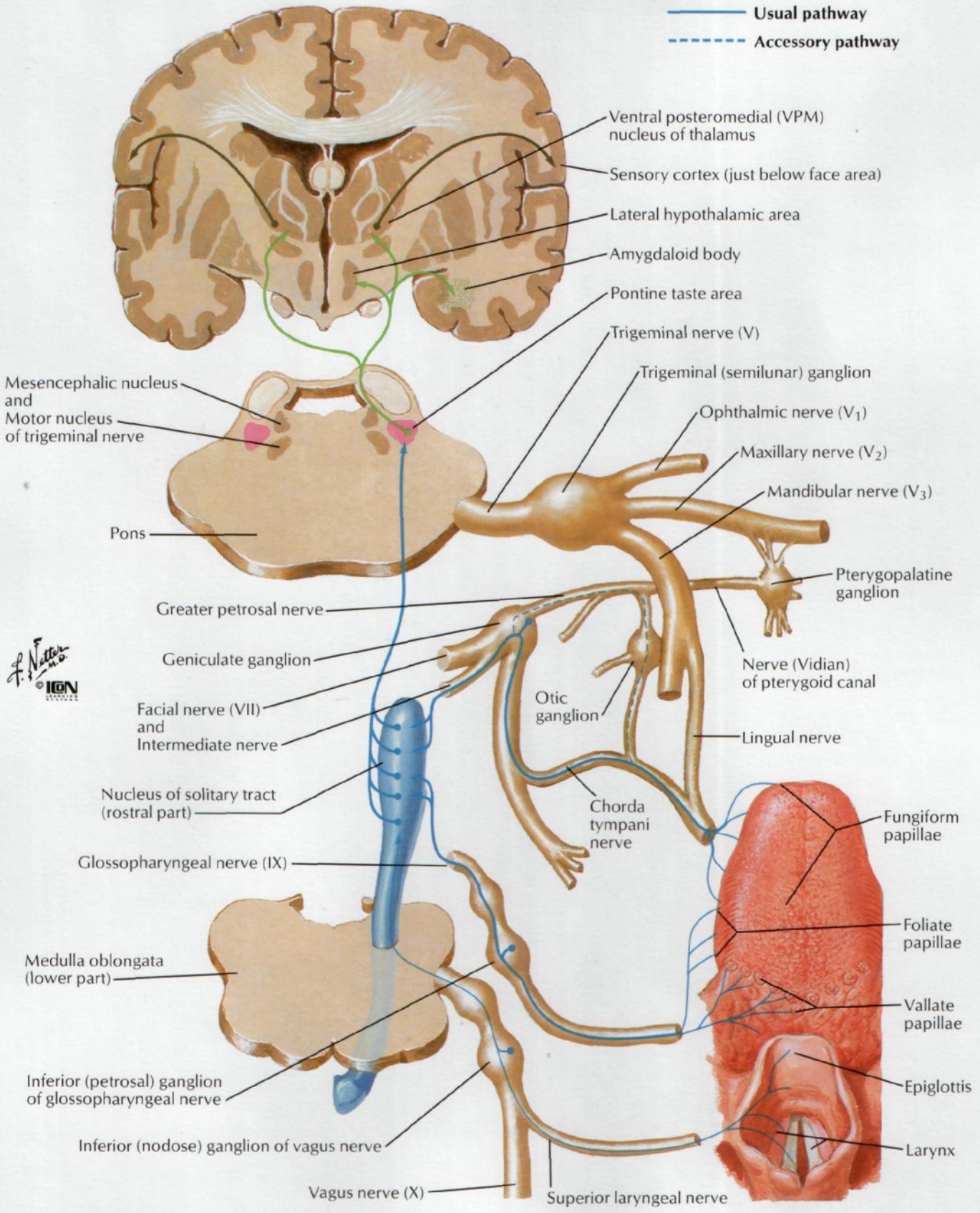

Arteries to Brain and Meninges

SEE ALSO PLATES 29, 30

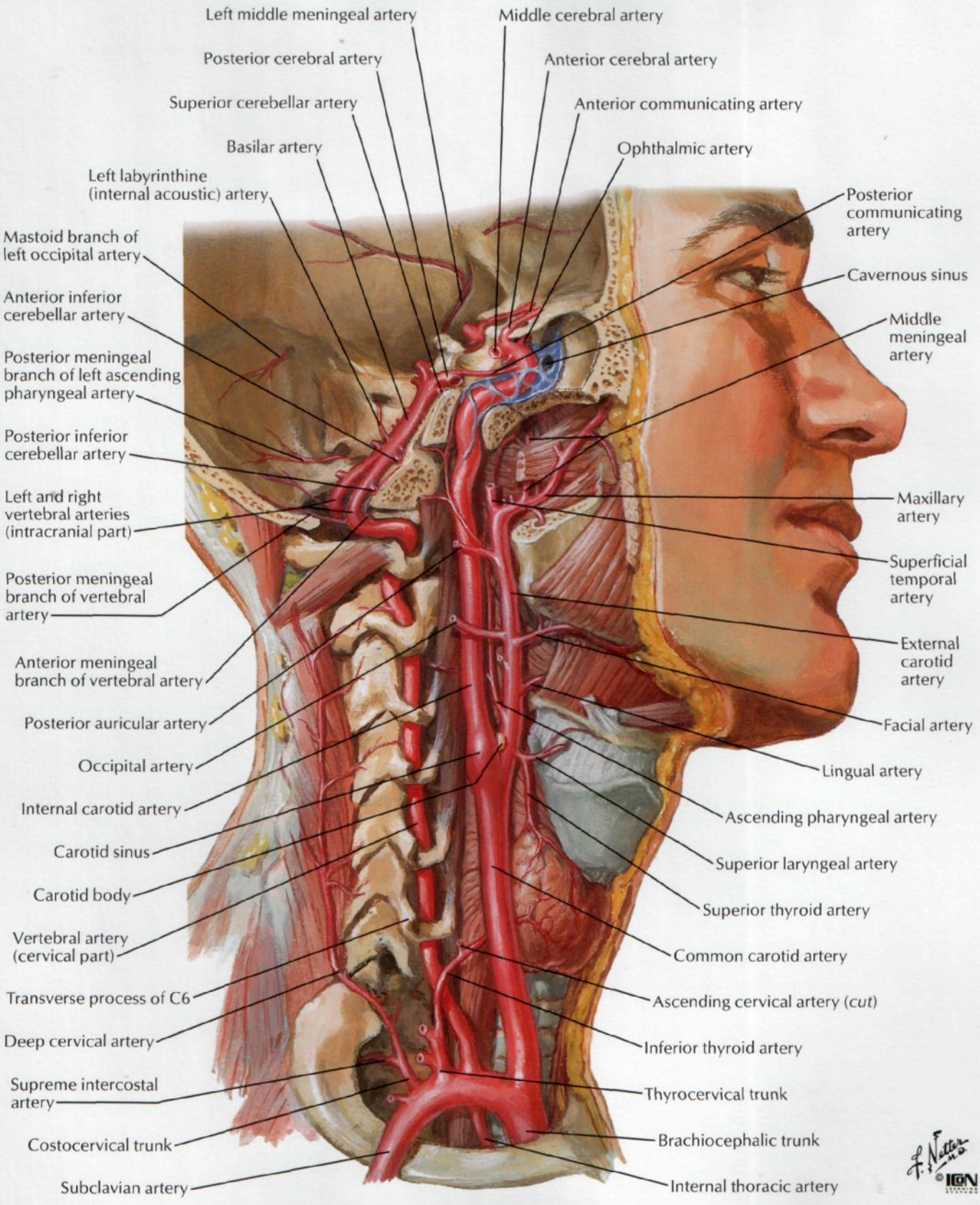

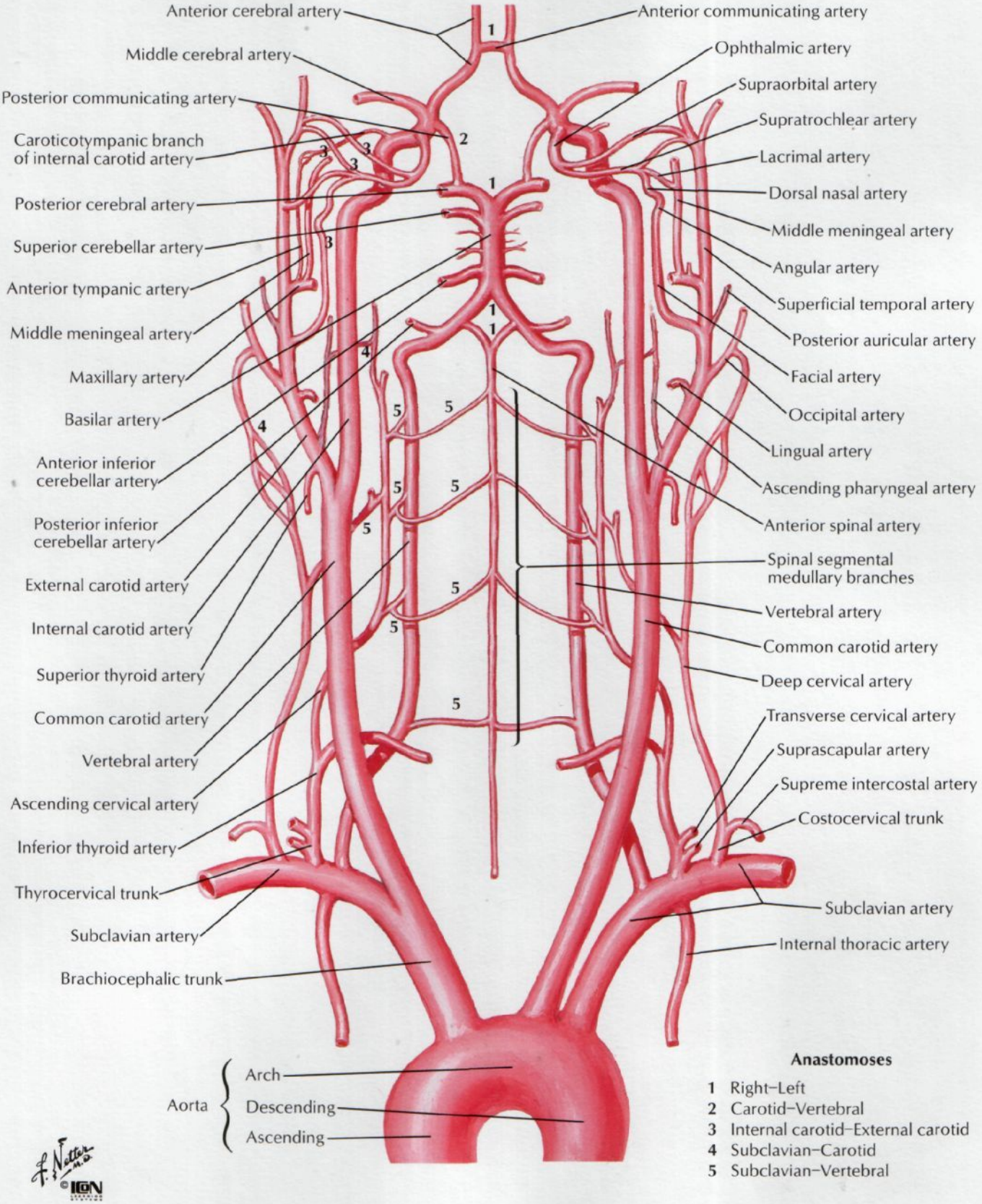

F. Netter M.D.
©IGN

Arteries of Brain: Inferior Views

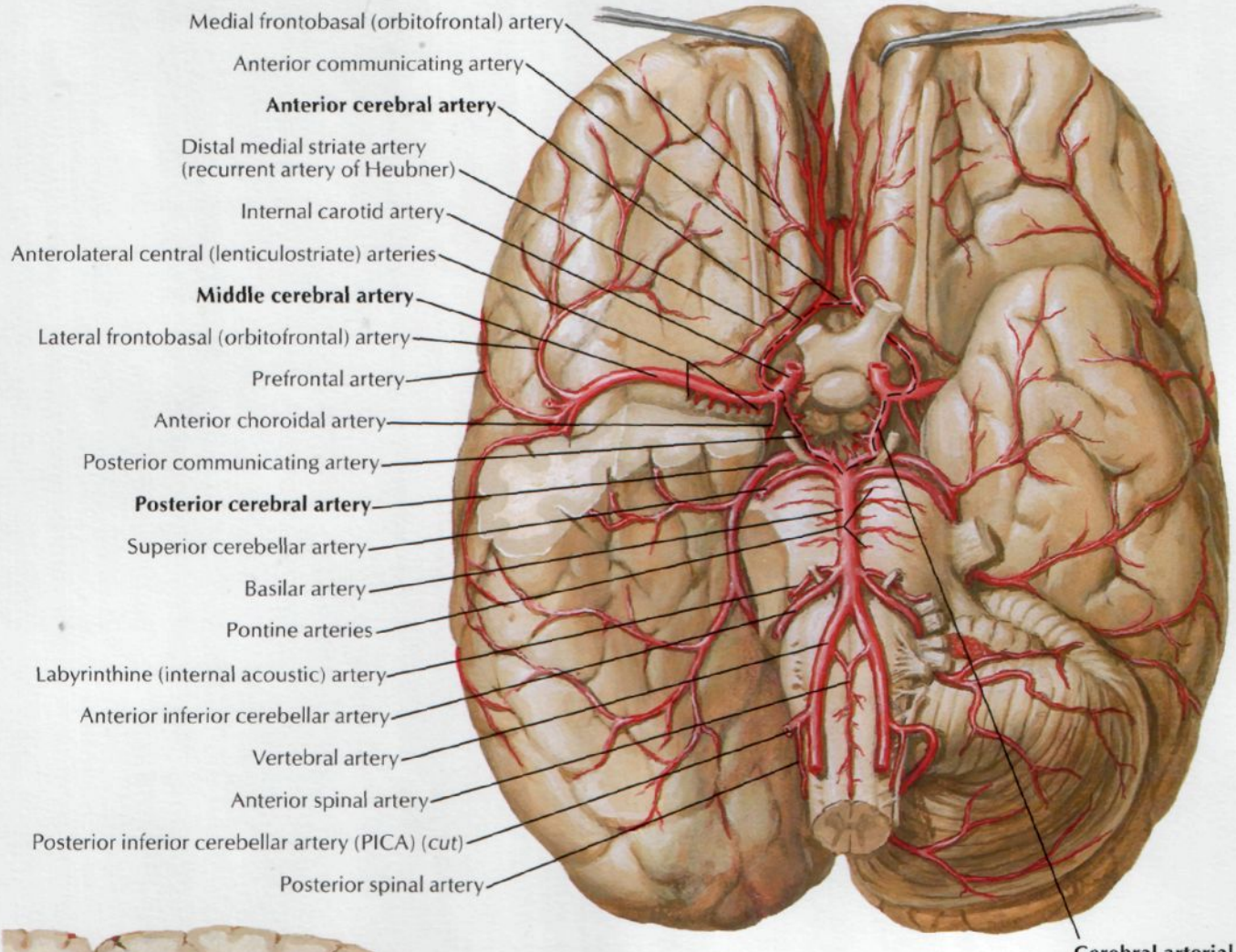

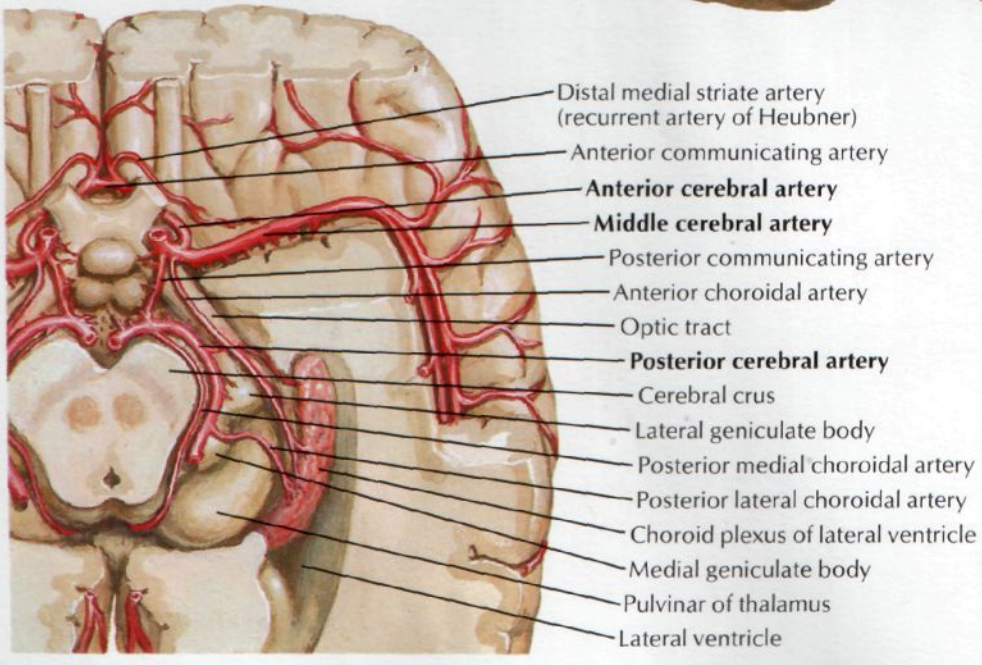

Cerebral Arterial Circle (Willis)

FOR HYPOPHYSEAL ARTERIES SEE PLATE 141

Vessels dissected out: inferior view

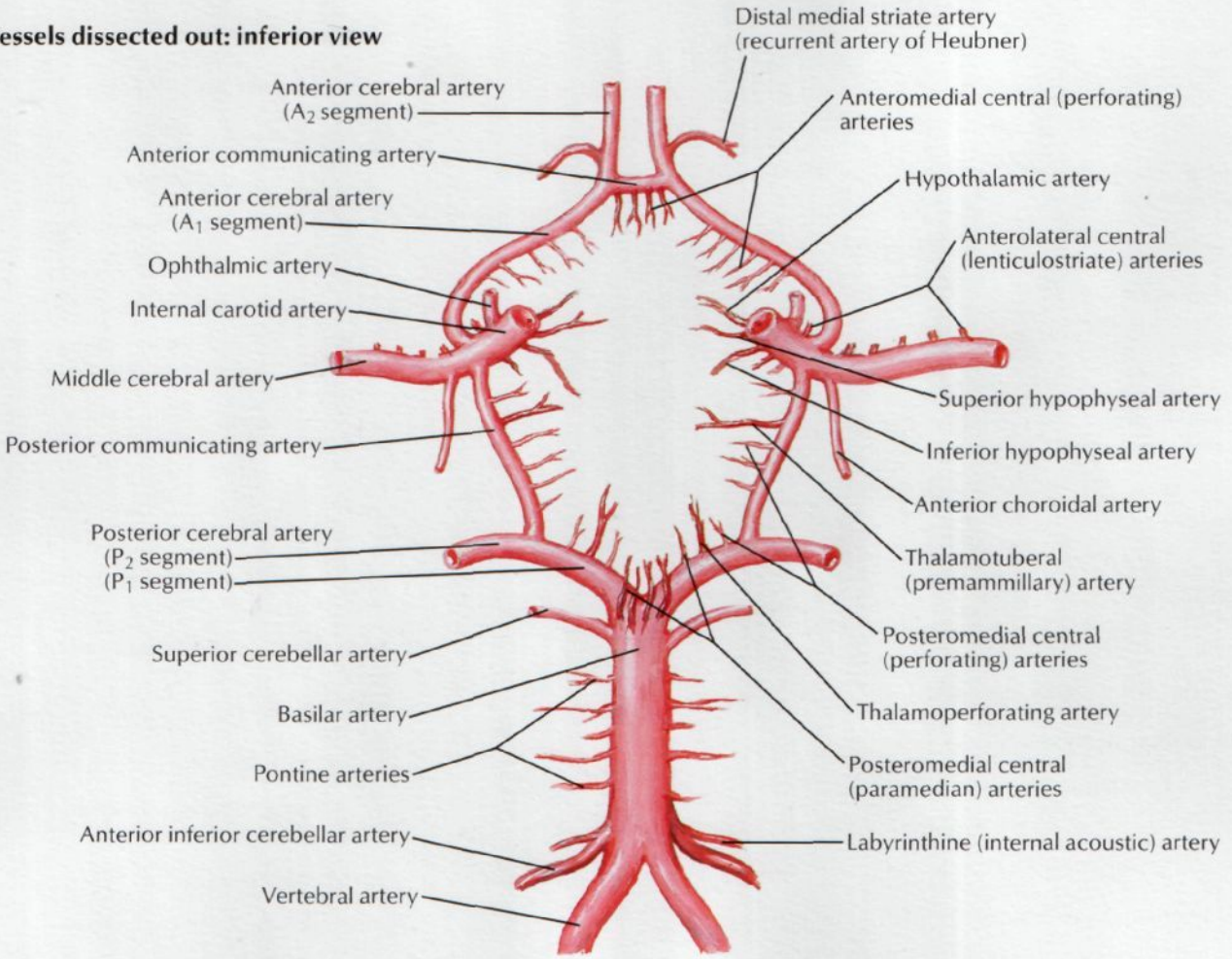

Vessels in situ: inferior view

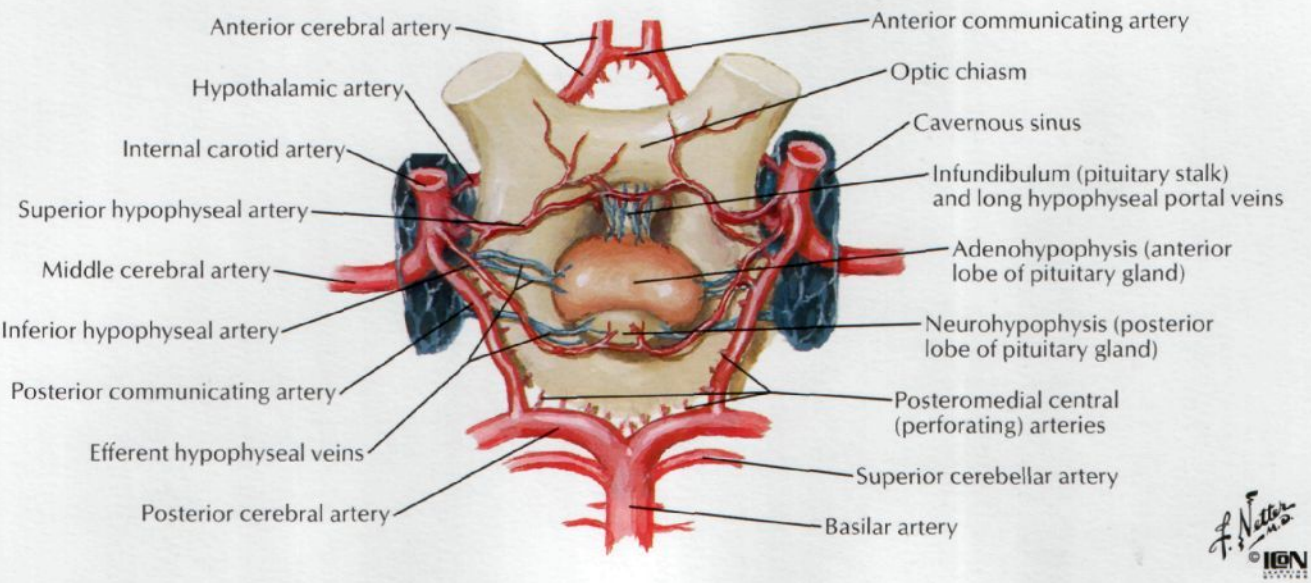

F. Netter M.D.
©IGN

Arteries of Brain: Frontal View and Section

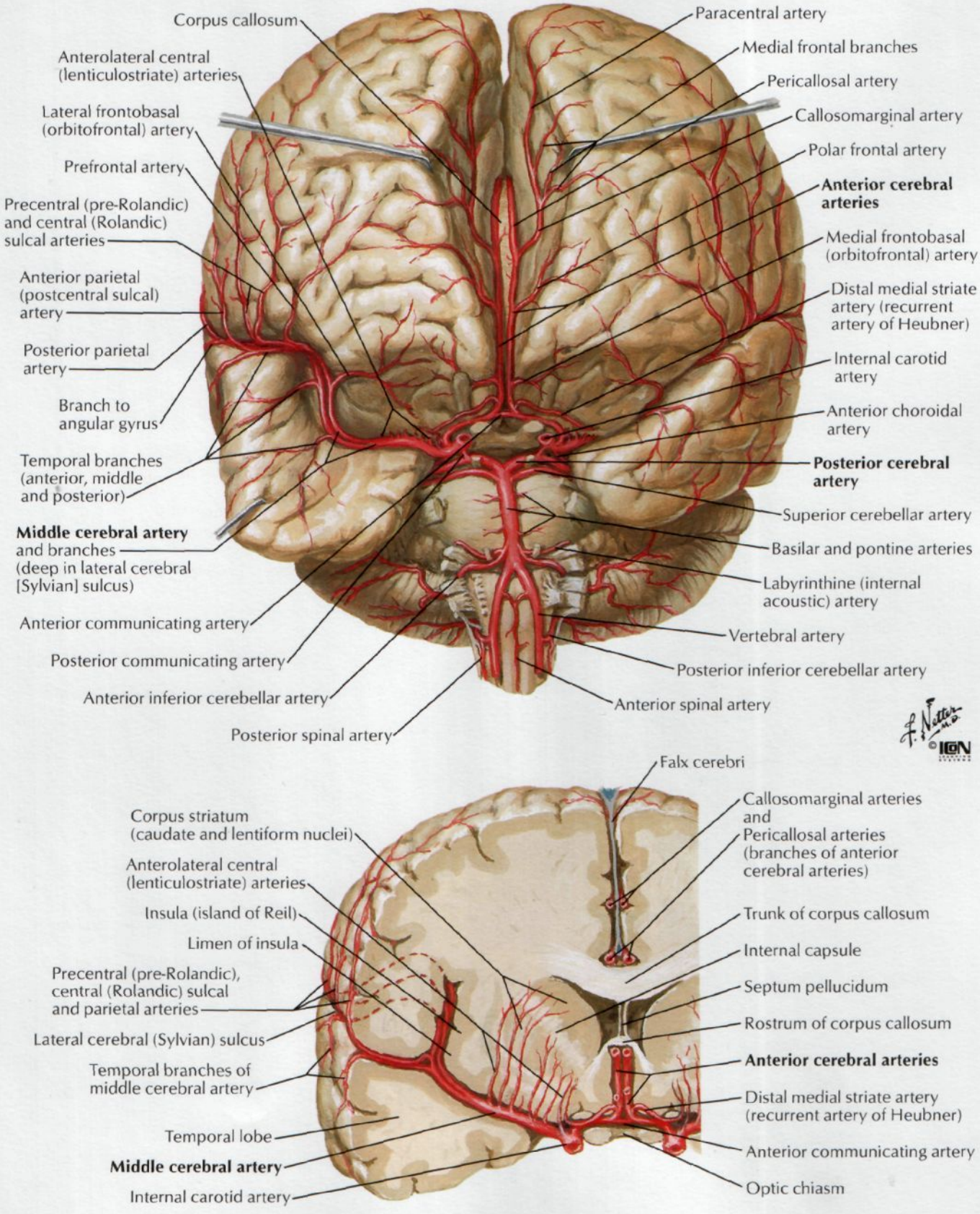

Arteries of Brain: Lateral and Medial Views

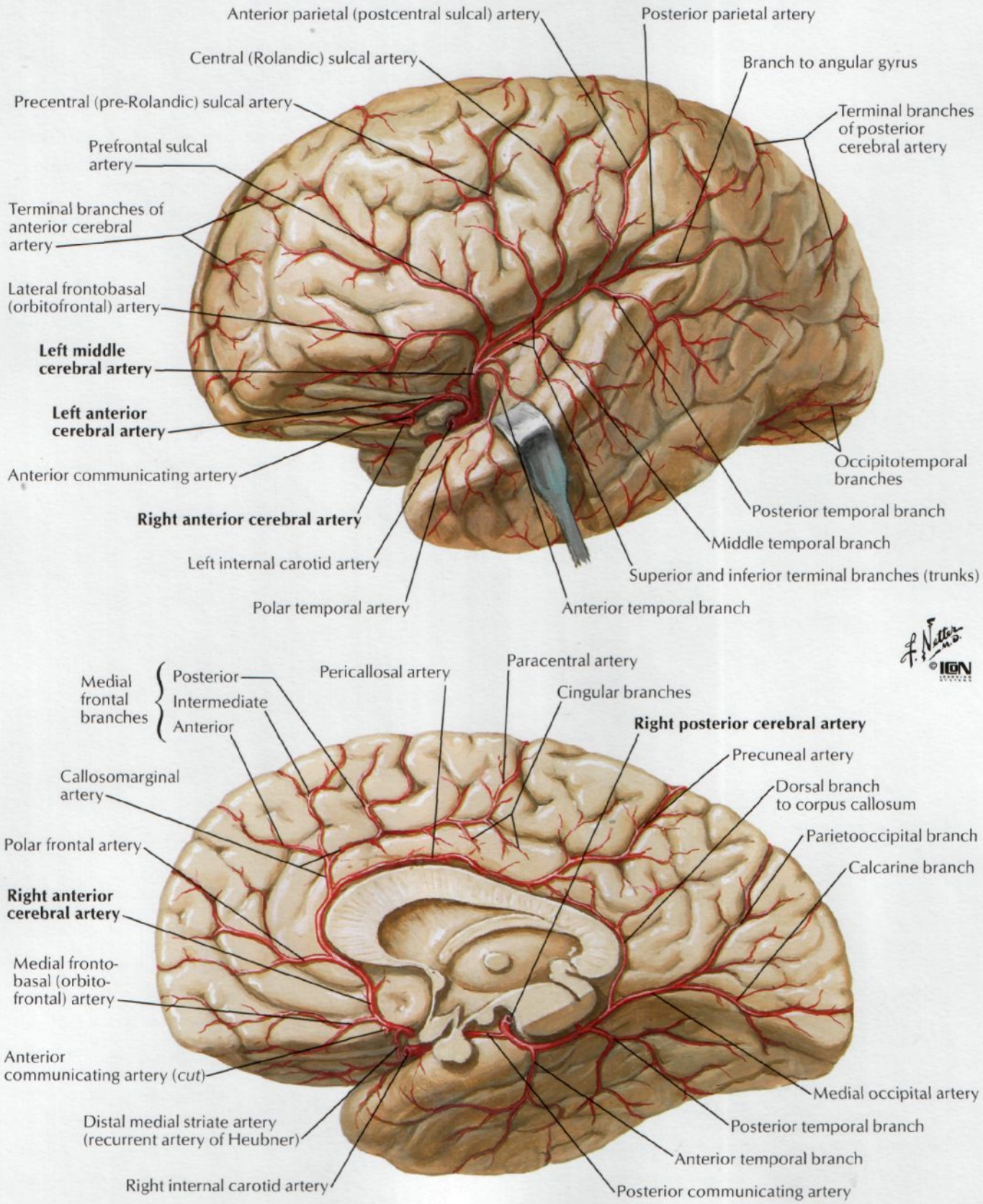

Note: Anterior parietal (postcentral sulcal) artery also occurs as separate anterior parietal and postcentral sulcal arteries

Arteries of Posterior Cranial Fossa

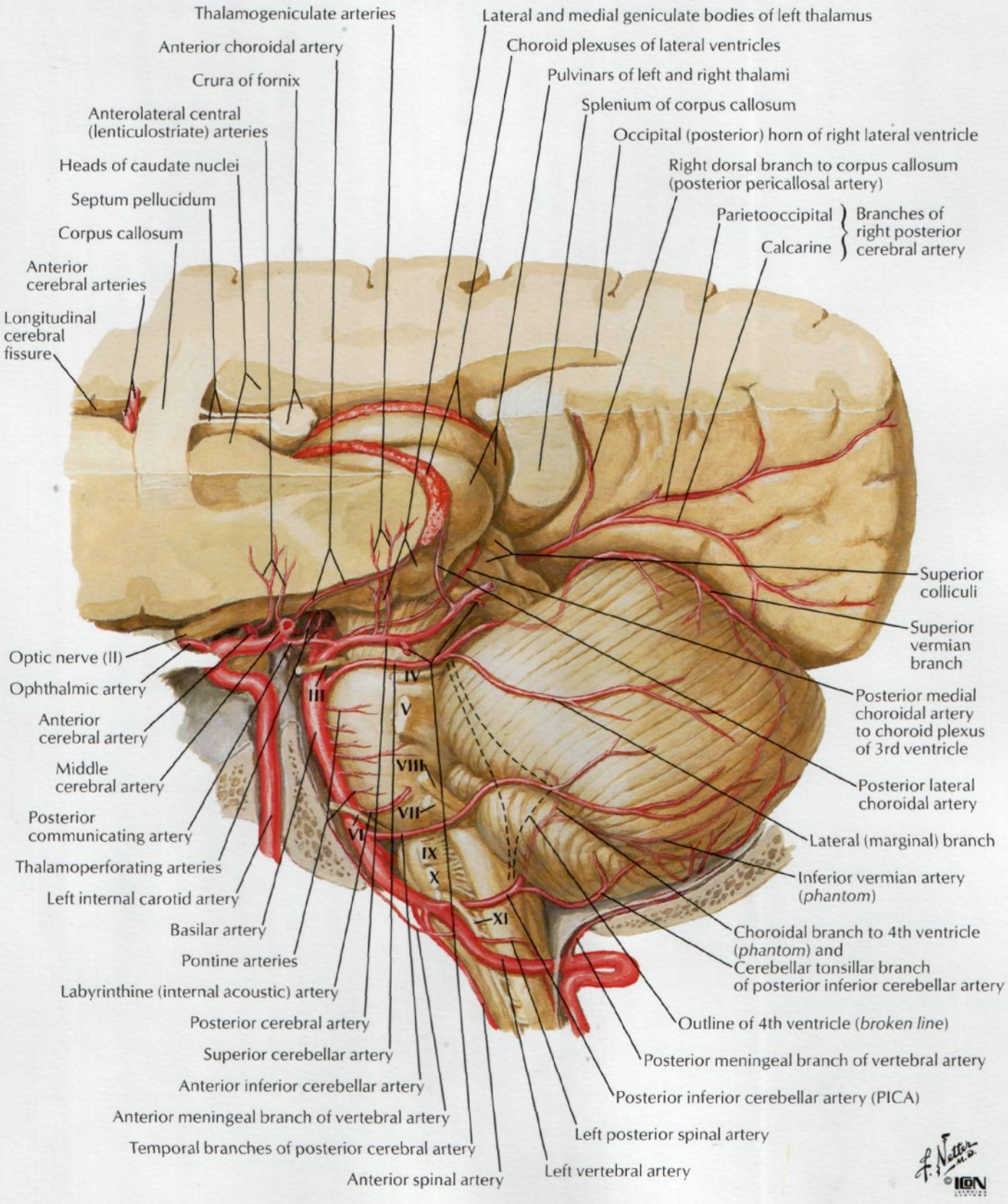

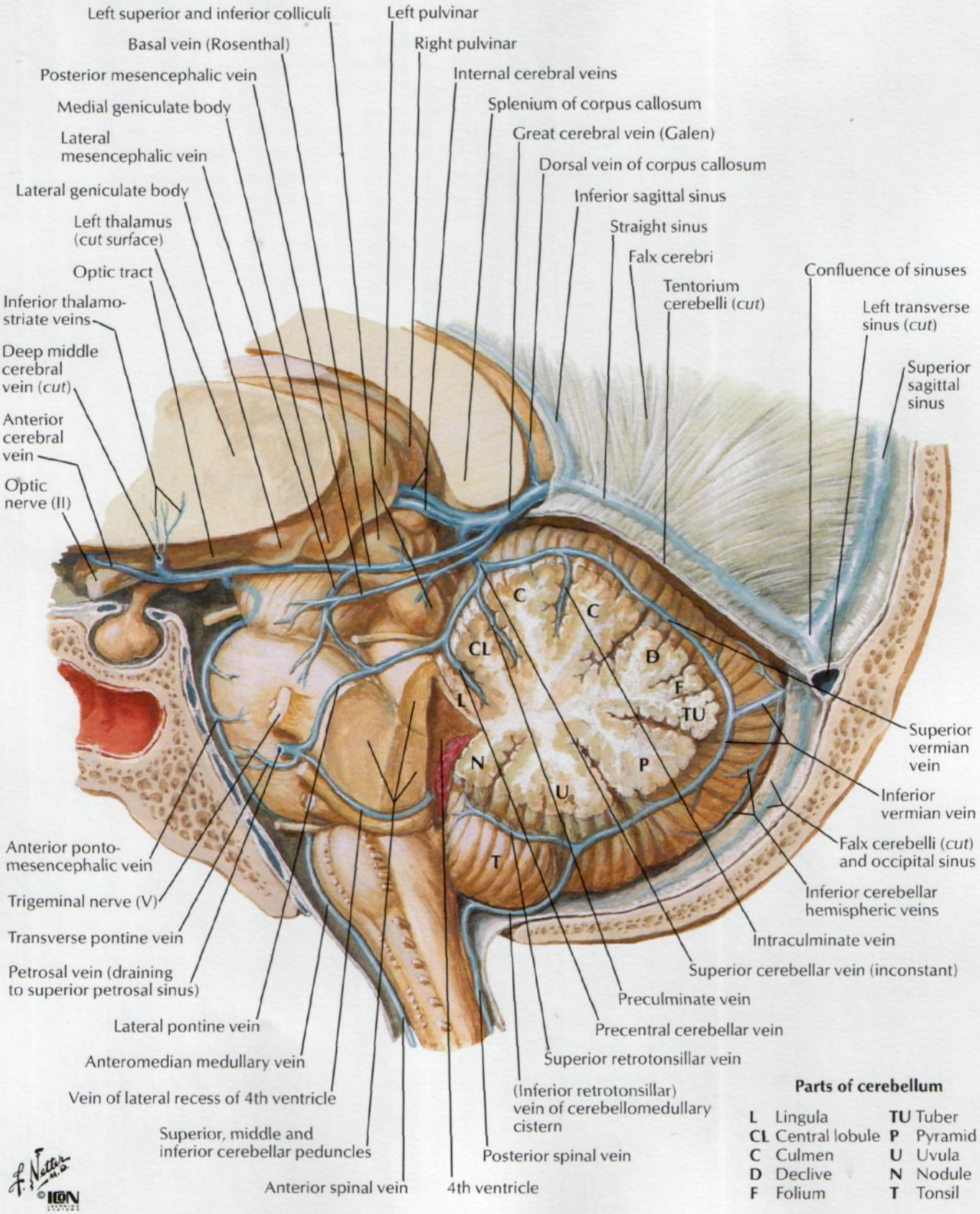

Parts of cerebellum

L	Lingula	**TU**	Tuber
CL	Central lobule	**P**	Pyramid
C	Culmen	**U**	Uvula
D	Declive	**N**	Nodule
F	Folium	**T**	Tonsil

F. Netter M.D. ©ICON

Deep Veins of Brain

FOR SUPERFICIAL VEINS OF BRAIN SEE PLATE 96

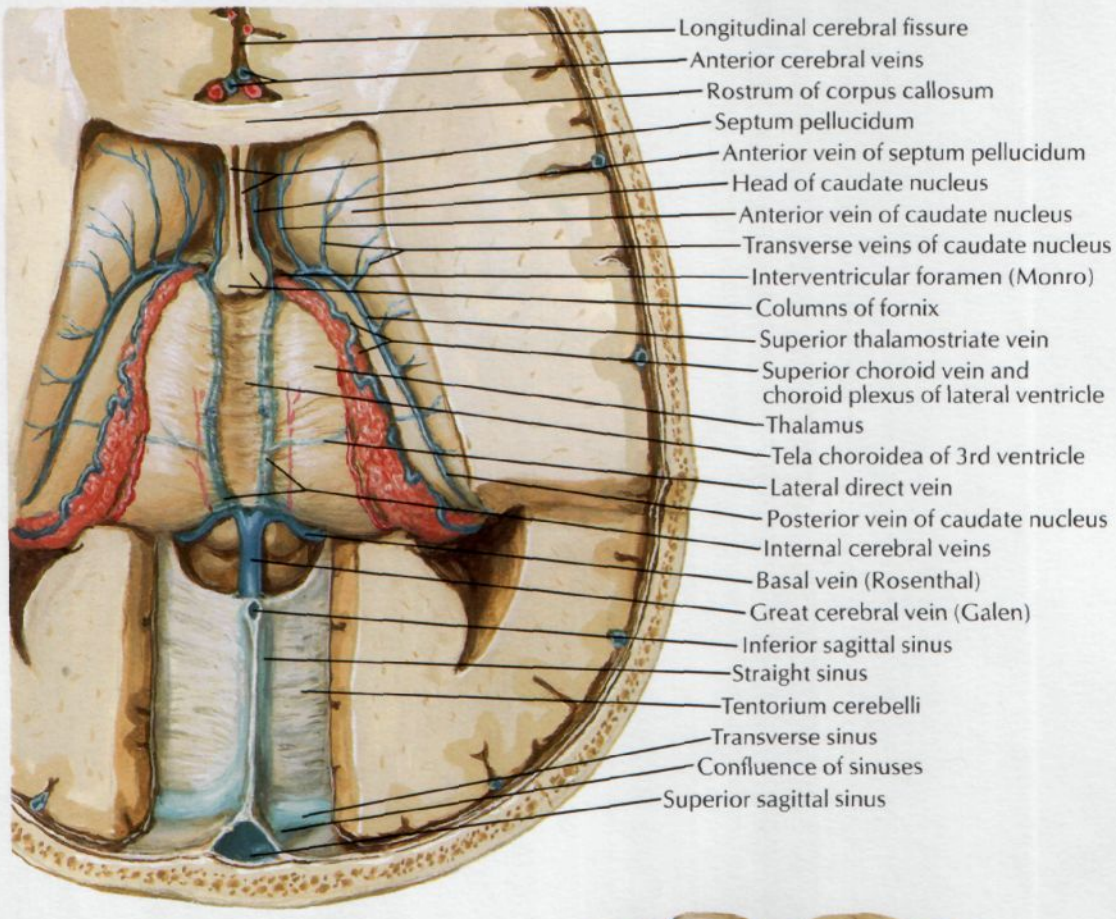

Dissection: superior view

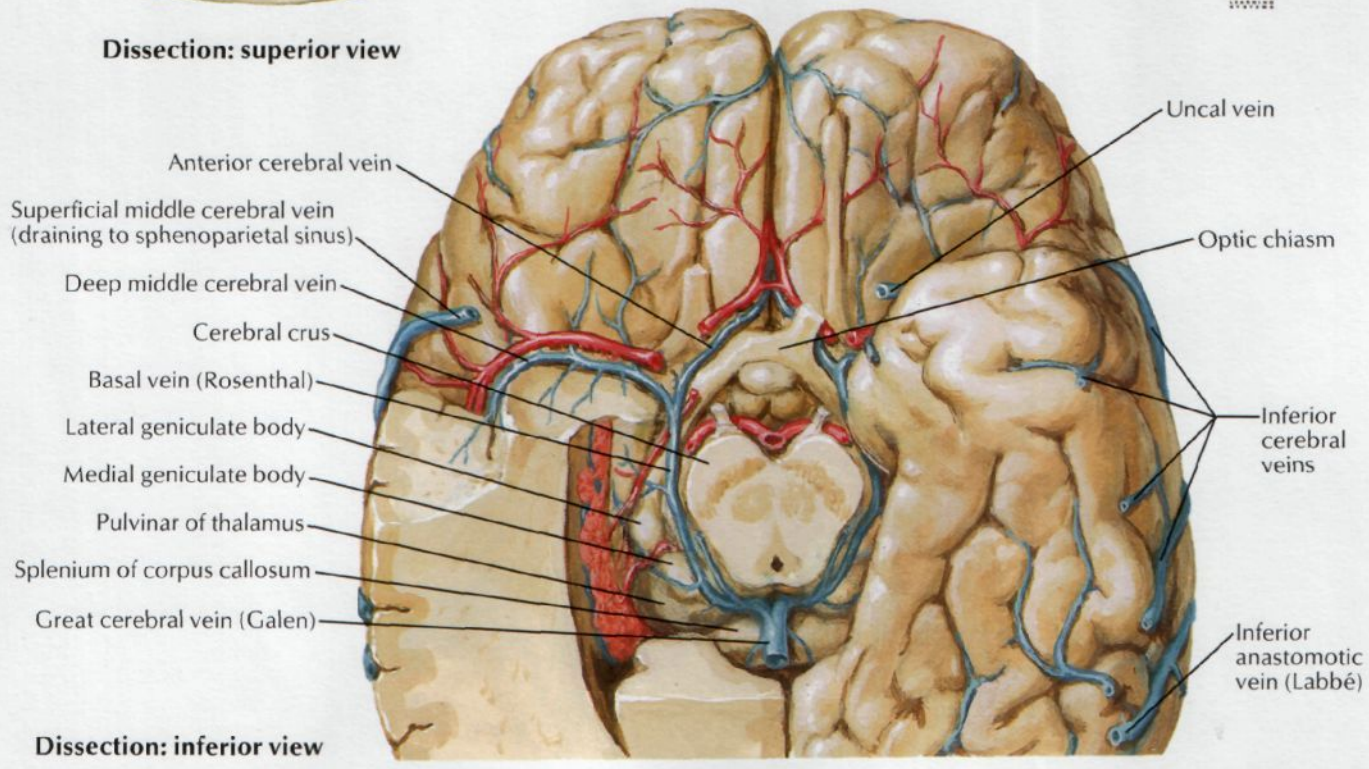

Dissection: inferior view

Subependymal Veins of Brain

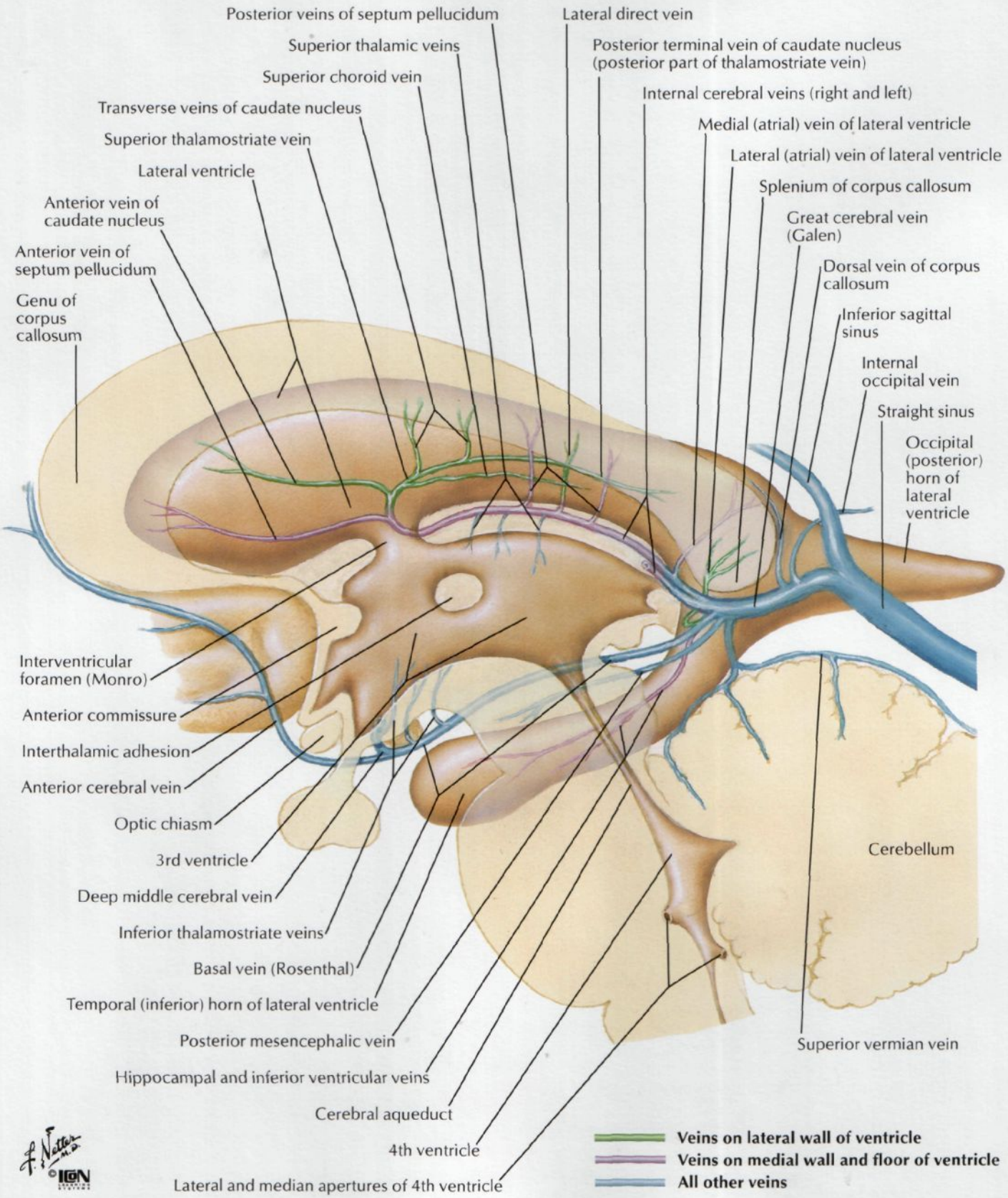

Hypothalamus and Hypophysis

SEE ALSO PLATES 100, 101

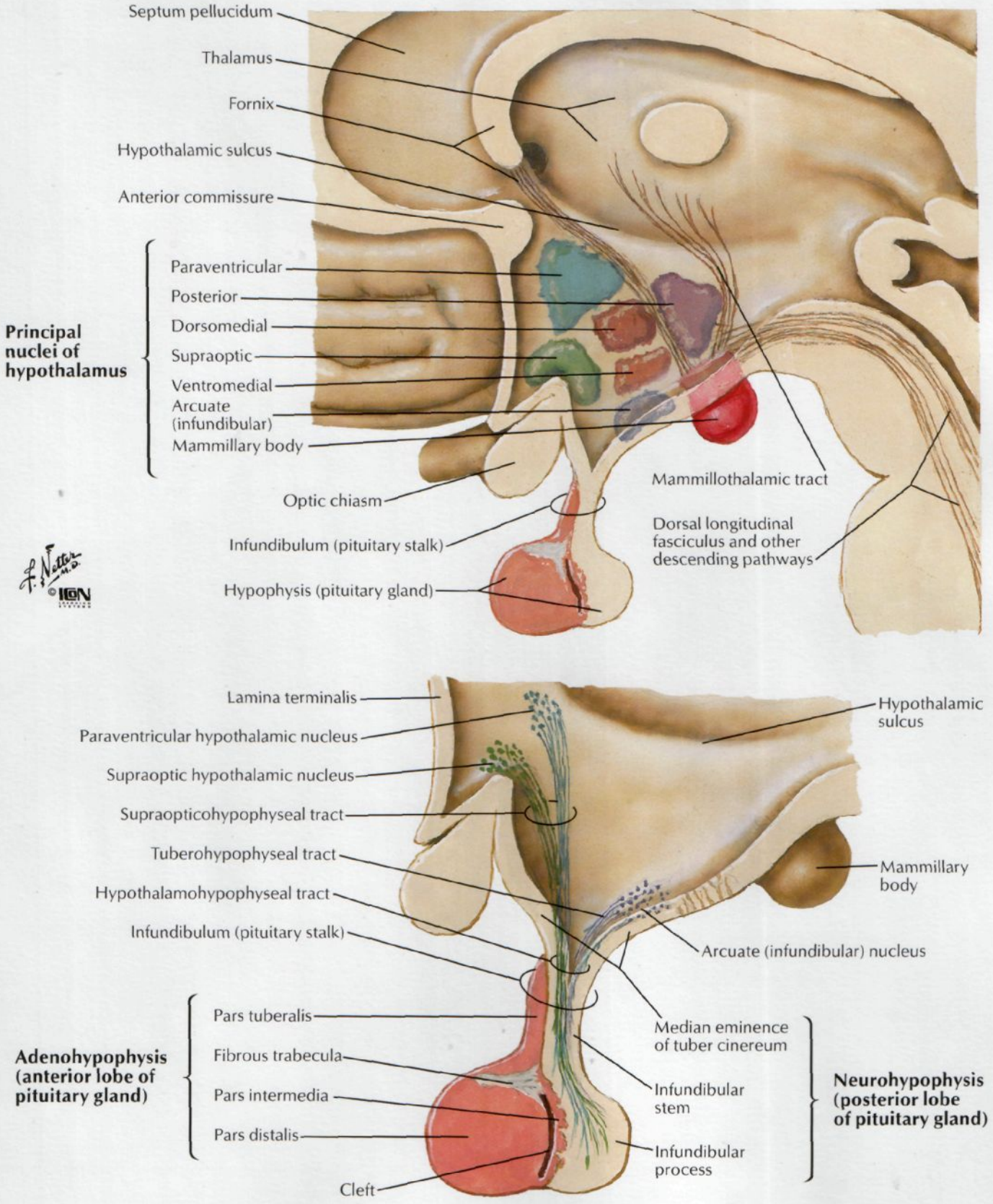

Arteries and Veins of Hypothalamus and Hypophysis

SEE ALSO PLATE 133

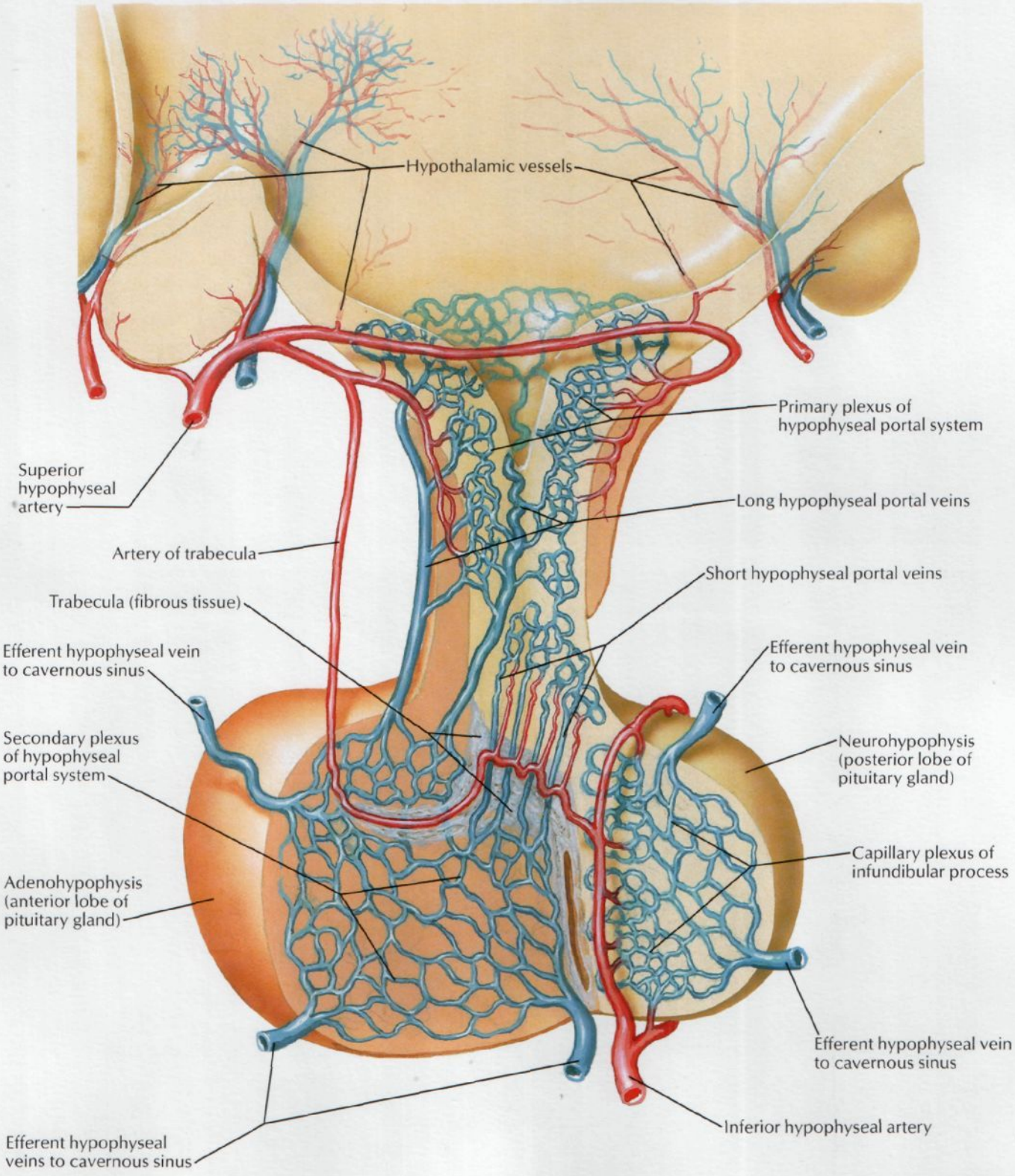

Head Scans: Sagittal MR Images

SEE ALSO PLATE 100

Median (A) and paramedian (B,C) sagittal MR images

A

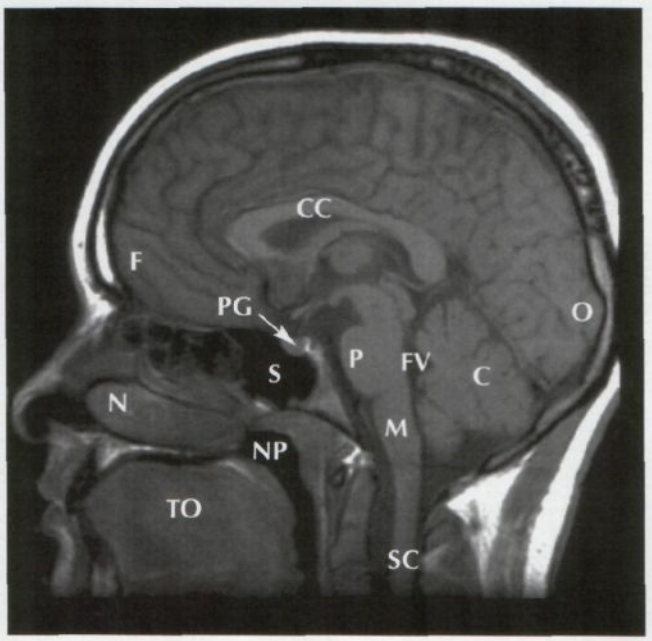

C Cerebellum
CC Corpus callosum
E Extraocular muscles
F Frontal pole
FV Fourth ventricle
L Lateral ventricle
M Medulla oblongata
MB Midbrain
MS Maxillary sinus
N Inferior nasal concha
NP Nasopharynx
O Occipital pole
ON Optic nerve
P Pons
PG Pituitary gland
S Sphenoid sinus
SC Spinal cord
T Thalamus
TC Tentorium cerebelli
TO Tongue

B

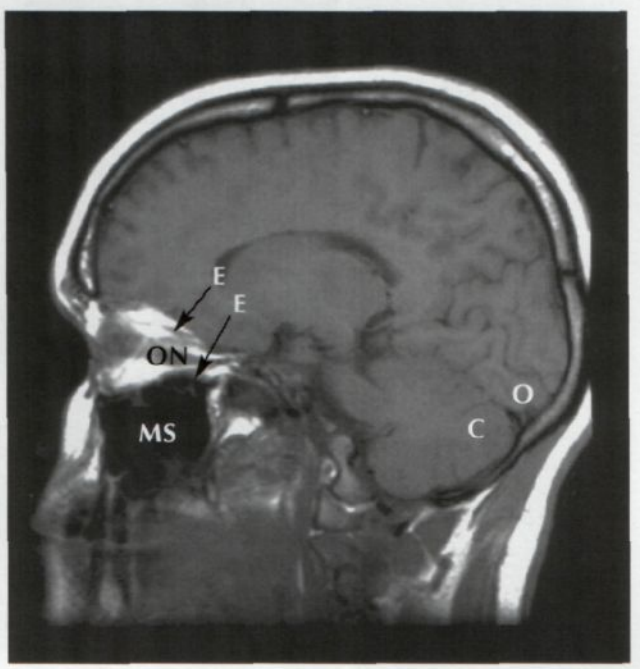

C

SEE ALSO PLATE 43

Axial CT images of the head from inferior (A) to superior (C)

A

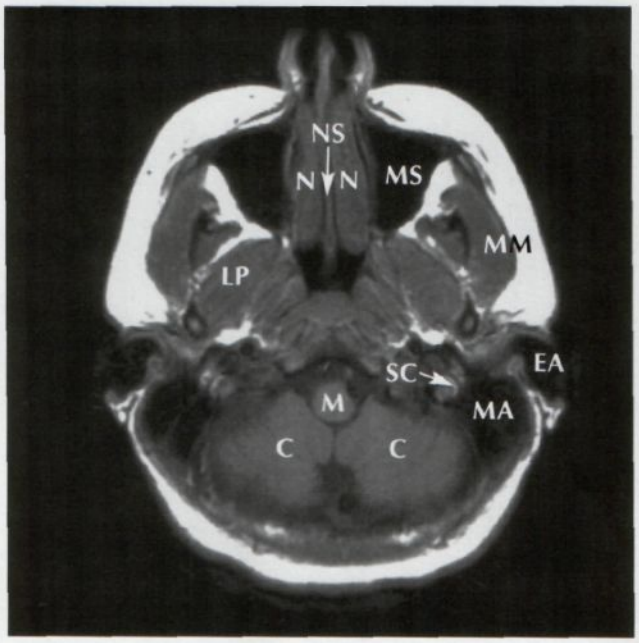

B	Basilar artery
C	Cerebellum
CH	Cerebral hemisphere
CS	Confluence of sinuses
E	Eye
EA	External acoustic meatus
ES	Ethmoid sinus
F	Fat in orbit
FV	Fourth ventricle
L	Lens
LP	Lateral pterygoid muscle
LR	Lateral rectus muscle
M	Medulla oblongata
MA	Mastoid air cells
MB	Midbrain
MM	Masseter muscle
MR	Medial rectus muscle
MS	Maxillary sinus
N	Nasal concha
NS	Nasal septum
P	Pons
S	Sphenoid sinus
SC	Semicircular canals
SS	Superior sagittal sinus
T	Temporalis muscle
TL	Temporal lobe

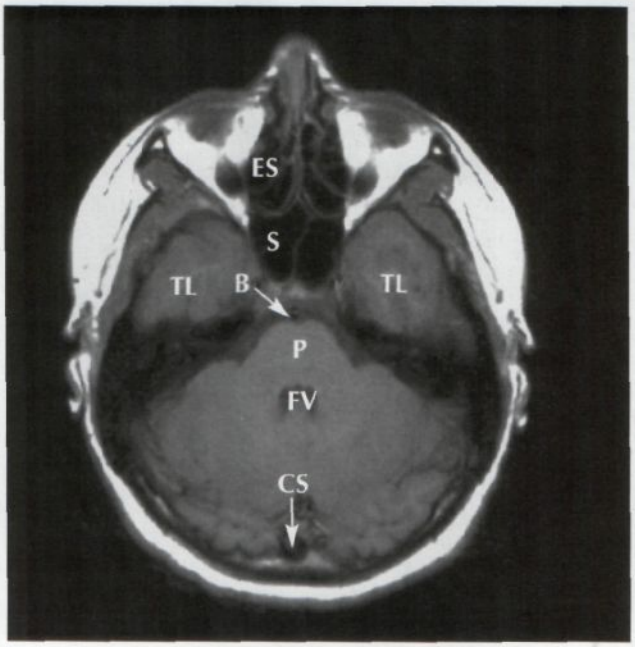

B

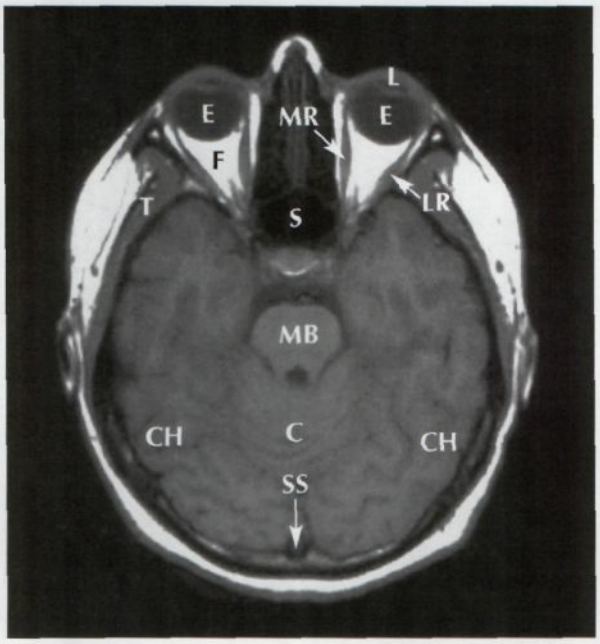

C

Head Scans: Coronal CT Images

SEE ALSO PLATES 44, 79

Coronal CT images of the head from anterior (A) to posterior (C)

A

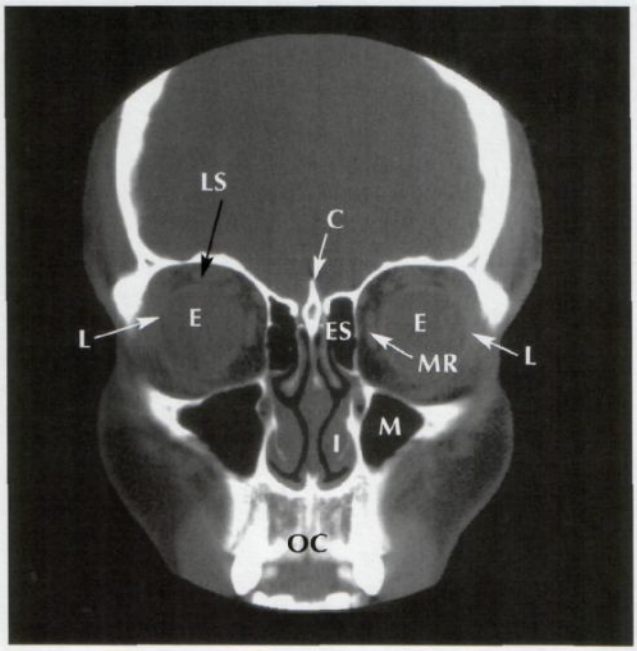

A	Anterior clinoid process
C	Crista galli
E	Eye (vitreous chamber)
ES	Ethmoid sinus
I	Inferior nasal concha
IR	Inferior rectus muscle
L	Lateral rectus muscle
LS	Levator palpebrae superioris and superior rectus muscles
M	Maxillary sinus
MR	Medial rectus muscle
N	Nasal septum
O	Optic nerve
OC	Oral cavity
S	Sphenoid sinus

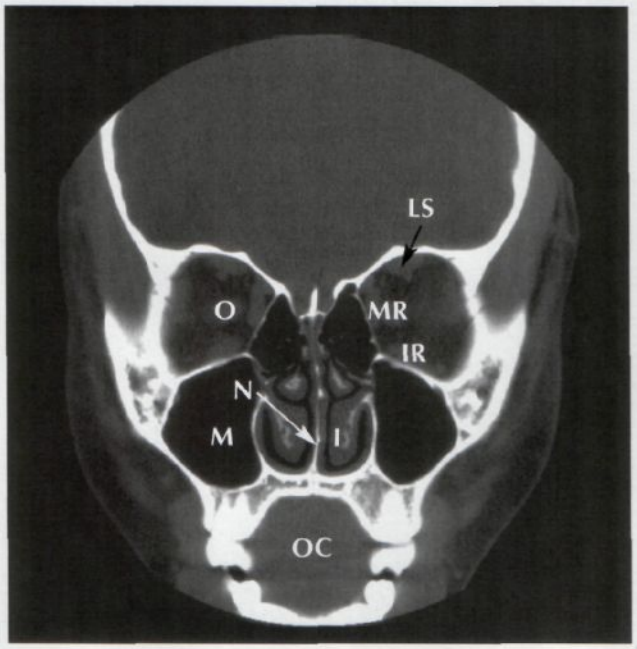

B

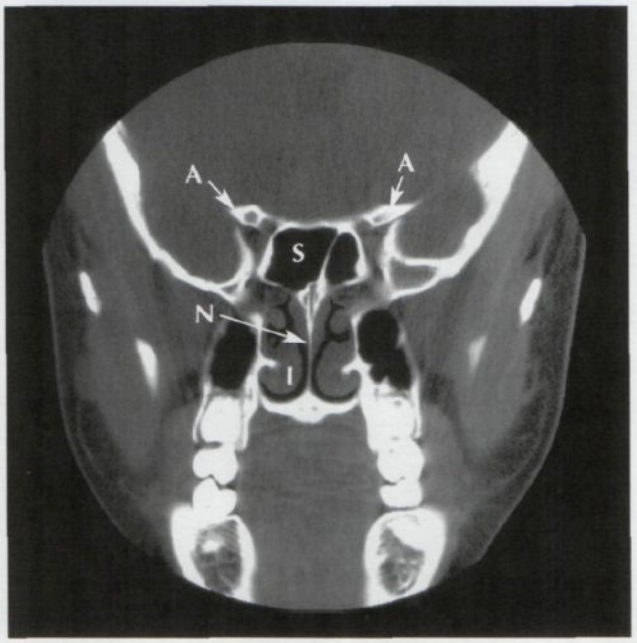

C

Section II

BACK AND SPINAL CORD

SURFACE ANATOMY
Plate 145
145. Back

BONES AND LIGAMENTS
Plates 146–152
146. Vertebral Column
147. Thoracic Vertebrae
148. Lumbar Vertebrae
149. Lumbar Vertebrae: Radiographs
150. Sacrum and Coccyx
151. Vertebral Ligaments: Lumbar Region
152. Vertebral Ligaments: Lumbosacral Region

SPINAL CORD
Plates 153–166
153. Spinal Cord and Ventral Rami In Situ
154. Relation of Spinal Nerve Roots to Vertebrae
155. Motor Impairment Related to Level of Spinal Cord Injury
156. Lumbar Disc Herniation: Clinical Manifestations
157. Dermatomes
158. Spinal Cord Cross Sections: Fiber Tracts
159. Autonomic Nervous System: General Topography
160. Autonomic Nervous System: Schema

161. Cholinergic and Adrenergic Synapses: Schema
162. Spinal Membranes and Nerve Roots
163. Spinal Nerve Origin: Cross Sections
164. Arteries of Spinal Cord: Schema
165. Arteries of Spinal Cord: Intrinsic Distribution
166. Veins of Spinal Cord and Vertebral Column

MUSCLES AND NERVES
Plates 167–173

167. Muscles of Back: Superficial Layers
168. Muscles of Back: Intermediate Layers
169. Muscles of Back: Deep Layers
170. Nerves of Back
171. Suboccipital Triangle
172. Lumbar Region of Back: Cross Section
173. Typical Thoracic Spinal Nerve

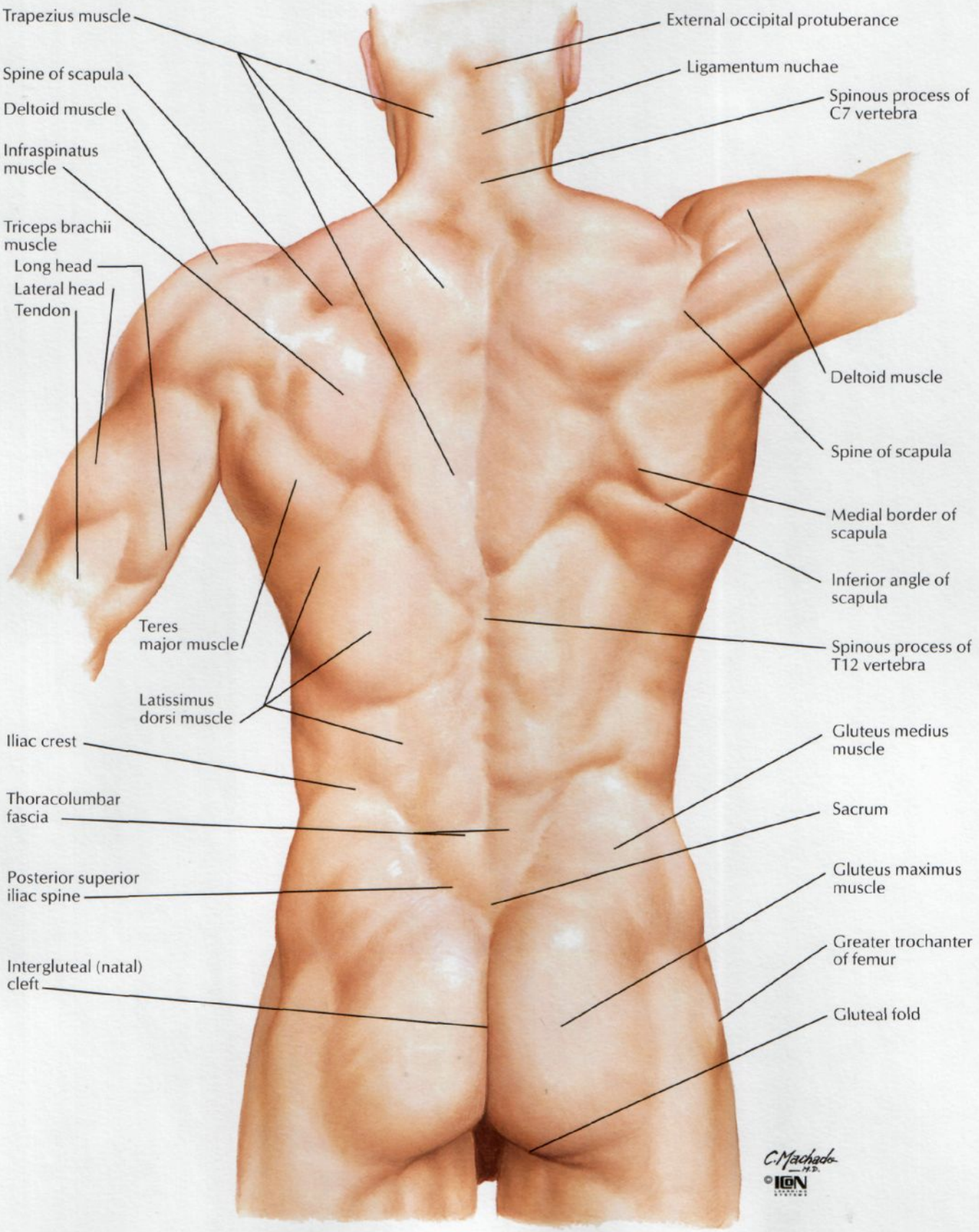
Trapezius muscle
Spine of scapula
Deltoid muscle
Infraspinatus muscle
Triceps brachii muscle
Long head
Lateral head
Tendon
Teres major muscle
Latissimus dorsi muscle
Iliac crest
Thoracolumbar fascia
Posterior superior iliac spine
Intergluteal (natal) cleft
External occipital protuberance
Ligamentum nuchae
Spinous process of C7 vertebra
Deltoid muscle
Spine of scapula
Medial border of scapula
Inferior angle of scapula
Spinous process of T12 vertebra
Gluteus medius muscle
Sacrum
Gluteus maximus muscle
Greater trochanter of femur
Gluteal fold
C. Machado, M.D.
©ION

Vertebral Column

SEE ALSO PLATES 12, 15, 16, 147, 148, 150, 178, 240

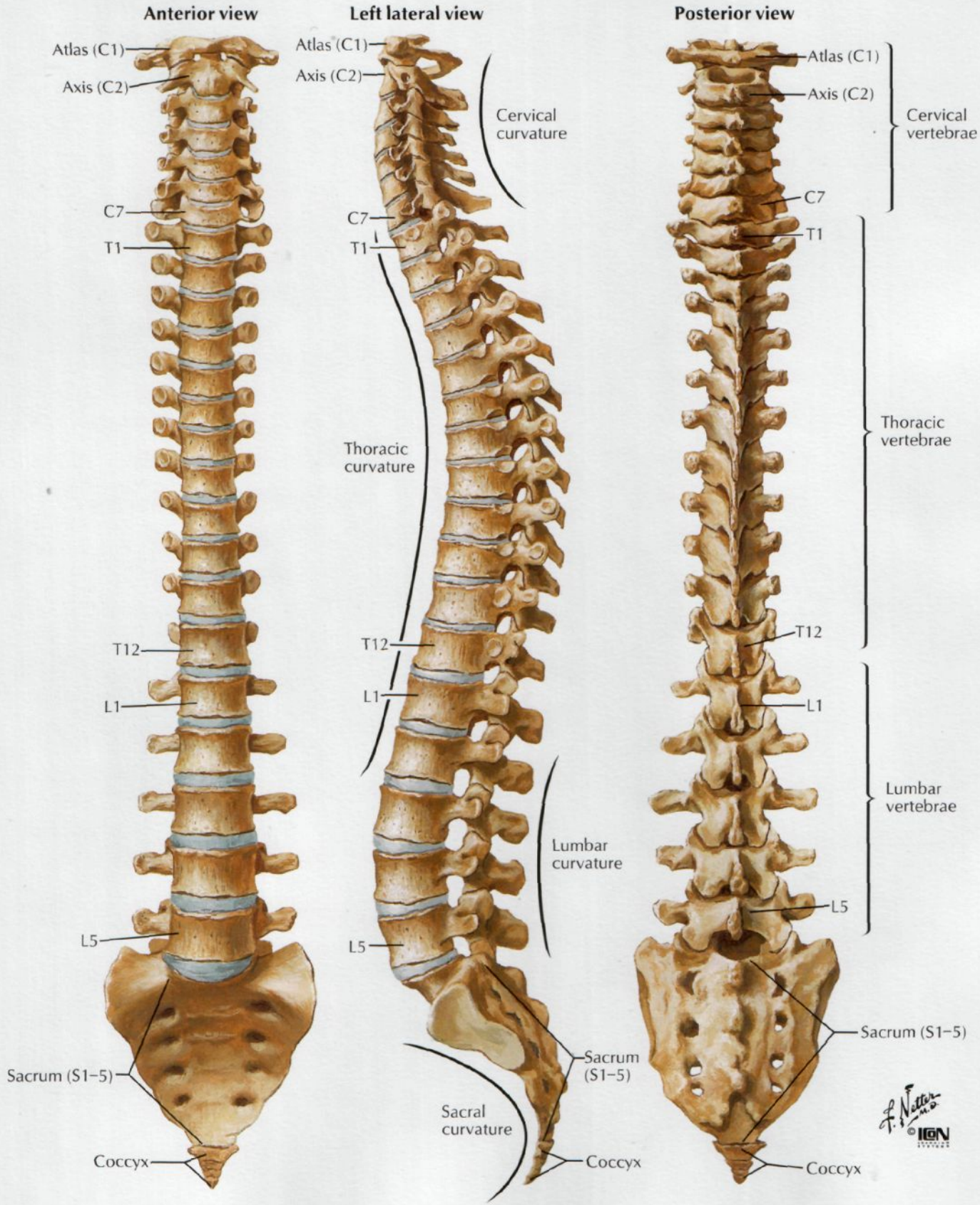

SEE ALSO PLATE 180

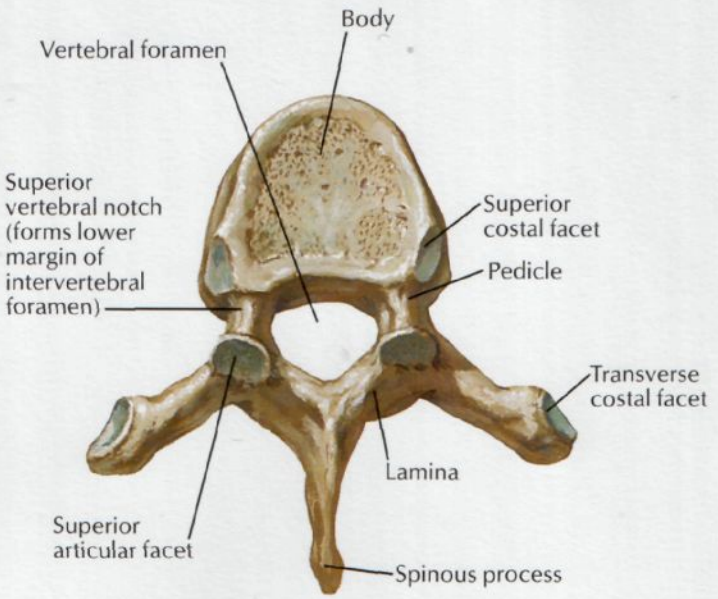

T6 vertebra: superior view

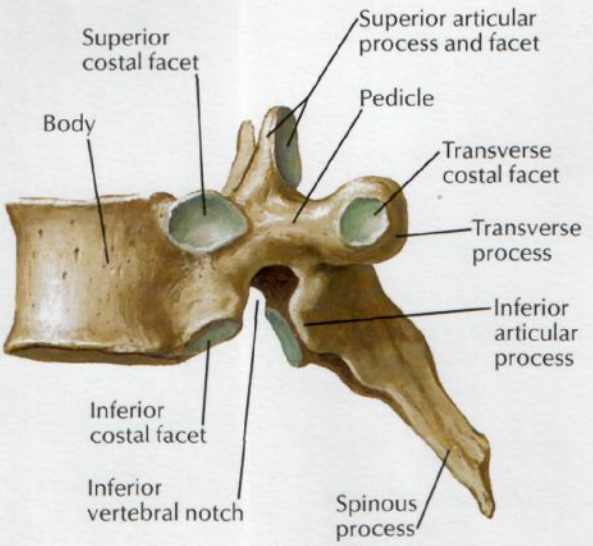

T6 vertebra: lateral view

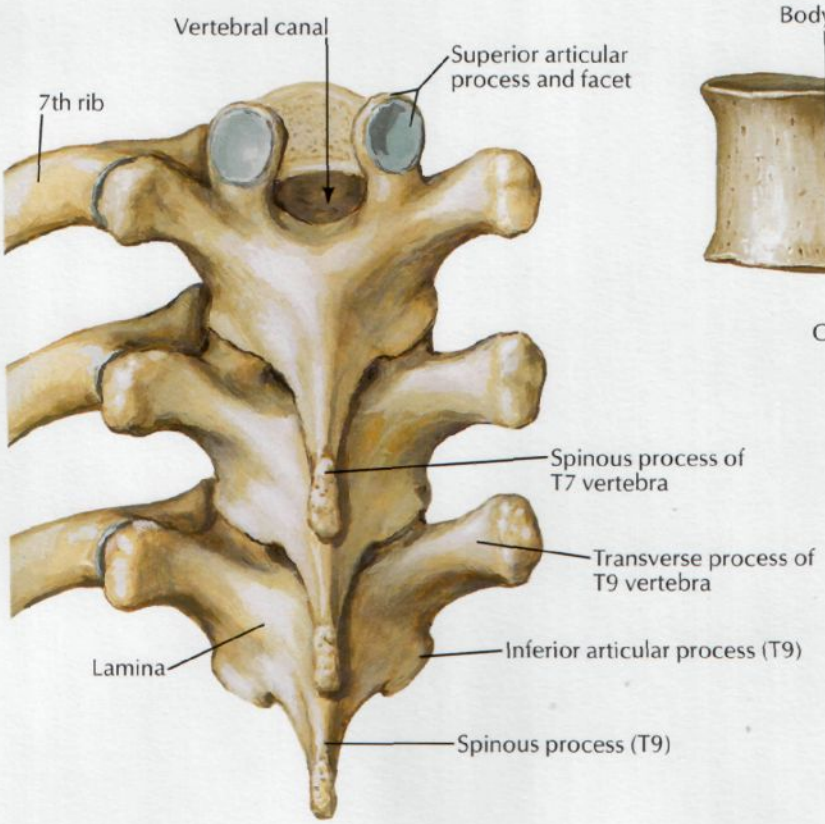

T7, T8 and T9 vertebrae: posterior view

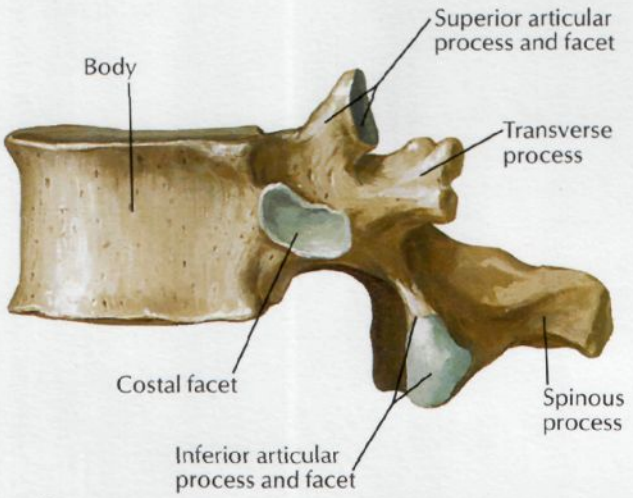

T12 vertebra: lateral view

Lumbar Vertebrae

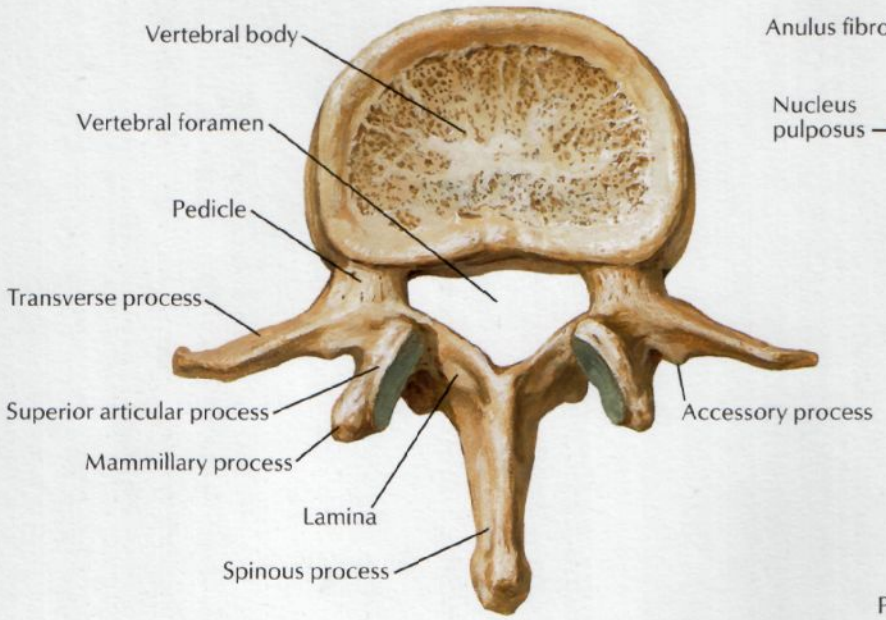

L2 vertebra: superior view

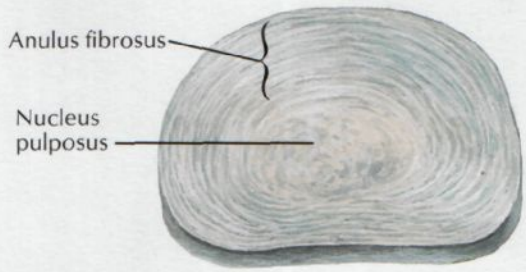

Intervertebral disc

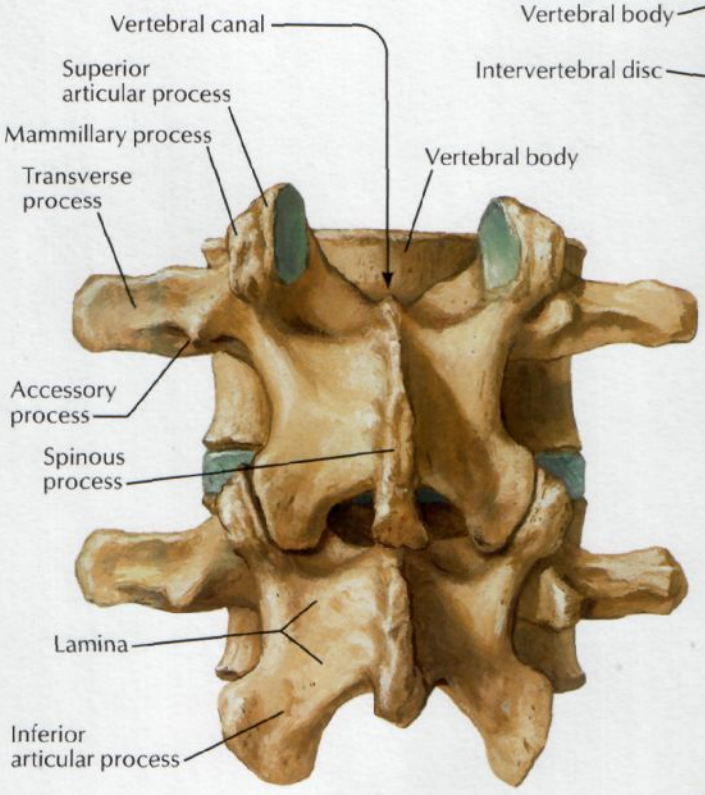

L3 and L4 vertebrae: posterior view

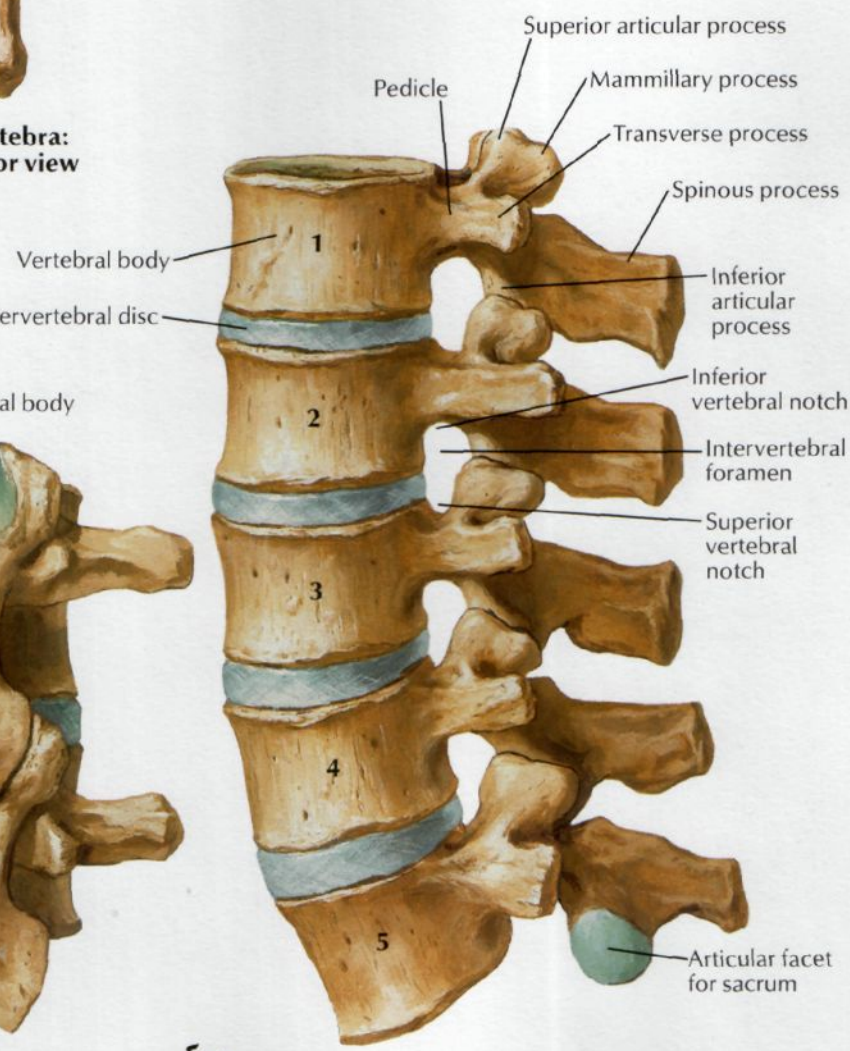

Lumbar vertebrae, assembled: left lateral view

F. Netter M.D. ©IGN

Anteroposterior radiograph

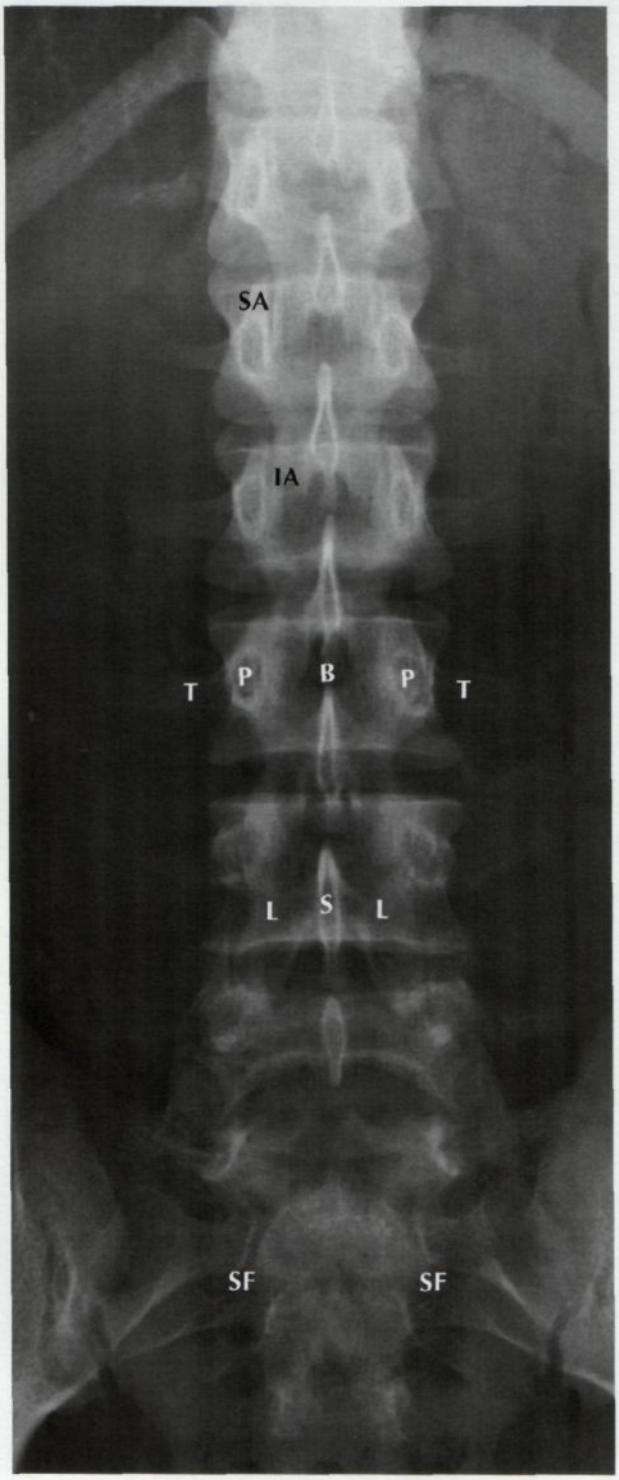

B Body of L3 vertebra
IA Inferior articular process of L1 vertebra
L Lamina of L4 vertebra
P Pedicle of L3 vertebra
S Spinous process of L4 vertebra
SA Superior articular process of L1 vertebra
SF Sacral foramen
T Transverse process of L3 vertebra

Lateral radiograph

D Intervertebral disc space
I Intervertebral foramen
IN Inferior vertebral notch of L4 vertebra
P Pedicle of L3 vertebra
S Spinous process of L3 vertebra
SA Sacrum
SN Superior vertebral notch of L5 vertebra
Note: The lumbar vertebral bodies are numbered

Sacrum and Coccyx

SEE ALSO PLATES 146, 152, 240, 340–342

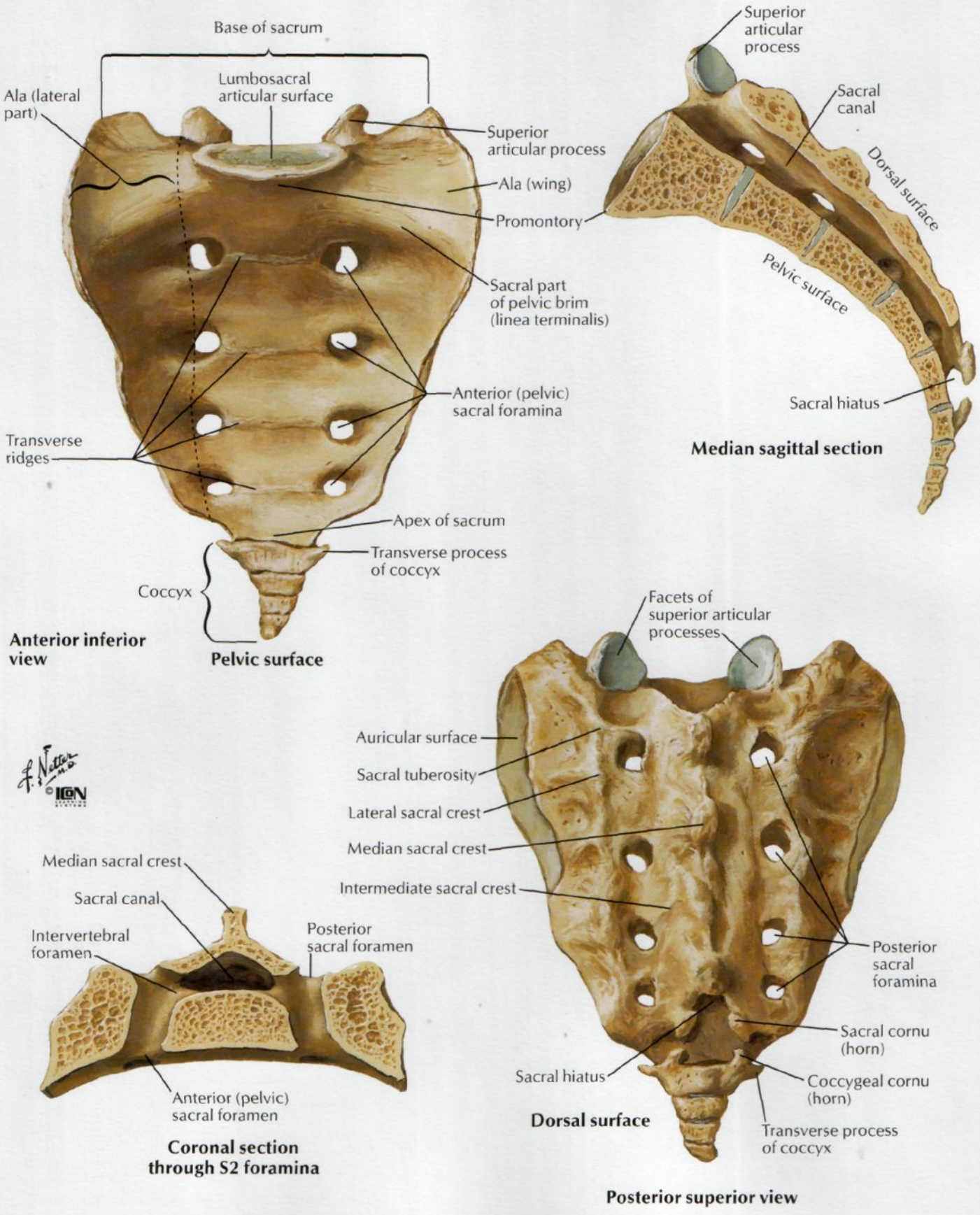

Left lateral view (*partially sectioned in median plane*)

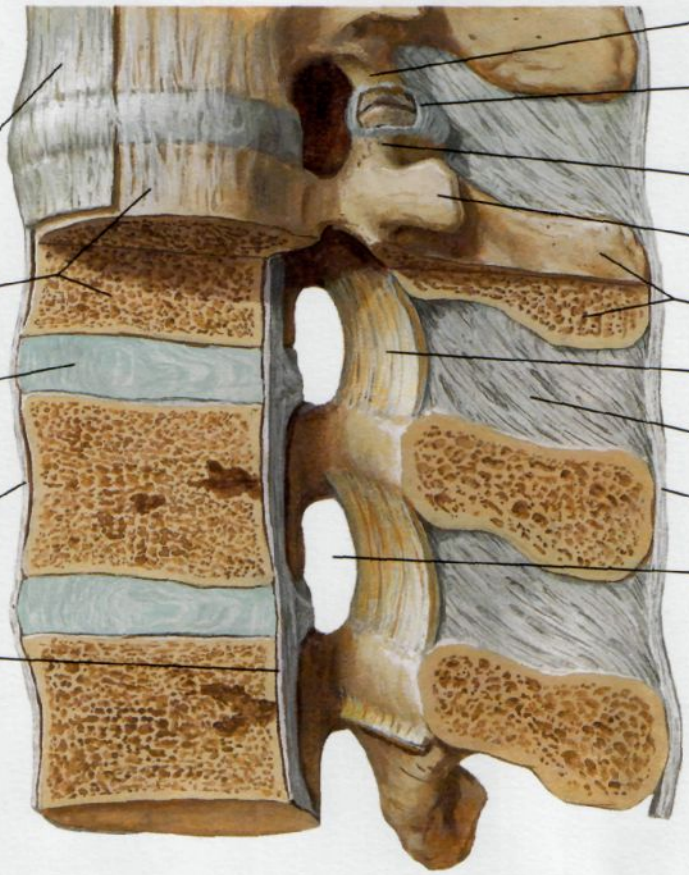

Anterior vertebral segments: posterior view (*pedicles sectioned*)

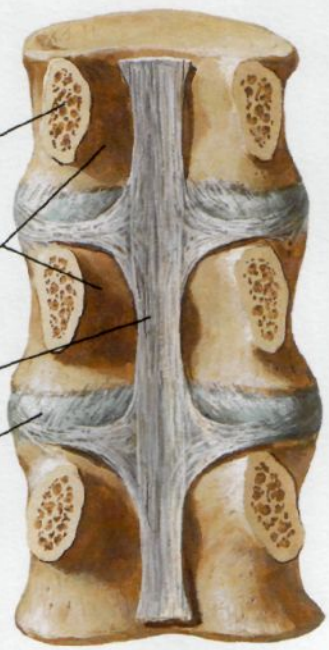

Posterior vertebral segments: anterior view

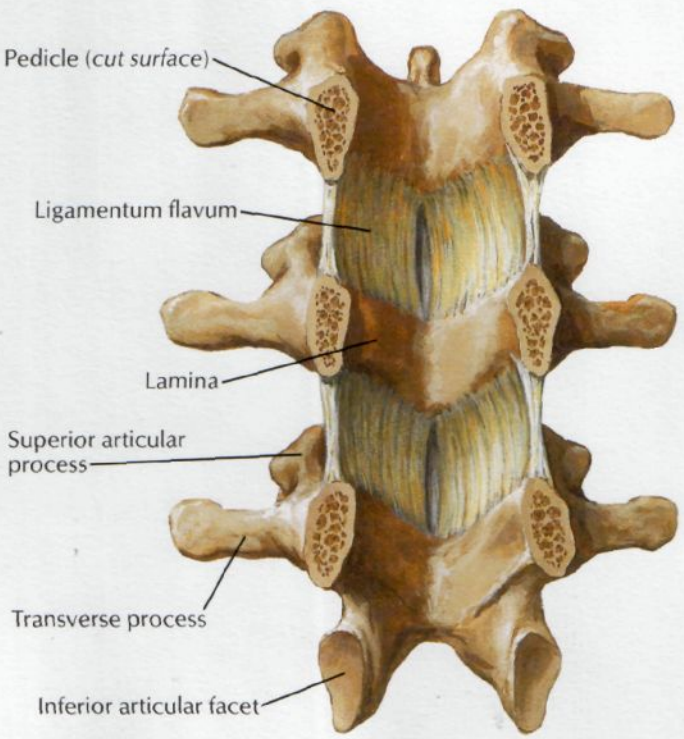

F. Netter M.D. ©IGN

Vertebral Ligaments: Lumbosacral Region

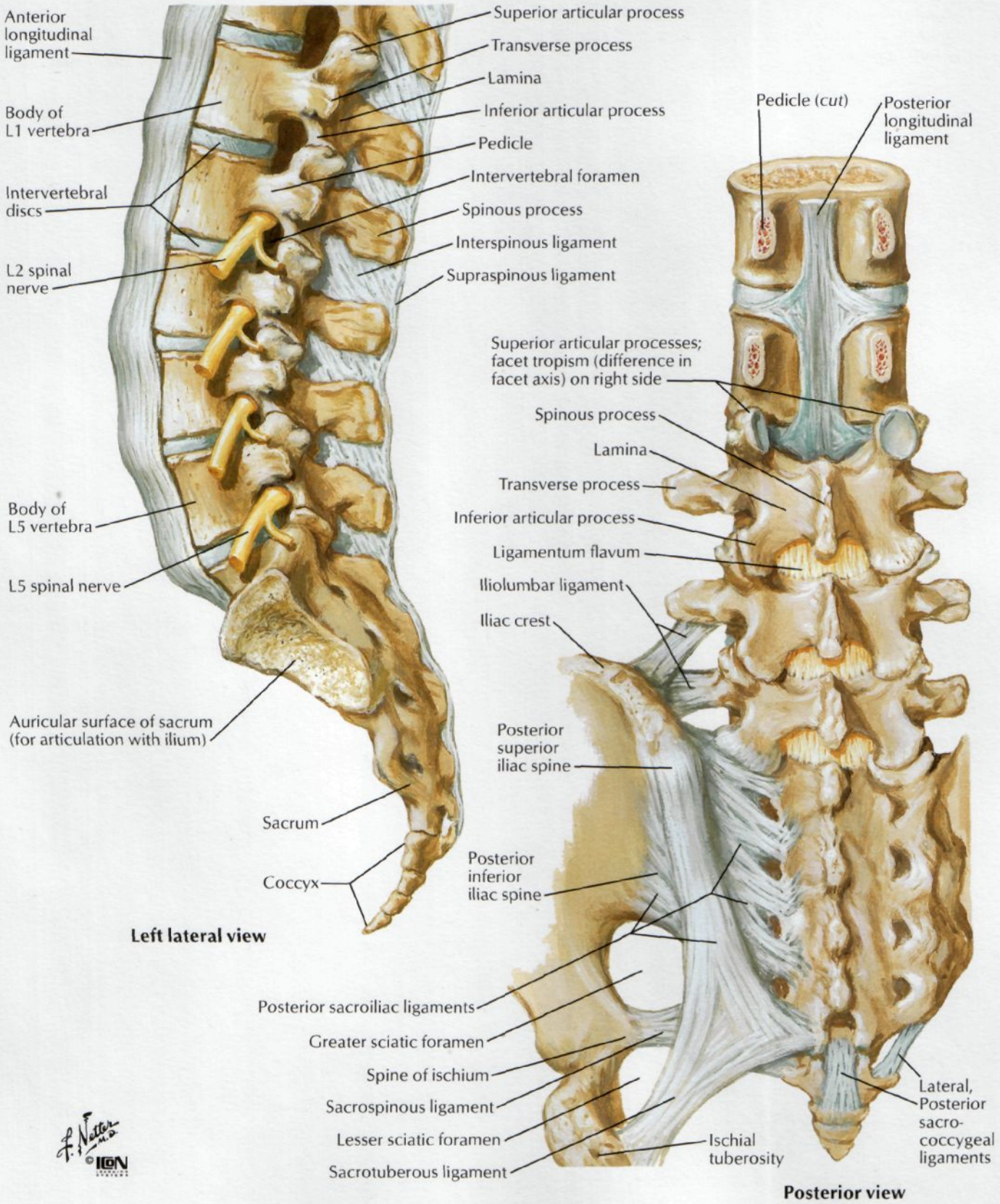

Spinal Cord and Ventral Rami In Situ

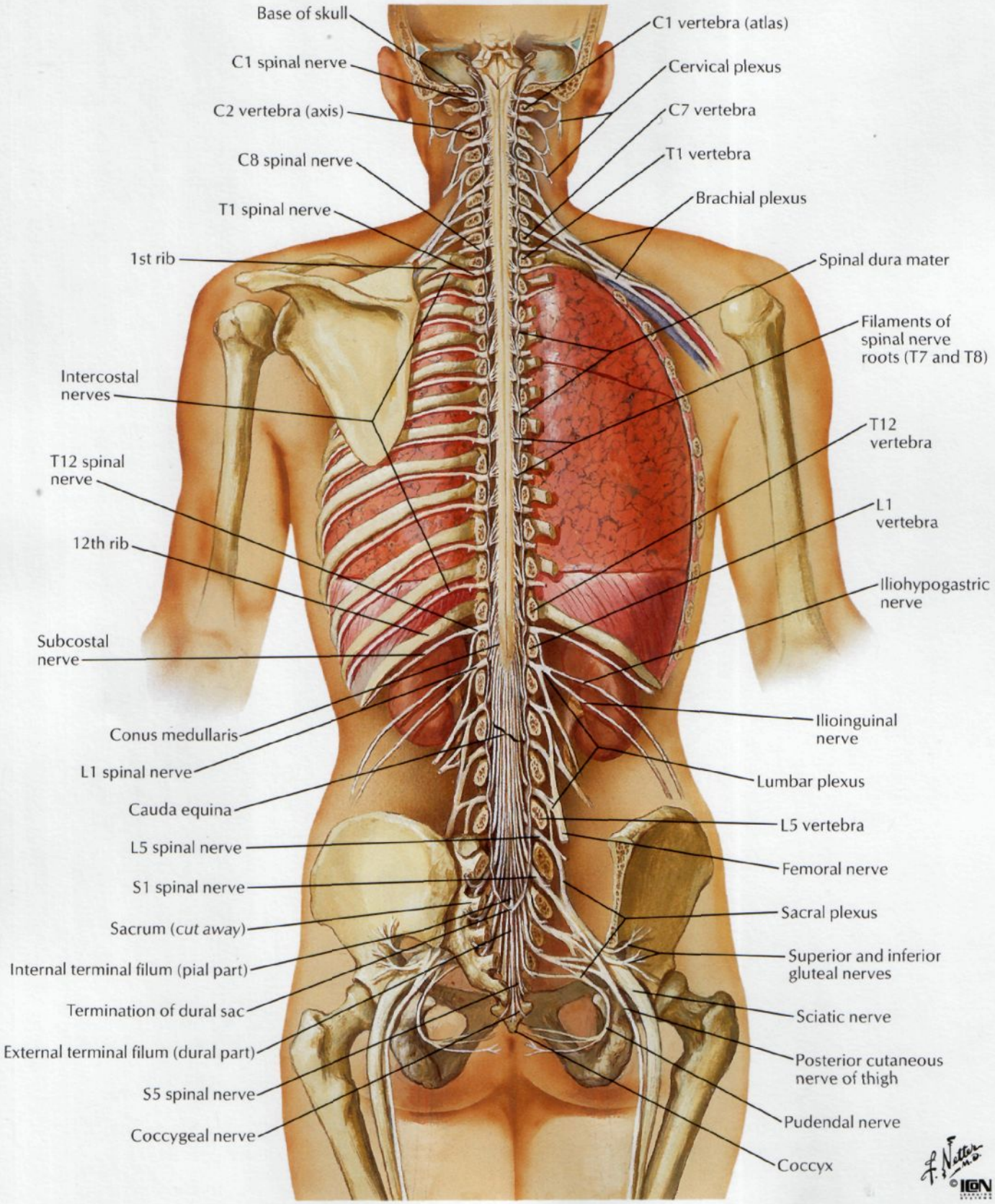

Relation of Spinal Nerve Roots to Vertebrae

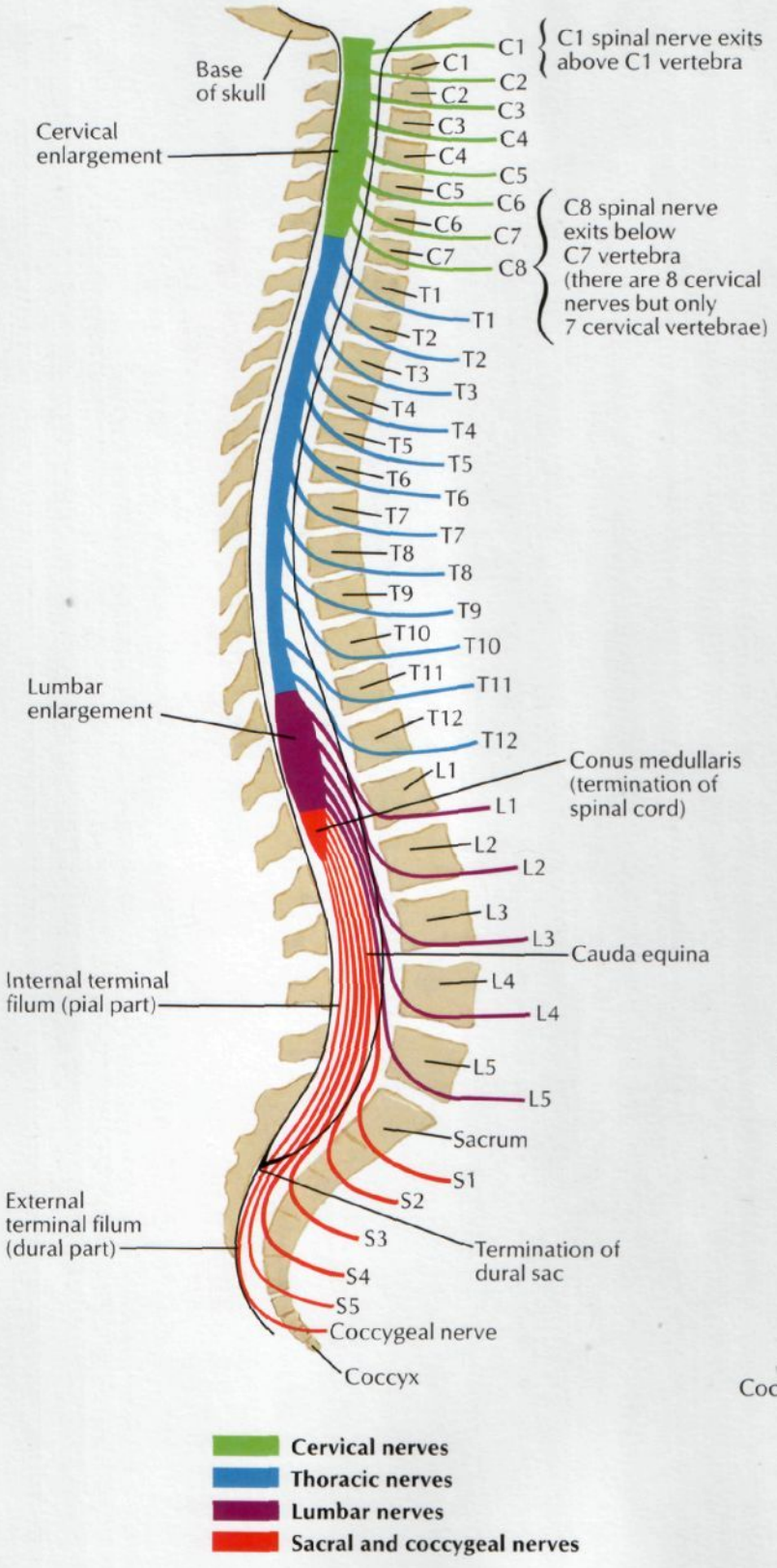

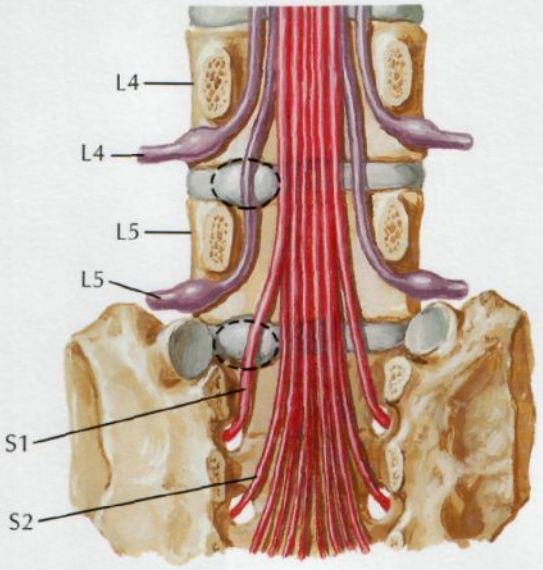

Lumbar disc protrusion does not usually affect nerve exiting above disc. Lateral protrusion at disc level L4–5 affects L5 spinal nerve, not L4 spinal nerve. Protrusion at disc level L5–S1 affects S1 spinal nerve, not L5 spinal nerve

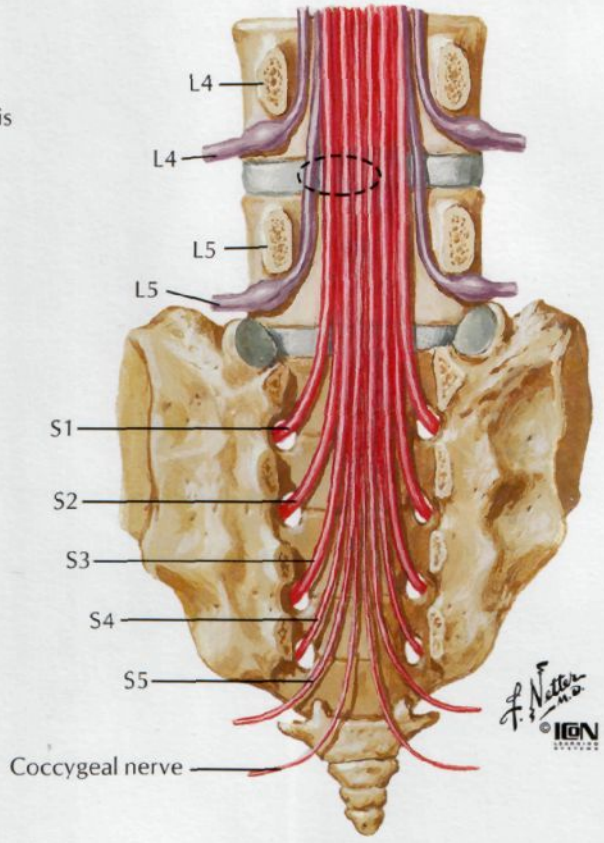

Medial protrusion at disc level L4–5 rarely affects L4 spinal nerve but may affect L5 spinal nerve and sometimes S1–4 spinal nerves

Motor Impairment Related to Level of Spinal Cord Injury

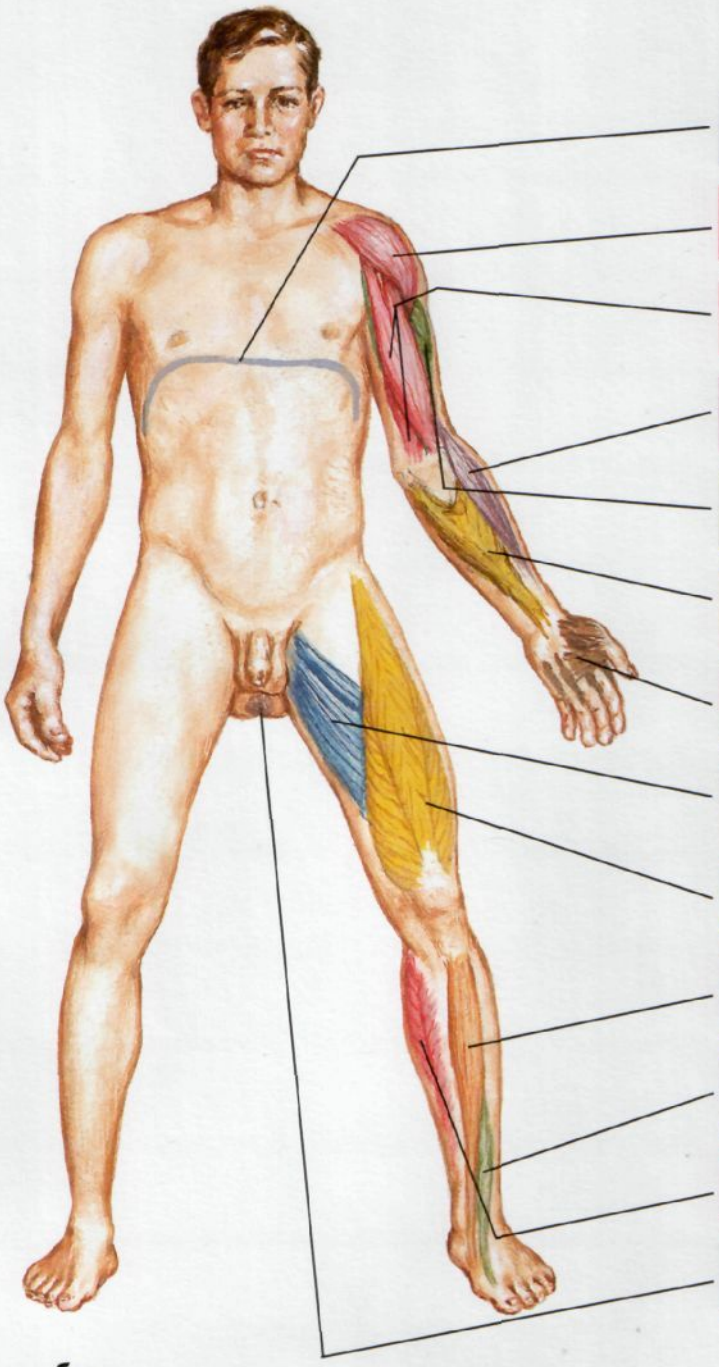

Function	Muscles	Segments
Inspiration	Diaphragm	C3,4, 5
Shoulder abduction	Deltoid	C5
Elbow flexion	Biceps brachii Brachialis	C5, 6
Wrist extension	Extensor carpi radialis longus and brevis	C6, 7
Elbow extension	Triceps brachii	C7, 8
Finger flexion	Flexor digitorum superficialis and profundus	C8
Finger abduction and adduction	Interossei	C8, T1
Thigh adduction	Adductor longus and brevis	L2, 3
Knee extension	Quadriceps	L3, 4
Ankle dorsiflexion	Tibialis anterior	L4, 5
Great toe extension	Extensor hallucis longus	L5, S1
Ankle plantar flexion	Gastrocnemius Soleus	S1, 2
Anal contraction	Sphincter ani externus	S2, 3, 4

F. Netter, M.D.

©IGN

Lumbar Disc Herniation: Clinical Manifestations

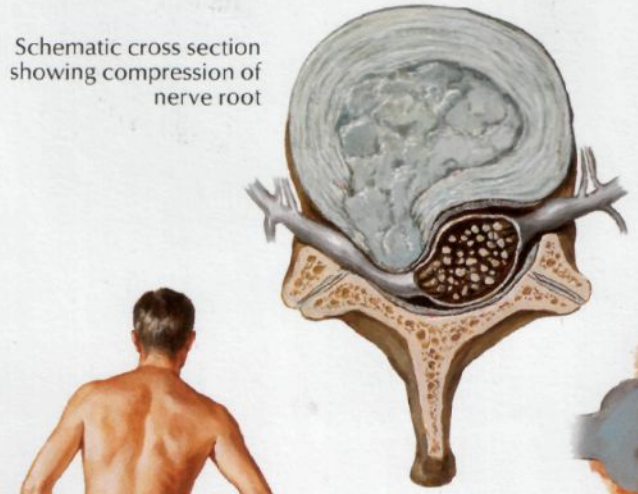

Schematic cross section showing compression of nerve root

Characteristic posture in left-sided lower lumbar disc herniation

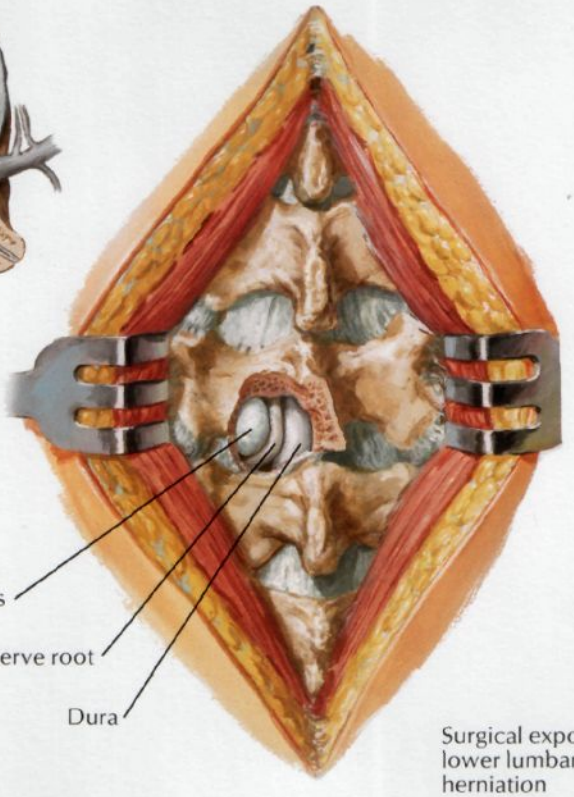

Surgical exposure of lower lumbar disc herniation

Clinical features of herniated lumbar nucleus pulposus

Level of herniation	Pain	Numbness	Weakness	Atrophy	Reflexes
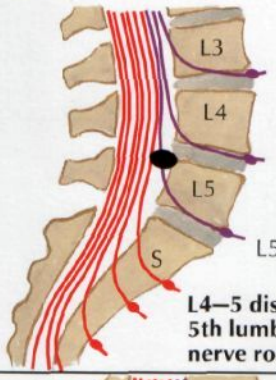 **L4–5 disc; 5th lumbar nerve root**	Over sacro-iliac joint, hip, lateral thigh and leg	Lateral leg, first 3 toes	Dorsiflexion of great toe and foot; difficulty walking on heels; foot drop may occur	Minor	Changes uncommon in knee and ankle jerks, but internal hamstring reflex diminished or absent
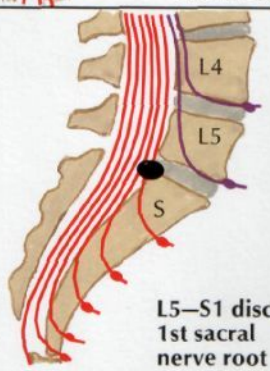 **L5–S1 disc; 1st sacral nerve root**	Over sacro-iliac joint, hip, postero-lateral thigh and leg to heel	Back of calf, lateral heel, foot to toe	Plantar flexion of foot and great toe may be affected; difficulty walking on toes	Gastrocnemi-us and soleus	Ankle jerk diminished or absent

SEE ALSO PLATES 465, 525; FOR MAPS OF CUTANEOUS NERVES SEE PLATES 20, 455, 457–459, 461, 464, 520–524

Schematic demarcation of dermatomes (according to Keegan and Garrett) shown as distinct segments. There is actually considerable overlap between any two adjacent dermatomes. An alternative dermatome map is that provided by Foerster (see References).

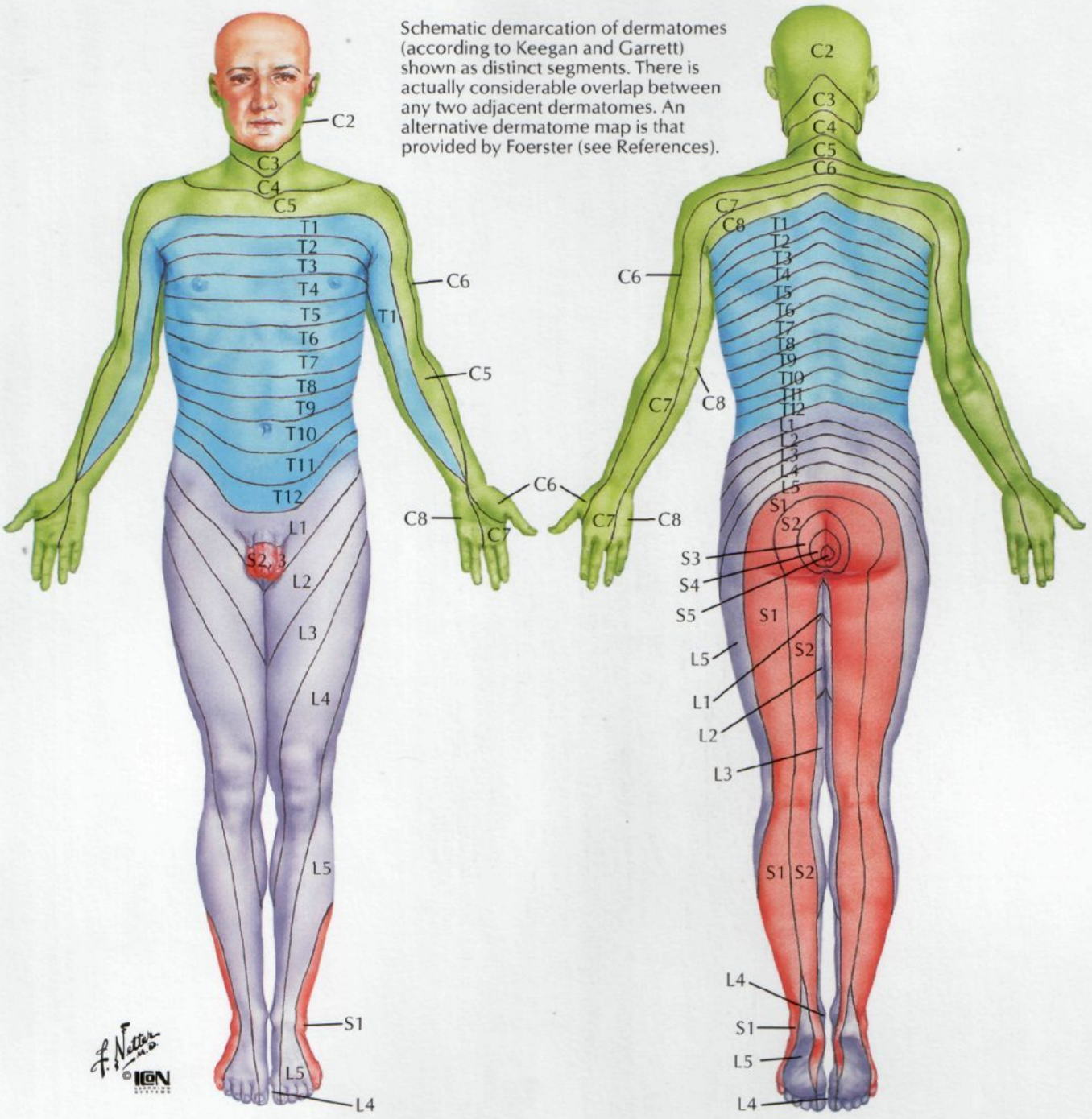

Levels of principal dermatomes

C5	Clavicles
C5, 6, 7	Lateral parts of upper limbs
C8, T1	Medial sides of upper limbs
C6	Thumb
C6, 7, 8	Hand
C8	Ring and little fingers
T4	Level of nipples
T10	Level of umbilicus
T12	Inguinal or groin regions
L1, 2, 3, 4	Anterior and inner surfaces of lower limbs
L4, 5, S1	Foot
L4	Medial side of great toe
S1, 2, L5	Posterior and outer surfaces of lower limbs
S1	Lateral margin of foot and little toe
S2, 3, 4	Perineum

Spinal Cord Cross Sections: Fiber Tracts

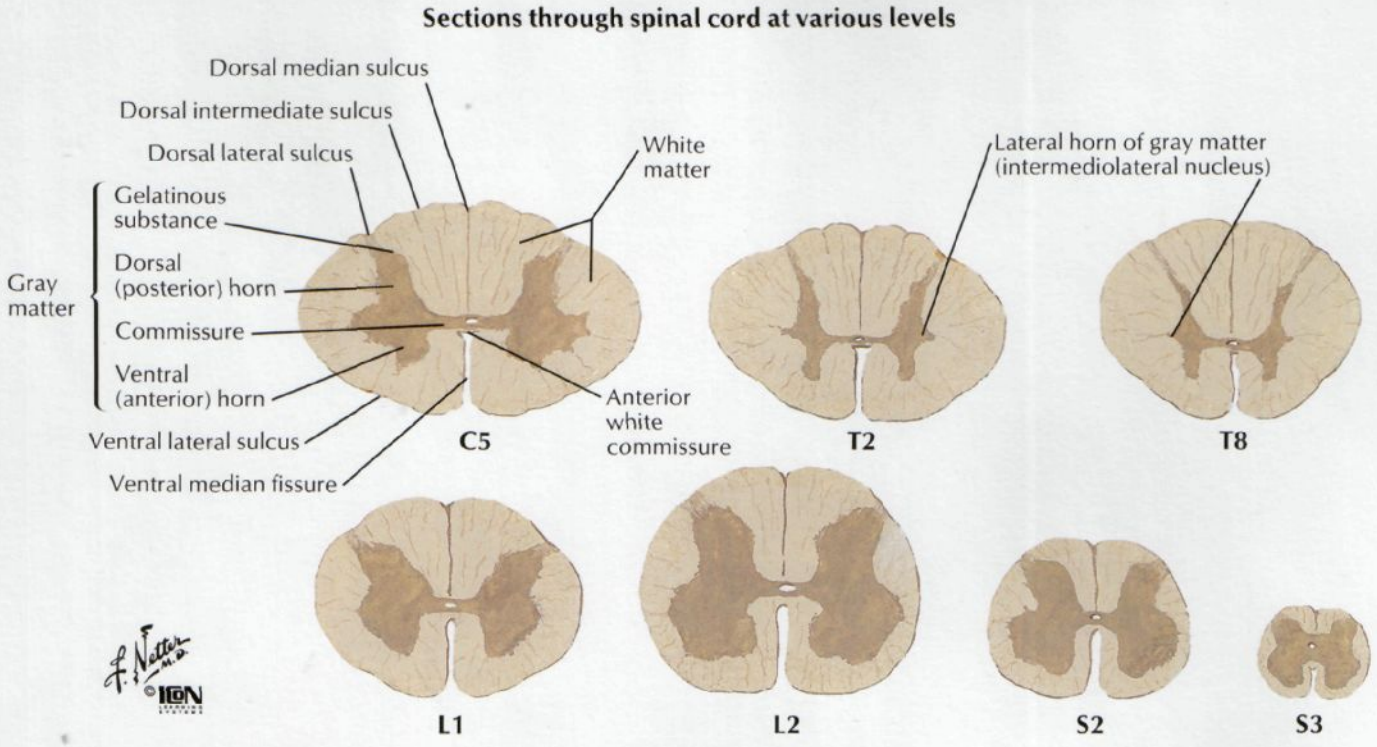

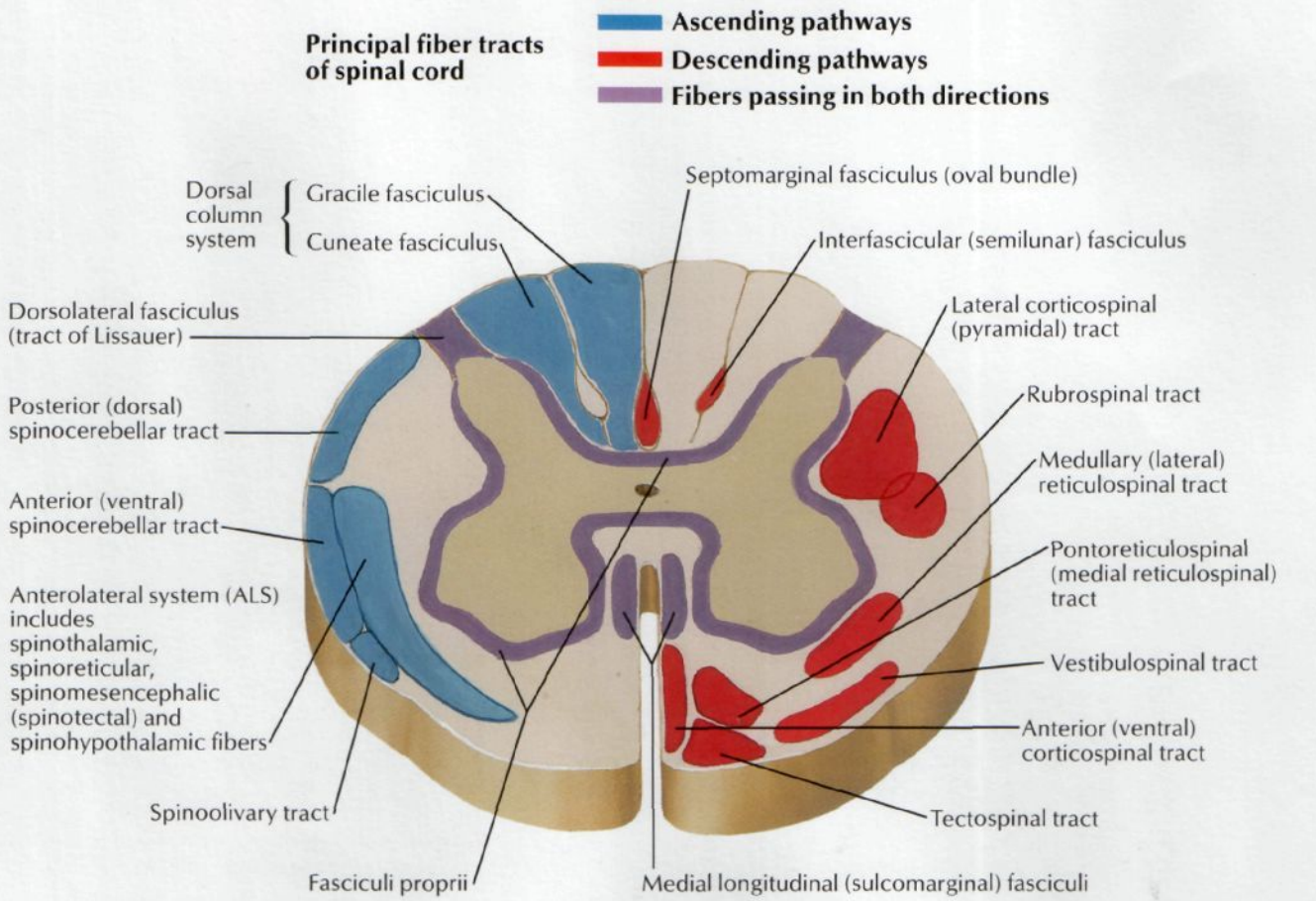

Autonomic Nervous System: General Topography

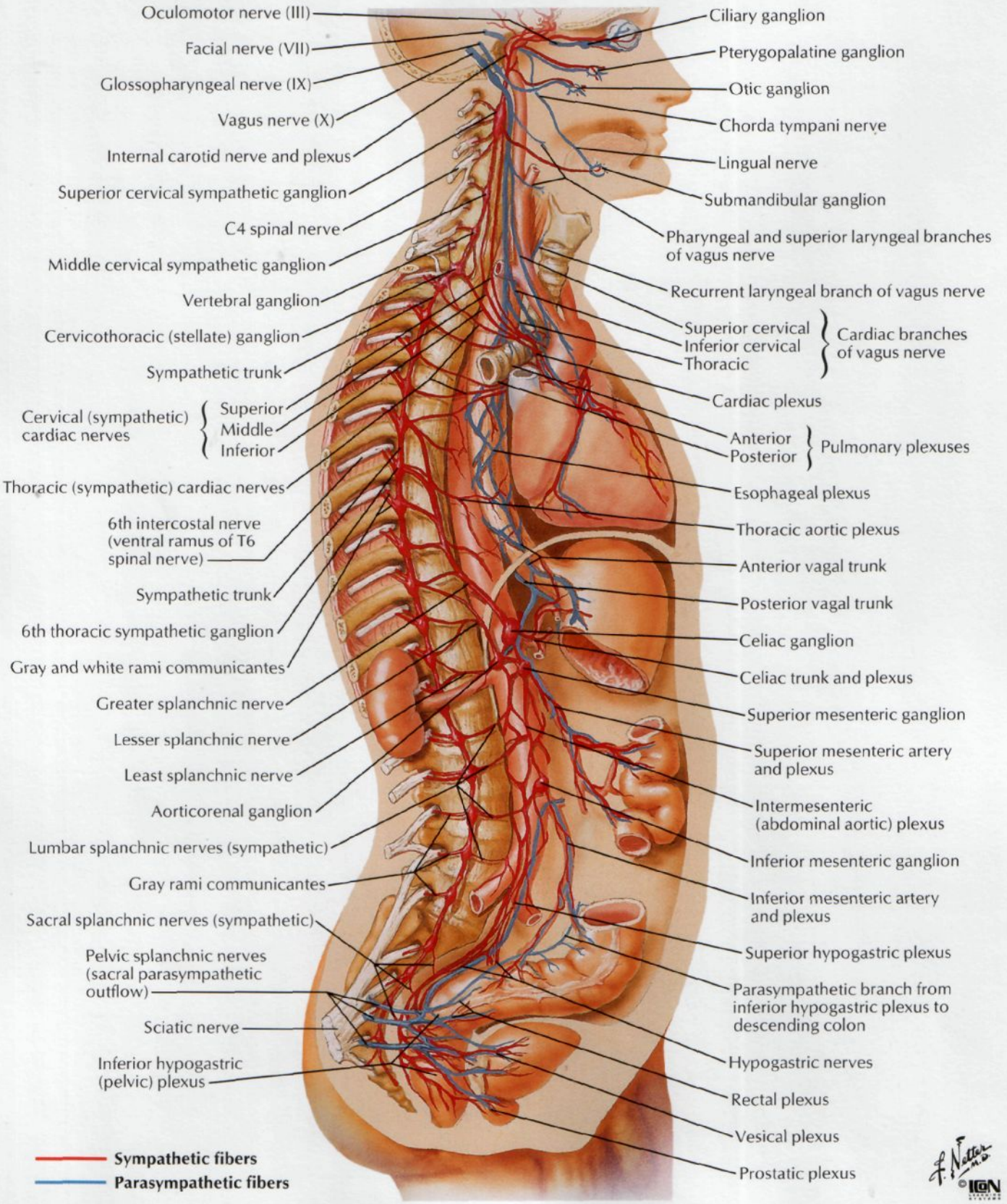

Autonomic Nervous System: Schema

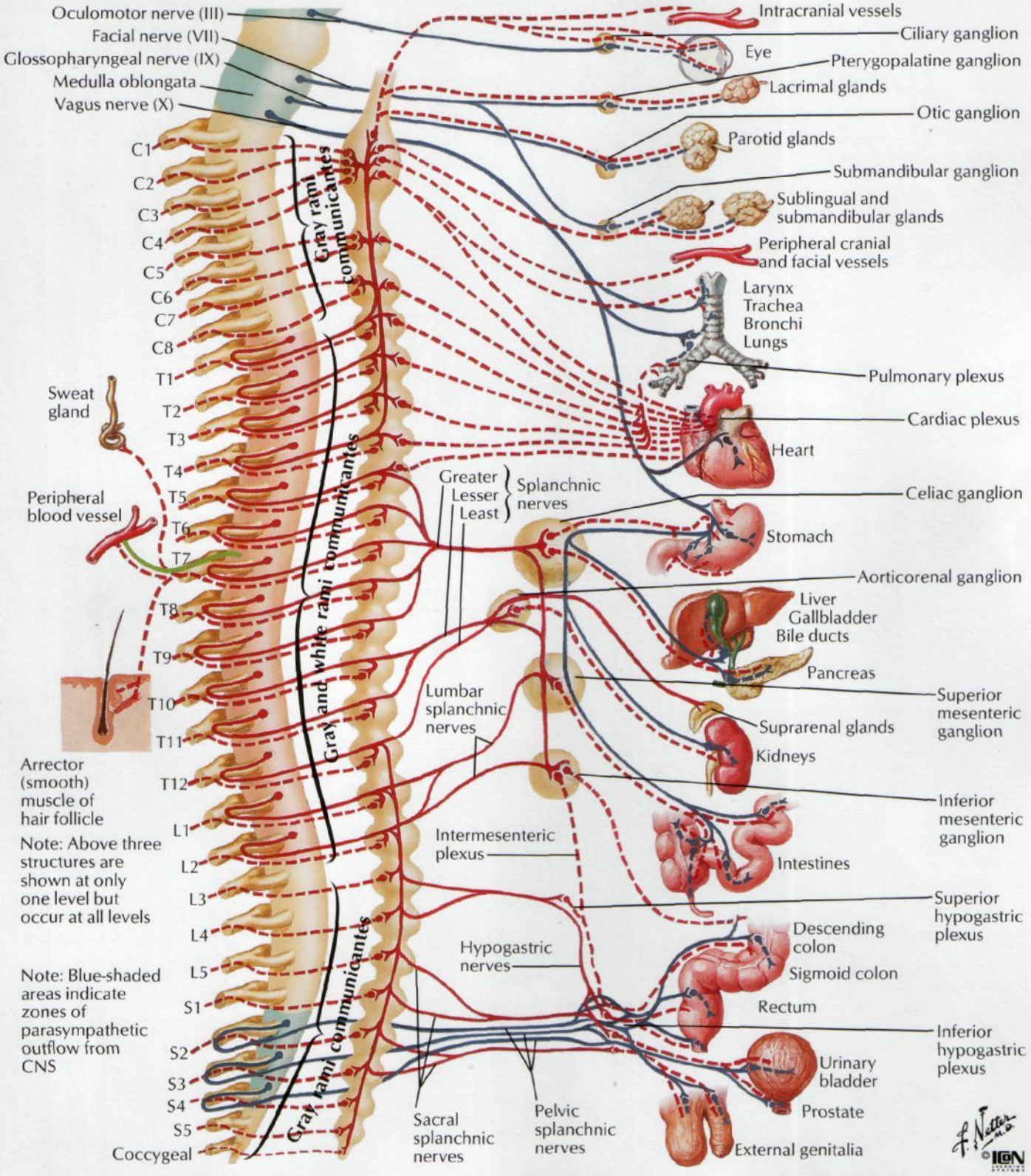

Cholinergic and Adrenergic Synapses: Schema

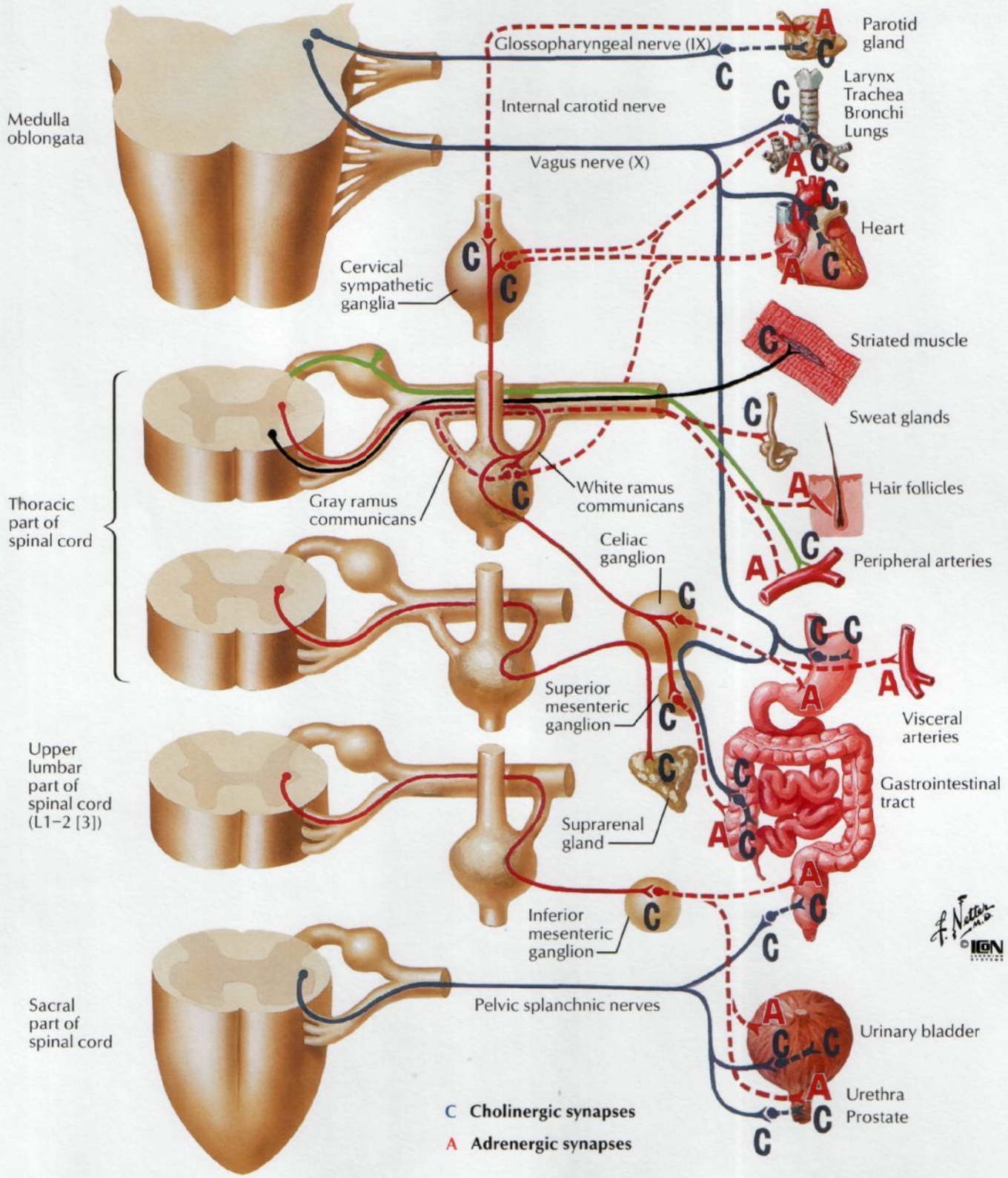

Spinal Membranes and Nerve Roots

Posterior view

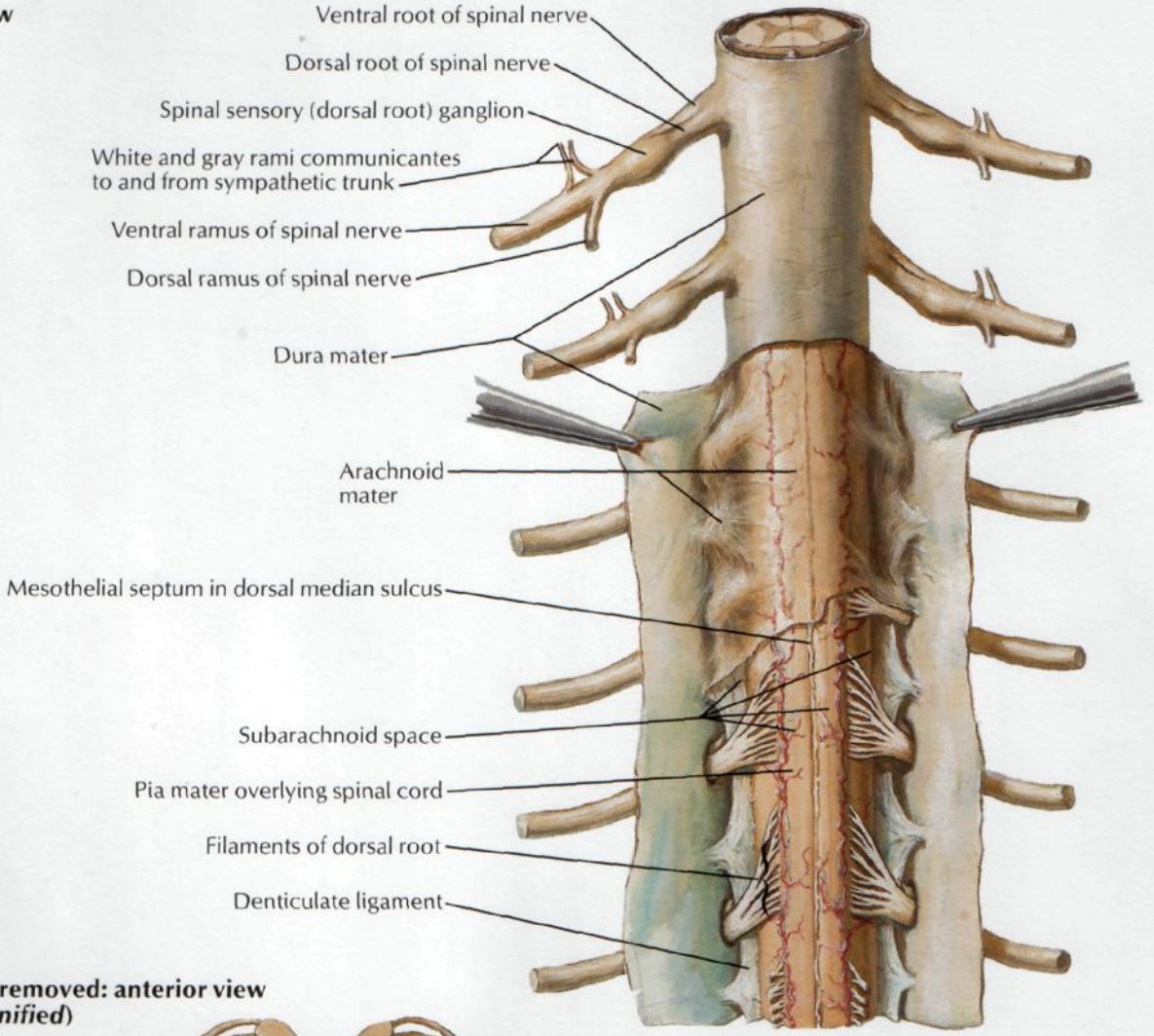

Membranes removed: anterior view
(greatly magnified)

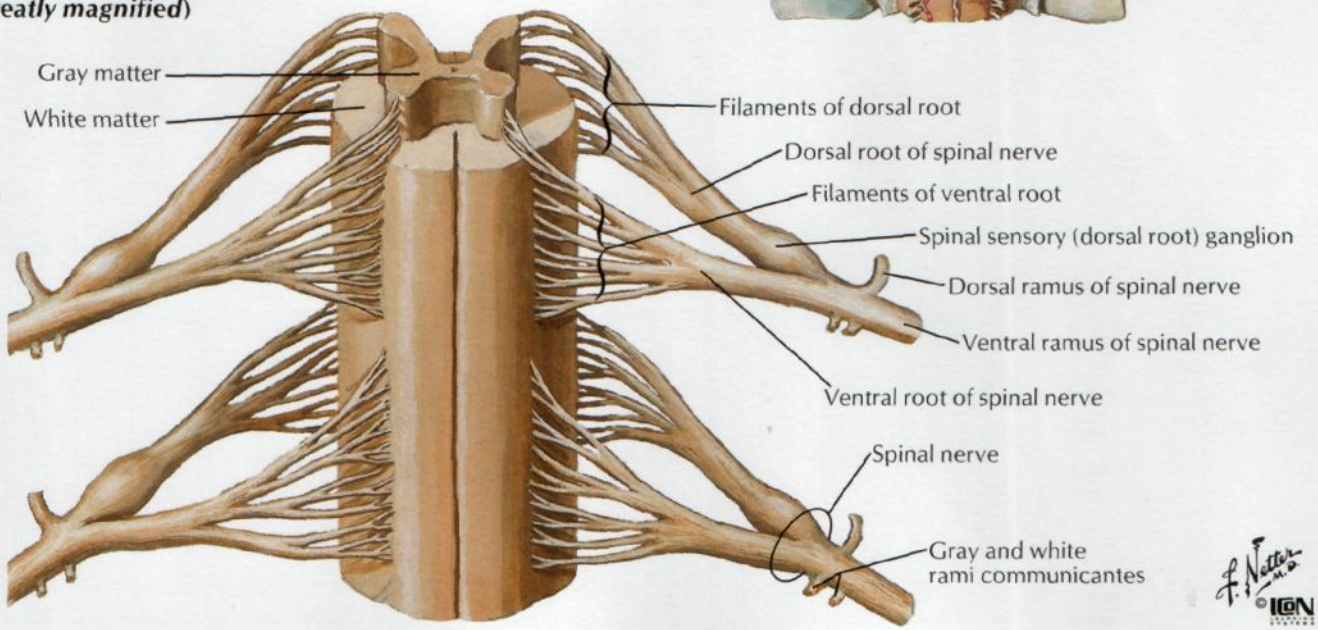

Spinal Nerve Origin: Cross Sections

SEE ALSO PLATES 161, 162, 165, 166

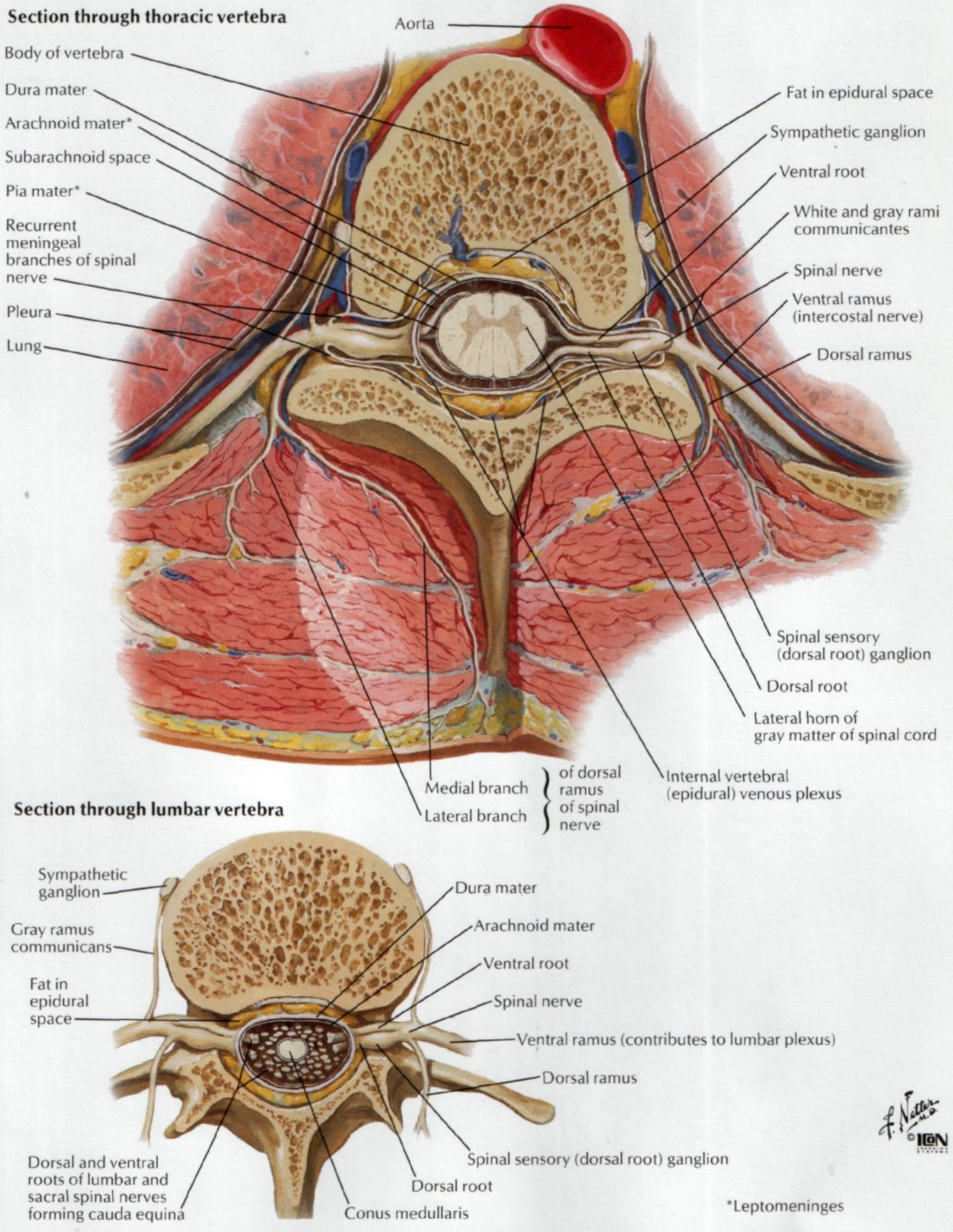

Arteries of Spinal Cord: Schema

SEE ALSO PLATE 131

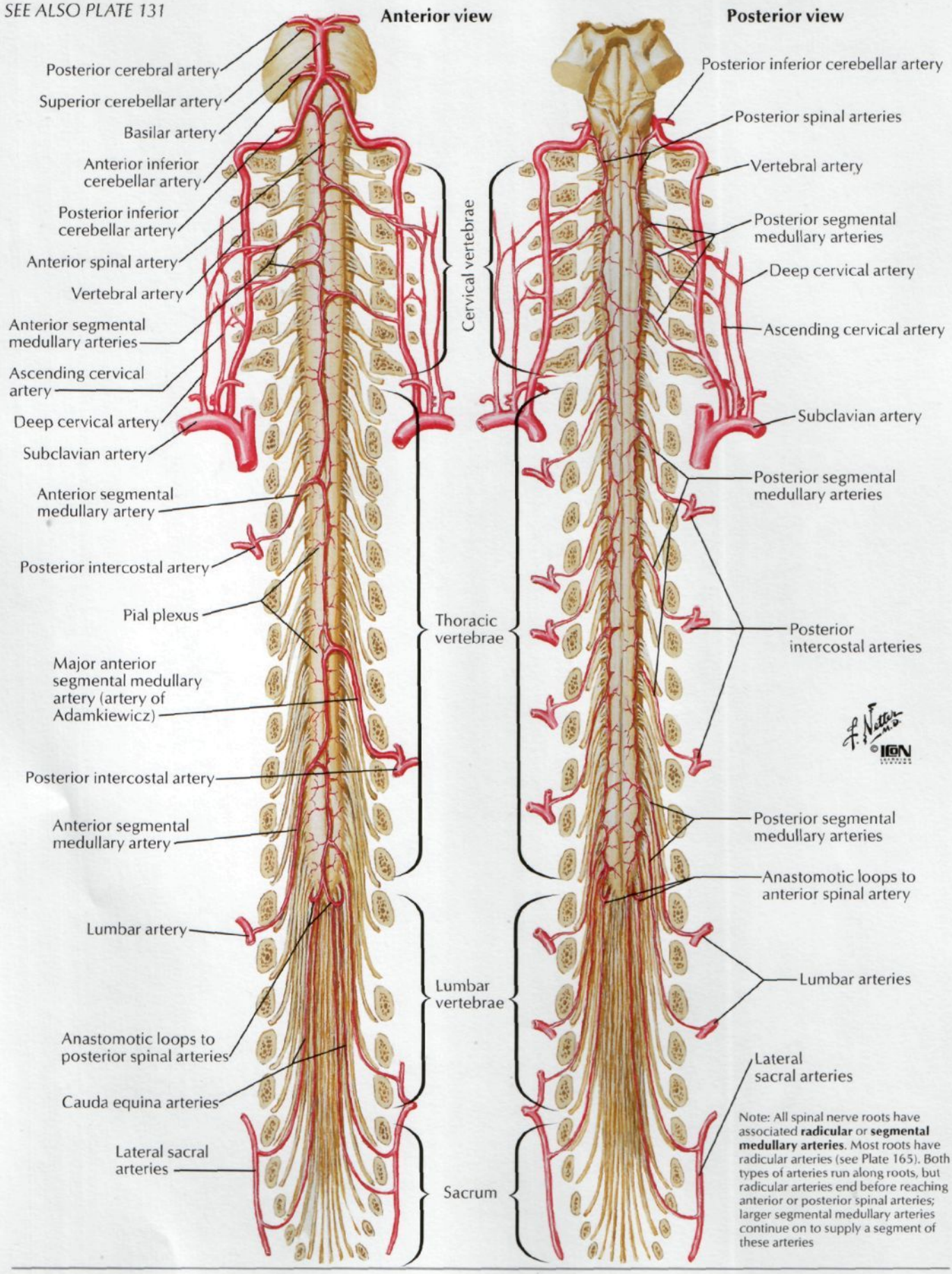

Note: All spinal nerve roots have associated **radicular** or **segmental medullary arteries**. Most roots have radicular arteries (see Plate 165). Both types of arteries run along roots, but radicular arteries end before reaching anterior or posterior spinal arteries; larger segmental medullary arteries continue on to supply a segment of these arteries

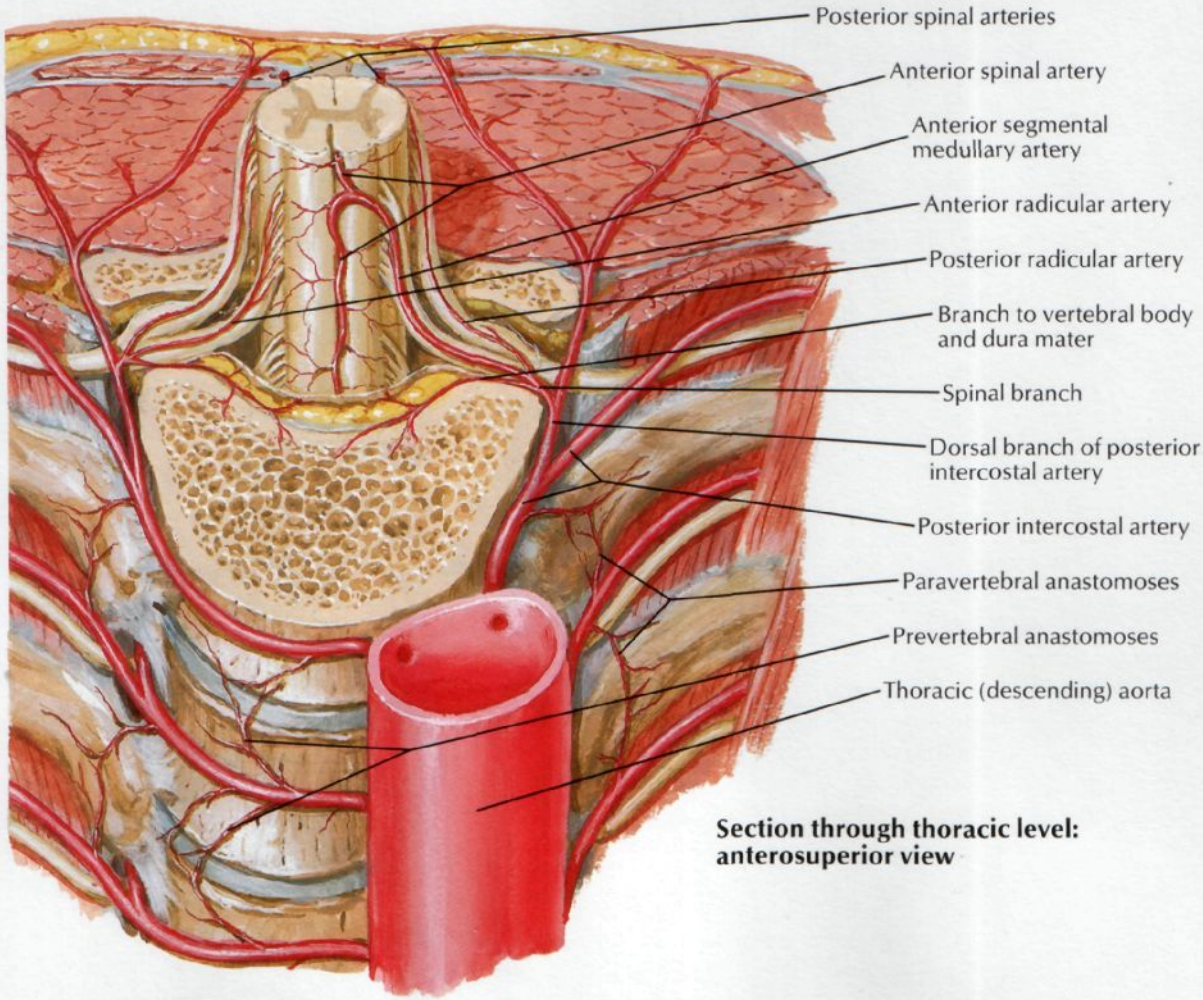

Section through thoracic level: anterosuperior view

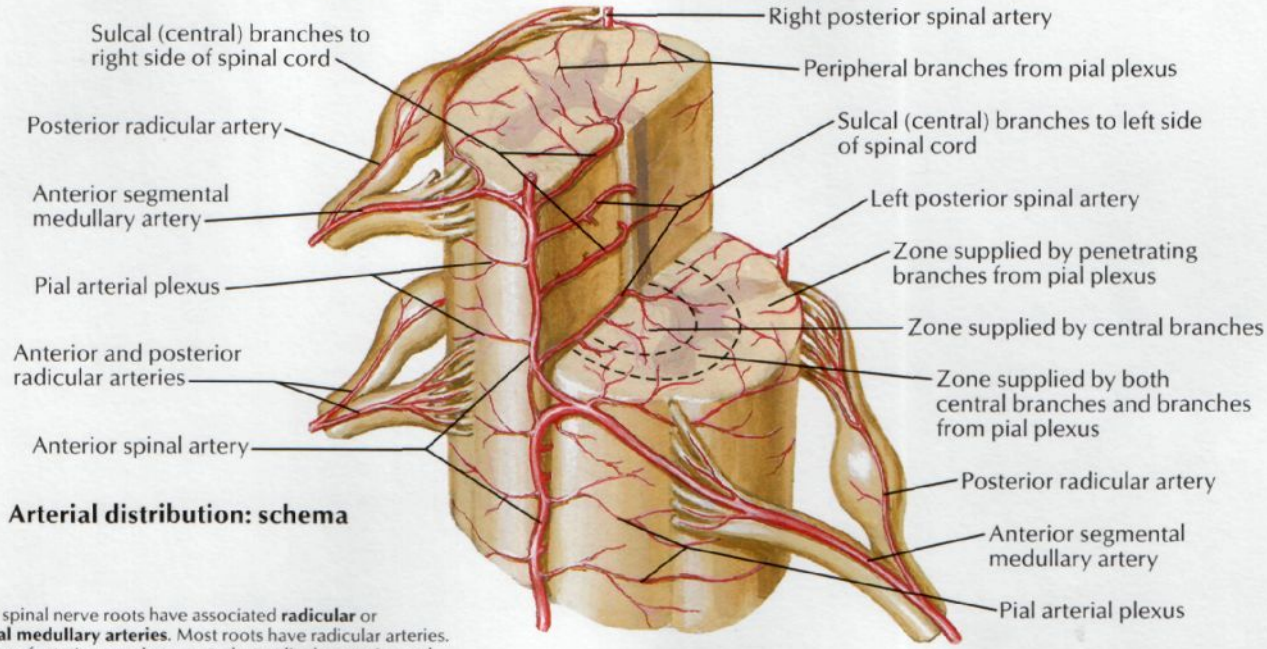

Arterial distribution: schema

Note: All spinal nerve roots have associated **radicular** or **segmental medullary arteries**. Most roots have radicular arteries. Both types of arteries run along roots, but radicular arteries end before reaching anterior or posterior spinal arteries; larger segmental medullary arteries continue on to supply a segment of these arteries

Veins of Spinal Cord and Vertebral Column

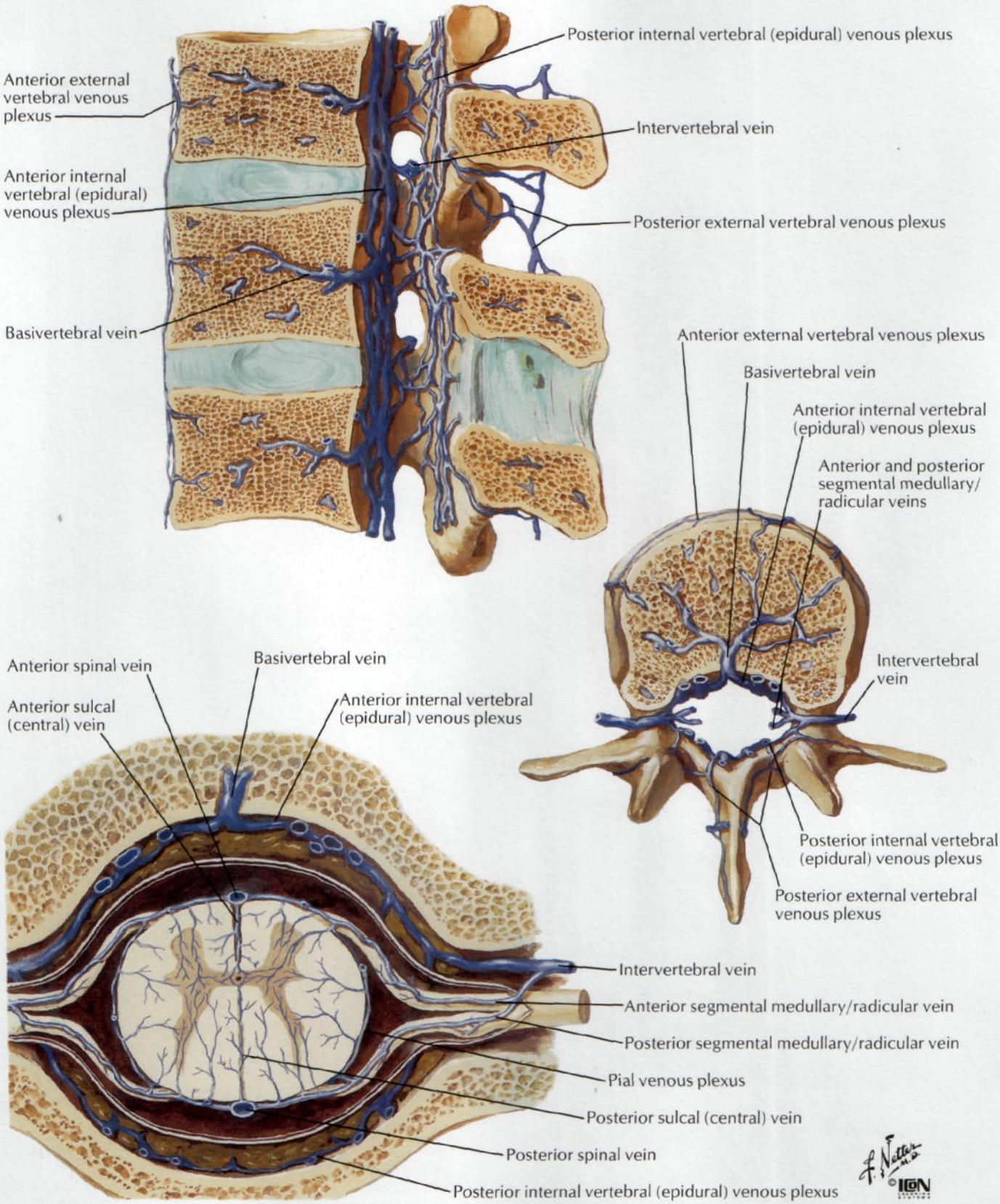

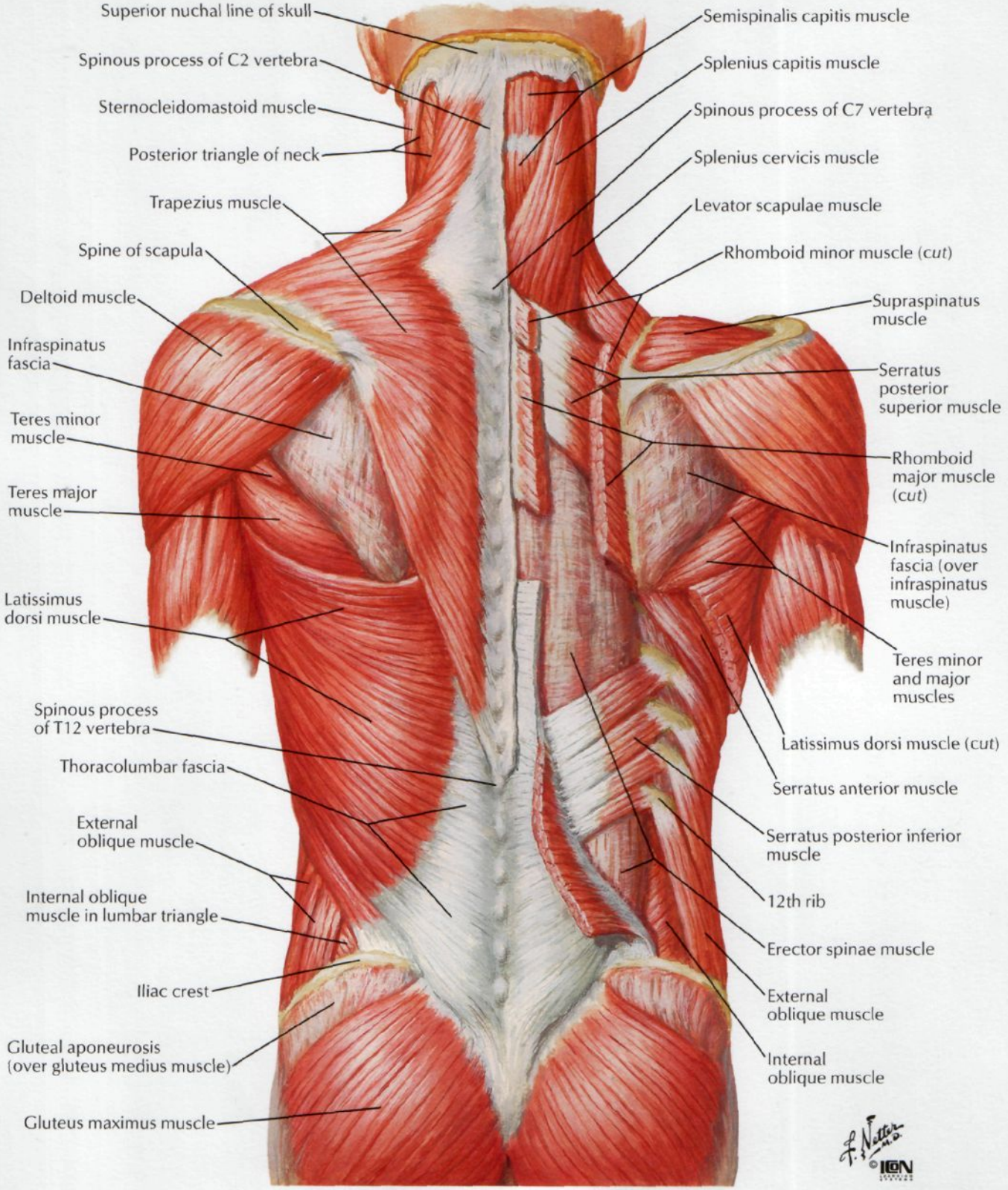
Superior nuchal line of skull
Spinous process of C2 vertebra
Sternocleidomastoid muscle
Posterior triangle of neck
Trapezius muscle
Spine of scapula
Deltoid muscle
Infraspinatus fascia
Teres minor muscle
Teres major muscle
Latissimus dorsi muscle
Spinous process of T12 vertebra
Thoracolumbar fascia
External oblique muscle
Internal oblique muscle in lumbar triangle
Iliac crest
Gluteal aponeurosis (over gluteus medius muscle)
Gluteus maximus muscle
Semispinalis capitis muscle
Splenius capitis muscle
Spinous process of C7 vertebra
Splenius cervicis muscle
Levator scapulae muscle
Rhomboid minor muscle (cut)
Supraspinatus muscle
Serratus posterior superior muscle
Rhomboid major muscle (cut)
Infraspinatus fascia (over infraspinatus muscle)
Teres minor and major muscles
Latissimus dorsi muscle (cut)
Serratus anterior muscle
Serratus posterior inferior muscle
12th rib
Erector spinae muscle
External oblique muscle
Internal oblique muscle

Muscles of Back: Intermediate Layers

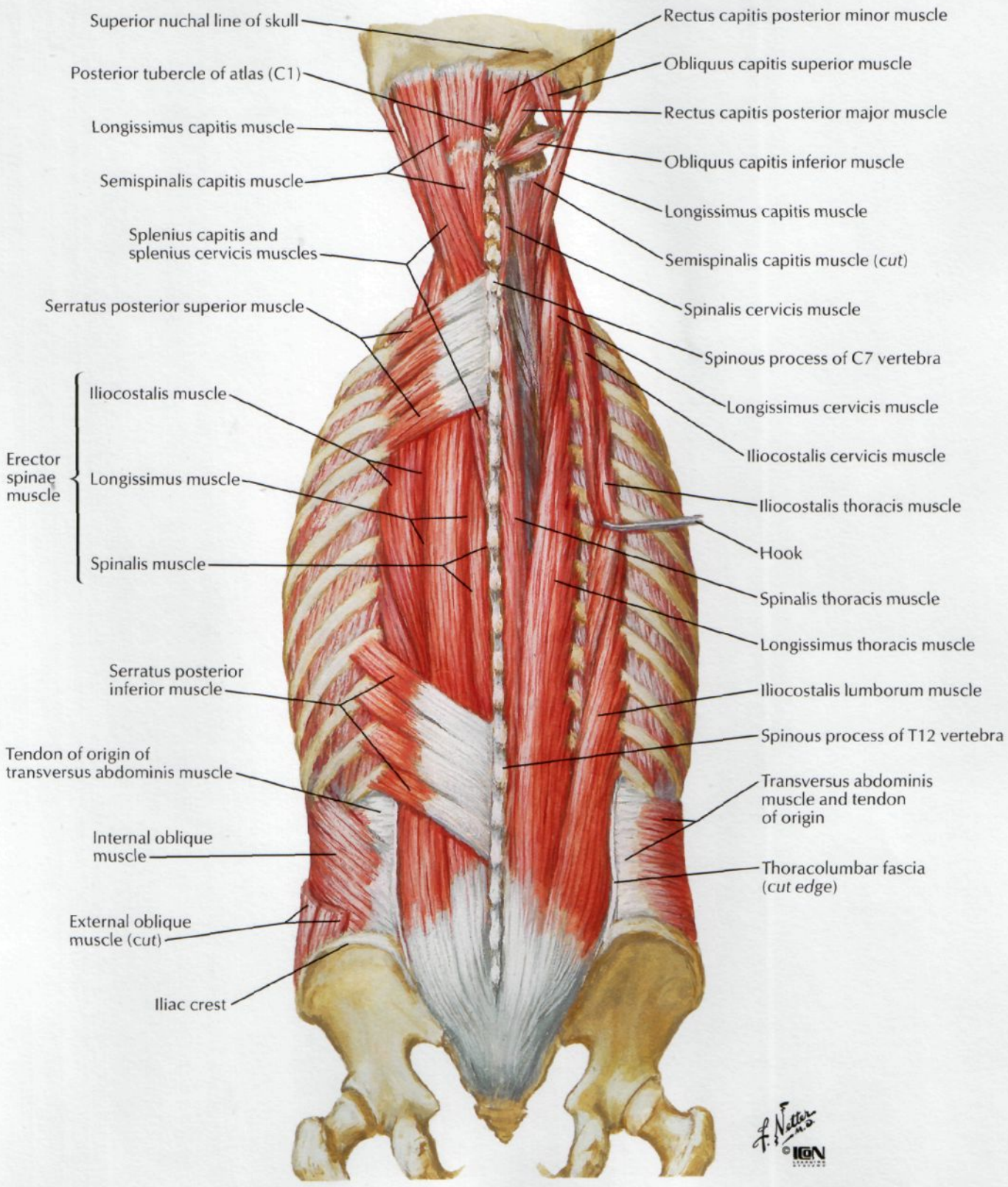

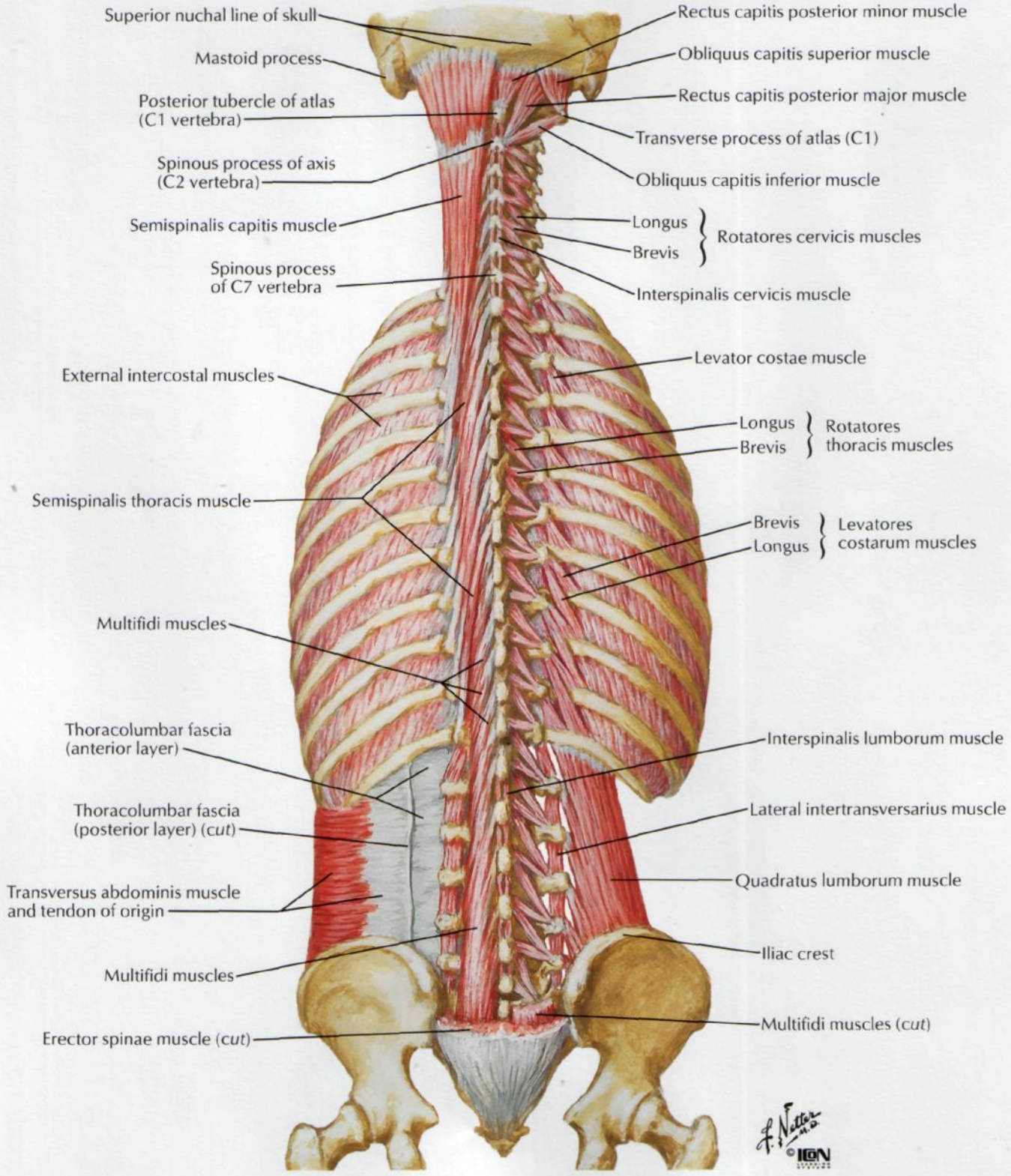
Superior nuchal line of skull
Mastoid process
Posterior tubercle of atlas (C1 vertebra)
Spinous process of axis (C2 vertebra)
Semispinalis capitis muscle
Spinous process of C7 vertebra
External intercostal muscles
Semispinalis thoracis muscle
Multifidi muscles
Thoracolumbar fascia (anterior layer)
Thoracolumbar fascia (posterior layer) (cut)
Transversus abdominis muscle and tendon of origin
Multifidi muscles
Erector spinae muscle (cut)
Rectus capitis posterior minor muscle
Obliquus capitis superior muscle
Rectus capitis posterior major muscle
Transverse process of atlas (C1)
Obliquus capitis inferior muscle
Longus
Brevis
Rotatores cervicis muscles
Interspinalis cervicis muscle
Levator costae muscle
Longus
Brevis
Rotatores thoracis muscles
Brevis
Longus
Levatores costarum muscles
Interspinalis lumborum muscle
Lateral intertransversarius muscle
Quadratus lumborum muscle
Iliac crest
Multifidi muscles (cut)

Nerves of Back

SEE ALSO PLATES 173, 187, 246, 250

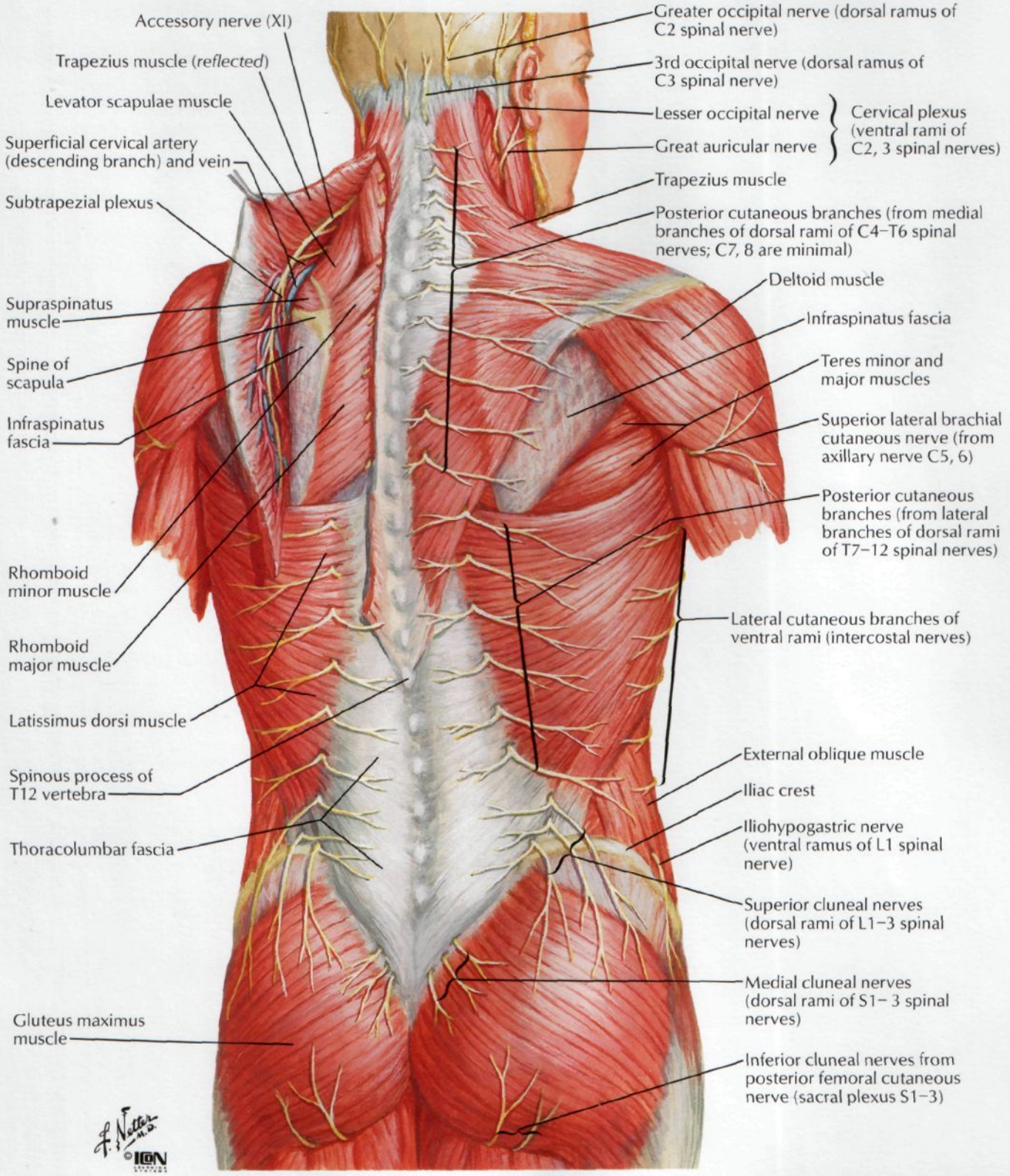

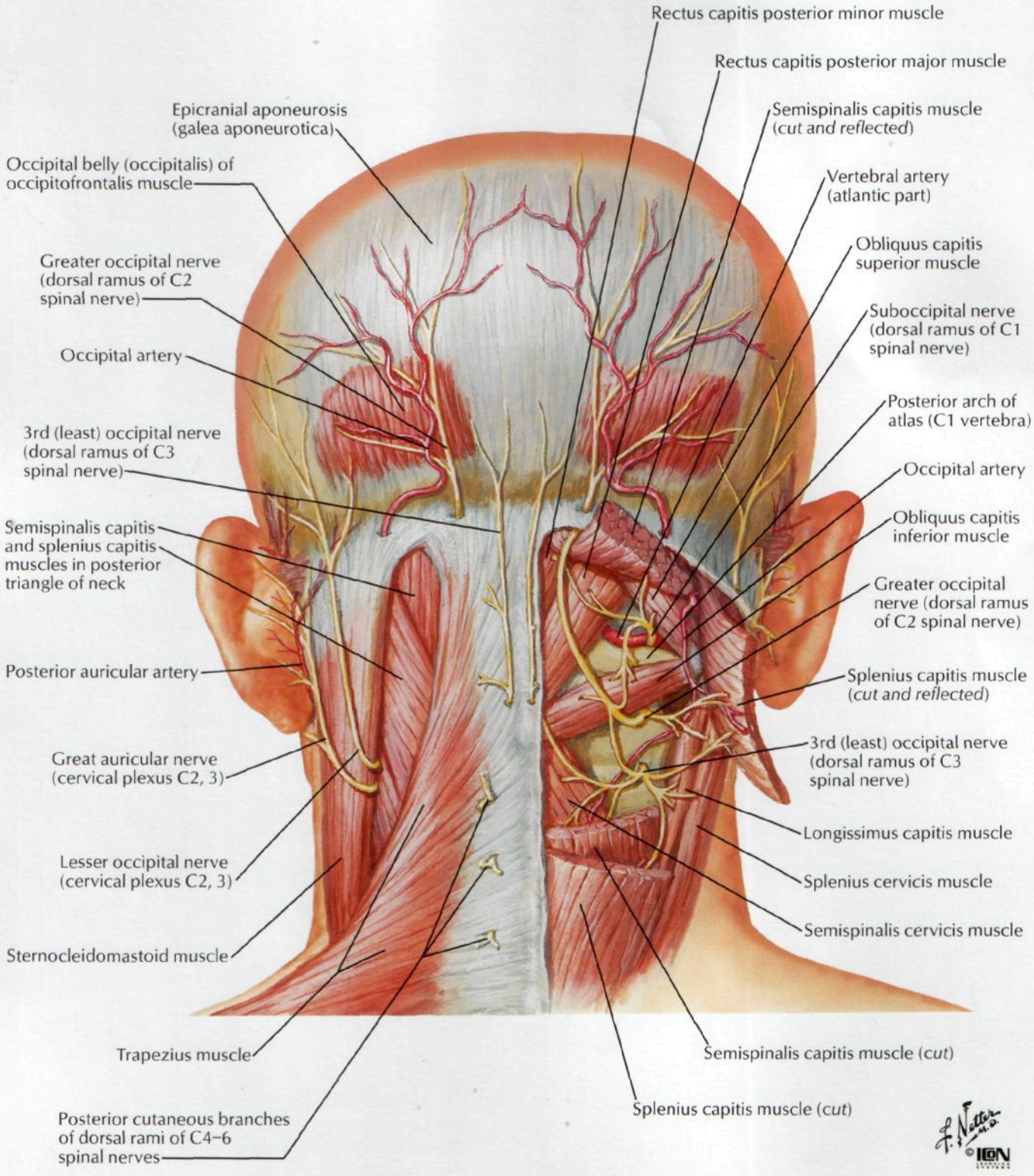
Rectus capitis posterior minor muscle
Rectus capitis posterior major muscle
Epicranial aponeurosis (galea aponeurotica)
Semispinalis capitis muscle (cut and reflected)
Occipital belly (occipitalis) of occipitofrontalis muscle
Vertebral artery (atlantic part)
Obliquus capitis superior muscle
Greater occipital nerve (dorsal ramus of C2 spinal nerve)
Suboccipital nerve (dorsal ramus of C1 spinal nerve)
Occipital artery
Posterior arch of atlas (C1 vertebra)
3rd (least) occipital nerve (dorsal ramus of C3 spinal nerve)
Occipital artery
Semispinalis capitis and splenius capitis muscles in posterior triangle of neck
Obliquus capitis inferior muscle
Greater occipital nerve (dorsal ramus of C2 spinal nerve)
Posterior auricular artery
Splenius capitis muscle (cut and reflected)
Great auricular nerve (cervical plexus C2, 3)
3rd (least) occipital nerve (dorsal ramus of C3 spinal nerve)
Longissimus capitis muscle
Lesser occipital nerve (cervical plexus C2, 3)
Splenius cervicis muscle
Semispinalis cervicis muscle
Sternocleidomastoid muscle
Trapezius muscle
Semispinalis capitis muscle (cut)
Splenius capitis muscle (cut)
Posterior cutaneous branches of dorsal rami of C4–6 spinal nerves

Lumbar Region of Back: Cross Section

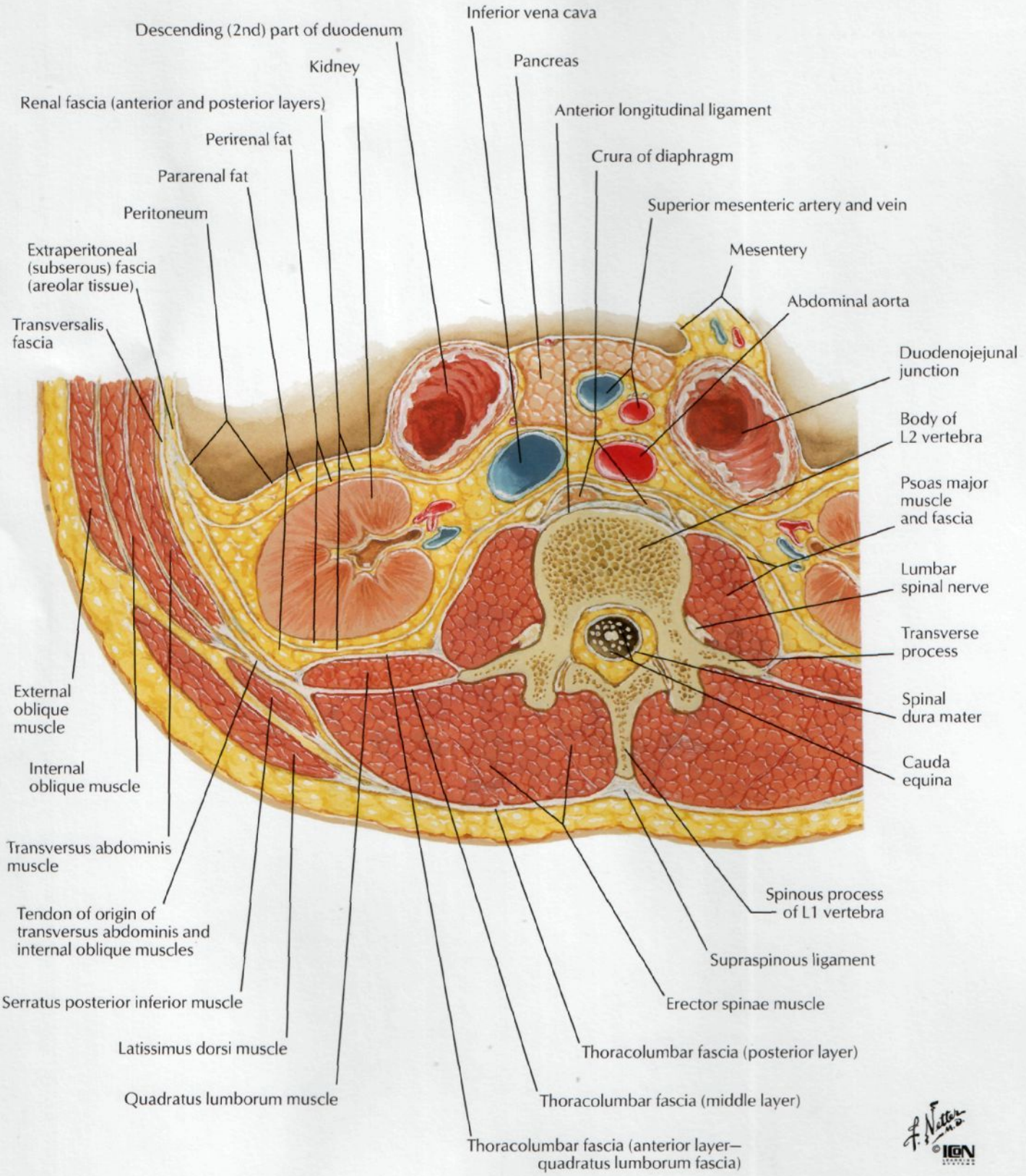

Typical Thoracic Spinal Nerve

SEE ALSO PLATES 187, 250

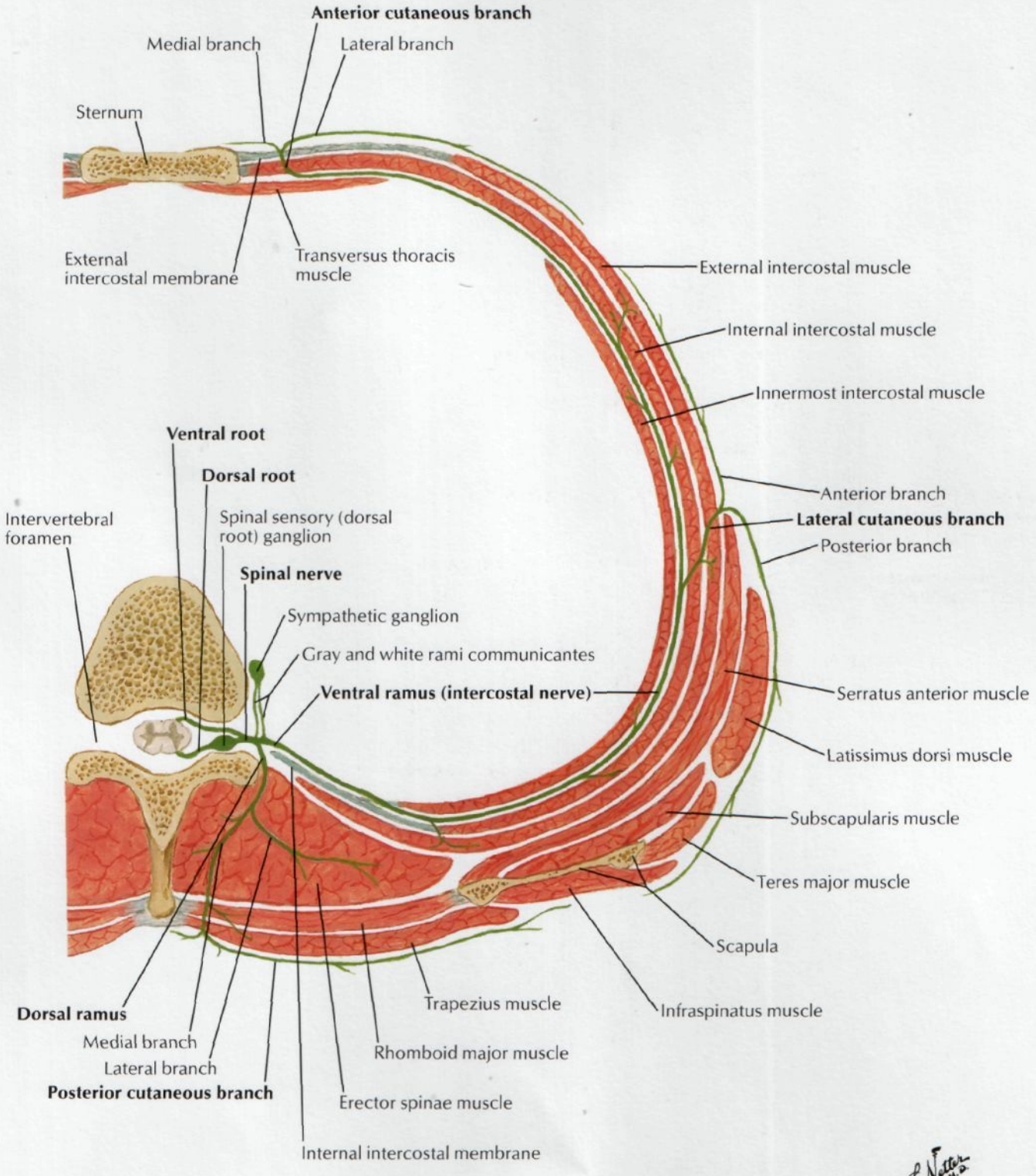

Note: In lower thoracic region, lateral branch of dorsal ramus is longer, motor and cutaneous; medial branch is shorter and motor only

Section III
THORAX

SURFACE ANATOMY
Plate 174
174. Thorax

MAMMARY GLAND
Plates 175–177
175. Mammary Gland
176. Arteries of Mammary Gland
177. Lymph Vessels and Nodes of Mammary Gland

BODY WALL
Plates 178–191
178. Bony Framework of Thorax
179. Ribs and Sternocostal Joints
180. Costovertebral Joints
181. Cervical Ribs and Related Anomalies
182. Anterior Thoracic Wall
183. Anterior Thoracic Wall (*continued*)
184. Anterior Thoracic Wall: Internal View
185. Posterior and Lateral Thoracic Walls
186. Posterior Thoracic Wall
187. Intercostal Nerves and Arteries
188. Diaphragm: Thoracic Surface
189. Diaphragm: Abdominal Surface
190. Phrenic Nerve
191. Muscles of Respiration

LUNGS
Plates 192–206
192. Topography of Lungs: Anterior View
193. Topography of Lungs: Posterior View
194. Lungs In Situ: Anterior View
195. Lungs: Medial Views
196. Bronchopulmonary Segments
197. Bronchopulmonary Segments (*continued*)
198. Trachea and Major Bronchi
199. Nomenclature of Bronchi: Schema

200. Intrapulmonary Airways: Schema
201. Intrapulmonary Blood Circulation: Schema
202. Great Vessels of Superior Mediastinum
203. Bronchial Arteries and Veins
204. Lymph Vessels and Nodes of Lung
205. Autonomic Nerves in Thorax
206. Innervation of Tracheobronchial Tree: Schema

HEART
Plates 207–225

207. Heart In Situ
208. Heart: Anterior Exposure
209. Radiograph of Chest
210. Heart: Base and Diaphragmatic Surfaces
211. Pericardial Sac
212. Coronary Arteries and Cardiac Veins
213. Coronary Arteries and Cardiac Veins: Variations
214. Coronary Arteries: Arteriographic Views
215. Coronary Arteries: Arteriographic Views (*continued*)
216. Right Atrium and Ventricle
217. Left Atrium and Ventricle
218. Valves and Fibrous Skeleton of Heart
219. Valves and Fibrous Skeleton of Heart (*continued*)
220. Atria, Ventricles and Interventricular Septum
221. Conducting System of Heart
222. Nerves of Heart
223. Innervation of Heart: Schema
224. Innervation of Blood Vessels: Schema
225. Prenatal and Postnatal Circulation

MEDIASTINUM
Plates 226–237

226. Mediastinum: Right Lateral View
227. Mediastinum: Left Lateral View
228. Esophagus In Situ
229. Topography and Constrictions of Esophagus
230. Musculature of Esophagus
231. Pharyngoesophageal Junction
232. Esophagogastric Junction
233. Arteries of Esophagus
234. Veins of Esophagus
235. Lymph Vessels and Nodes of Esophagus
236. Nerves of Esophagus
237. Mediastinum: Cross Section

REGIONAL SCANS
Plate 238

238. Chest Scans: Axial CT Images

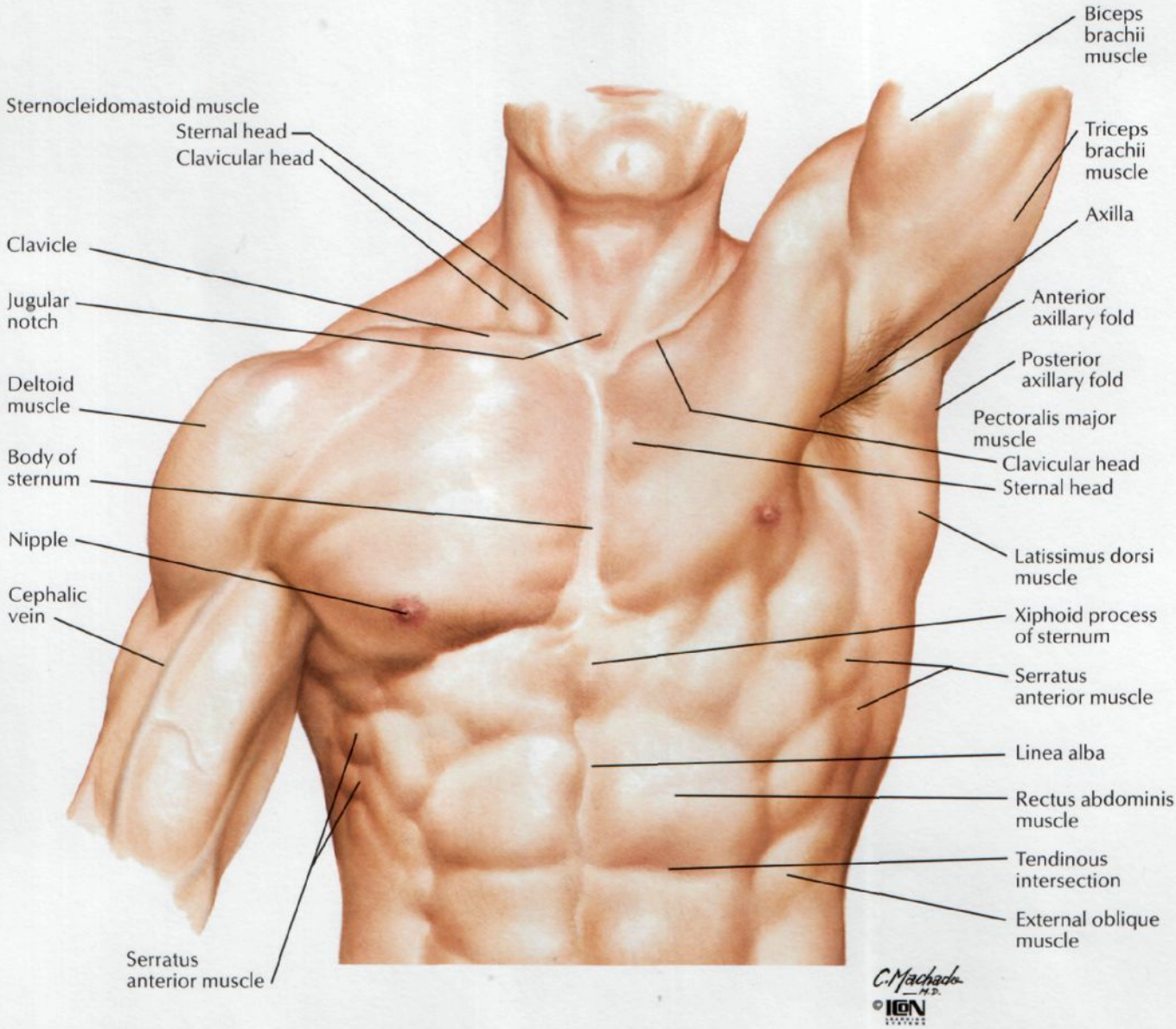
Biceps brachii muscle
Sternocleidomastoid muscle
Sternal head
Clavicular head
Triceps brachii muscle
Axilla
Clavicle
Jugular notch
Anterior axillary fold
Posterior axillary fold
Deltoid muscle
Pectoralis major muscle
Clavicular head
Body of sternum
Sternal head
Nipple
Latissimus dorsi muscle
Cephalic vein
Xiphoid process of sternum
Serratus anterior muscle
Linea alba
Rectus abdominis muscle
Tendinous intersection
External oblique muscle
Serratus anterior muscle
C. Machado M.D.
©ICON

Mammary Gland

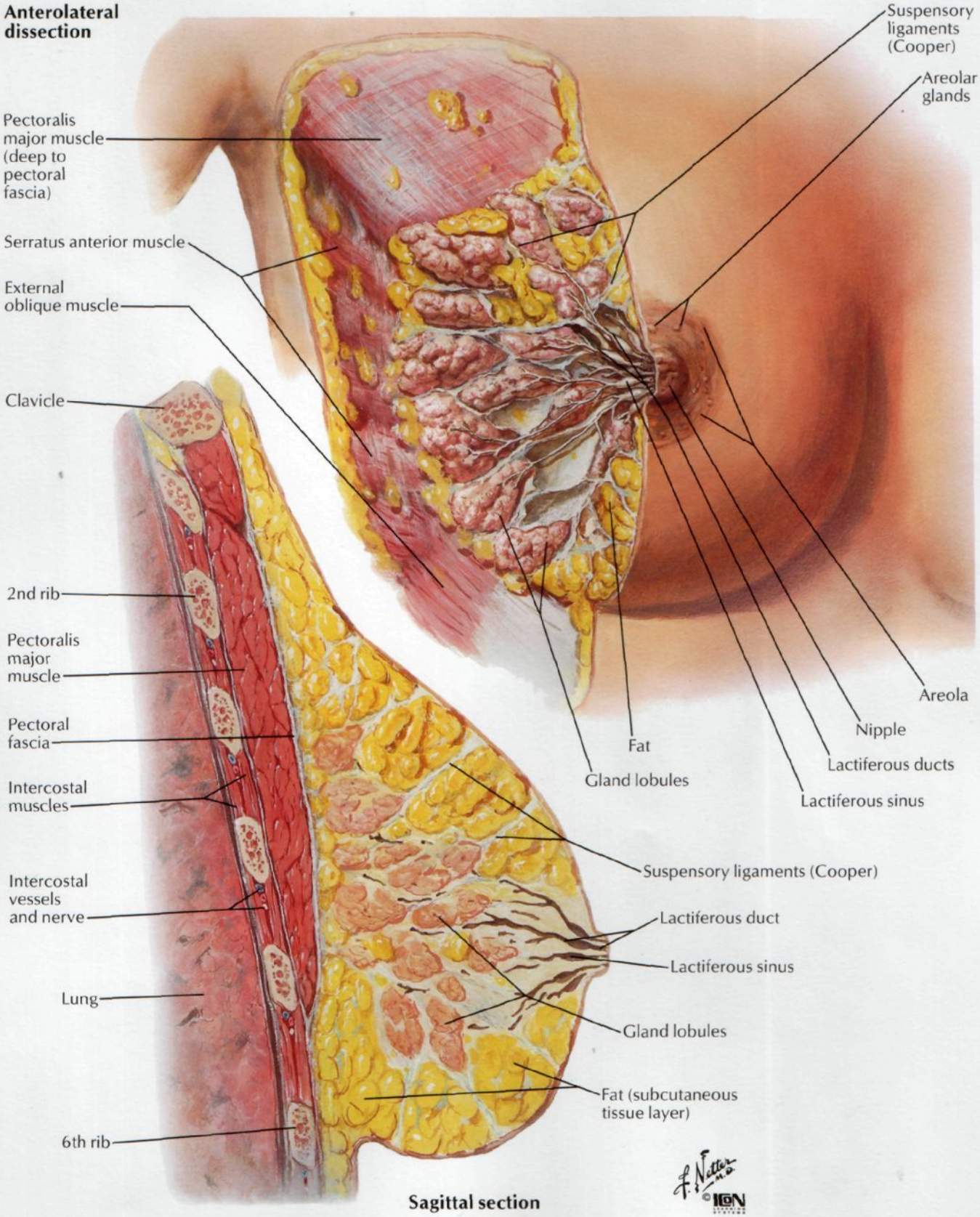

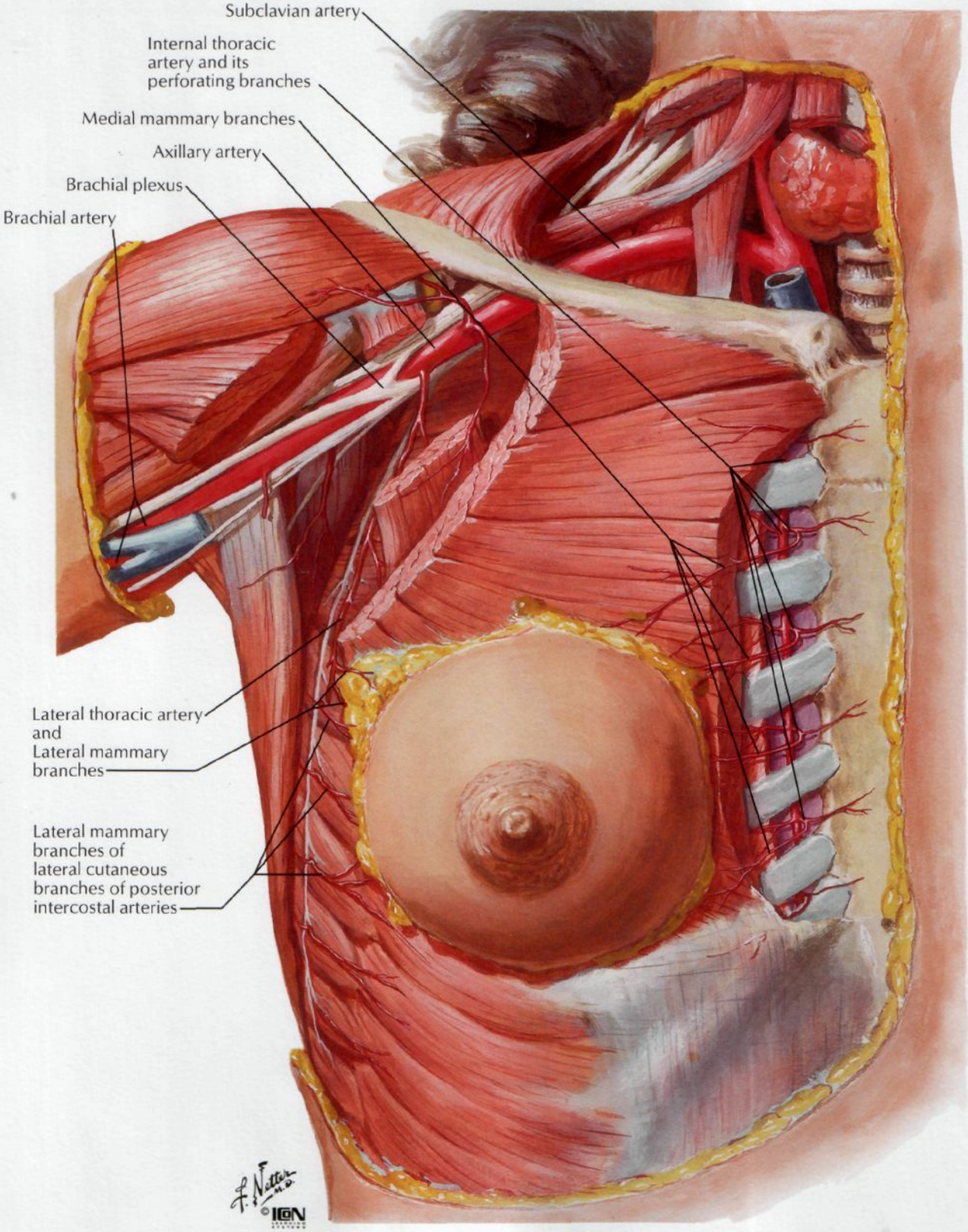
Subclavian artery
Internal thoracic artery and its perforating branches
Medial mammary branches
Axillary artery
Brachial plexus
Brachial artery
Lateral thoracic artery and Lateral mammary branches
Lateral mammary branches of lateral cutaneous branches of posterior intercostal arteries
F. Netter M.D.
©IGN

Lymph Vessels and Nodes of Mammary Gland

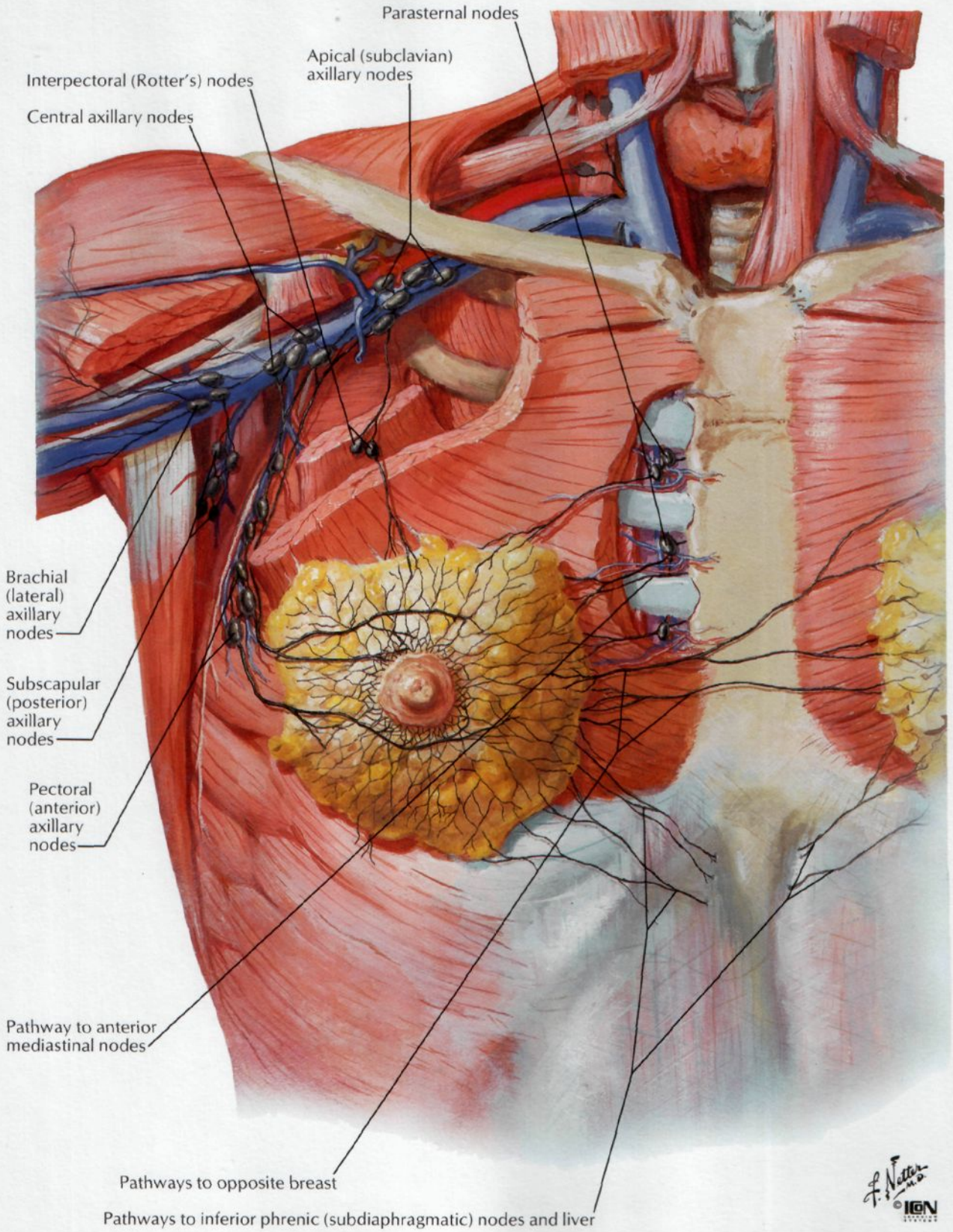

SEE ALSO PLATE 240

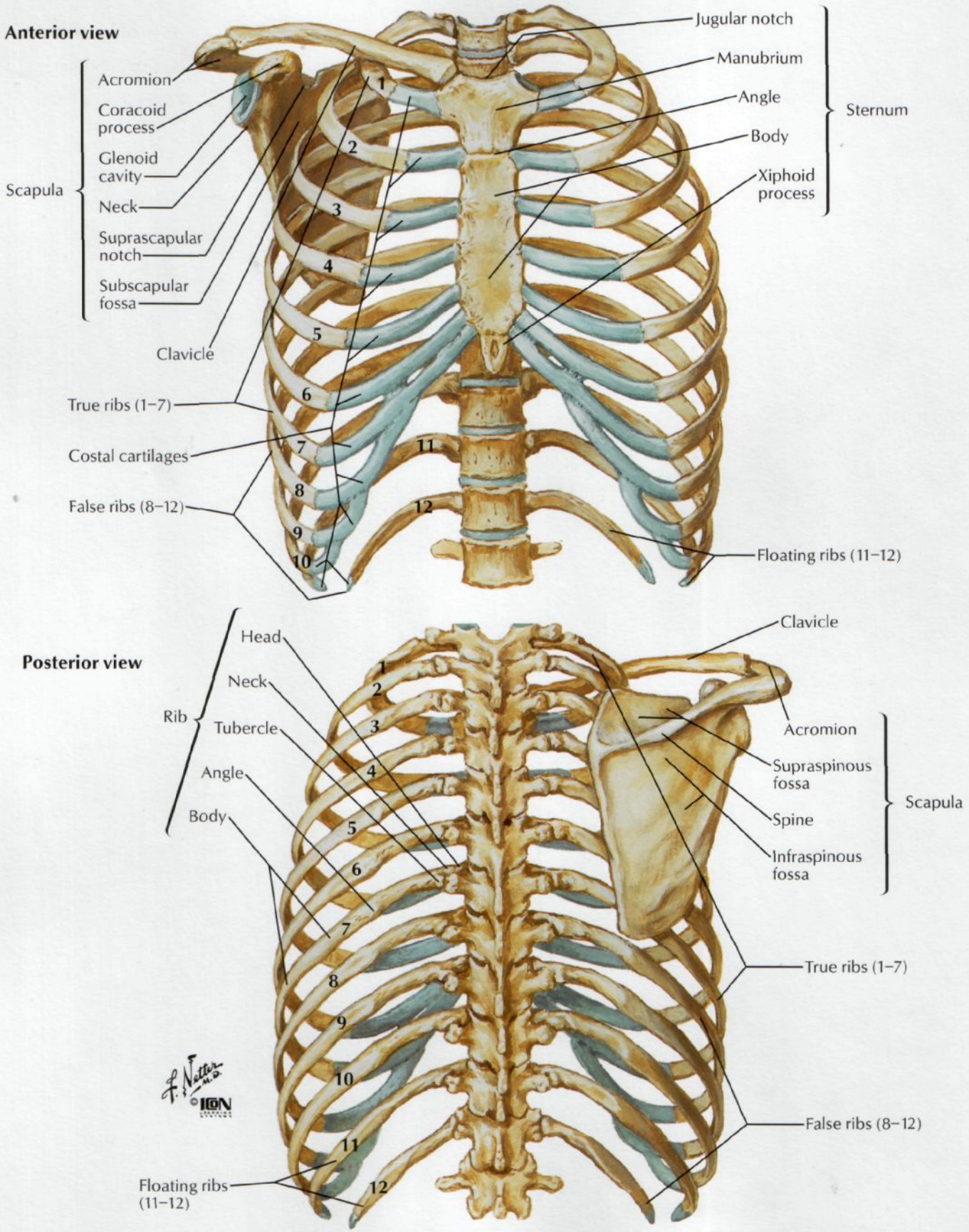

Ribs and Sternocostal Joints

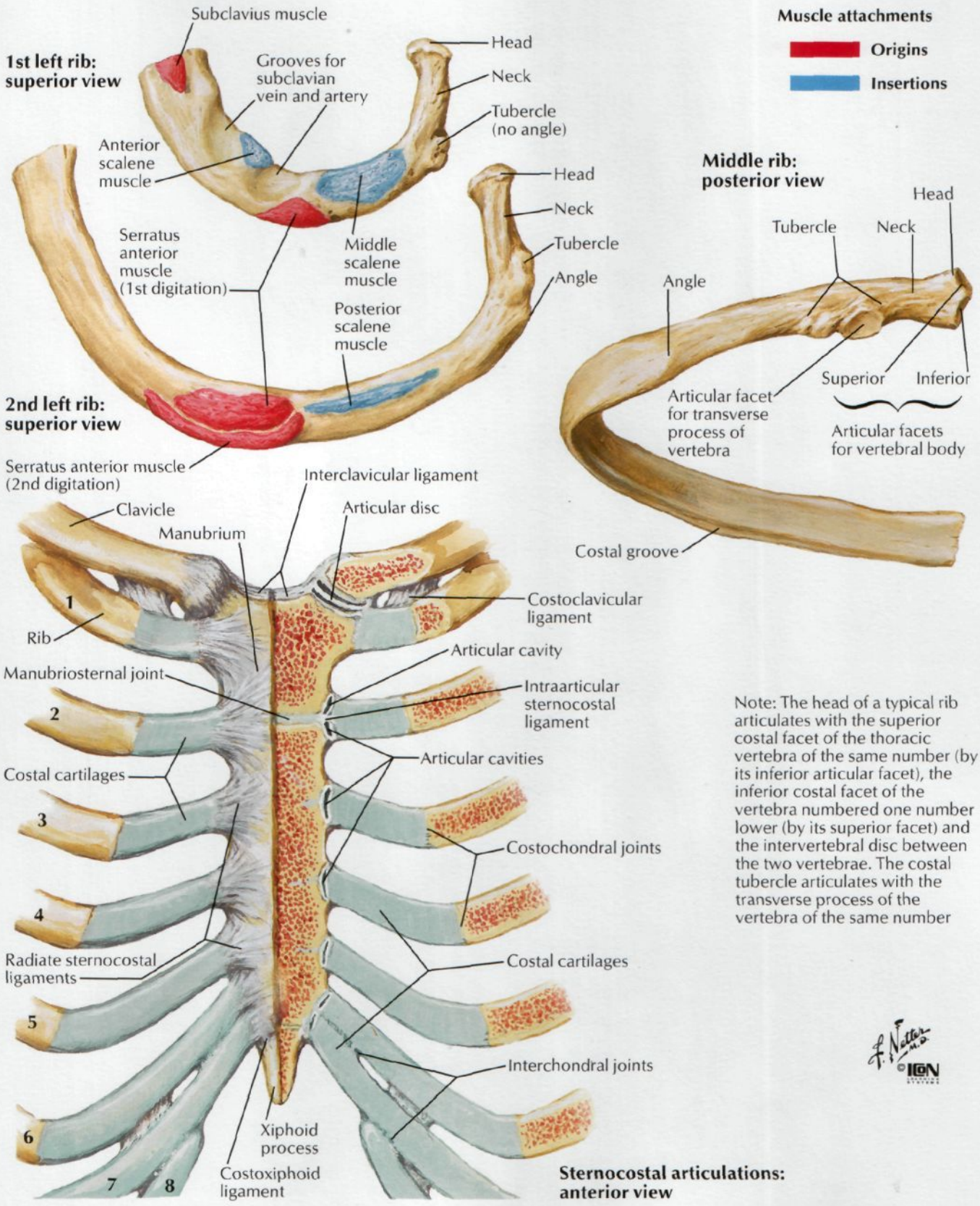

Note: The head of a typical rib articulates with the superior costal facet of the thoracic vertebra of the same number (by its inferior articular facet), the inferior costal facet of the vertebra numbered one number lower (by its superior facet) and the intervertebral disc between the two vertebrae. The costal tubercle articulates with the transverse process of the vertebra of the same number

SEE ALSO PLATE 147

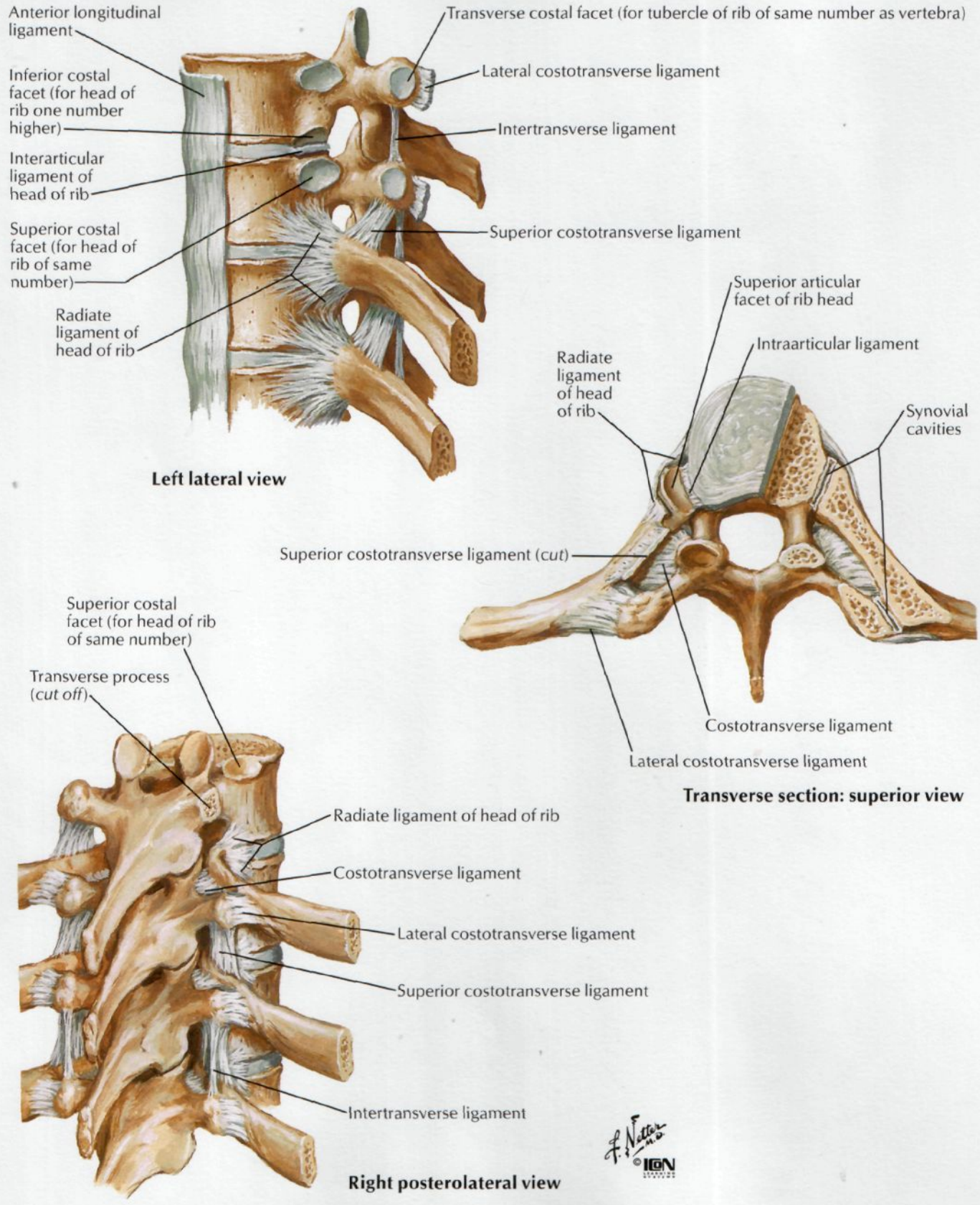

Cervical Ribs and Related Anomalies

SEE ALSO PLATES 29, 412, 413

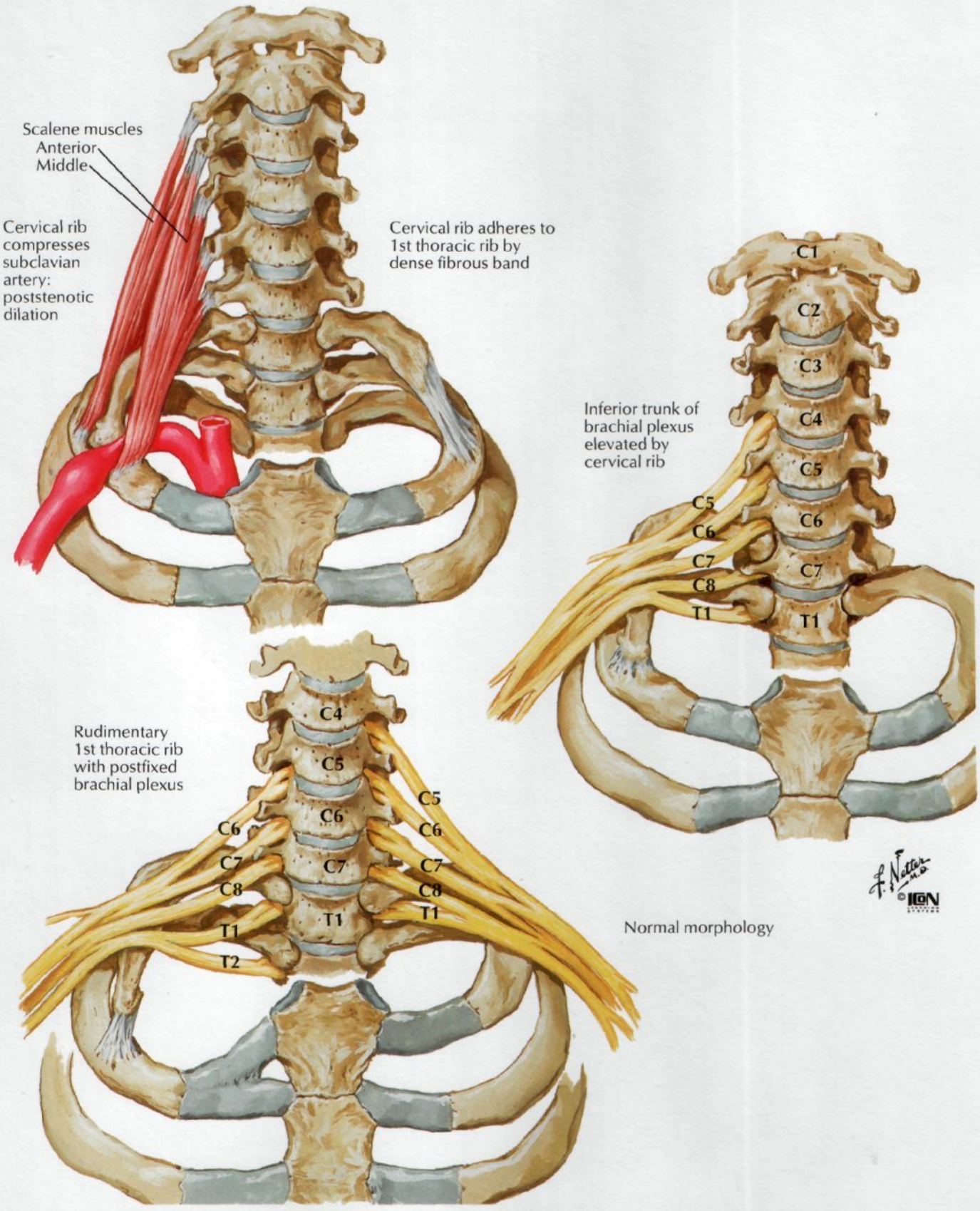

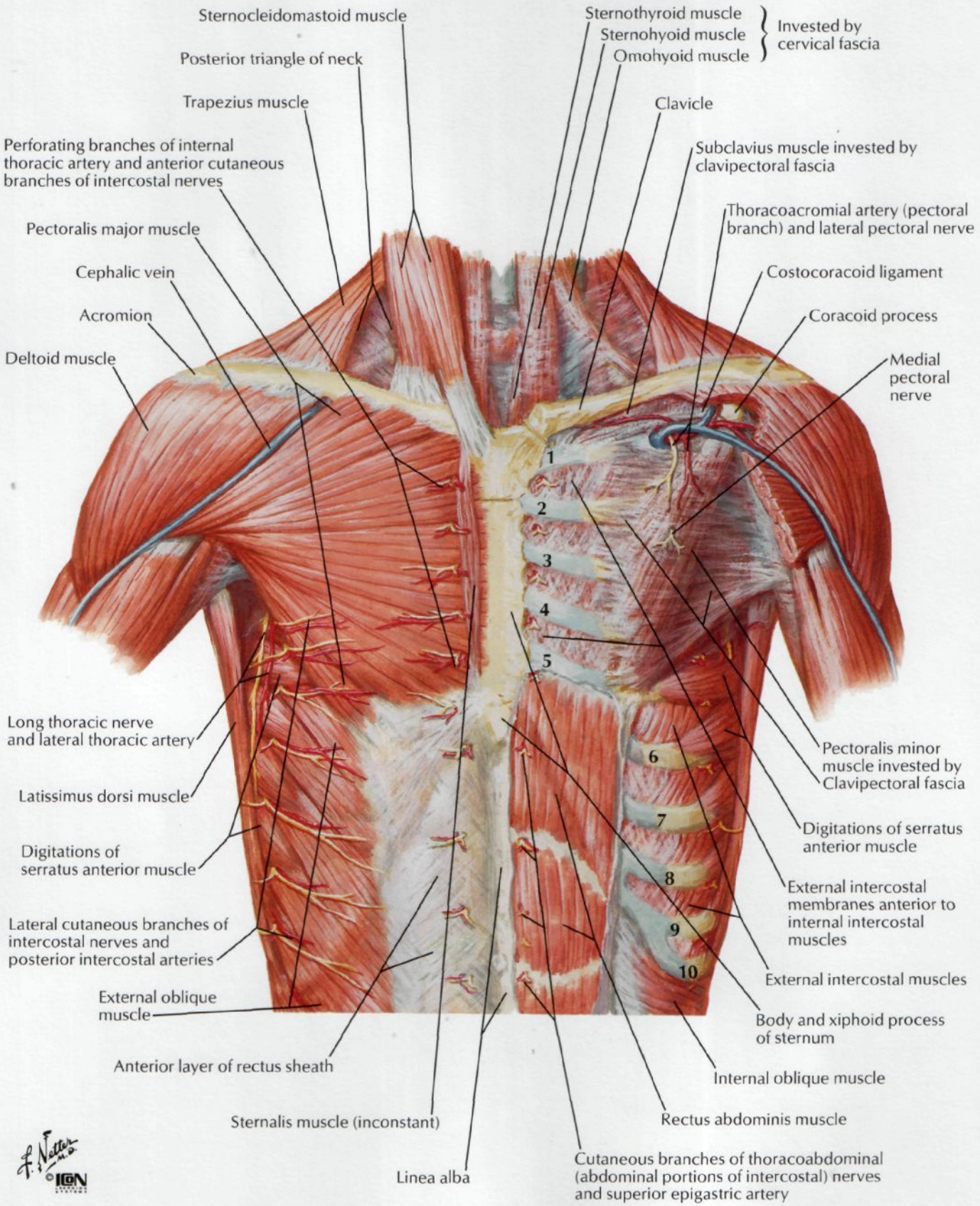
Sternocleidomastoid muscle
Posterior triangle of neck
Trapezius muscle
Perforating branches of internal thoracic artery and anterior cutaneous branches of intercostal nerves
Pectoralis major muscle
Cephalic vein
Acromion
Deltoid muscle
Sternothyroid muscle
Sternohyoid muscle
Omohyoid muscle
Invested by cervical fascia
Clavicle
Subclavius muscle invested by clavipectoral fascia
Thoracoacromial artery (pectoral branch) and lateral pectoral nerve
Costocoracoid ligament
Coracoid process
Medial pectoral nerve
1
2
3
4
5
6
7
8
9
10
Long thoracic nerve and lateral thoracic artery
Latissimus dorsi muscle
Digitations of serratus anterior muscle
Lateral cutaneous branches of intercostal nerves and posterior intercostal arteries
External oblique muscle
Anterior layer of rectus sheath
Sternalis muscle (inconstant)
Linea alba
Pectoralis minor muscle invested by Clavipectoral fascia
Digitations of serratus anterior muscle
External intercostal membranes anterior to internal intercostal muscles
External intercostal muscles
Body and xiphoid process of sternum
Internal oblique muscle
Rectus abdominis muscle
Cutaneous branches of thoracoabdominal (abdominal portions of intercostal) nerves and superior epigastric artery

Anterior Thoracic Wall (continued)

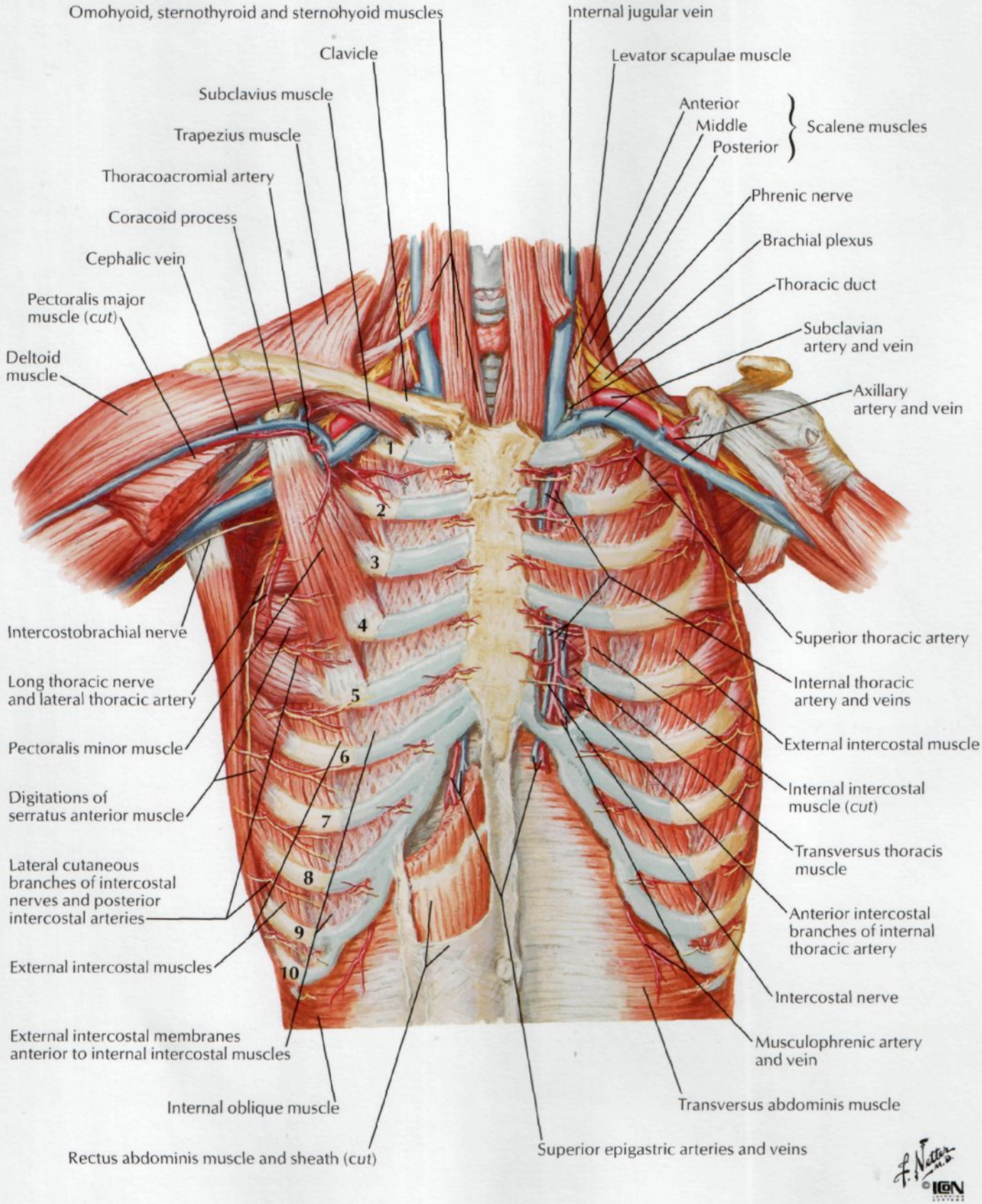

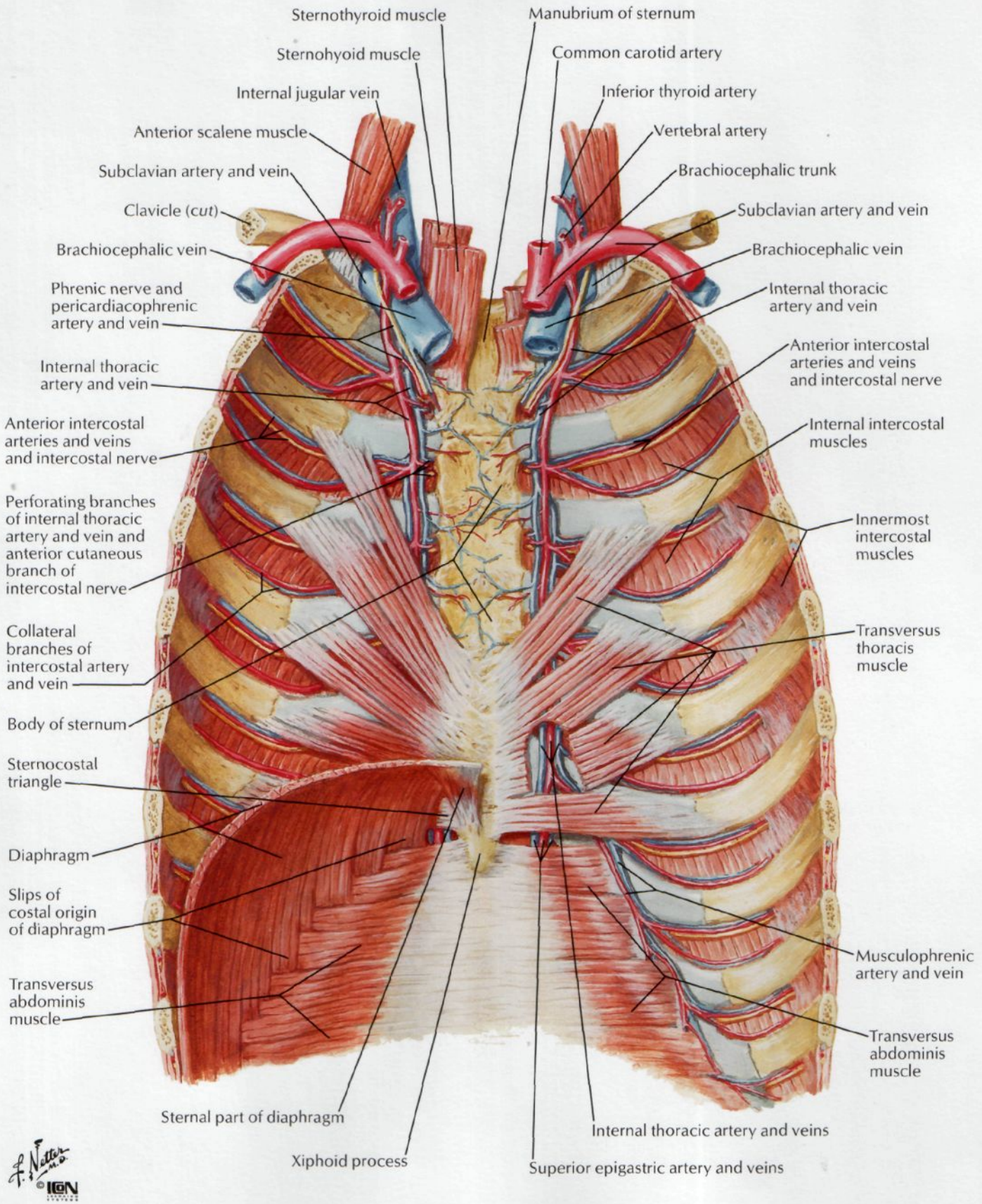
Sternothyroid muscle
Sternohyoid muscle
Internal jugular vein
Anterior scalene muscle
Subclavian artery and vein
Clavicle (cut)
Brachiocephalic vein
Phrenic nerve and pericardiacophrenic artery and vein
Internal thoracic artery and vein
Anterior intercostal arteries and veins and intercostal nerve
Perforating branches of internal thoracic artery and vein and anterior cutaneous branch of intercostal nerve
Collateral branches of intercostal artery and vein
Body of sternum
Sternocostal triangle
Diaphragm
Slips of costal origin of diaphragm
Transversus abdominis muscle
Sternal part of diaphragm
Xiphoid process
Manubrium of sternum
Common carotid artery
Inferior thyroid artery
Vertebral artery
Brachiocephalic trunk
Subclavian artery and vein
Brachiocephalic vein
Internal thoracic artery and vein
Anterior intercostal arteries and veins and intercostal nerve
Internal intercostal muscles
Innermost intercostal muscles
Transversus thoracis muscle
Musculophrenic artery and vein
Transversus abdominis muscle
Internal thoracic artery and veins
Superior epigastric artery and veins

Posterior and Lateral Thoracic Walls

SEE ALSO PLATES 167–169

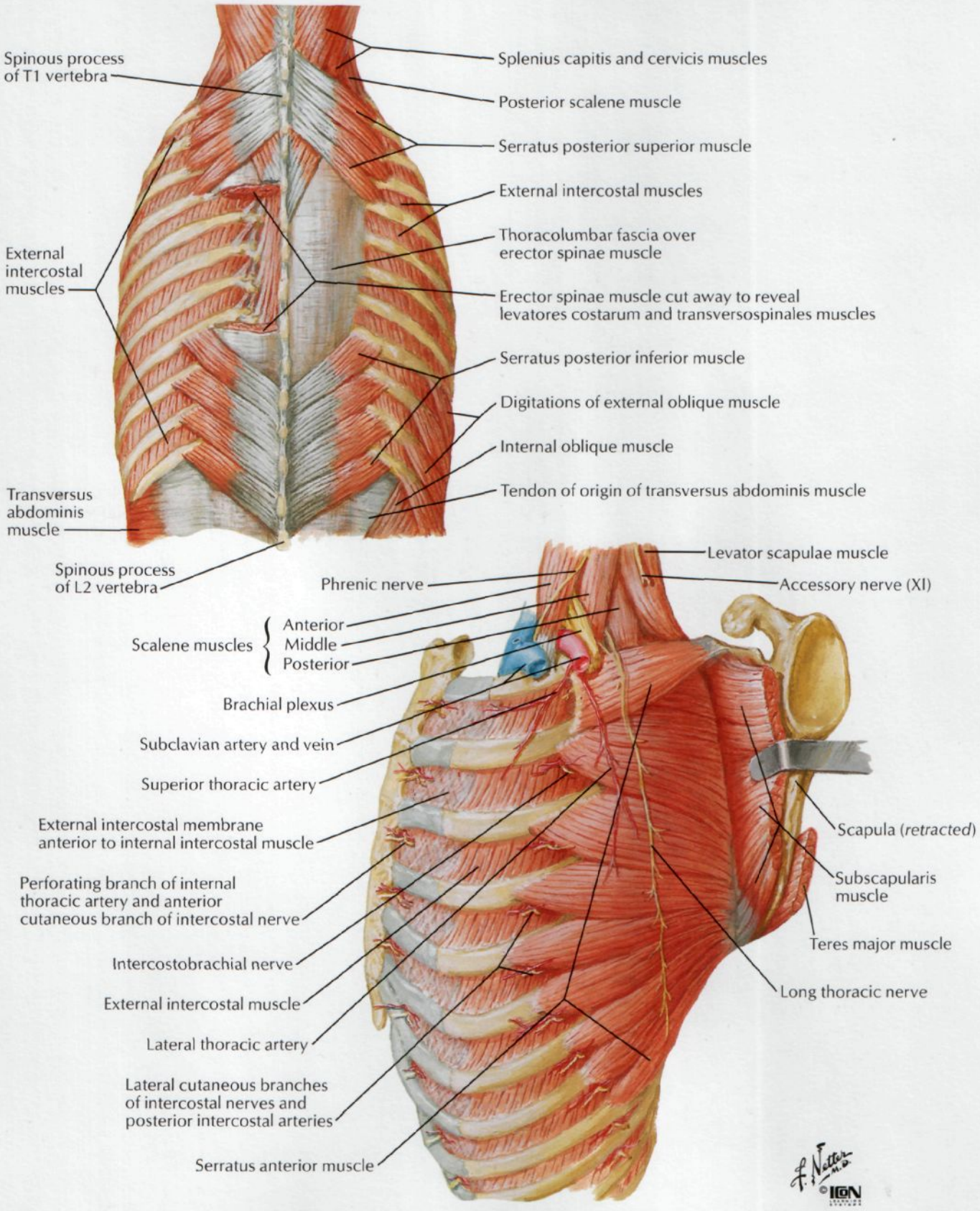

Posterior Thoracic Wall

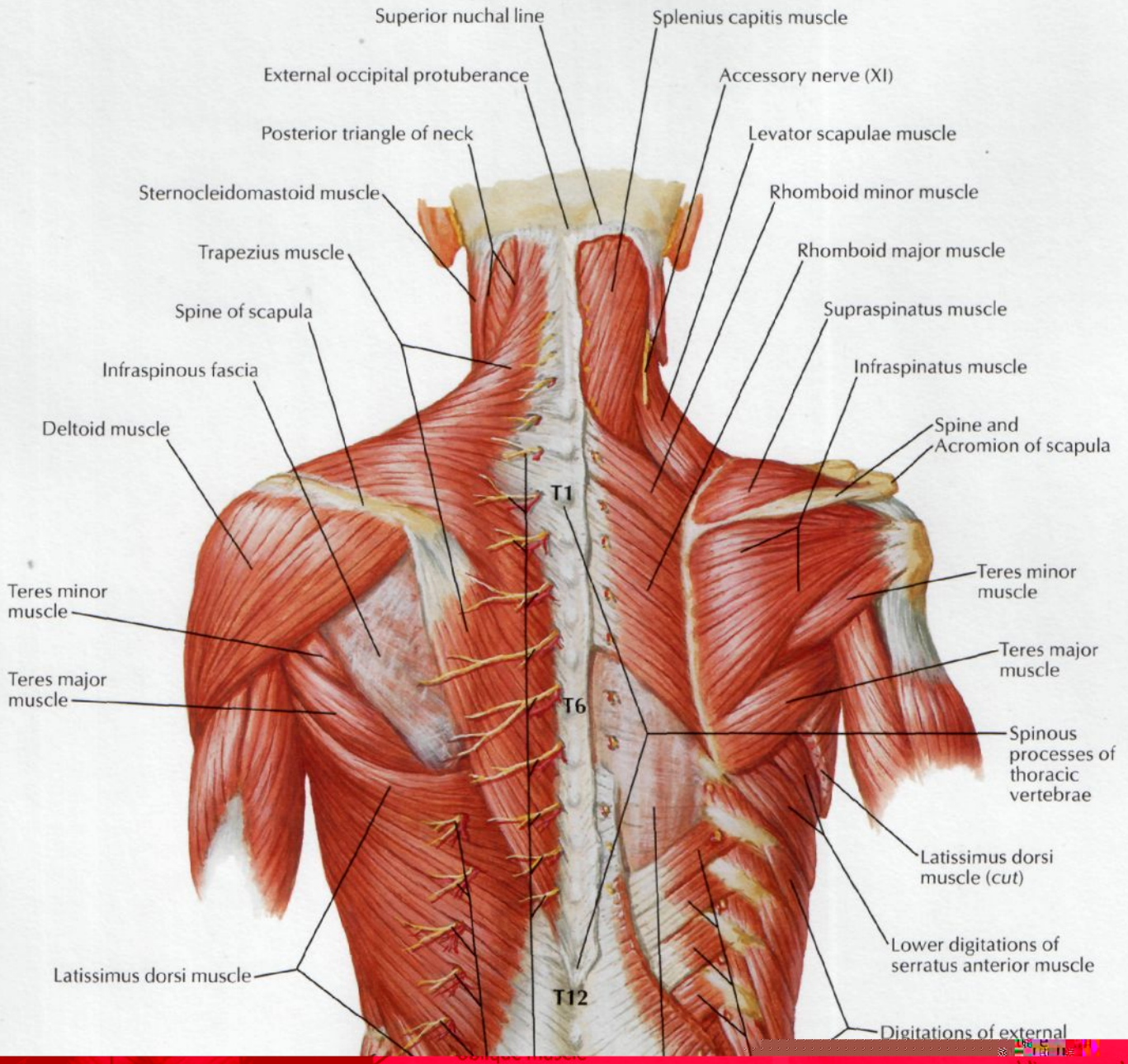

Intercostal Nerves and Arteries

SEE ALSO PLATES 173, 250

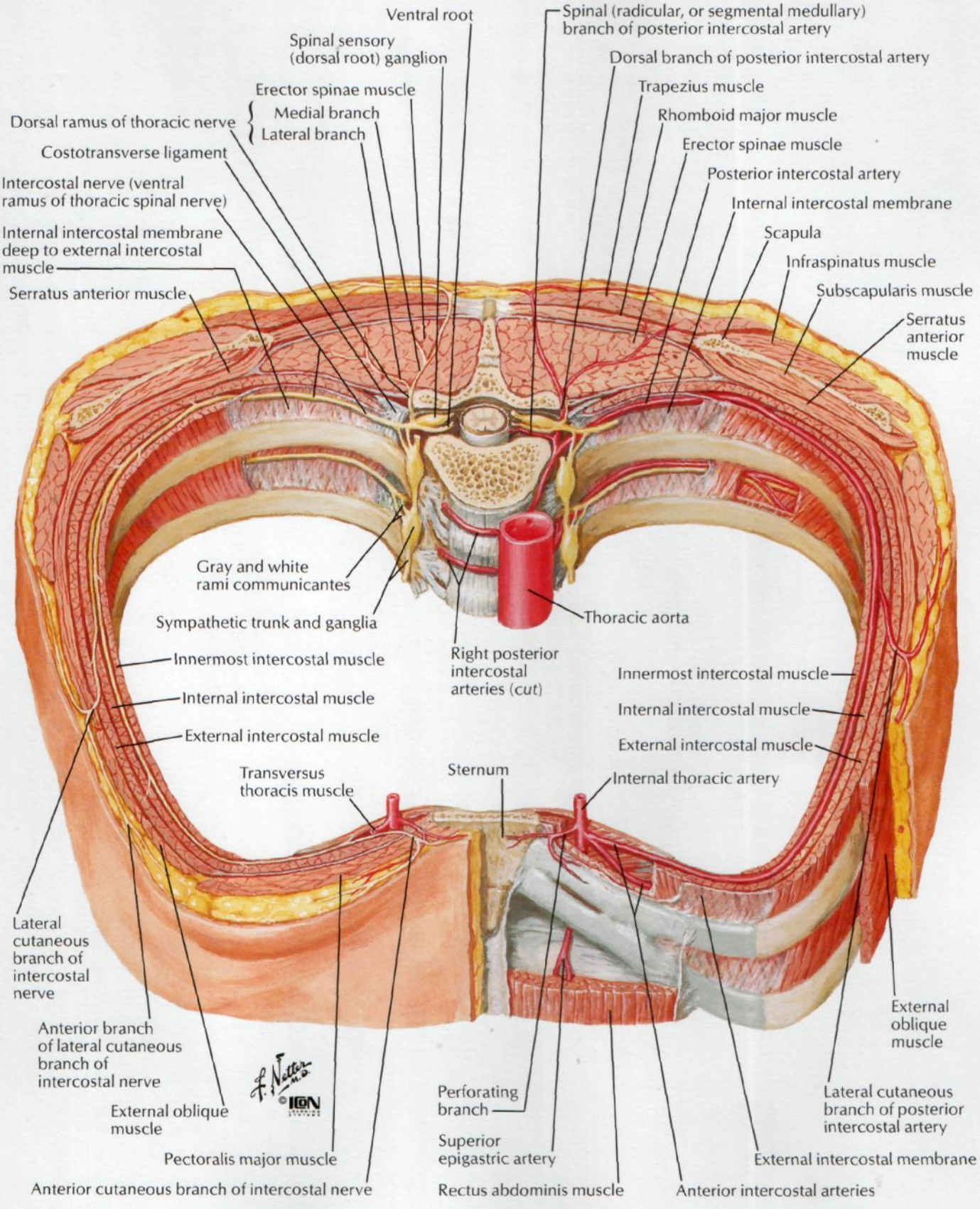

Diaphragm: Thoracic Surface

SEE ALSO PLATES 226, 227

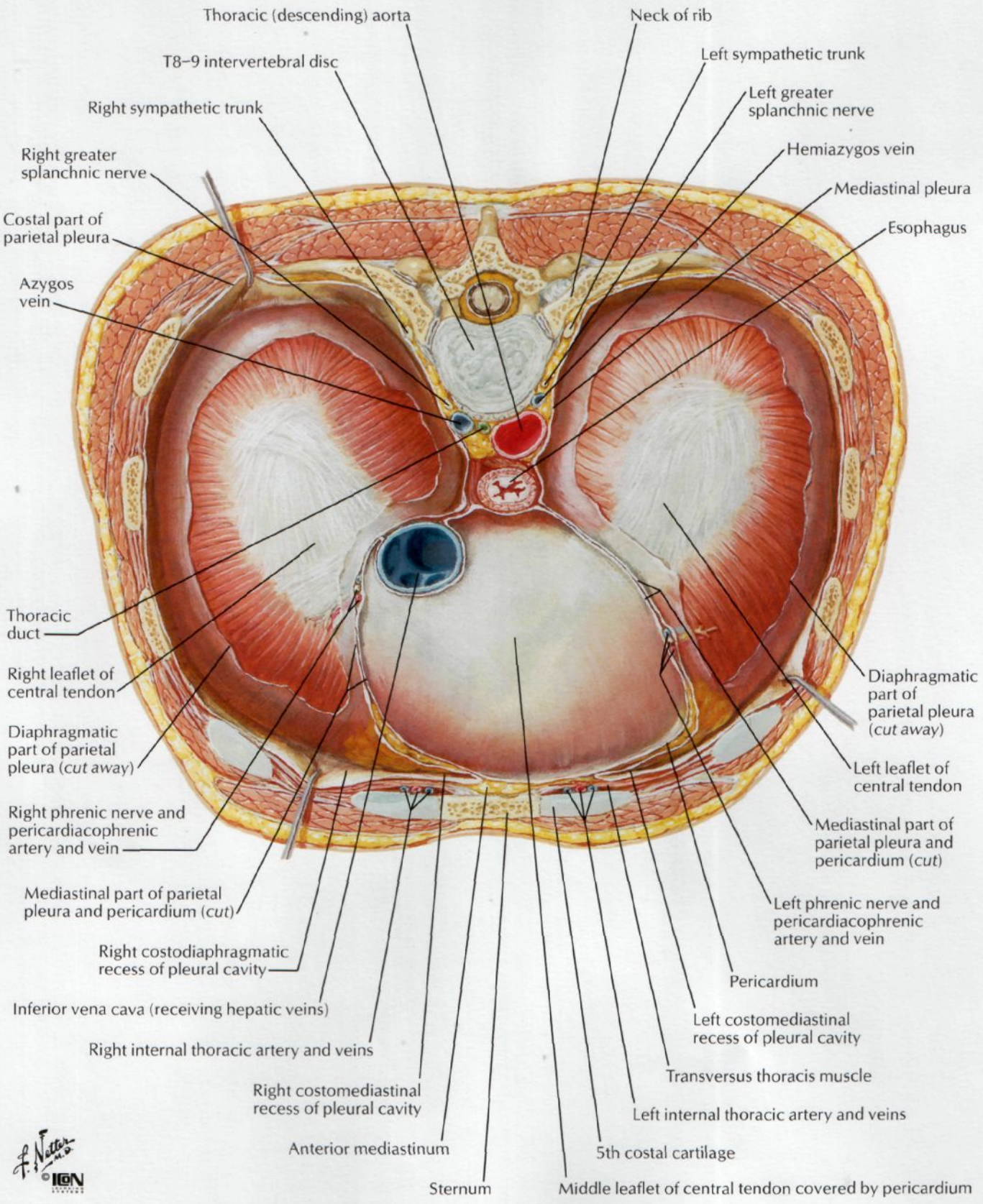

Diaphragm: Abdominal Surface

SEE ALSO PLATES 245, 255, 262

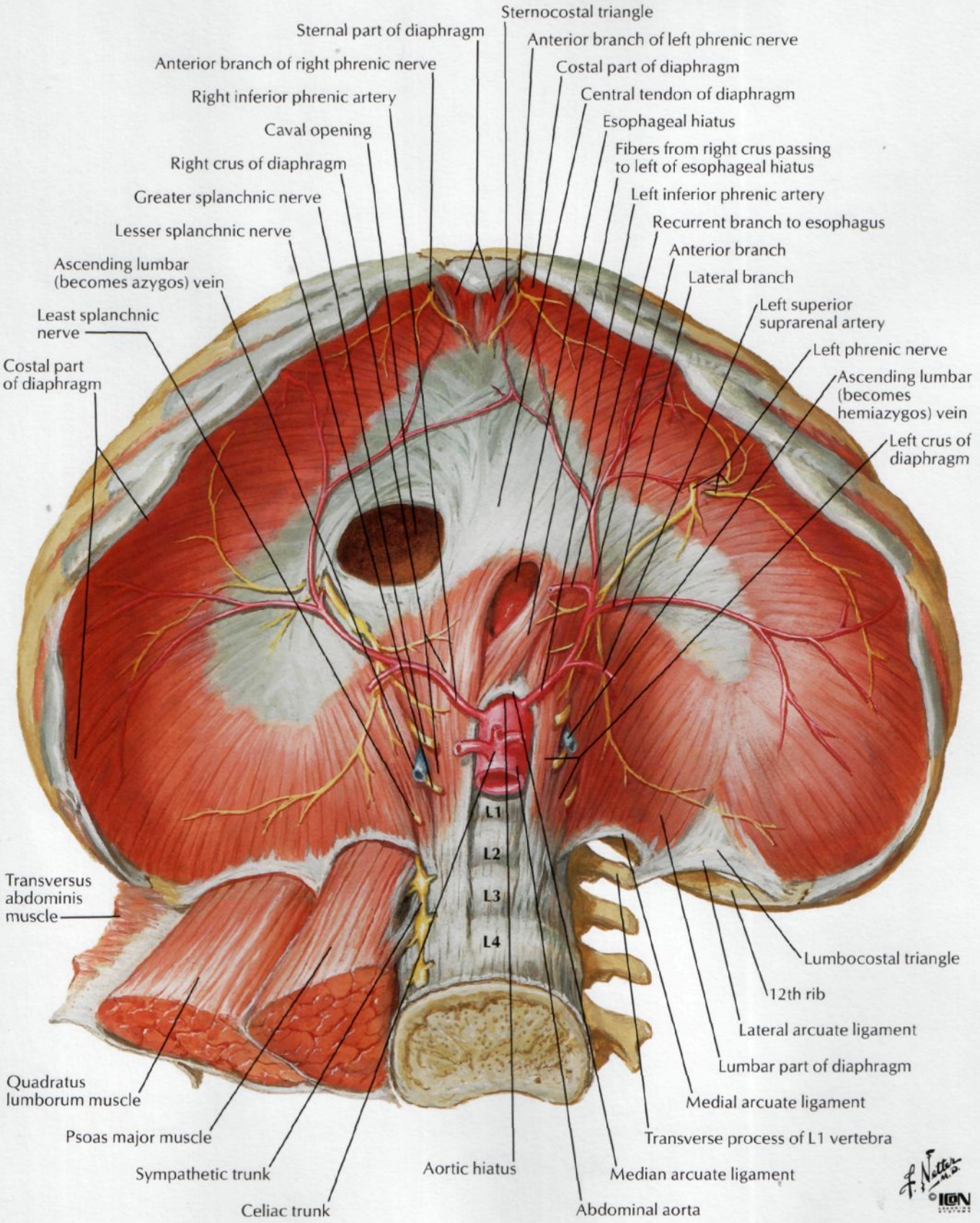

SEE ALSO PLATES 28, 123

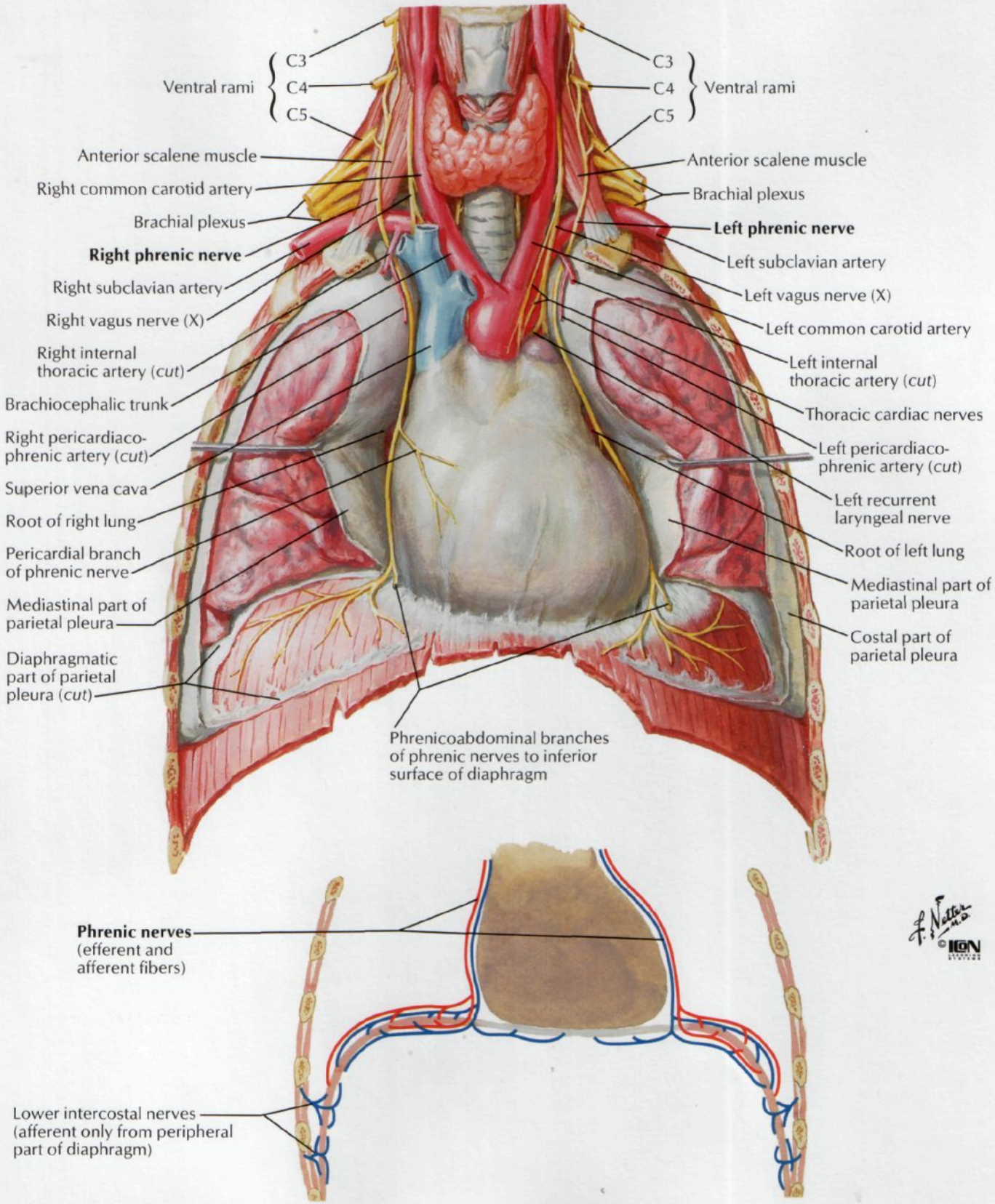

Muscles of Respiration

FOR ADDITIONAL MUSCLES OF INSPIRATION SEE PLATES 169, 185

Muscles of inspiration

Accessory

Sternocleidomastoid (elevates sternum)

Scalenes
- Anterior
- Middle
- Posterior

(elevate and fix upper ribs)

Principal

External intercostals (elevate ribs, thus increasing width of thoracic cavity)

Interchondral part of internal intercostals (also elevates ribs)

Diaphragm (domes descend, thus increasing vertical dimension of thoracic cavity; also elevates lower ribs)

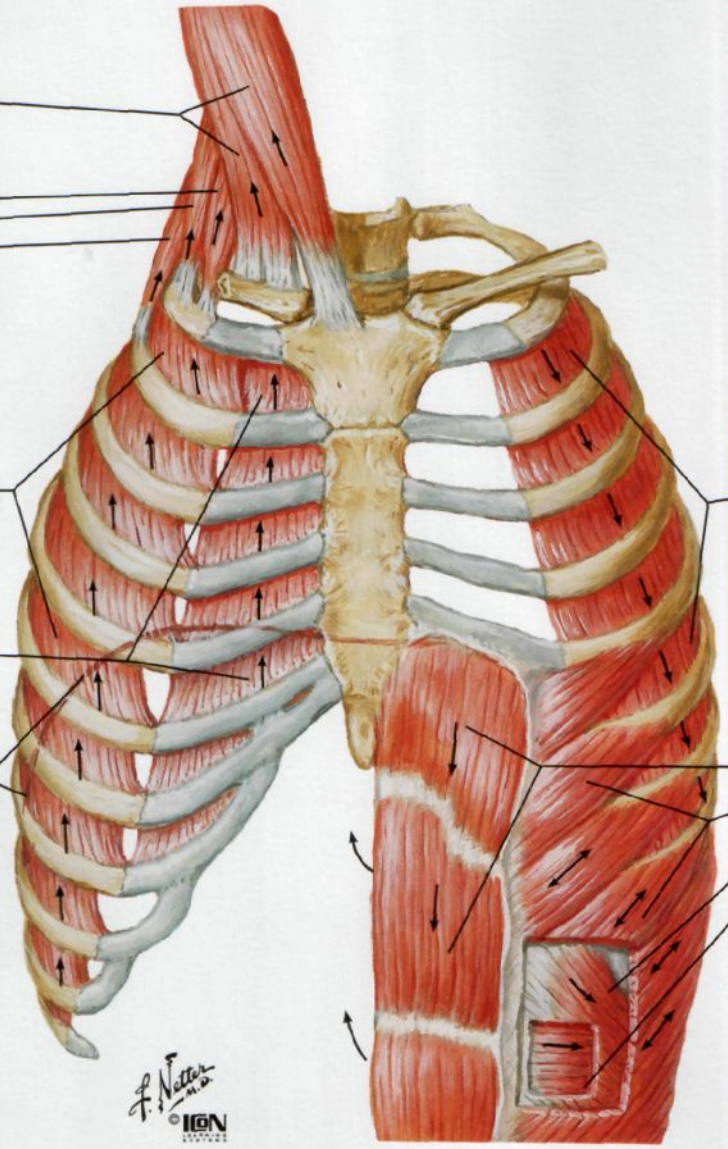

Muscles of expiration

Quiet breathing

Expiration results from passive recoil of lungs and rib cage

Active breathing

Internal intercostals, except interchondral part

Abdominals (depress lower ribs, compress abdominal contents, thus pushing up diaphragm)
- Rectus abdominis
- External oblique
- Internal oblique
- Transversus abdominis

Topography of Lungs: Anterior View

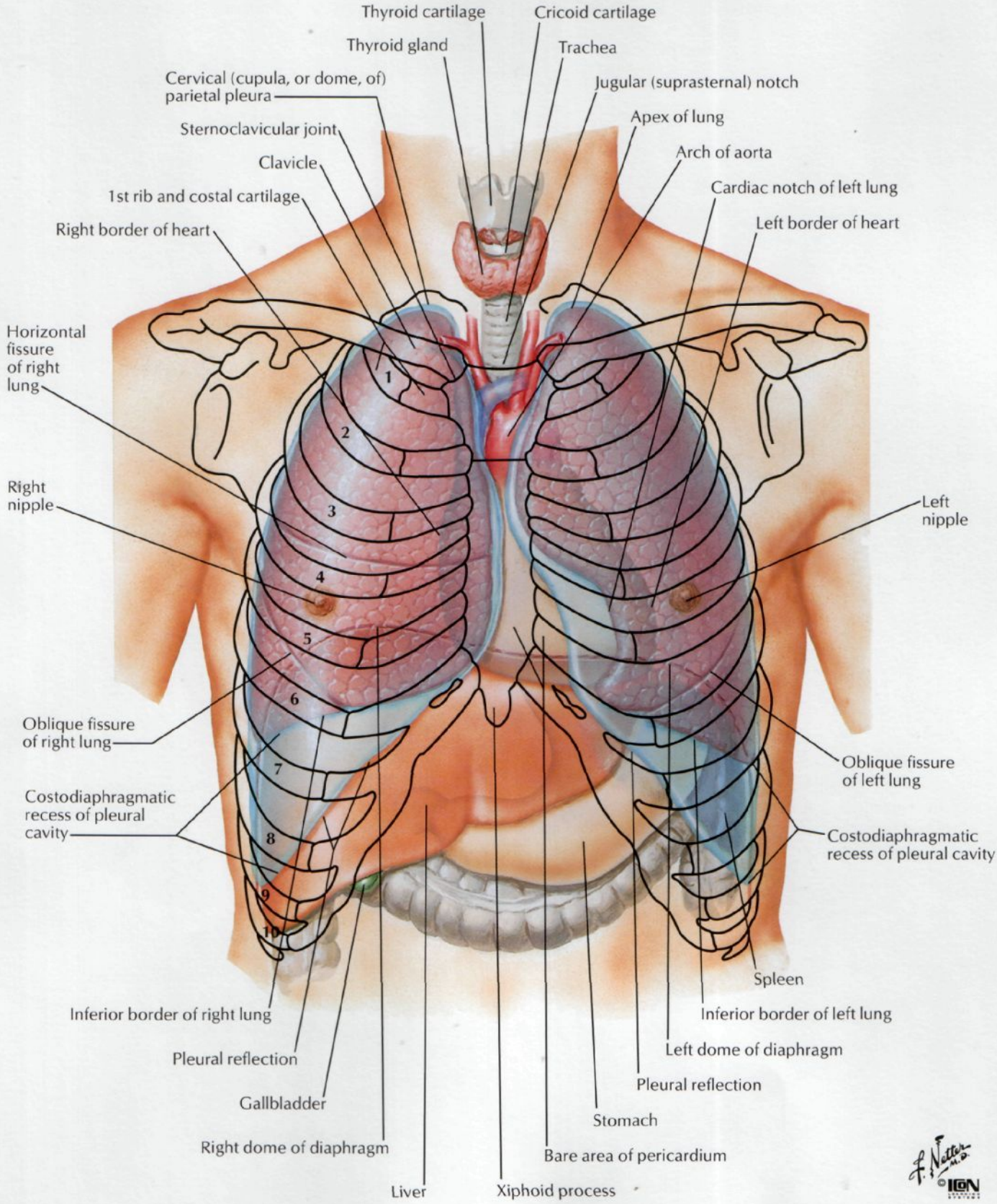

Topography of Lungs: Posterior View

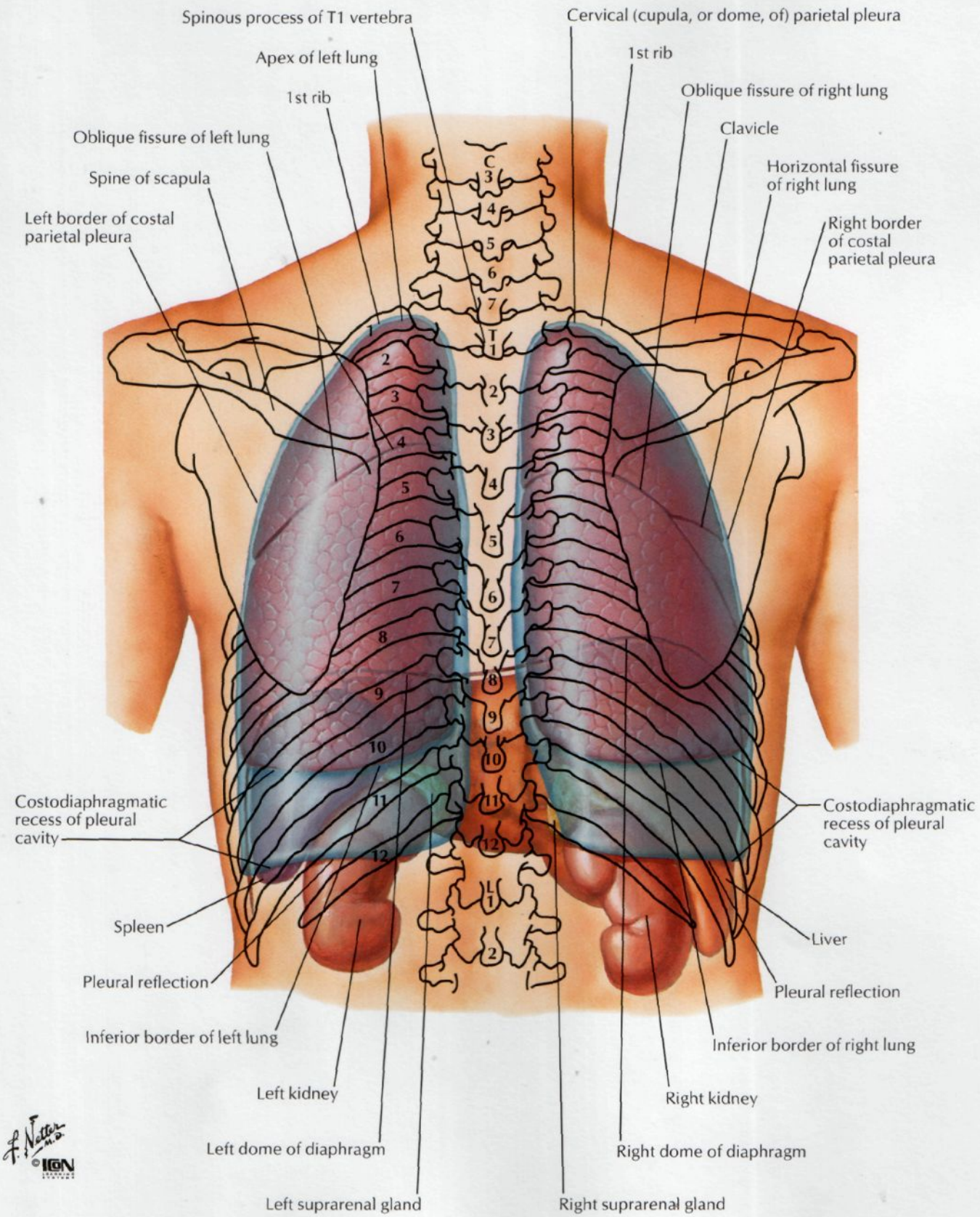

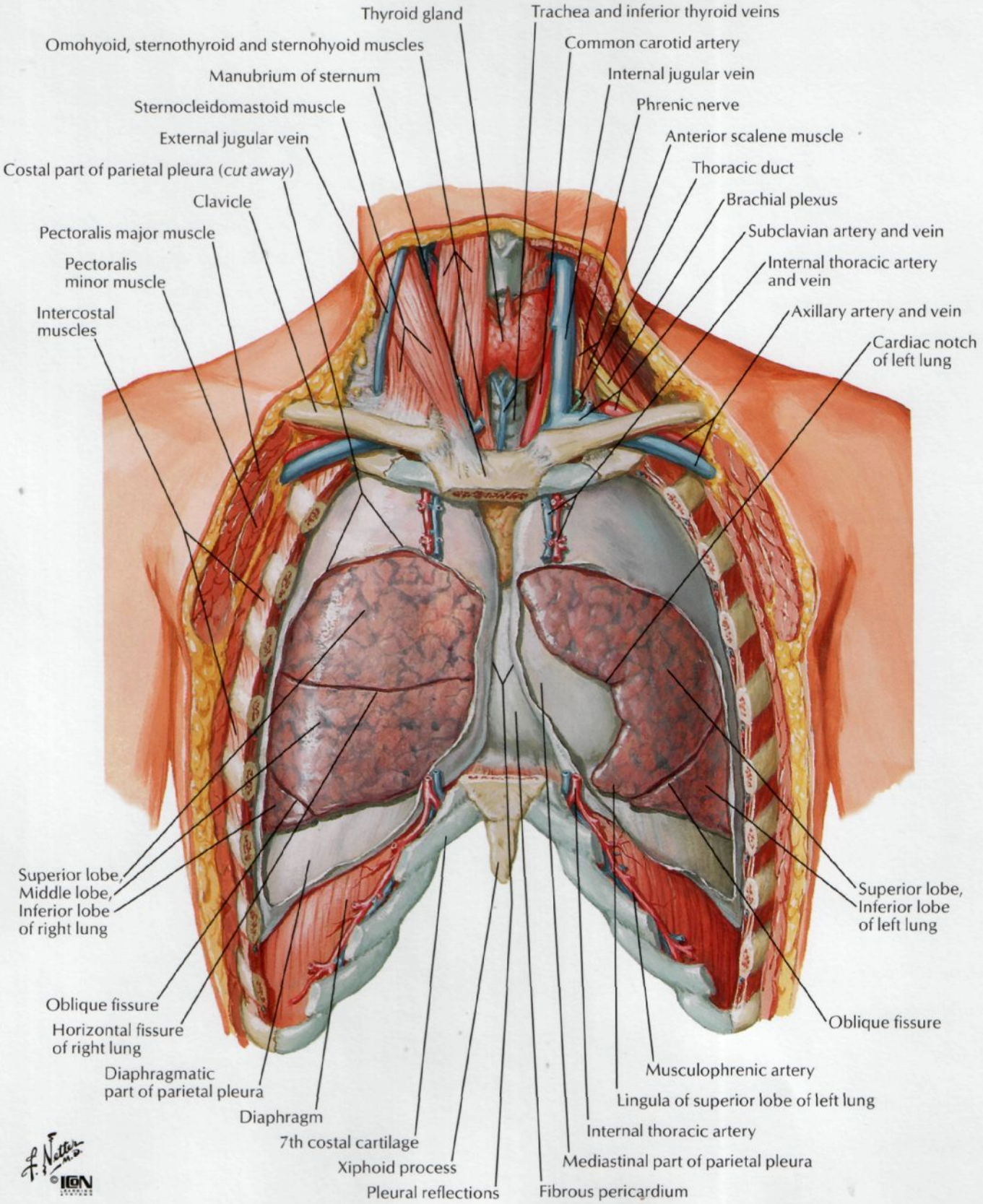
Thyroid gland
Trachea and inferior thyroid veins
Omohyoid, sternothyroid and sternohyoid muscles
Common carotid artery
Manubrium of sternum
Internal jugular vein
Sternocleidomastoid muscle
Phrenic nerve
External jugular vein
Anterior scalene muscle
Costal part of parietal pleura (cut away)
Thoracic duct
Clavicle
Brachial plexus
Pectoralis major muscle
Subclavian artery and vein
Pectoralis minor muscle
Internal thoracic artery and vein
Intercostal muscles
Axillary artery and vein
Cardiac notch of left lung
Superior lobe, Middle lobe, Inferior lobe of right lung
Superior lobe, Inferior lobe of left lung
Oblique fissure
Horizontal fissure of right lung
Oblique fissure
Musculophrenic artery
Diaphragmatic part of parietal pleura
Lingula of superior lobe of left lung
Diaphragm
Internal thoracic artery
7th costal cartilage
Mediastinal part of parietal pleura
Xiphoid process
Pleural reflections
Fibrous pericardium

Lungs: Medial Views

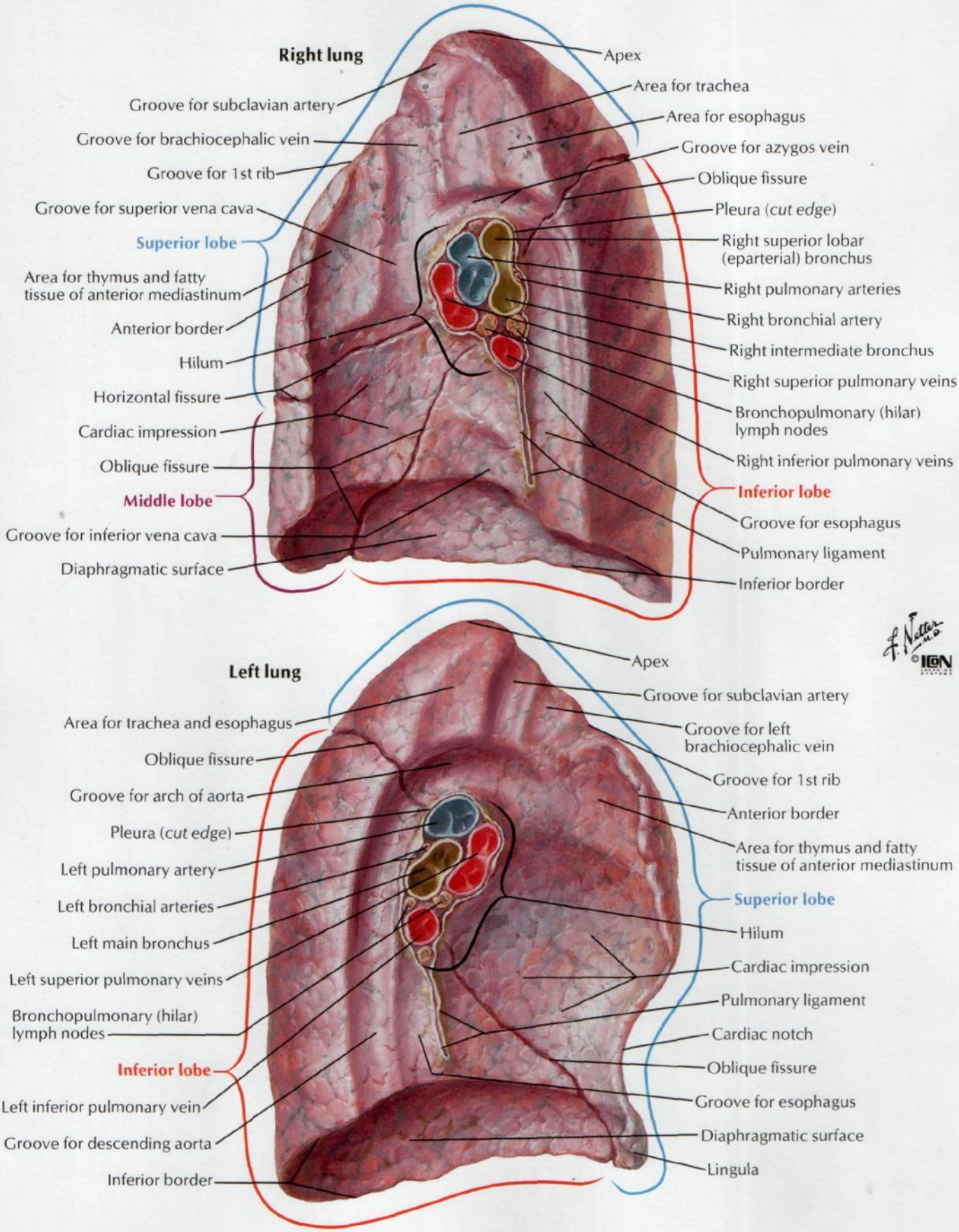

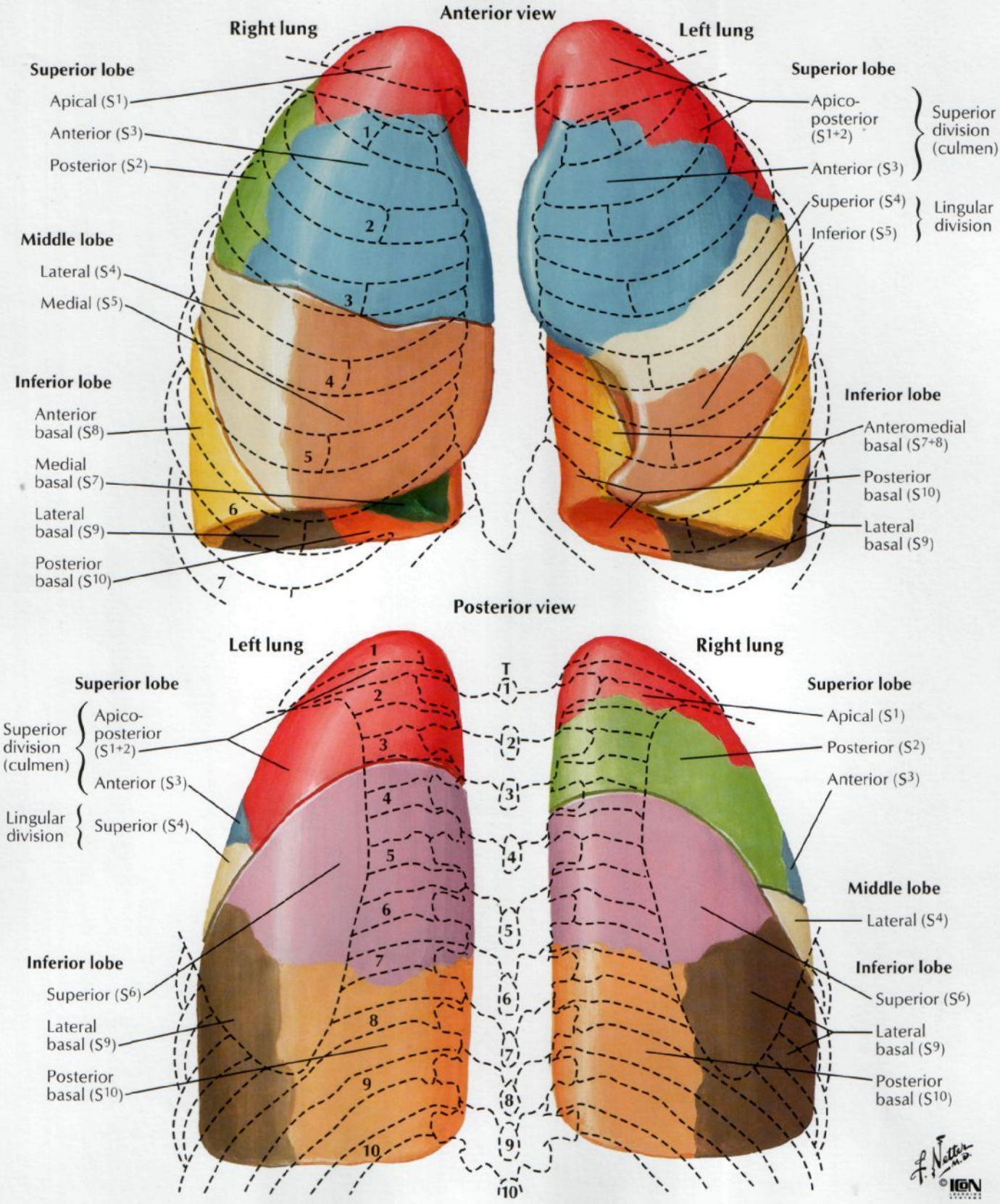
Anterior view
Right lung
Left lung
Superior lobe
Apical (S1)
Anterior (S3)
Posterior (S2)
Middle lobe
Lateral (S4)
Medial (S5)
Inferior lobe
Anterior basal (S8)
Medial basal (S7)
Lateral basal (S9)
Posterior basal (S10)
Superior lobe
Apico-posterior (S1+2)
Anterior (S3)
Superior division (culmen)
Superior (S4)
Inferior (S5)
Lingular division
Inferior lobe
Anteromedial basal (S7+8)
Posterior basal (S10)
Lateral basal (S9)
Posterior view
Left lung
Right lung
Superior lobe
Superior division (culmen)
Apico-posterior (S1+2)
Anterior (S3)
Lingular division
Superior (S4)
Inferior lobe
Superior (S6)
Lateral basal (S9)
Posterior basal (S10)
Apical (S1)
Posterior (S2)
Anterior (S3)
Middle lobe
Lateral (S4)
Inferior lobe
Superior (S6)
Lateral basal (S9)
Posterior basal (S10)

Bronchopulmonary Segments (continued)

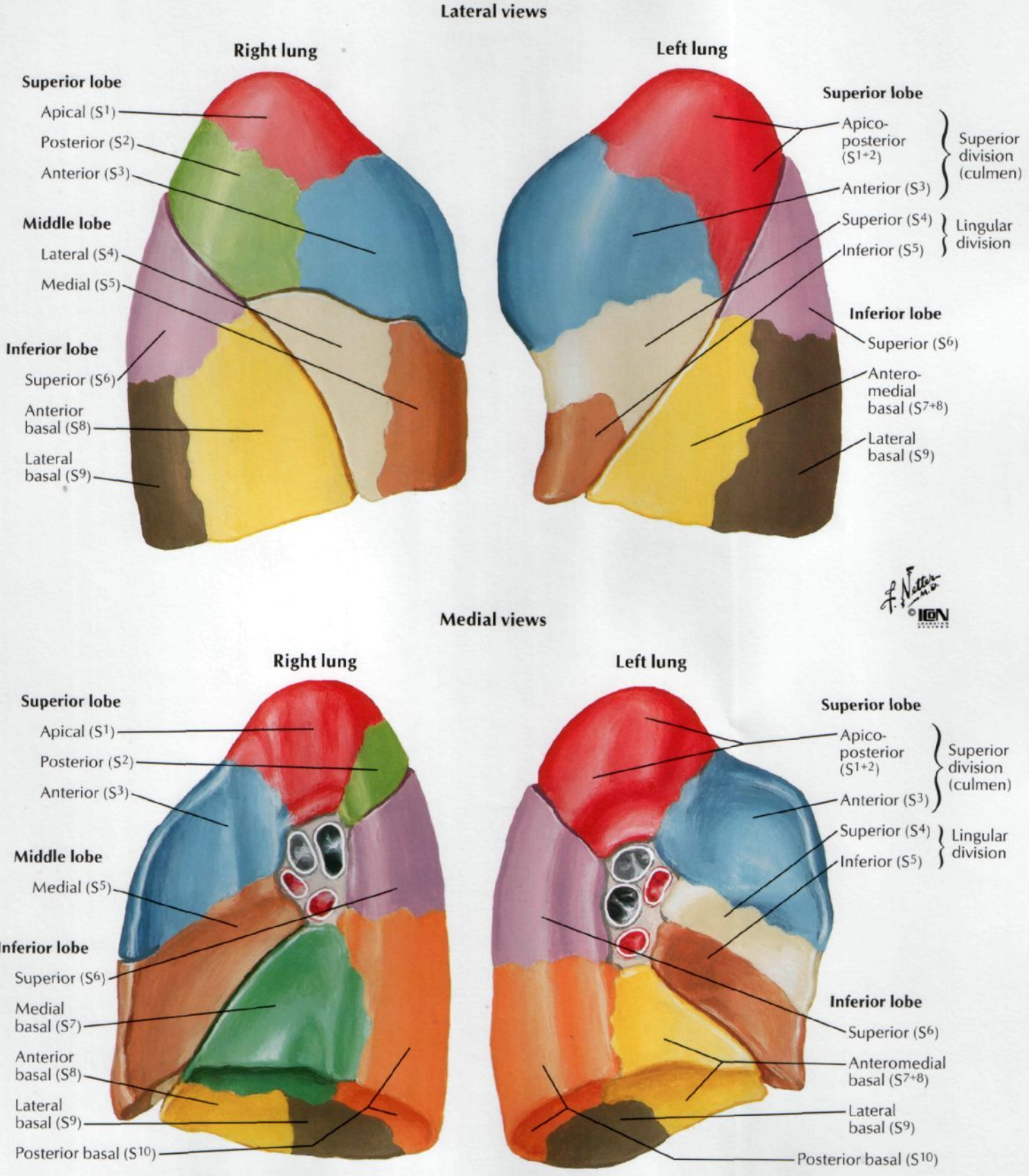

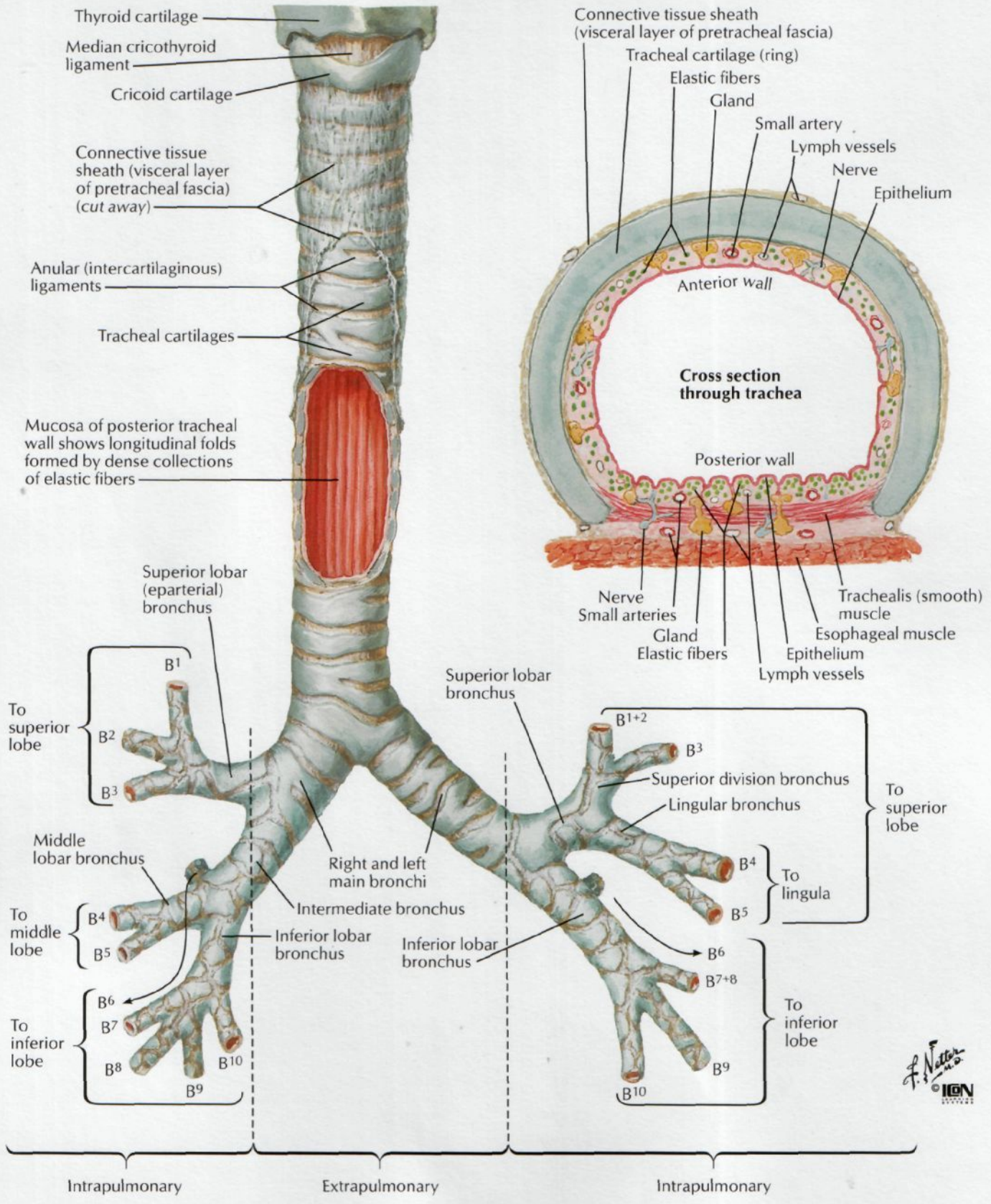
Thyroid cartilage
Median cricothyroid ligament
Cricoid cartilage
Connective tissue sheath (visceral layer of pretracheal fascia) (cut away)
Anular (intercartilaginous) ligaments
Tracheal cartilages
Mucosa of posterior tracheal wall shows longitudinal folds formed by dense collections of elastic fibers
Connective tissue sheath (visceral layer of pretracheal fascia)
Tracheal cartilage (ring)
Elastic fibers
Gland
Small artery
Lymph vessels
Nerve
Epithelium
Anterior wall
Cross section through trachea
Posterior wall
Nerve
Small arteries
Gland
Elastic fibers
Lymph vessels
Epithelium
Esophageal muscle
Trachealis (smooth) muscle
Superior lobar (eparterial) bronchus
B1
To superior lobe
B2
B3
Middle lobar bronchus
To middle lobe
B4
B5
To inferior lobe
B6
B7
B8
B10
B9
Right and left main bronchi
Intermediate bronchus
Inferior lobar bronchus
Superior lobar bronchus
B1+2
B3
Superior division bronchus
Lingular bronchus
B4
B5
To lingula
To superior lobe
Inferior lobar bronchus
B6
B7+8
B9
B10
To inferior lobe
Intrapulmonary
Extrapulmonary
Intrapulmonary

Nomenclature of Bronchi: Schema

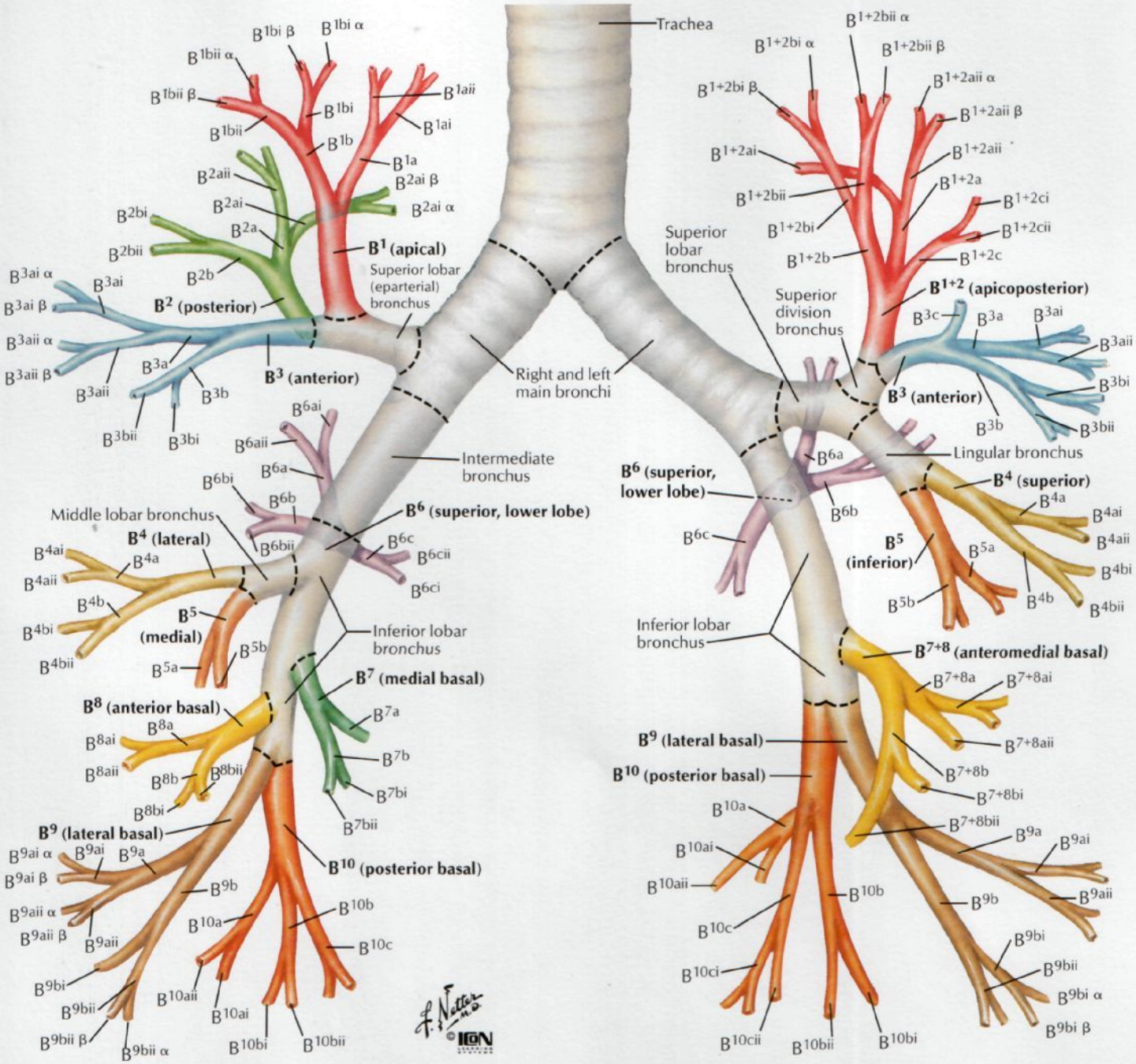

Nomenclature in common usage for bronchopulmonary segments (Plates 196 and 197) is that of Jackson and Huber, and segmental bronchi are named accordingly. Ikeda proposed nomenclature (as demonstrated here) for bronchial subdivisions as far as 6th generation. For simplification on this illustration, only some bronchial subdivisions are labeled as far as 5th or 6th generation. Segmental bronchi (B) are numbered from 1 to 10 in each lung, corresponding to pulmonary segments. In left lung, B^1 and B^2 are combined as are B^7 and B^8. Subsegmental, or 4th order, bronchi are indicated by addition of lowercase letters a, b or c when an additional branch is present. Fifth order bronchi are designated by Roman numerals i (anterior) or ii (posterior) and 6th order bronchi by Greek letters α or β. Several texts use alternate numbers (as proposed by Boyden) for segmental bronchi.

Variations of standard bronchial pattern shown here are common, especially in peripheral airways.

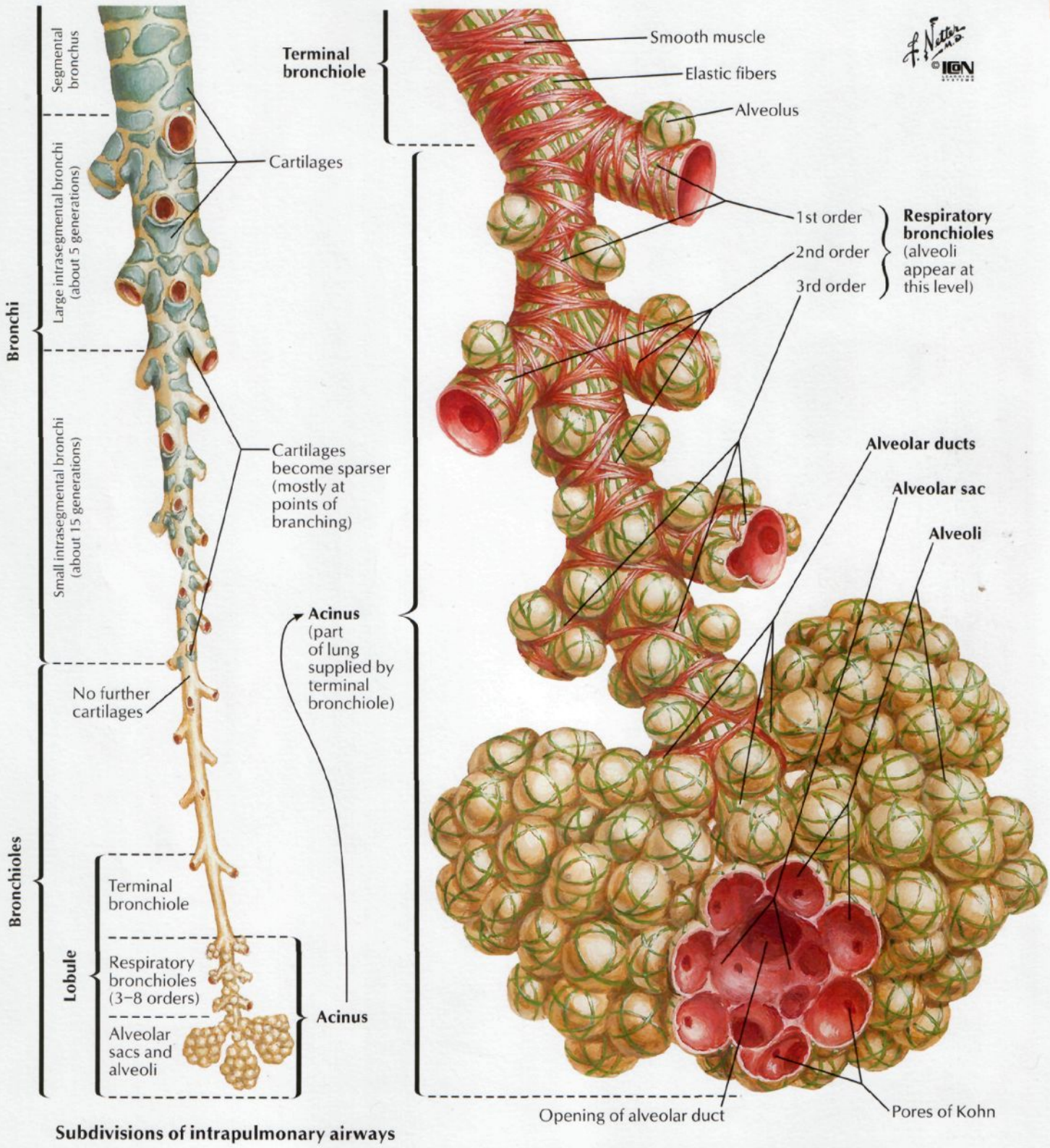

Subdivisions of intrapulmonary airways

Structure of intrapulmonary airways

Intrapulmonary Blood Circulation: Schema

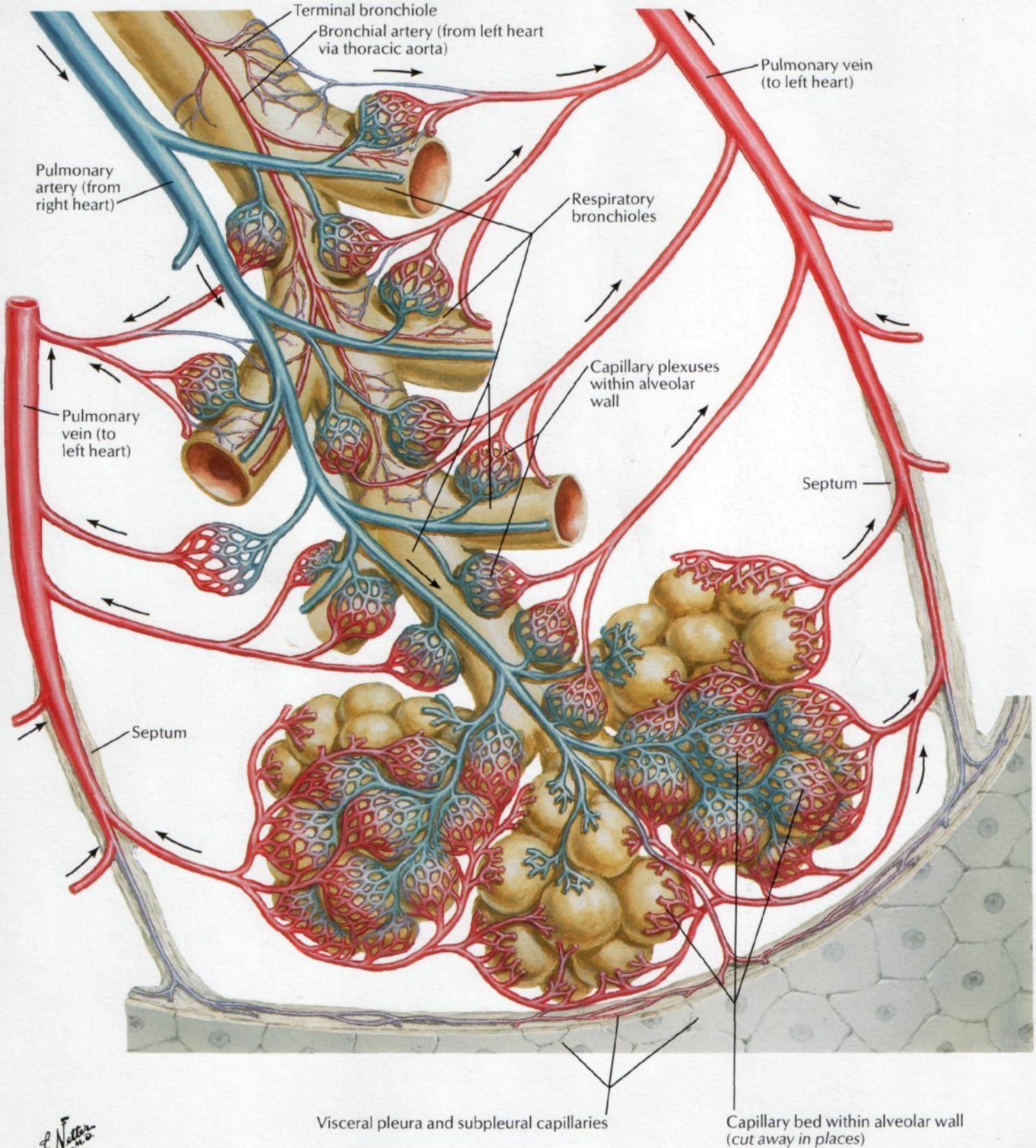

F. Netter M.D.
©

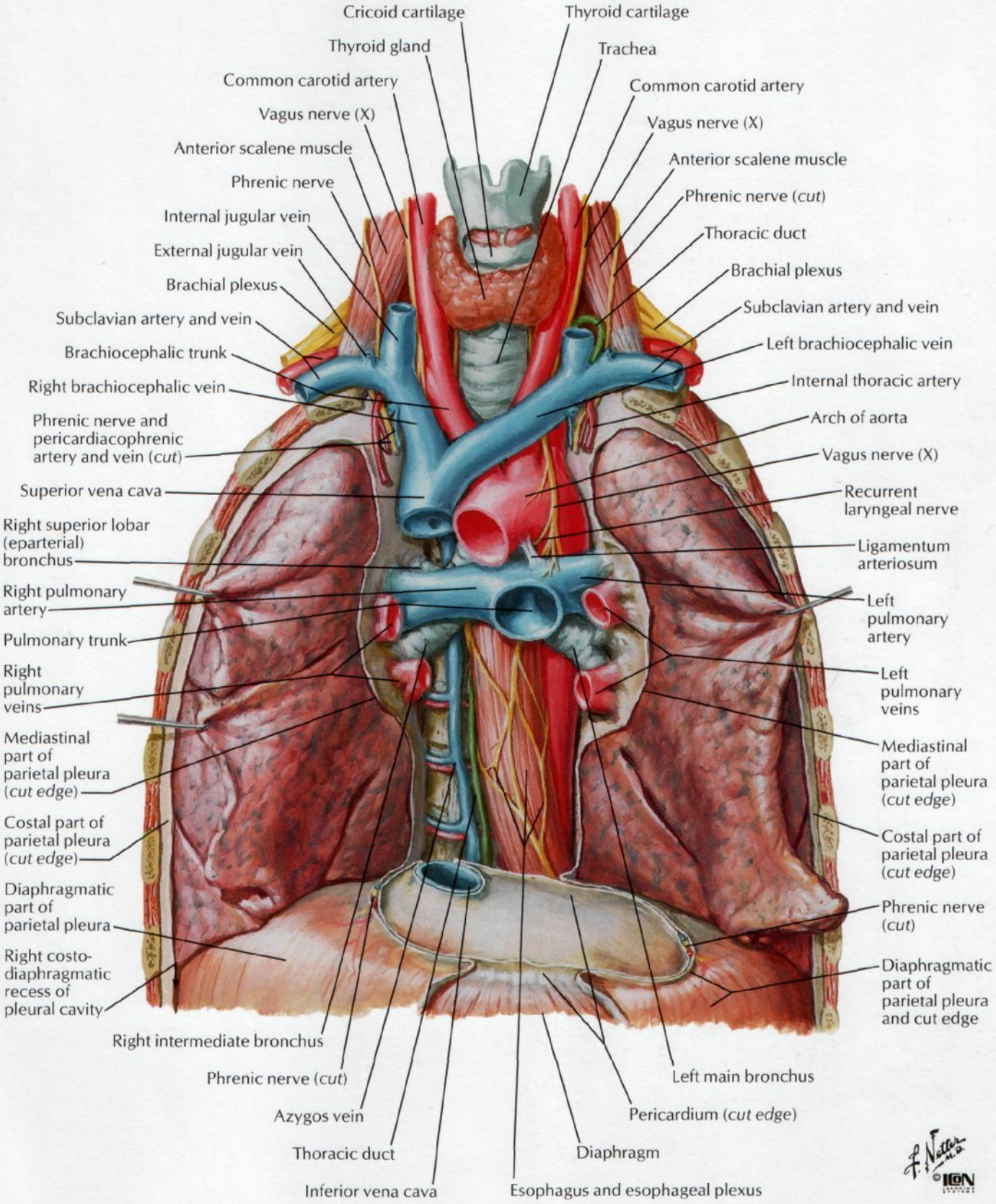
Cricoid cartilage
Thyroid cartilage
Thyroid gland
Trachea
Common carotid artery
Common carotid artery
Vagus nerve (X)
Vagus nerve (X)
Anterior scalene muscle
Anterior scalene muscle
Phrenic nerve
Phrenic nerve (cut)
Internal jugular vein
Thoracic duct
External jugular vein
Brachial plexus
Brachial plexus
Subclavian artery and vein
Subclavian artery and vein
Brachiocephalic trunk
Left brachiocephalic vein
Right brachiocephalic vein
Internal thoracic artery
Phrenic nerve and pericardiacophrenic artery and vein (cut)
Arch of aorta
Vagus nerve (X)
Superior vena cava
Recurrent laryngeal nerve
Right superior lobar (eparterial) bronchus
Ligamentum arteriosum
Right pulmonary artery
Left pulmonary artery
Pulmonary trunk
Right pulmonary veins
Left pulmonary veins
Mediastinal part of parietal pleura (cut edge)
Mediastinal part of parietal pleura (cut edge)
Costal part of parietal pleura (cut edge)
Costal part of parietal pleura (cut edge)
Diaphragmatic part of parietal pleura
Phrenic nerve (cut)
Right costo-diaphragmatic recess of pleural cavity
Diaphragmatic part of parietal pleura and cut edge
Right intermediate bronchus
Phrenic nerve (cut)
Left main bronchus
Azygos vein
Pericardium (cut edge)
Thoracic duct
Diaphragm
Inferior vena cava
Esophagus and esophageal plexus

Bronchial Arteries and Veins

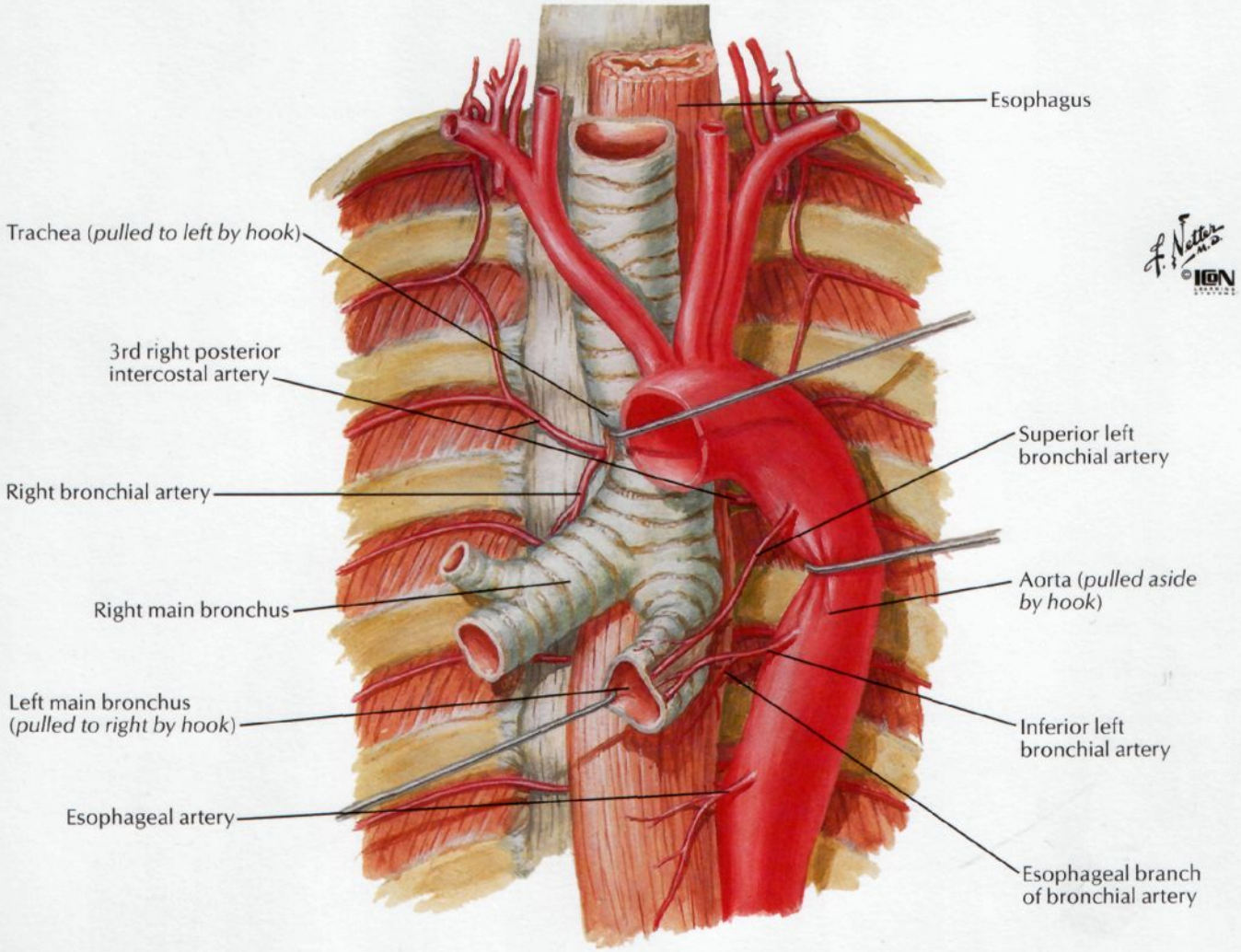

Variations in bronchial arteries

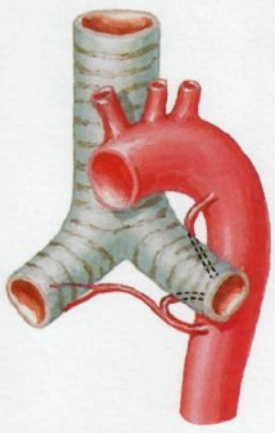

Right and left bronchial arteries originating from aorta by single stem

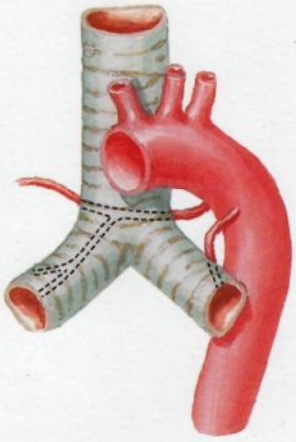

Only single bronchial artery to each bronchus (normally, two to left bronchus)

Bronchial veins

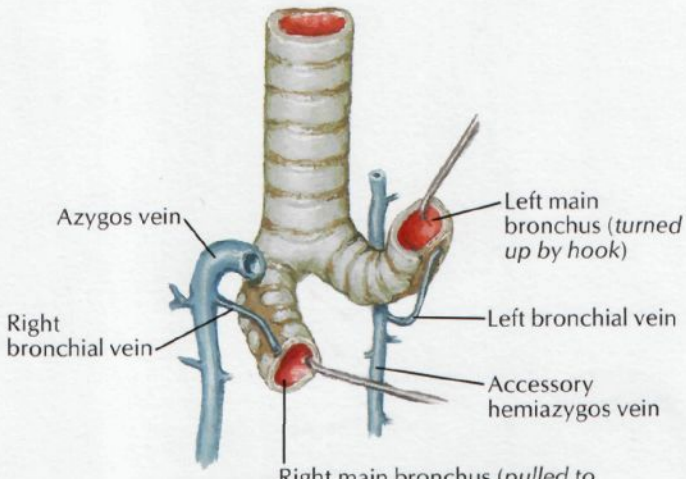

Lymph Vessels and Nodes of Lung

SEE ALSO PLATES 68, 177, 235

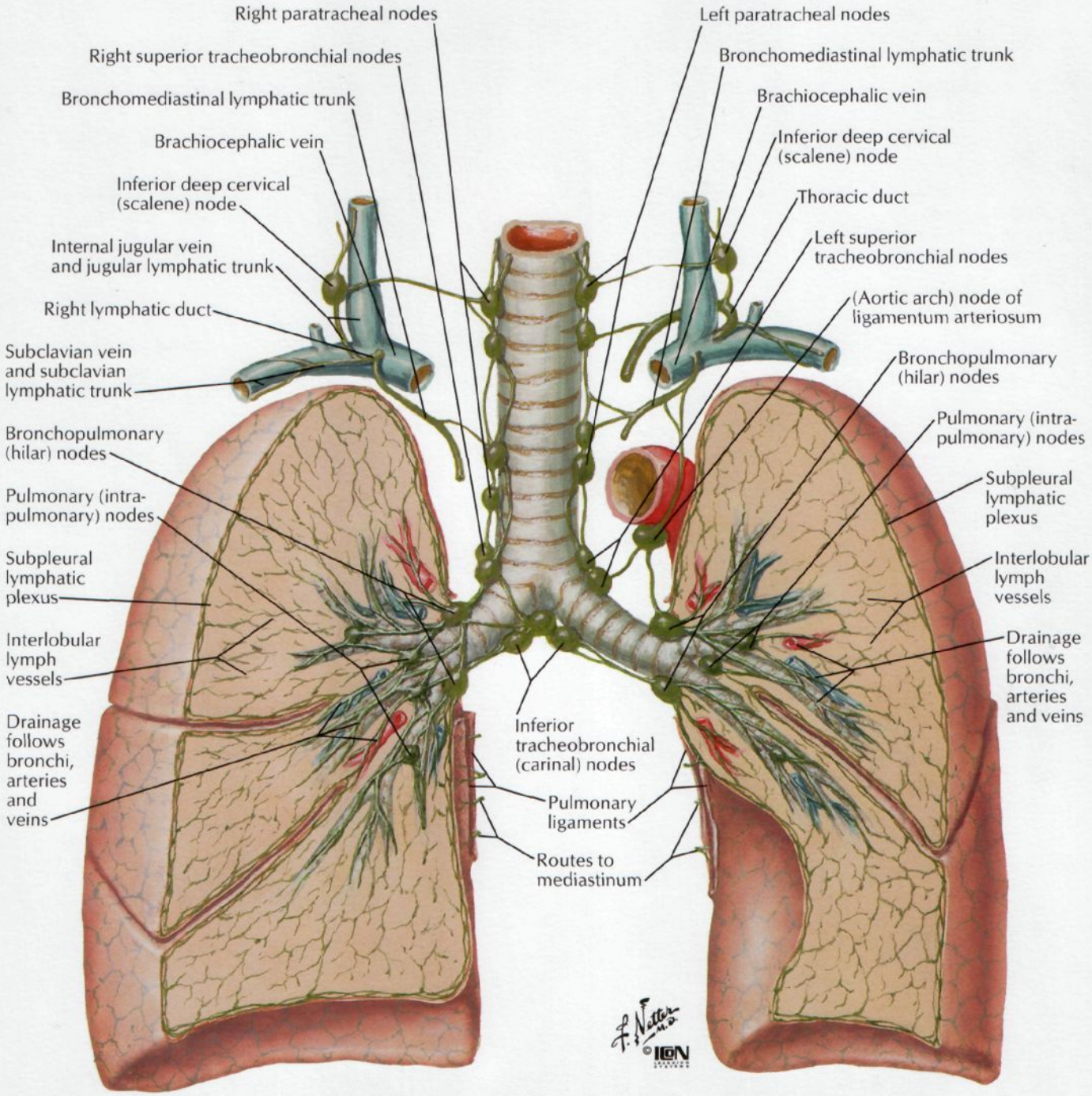

Drainage routes

Right lung: All lobes drain to pulmonary and bronchopulmonary (hilar) nodes, then to inferior tracheobronchial (carinal) nodes, right superior tracheobronchial nodes and to right paratracheal nodes on way to brachiocephalic vein via bronchomediastinal lymphatic trunk and/or inferior deep cervical (scalene) node.

Left lung: Superior lobe drains to pulmonary and bronchopulmonary (hilar) nodes, inferior tracheobronchial (carinal) nodes, left superior tracheobronchial nodes, left paratracheal nodes and/or (aortic arch) node of ligamentum arteriosum, then to brachiocephalic vein via left bronchomediastinal trunk and thoracic duct. Left inferior lobe drains also to pulmonary and bronchopulmonary (hilar) nodes and to inferior tracheobronchial (carinal) nodes, but then mostly to right superior tracheobronchial nodes, where it follows same route as lymph from right lung.

Autonomic Nerves in Thorax

SEE ALSO PLATES 124, 125, 159, 308

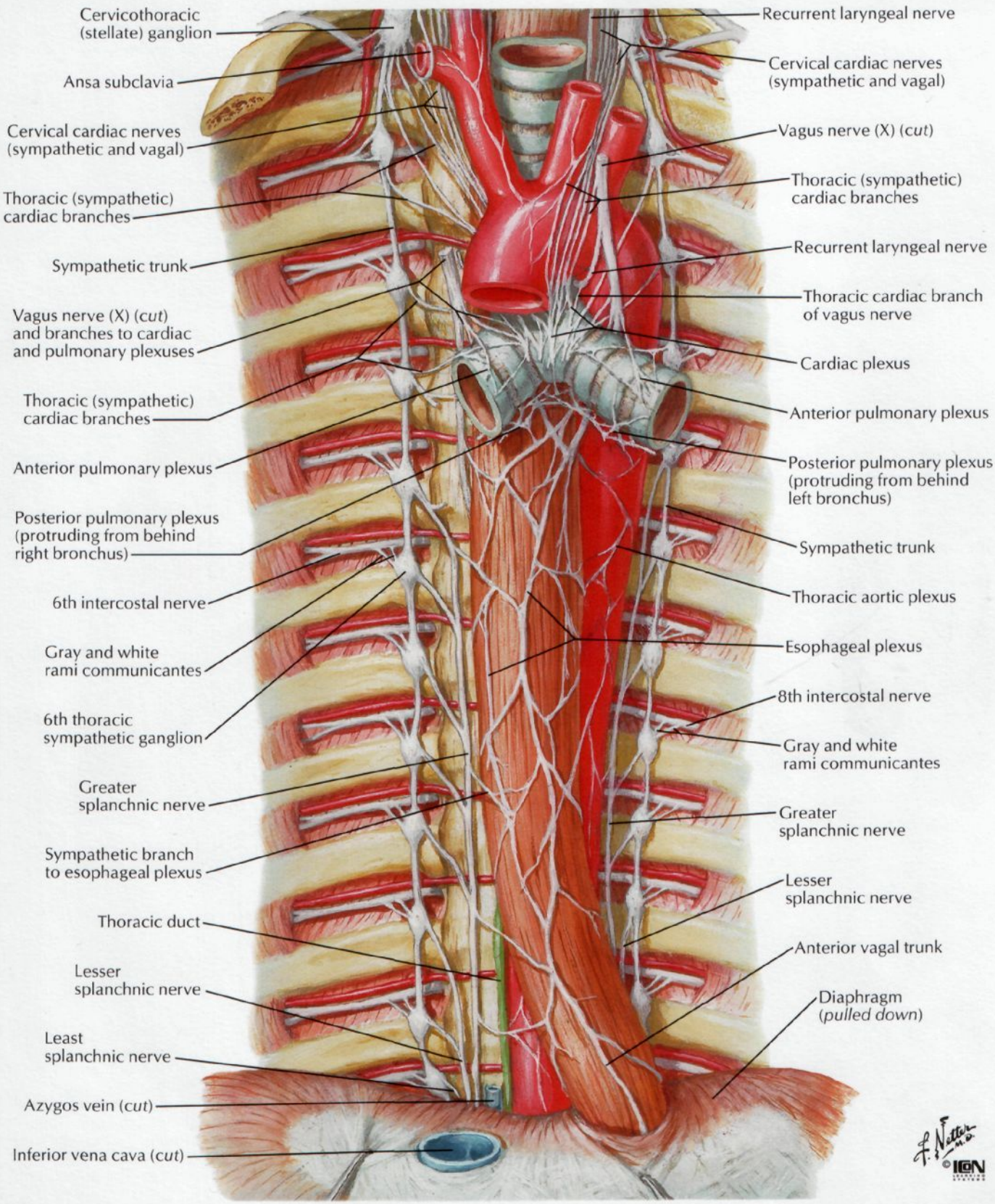

Innervation of Tracheobronchial Tree: Schema

SEE ALSO PLATE 160

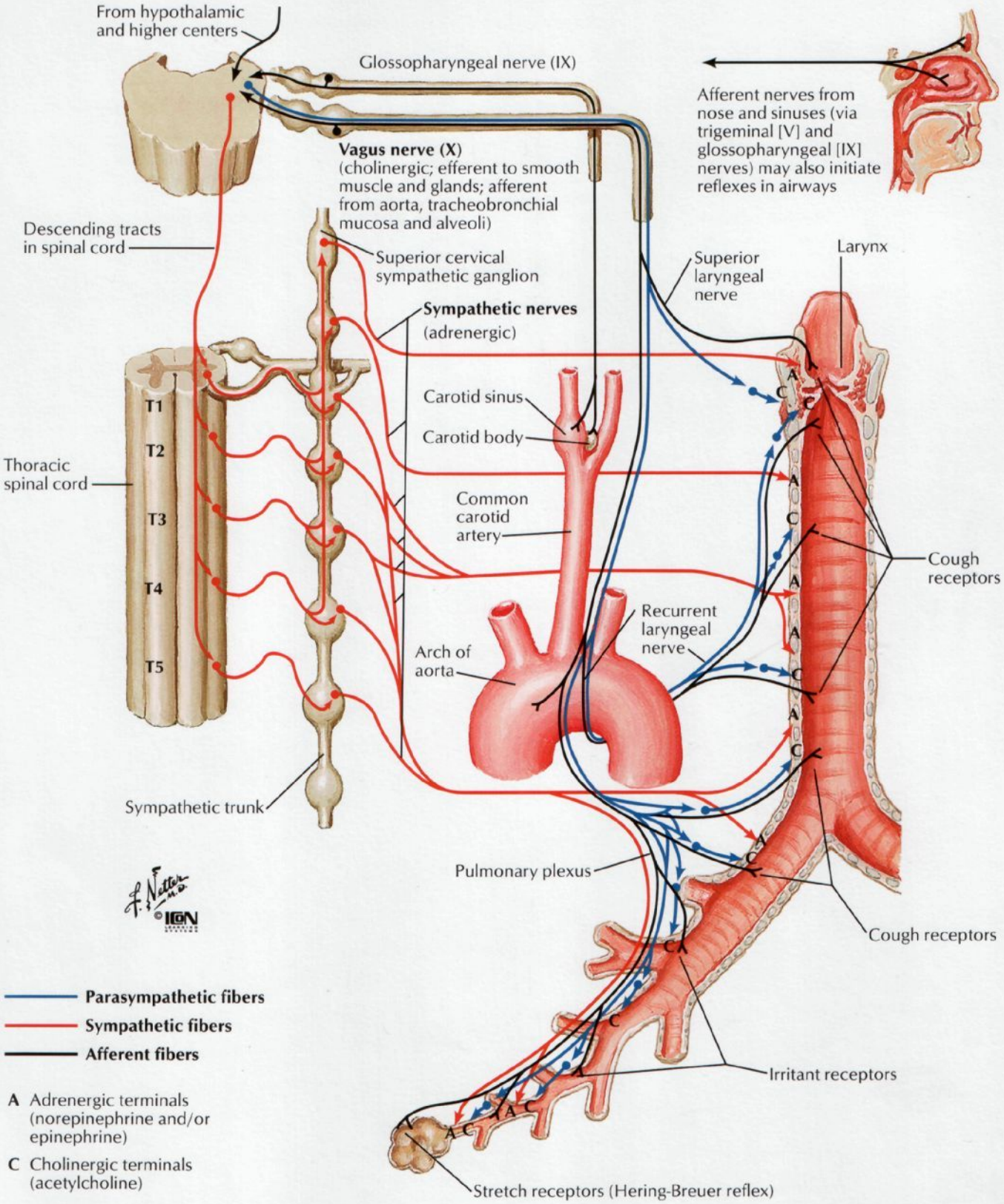

Heart In Situ

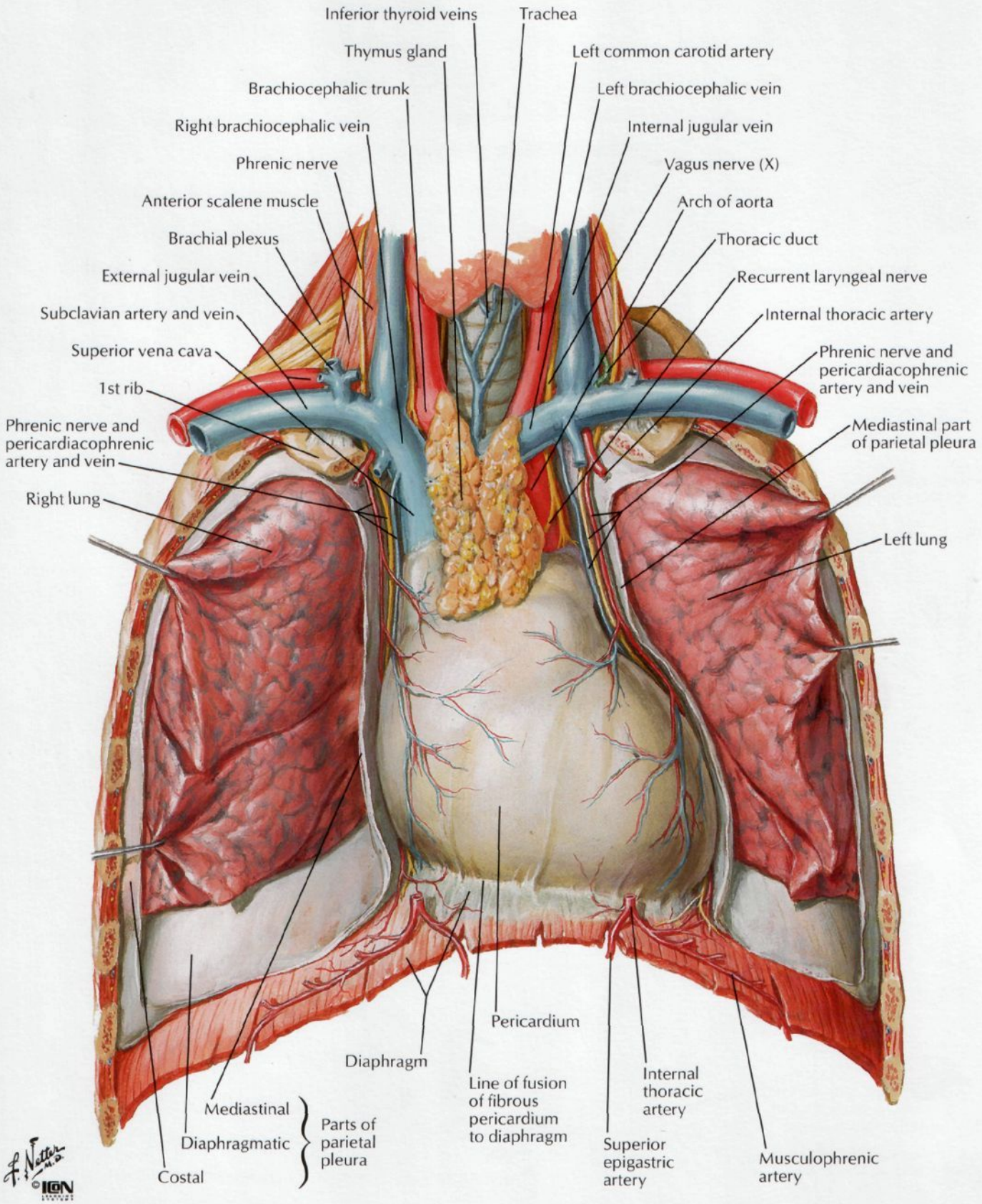

©IGN

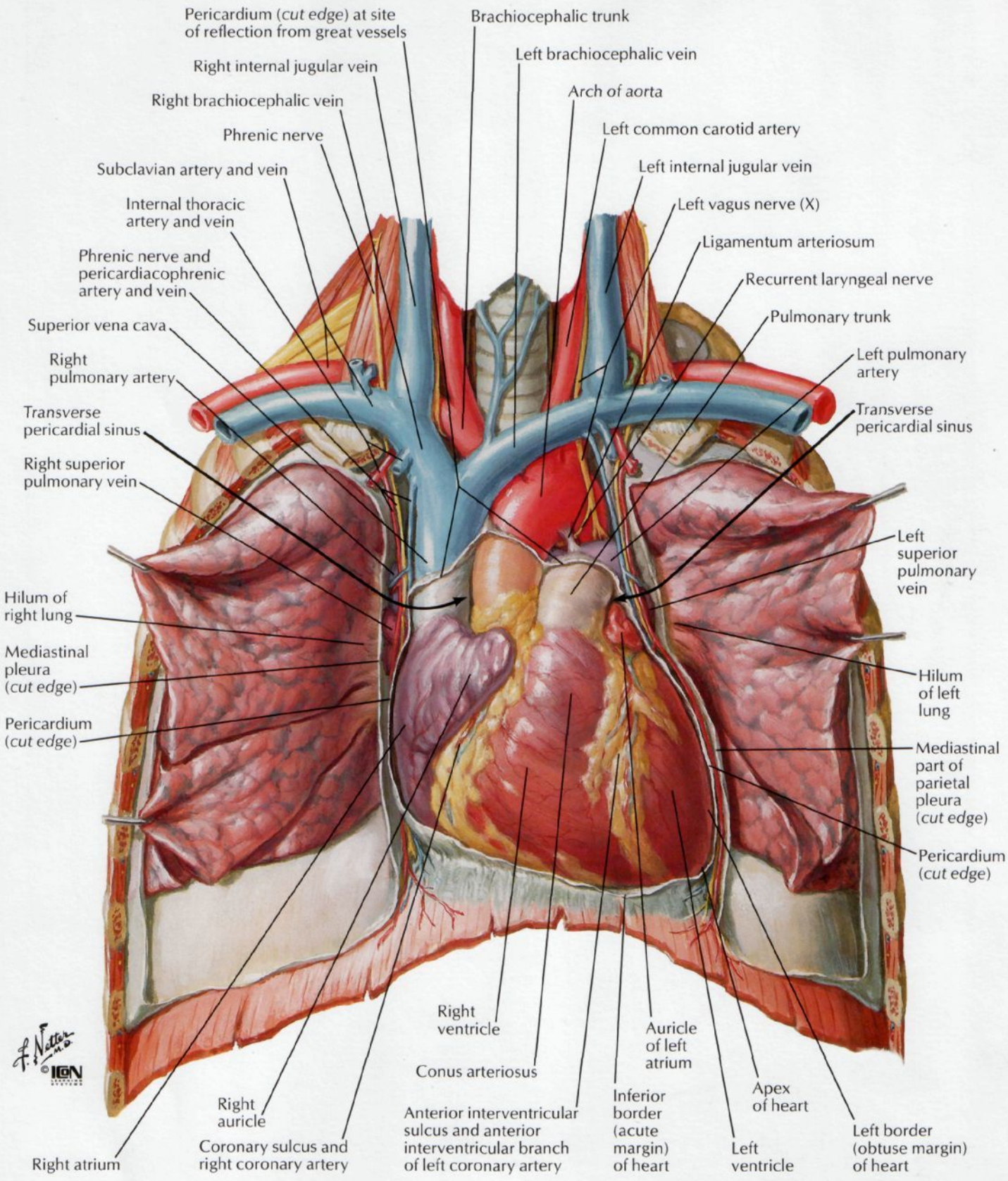
Pericardium (cut edge) at site of reflection from great vessels
Brachiocephalic trunk
Left brachiocephalic vein
Right internal jugular vein
Arch of aorta
Right brachiocephalic vein
Left common carotid artery
Phrenic nerve
Left internal jugular vein
Subclavian artery and vein
Left vagus nerve (X)
Internal thoracic artery and vein
Ligamentum arteriosum
Phrenic nerve and pericardiacophrenic artery and vein
Recurrent laryngeal nerve
Pulmonary trunk
Superior vena cava
Left pulmonary artery
Right pulmonary artery
Transverse pericardial sinus
Transverse pericardial sinus
Right superior pulmonary vein
Left superior pulmonary vein
Hilum of right lung
Mediastinal pleura (cut edge)
Hilum of left lung
Pericardium (cut edge)
Mediastinal part of parietal pleura (cut edge)
Pericardium (cut edge)
Right ventricle
Auricle of left atrium
Conus arteriosus
Apex of heart
Right auricle
Inferior border (acute margin) of heart
Anterior interventricular sulcus and anterior interventricular branch of left coronary artery
Left ventricle
Left border (obtuse margin) of heart
Coronary sulcus and right coronary artery
Right atrium

Radiograph of Chest

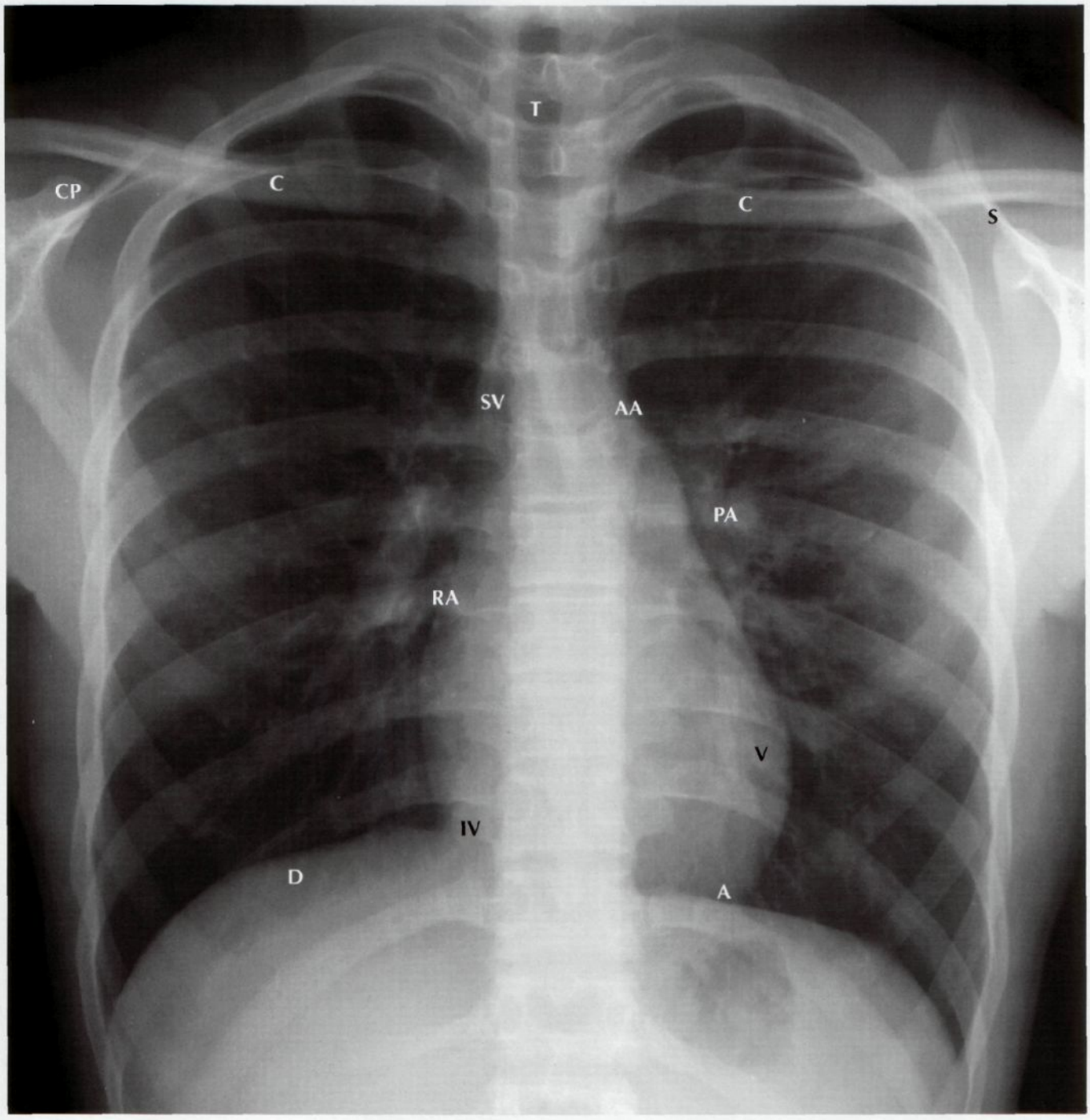

A	Apex of heart
AA	Aortic arch
C	Clavicle
CP	Coracoid process of scapula
D	Dome of diaphragm (right)
IV	Inferior vena cava
PA	Pulmonary artery (left)
RA	Right atrium
S	Spine of scapula
SV	Superior vena cava
T	Trachea (air)
V	Left ventricle

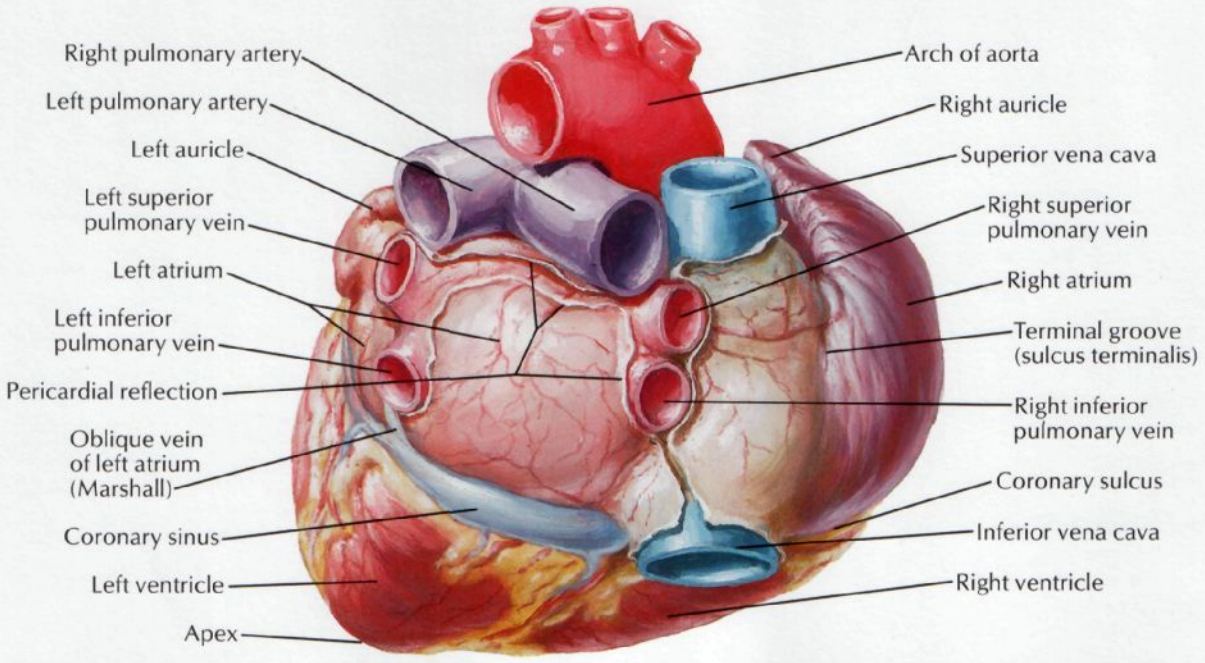

Base of heart: posterior view

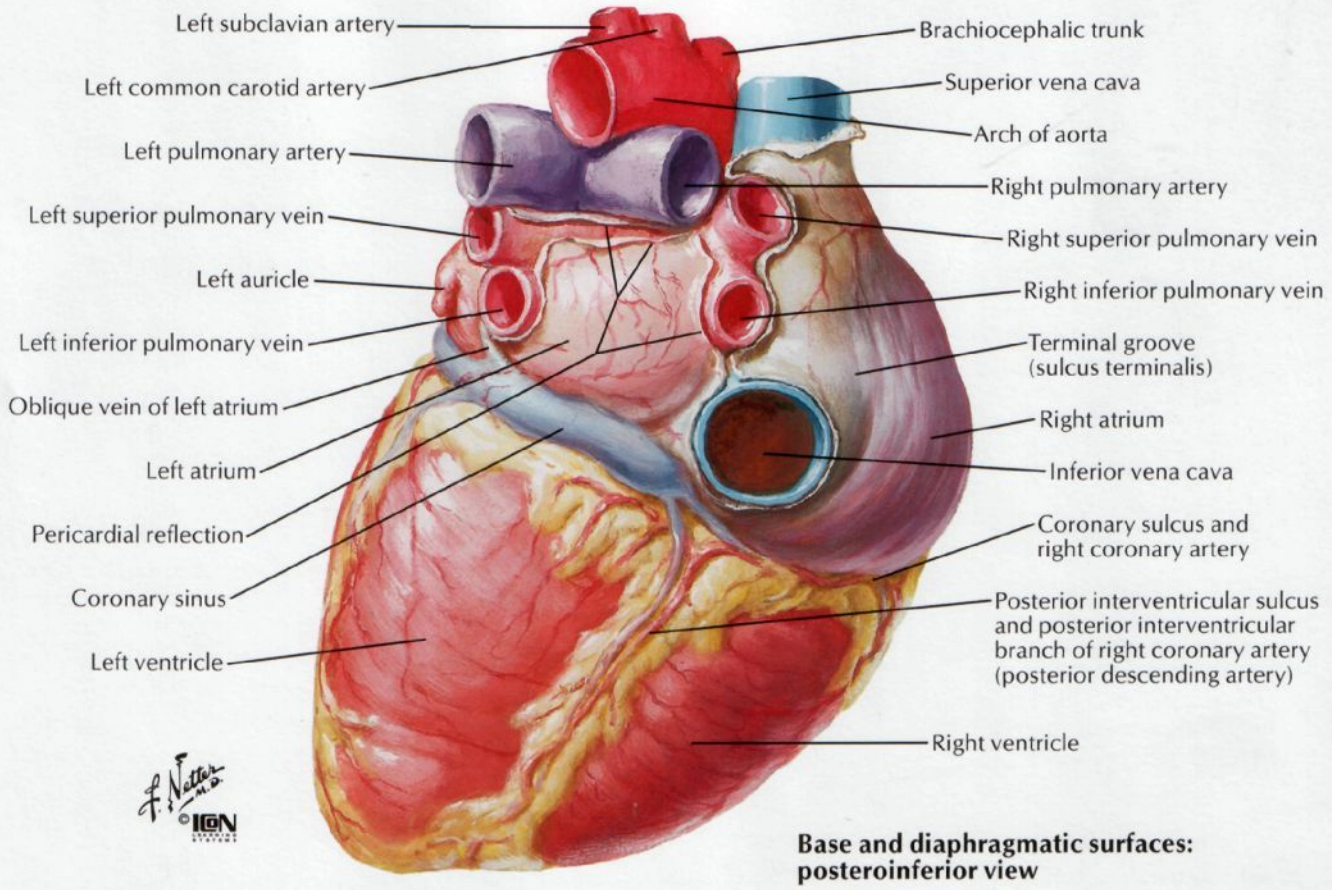

Base and diaphragmatic surfaces: posteroinferior view

Pericardial Sac

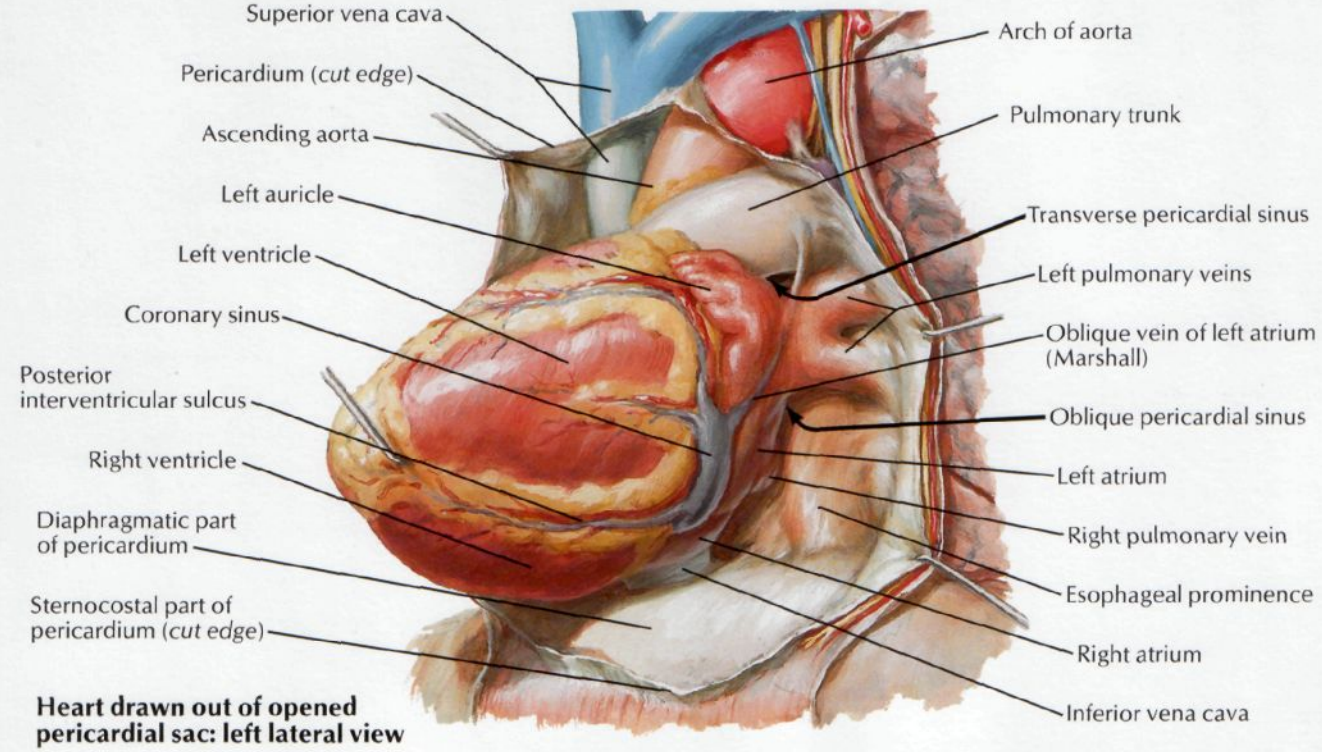

Heart drawn out of opened pericardial sac: left lateral view

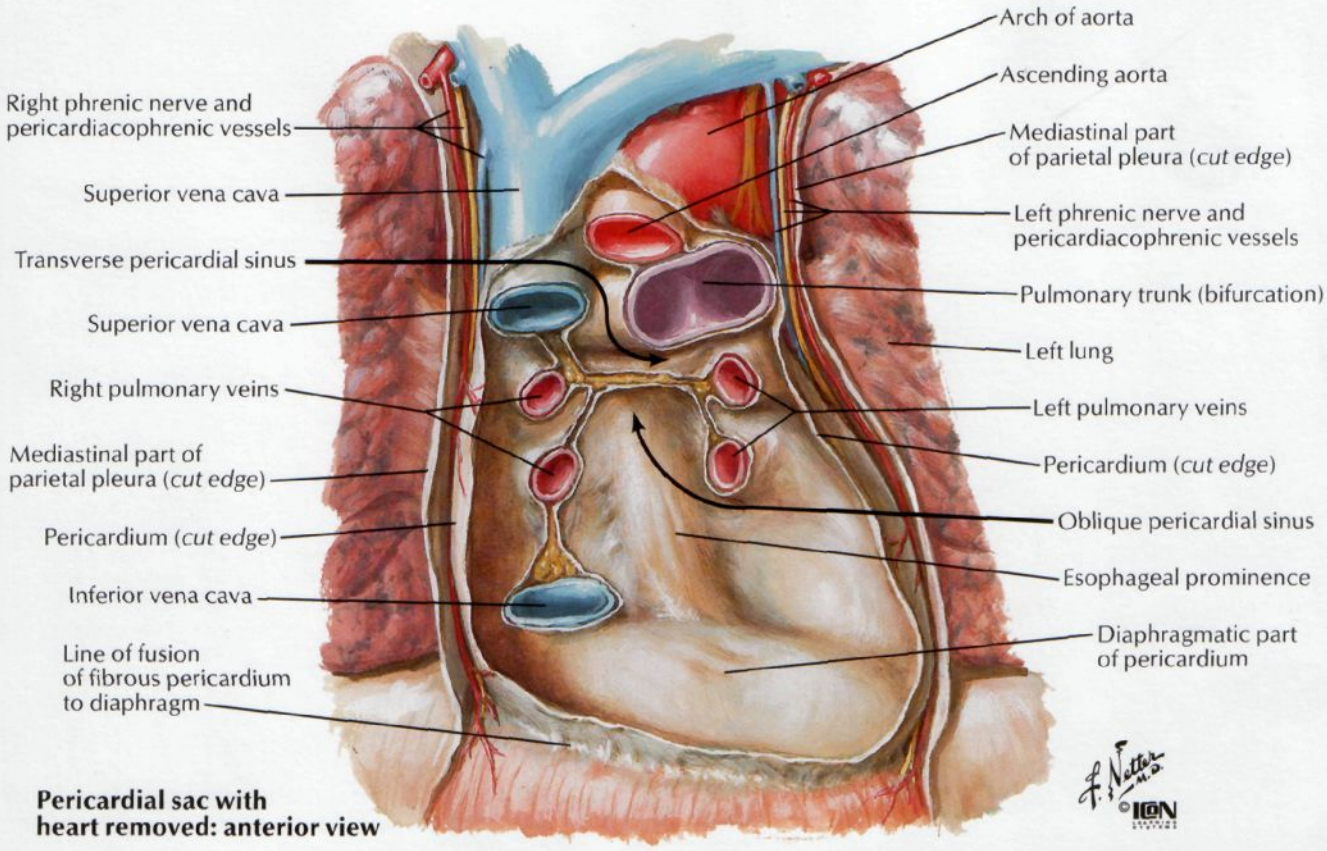

Pericardial sac with heart removed: anterior view

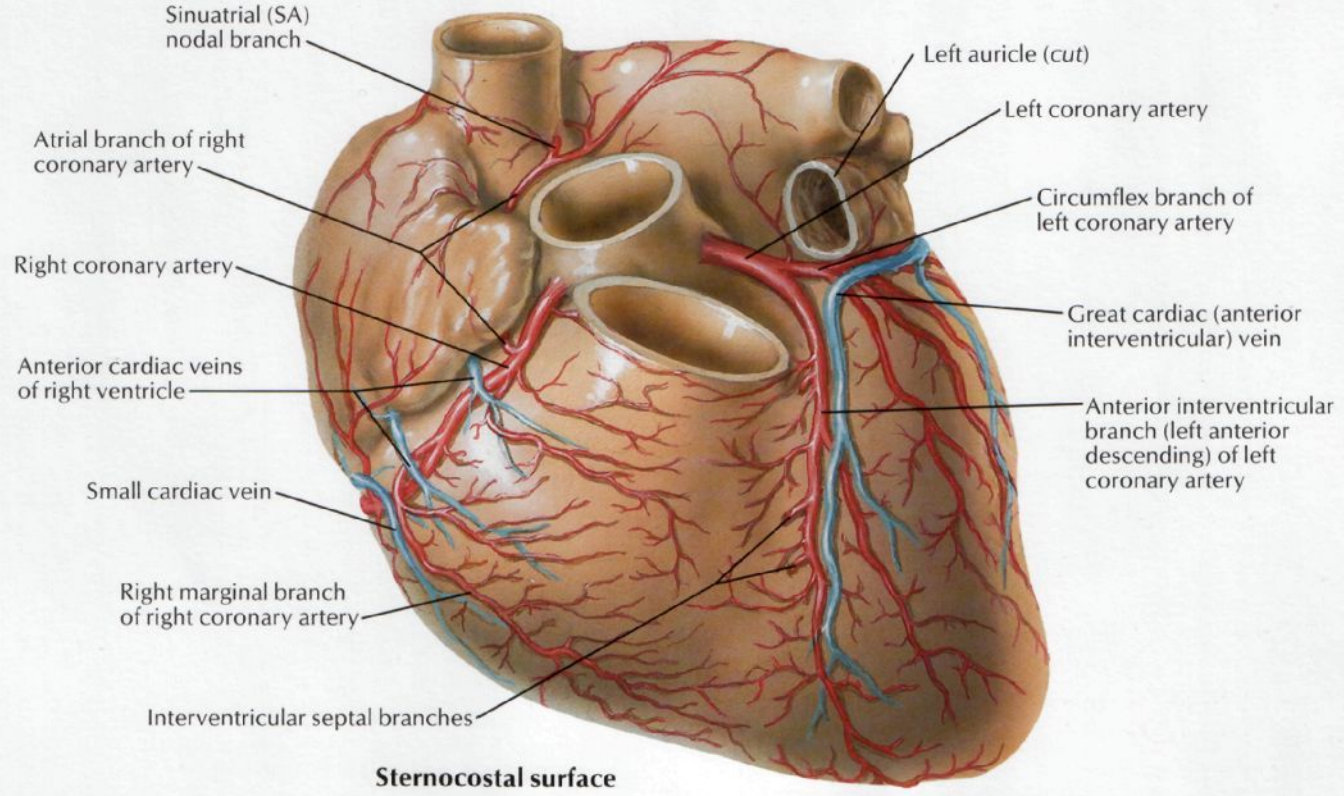

Sternocostal surface

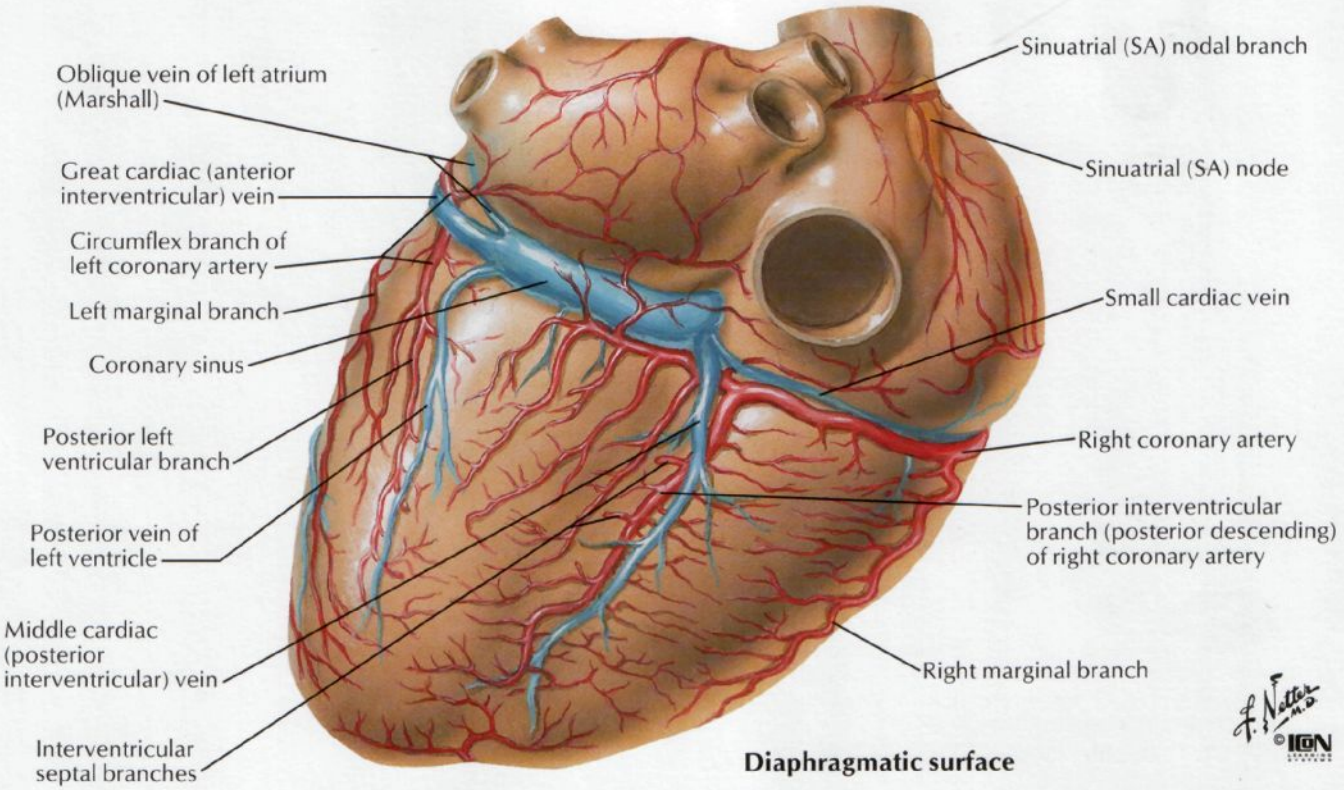

Diaphragmatic surface

F. Netter M.D. ©IGN

Coronary Arteries and Cardiac Veins: Variations

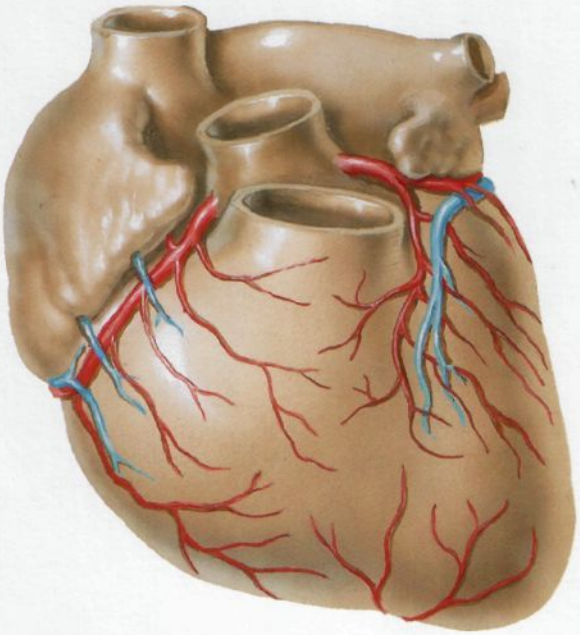

Anterior interventricular (left anterior descending) branch of left coronary artery very short. Apical part of anterior (sternocostal) surface supplied by branches from posterior interventricular (posterior descending) branch of right coronary artery curving around apex

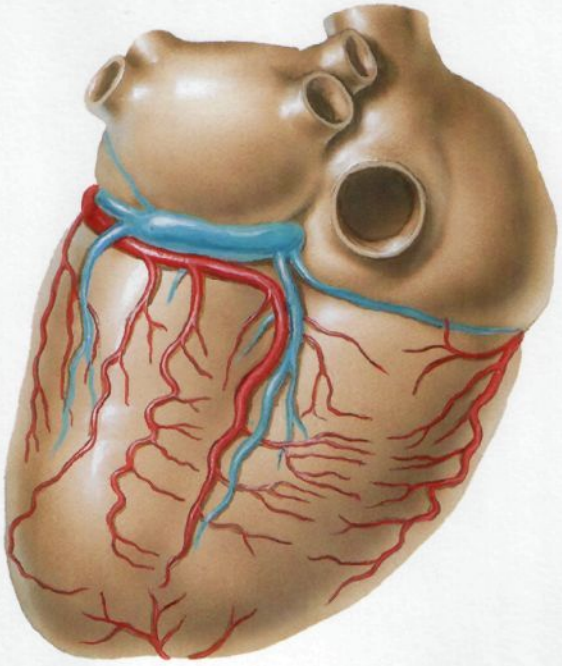

Posterior interventricular (posterior descending) branch derived from circumflex branch of left coronary artery instead of from right coronary artery

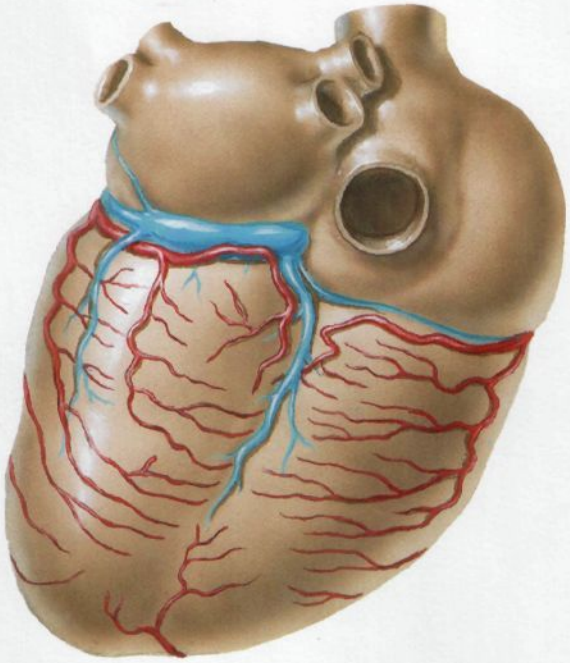

Posterior interventricular (posterior descending) branch absent. Area supplied chiefly by small branches from circumflex branch of left coronary artery and from right coronary artery

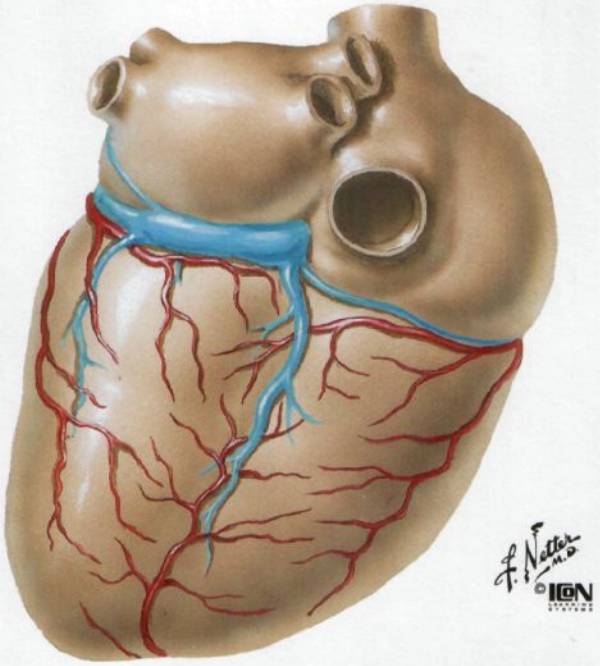

Posterior interventricular (posterior descending) branch absent. Area supplied chiefly by elongated anterior interventricular (left anterior descending) branch curving around apex

Right coronary artery: left anterior oblique view

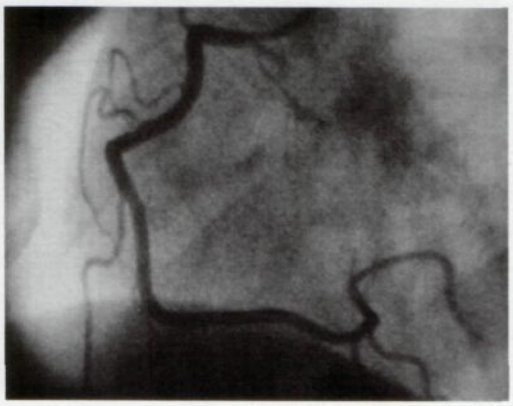

Arteriogram

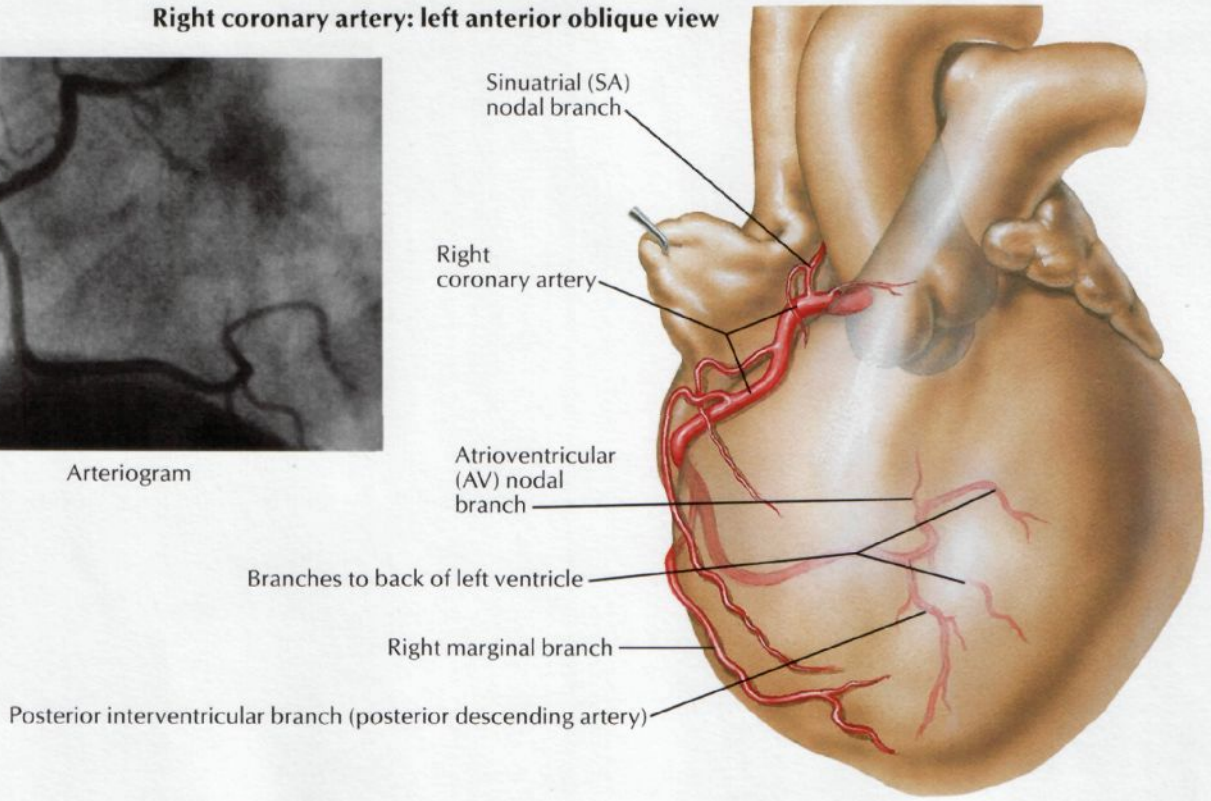

Right coronary artery: right anterior oblique view

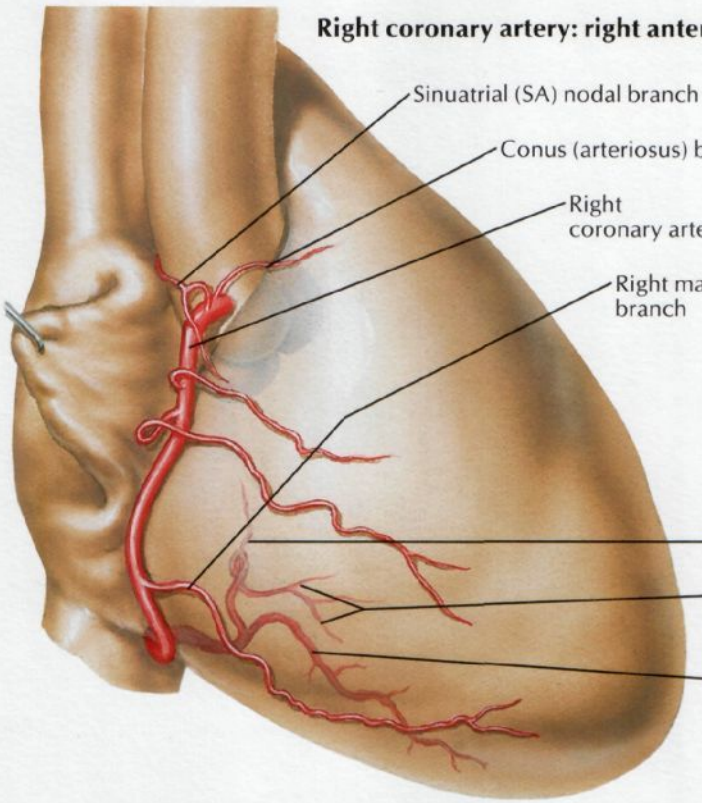

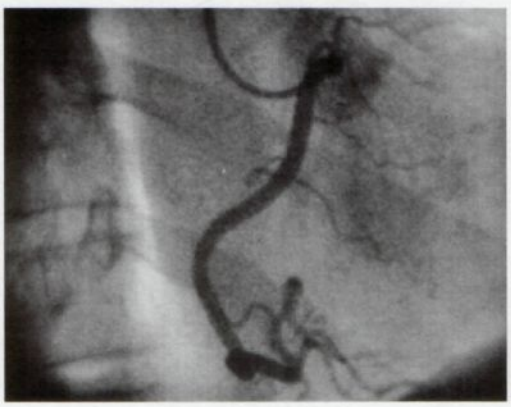

Arteriogram

Coronary Arteries: Arteriographic Views (continued)

Left coronary artery: left anterior oblique view

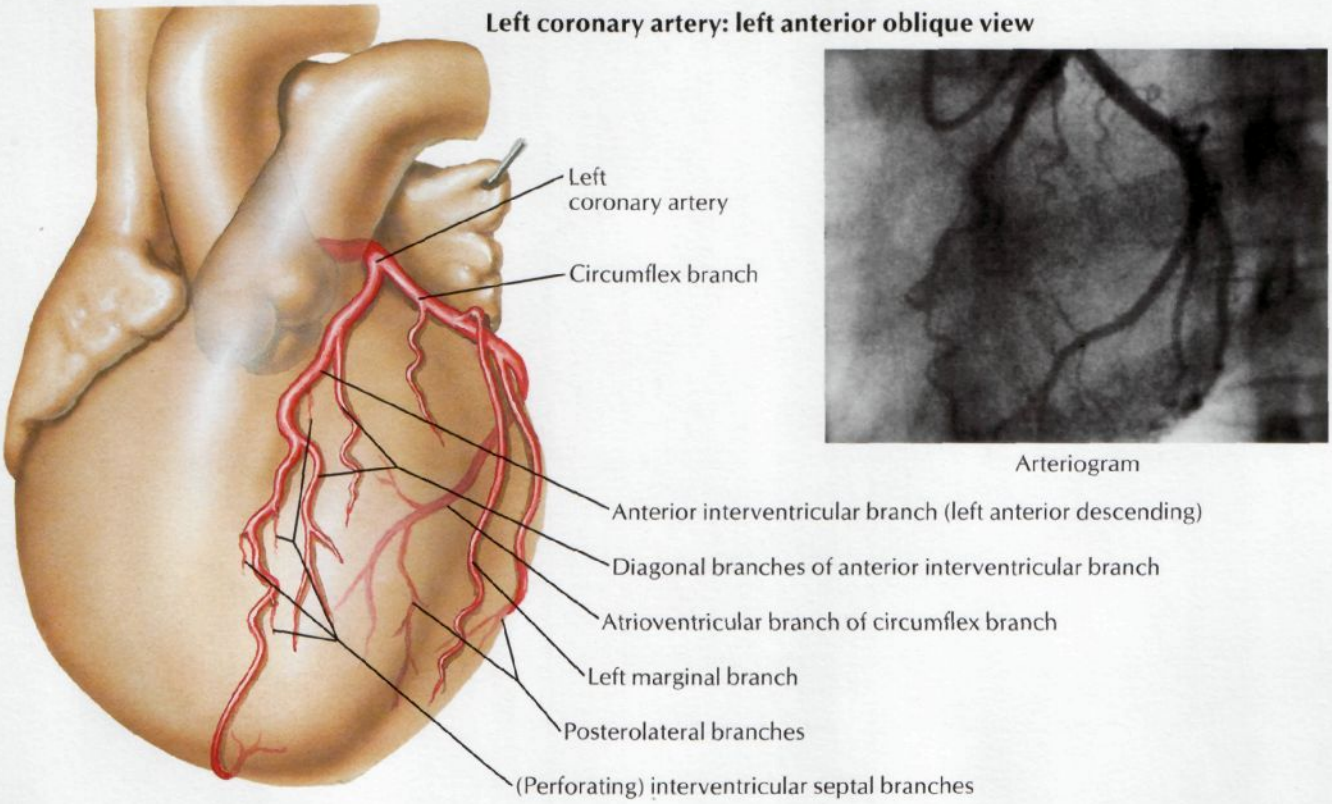

Left coronary artery: right anterior oblique view

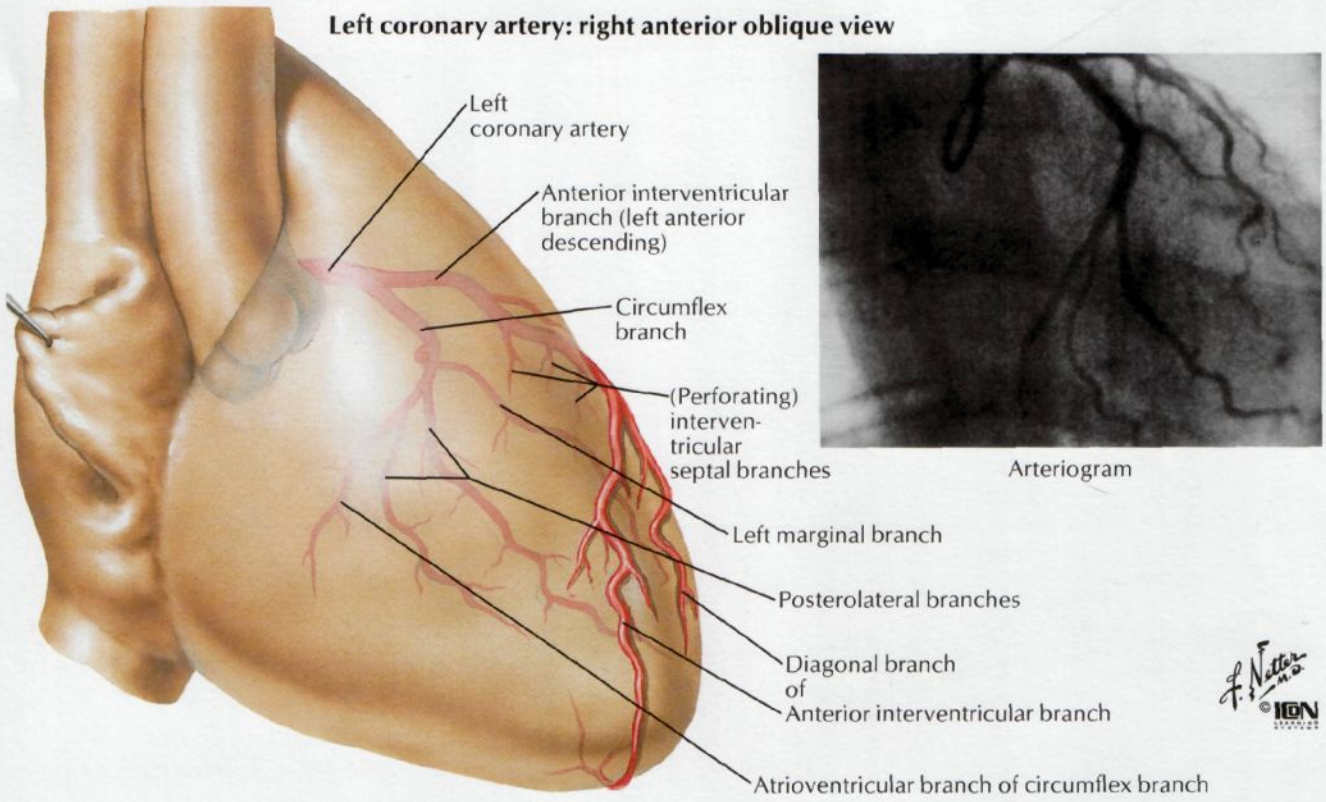

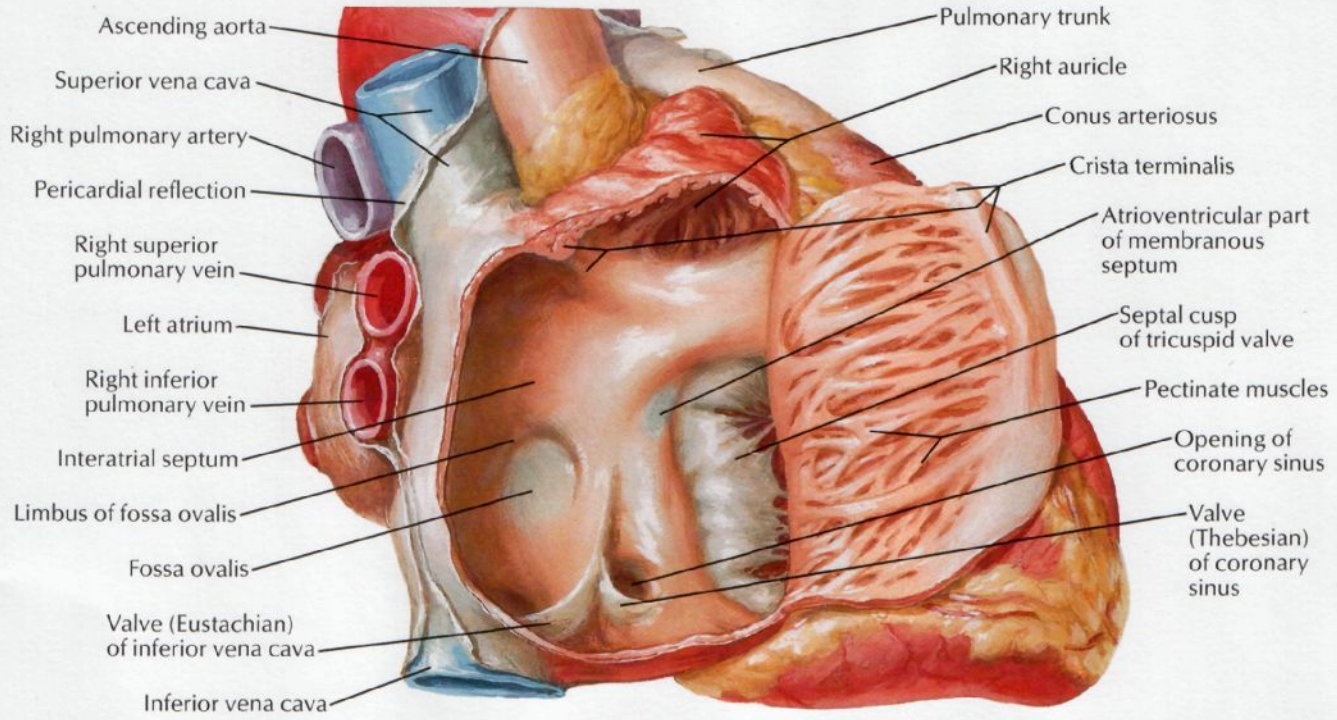

Opened right atrium: right lateral view

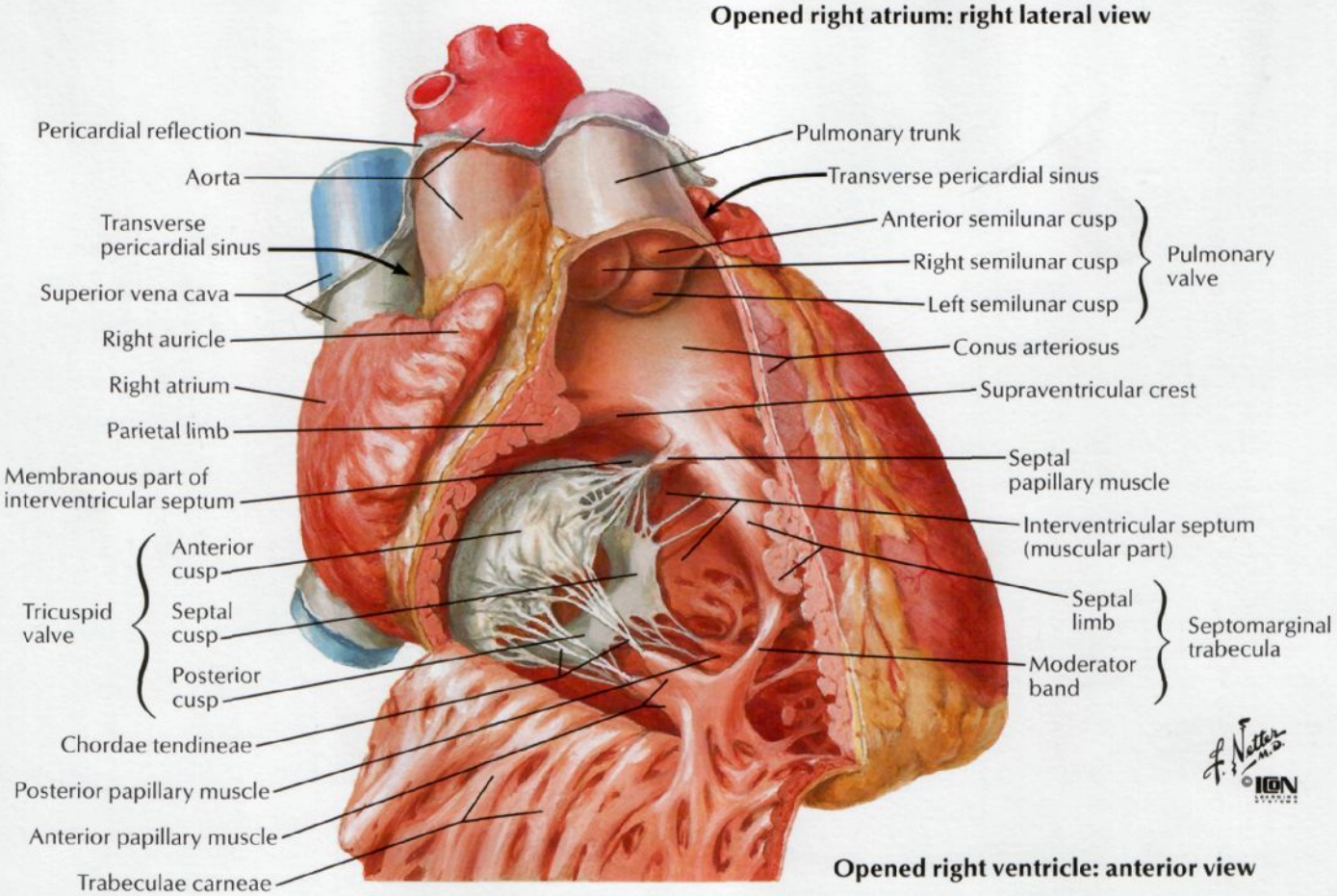

Opened right ventricle: anterior view

Left Atrium and Ventricle

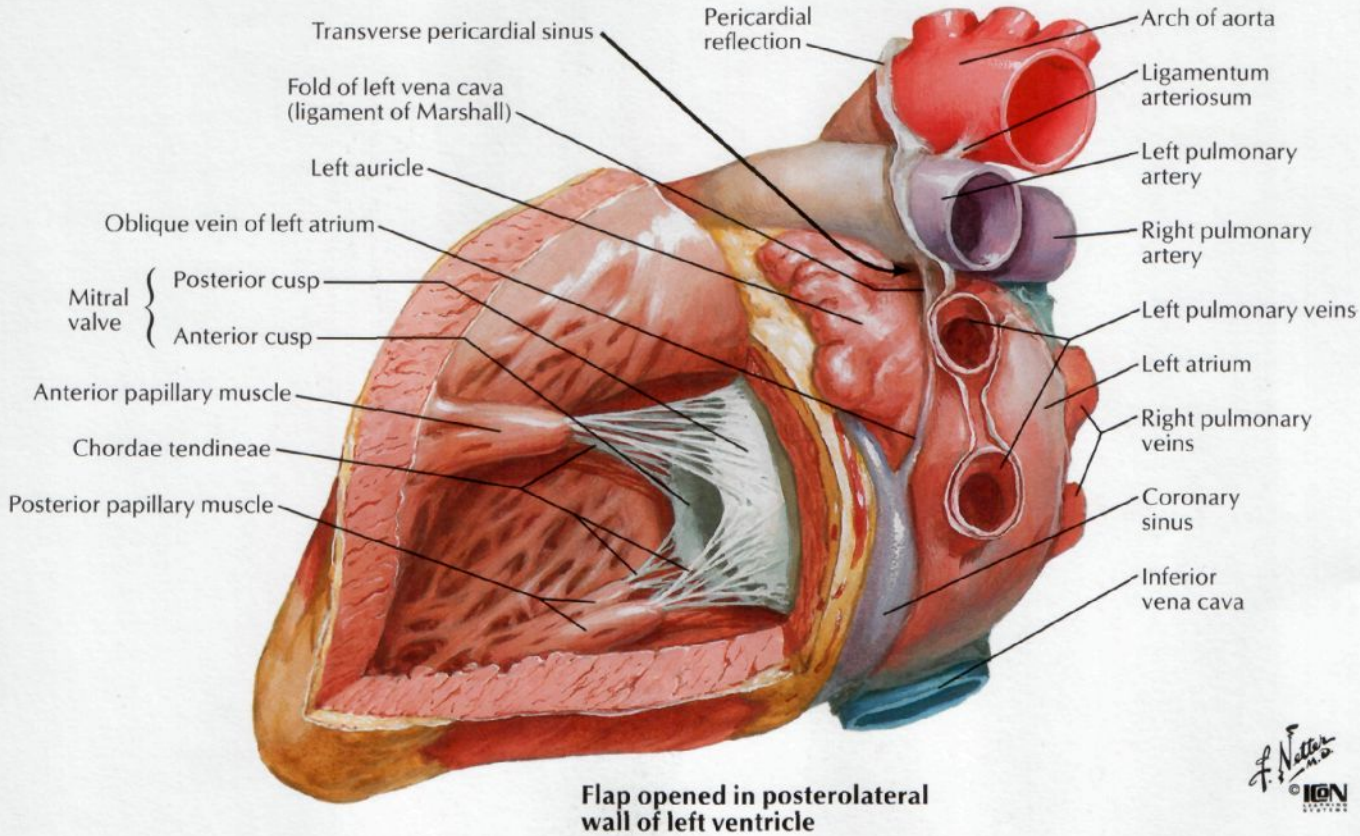

Flap opened in posterolateral wall of left ventricle

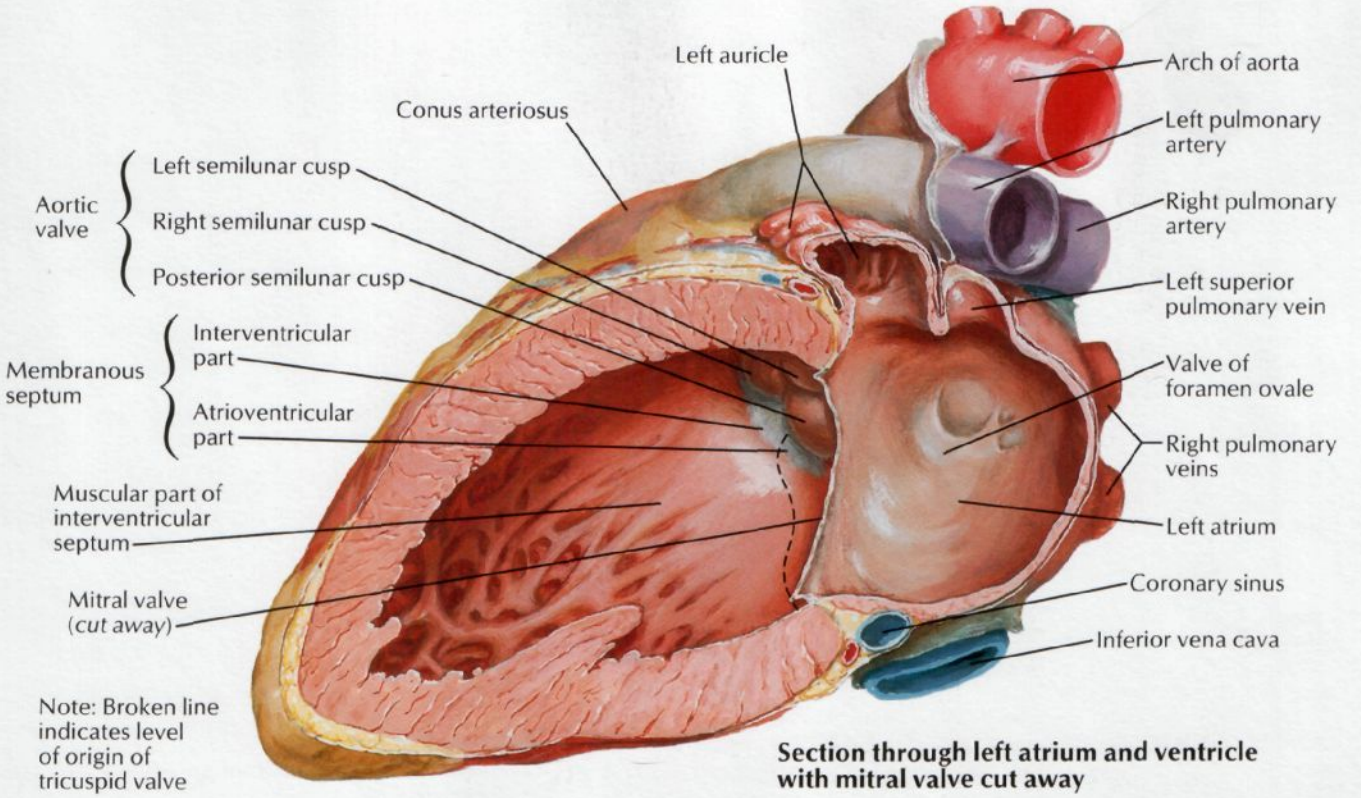

Note: Broken line indicates level of origin of tricuspid valve

Section through left atrium and ventricle with mitral valve cut away

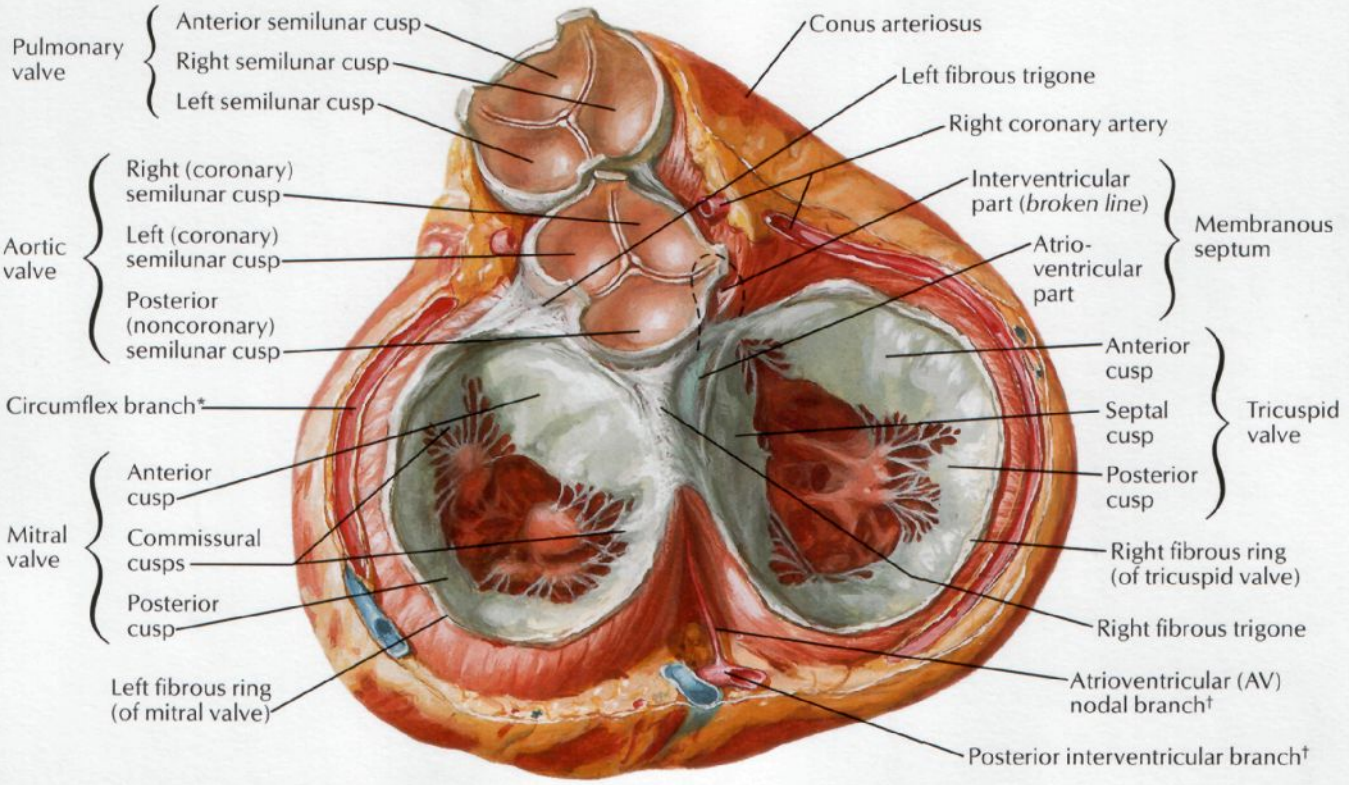

Heart in diastole:
viewed from base with atria removed

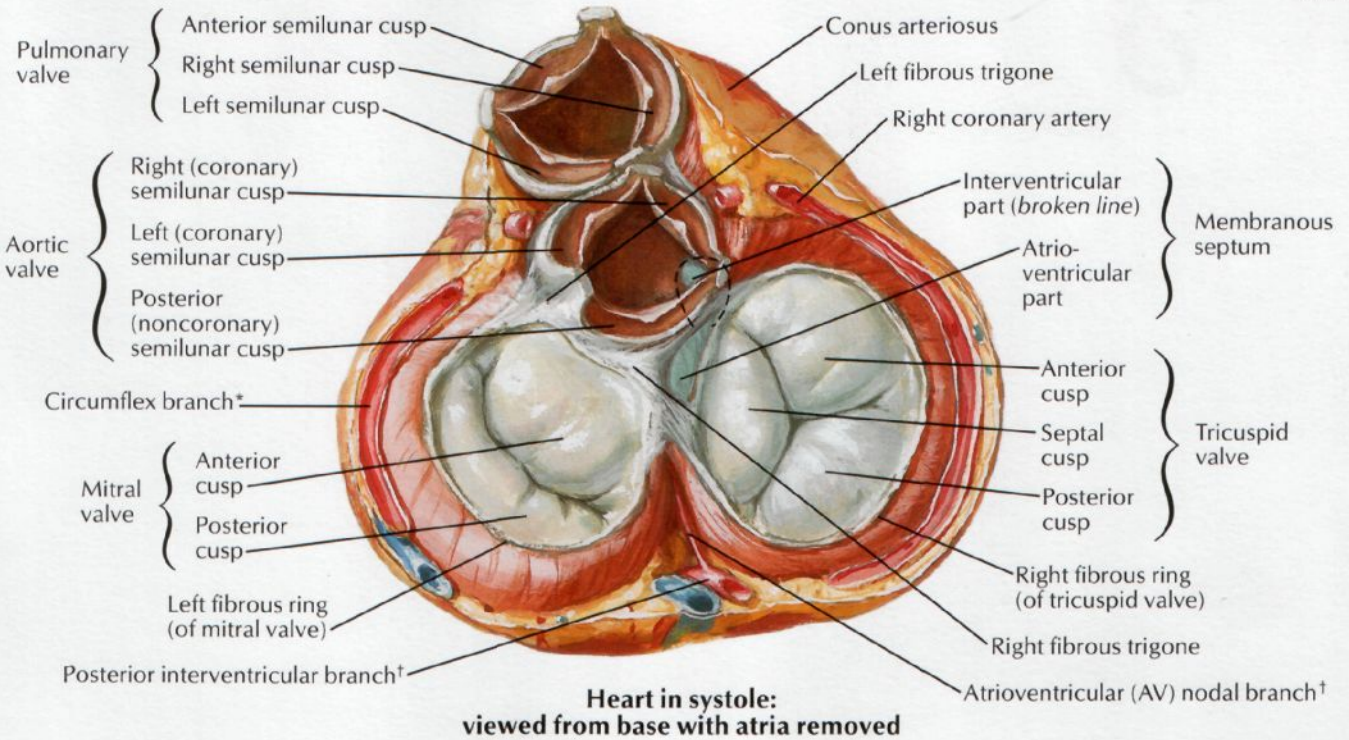

Heart in systole:
viewed from base with atria removed

*Of left coronary artery
†Of right coronary artery

Valves and Fibrous Skeleton of Heart (continued)

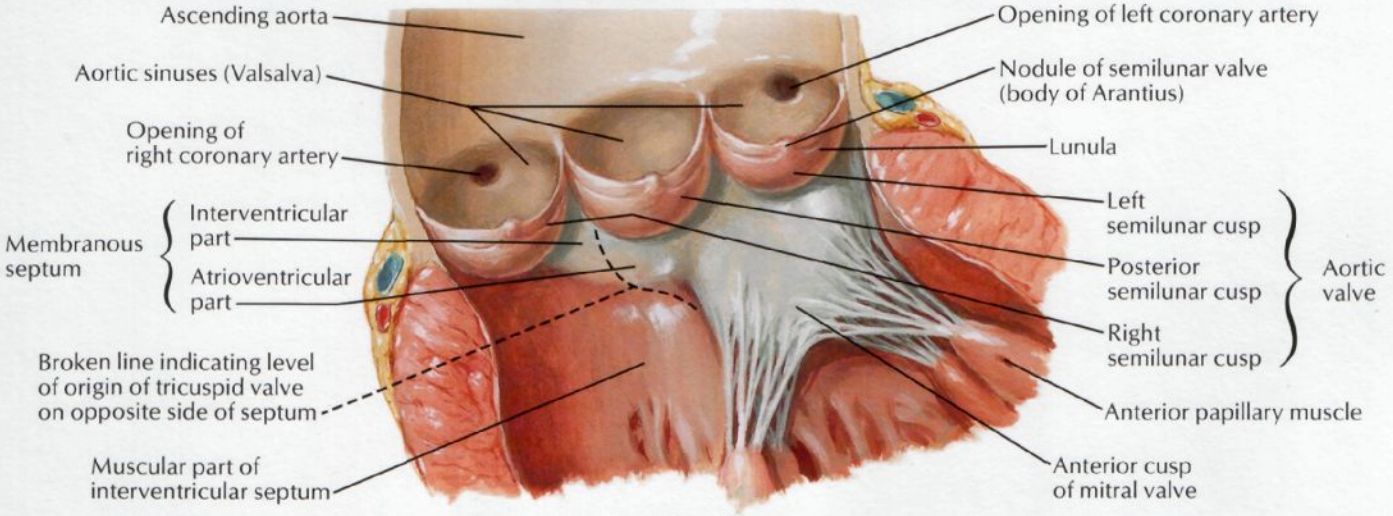

Aortic valve

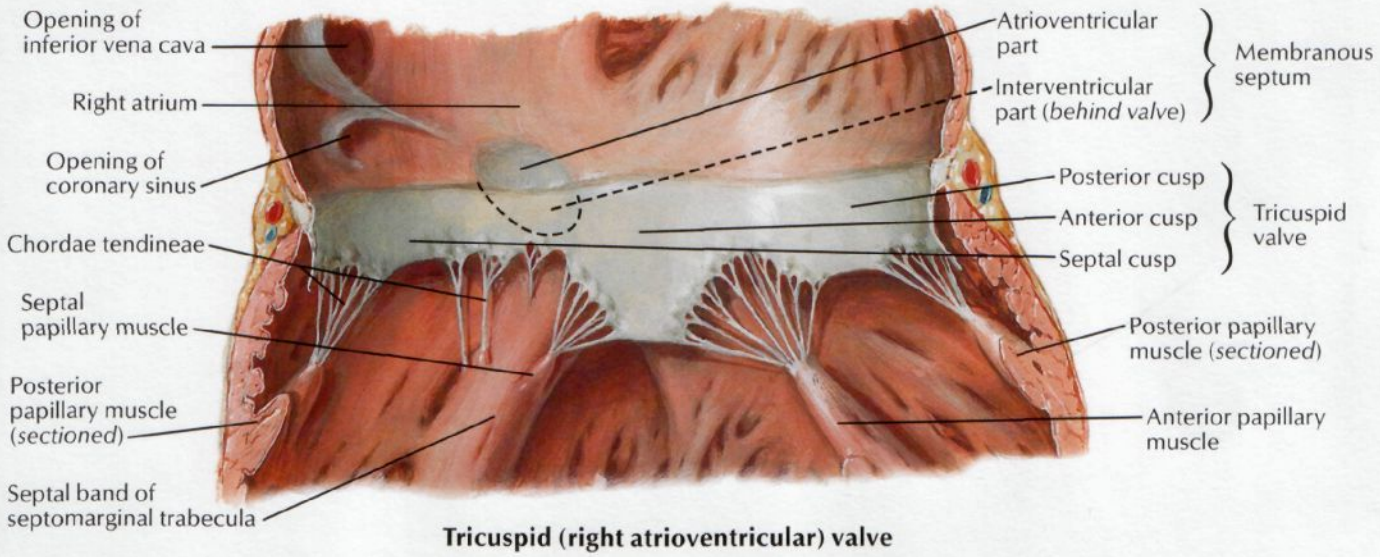

Tricuspid (right atrioventricular) valve

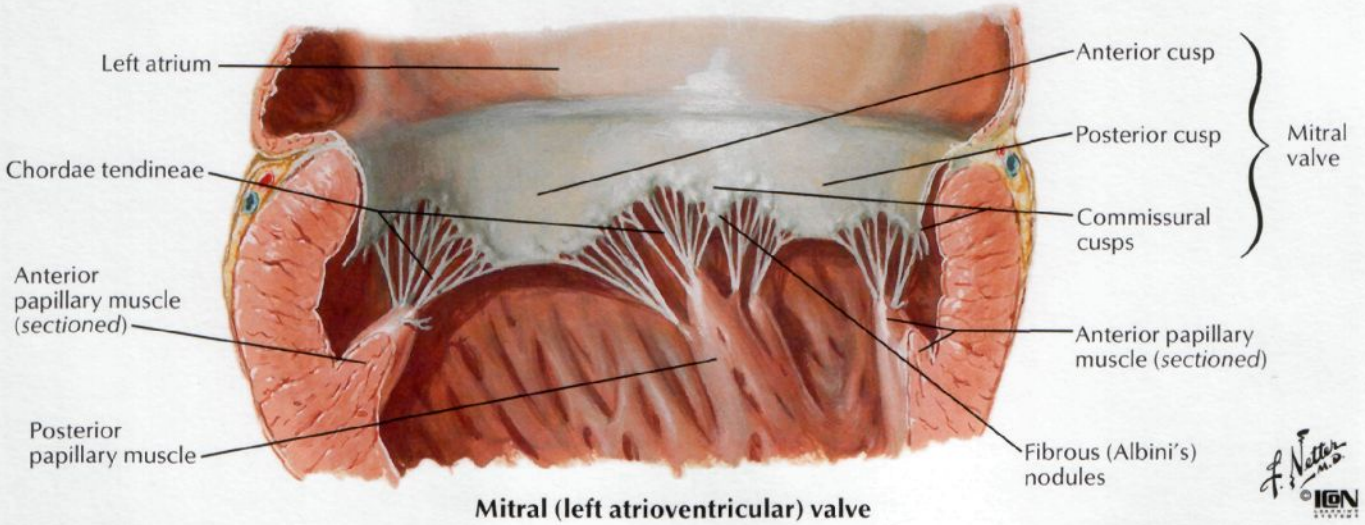

Mitral (left atrioventricular) valve

Atria, Ventricles and Interventricular Septum

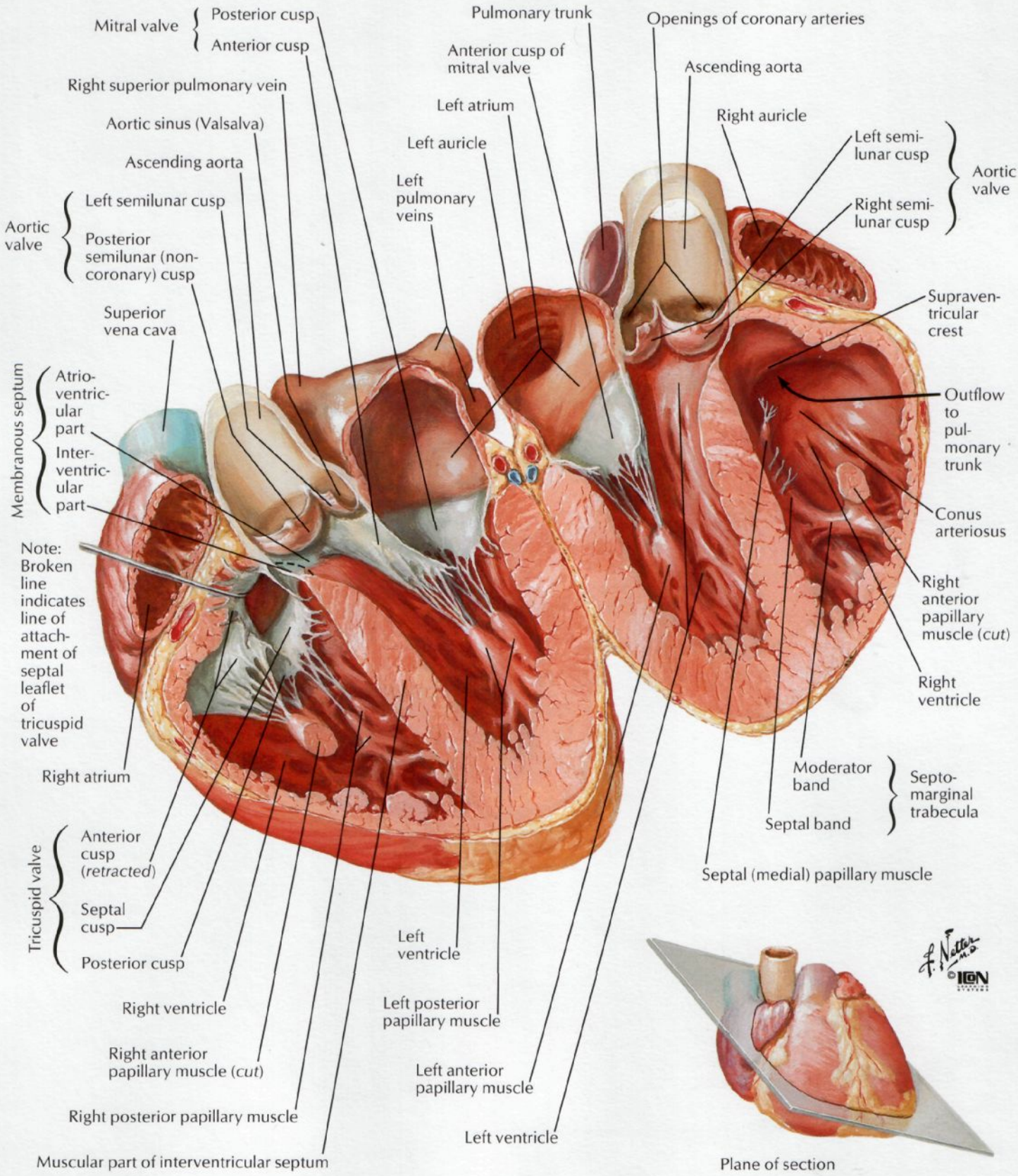

Conducting System of Heart

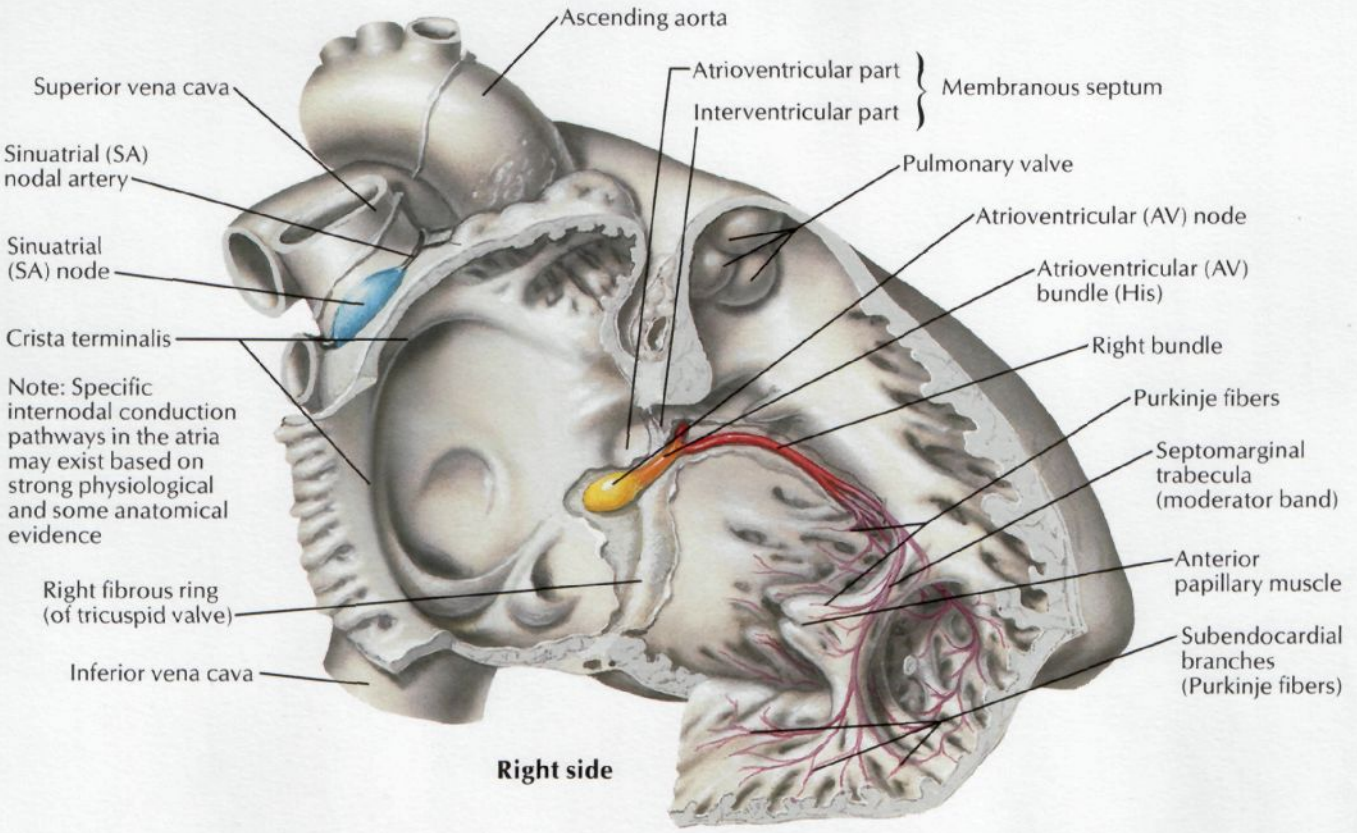

Right side

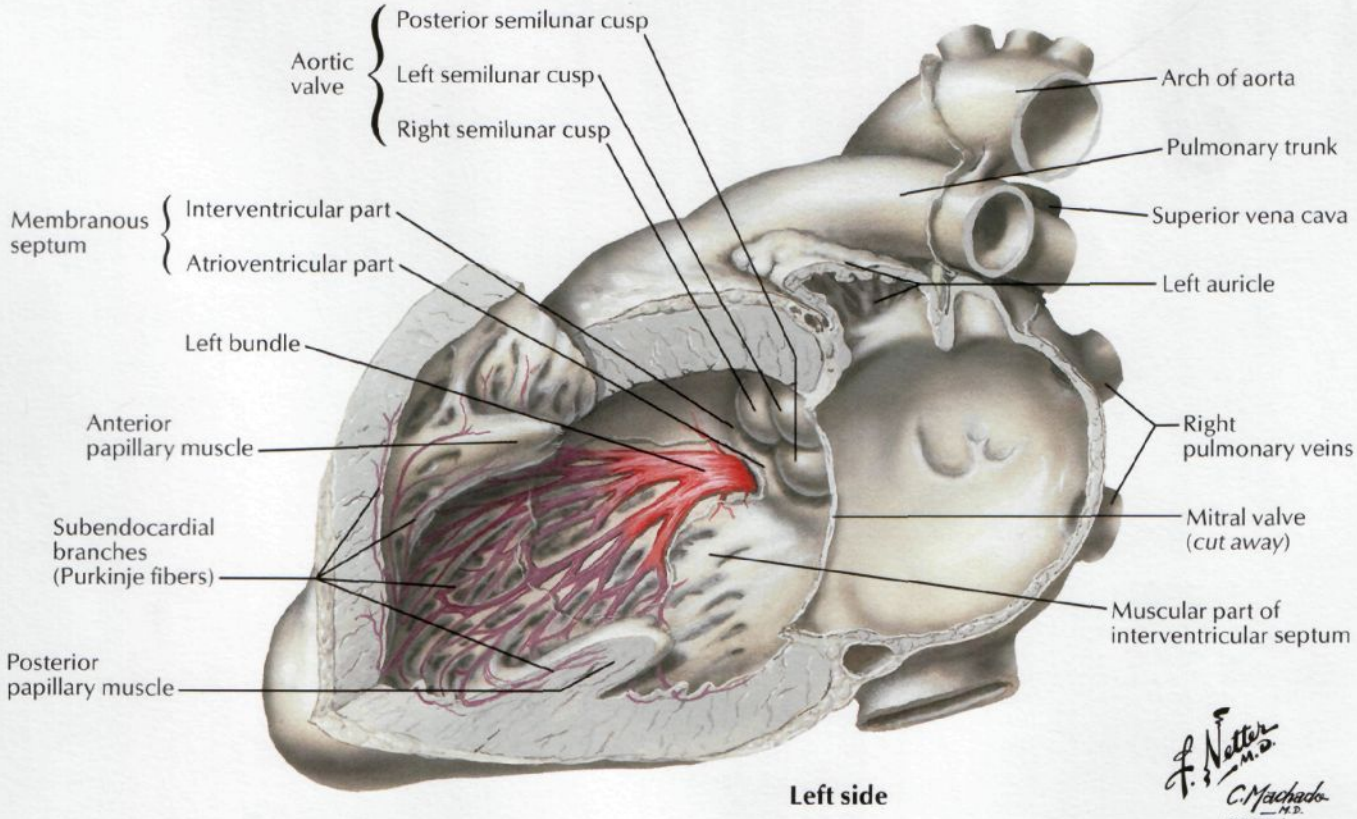

Left side

F. Netter M.D.
C. Machado M.D.
© ICN

SEE ALSO PLATES 124, 159, 205

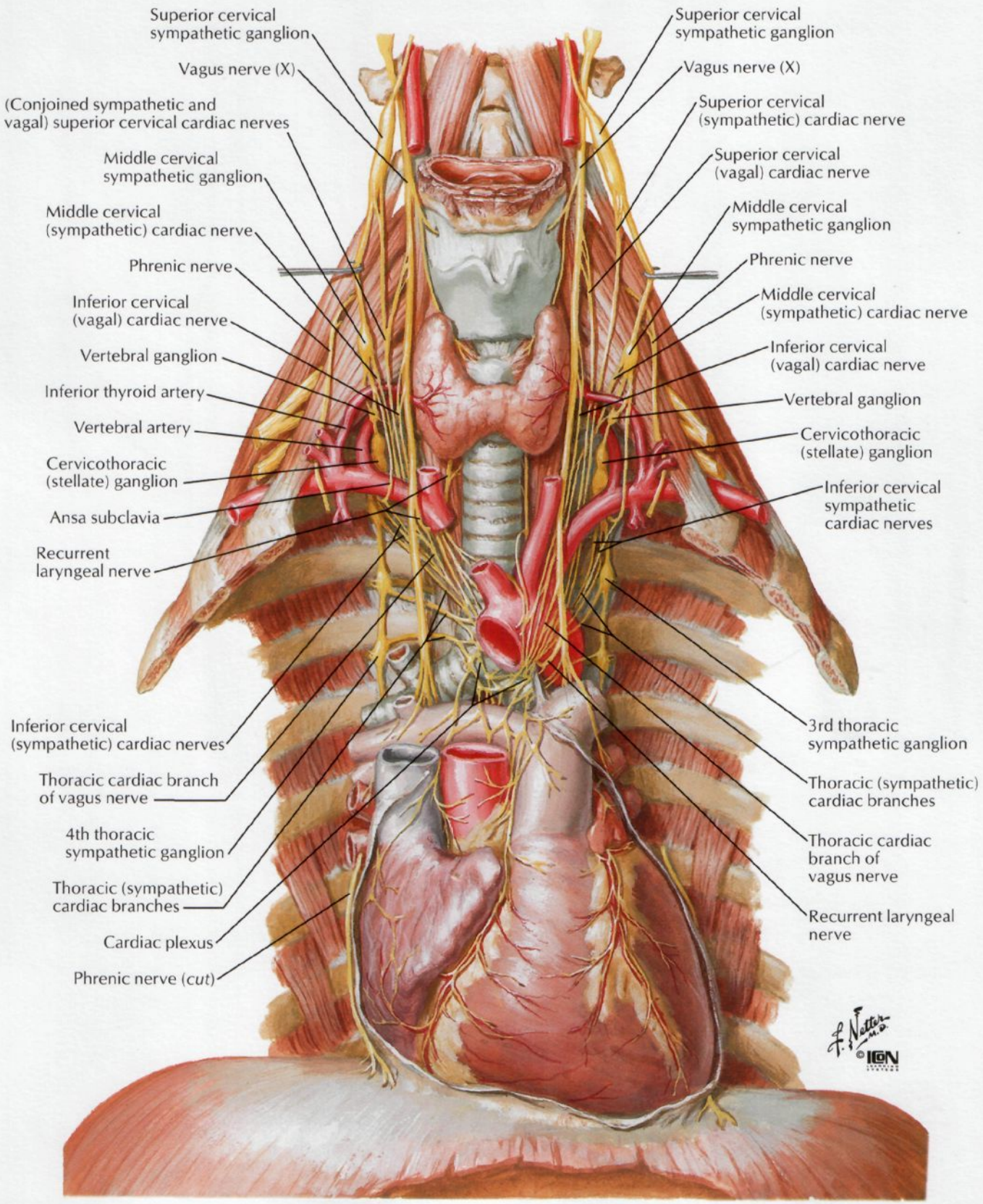

Innervation of Heart: Schema

SEE ALSO PLATES 120, 160

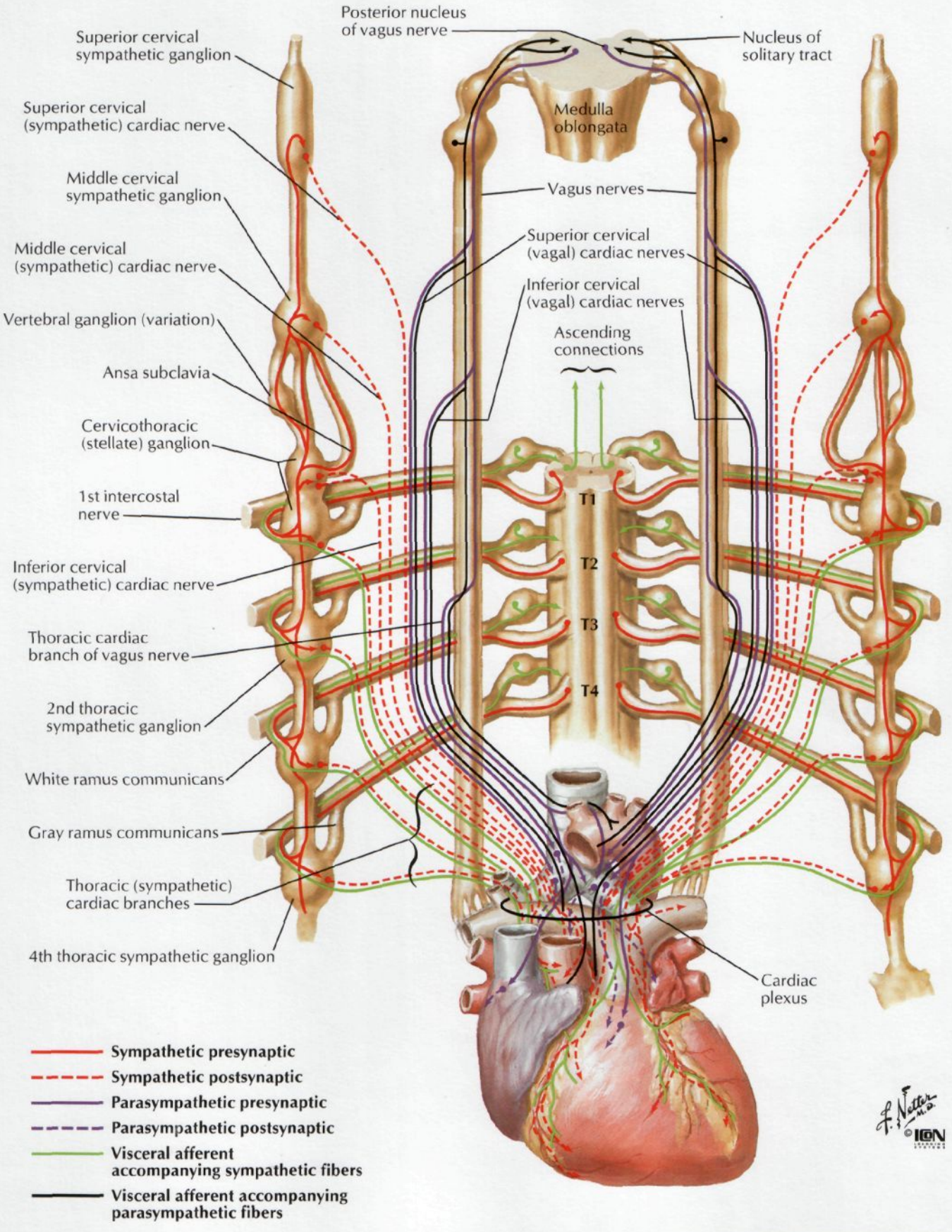

SEE ALSO PLATE 160

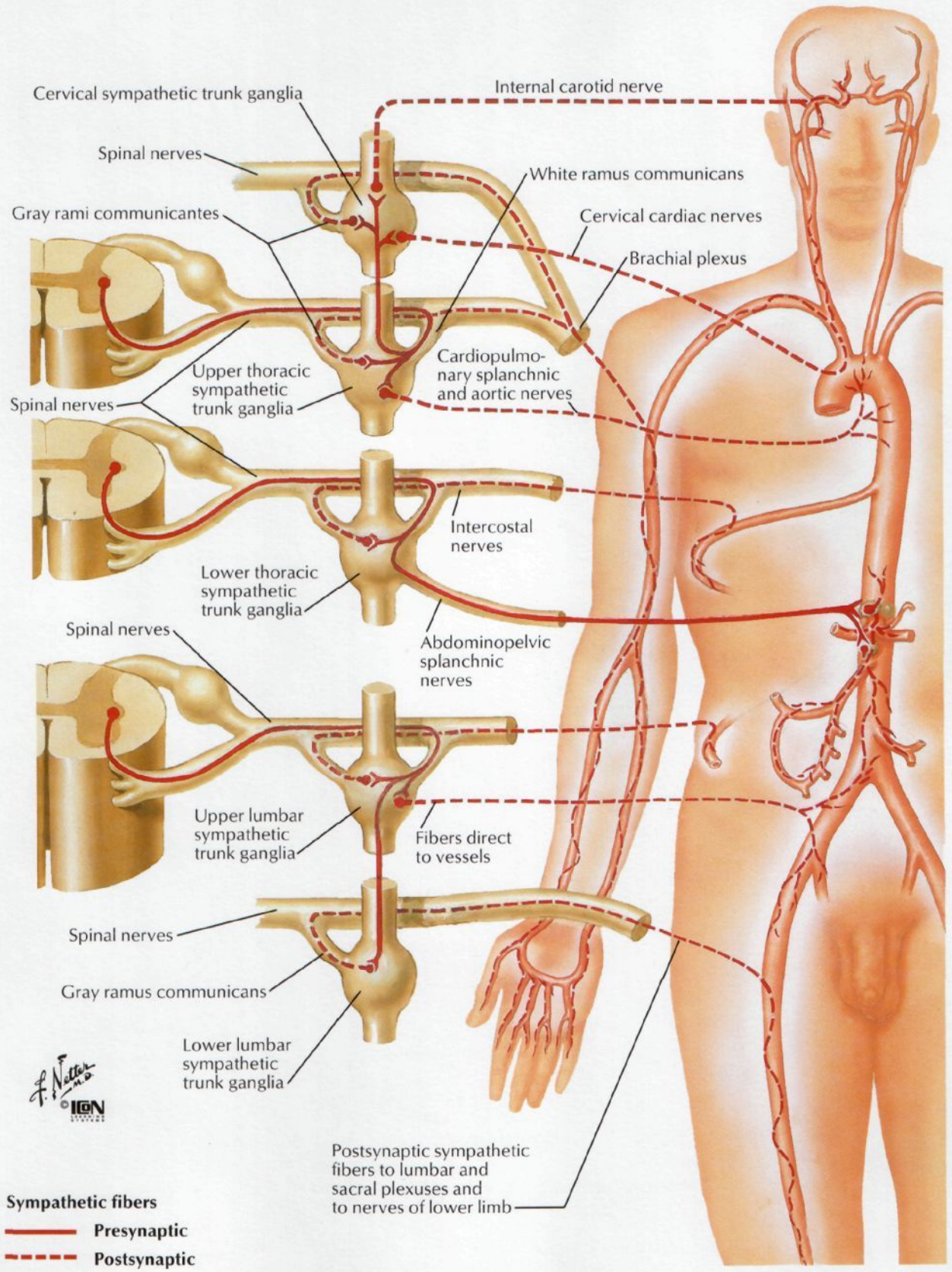

Prenatal and Postnatal Circulation

FOR OCCLUDED PART OF UMBILICAL VESSELS SEE PLATE 245

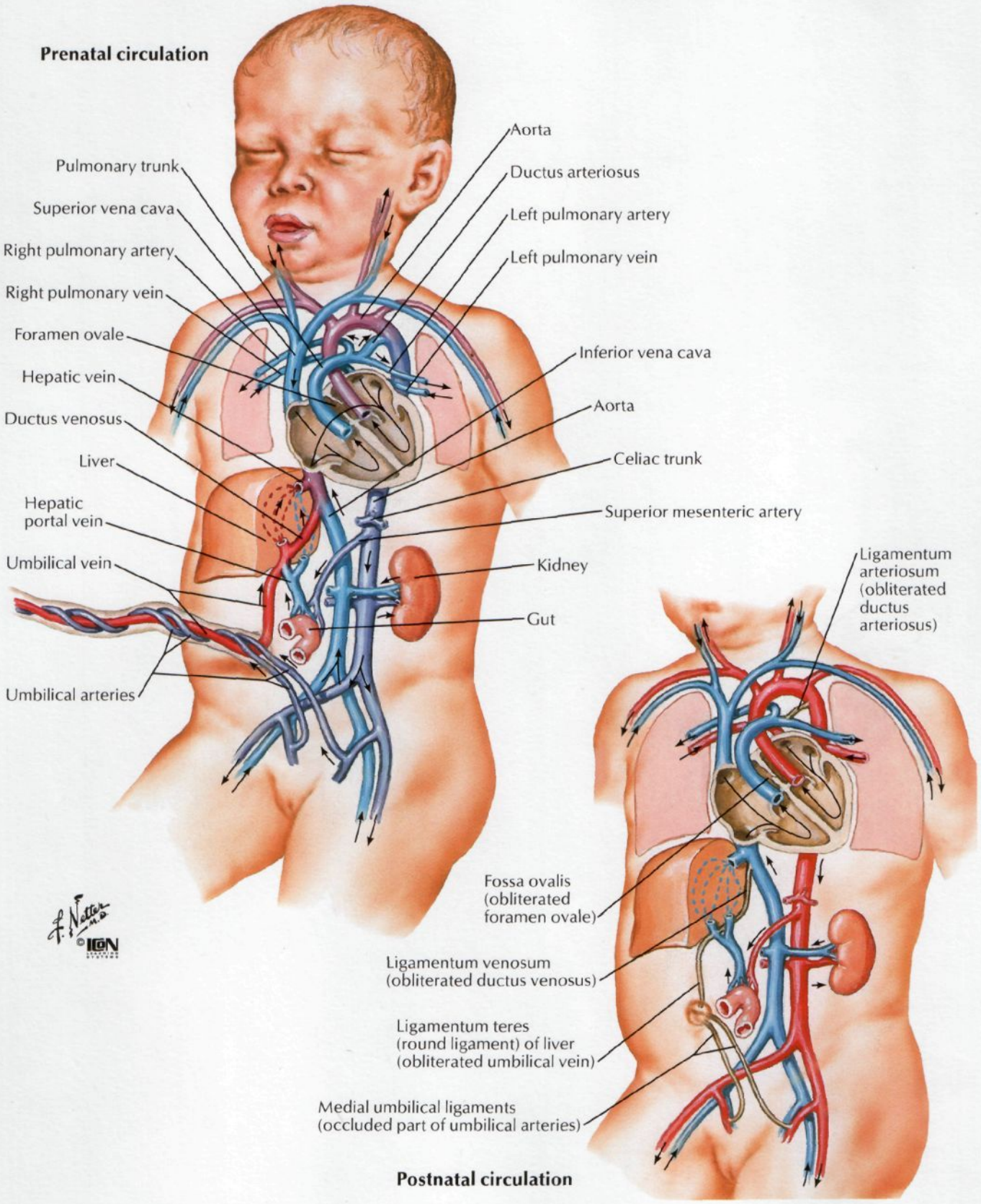

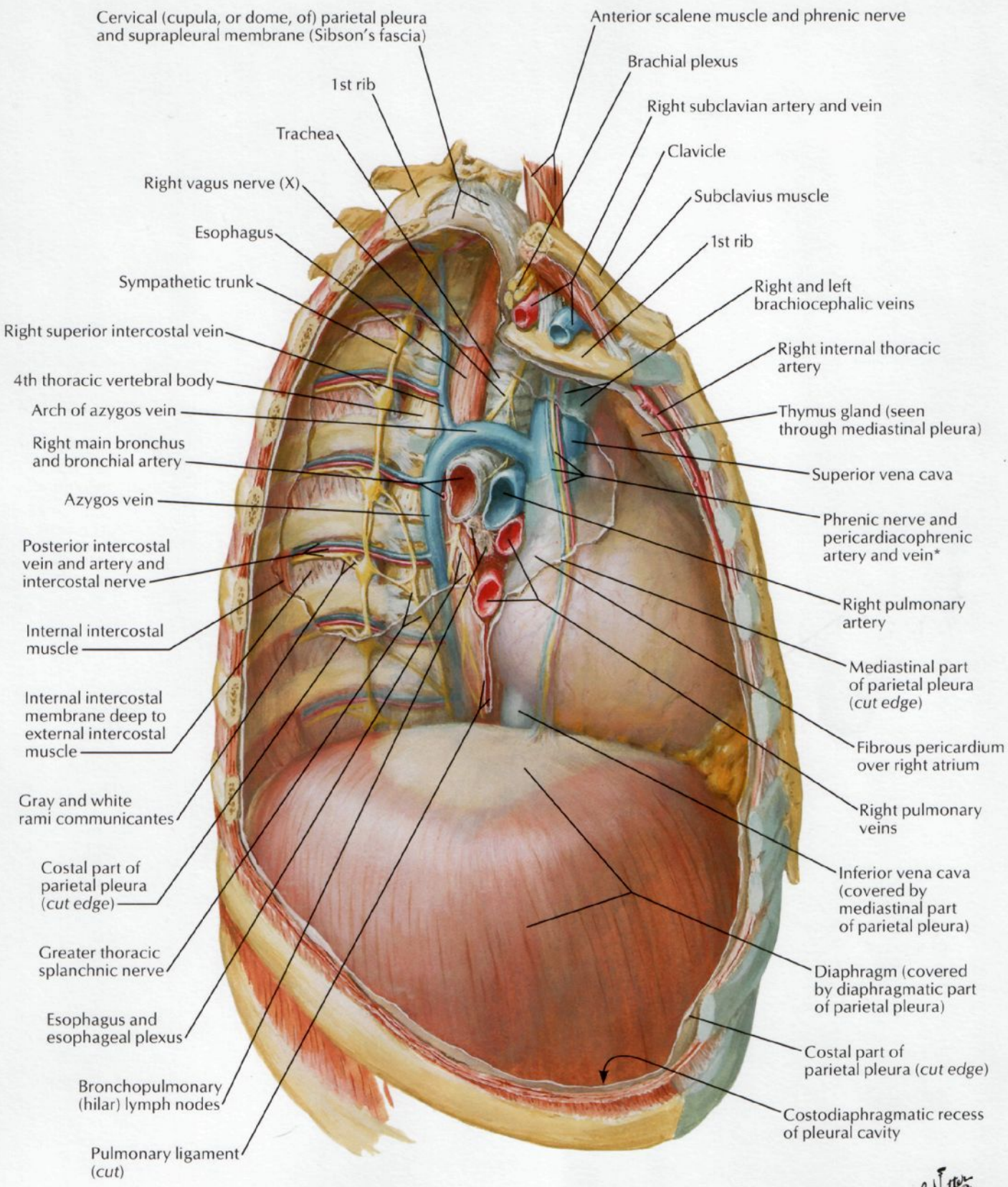

*Nerve and vessels commonly run independently

Mediastinum: Left Lateral View

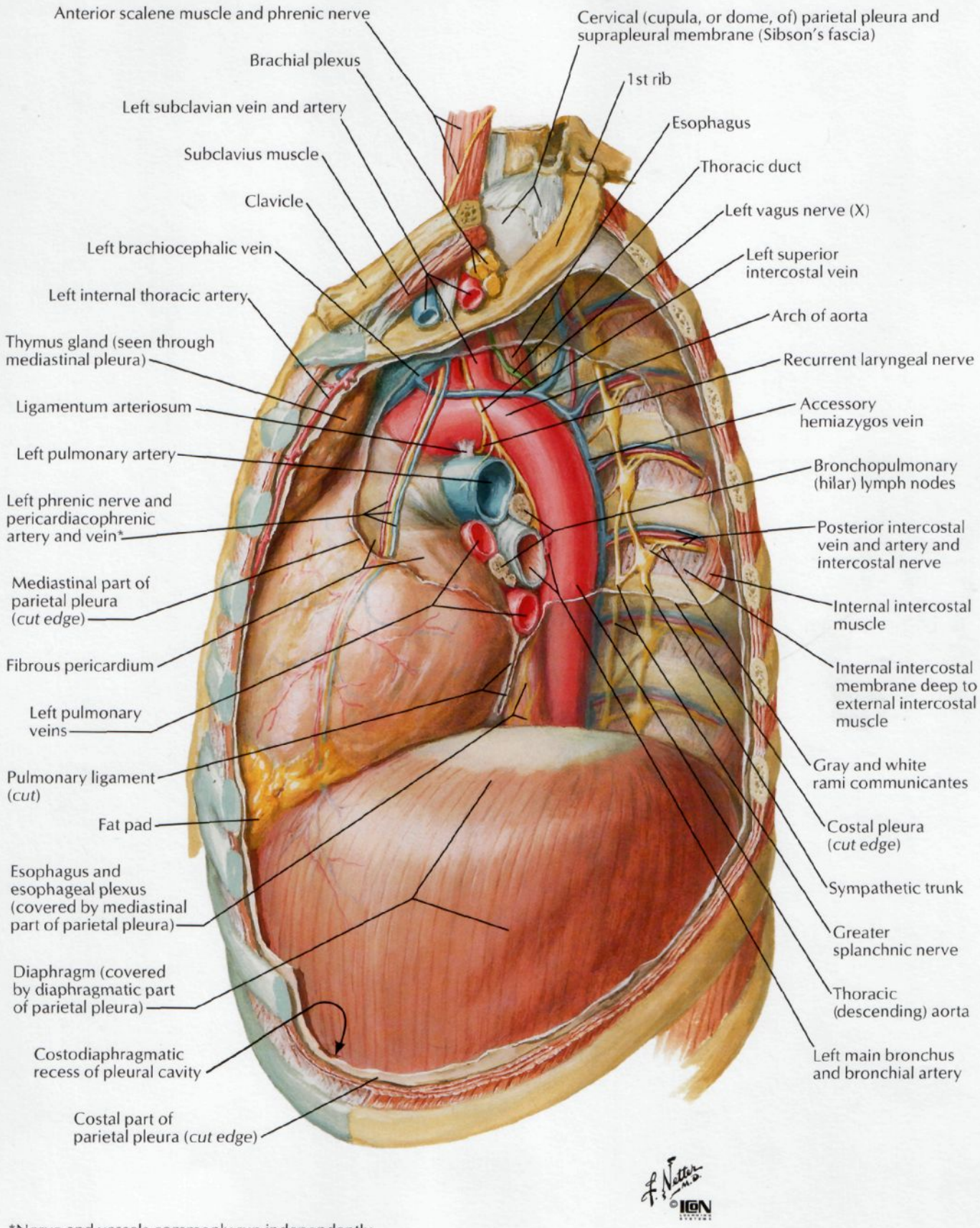

*Nerve and vessels commonly run independently

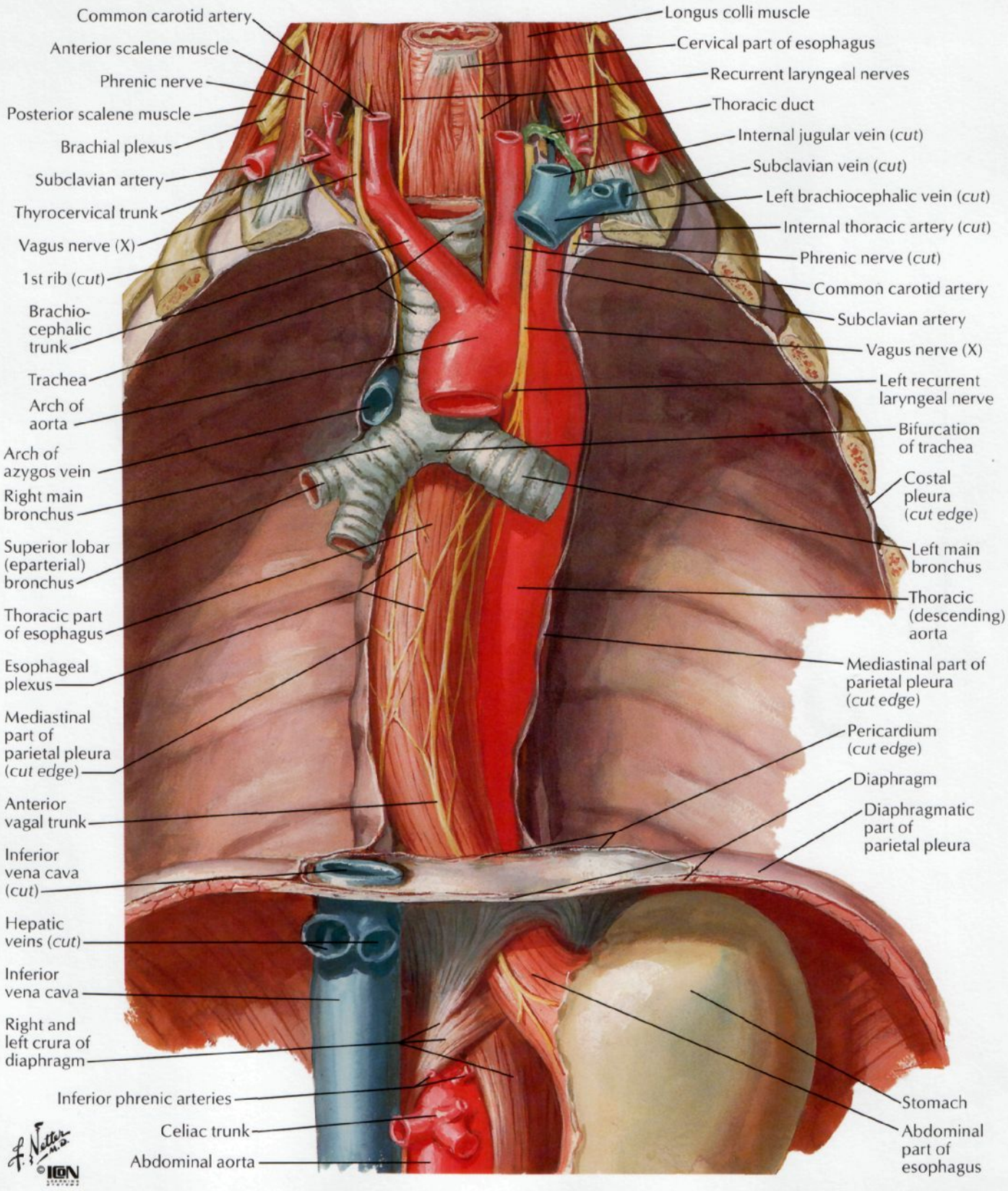
Common carotid artery
Anterior scalene muscle
Phrenic nerve
Posterior scalene muscle
Brachial plexus
Subclavian artery
Thyrocervical trunk
Vagus nerve (X)
1st rib (cut)
Brachio-cephalic trunk
Trachea
Arch of aorta
Arch of azygos vein
Right main bronchus
Superior lobar (eparterial) bronchus
Thoracic part of esophagus
Esophageal plexus
Mediastinal part of parietal pleura (cut edge)
Anterior vagal trunk
Inferior vena cava (cut)
Hepatic veins (cut)
Inferior vena cava
Right and left crura of diaphragm
Inferior phrenic arteries
Celiac trunk
Abdominal aorta
Longus colli muscle
Cervical part of esophagus
Recurrent laryngeal nerves
Thoracic duct
Internal jugular vein (cut)
Subclavian vein (cut)
Left brachiocephalic vein (cut)
Internal thoracic artery (cut)
Phrenic nerve (cut)
Common carotid artery
Subclavian artery
Vagus nerve (X)
Left recurrent laryngeal nerve
Bifurcation of trachea
Costal pleura (cut edge)
Left main bronchus
Thoracic (descending) aorta
Mediastinal part of parietal pleura (cut edge)
Pericardium (cut edge)
Diaphragm
Diaphragmatic part of parietal pleura
Stomach
Abdominal part of esophagus

Topography and Constrictions of Esophagus

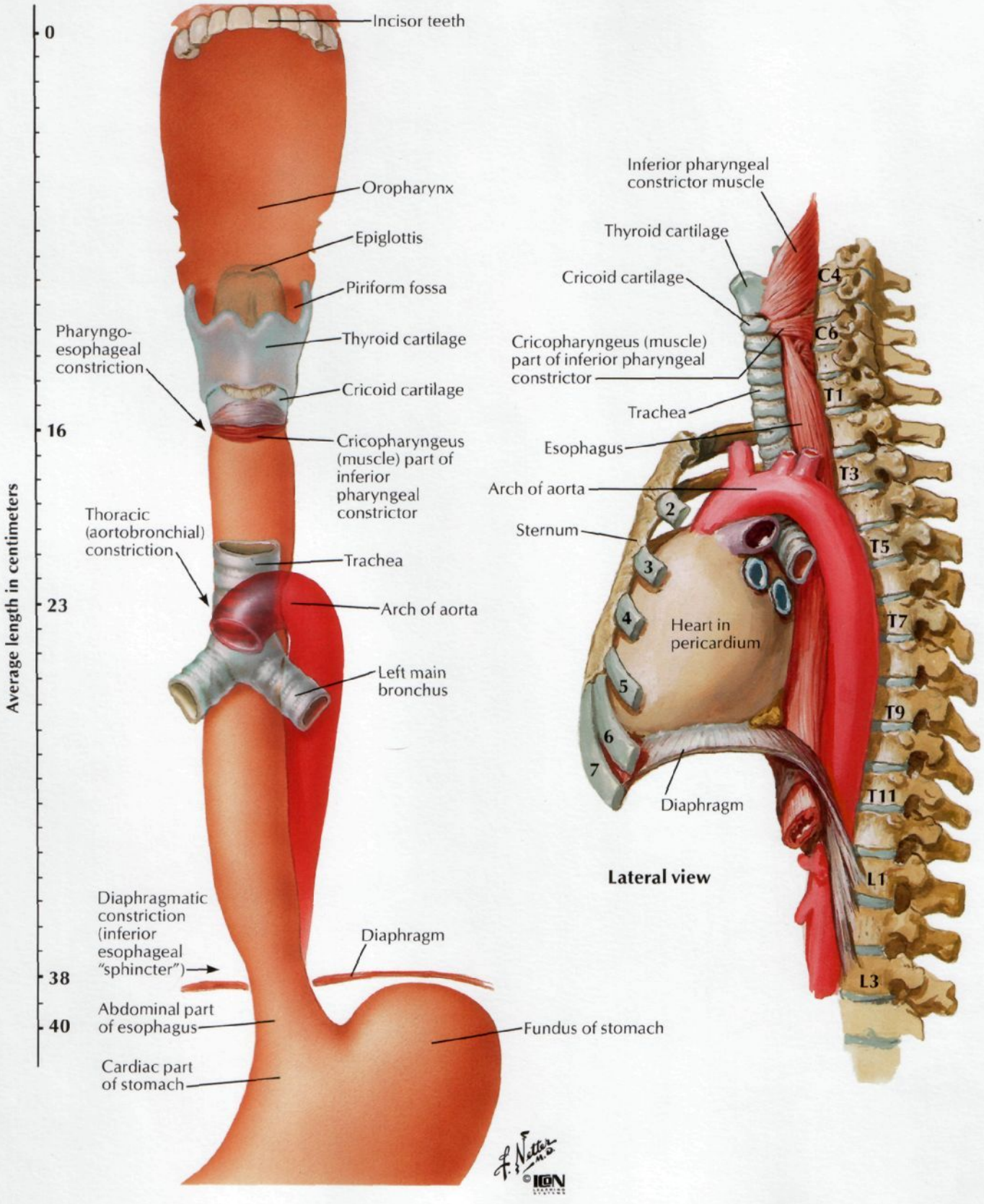

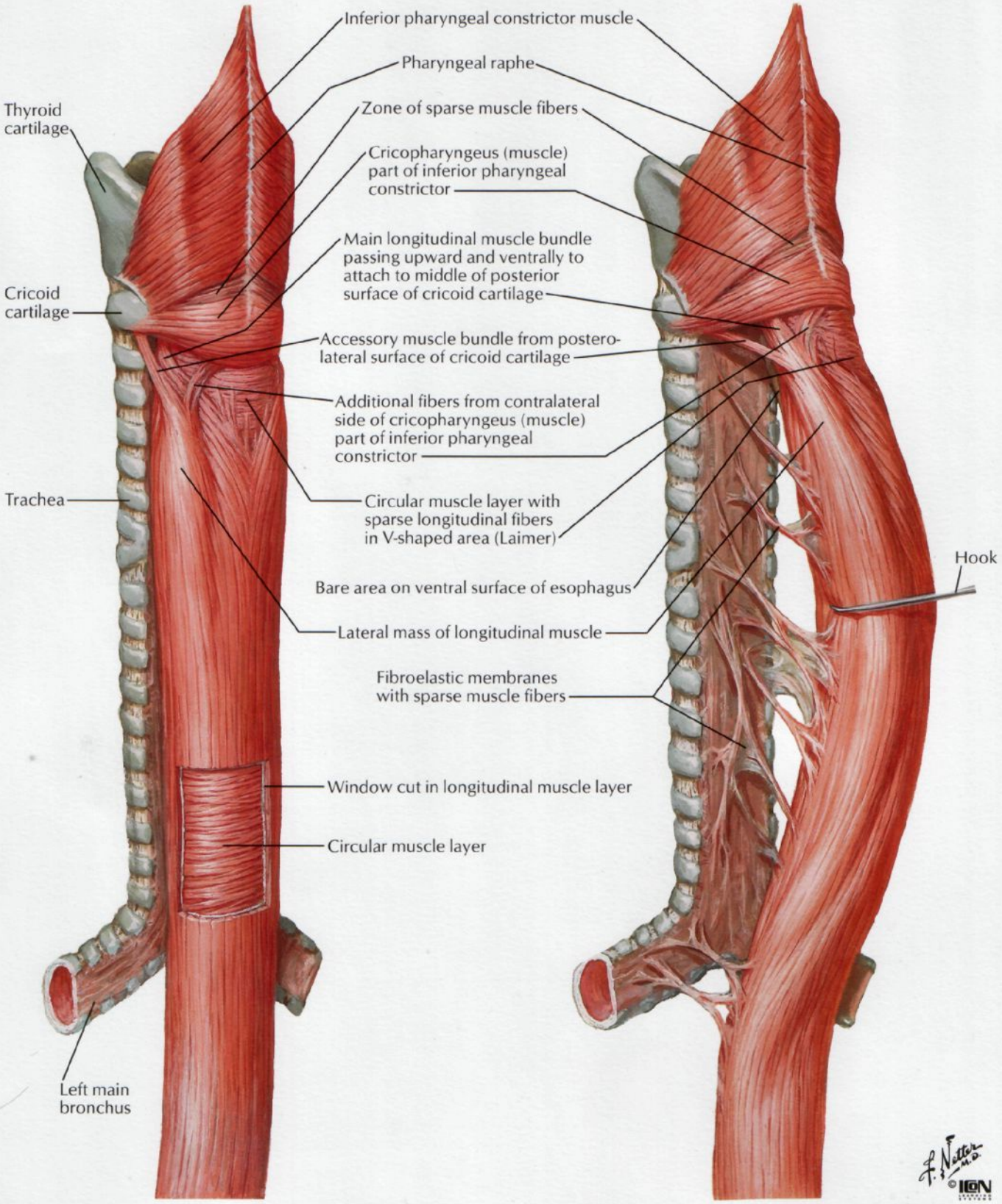
Inferior pharyngeal constrictor muscle
Pharyngeal raphe
Thyroid cartilage
Zone of sparse muscle fibers
Cricopharyngeus (muscle) part of inferior pharyngeal constrictor
Main longitudinal muscle bundle passing upward and ventrally to attach to middle of posterior surface of cricoid cartilage
Cricoid cartilage
Accessory muscle bundle from postero-lateral surface of cricoid cartilage
Additional fibers from contralateral side of cricopharyngeus (muscle) part of inferior pharyngeal constrictor
Trachea
Circular muscle layer with sparse longitudinal fibers in V-shaped area (Laimer)
Hook
Bare area on ventral surface of esophagus
Lateral mass of longitudinal muscle
Fibroelastic membranes with sparse muscle fibers
Window cut in longitudinal muscle layer
Circular muscle layer
Left main bronchus

Pharyngoesophageal Junction

SEE ALSO PLATE 63

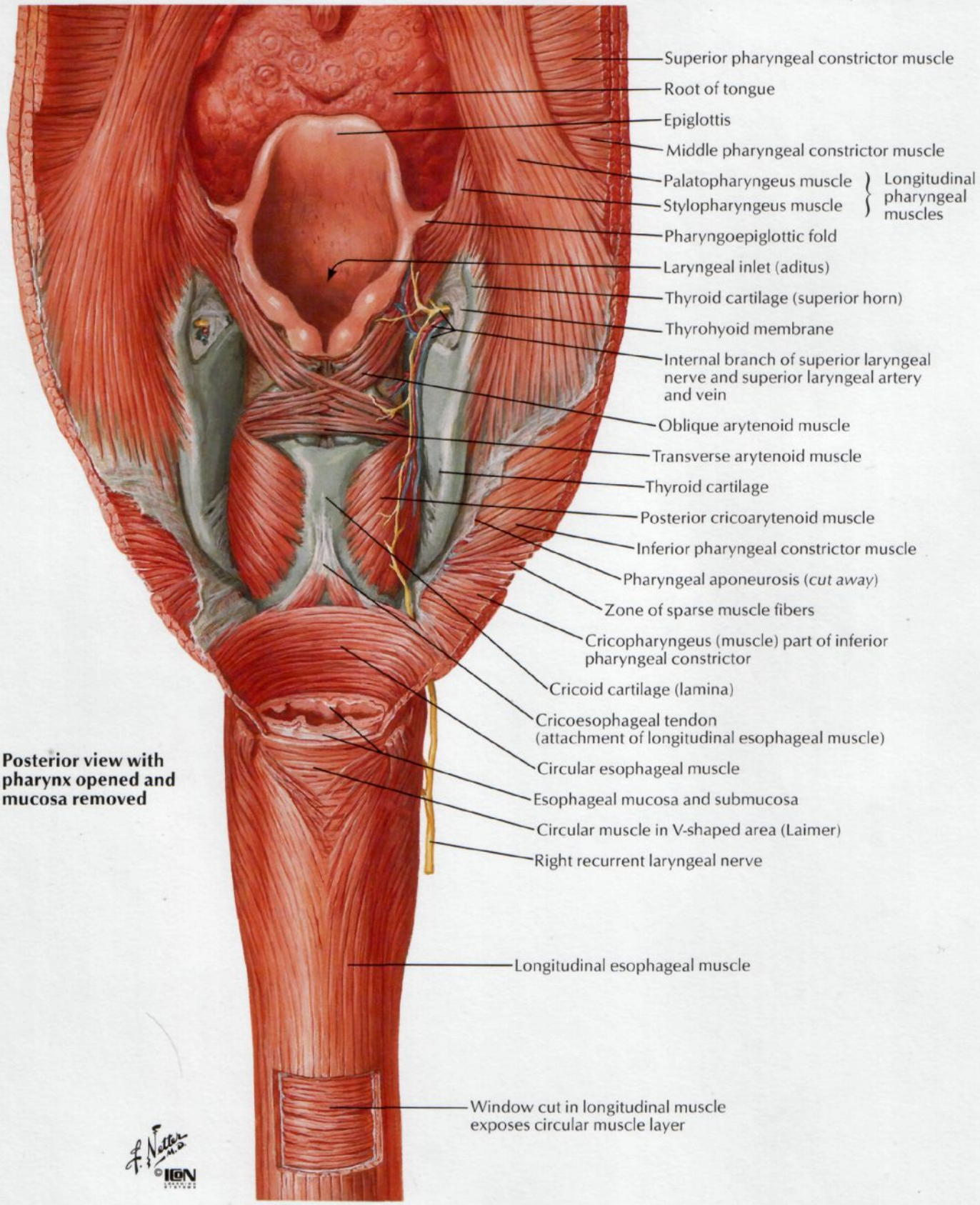

Posterior view with pharynx opened and mucosa removed

F. Netter M.D. ©ICON

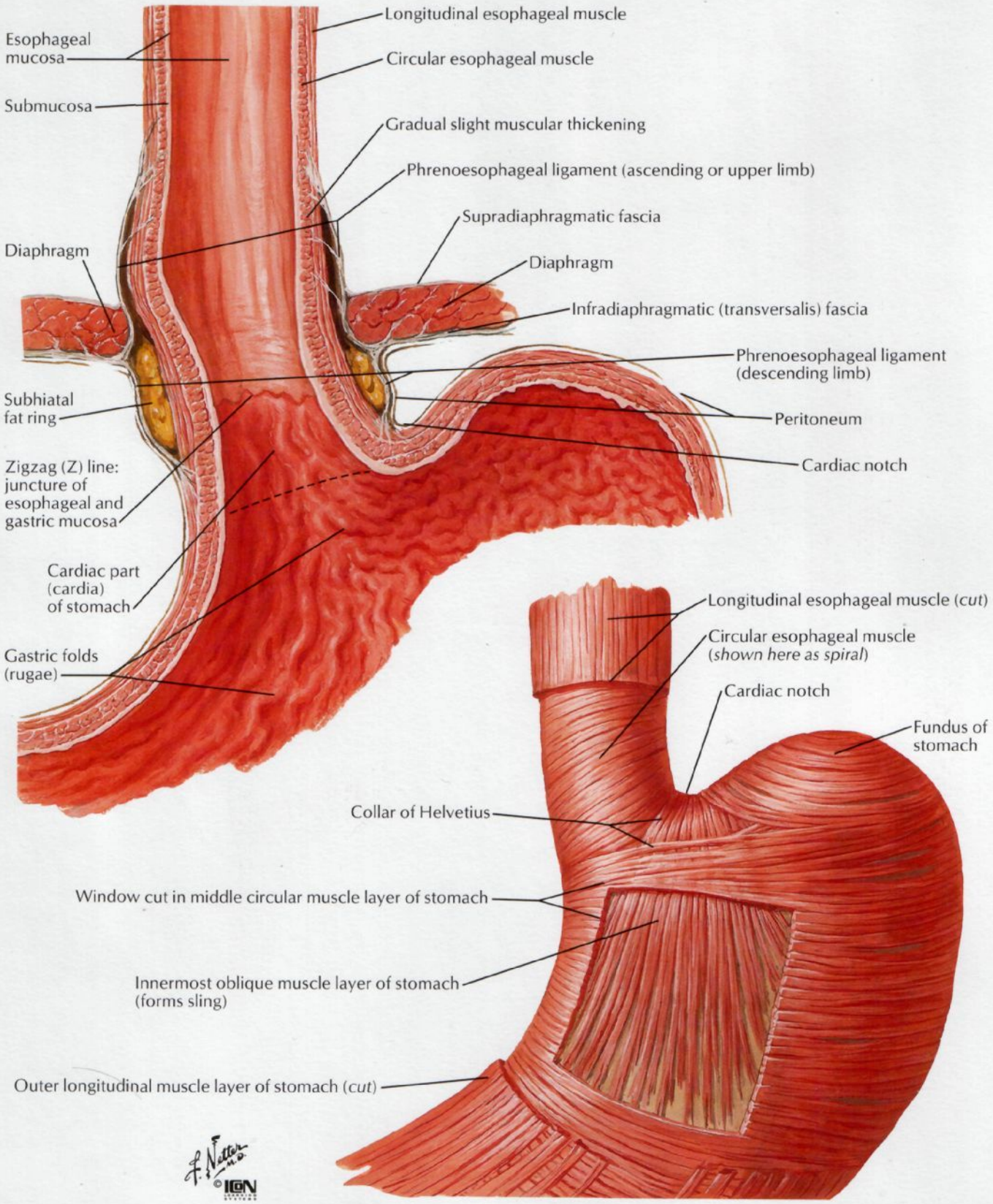
Esophageal mucosa
Submucosa
Diaphragm
Subhiatal fat ring
Zigzag (Z) line: juncture of esophageal and gastric mucosa
Cardiac part (cardia) of stomach
Gastric folds (rugae)
Longitudinal esophageal muscle
Circular esophageal muscle
Gradual slight muscular thickening
Phrenoesophageal ligament (ascending or upper limb)
Supradiaphragmatic fascia
Diaphragm
Infradiaphragmatic (transversalis) fascia
Phrenoesophageal ligament (descending limb)
Peritoneum
Cardiac notch
Longitudinal esophageal muscle (cut)
Circular esophageal muscle (shown here as spiral)
Cardiac notch
Fundus of stomach
Collar of Helvetius
Window cut in middle circular muscle layer of stomach
Innermost oblique muscle layer of stomach (forms sling)
Outer longitudinal muscle layer of stomach (cut)

Arteries of Esophagus

SEE ALSO PLATES 290, 291

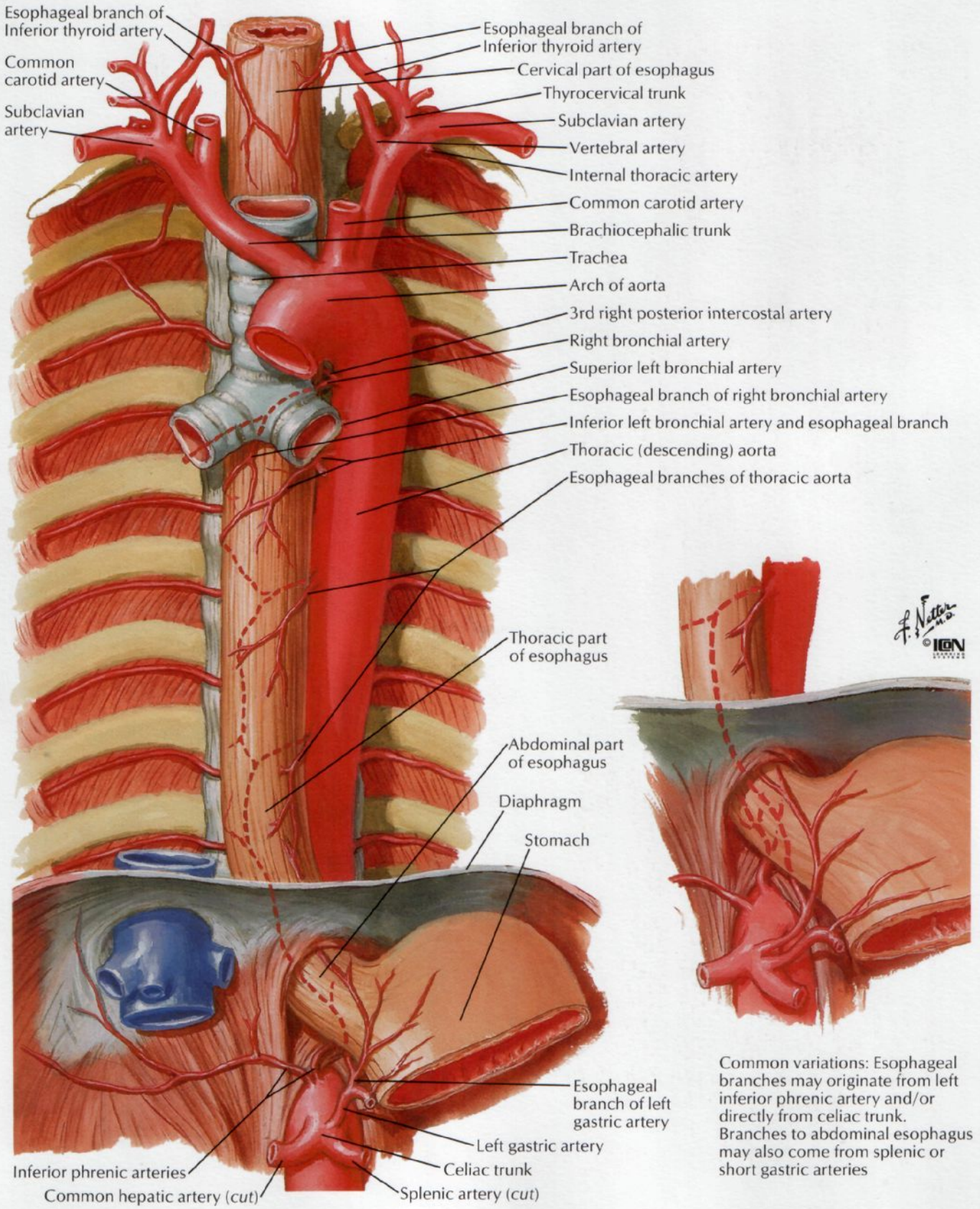

Common variations: Esophageal branches may originate from left inferior phrenic artery and/or directly from celiac trunk. Branches to abdominal esophagus may also come from splenic or short gastric arteries

SEE ALSO PLATE 302

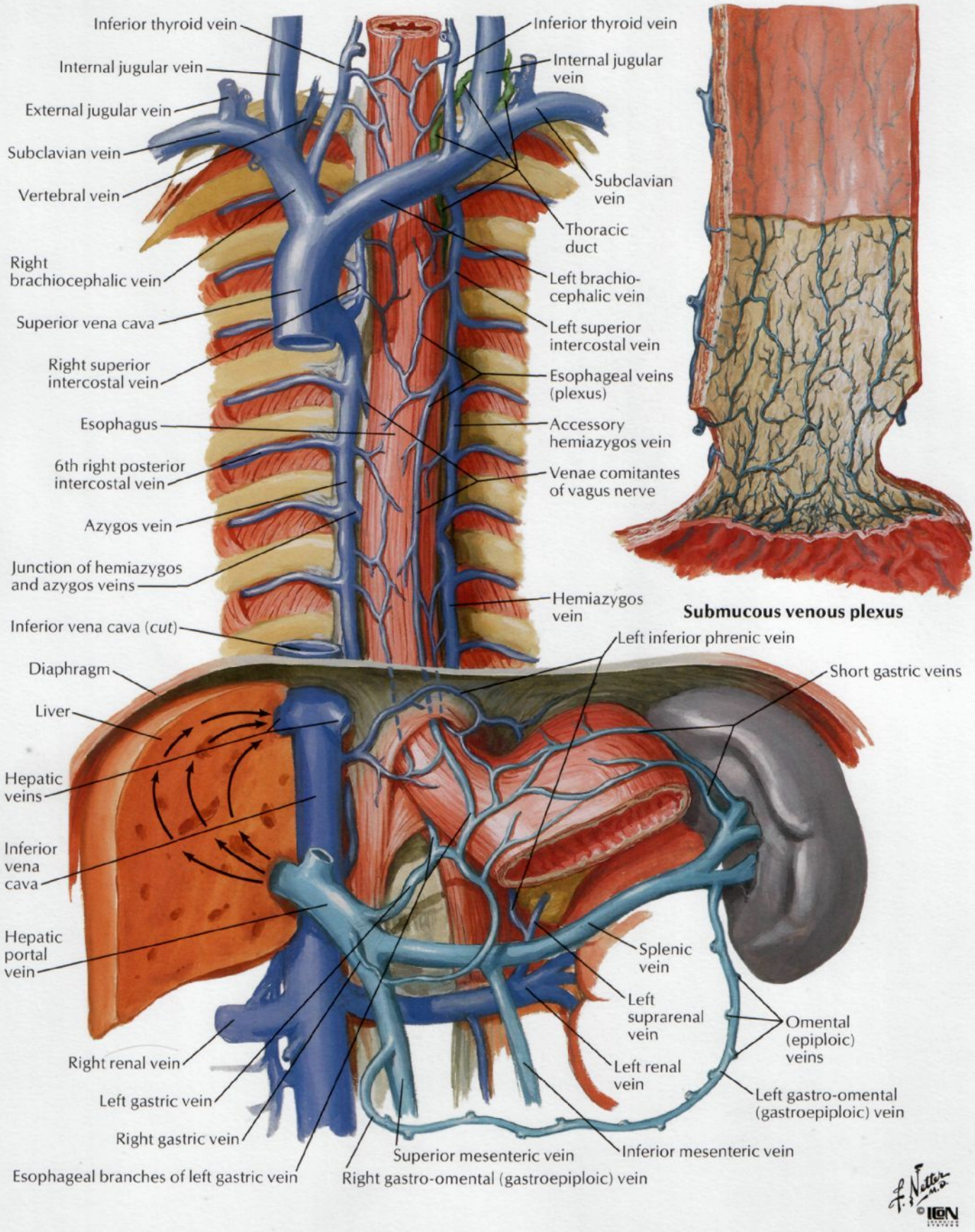

Lymph Vessels and Nodes of Esophagus

SEE ALSO PLATES 204, 258

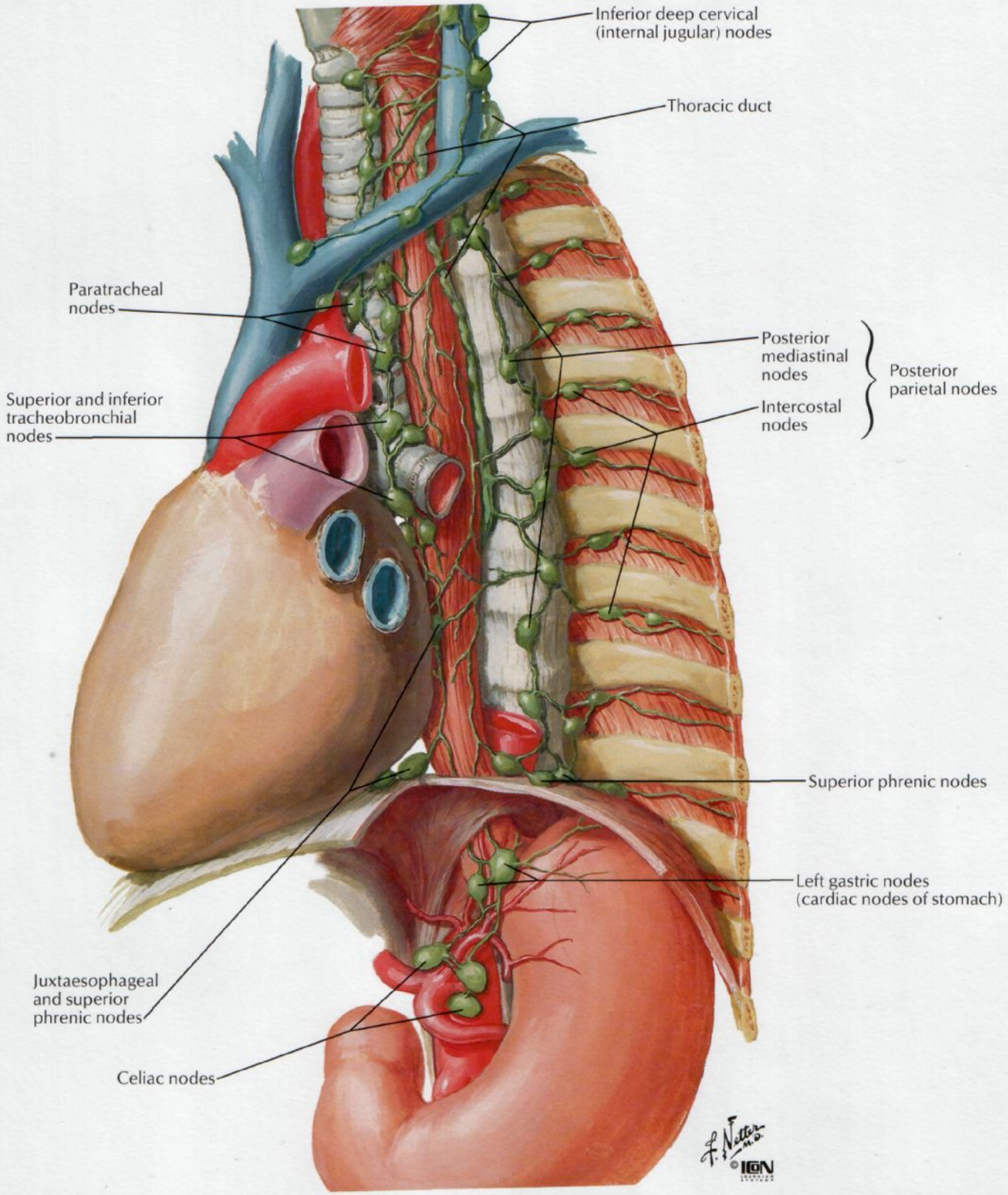

SEE ALSO PLATES 159, 205

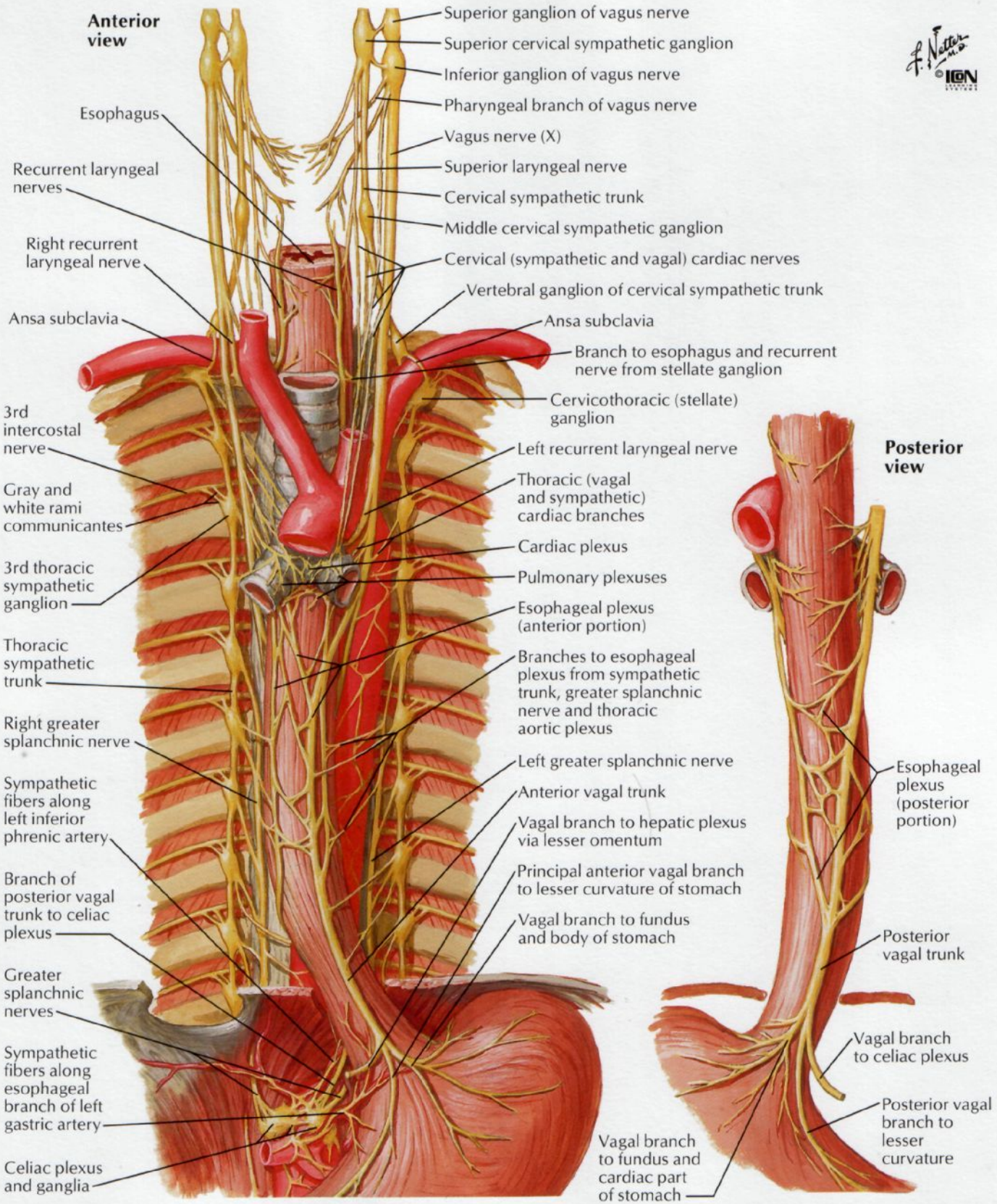

Mediastinum: Cross Section

SEE ALSO PLATE 533

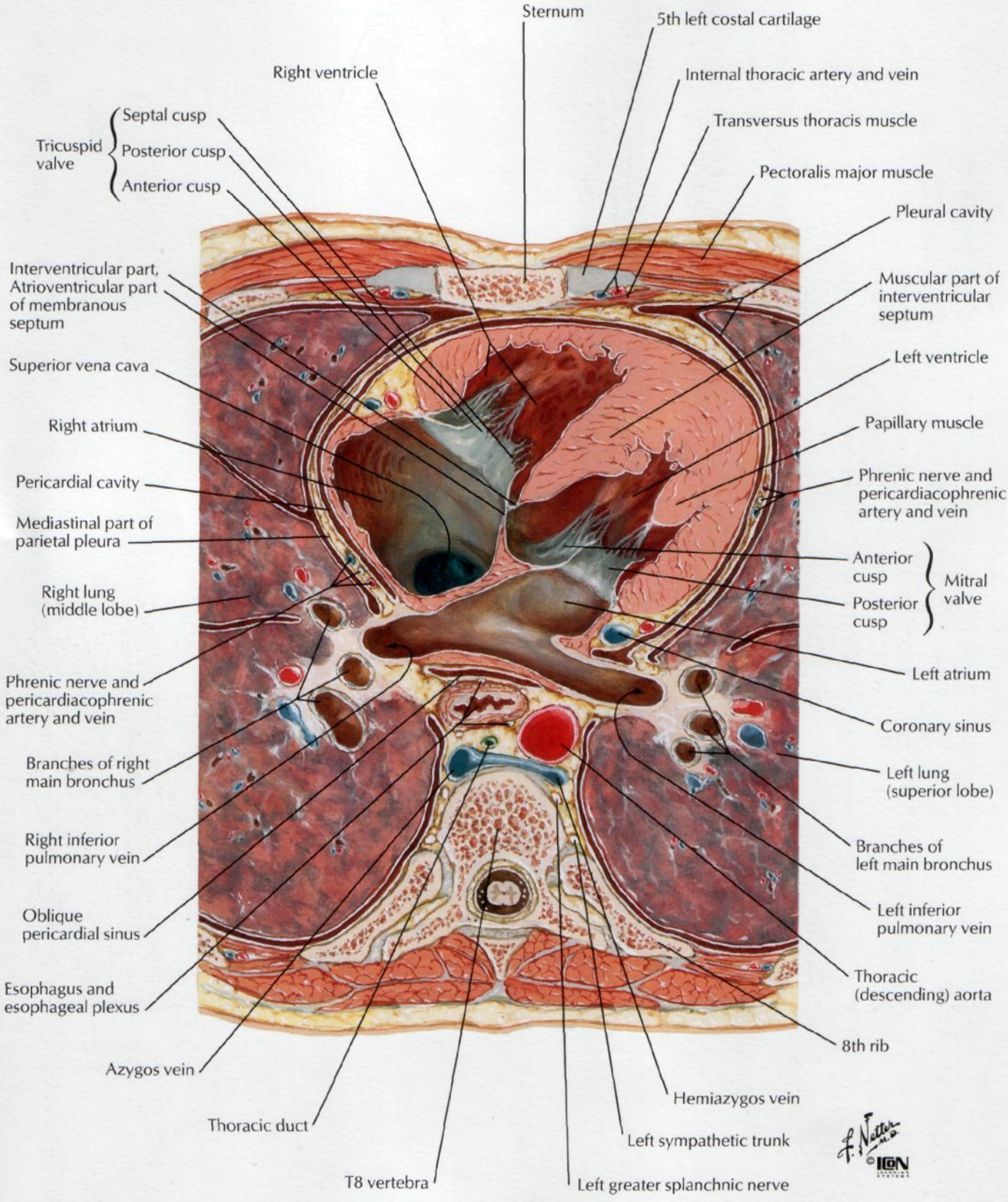

Series of chest axial CT images from superior (A) to inferior (C)

A

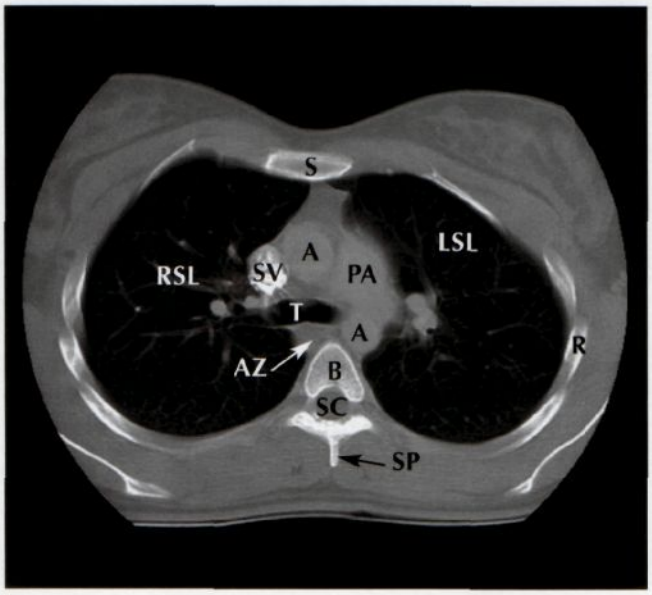

A	Aorta
AZ	Azygos vein
B	Body of vertebra
IV	Inferior vena cava
L	Liver
LB	Left bronchus
LSL	Left superior lobe of lung
LV	Left ventricle
PA	Pulmonary artery
R	Rib
RB	Right bronchus
RSL	Right superior lobe of lung
RV	Right ventricle
S	Sternum
SC	Spinal cord
SP	Spinous process of vertebra
SV	Superior vena cava
T	Trachea (bifurcation)

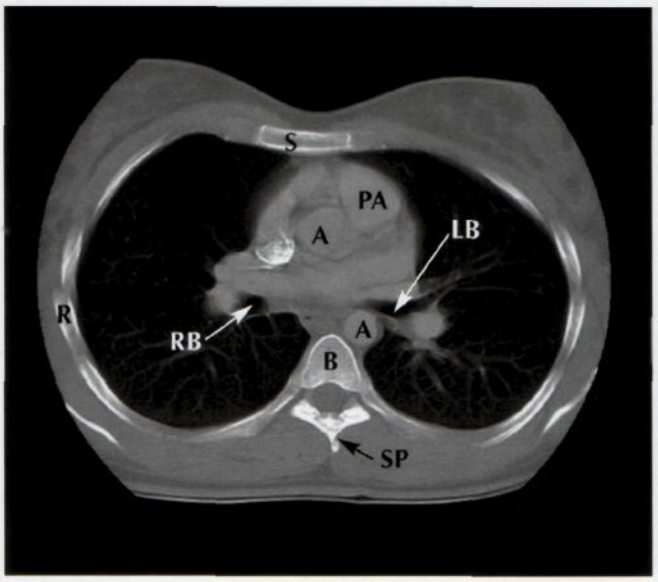

B

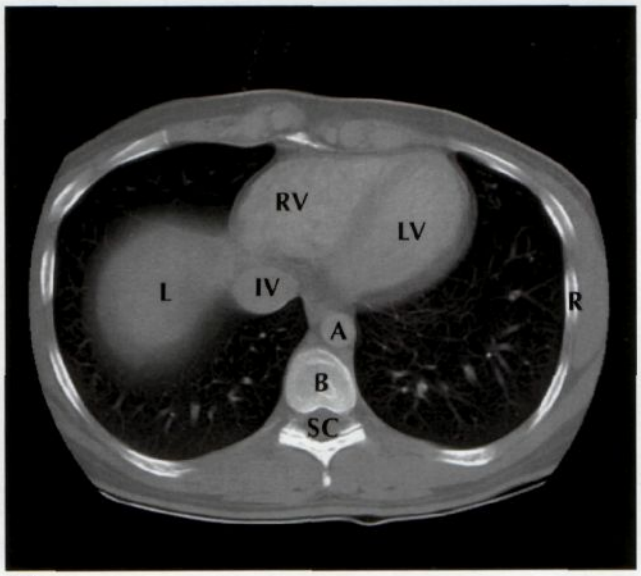

C

Section IV
ABDOMEN

SURFACE ANATOMY
Plate 239
239. Abdomen

BODY WALL
Plates 240–259
240. Bony Framework of Abdomen
241. Anterior Abdominal Wall: Superficial Dissection
242. Anterior Abdominal Wall: Intermediate Dissection
243. Anterior Abdominal Wall: Deep Dissection
244. Rectus Sheath: Cross Sections
245. Anterior Abdominal Wall: Internal View
246. Posterolateral Abdominal Wall
247. Arteries of Anterior Abdominal Wall
248. Veins of Anterior Abdominal Wall
249. Nerves of Anterior Abdominal Wall
250. Thoracoabdominal Nerves
251. Inguinal Region: Dissections
252. Femoral Sheath and Inguinal Canal
253. Inguinal Canal and Spermatic Cord
254. Indirect Inguinal Hernia
255. Posterior Abdominal Wall: Internal View
256. Arteries of Posterior Abdominal Wall
257. Veins of Posterior Abdominal Wall
258. Lymph Vessels and Nodes of Posterior Abdominal Wall
259. Nerves of Posterior Abdominal Wall

PERITONEAL CAVITY
Plates 260–266
260. Regions and Planes of Abdomen
261. Greater Omentum and Abdominal Viscera

262. Mesenteric Relations of Intestines
263. Mesenteric Relations of Intestines (*continued*)
264. Omental Bursa: Stomach Reflected
265. Omental Bursa: Cross Section
266. Peritoneum of Posterior Abdominal Wall

VISCERA (GUT)
Plates 267–277

267. Stomach In Situ
268. Mucosa of Stomach
269. Musculature of Stomach
270. Duodenum In Situ
271. Mucosa and Musculature of Duodenum
272. Mucosa and Musculature of Small Intestine
273. Ileocecal Region
274. Ileocecal Region (*continued*)
275. (Vermiform) Appendix
276. Mucosa and Musculature of Large Intestine
277. Sigmoid Colon: Variations in Position

VISCERA (ACCESSORY ORGANS)
Plates 278–289

278. Topography of Liver
279. Surfaces and Bed of Liver
280. Liver In Situ and Variations in Form
281. Liver Segments and Lobes: Vessel and Duct Distribution
282. Intrahepatic Vascular and Duct Systems
283. Liver Structure: Schema
284. Intrahepatic Biliary System: Schema
285. Gallbladder and Extrahepatic Bile Ducts
286. Variations in Cystic and Hepatic Ducts
287. Junction of (Common) Bile Duct and Duodenum
288. Pancreas In Situ
289. Spleen

VISCERAL VASCULATURE
Plates 290–307

290. Arteries of Stomach, Liver and Spleen
291. Arteries of Stomach, Duodenum, Pancreas and Spleen
292. Arteries of Liver, Pancreas, Duodenum and Spleen
293. Celiac Arteriogram
294. Arteries of Duodenum and Head of Pancreas
295. Arteries of Small Intestine
296. Arteries of Large Intestine
297. Arterial Variations and Collateral Supply of Liver and Gallbladder
298. Variations in Colic Arteries
299. Veins of Stomach, Duodenum, Pancreas and Spleen
300. Veins of Small Intestine
301. Veins of Large Intestine
302. Hepatic Portal Vein Tributaries: Portocaval Anastomoses
303. Variations of Hepatic Portal Vein
304. Lymph Vessels and Nodes of Stomach
305. Lymph Vessels and Nodes of Small Intestine

306. Lymph Vessels and Nodes of Large Intestine
307. Lymph Vessels and Nodes of Pancreas

INNERVATION
Plates 308–318

308. Autonomic Nerves and Ganglia of Abdomen
309. Nerves of Stomach and Duodenum
310. Nerves of Stomach and Duodenum (*continued*)
311. Innervation of Stomach and Duodenum: Schema
312. Nerves of Small Intestine
313. Nerves of Large Intestine
314. Innervation of Small and Large Intestines: Schema
315. Autonomic Reflex Pathways: Schema
316. Intrinsic Autonomic Plexuses of Intestine: Schema
317. Innervation of Liver and Biliary Tract: Schema
318. Innervation of Pancreas: Schema

KIDNEYS AND SUPRARENAL GLANDS
Plates 319–334

319. Kidneys In Situ: Anterior Views
320. Kidneys In Situ: Posterior Views
321. Gross Structure of Kidney
322. Renal Artery and Vein In Situ
323. Intrarenal Arteries and Renal Segments
324. Variations in Renal Artery and Vein
325. Nephron and Collecting Tubule: Schema
326. Blood Vessels in Parenchyma of Kidney: Schema
327. Ureters
328. Arteries of Ureters and Urinary Bladder
329. Lymph Vessels and Nodes of Kidneys and Urinary Bladder
330. Nerves of Kidneys, Ureters and Urinary Bladder
331. Innervation of Kidneys and Upper Ureters: Schema
332. Renal Fascia
333. Arteries and Veins of Suprarenal Glands In Situ
334. Nerves of Suprarenal Glands: Dissection and Schema

ABDOMINAL SECTIONS
Plates 335–337

335. Abdominal Wall and Viscera: Median (Sagittal) Section
336. Schematic Cross Section of Abdomen at T12
337. Schematic Cross Section of Abdomen at L3, 4

REGIONAL SCANS
Plate 338

338. Abdominal Scans: Axial CT Images

FOR REGIONS SEE PLATE 260

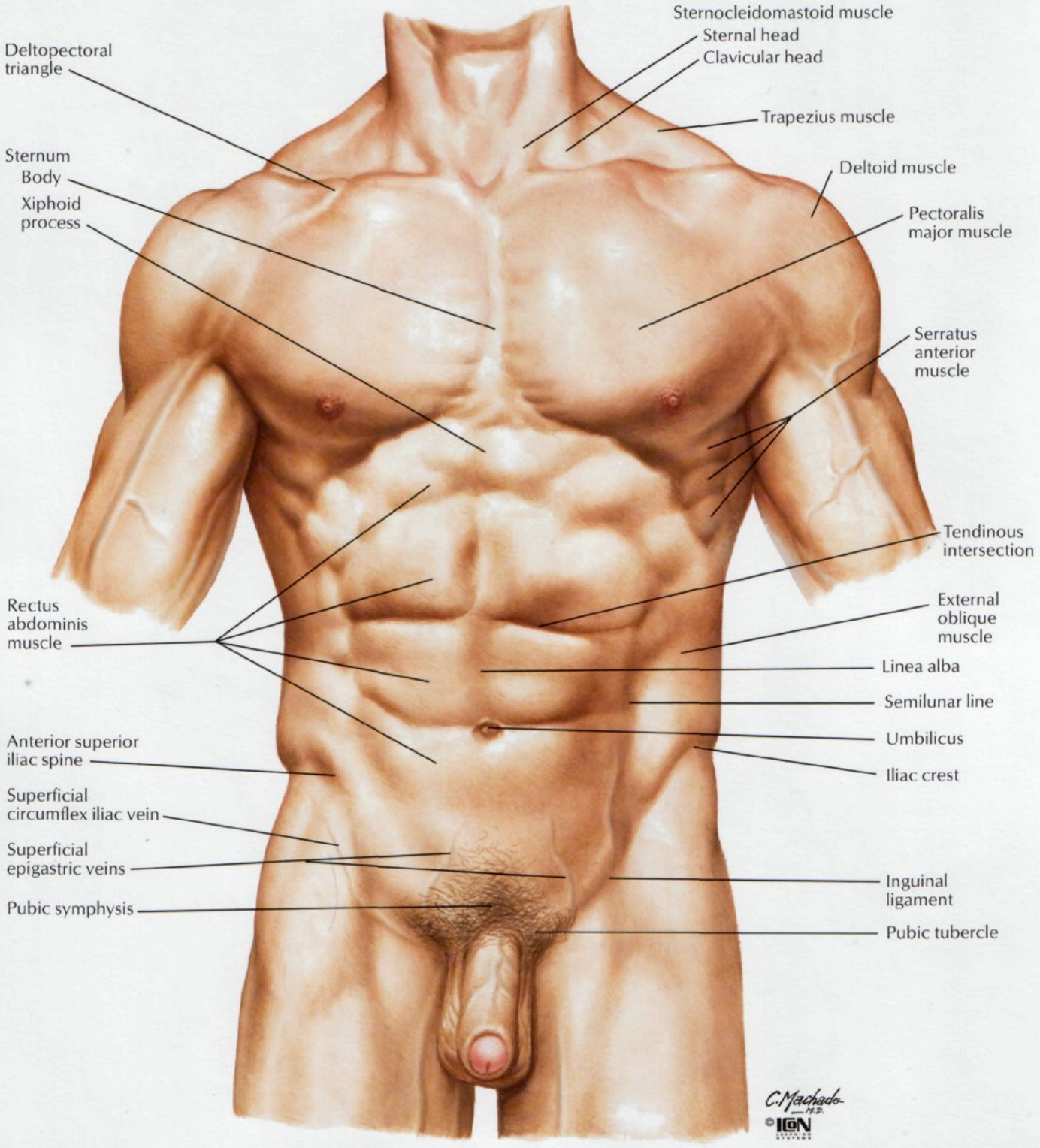

Bony Framework of Abdomen

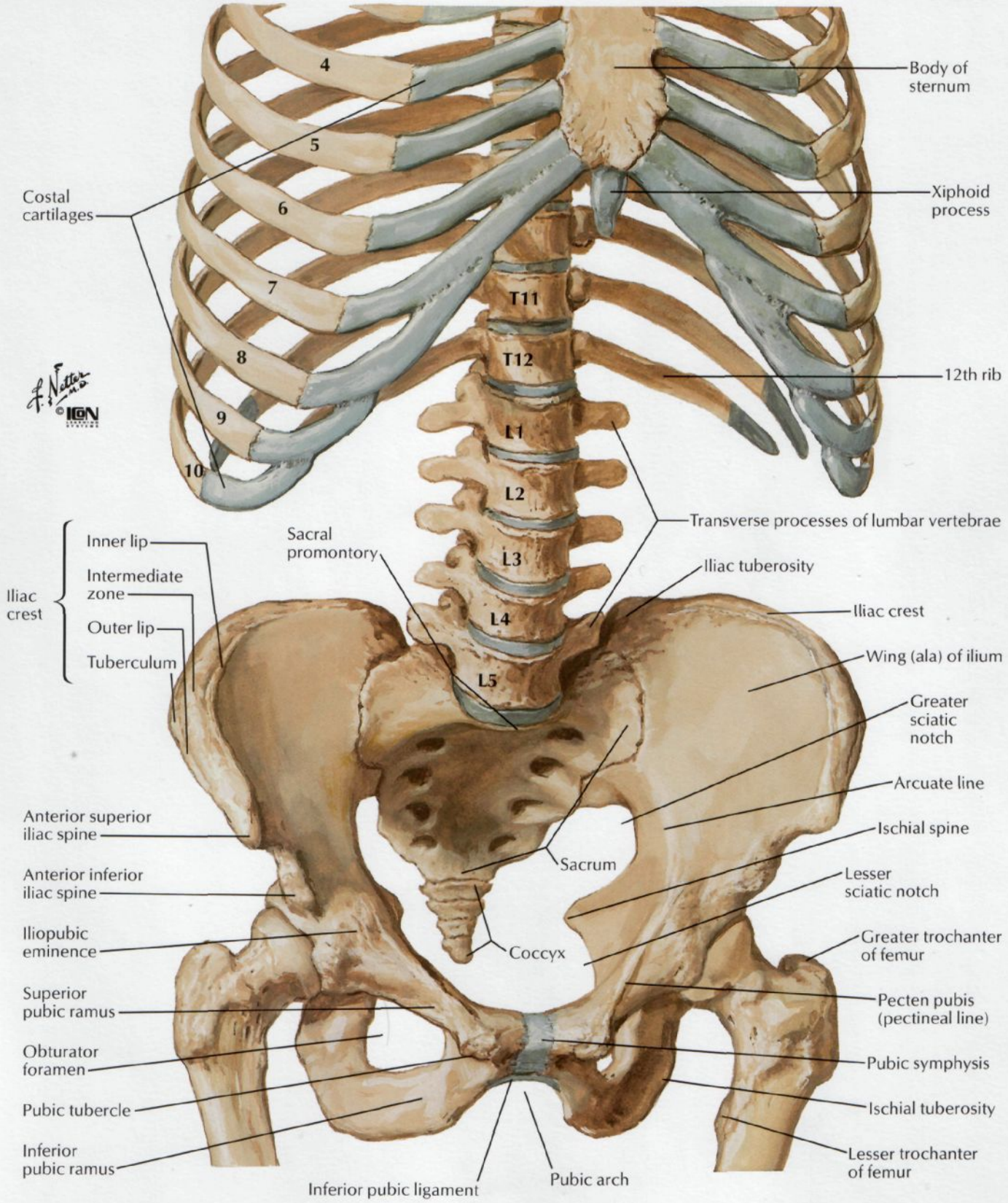

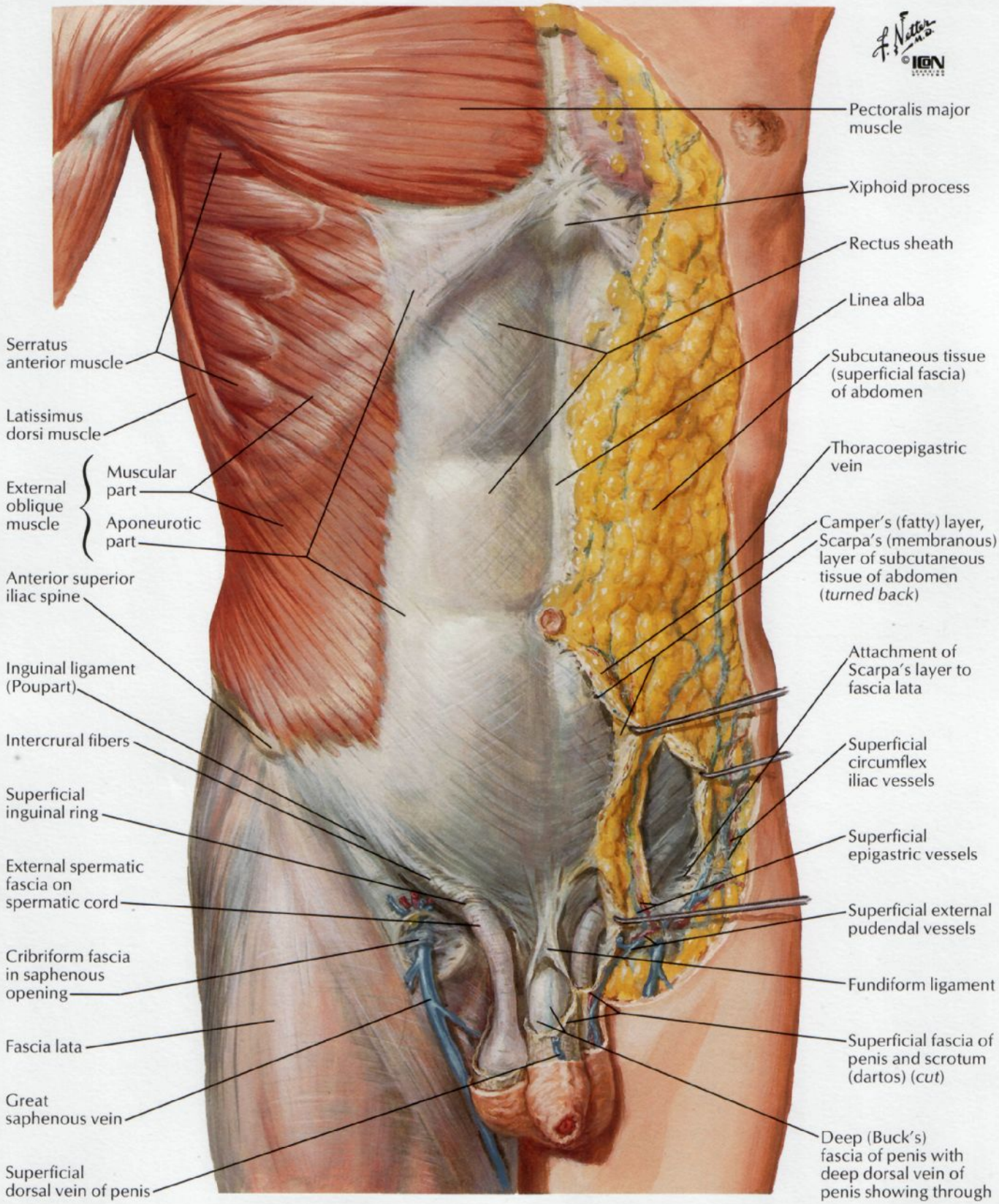
Pectoralis major muscle
Xiphoid process
Rectus sheath
Linea alba
Subcutaneous tissue (superficial fascia) of abdomen
Thoracoepigastric vein
Camper's (fatty) layer, Scarpa's (membranous) layer of subcutaneous tissue of abdomen (turned back)
Attachment of Scarpa's layer to fascia lata
Superficial circumflex iliac vessels
Superficial epigastric vessels
Superficial external pudendal vessels
Fundiform ligament
Superficial fascia of penis and scrotum (dartos) (cut)
Deep (Buck's) fascia of penis with deep dorsal vein of penis showing through
Serratus anterior muscle
Latissimus dorsi muscle
External oblique muscle
Muscular part
Aponeurotic part
Anterior superior iliac spine
Inguinal ligament (Poupart)
Intercrural fibers
Superficial inguinal ring
External spermatic fascia on spermatic cord
Cribriform fascia in saphenous opening
Fascia lata
Great saphenous vein
Superficial dorsal vein of penis

Anterior Abdominal Wall: Intermediate Dissection

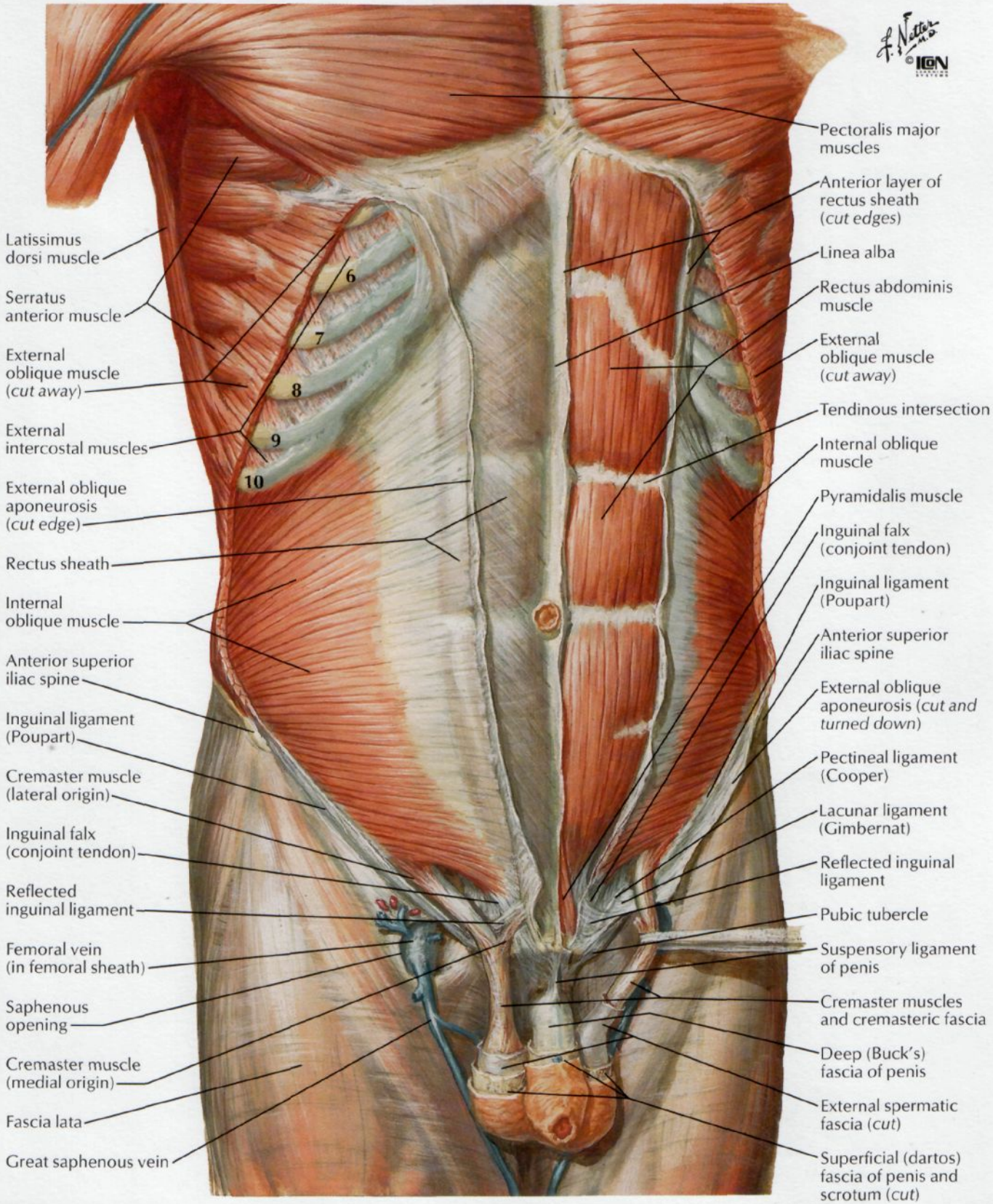

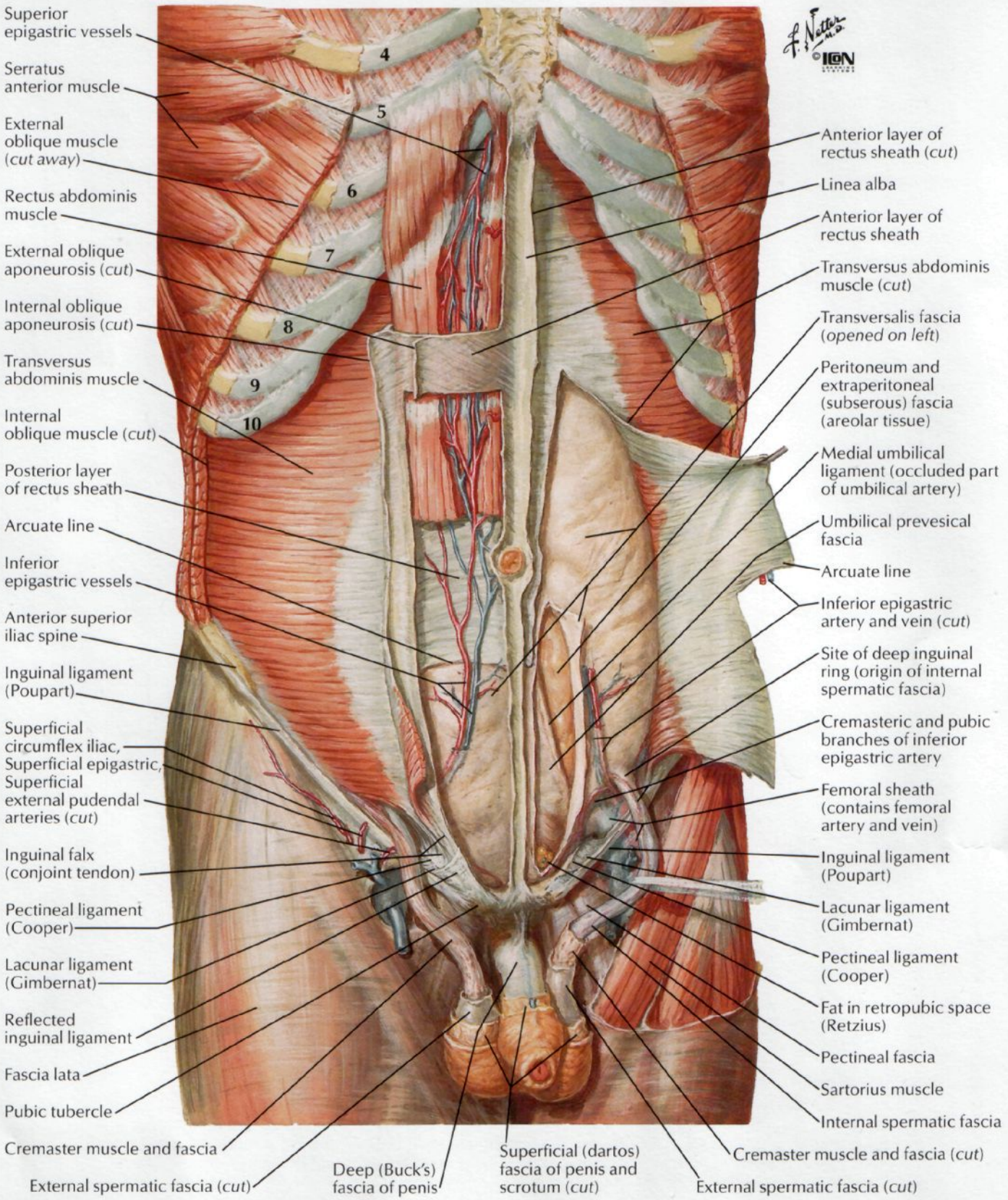
Superior epigastric vessels
Serratus anterior muscle
External oblique muscle (cut away)
Rectus abdominis muscle
External oblique aponeurosis (cut)
Internal oblique aponeurosis (cut)
Transversus abdominis muscle
Internal oblique muscle (cut)
Posterior layer of rectus sheath
Arcuate line
Inferior epigastric vessels
Anterior superior iliac spine
Inguinal ligament (Poupart)
Superficial circumflex iliac, Superficial epigastric, Superficial external pudendal arteries (cut)
Inguinal falx (conjoint tendon)
Pectineal ligament (Cooper)
Lacunar ligament (Gimbernat)
Reflected inguinal ligament
Fascia lata
Pubic tubercle
Cremaster muscle and fascia
External spermatic fascia (cut)
Deep (Buck's) fascia of penis
Superficial (dartos) fascia of penis and scrotum (cut)
External spermatic fascia (cut)
Cremaster muscle and fascia (cut)
Internal spermatic fascia
Sartorius muscle
Pectineal fascia
Fat in retropubic space (Retzius)
Pectineal ligament (Cooper)
Lacunar ligament (Gimbernat)
Inguinal ligament (Poupart)
Femoral sheath (contains femoral artery and vein)
Cremasteric and pubic branches of inferior epigastric artery
Site of deep inguinal ring (origin of internal spermatic fascia)
Inferior epigastric artery and vein (cut)
Arcuate line
Umbilical prevesical fascia
Medial umbilical ligament (occluded part of umbilical artery)
Peritoneum and extraperitoneal (subserous) fascia (areolar tissue)
Transversalis fascia (opened on left)
Transversus abdominis muscle (cut)
Anterior layer of rectus sheath
Linea alba
Anterior layer of rectus sheath (cut)
4
5
6
7
8
9
10

Rectus Sheath: Cross Sections

Section above arcuate line

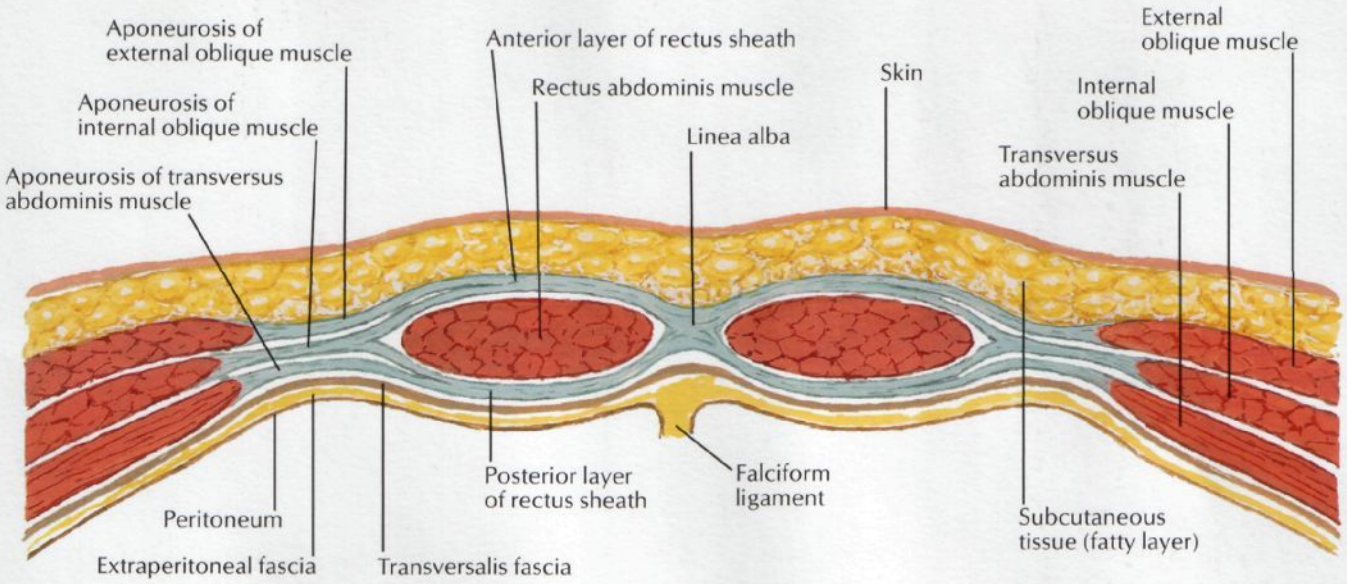

Aponeurosis of internal oblique muscle splits to form anterior and posterior layers of rectus sheath. Aponeurosis of external oblique muscle joins anterior layer of sheath; aponeurosis of transversus abdominis muscle joins posterior layer. Anterior and posterior layers of rectus sheath unite medially to form linea alba

Section below arcuate line

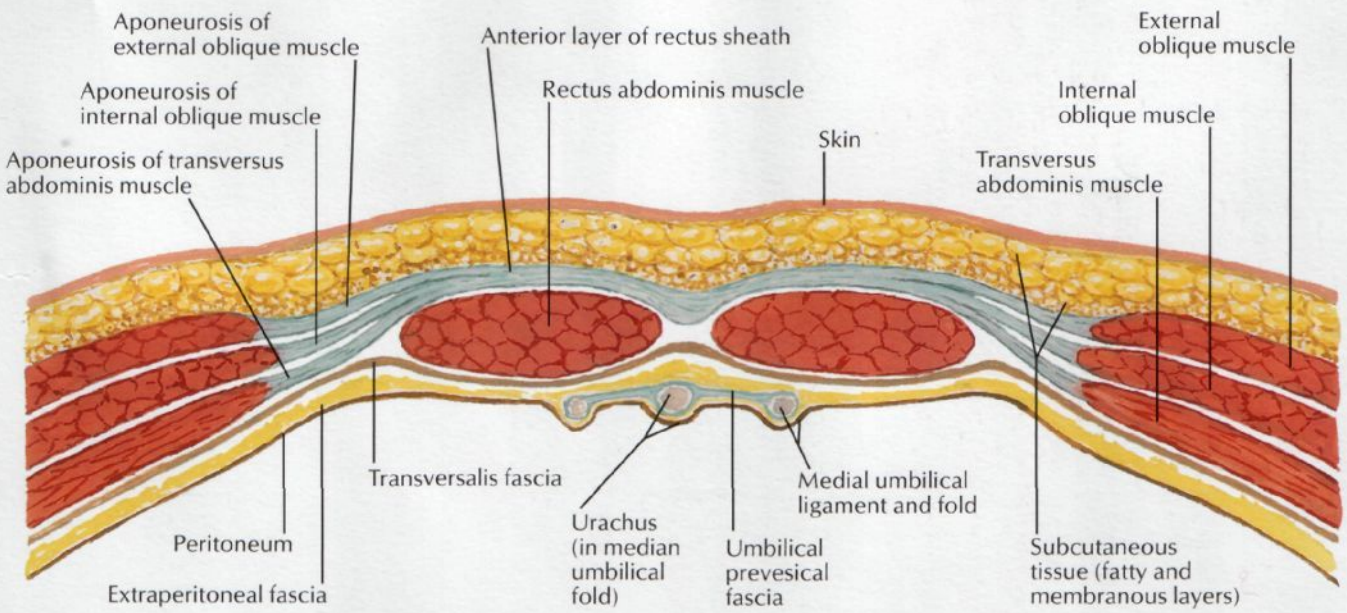

Aponeurosis of internal oblique muscle does not split at this level but passes completely anterior to rectus abdominis muscle and is fused there with both aponeurosis of external oblique muscle and that of transversus abdominis muscle. Thus, posterior wall of rectus sheath is absent below arcuate line and rectus abdominis muscle lies on transversalis fascia

F. Netter M.D. ©ICON

Anterior Abdominal Wall: Internal View

FOR UMBILICAL VESSELS SEE PLATE 225

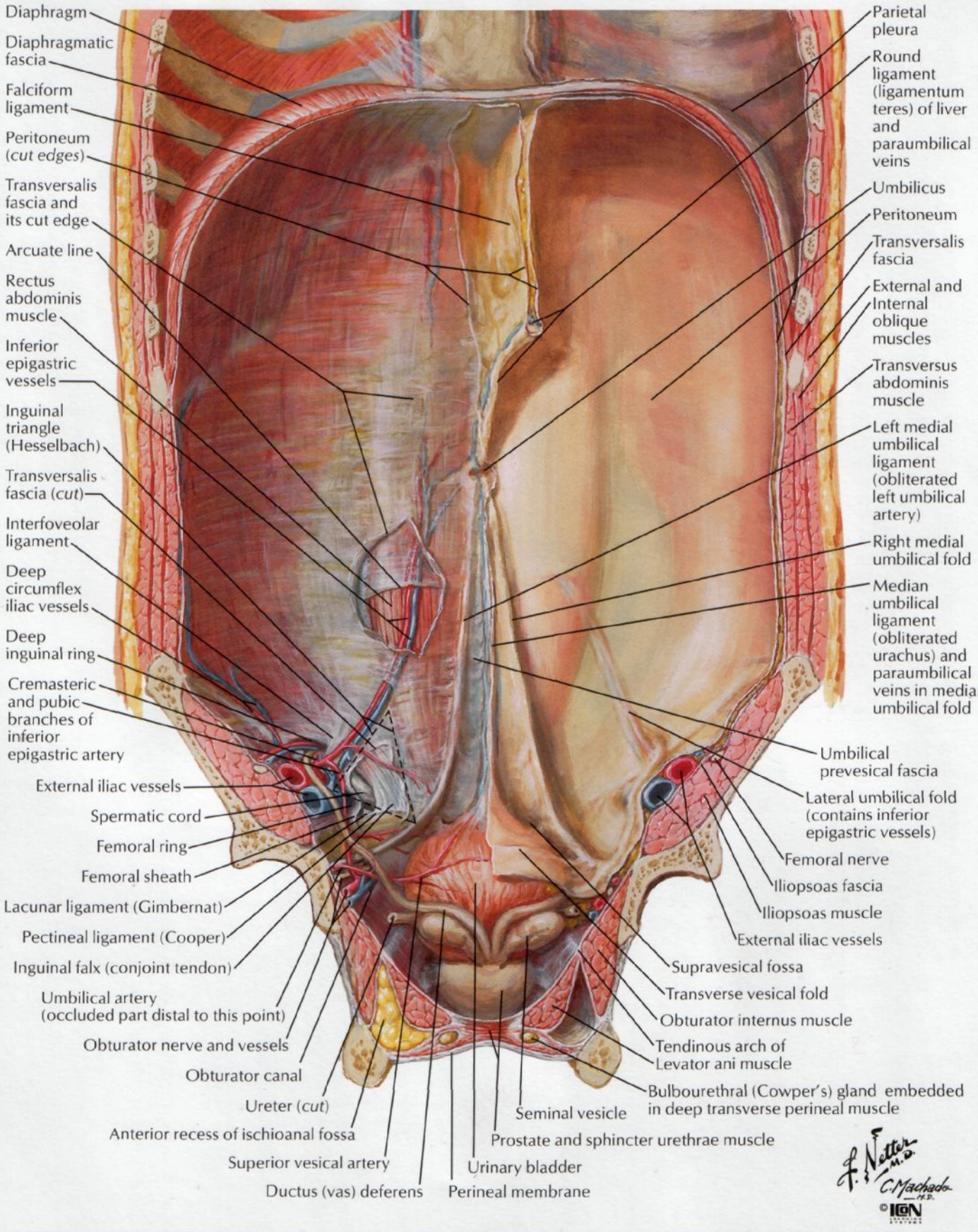

F. Netter M.D.
C. Machado M.D.
©IGN

Posterolateral Abdominal Wall

SEE ALSO PLATES 167, 170, 172, 173, 250

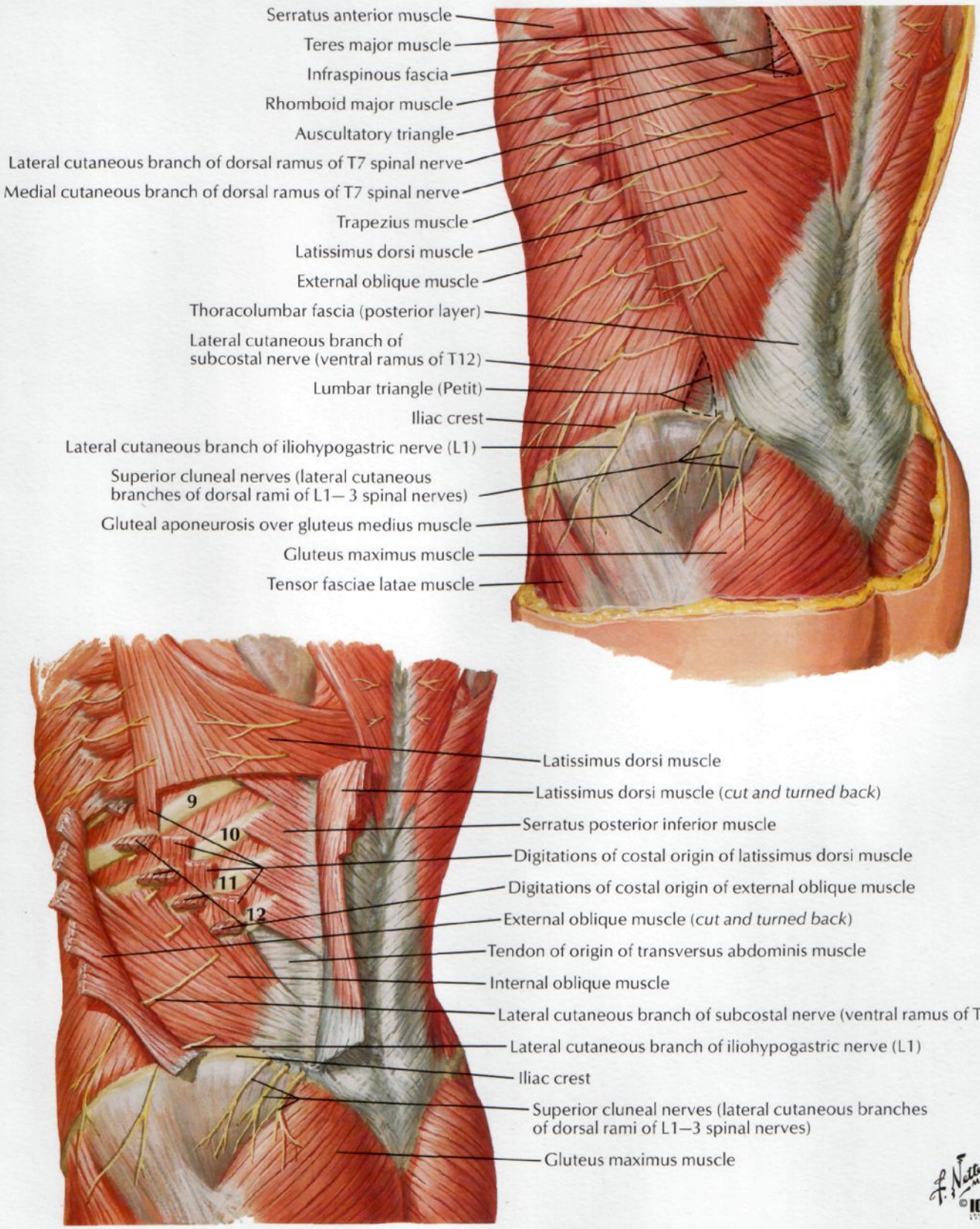

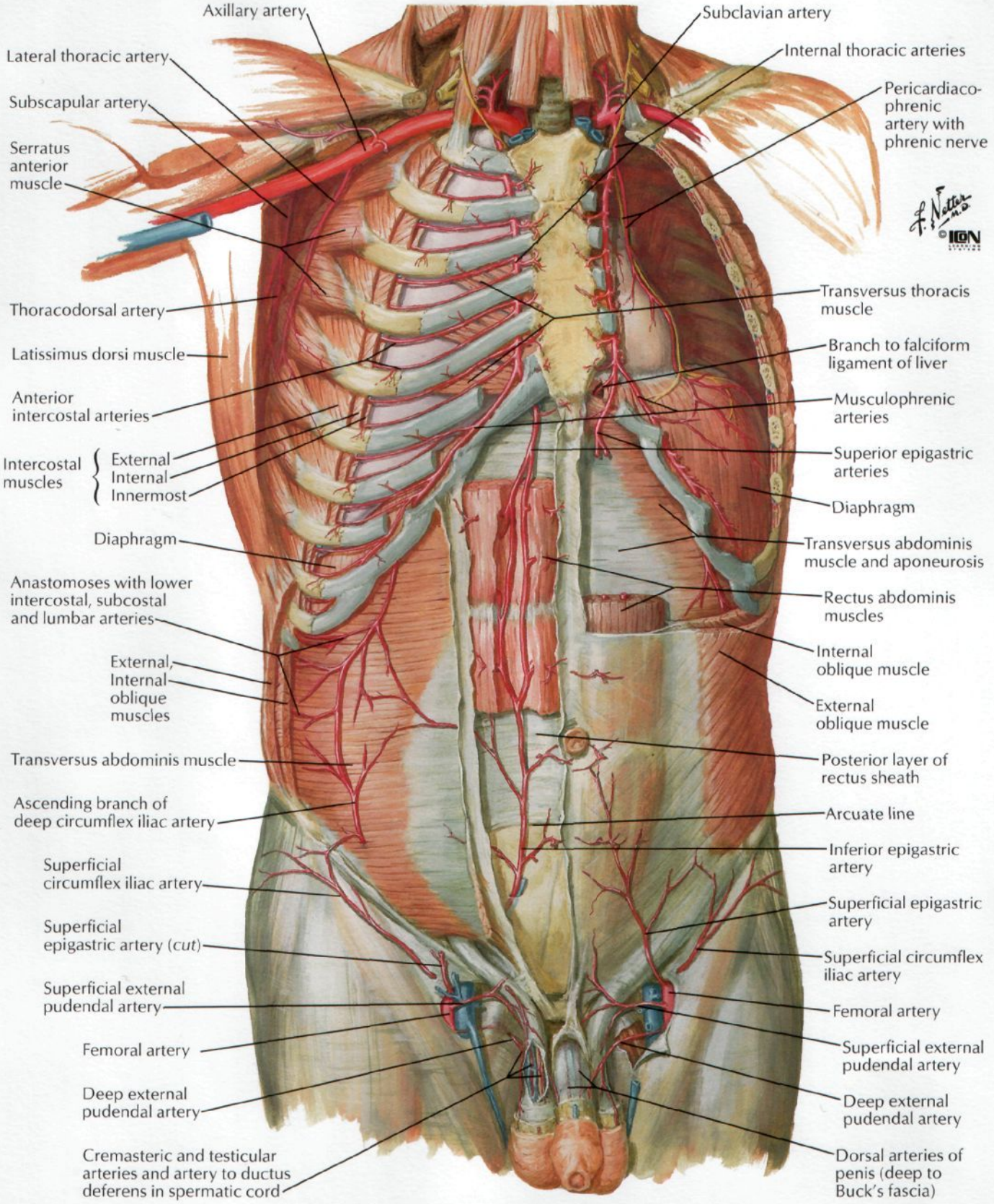
Axillary artery
Subclavian artery
Lateral thoracic artery
Internal thoracic arteries
Subscapular artery
Pericardiacophrenic artery with phrenic nerve
Serratus anterior muscle
Thoracodorsal artery
Transversus thoracis muscle
Latissimus dorsi muscle
Branch to falciform ligament of liver
Anterior intercostal arteries
Musculophrenic arteries
Intercostal muscles
External
Internal
Innermost
Superior epigastric arteries
Diaphragm
Diaphragm
Transversus abdominis muscle and aponeurosis
Anastomoses with lower intercostal, subcostal and lumbar arteries
Rectus abdominis muscles
External, Internal oblique muscles
Internal oblique muscle
External oblique muscle
Transversus abdominis muscle
Posterior layer of rectus sheath
Ascending branch of deep circumflex iliac artery
Arcuate line
Inferior epigastric artery
Superficial circumflex iliac artery
Superficial epigastric artery
Superficial epigastric artery (cut)
Superficial circumflex iliac artery
Superficial external pudendal artery
Femoral artery
Femoral artery
Superficial external pudendal artery
Deep external pudendal artery
Deep external pudendal artery
Cremasteric and testicular arteries and artery to ductus deferens in spermatic cord
Dorsal arteries of penis (deep to Buck's fascia)

Veins of Anterior Abdominal Wall

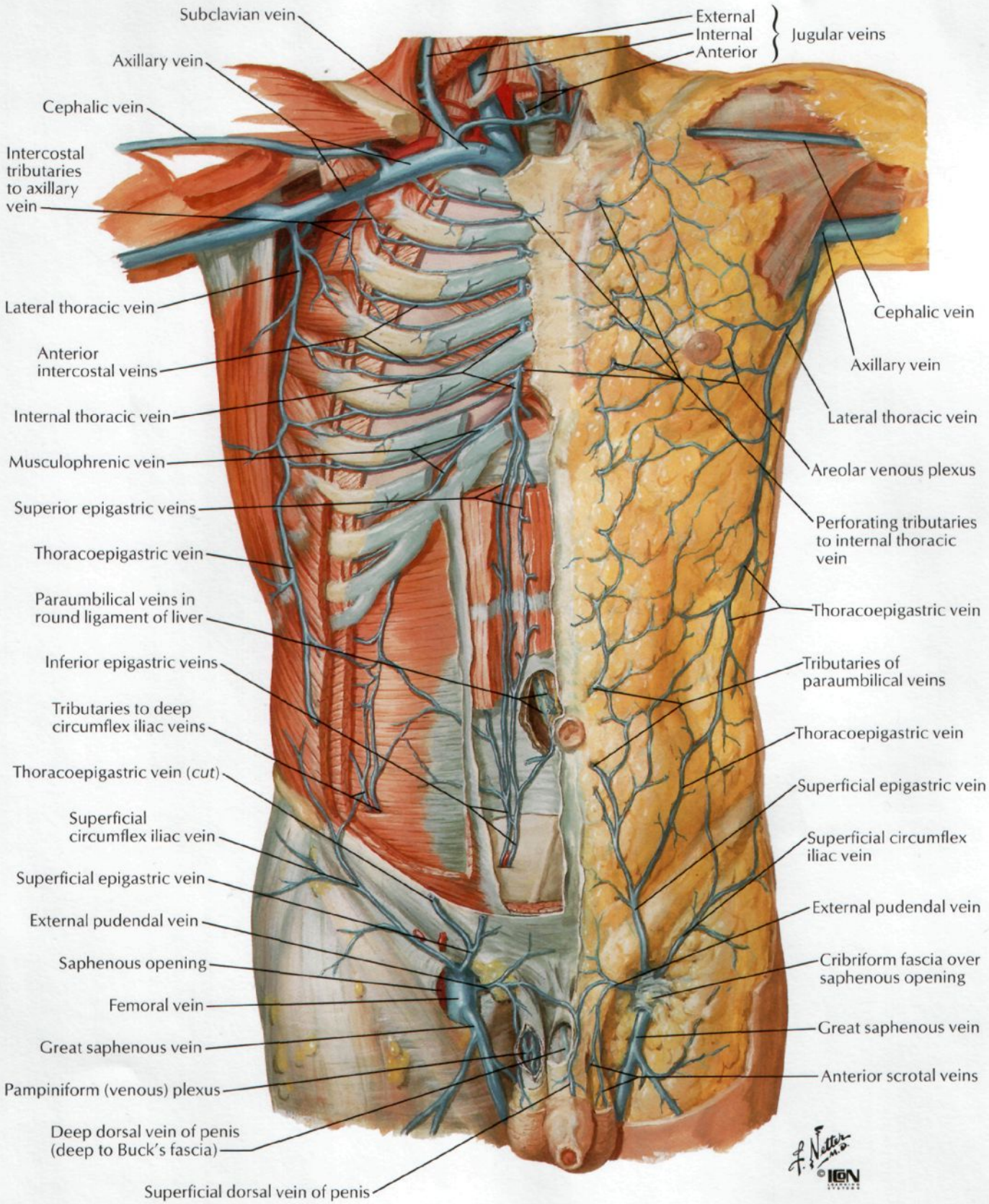

SEE ALSO PLATES 170, 246, 259, 480

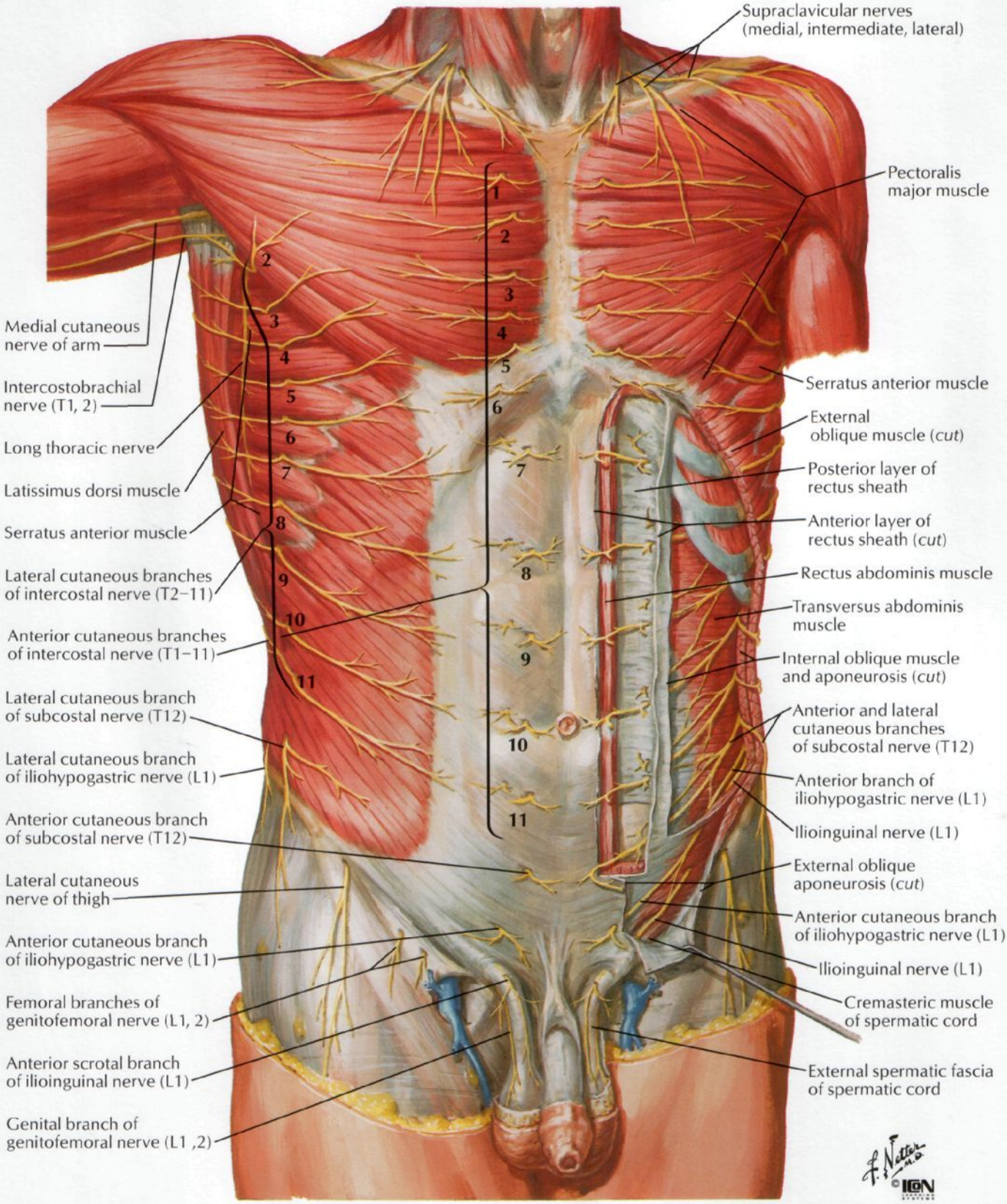

Thoracoabdominal Nerves

SEE ALSO PLATES 173, 187

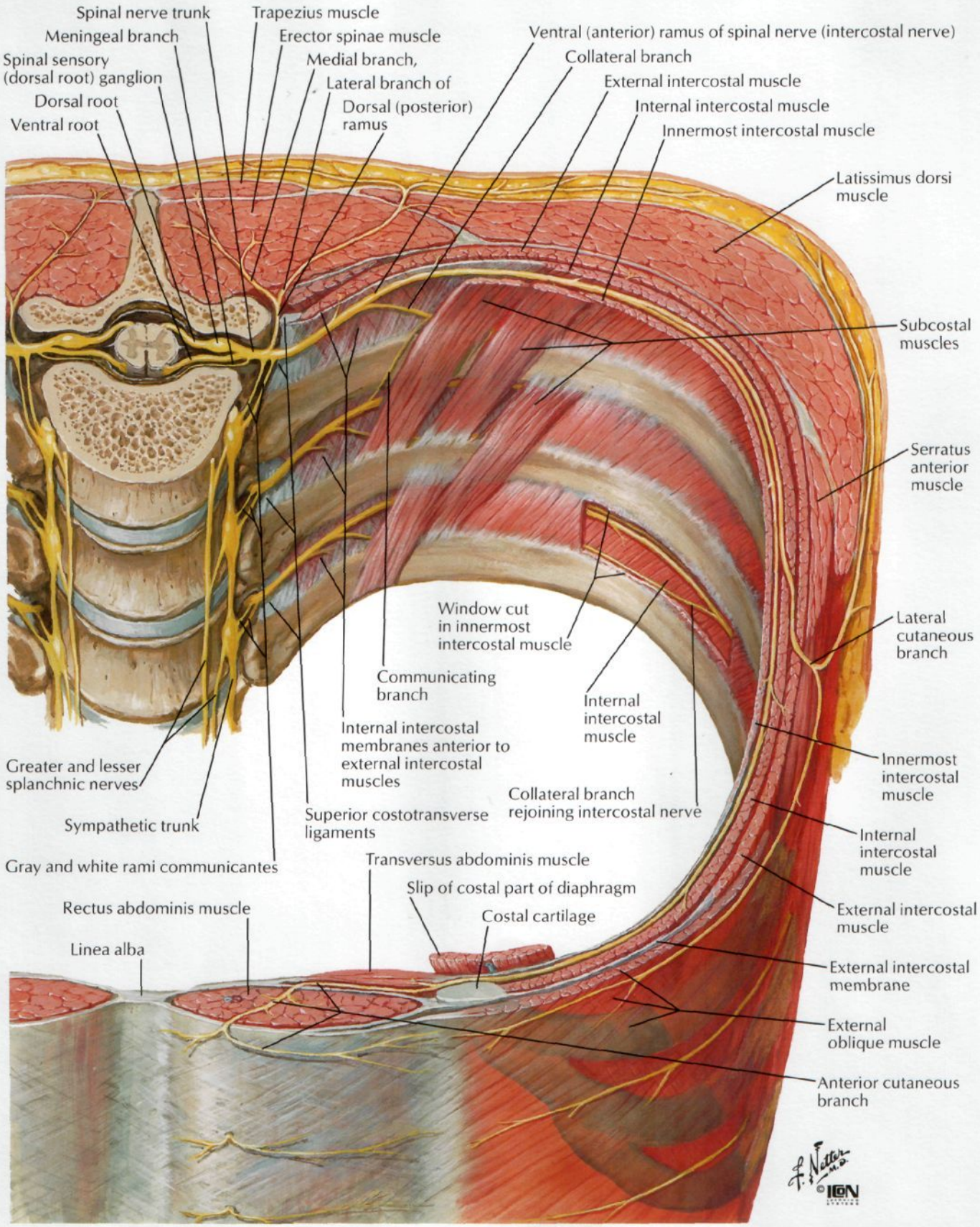

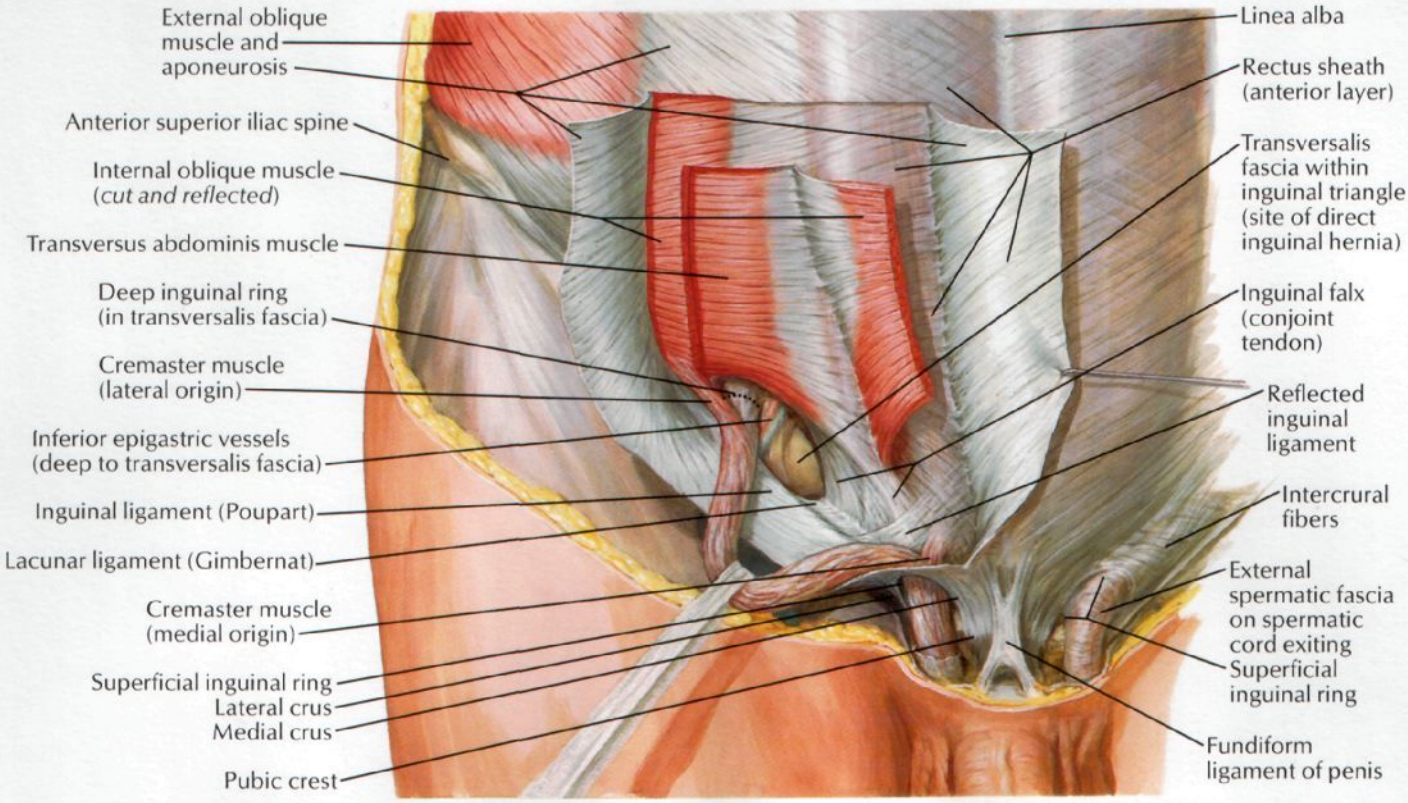

Anterior view

Posterior (internal) view

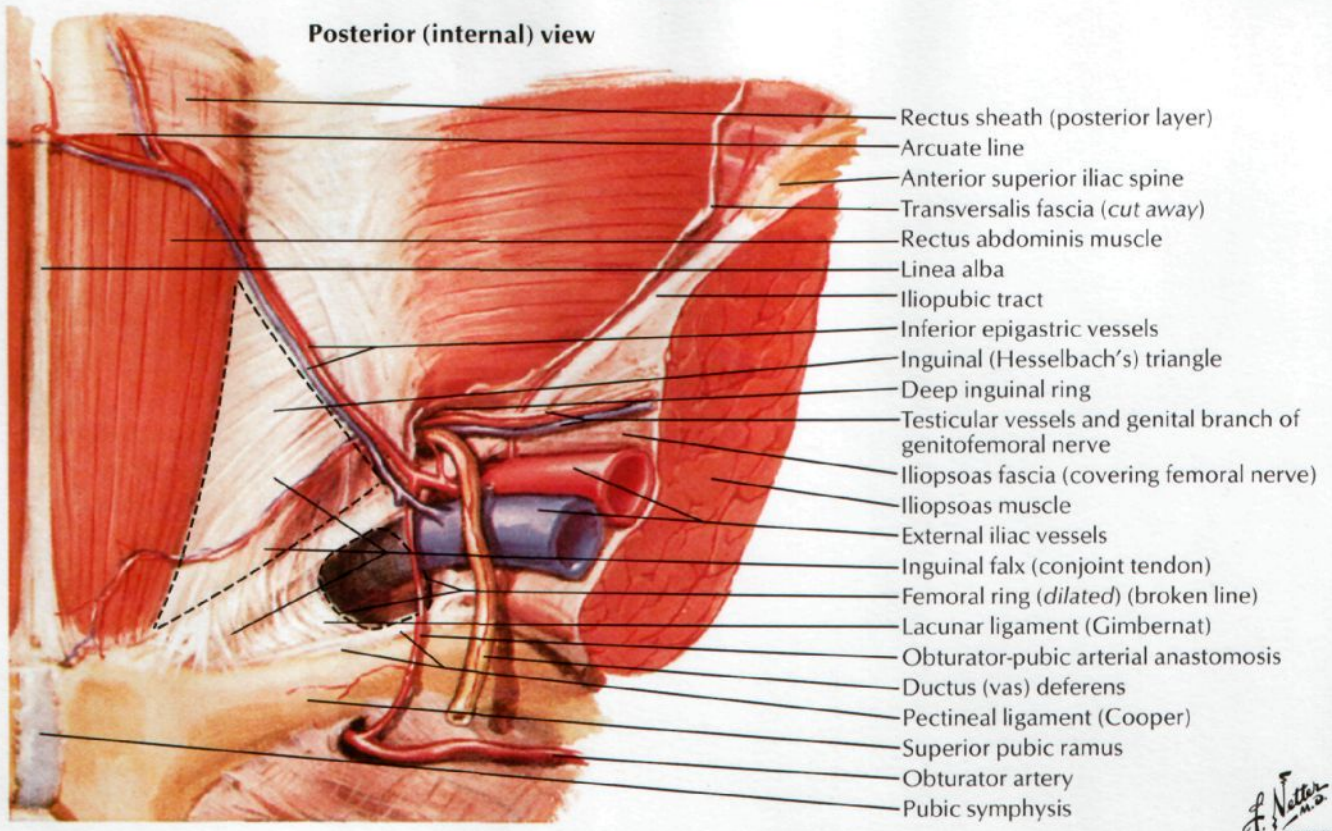

Femoral Sheath and Inguinal Canal

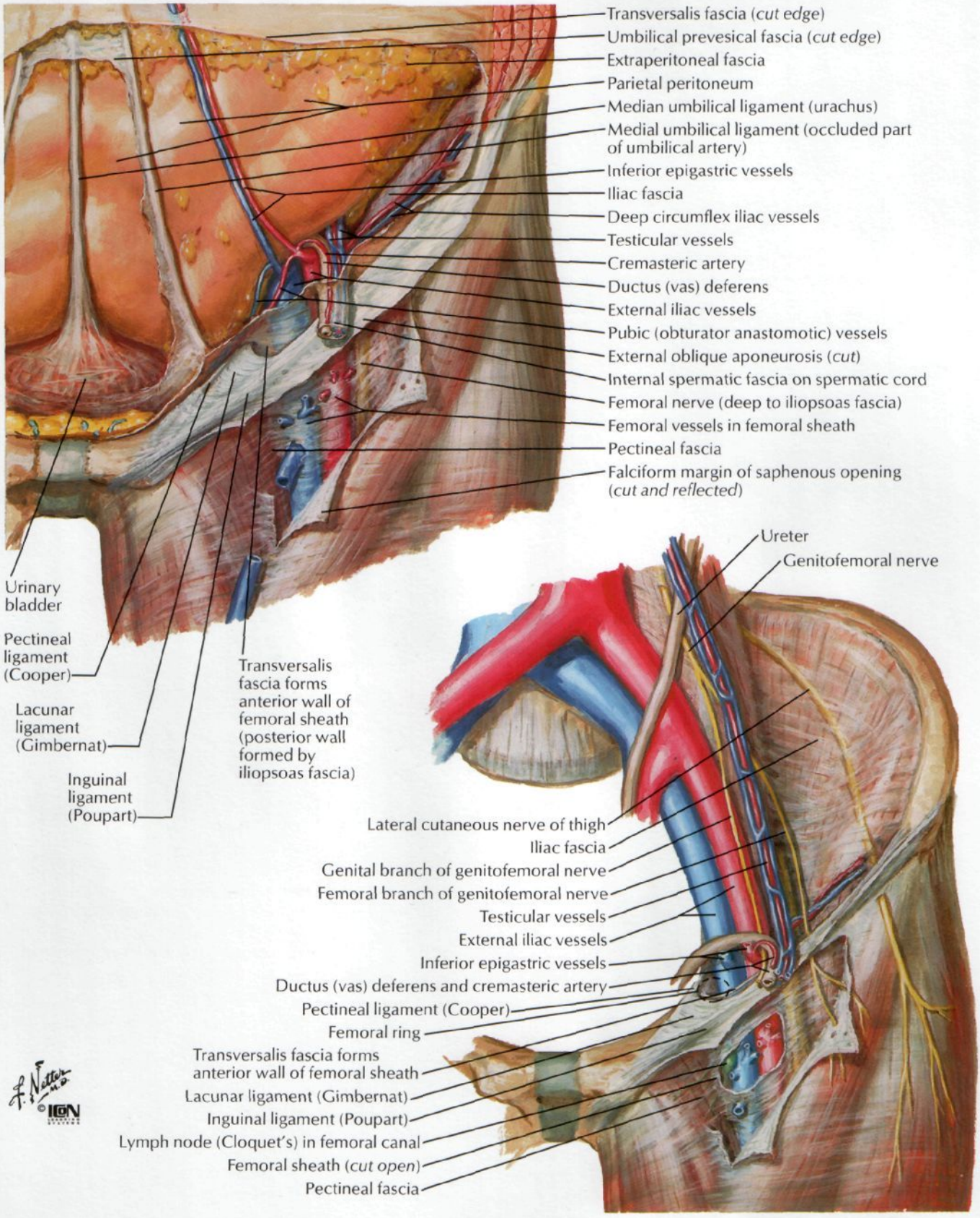

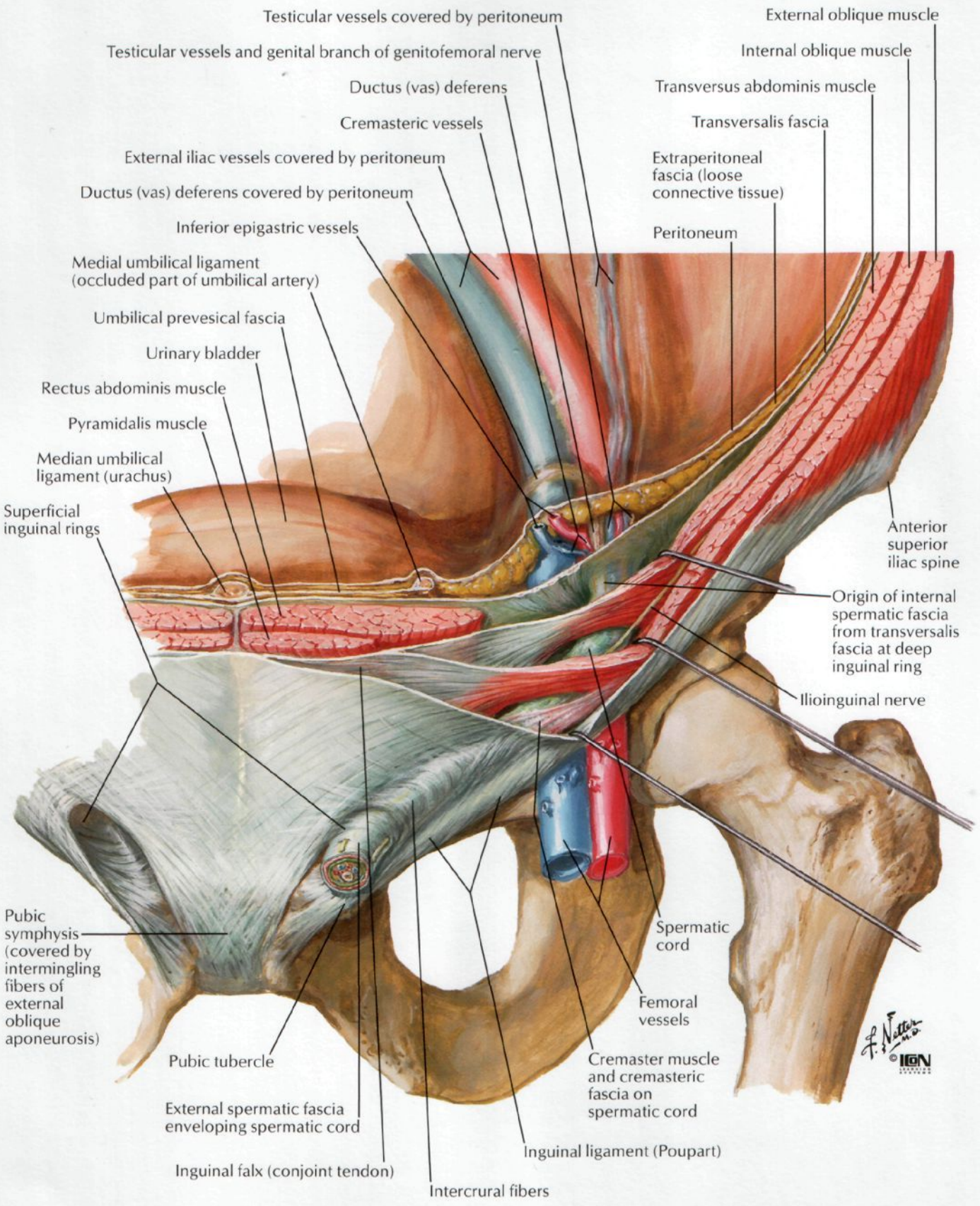
Testicular vessels covered by peritoneum
Testicular vessels and genital branch of genitofemoral nerve
Ductus (vas) deferens
Cremasteric vessels
External iliac vessels covered by peritoneum
Ductus (vas) deferens covered by peritoneum
Inferior epigastric vessels
Medial umbilical ligament (occluded part of umbilical artery)
Umbilical prevesical fascia
Urinary bladder
Rectus abdominis muscle
Pyramidalis muscle
Median umbilical ligament (urachus)
Superficial inguinal rings
External oblique muscle
Internal oblique muscle
Transversus abdominis muscle
Transversalis fascia
Extraperitoneal fascia (loose connective tissue)
Peritoneum
Anterior superior iliac spine
Origin of internal spermatic fascia from transversalis fascia at deep inguinal ring
Ilioinguinal nerve
Spermatic cord
Femoral vessels
Cremaster muscle and cremasteric fascia on spermatic cord
Inguinal ligament (Poupart)
Intercrural fibers
Inguinal falx (conjoint tendon)
External spermatic fascia enveloping spermatic cord
Pubic tubercle
Pubic symphysis (covered by intermingling fibers of external oblique aponeurosis)

Indirect Inguinal Hernia

COMPARE TO PLATE 253

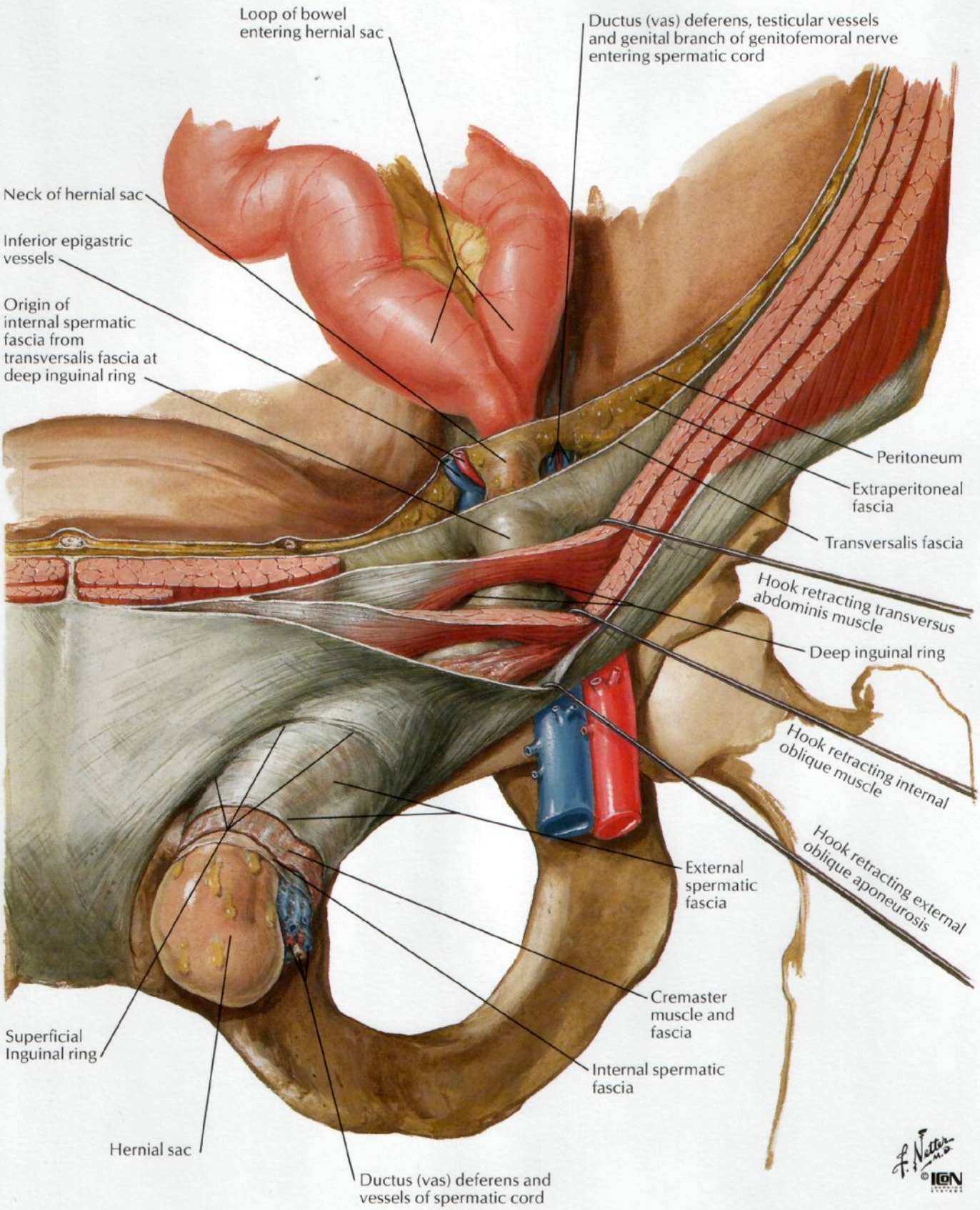

Posterior Abdominal Wall: Internal View

FOR DIAPHRAGM SEE ALSO PLATE 189

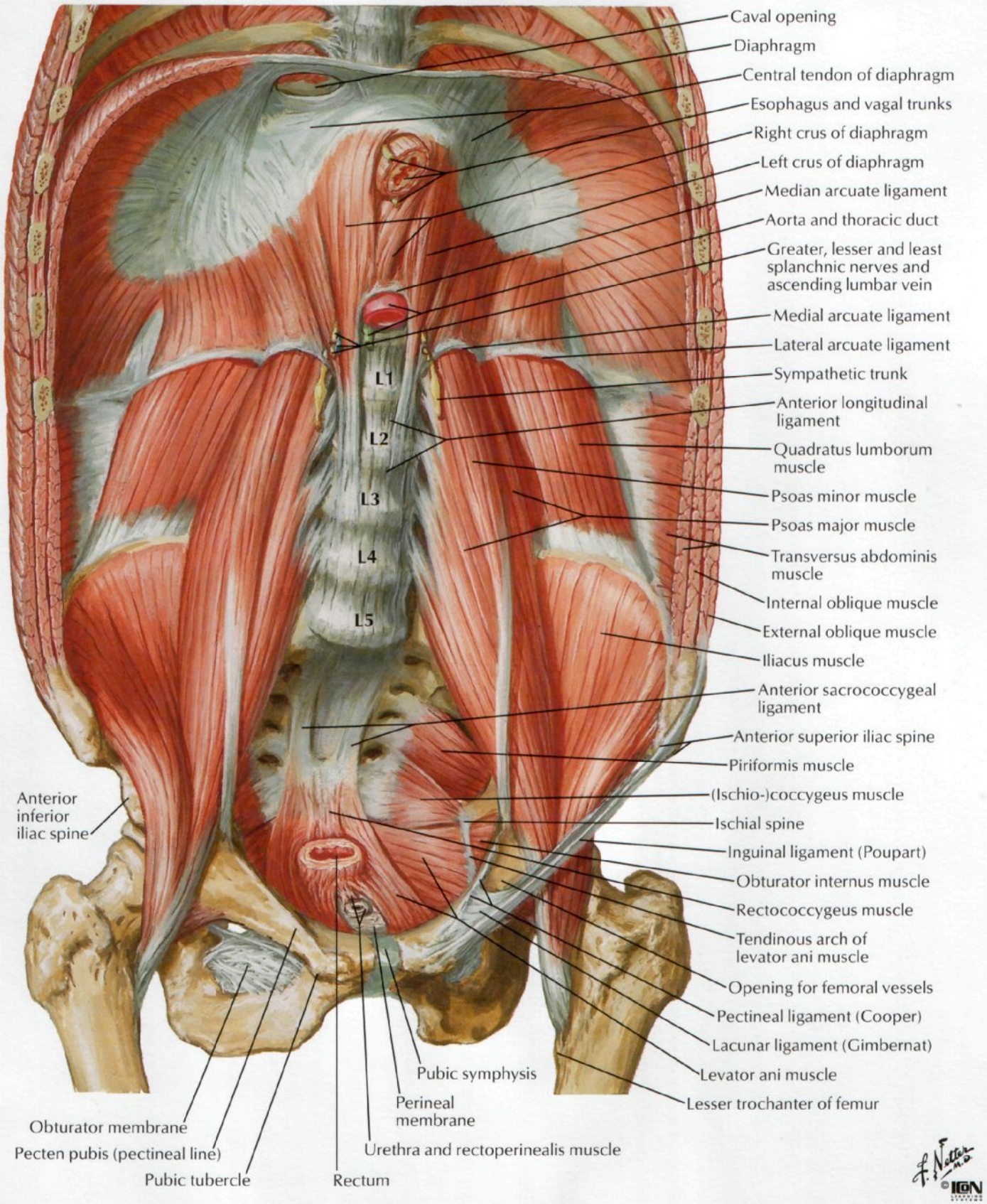

F. Netter M.D.
©IGN

Arteries of Posterior Abdominal Wall

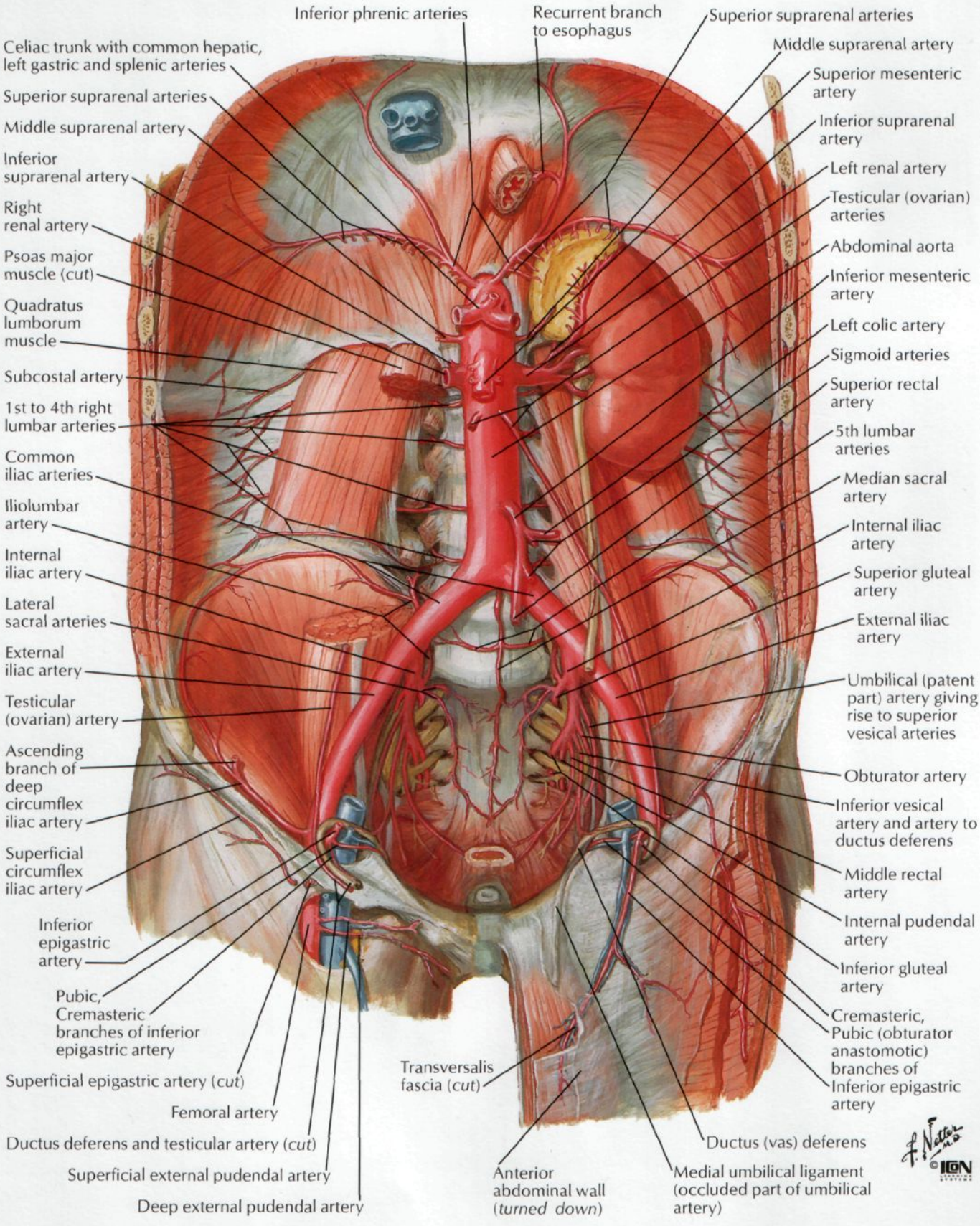

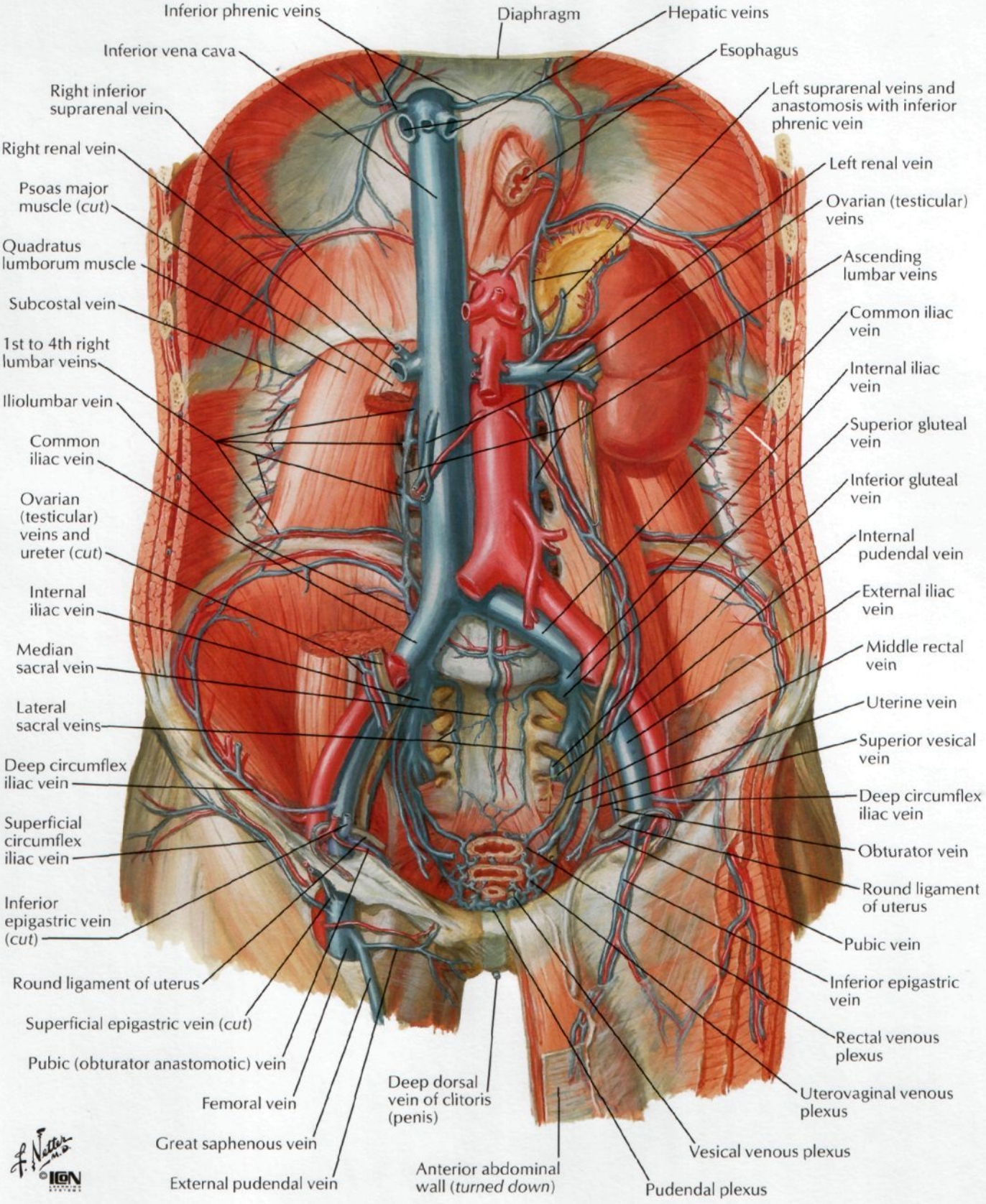
Inferior phrenic veins
Diaphragm
Hepatic veins
Inferior vena cava
Esophagus
Right inferior suprarenal vein
Left suprarenal veins and anastomosis with inferior phrenic vein
Right renal vein
Left renal vein
Psoas major muscle (cut)
Ovarian (testicular) veins
Quadratus lumborum muscle
Ascending lumbar veins
Subcostal vein
Common iliac vein
1st to 4th right lumbar veins
Internal iliac vein
Iliolumbar vein
Superior gluteal vein
Common iliac vein
Inferior gluteal vein
Ovarian (testicular) veins and ureter (cut)
Internal pudendal vein
Internal iliac vein
External iliac vein
Median sacral vein
Middle rectal vein
Lateral sacral veins
Uterine vein
Deep circumflex iliac vein
Superior vesical vein
Superficial circumflex iliac vein
Deep circumflex iliac vein
Obturator vein
Inferior epigastric vein (cut)
Round ligament of uterus
Pubic vein
Round ligament of uterus
Inferior epigastric vein
Superficial epigastric vein (cut)
Rectal venous plexus
Pubic (obturator anastomotic) vein
Deep dorsal vein of clitoris (penis)
Uterovaginal venous plexus
Femoral vein
Great saphenous vein
Vesical venous plexus
Anterior abdominal wall (turned down)
External pudendal vein
Pudendal plexus

Lymph Vessels and Nodes of Posterior Abdominal Wall

SEE ALSO PLATE 387

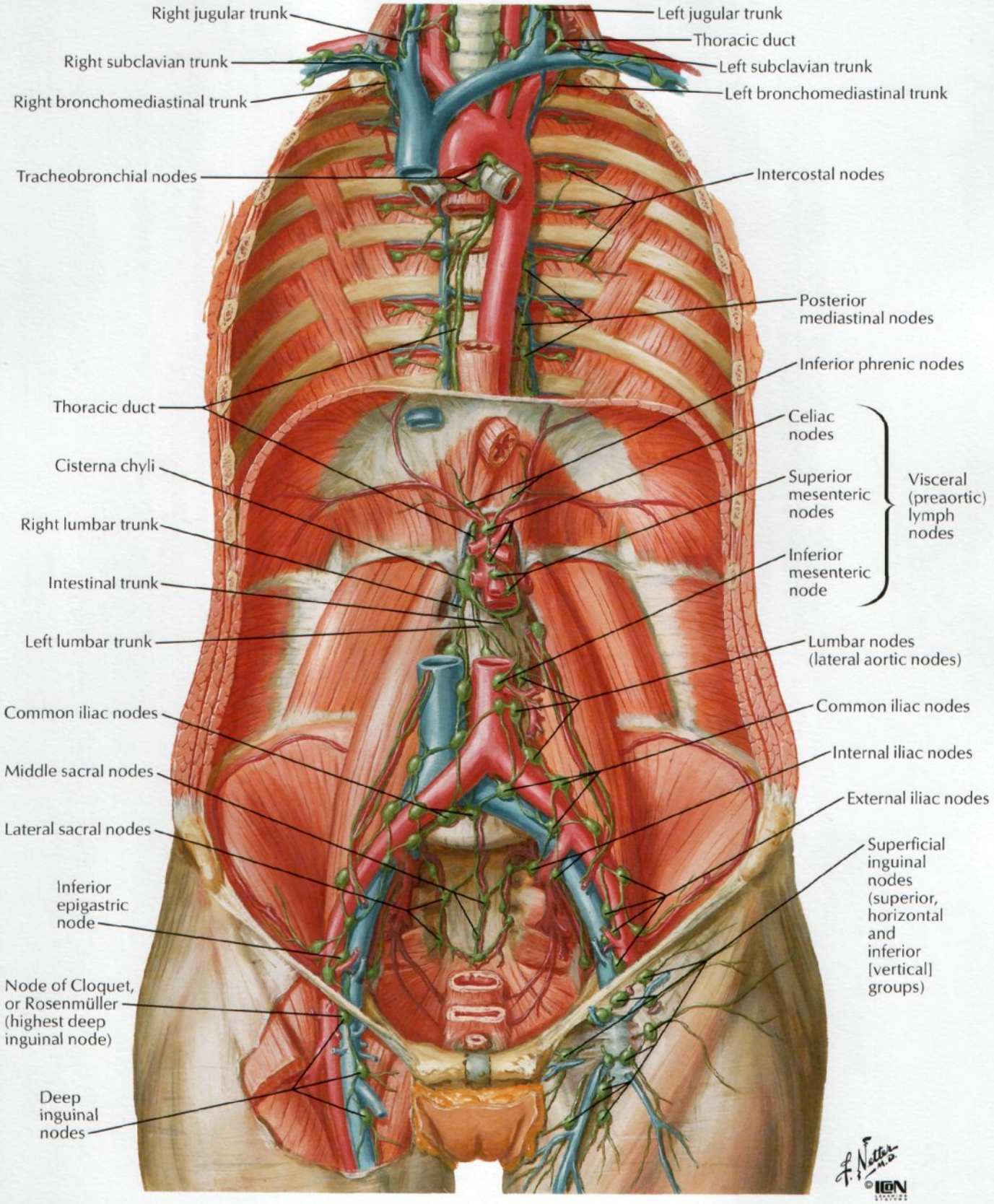

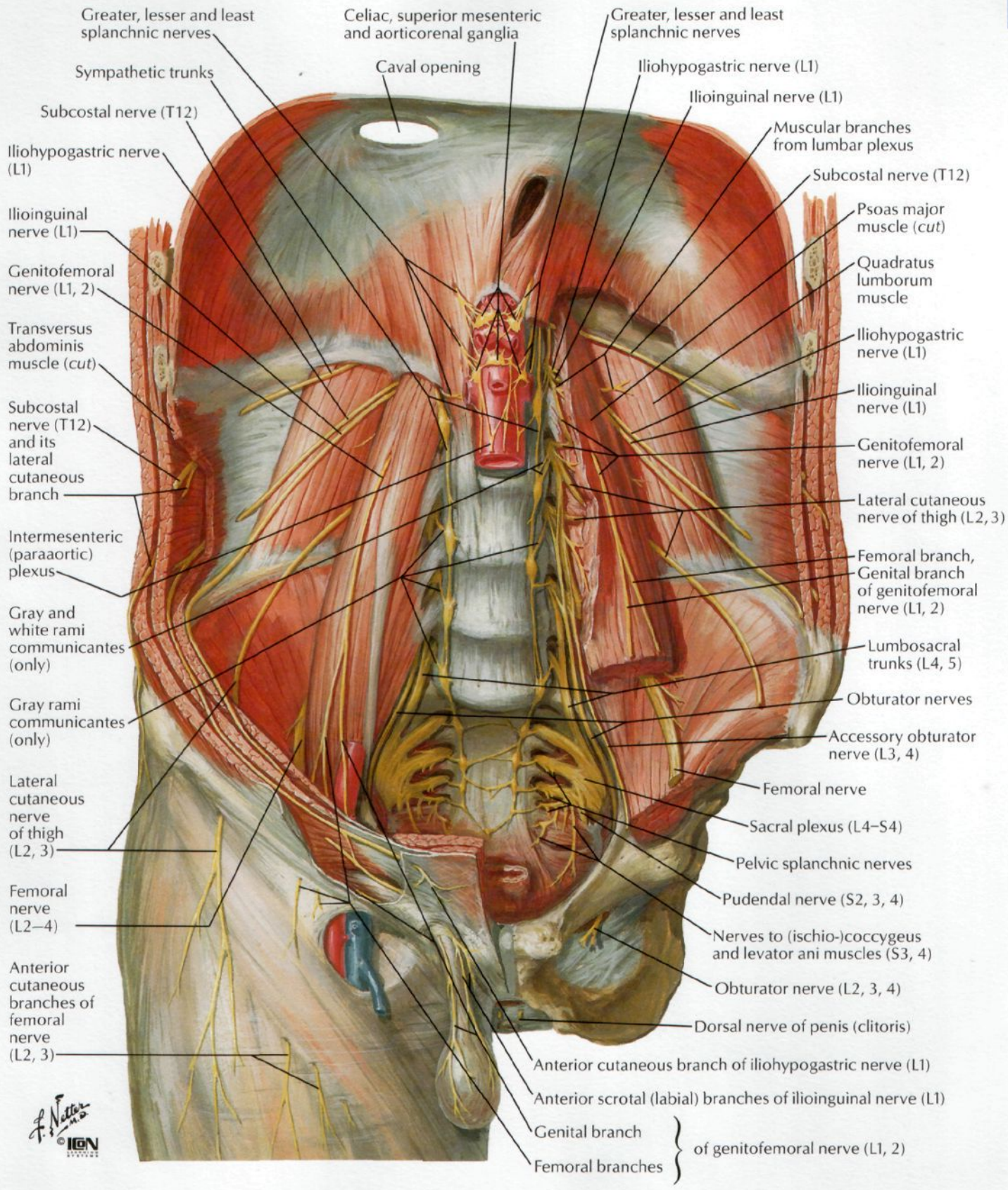
Greater, lesser and least splanchnic nerves
Sympathetic trunks
Subcostal nerve (T12)
Iliohypogastric nerve (L1)
Ilioinguinal nerve (L1)
Genitofemoral nerve (L1, 2)
Transversus abdominis muscle (cut)
Subcostal nerve (T12) and its lateral cutaneous branch
Intermesenteric (paraaortic) plexus
Gray and white rami communicantes (only)
Gray rami communicantes (only)
Lateral cutaneous nerve of thigh (L2, 3)
Femoral nerve (L2–4)
Anterior cutaneous branches of femoral nerve (L2, 3)
Celiac, superior mesenteric and aorticorenal ganglia
Caval opening
Greater, lesser and least splanchnic nerves
Iliohypogastric nerve (L1)
Ilioinguinal nerve (L1)
Muscular branches from lumbar plexus
Subcostal nerve (T12)
Psoas major muscle (cut)
Quadratus lumborum muscle
Iliohypogastric nerve (L1)
Ilioinguinal nerve (L1)
Genitofemoral nerve (L1, 2)
Lateral cutaneous nerve of thigh (L2, 3)
Femoral branch, Genital branch of genitofemoral nerve (L1, 2)
Lumbosacral trunks (L4, 5)
Obturator nerves
Accessory obturator nerve (L3, 4)
Femoral nerve
Sacral plexus (L4–S4)
Pelvic splanchnic nerves
Pudendal nerve (S2, 3, 4)
Nerves to (ischio-)coccygeus and levator ani muscles (S3, 4)
Obturator nerve (L2, 3, 4)
Dorsal nerve of penis (clitoris)
Anterior cutaneous branch of iliohypogastric nerve (L1)
Anterior scrotal (labial) branches of ilioinguinal nerve (L1)
Genital branch
Femoral branches
of genitofemoral nerve (L1, 2)
F. Netter M.D.
©IGN

Regions and Planes of Abdomen

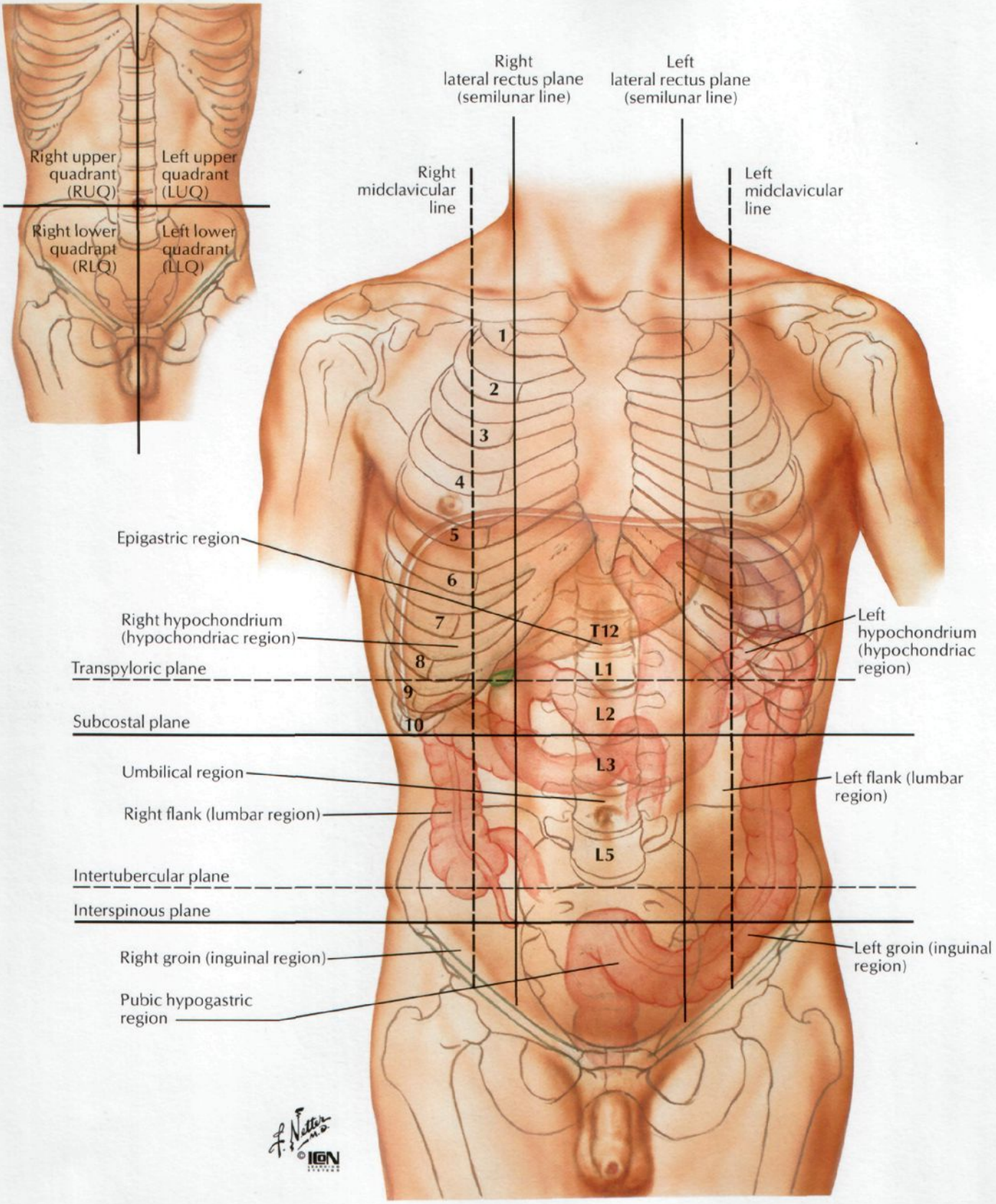

SEE ALSO PLATES 267, 335, 337

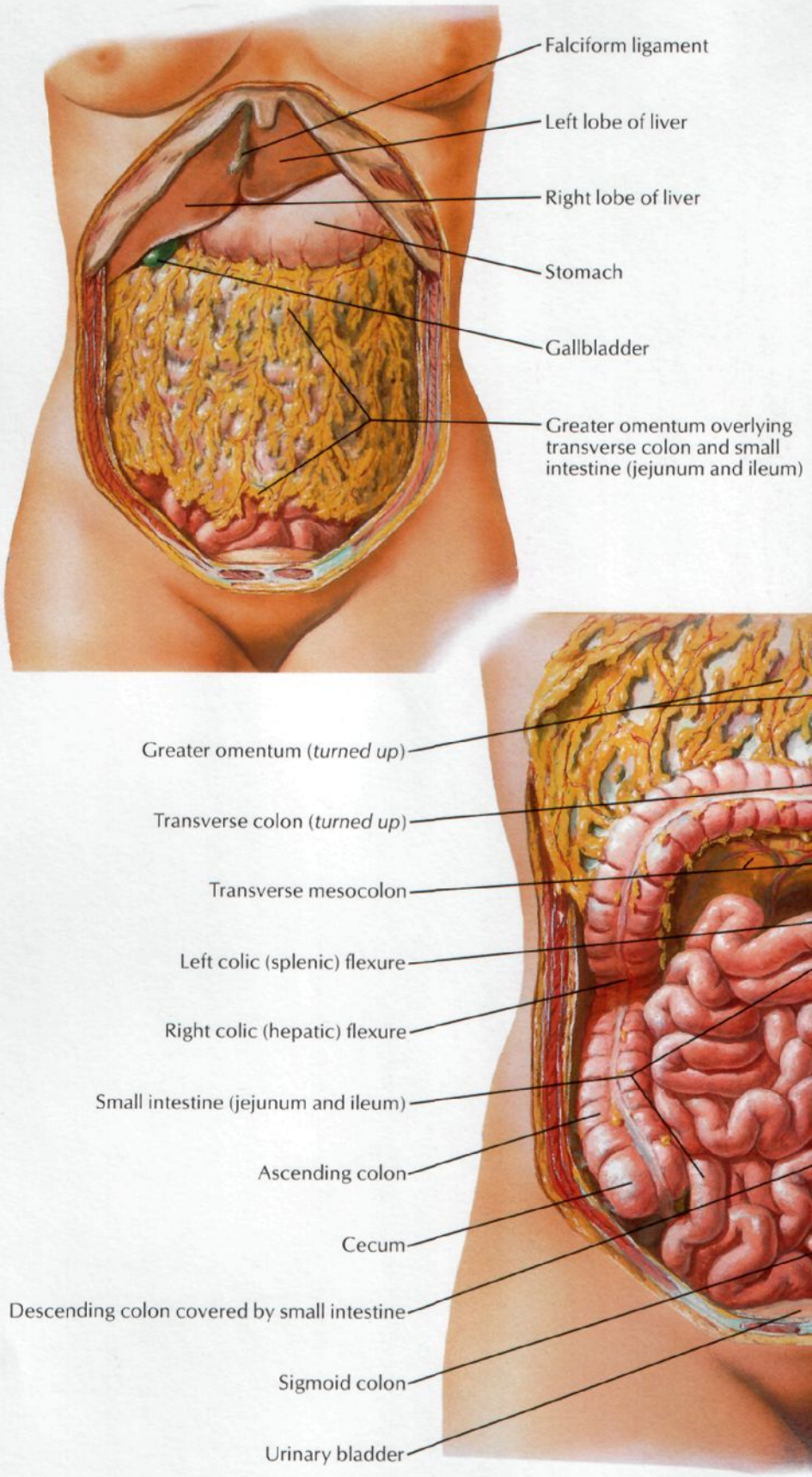

Mesenteric Relations of Intestines

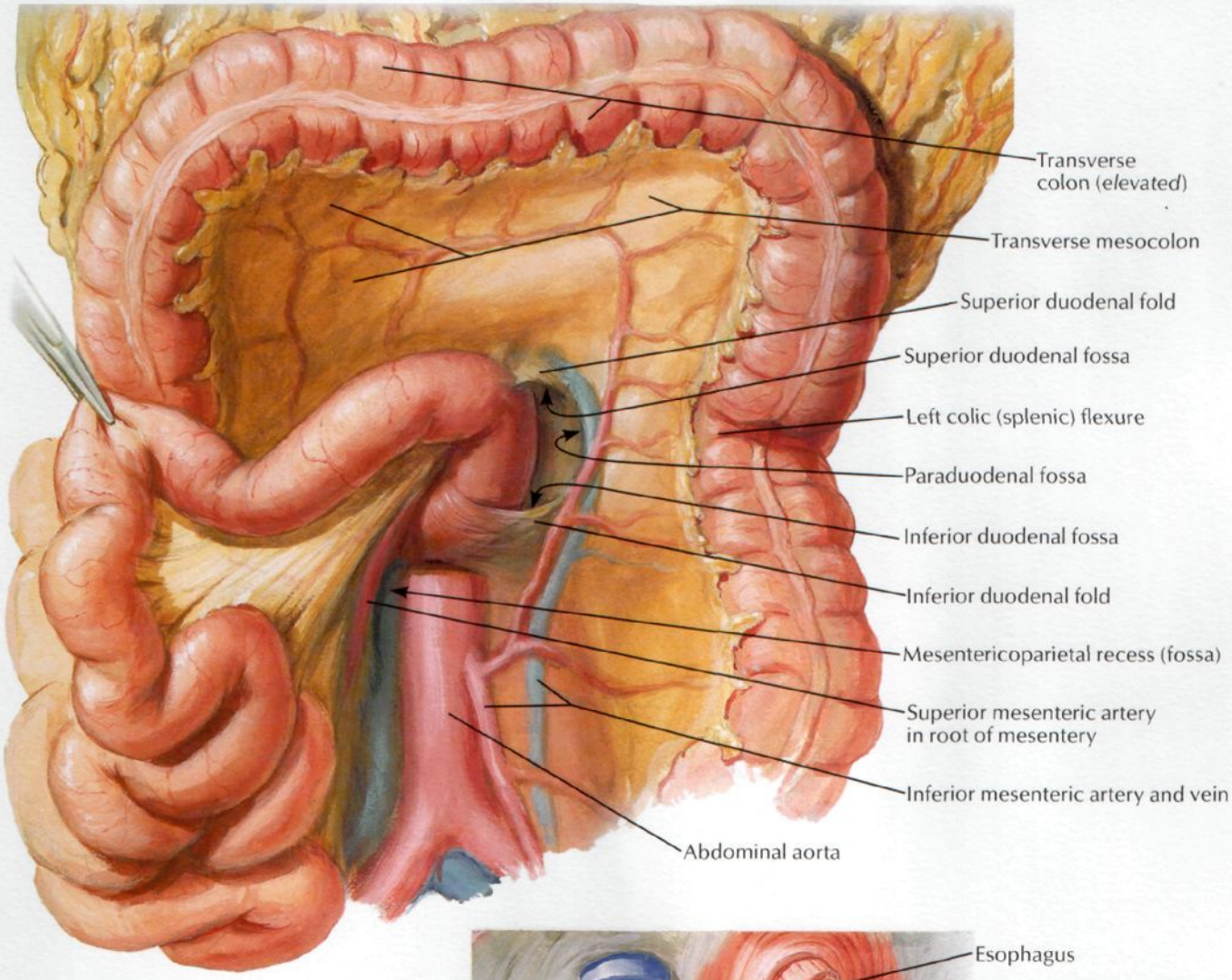

Exposure of suspensory muscle of duodenum (ligament of Treitz)

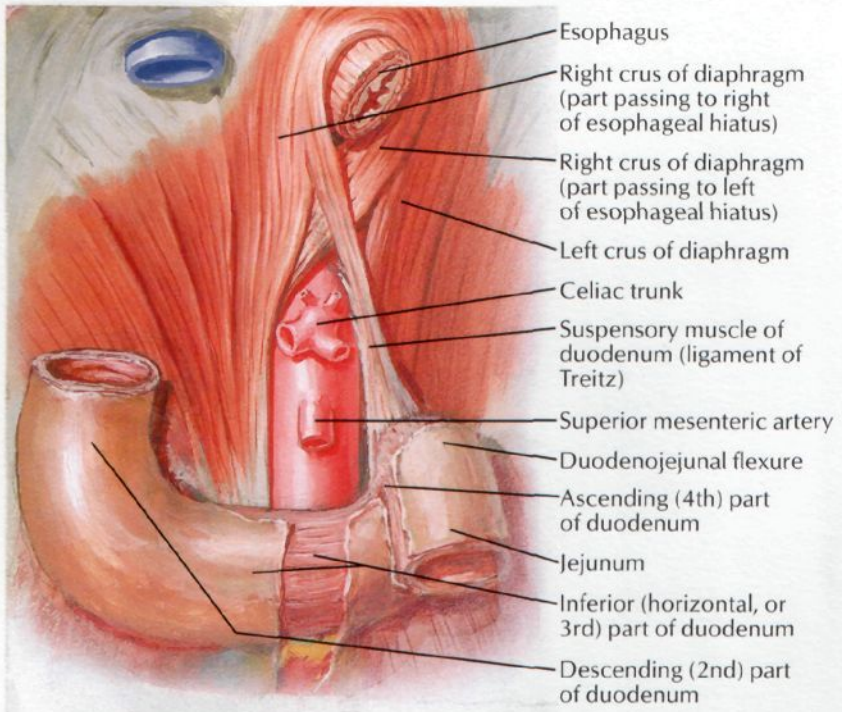

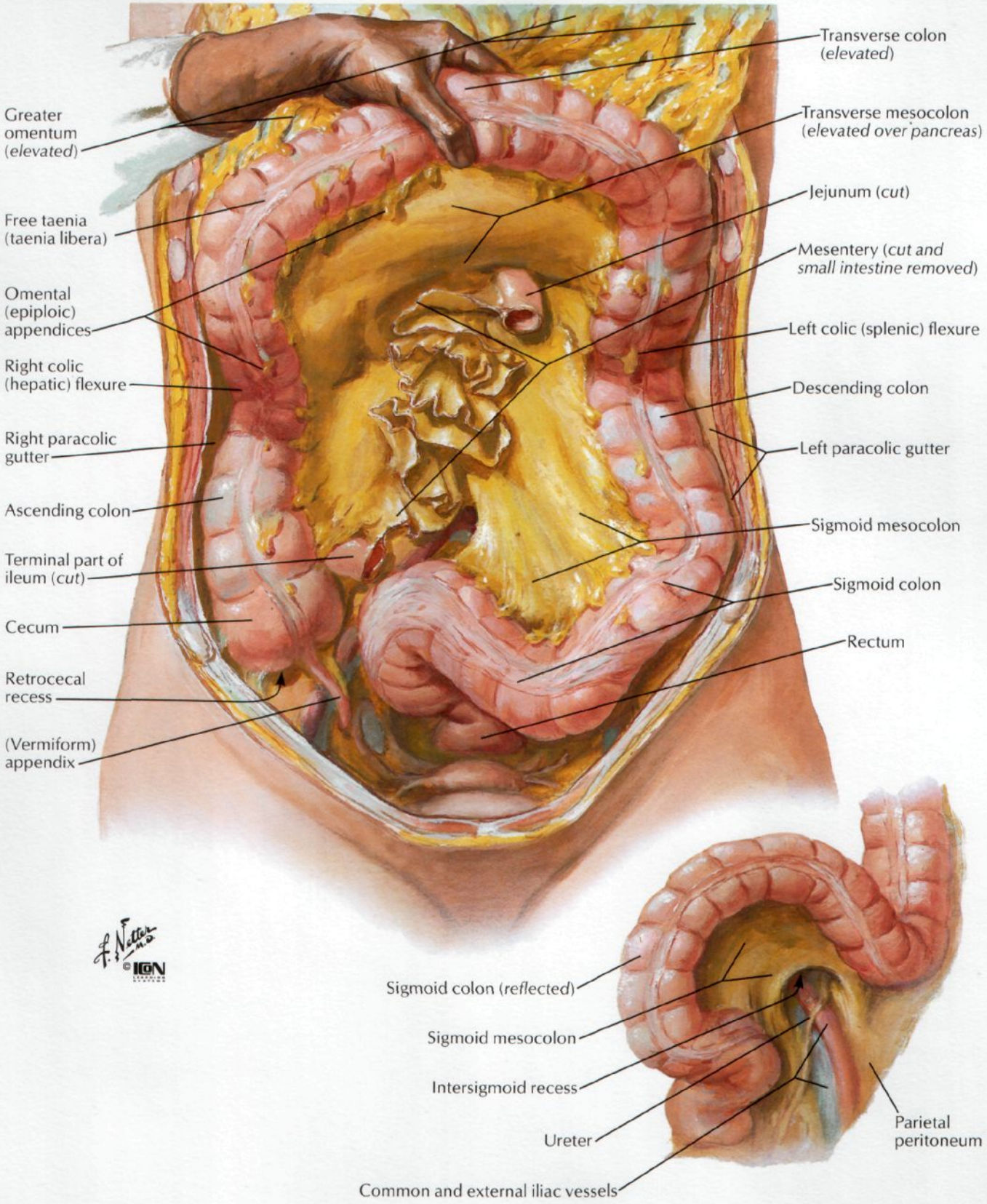
Transverse colon (elevated)
Greater omentum (elevated)
Transverse mesocolon (elevated over pancreas)
Jejunum (cut)
Free taenia (taenia libera)
Mesentery (cut and small intestine removed)
Omental (epiploic) appendices
Left colic (splenic) flexure
Right colic (hepatic) flexure
Descending colon
Right paracolic gutter
Left paracolic gutter
Ascending colon
Sigmoid mesocolon
Terminal part of ileum (cut)
Sigmoid colon
Cecum
Rectum
Retrocecal recess
(Vermiform) appendix
Sigmoid colon (reflected)
Sigmoid mesocolon
Intersigmoid recess
Ureter
Parietal peritoneum
Common and external iliac vessels

Omental Bursa: Stomach Reflected

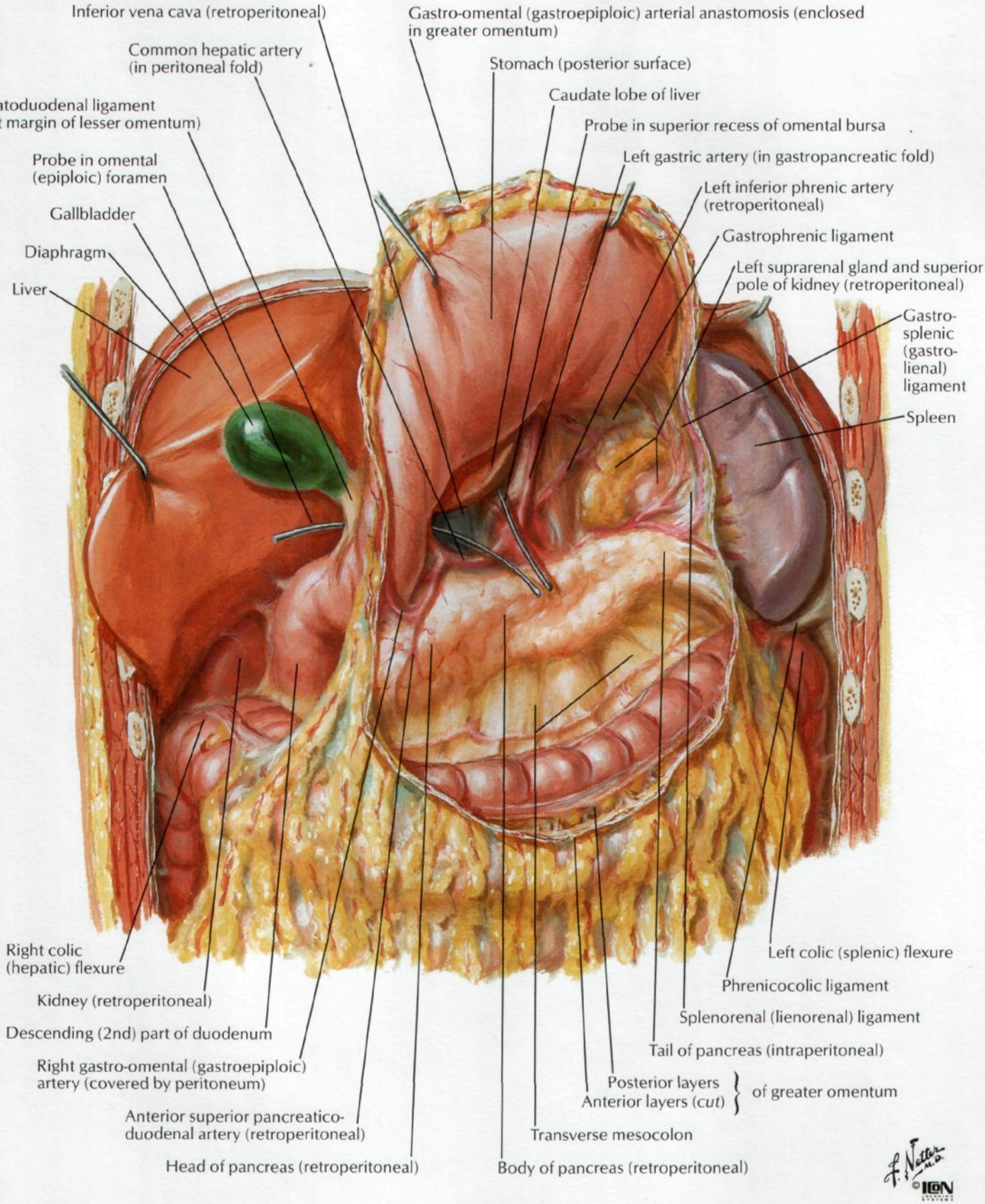

SEE ALSO PLATE 336

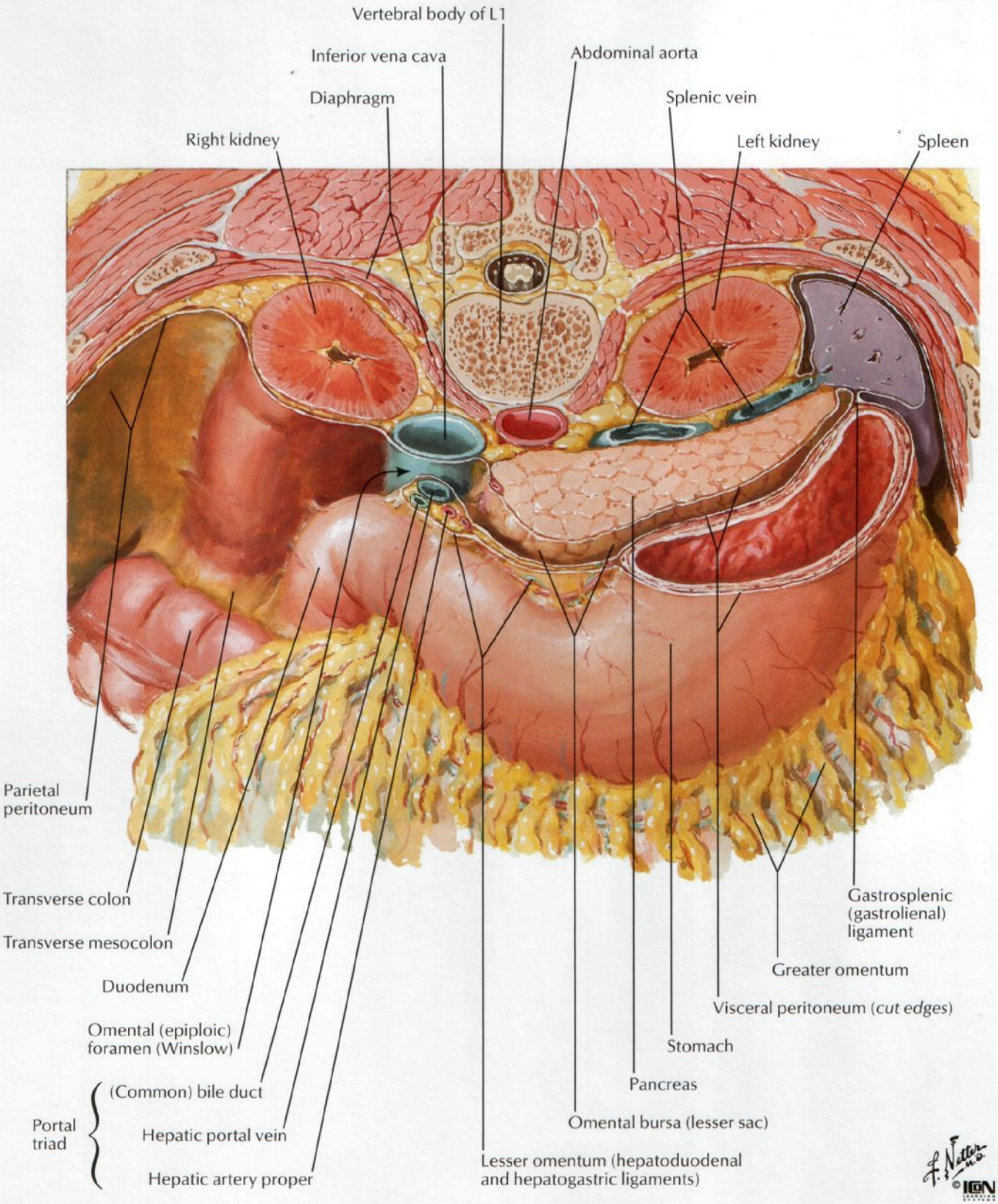

Peritoneum of Posterior Abdominal Wall

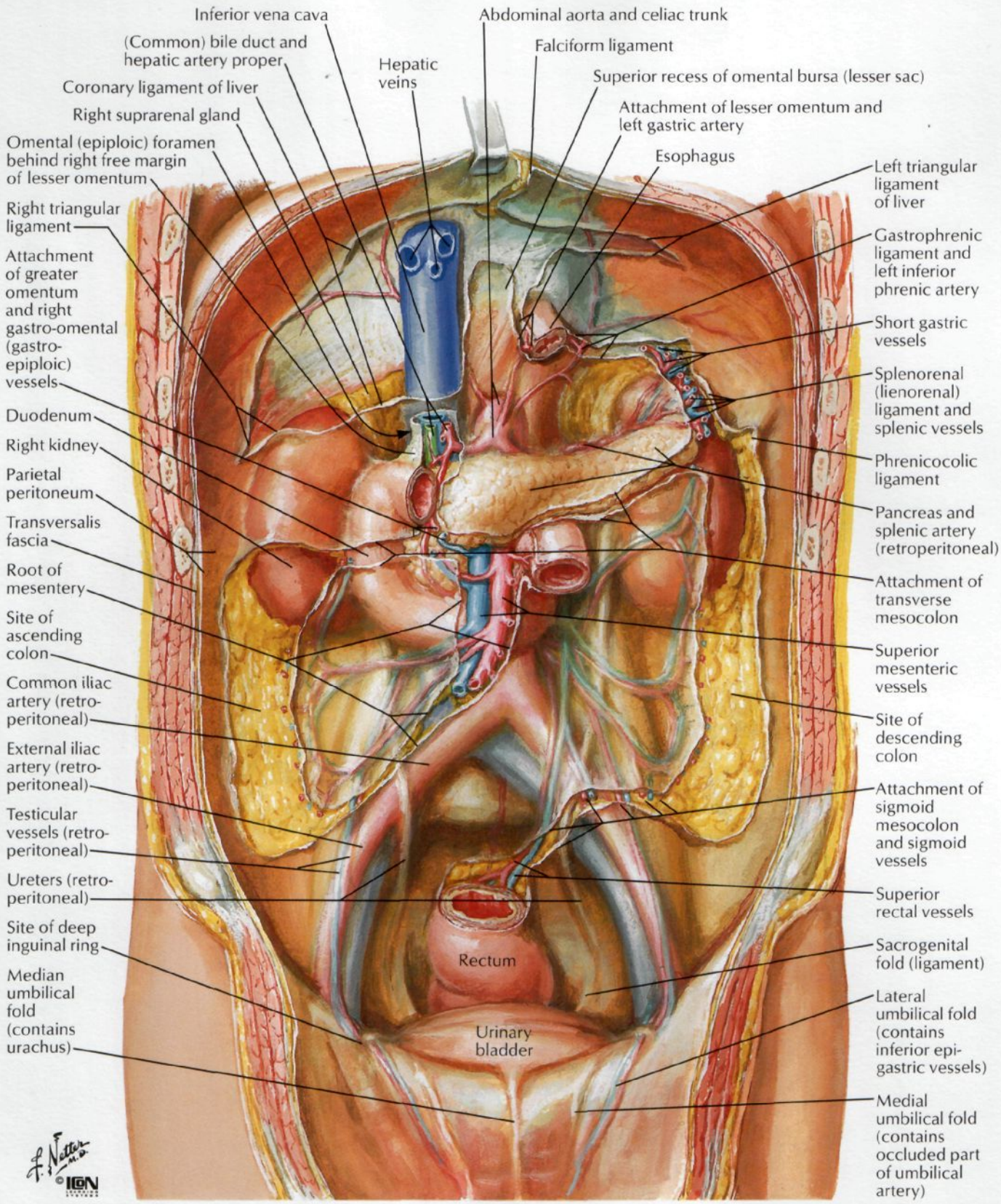

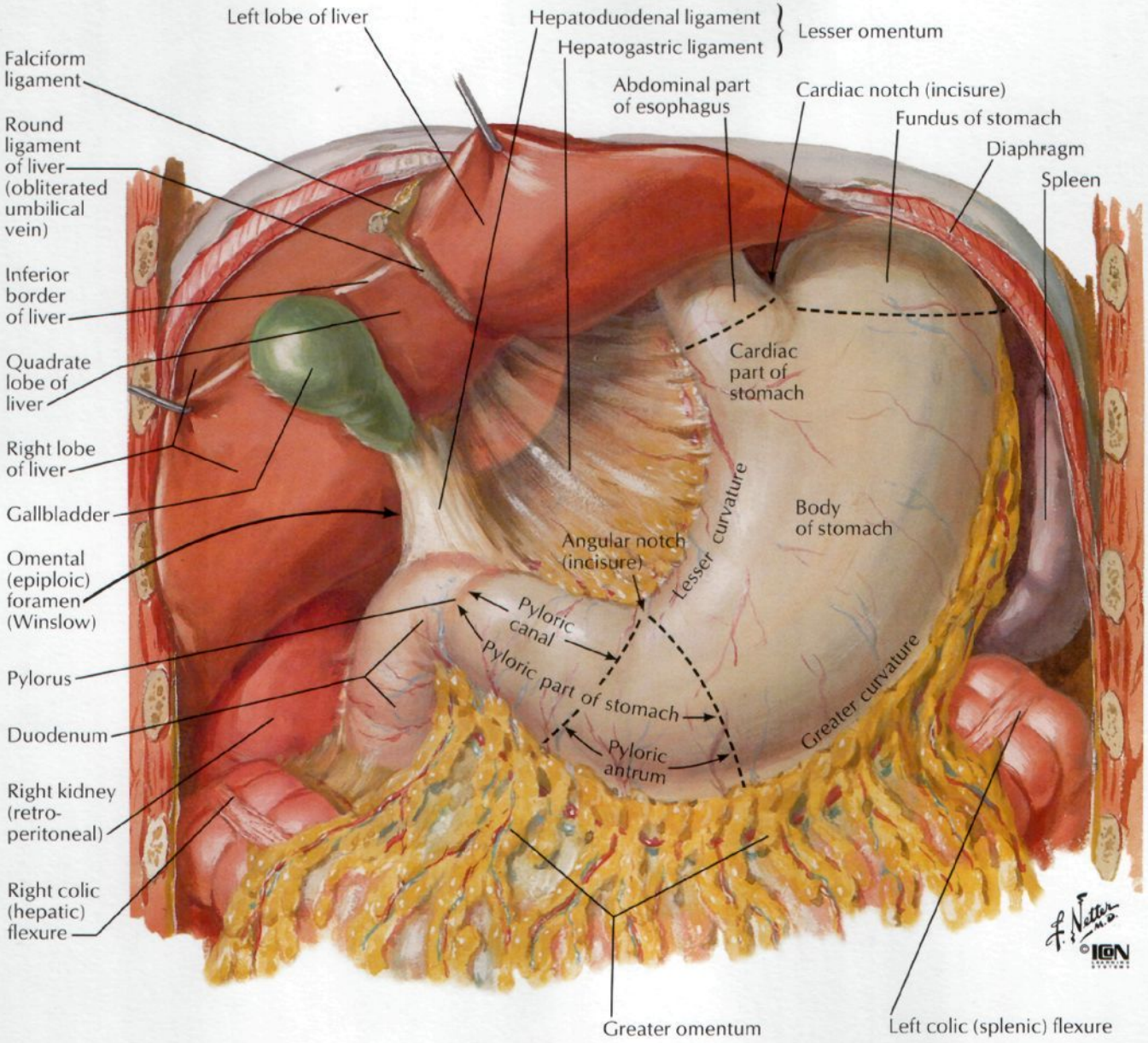

Variations in position and contour of stomach in relation to body habitus

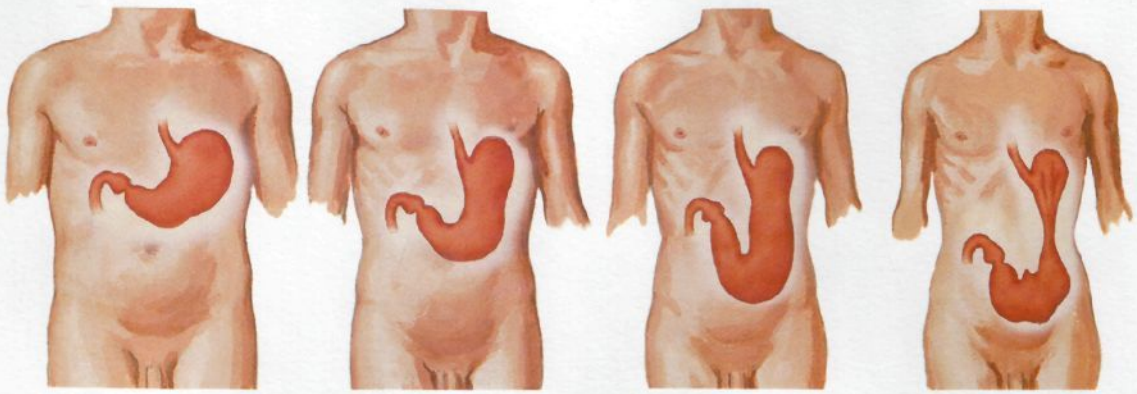

Hypertonic stomach | Orthotonic stomach | Hypotonic stomach | Atonic stomach

Mucosa of Stomach

SEE ALSO PLATE 232

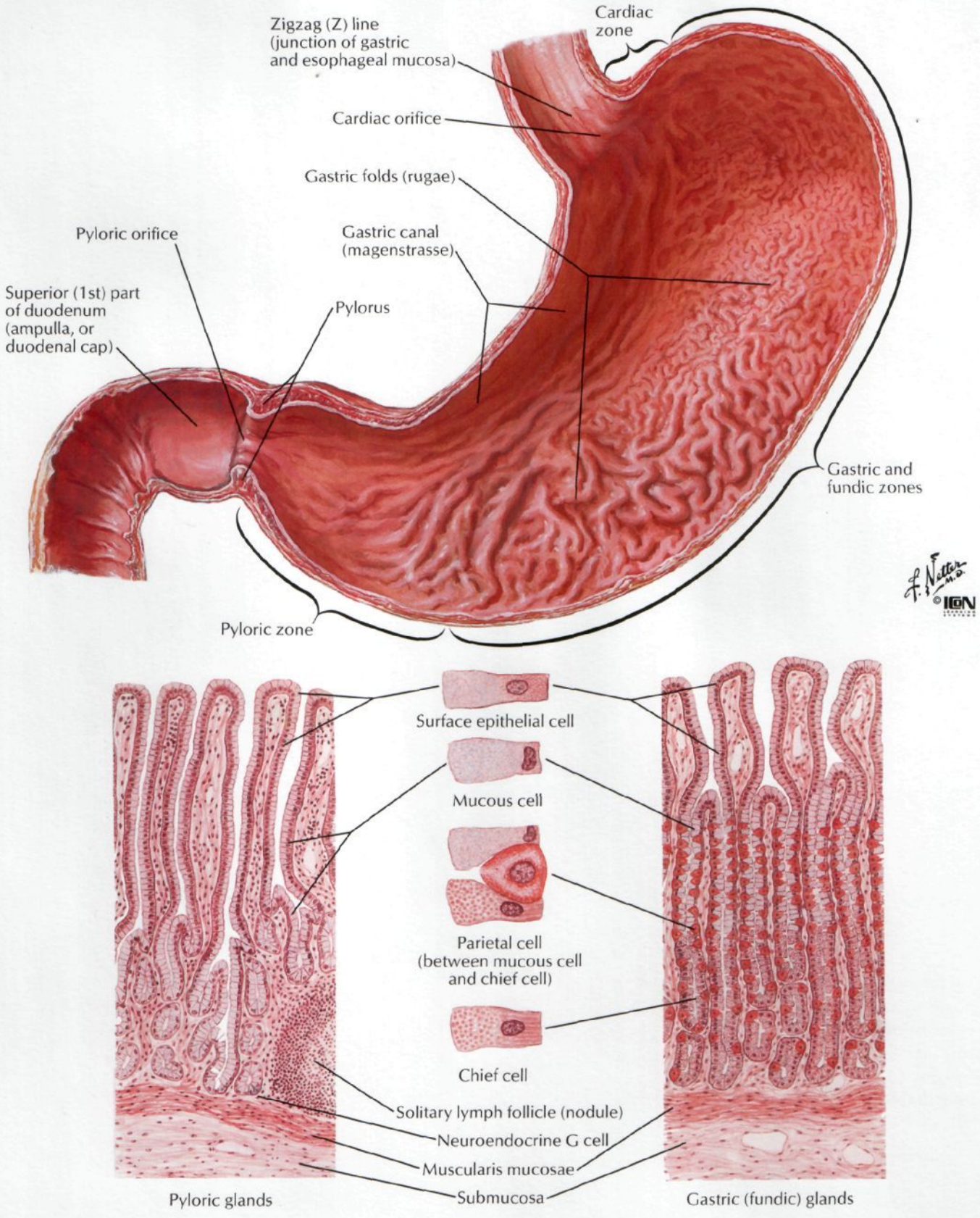

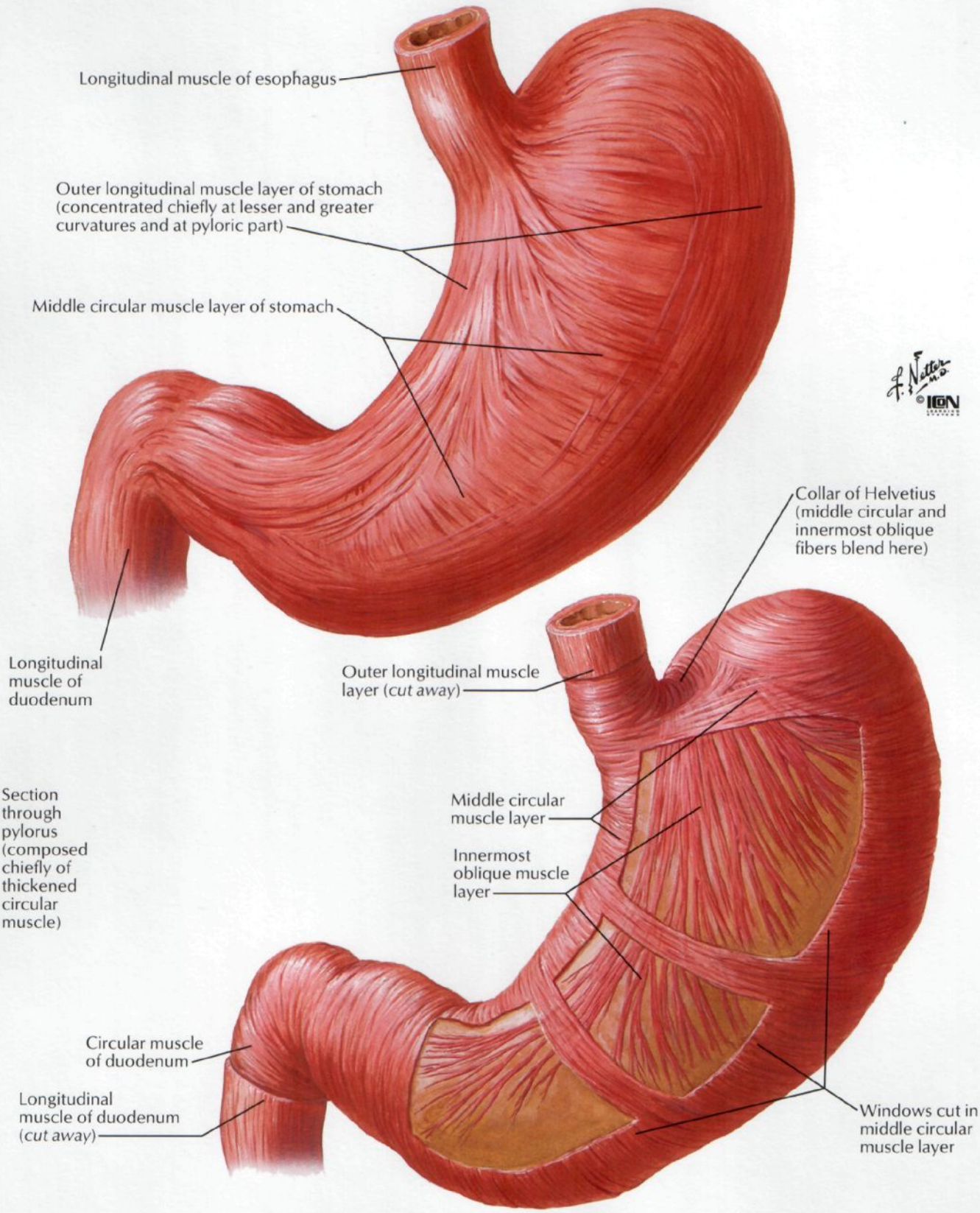
Longitudinal muscle of esophagus
Outer longitudinal muscle layer of stomach (concentrated chiefly at lesser and greater curvatures and at pyloric part)
Middle circular muscle layer of stomach
Longitudinal muscle of duodenum
Collar of Helvetius (middle circular and innermost oblique fibers blend here)
Outer longitudinal muscle layer (cut away)
Section through pylorus (composed chiefly of thickened circular muscle)
Middle circular muscle layer
Innermost oblique muscle layer
Circular muscle of duodenum
Longitudinal muscle of duodenum (cut away)
Windows cut in middle circular muscle layer

Duodenum In Situ

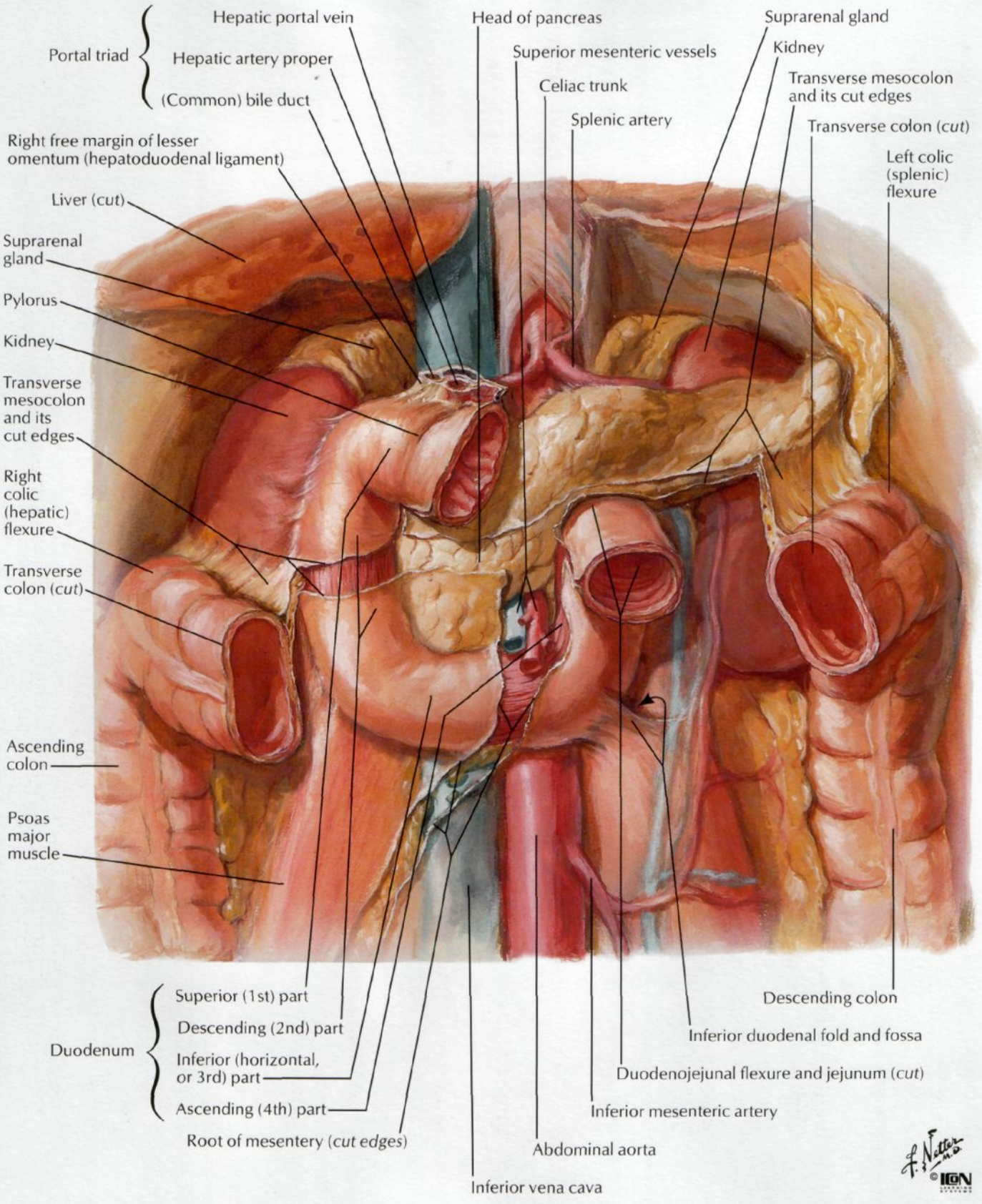

Mucosa and Musculature of Duodenum

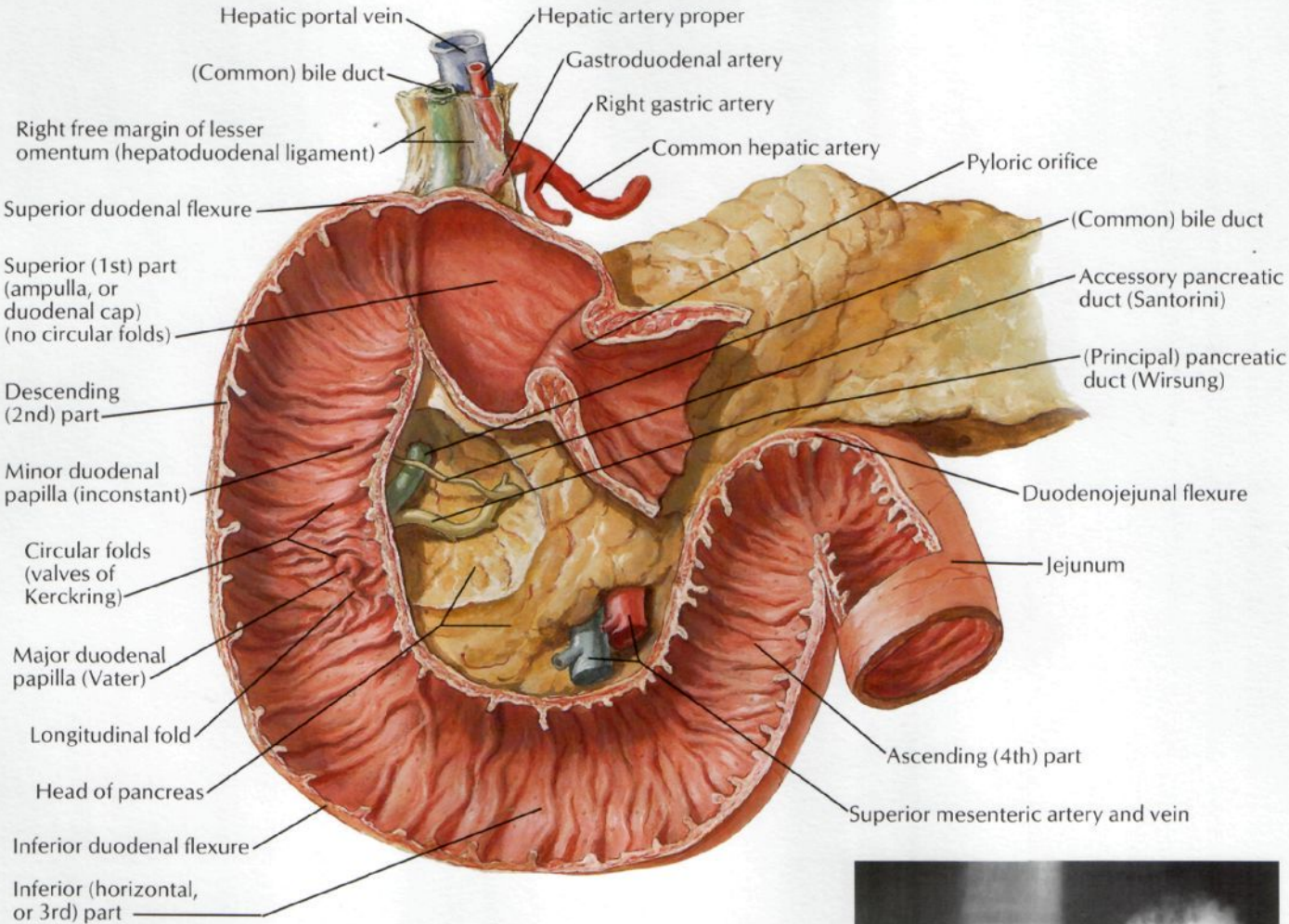

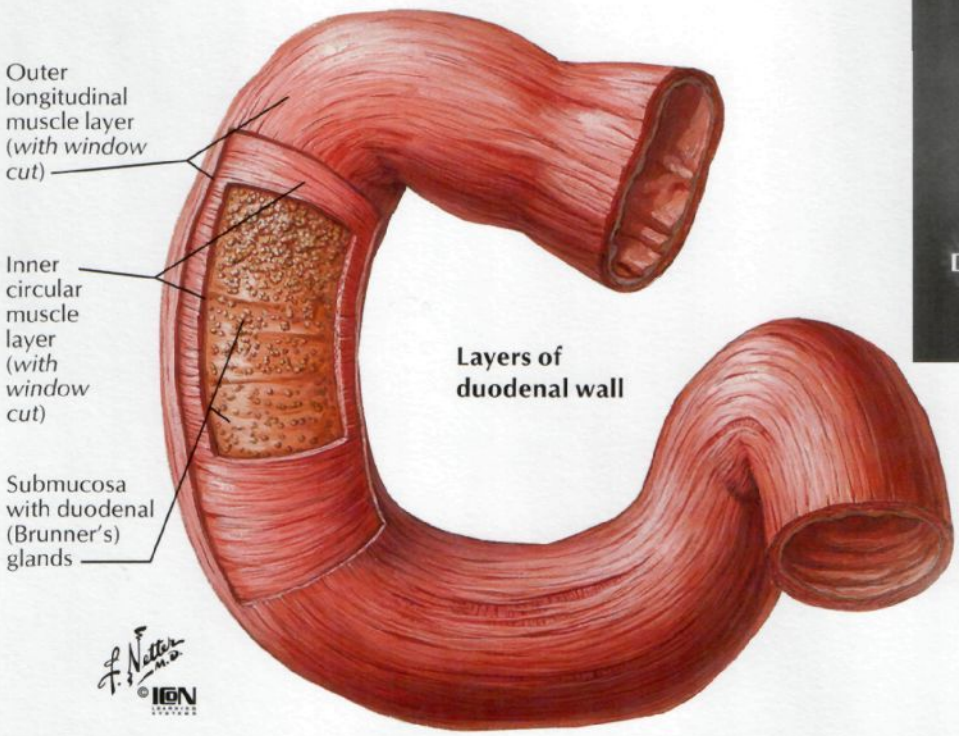

Layers of duodenal wall

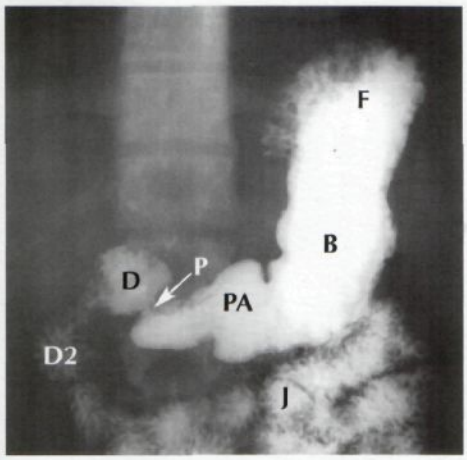

Barium radiograph of stomach, duodenum and proximal jejunum

- **B** Body of stomach
- **D** Duodenal cap
- **D2** Descending (2nd) part of duodenum
- **F** Fundus of stomach
- **J** Proximal jejunum
- **P** Pylorus
- **PA** Pyloric antrum

Mucosa and Musculature of Small Intestine

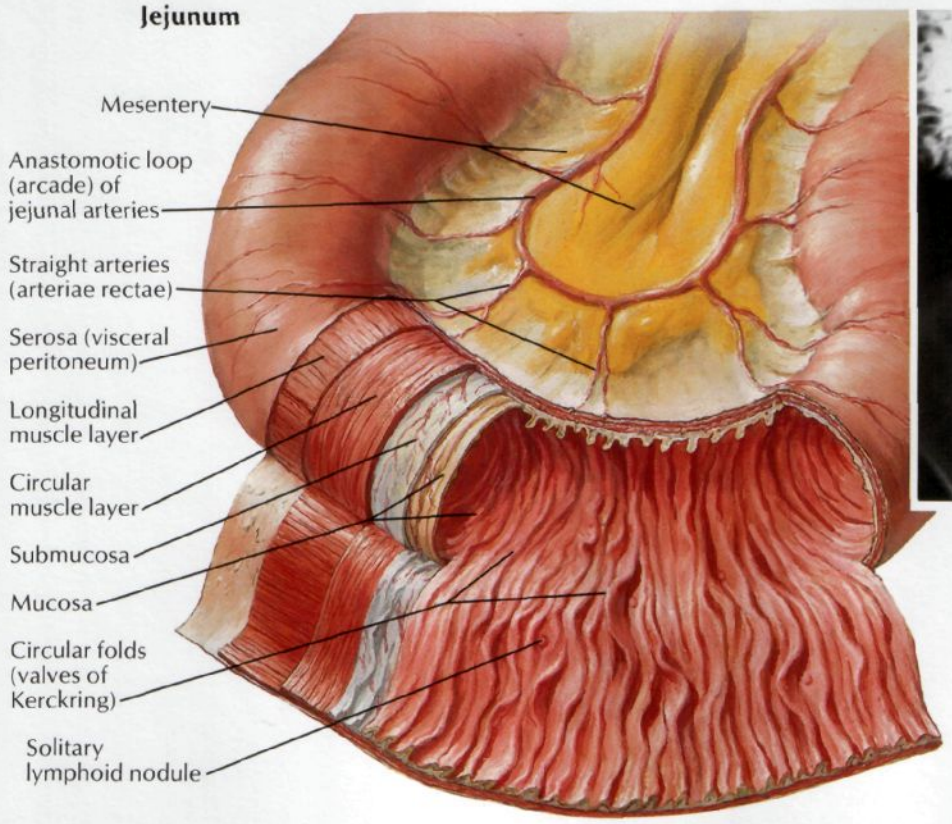

Barium radiograph of jejunum

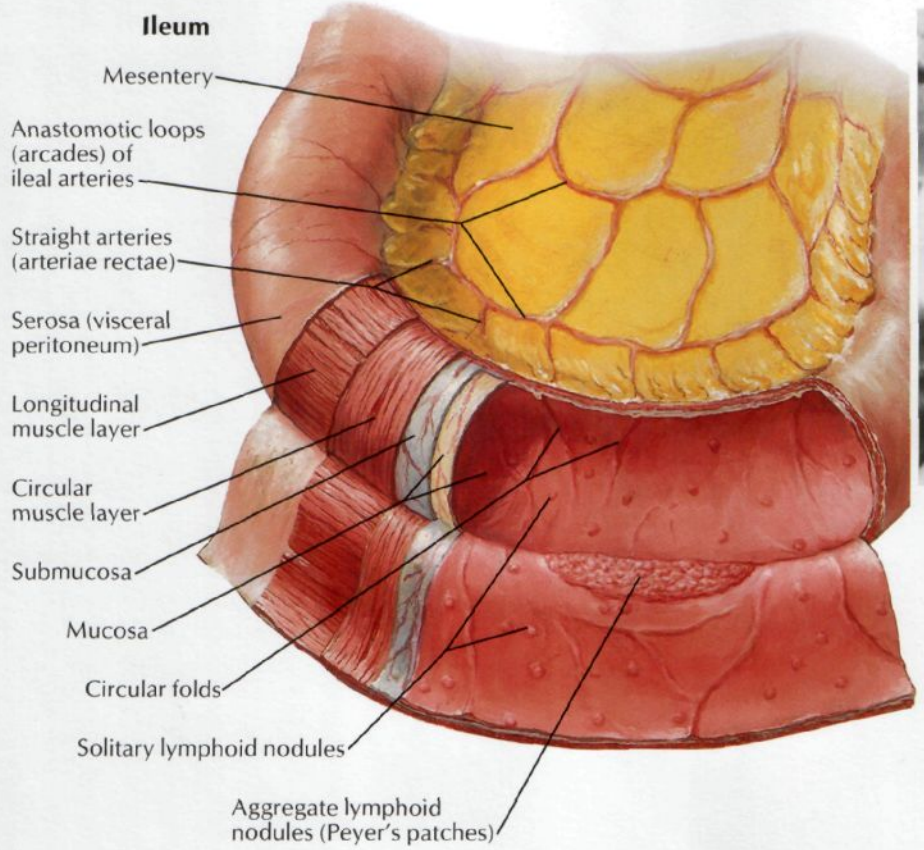

Barium radiograph of ileum

F. Netter M.D.
© ICON

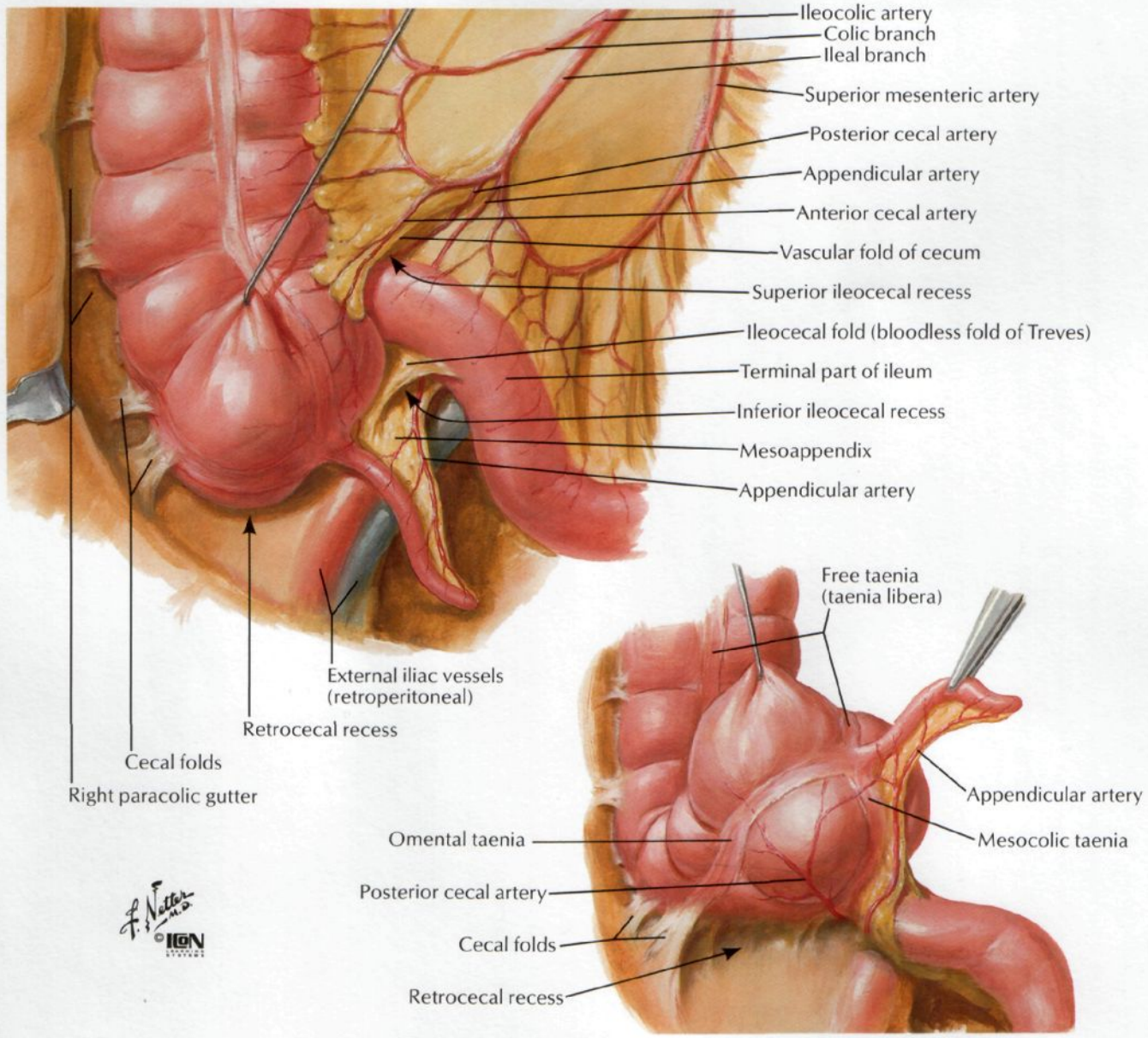

Some variations in posterior peritoneal attachment of cecum

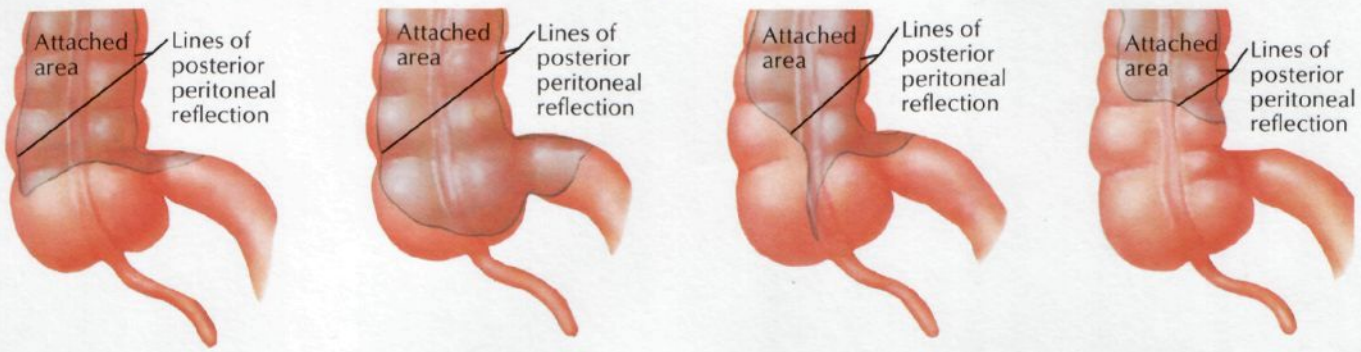

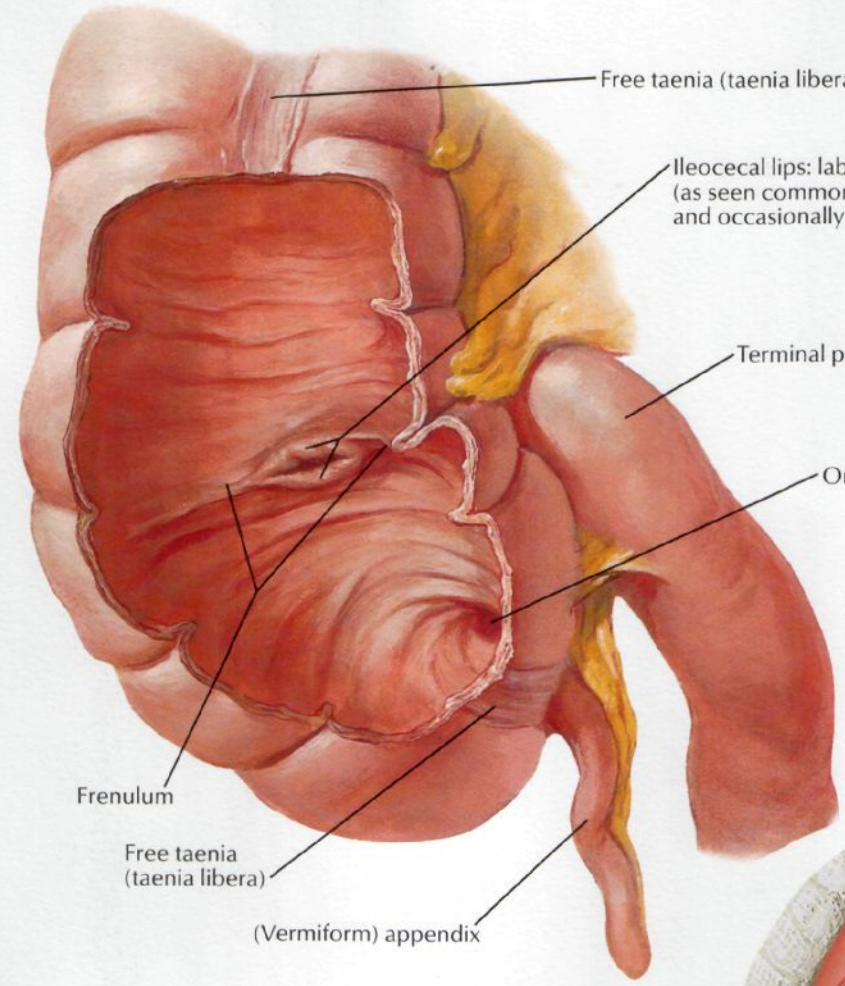

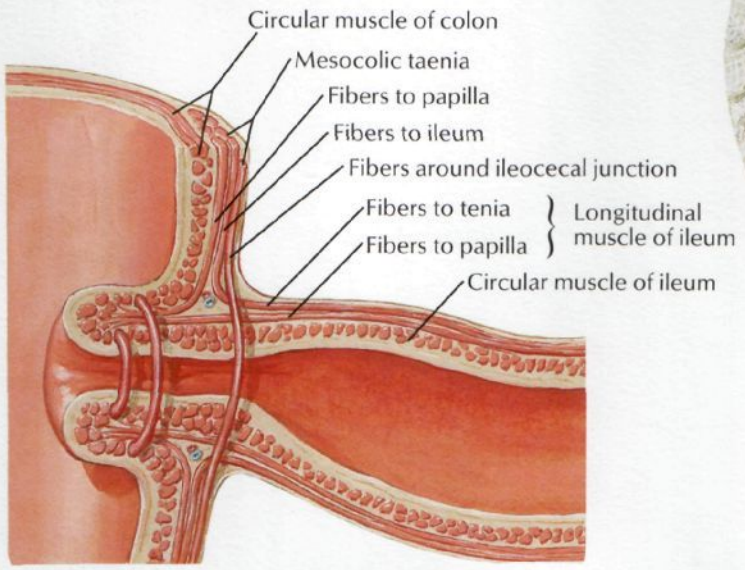

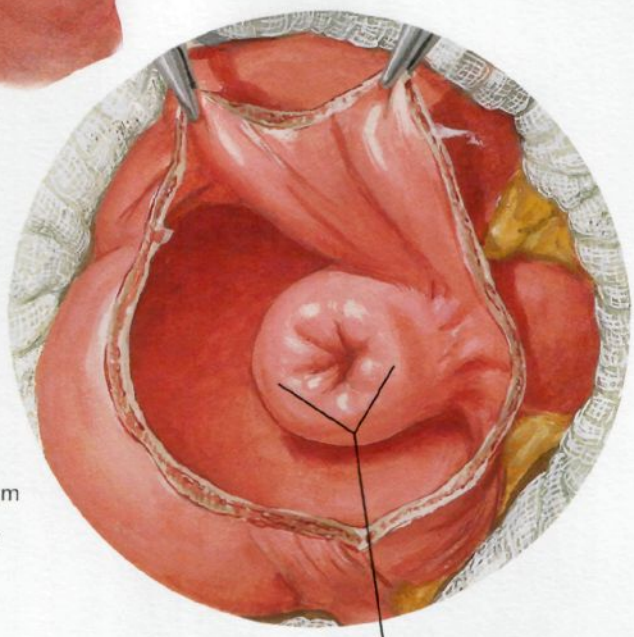

Schema of muscle fibers at ileal orifice

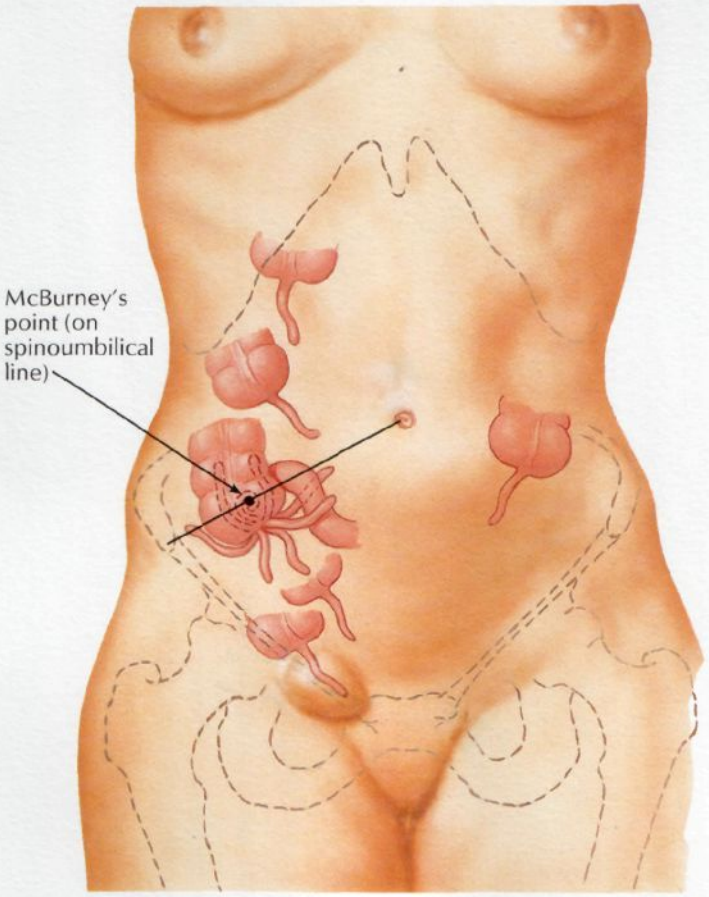

Variations in position of appendix

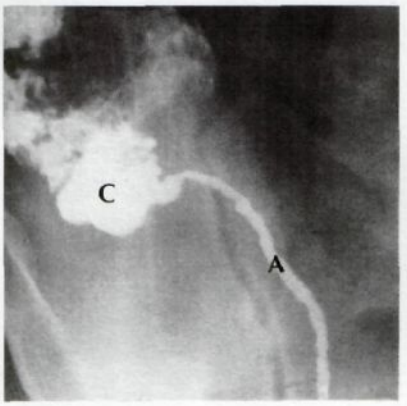

Barium radiograph of unusually long appendix (**A** Appendix; **C** Cecum)

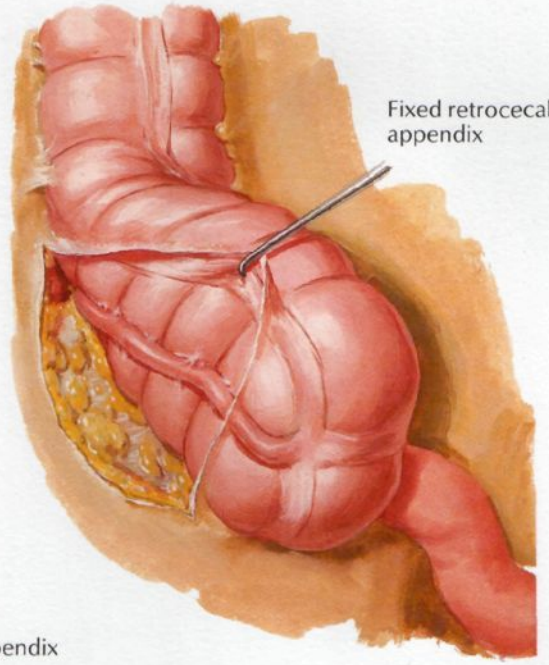

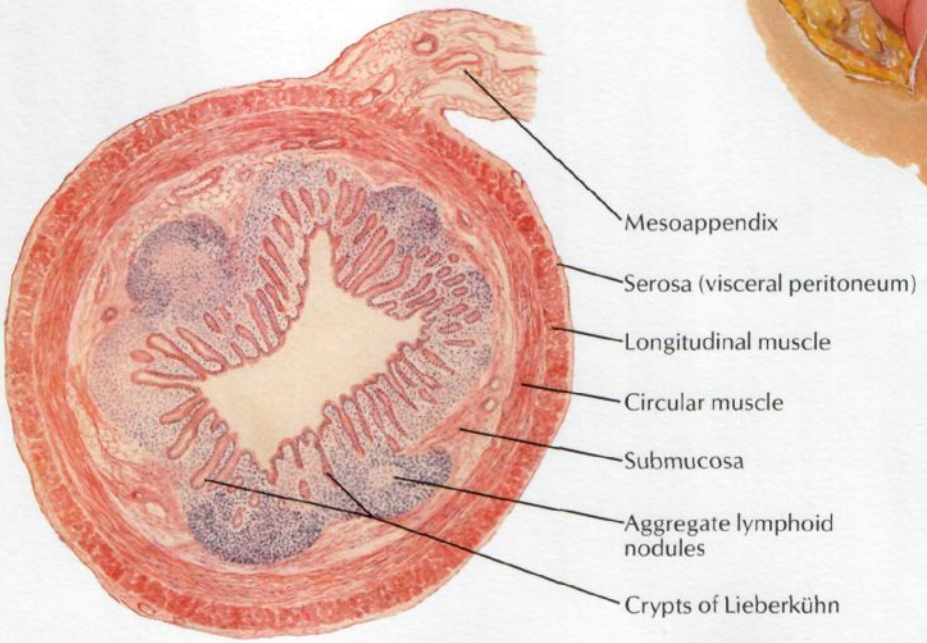

Mucosa and Musculature of Large Intestine

FOR RECTUM AND ANAL CANAL SEE PLATES 372–377

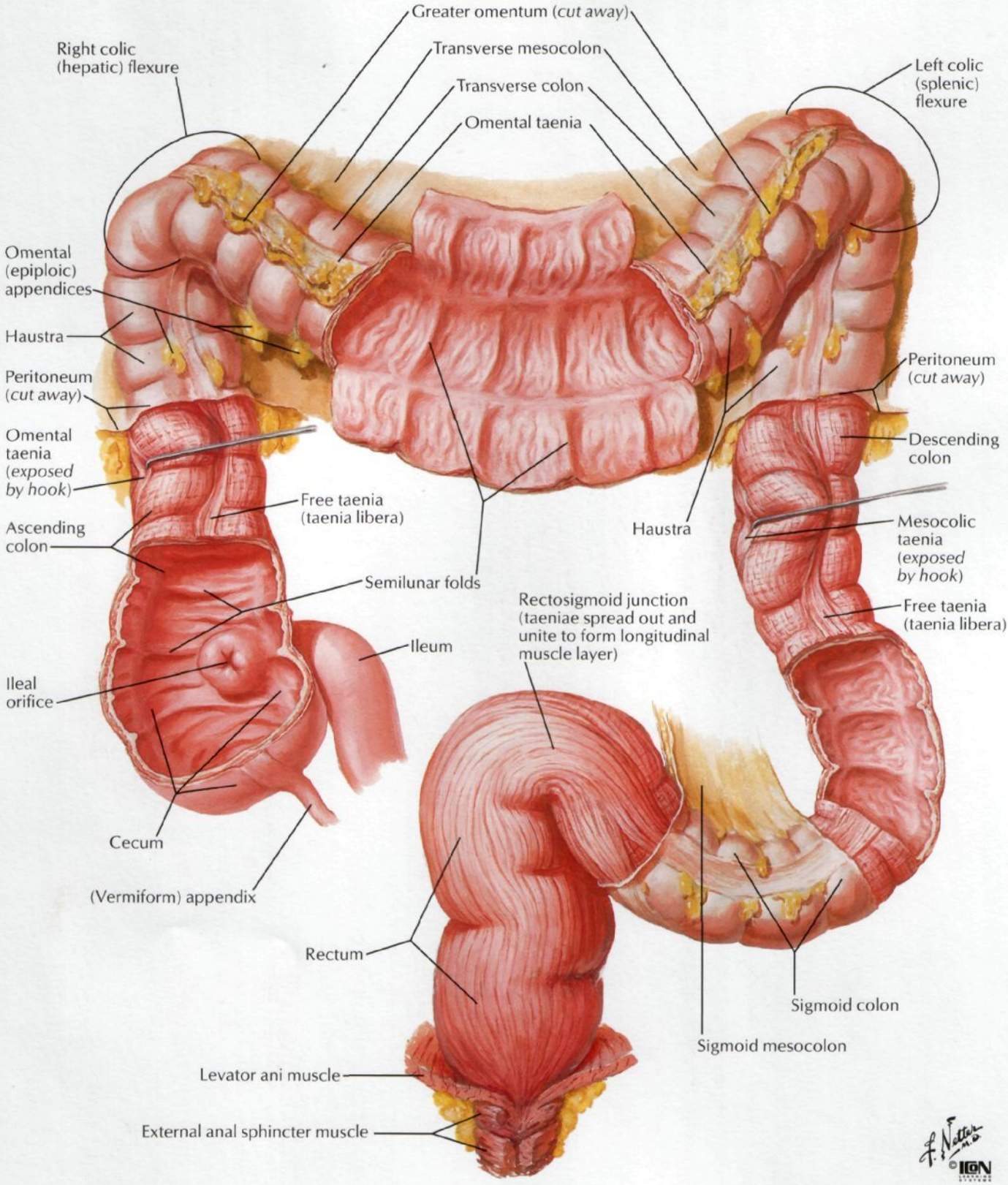

Sigmoid Colon: Variations in Position

FOR RECTUM SEE PLATES 347, 348, 372–375

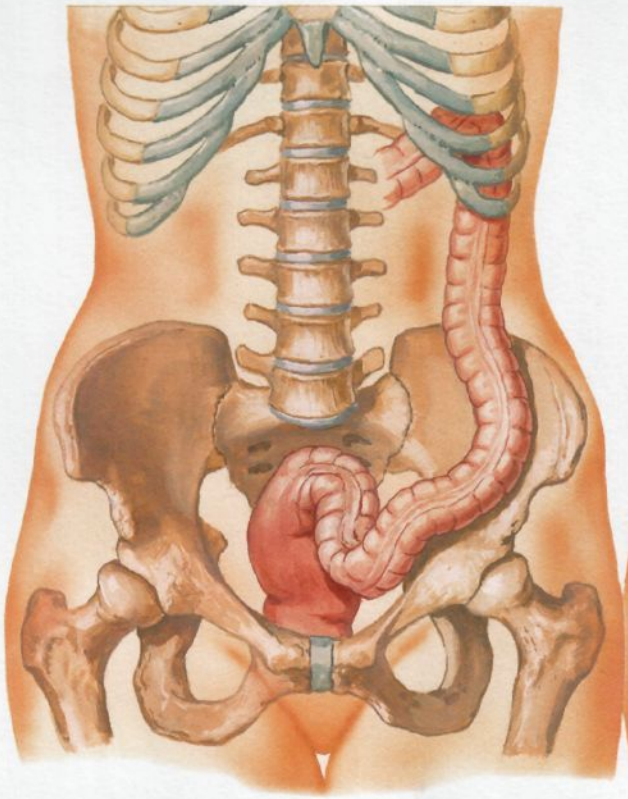

Typical

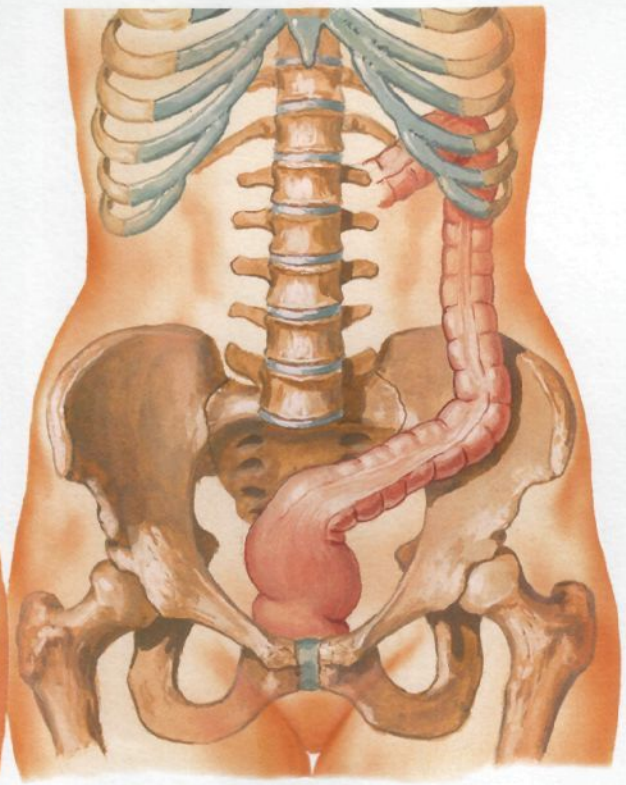

Short, straight, obliquely into pelvis

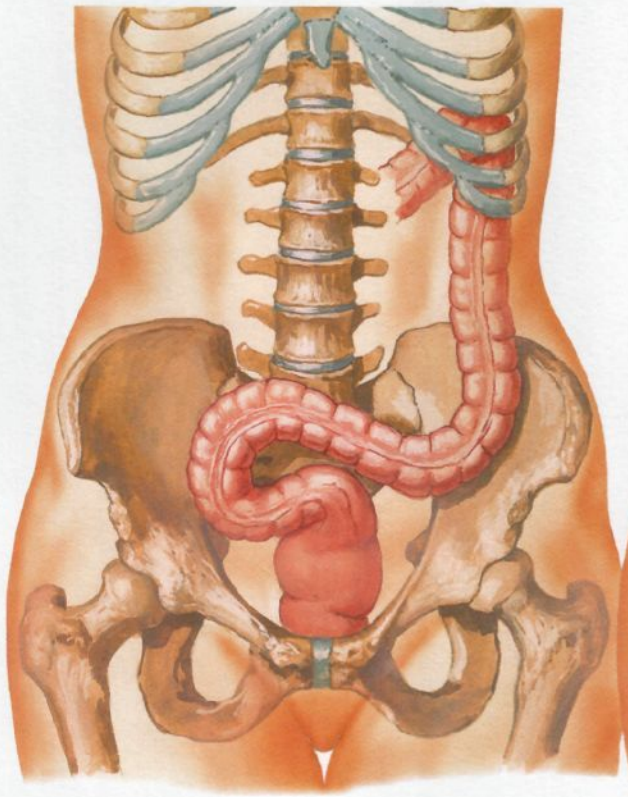

Looping to right side

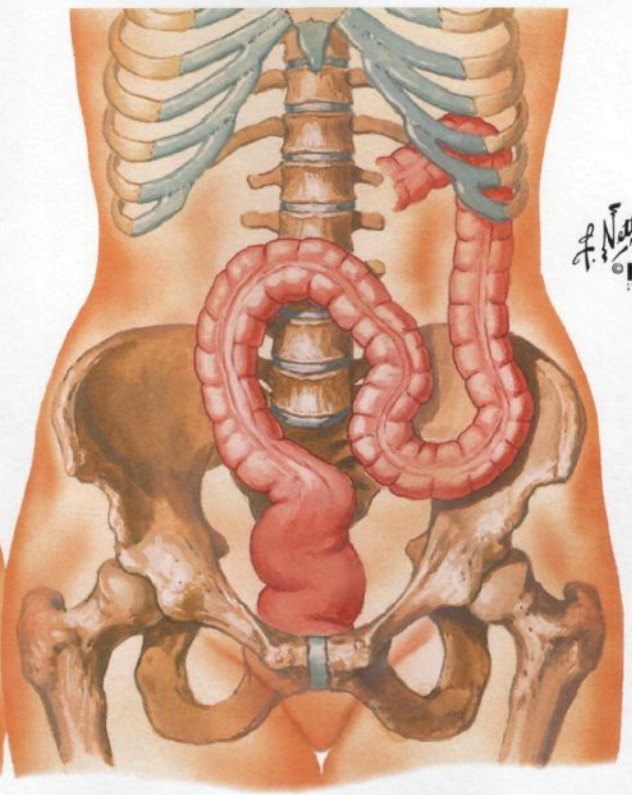

Ascending high into abdomen

Topography of Liver

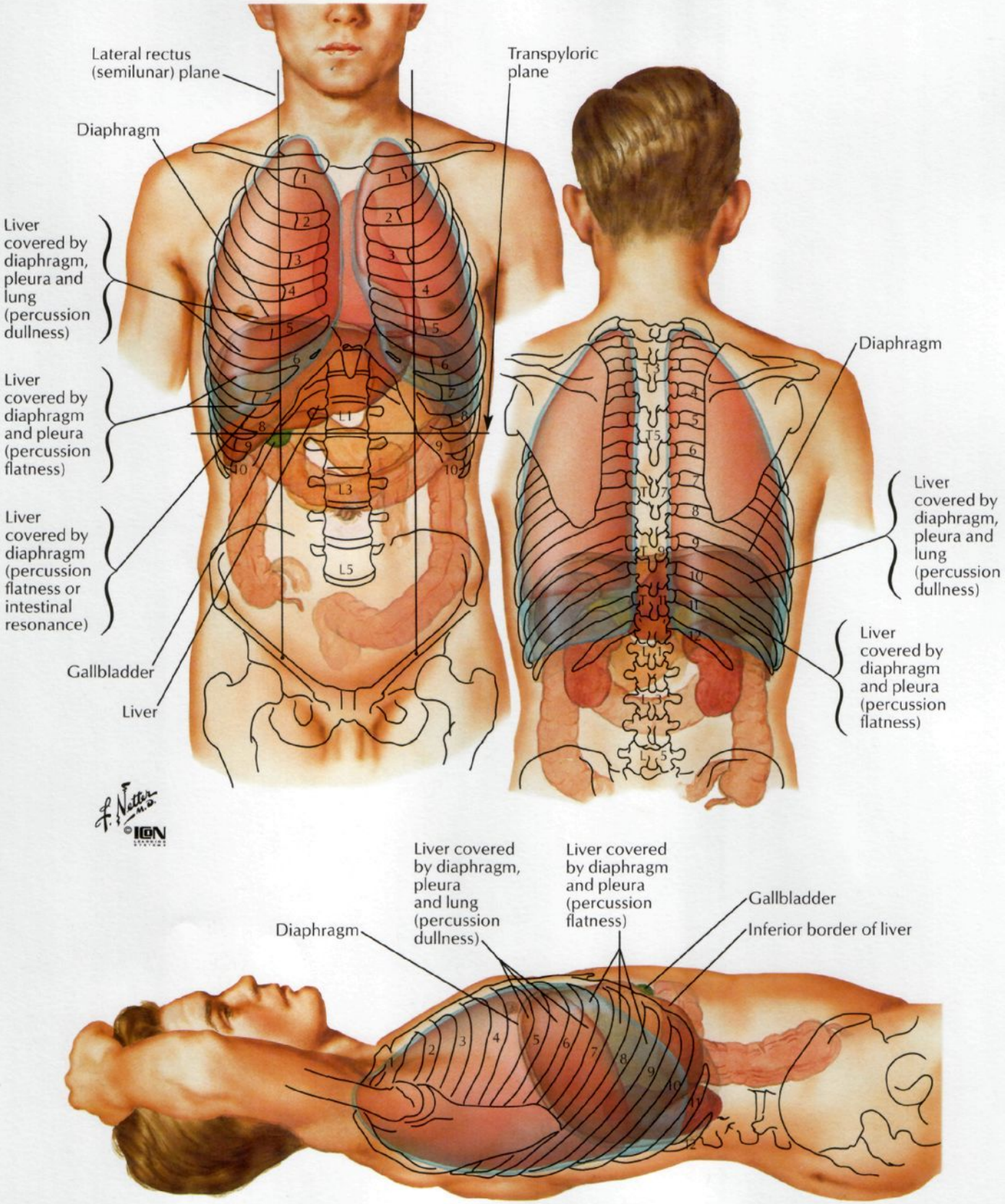

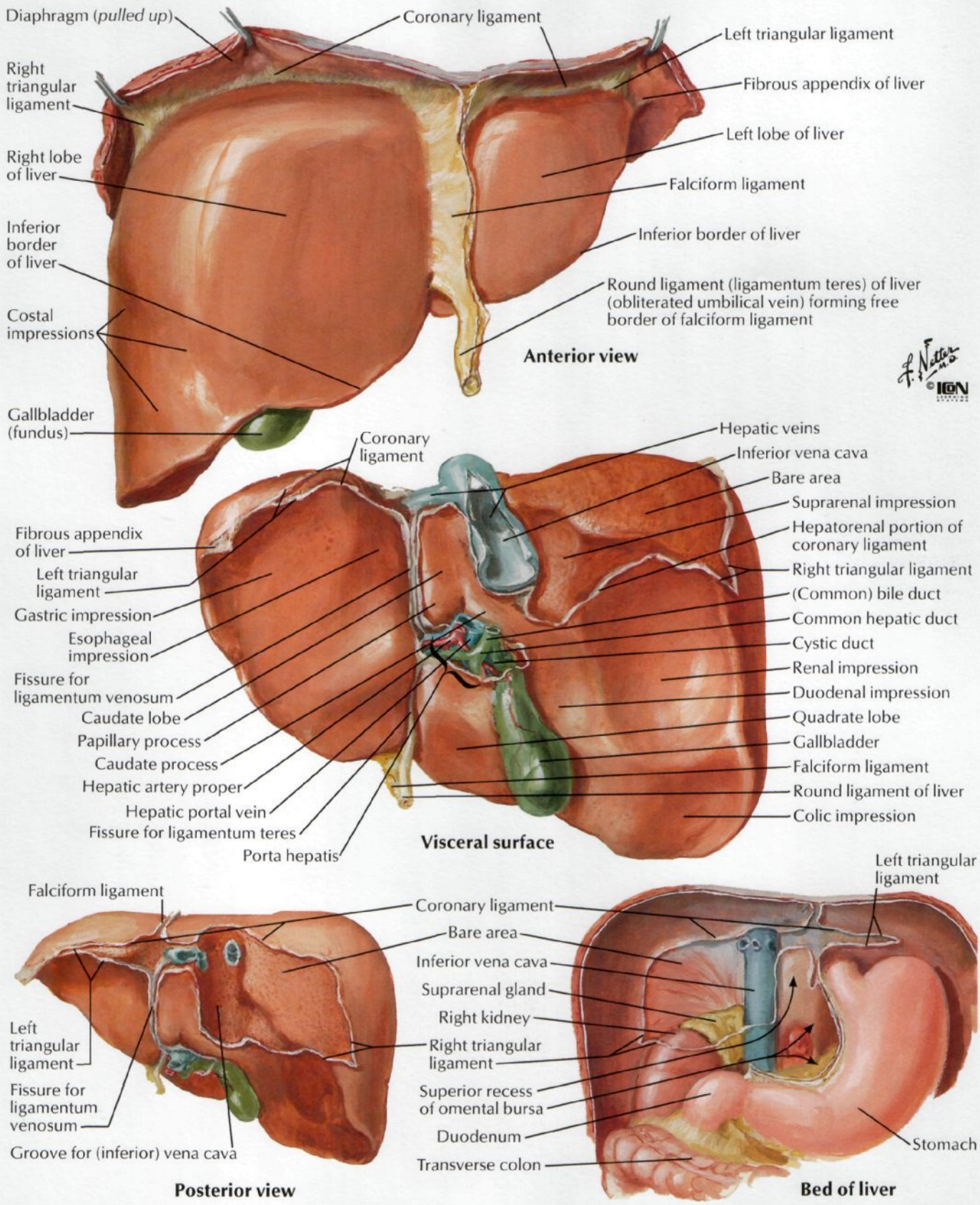
Diaphragm (pulled up)
Coronary ligament
Left triangular ligament
Right triangular ligament
Fibrous appendix of liver
Left lobe of liver
Right lobe of liver
Falciform ligament
Inferior border of liver
Inferior border of liver
Round ligament (ligamentum teres) of liver (obliterated umbilical vein) forming free border of falciform ligament
Costal impressions
Anterior view
Gallbladder (fundus)
Coronary ligament
Hepatic veins
Inferior vena cava
Bare area
Suprarenal impression
Hepatorenal portion of coronary ligament
Fibrous appendix of liver
Left triangular ligament
Right triangular ligament
(Common) bile duct
Gastric impression
Common hepatic duct
Esophageal impression
Cystic duct
Fissure for ligamentum venosum
Renal impression
Duodenal impression
Caudate lobe
Quadrate lobe
Papillary process
Gallbladder
Caudate process
Falciform ligament
Hepatic artery proper
Round ligament of liver
Hepatic portal vein
Colic impression
Fissure for ligamentum teres
Porta hepatis
Visceral surface
Falciform ligament
Coronary ligament
Left triangular ligament
Bare area
Inferior vena cava
Suprarenal gland
Right kidney
Left triangular ligament
Right triangular ligament
Fissure for ligamentum venosum
Superior recess of omental bursa
Duodenum
Stomach
Groove for (inferior) vena cava
Transverse colon
Posterior view
Bed of liver

Liver In Situ and Variations in Form

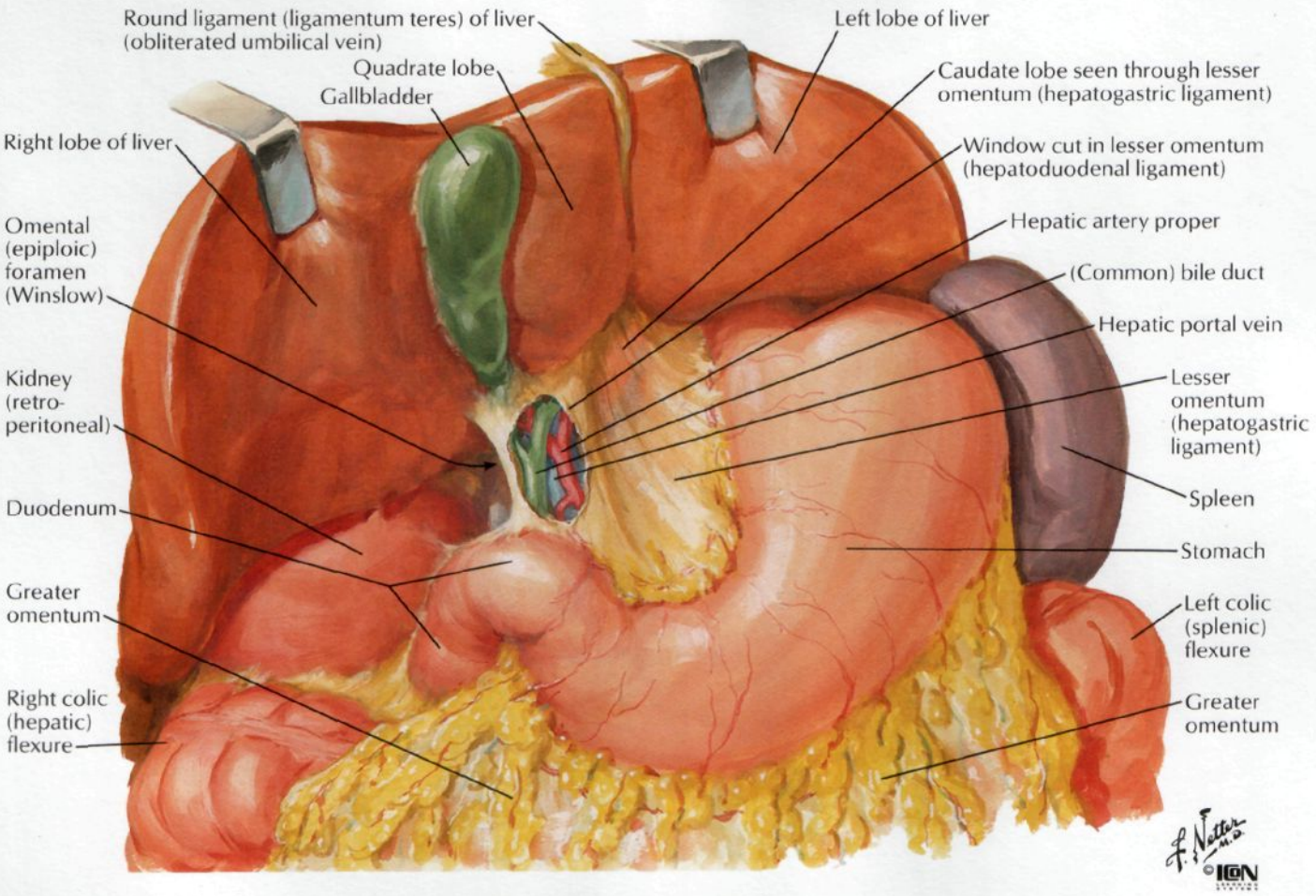

Variations in form of liver

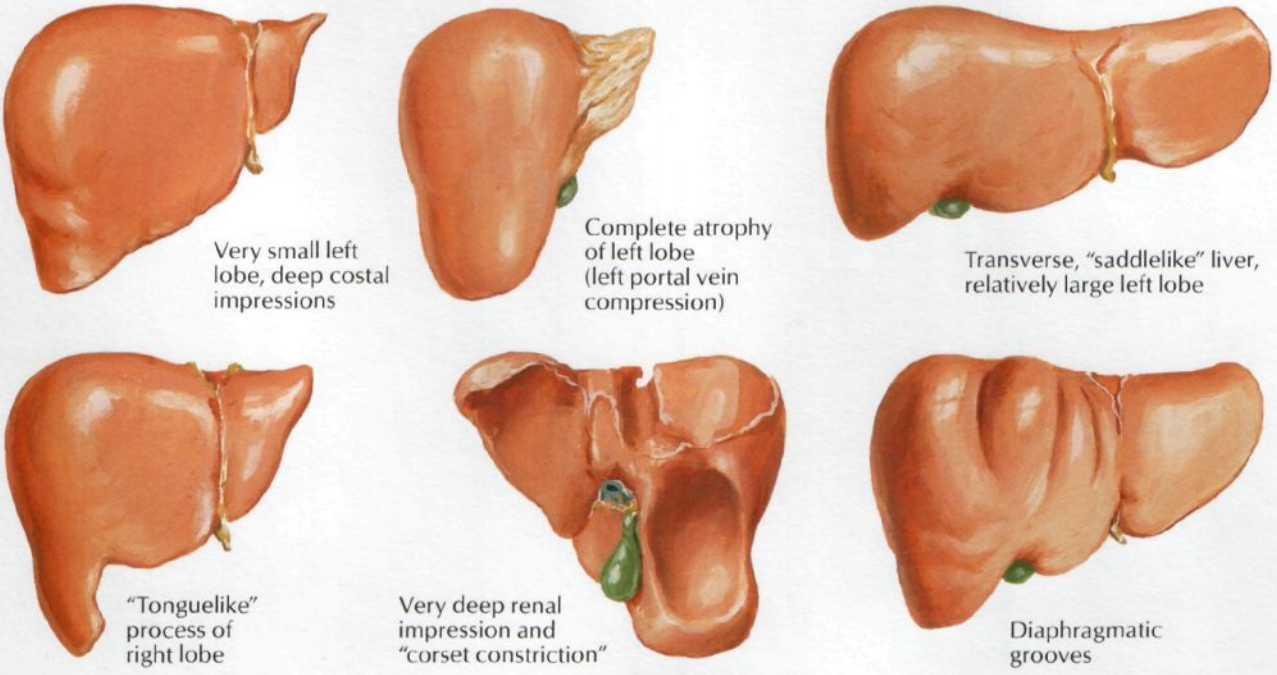

Liver Segments and Lobes: Vessel and Duct Distribution

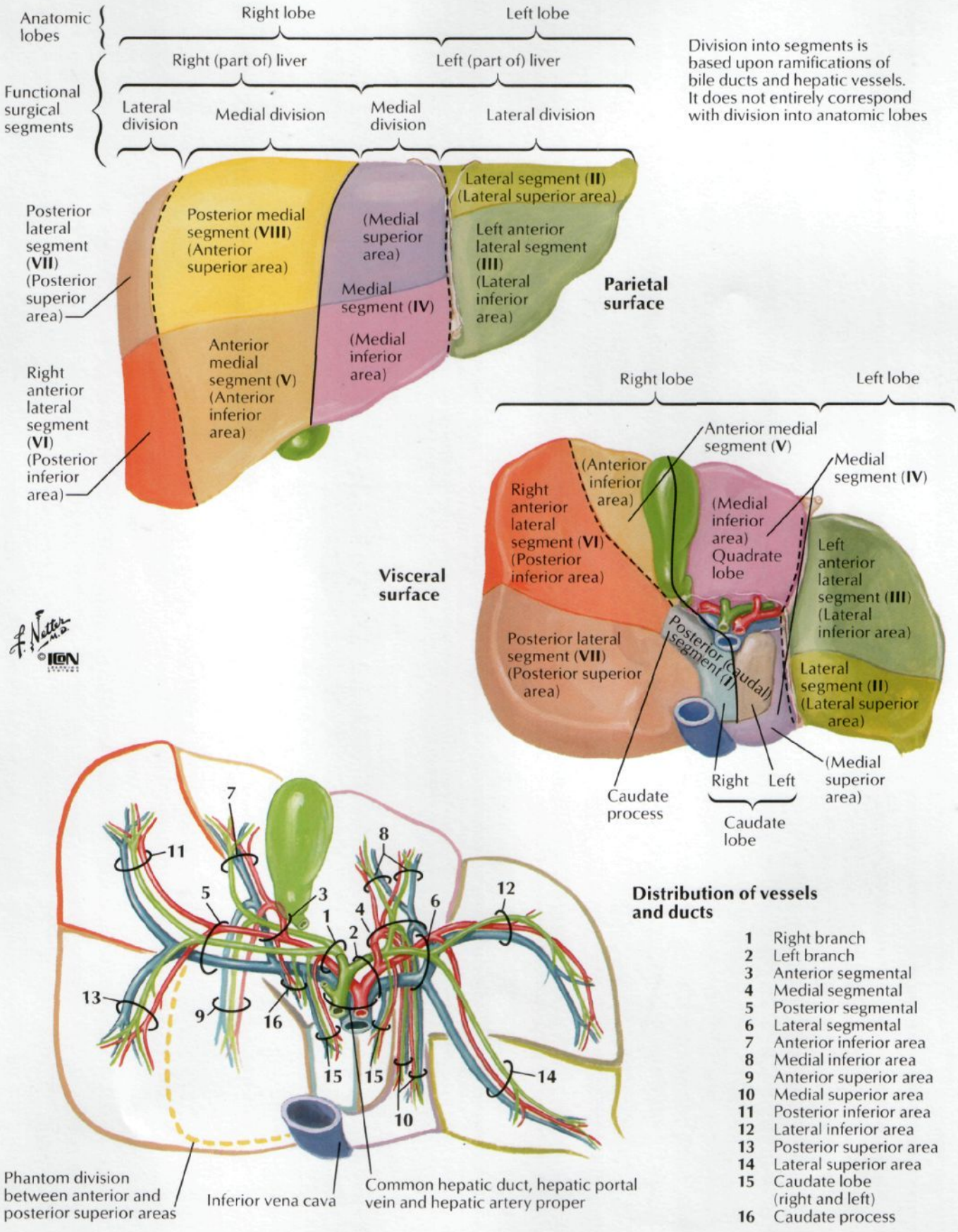

Distribution of vessels and ducts

1	Right branch
2	Left branch
3	Anterior segmental
4	Medial segmental
5	Posterior segmental
6	Lateral segmental
7	Anterior inferior area
8	Medial inferior area
9	Anterior superior area
10	Medial superior area
11	Posterior inferior area
12	Lateral inferior area
13	Posterior superior area
14	Lateral superior area
15	Caudate lobe (right and left)
16	Caudate process

Intrahepatic Vascular and Duct Systems

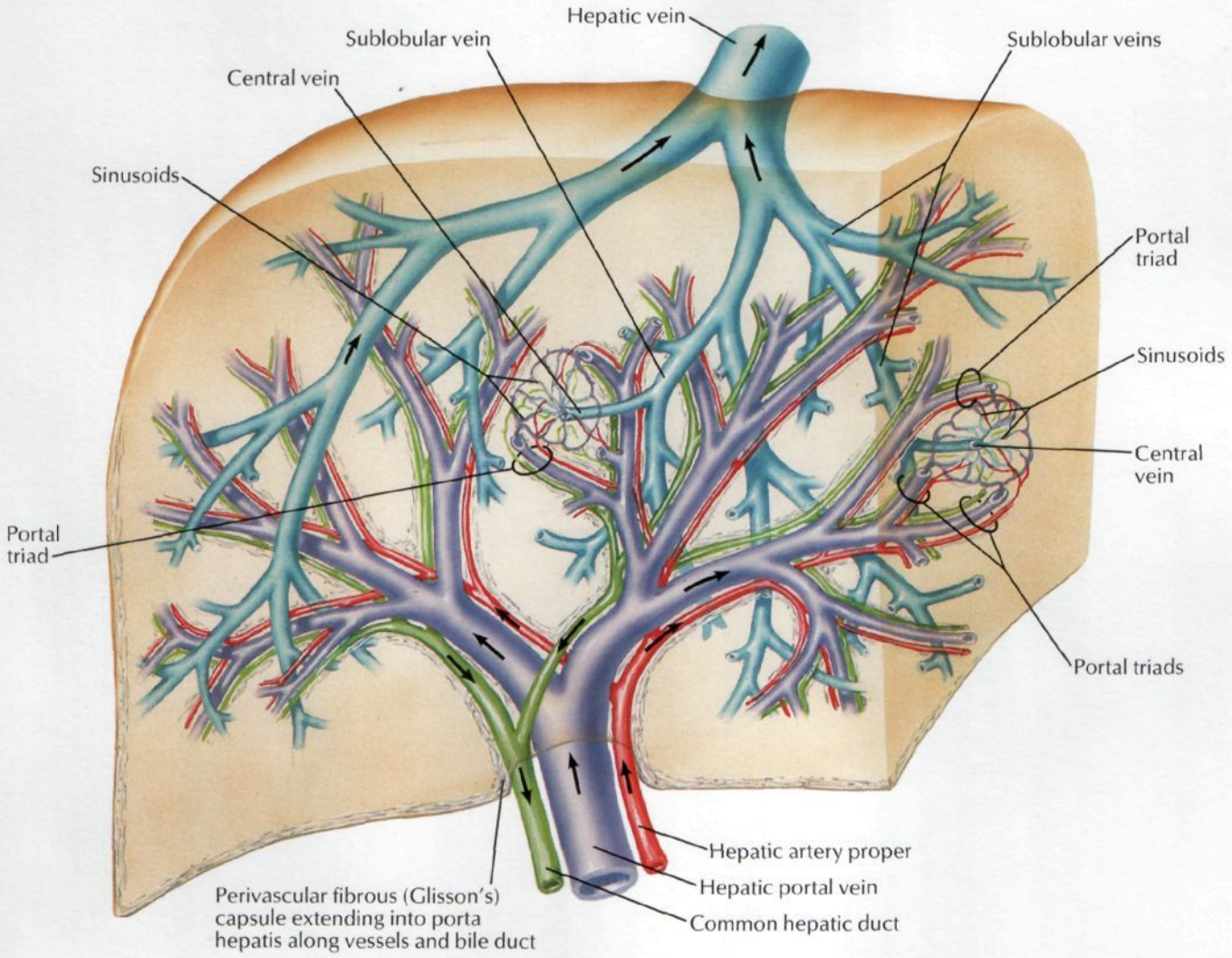

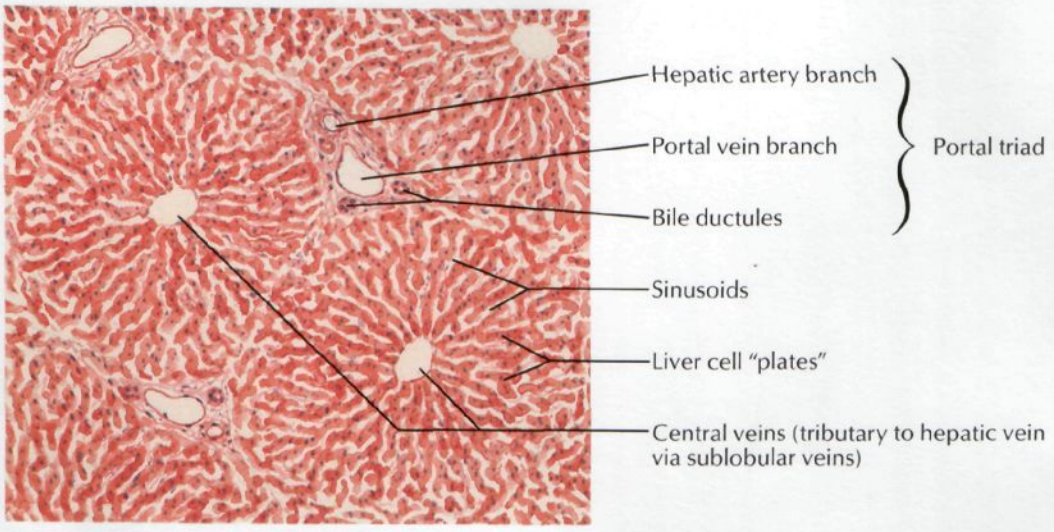

Normal lobular pattern of liver

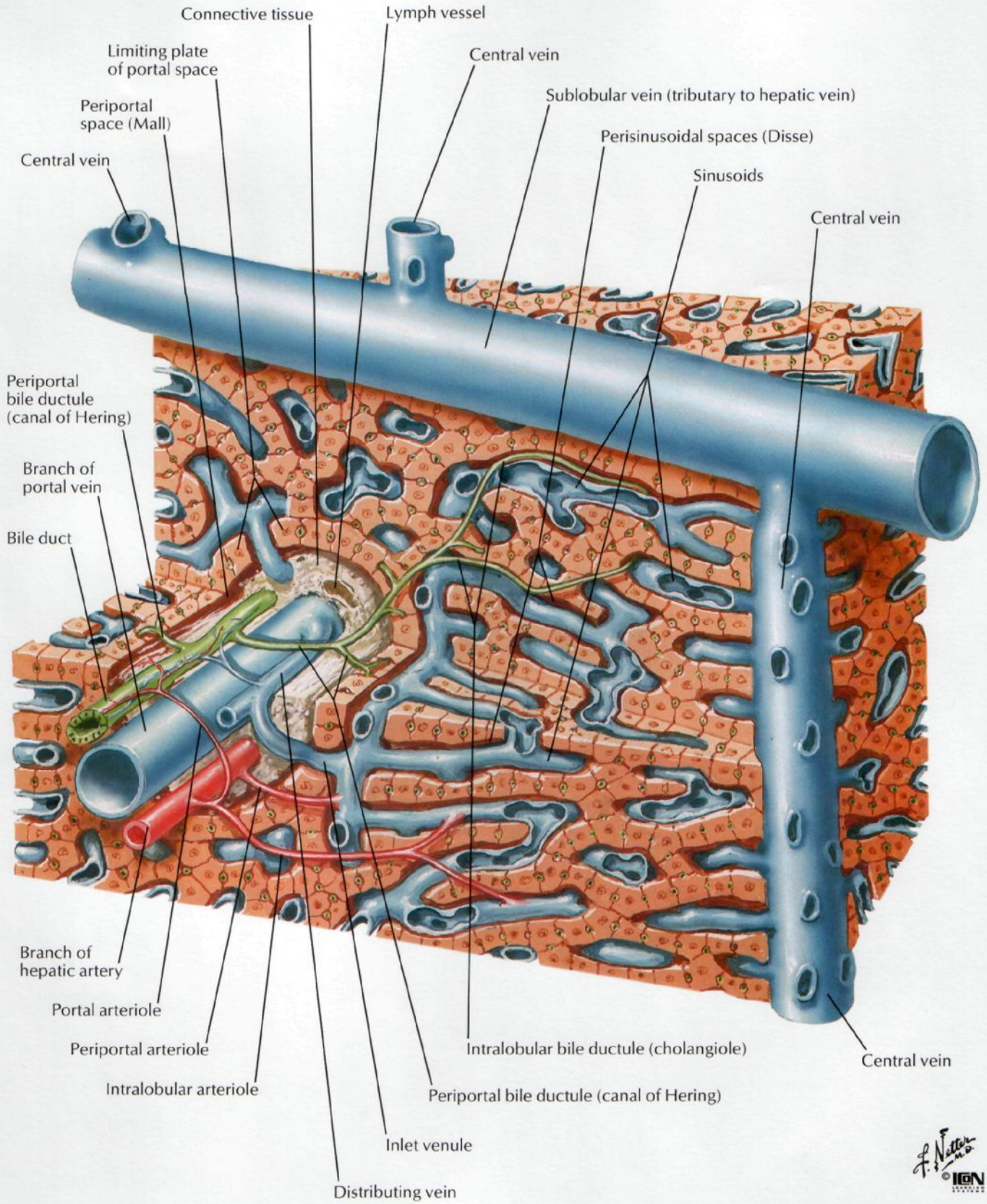
Connective tissue
Lymph vessel
Limiting plate of portal space
Central vein
Sublobular vein (tributary to hepatic vein)
Periportal space (Mall)
Perisinusoidal spaces (Disse)
Central vein
Sinusoids
Central vein
Periportal bile ductule (canal of Hering)
Branch of portal vein
Bile duct
Branch of hepatic artery
Portal arteriole
Periportal arteriole
Intralobular arteriole
Intralobular bile ductule (cholangiole)
Central vein
Periportal bile ductule (canal of Hering)
Inlet venule
Distributing vein

Intrahepatic Biliary System: Schema

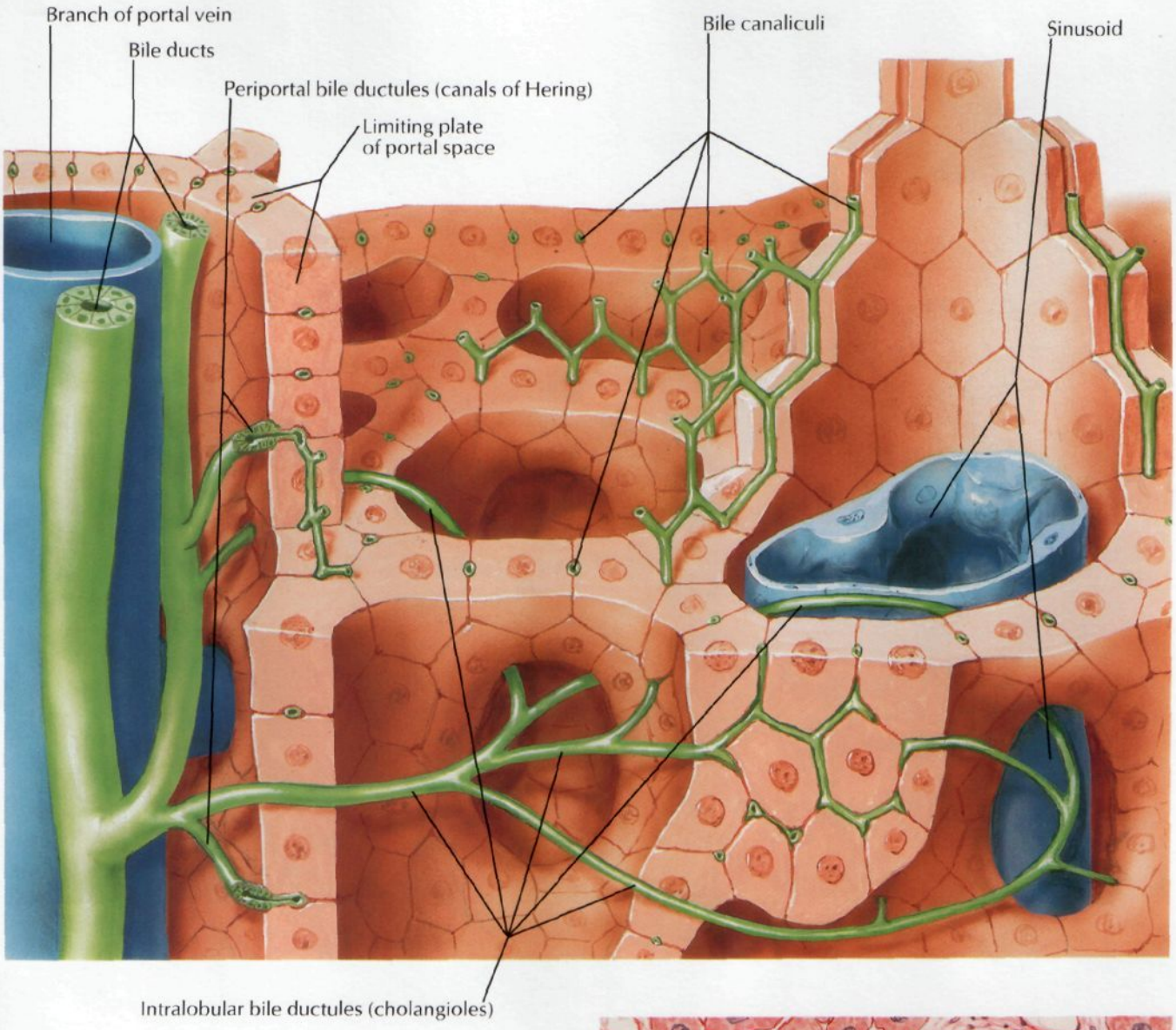

Note: In above illustration, bile canaliculi appear as structures with walls of their own. However, as shown in histologic section at right, boundaries of canaliculi are actually a specialization of surface membranes of adjoining liver parenchymal cells

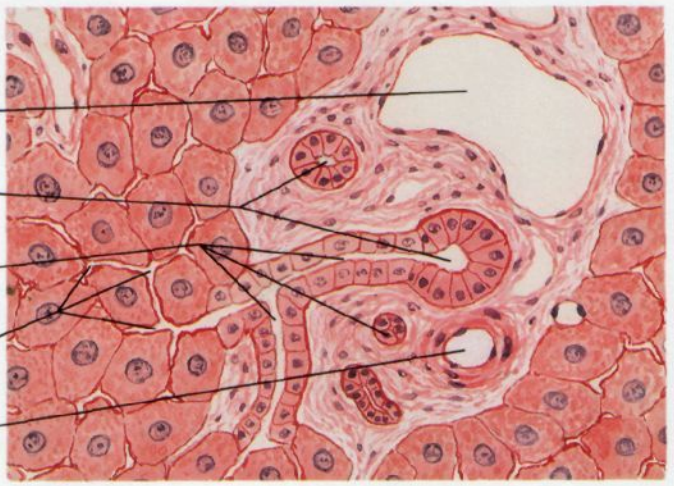

Low-power section of liver

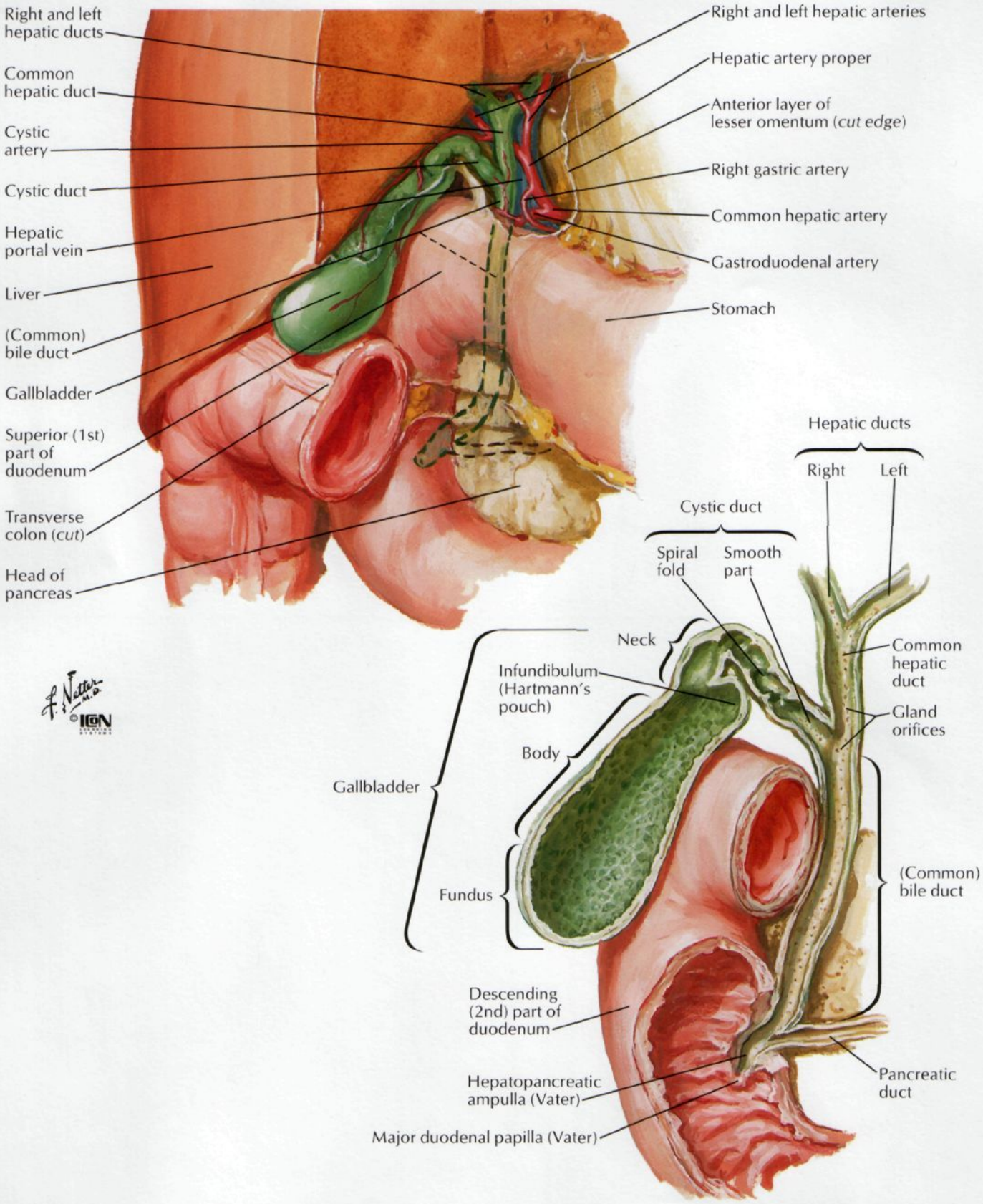
Right and left hepatic ducts
Common hepatic duct
Cystic artery
Cystic duct
Hepatic portal vein
Liver
(Common) bile duct
Gallbladder
Superior (1st) part of duodenum
Transverse colon (cut)
Head of pancreas
Right and left hepatic arteries
Hepatic artery proper
Anterior layer of lesser omentum (cut edge)
Right gastric artery
Common hepatic artery
Gastroduodenal artery
Stomach
Hepatic ducts
Right
Left
Cystic duct
Spiral fold
Smooth part
Neck
Infundibulum (Hartmann's pouch)
Body
Fundus
Gallbladder
Common hepatic duct
Gland orifices
(Common) bile duct
Descending (2nd) part of duodenum
Hepatopancreatic ampulla (Vater)
Major duodenal papilla (Vater)
Pancreatic duct

Variations in Cystic and Hepatic Ducts

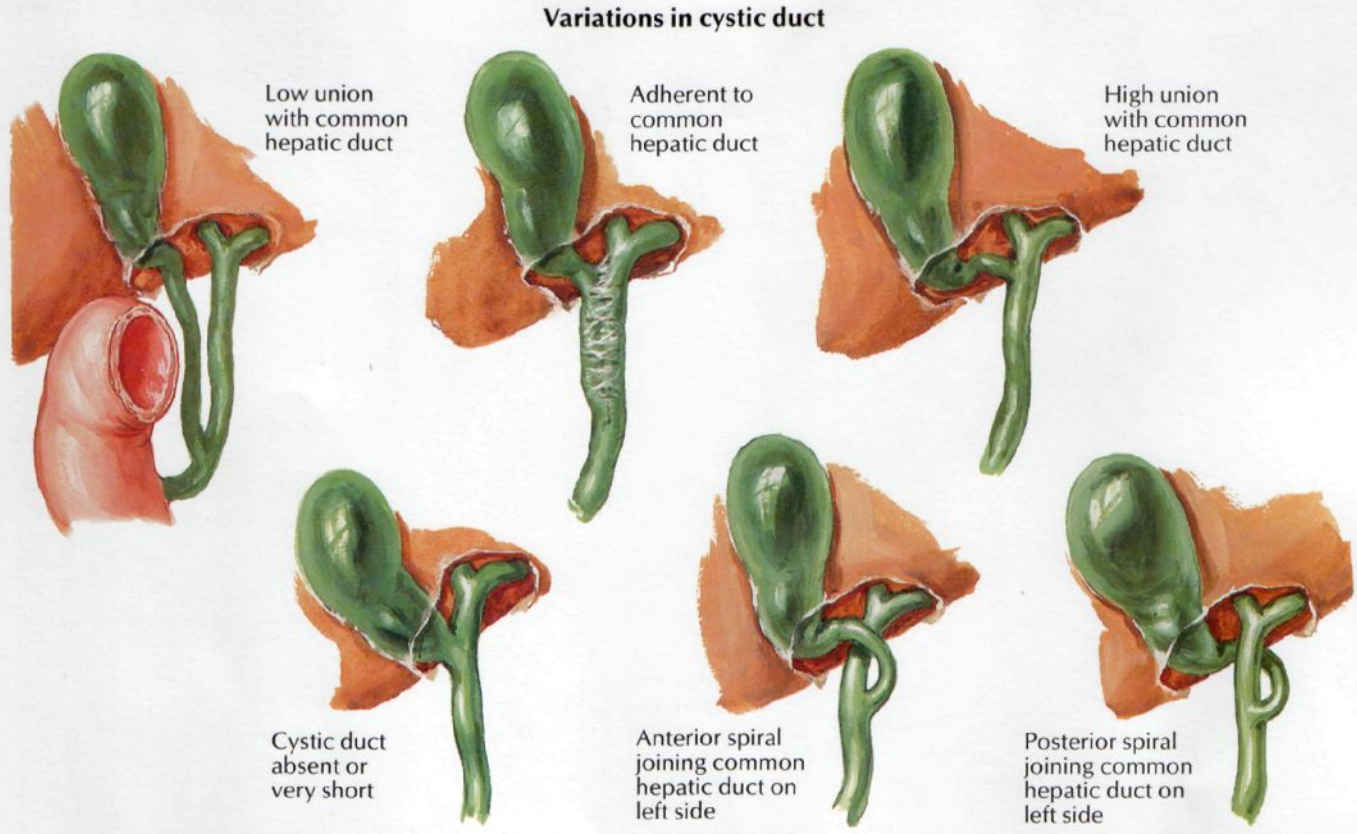

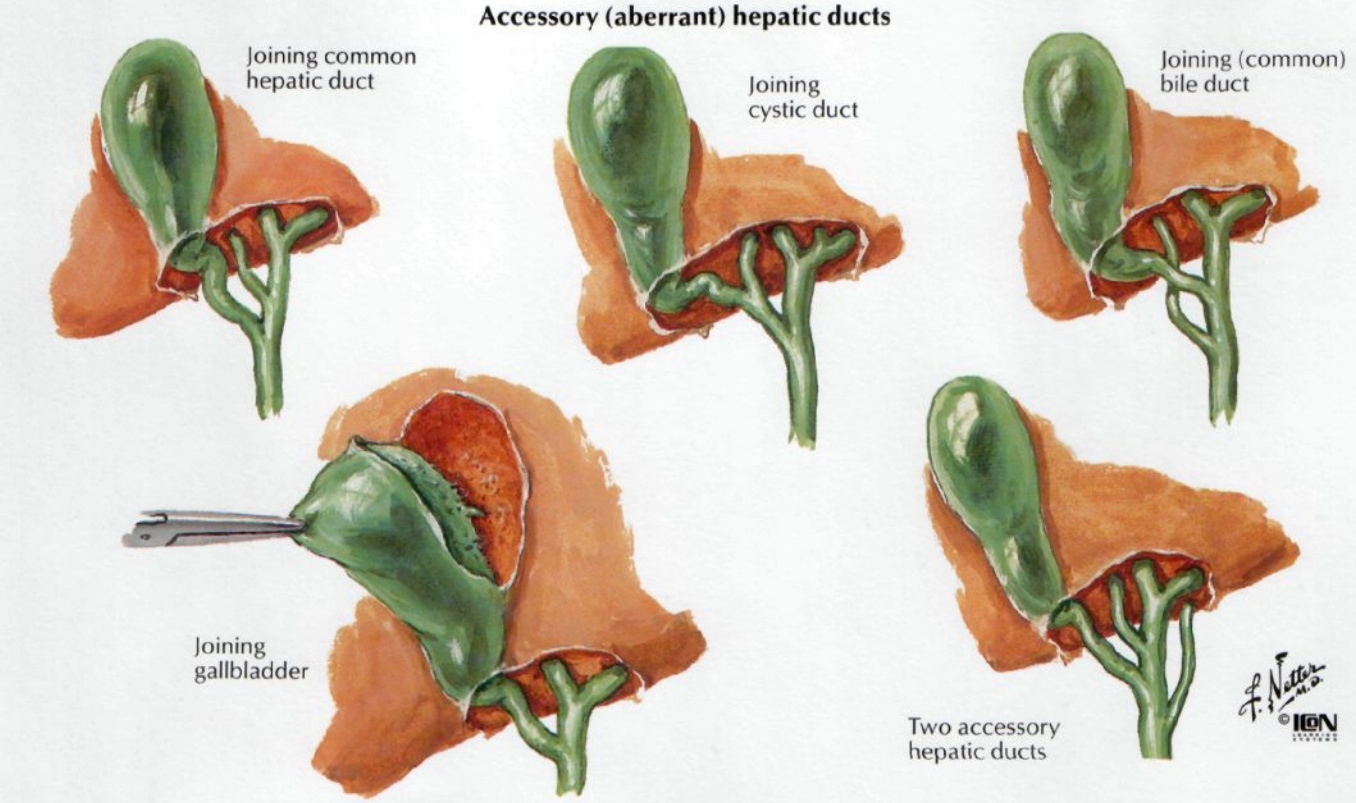

Junction of (Common) Bile Duct and Duodenum

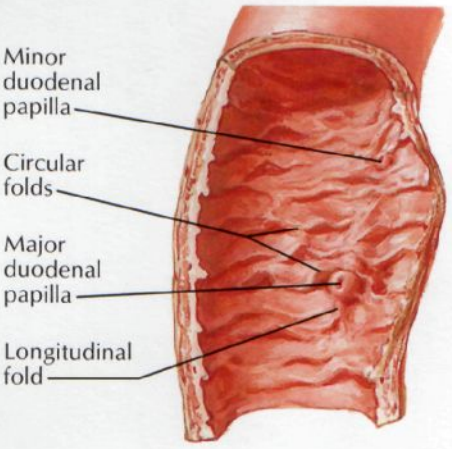

Interior of descending (2nd) part of duodenum

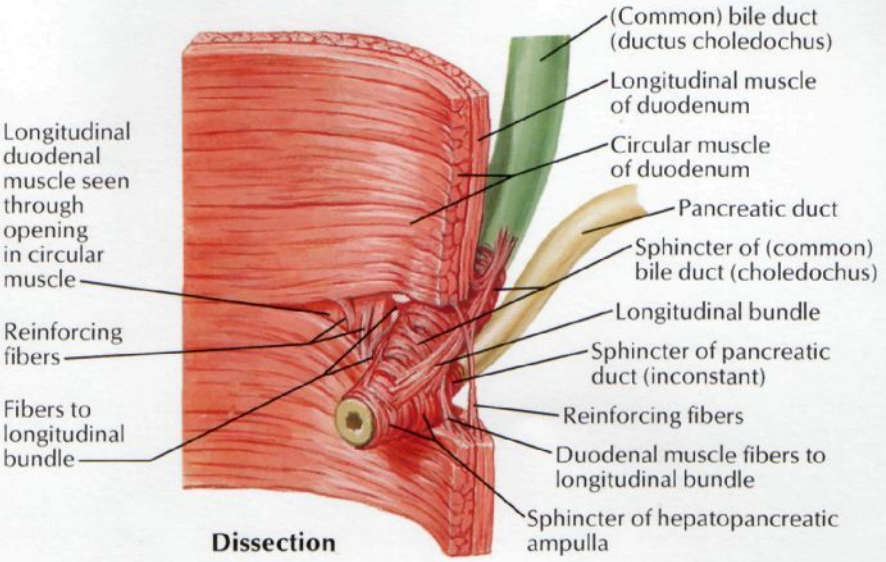

Dissection

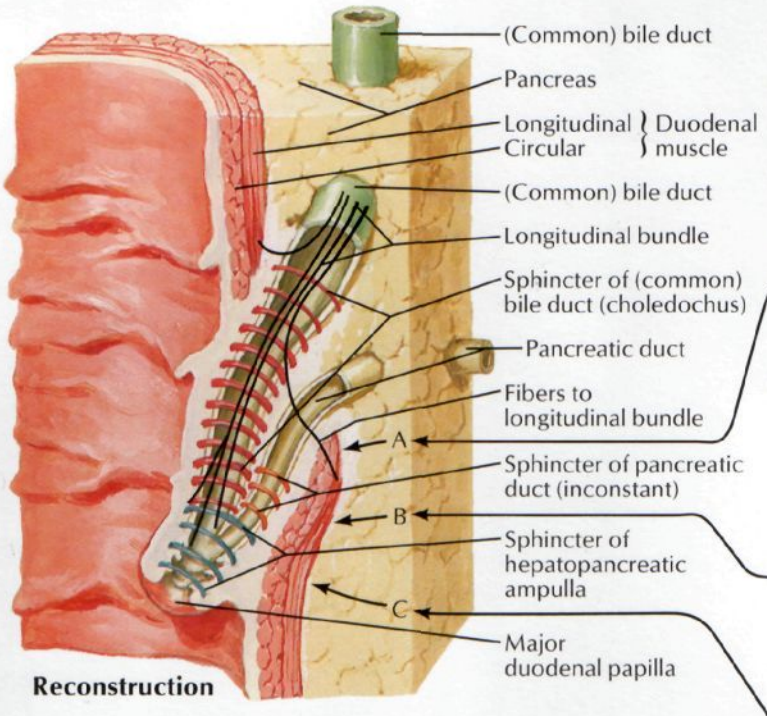

Reconstruction

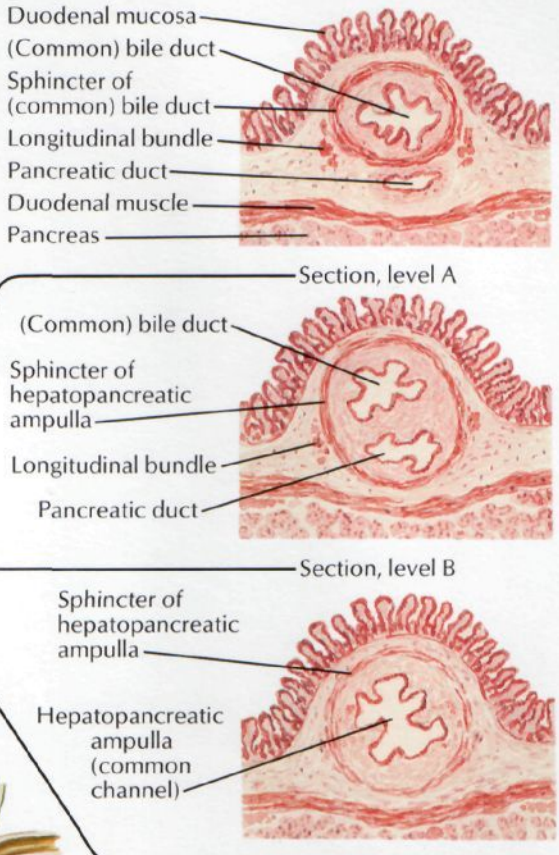

Variations in union of bile and pancreatic ducts

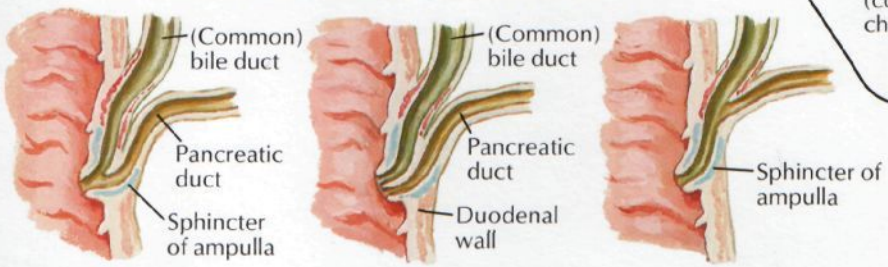

F. Netter M.D.
©IGN

Pancreas In Situ

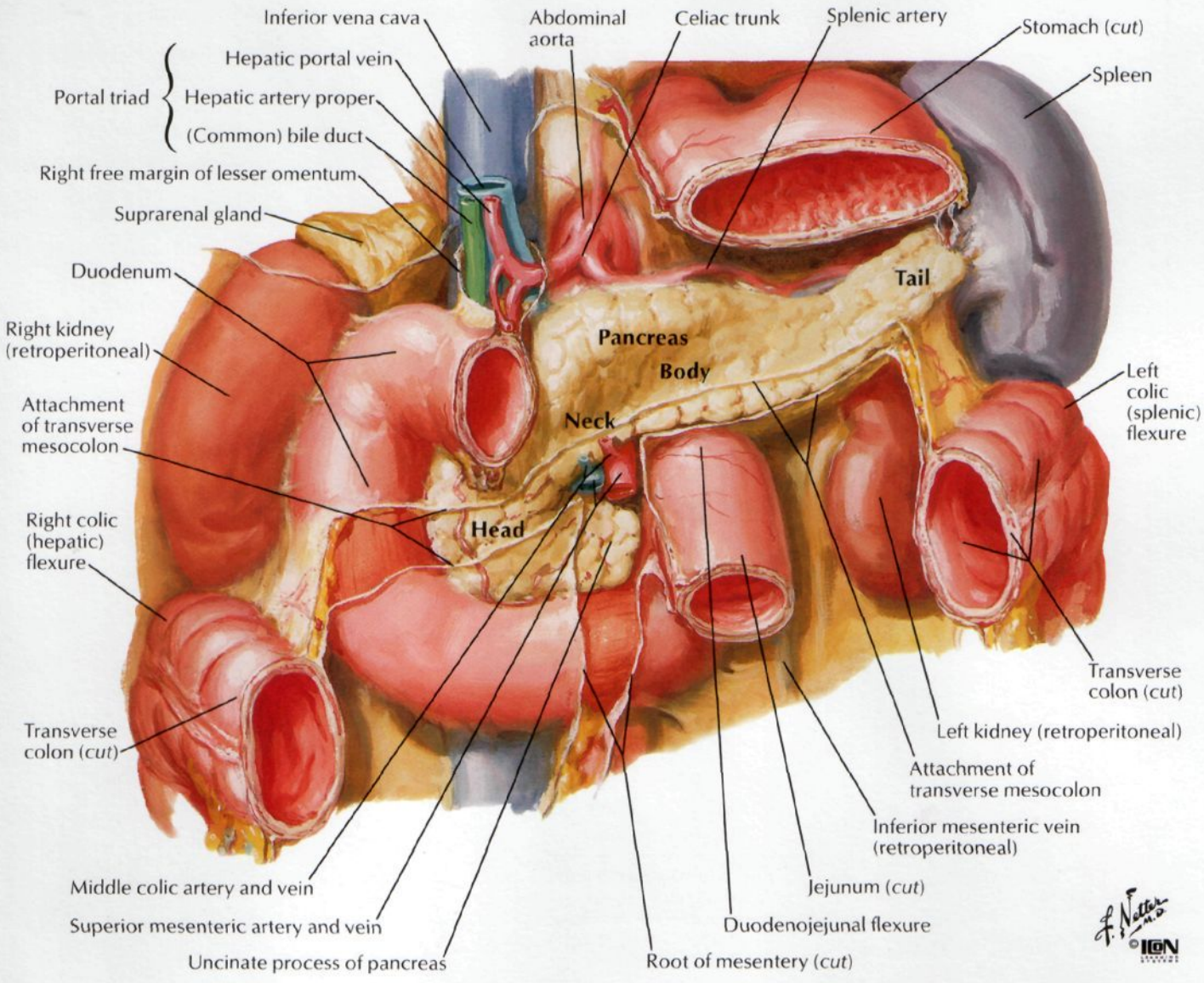

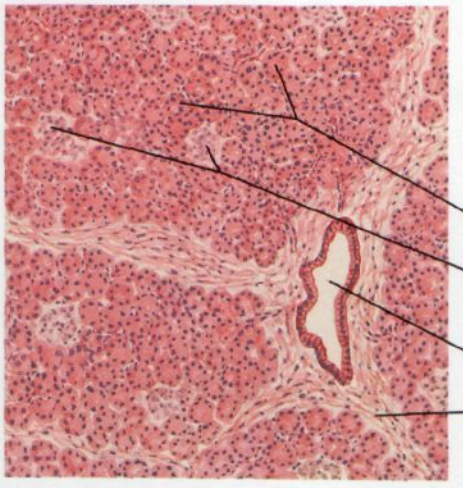

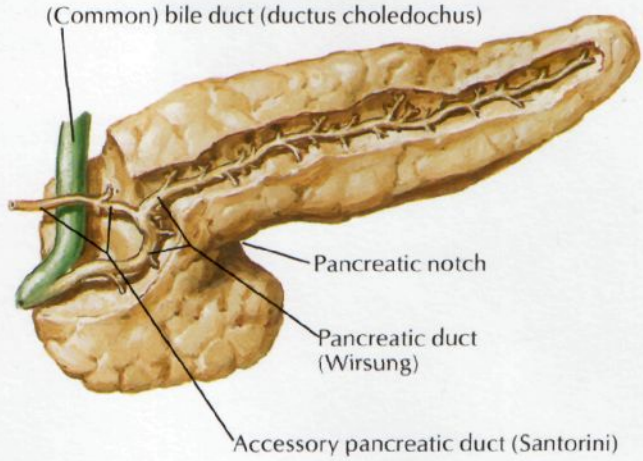

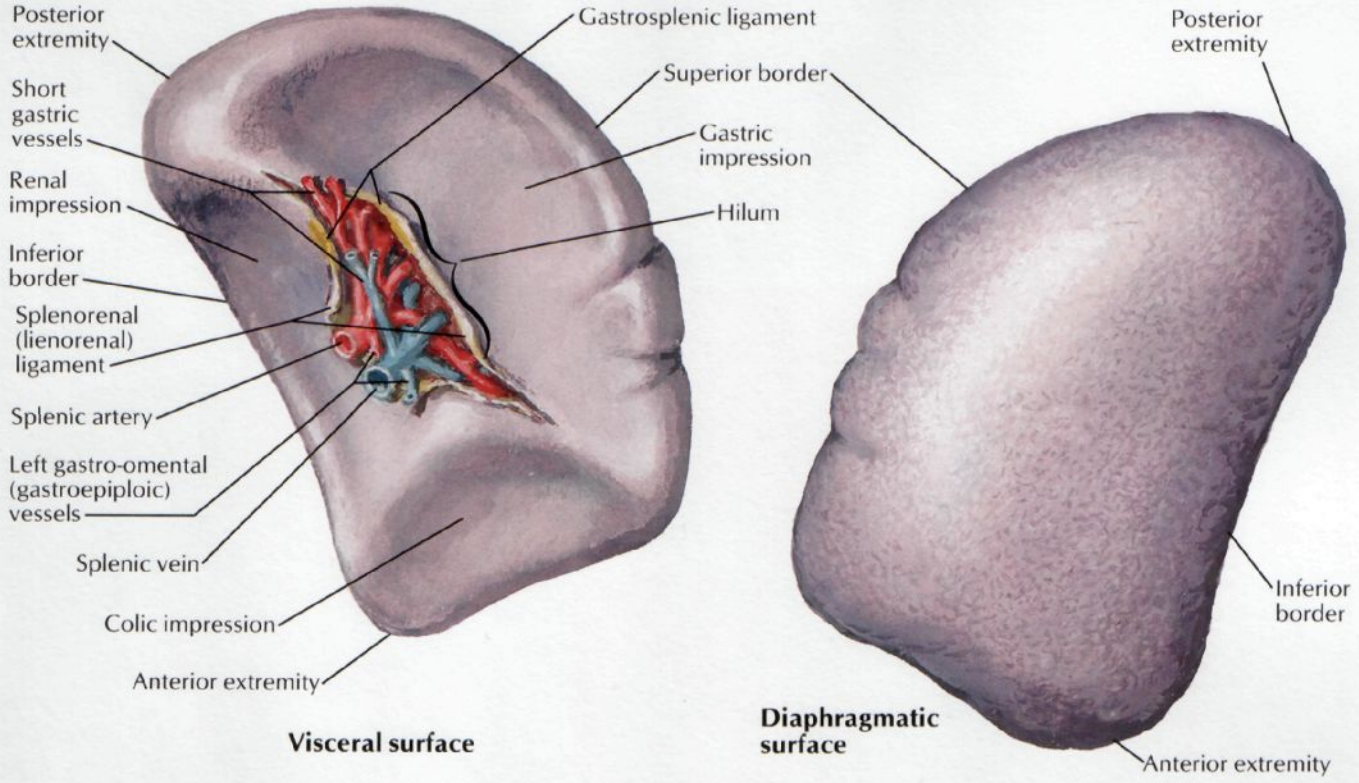

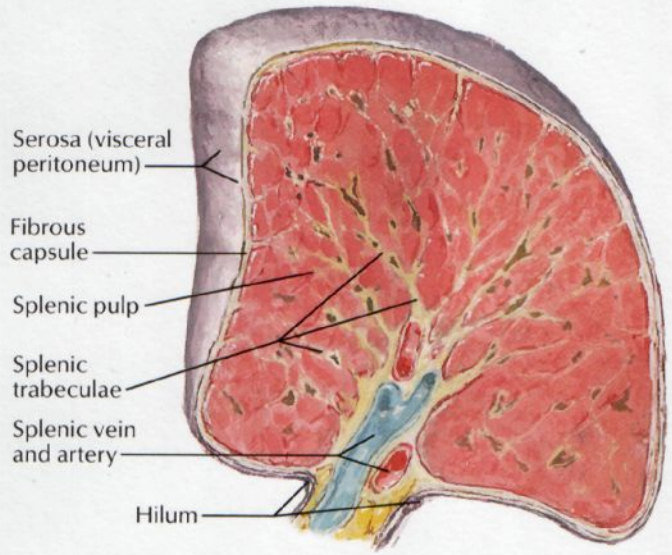

Cross section

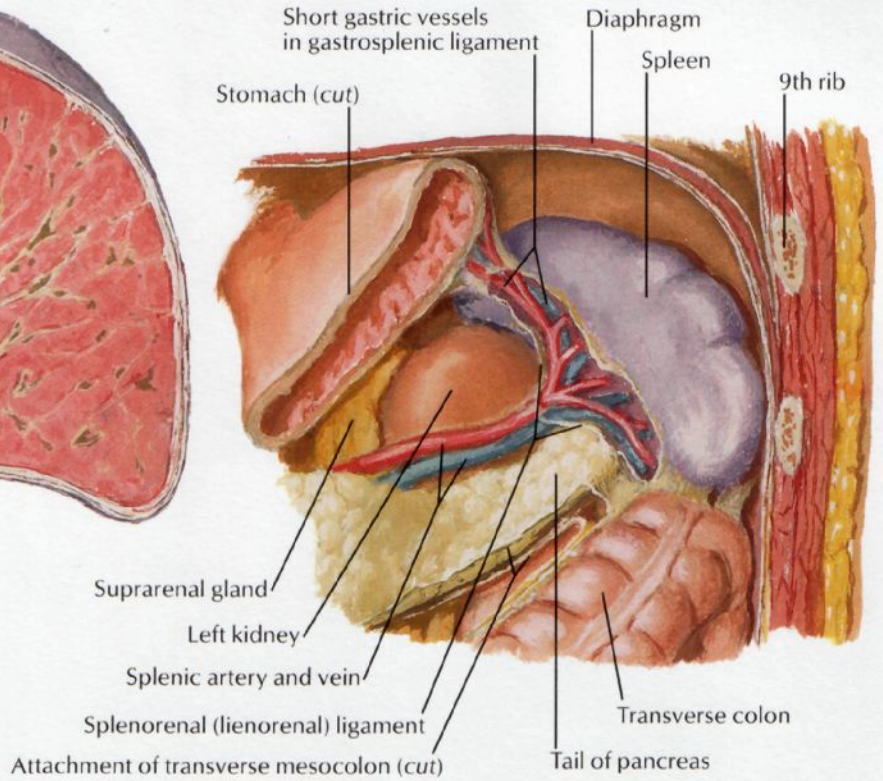

Spleen in situ

Arteries of Stomach, Liver and Spleen

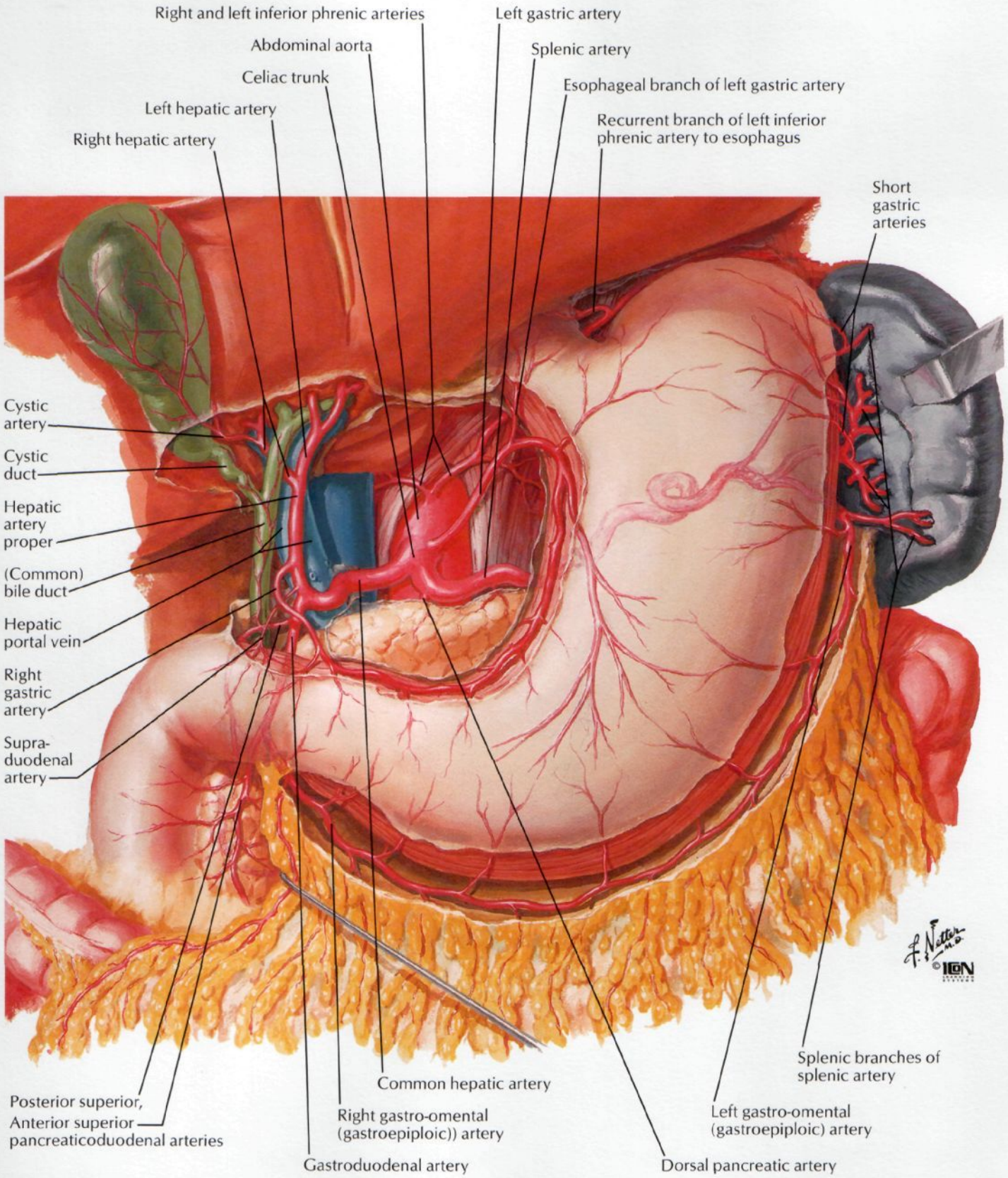

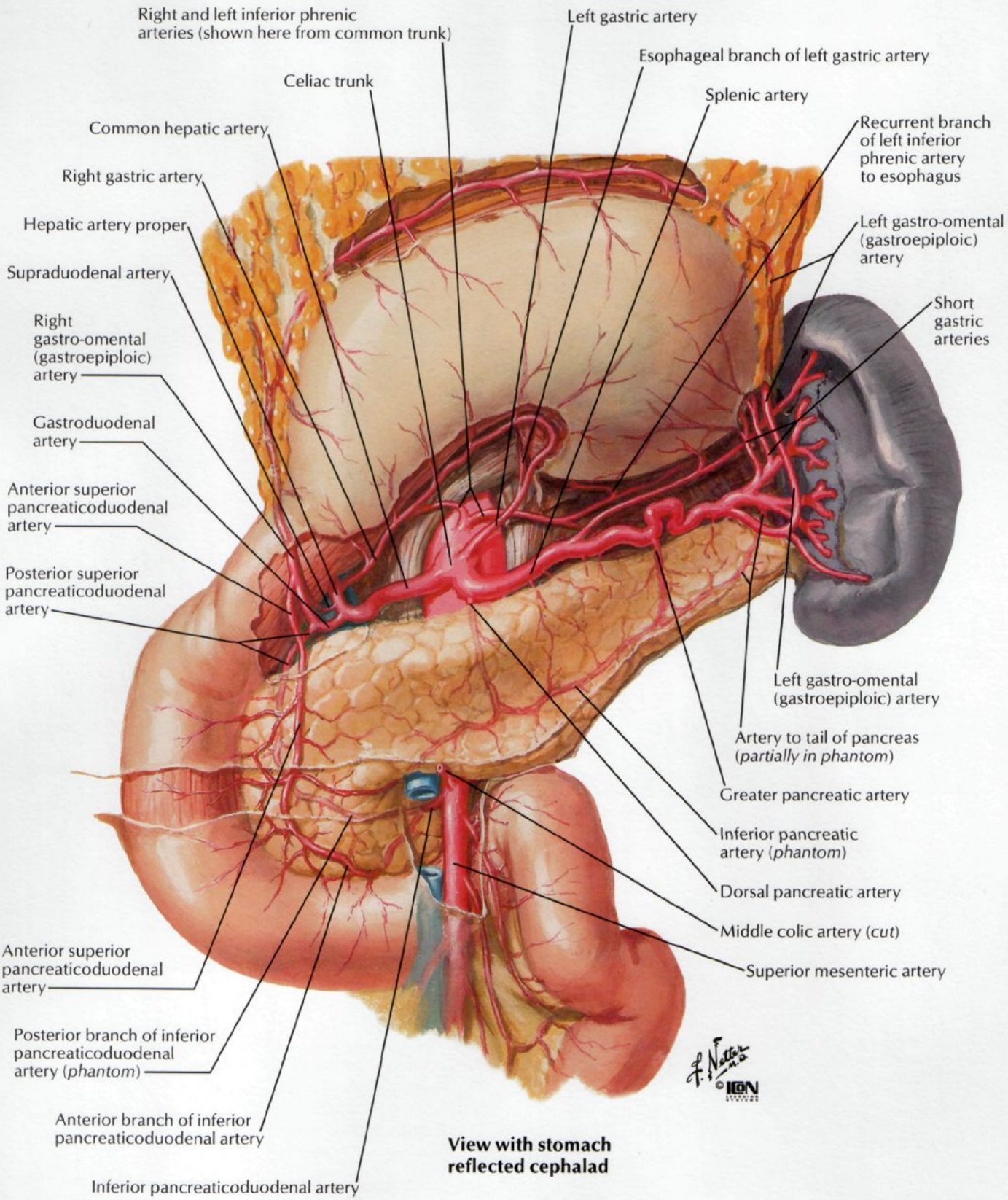

View with stomach reflected cephalad

Arteries of Liver, Pancreas, Duodenum and Spleen

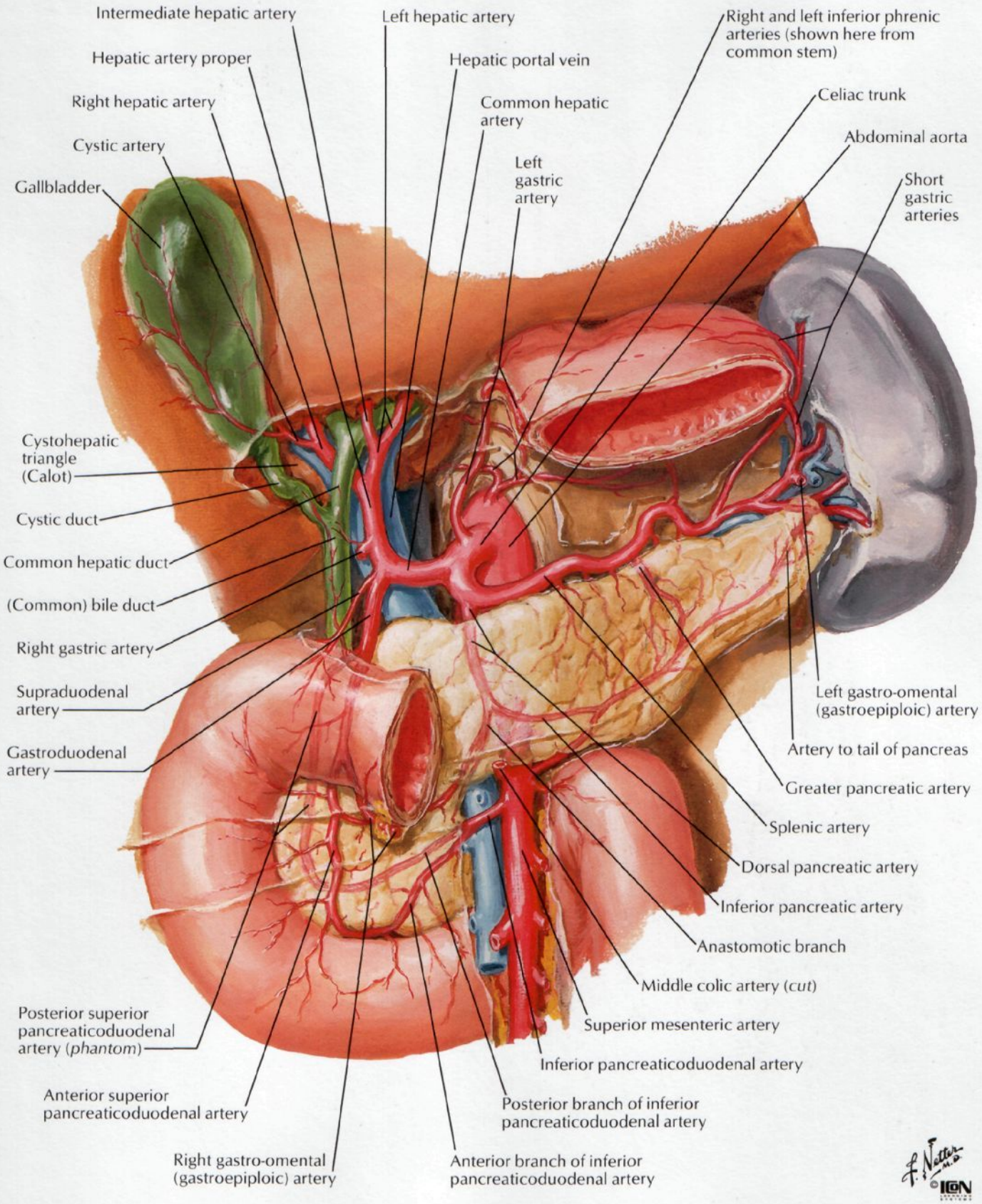

Celiac Arteriogram

SEE ALSO PLATE 290–292

CH Common hepatic artery
CT Celiac trunk
G Left gastric artery
GD Gastroduodenal artery
H Hepatic artery proper
RG Right gastric artery
S Splenic artery

Arteries of Duodenum and Head of Pancreas

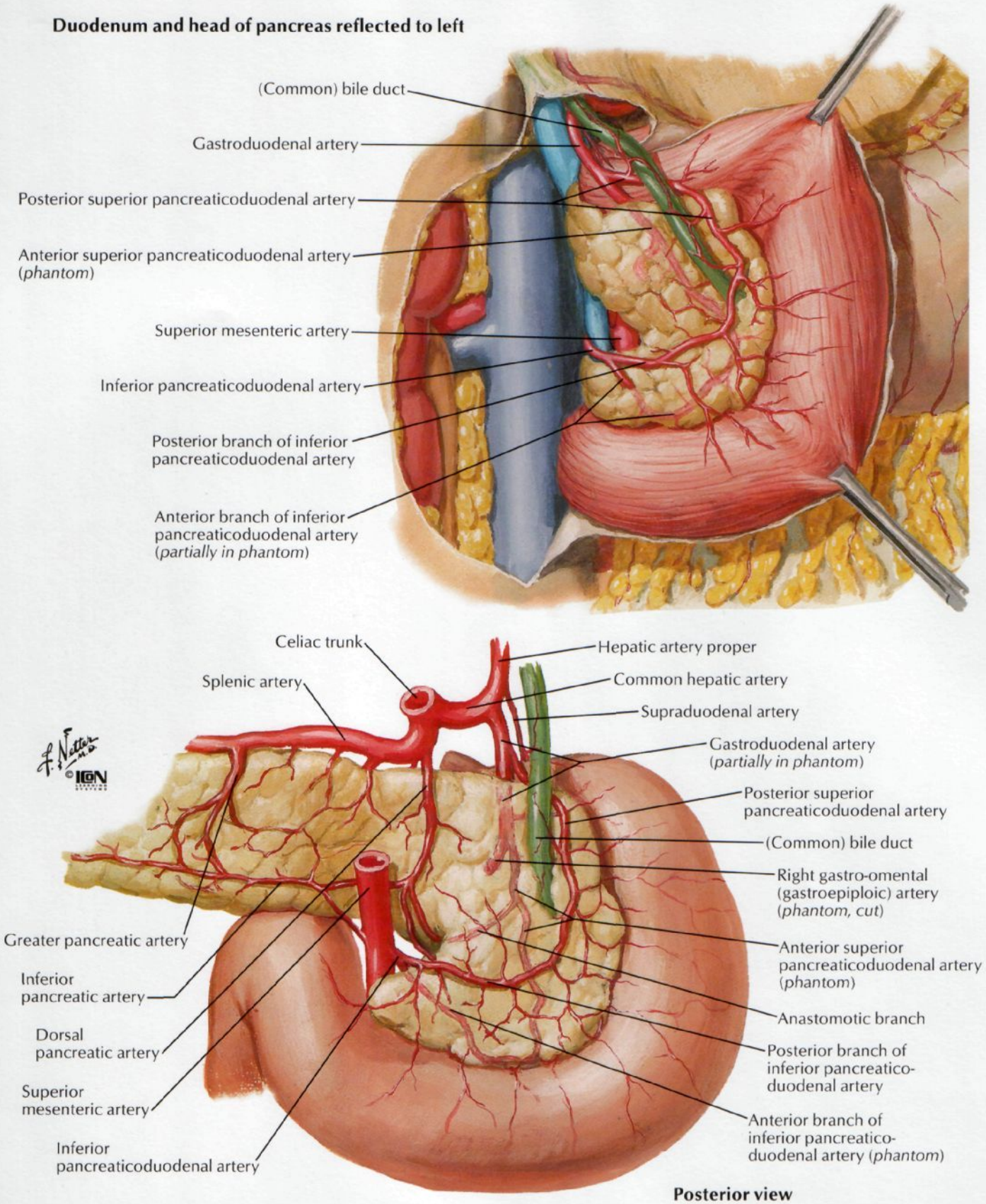

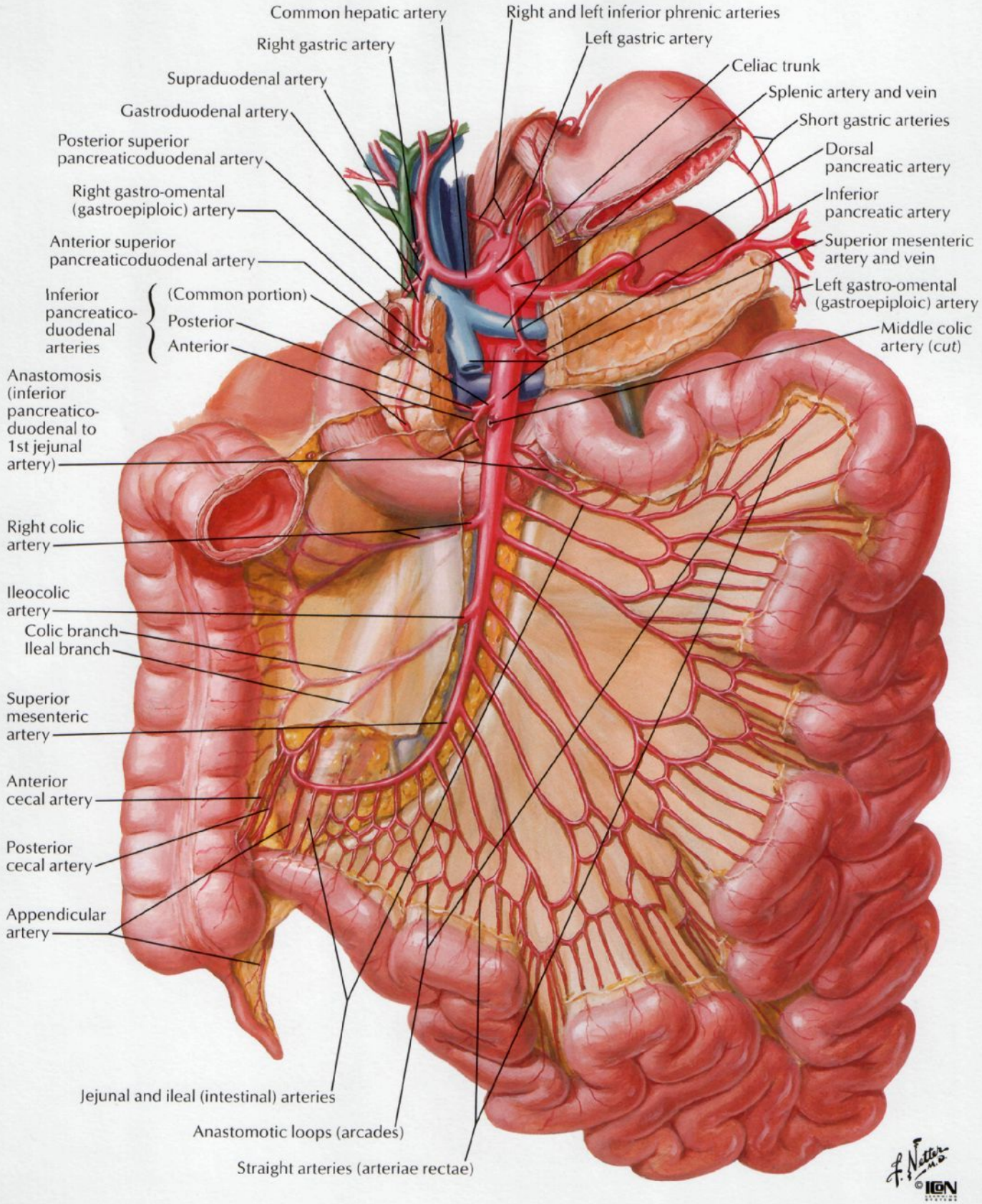
Common hepatic artery
Right and left inferior phrenic arteries
Right gastric artery
Left gastric artery
Supraduodenal artery
Celiac trunk
Gastroduodenal artery
Splenic artery and vein
Posterior superior pancreaticoduodenal artery
Short gastric arteries
Dorsal pancreatic artery
Right gastro-omental (gastroepiploic) artery
Inferior pancreatic artery
Anterior superior pancreaticoduodenal artery
Superior mesenteric artery and vein
Inferior pancreatico-duodenal arteries
(Common portion)
Posterior
Anterior
Left gastro-omental (gastroepiploic) artery
Middle colic artery (cut)
Anastomosis (inferior pancreatico-duodenal to 1st jejunal artery)
Right colic artery
Ileocolic artery
Colic branch
Ileal branch
Superior mesenteric artery
Anterior cecal artery
Posterior cecal artery
Appendicular artery
Jejunal and ileal (intestinal) arteries
Anastomotic loops (arcades)
Straight arteries (arteriae rectae)
F. Netter M.D.
©IGN

Arteries of Large Intestine

FOR ARTERIES OF RECTUM SEE ALSO PLATE 378

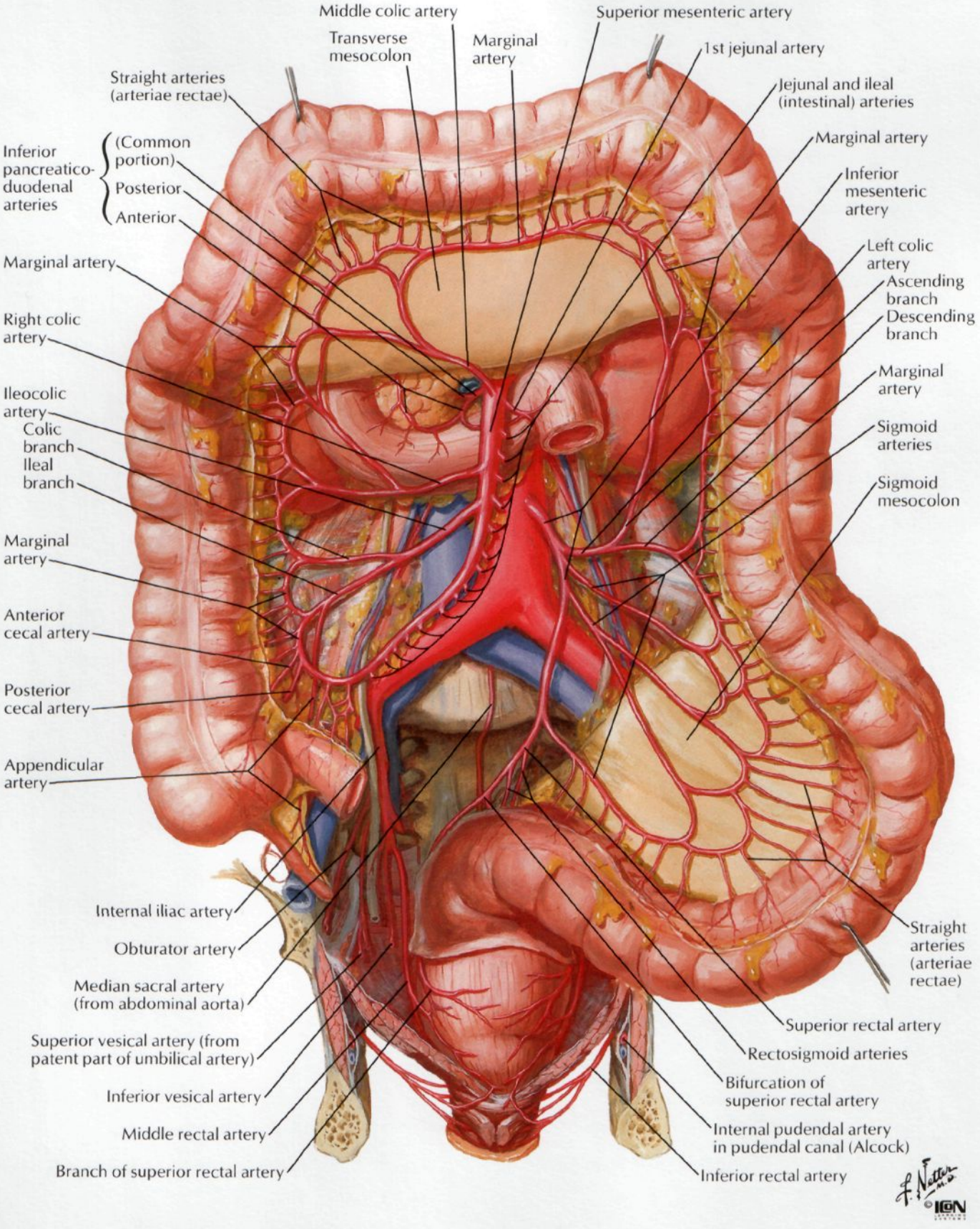

Arterial Variations and Collateral Supply of Liver and Gallbladder

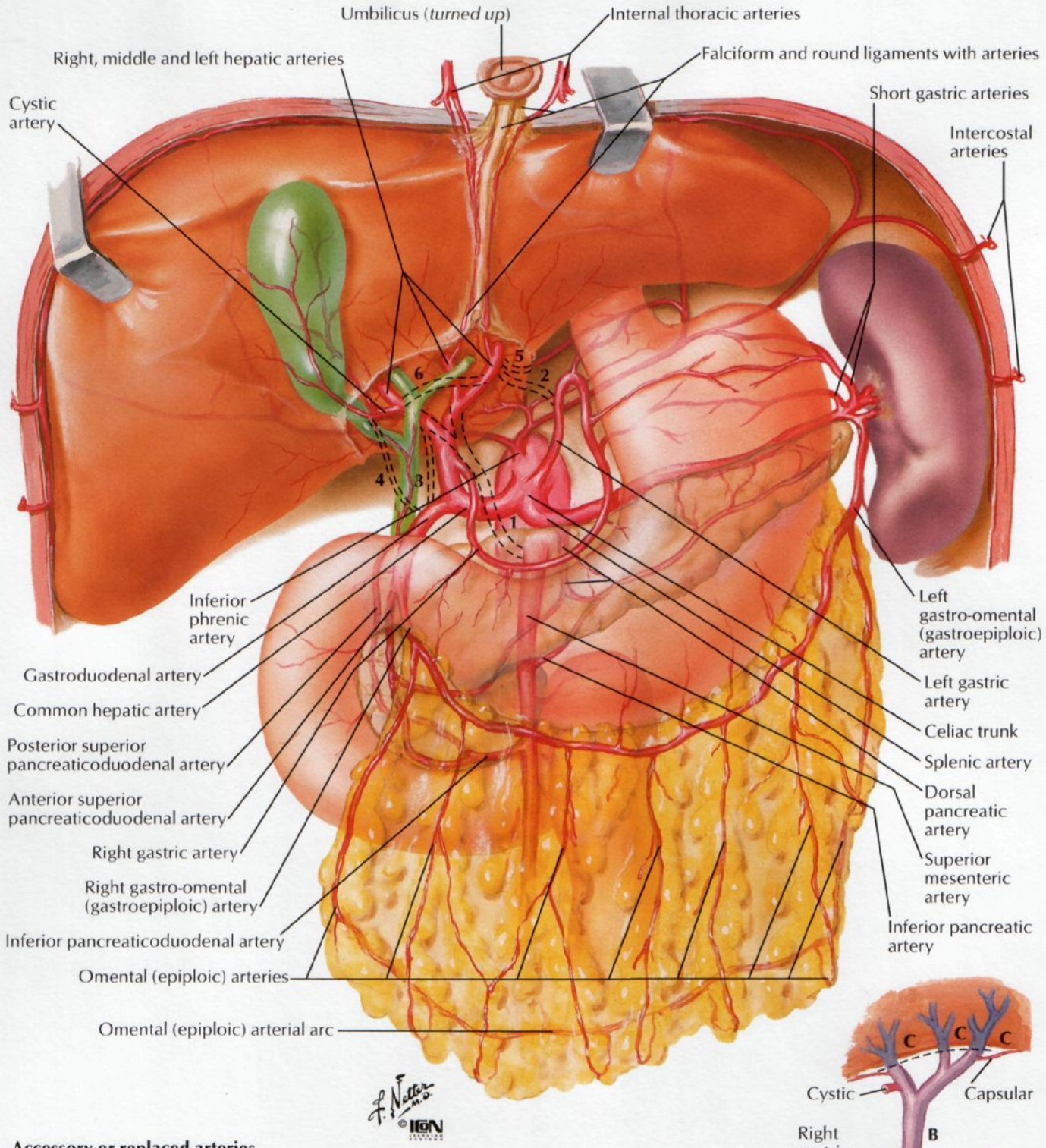

Accessory or replaced arteries
1. Right or common hepatic
2. Left hepatic
3. Right hepatic
4. Cystic

Anastomoses of corresponding arteries
5. Inferior phrenic/left gastric ⟷ left hepatic
6. Right ⟷ left hepatic

Effects of hepatic artery obstruction
- A. Zone of relative safety
- B. Zone of questionable effects
- C. Zone of inevitable infarction

Variations in Colic Arteries

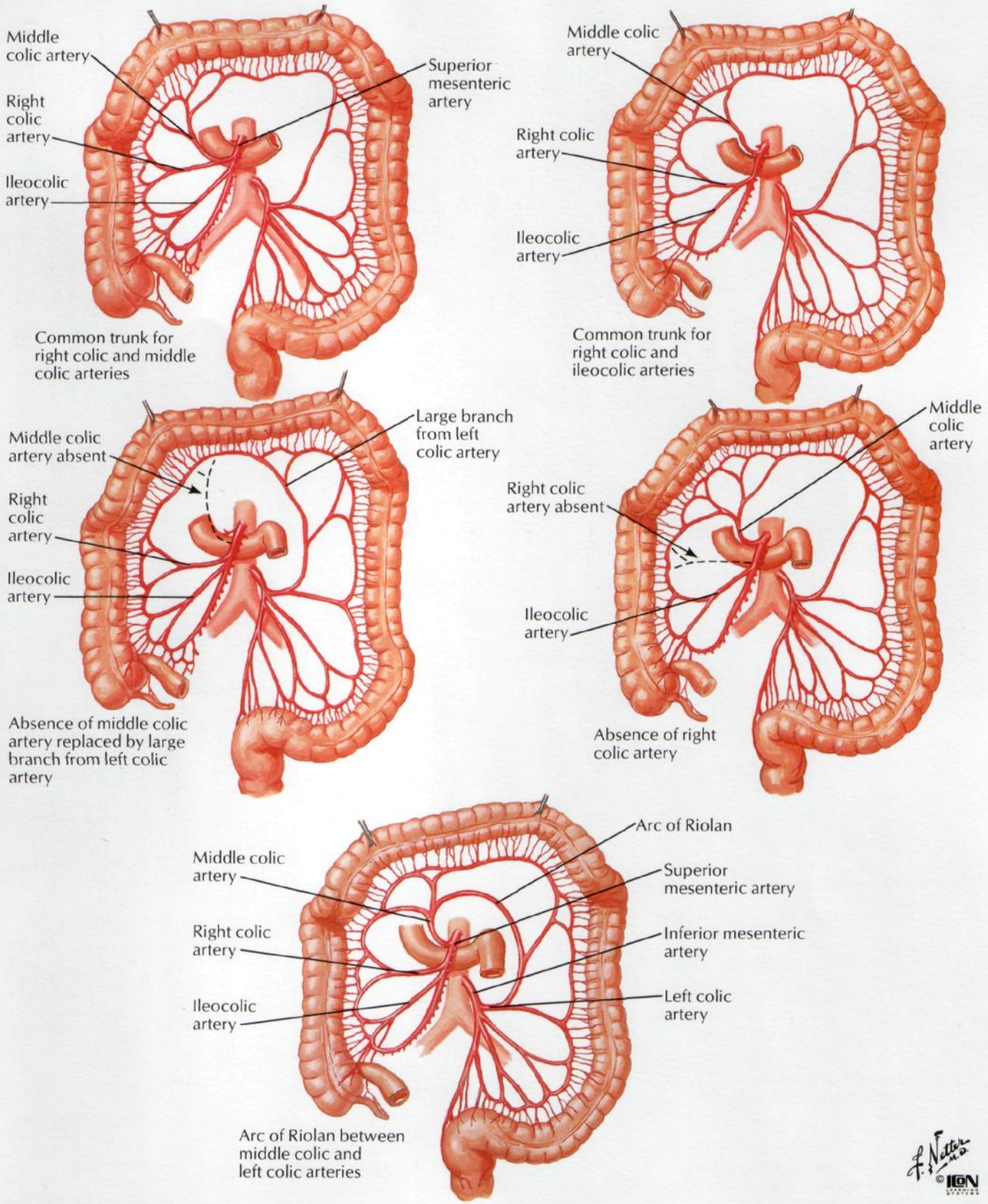

Veins of Stomach, Duodenum, Pancreas and Spleen

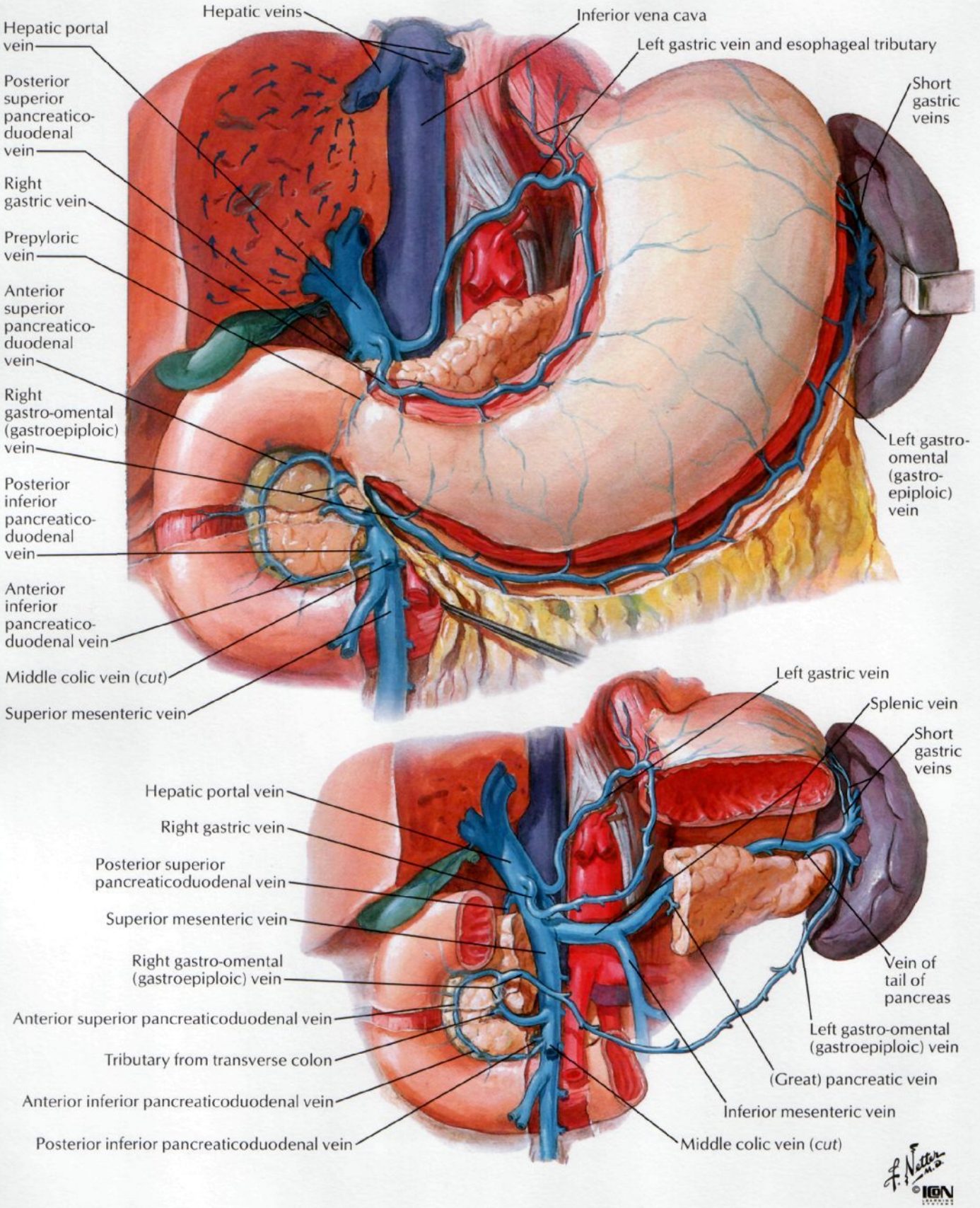

Veins of Small Intestine

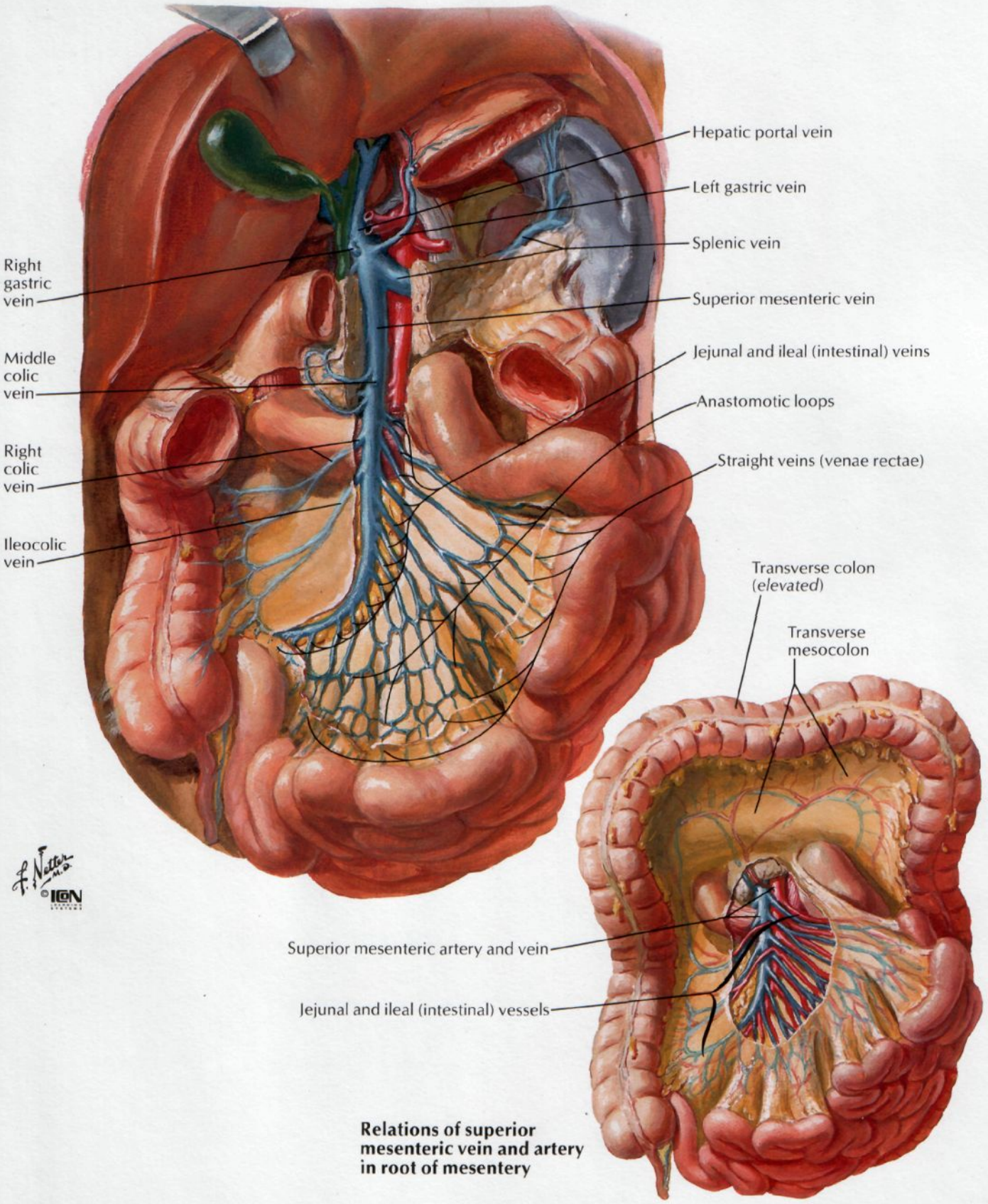

Relations of superior mesenteric vein and artery in root of mesentery

Veins of Large Intestine

FOR VEINS OF RECTUM SEE ALSO PLATE 379

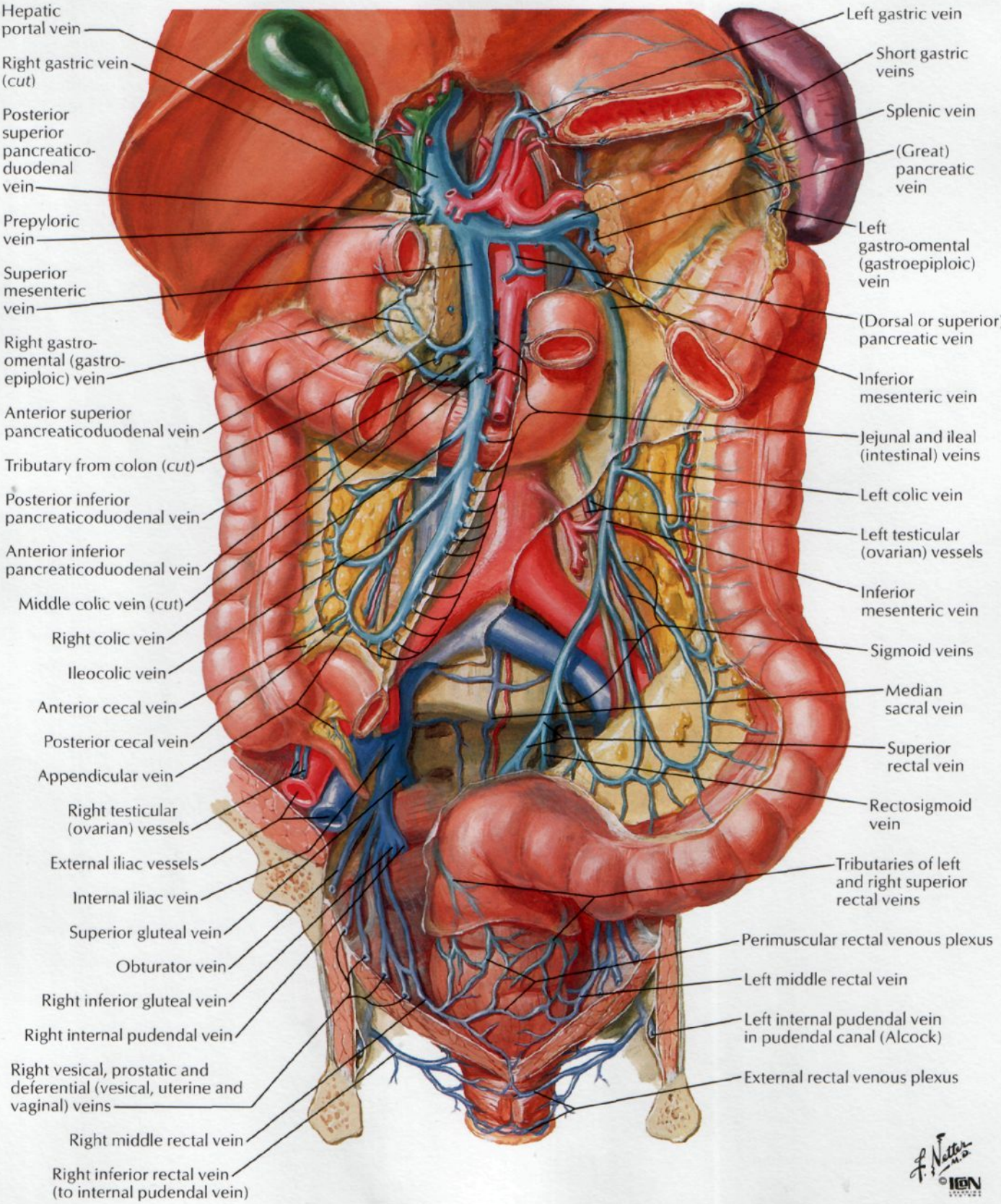

Hepatic Portal Vein Tributaries: Portocaval Anastomoses

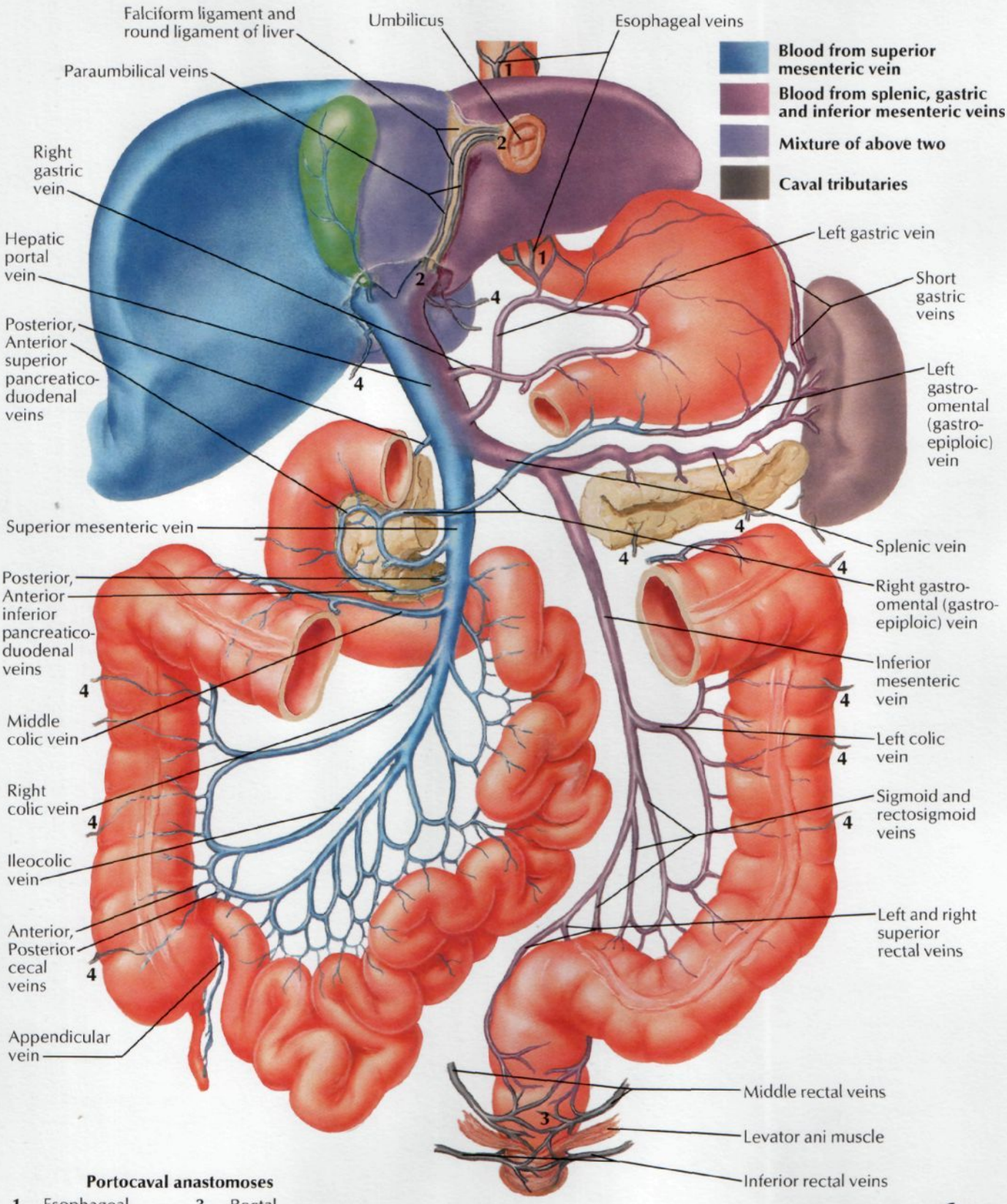

Portocaval anastomoses

1	Esophageal	3	Rectal
2	Paraumbilical	4	Retroperitoneal

F. Netter M.D. ©IGN

Typical arrangement

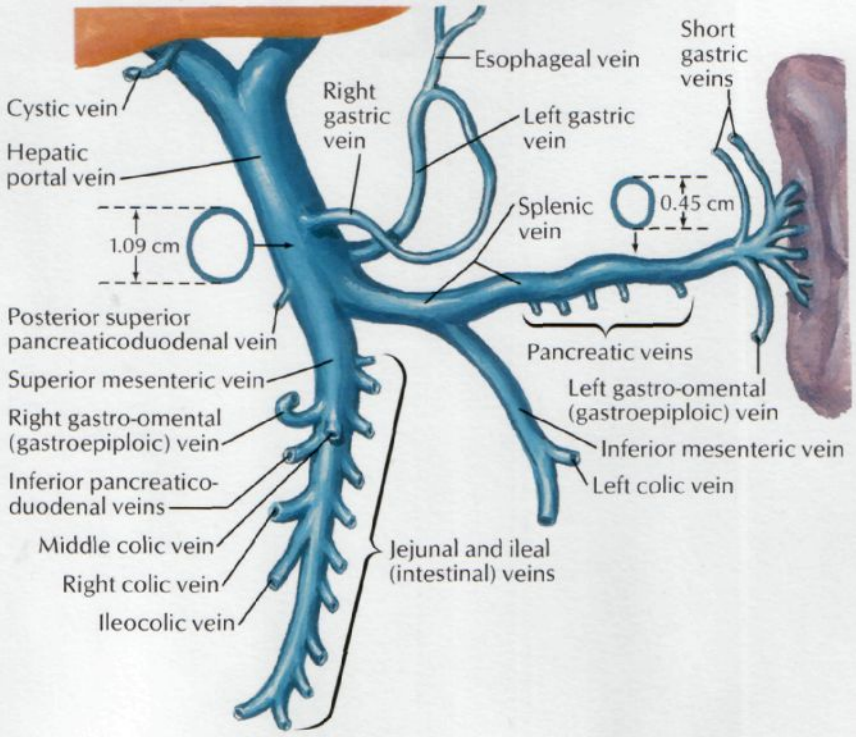

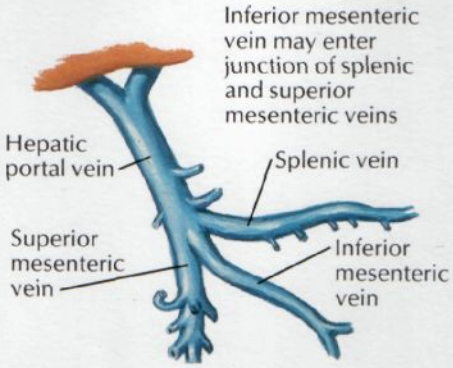

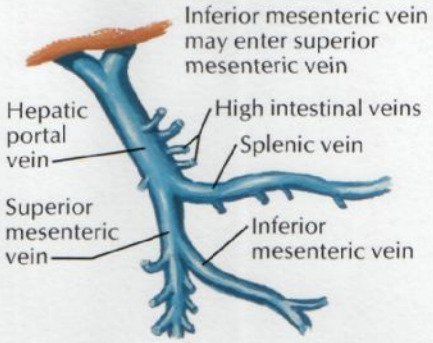

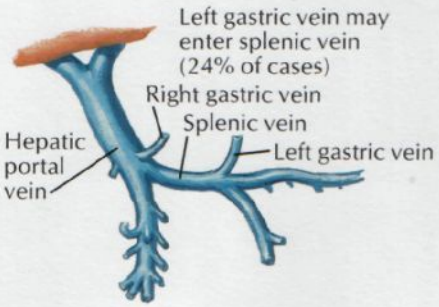

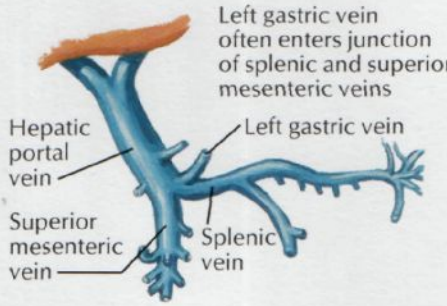

F. Netter M.D. ©IGN

Lymph Vessels and Nodes of Stomach

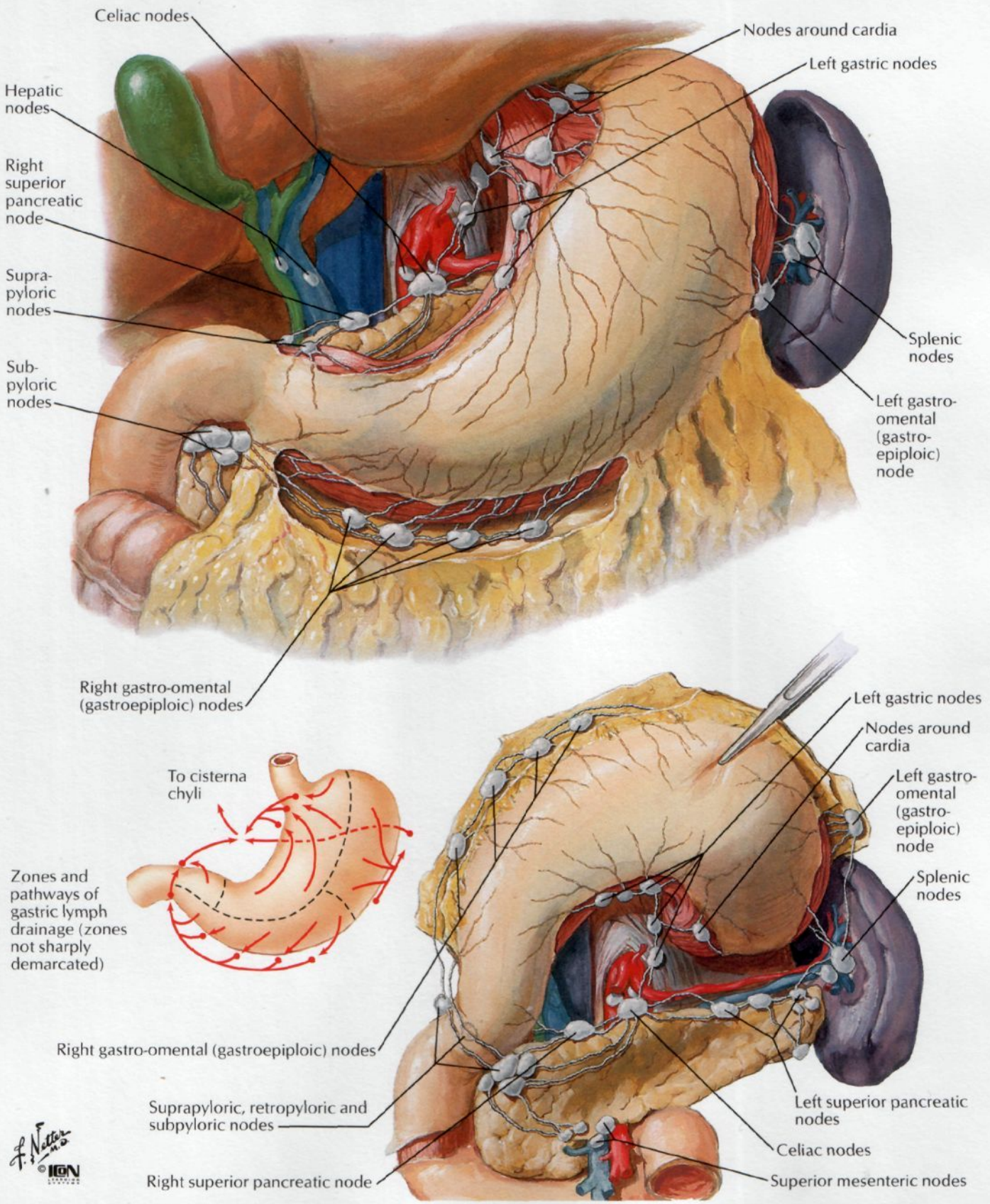

Lymph Vessels and Nodes of Small Intestine

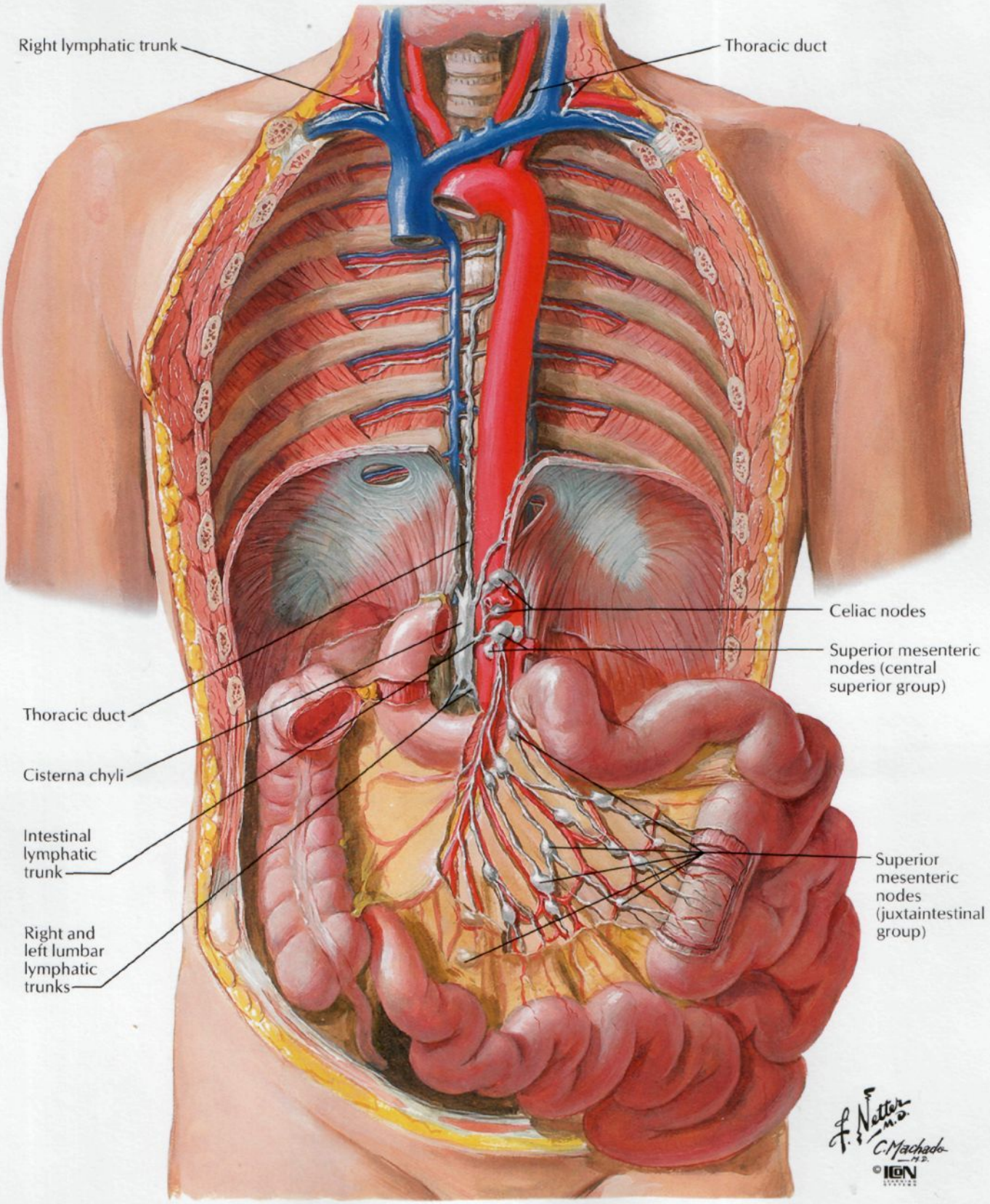

Lymph Vessels and Nodes of Large Intestine

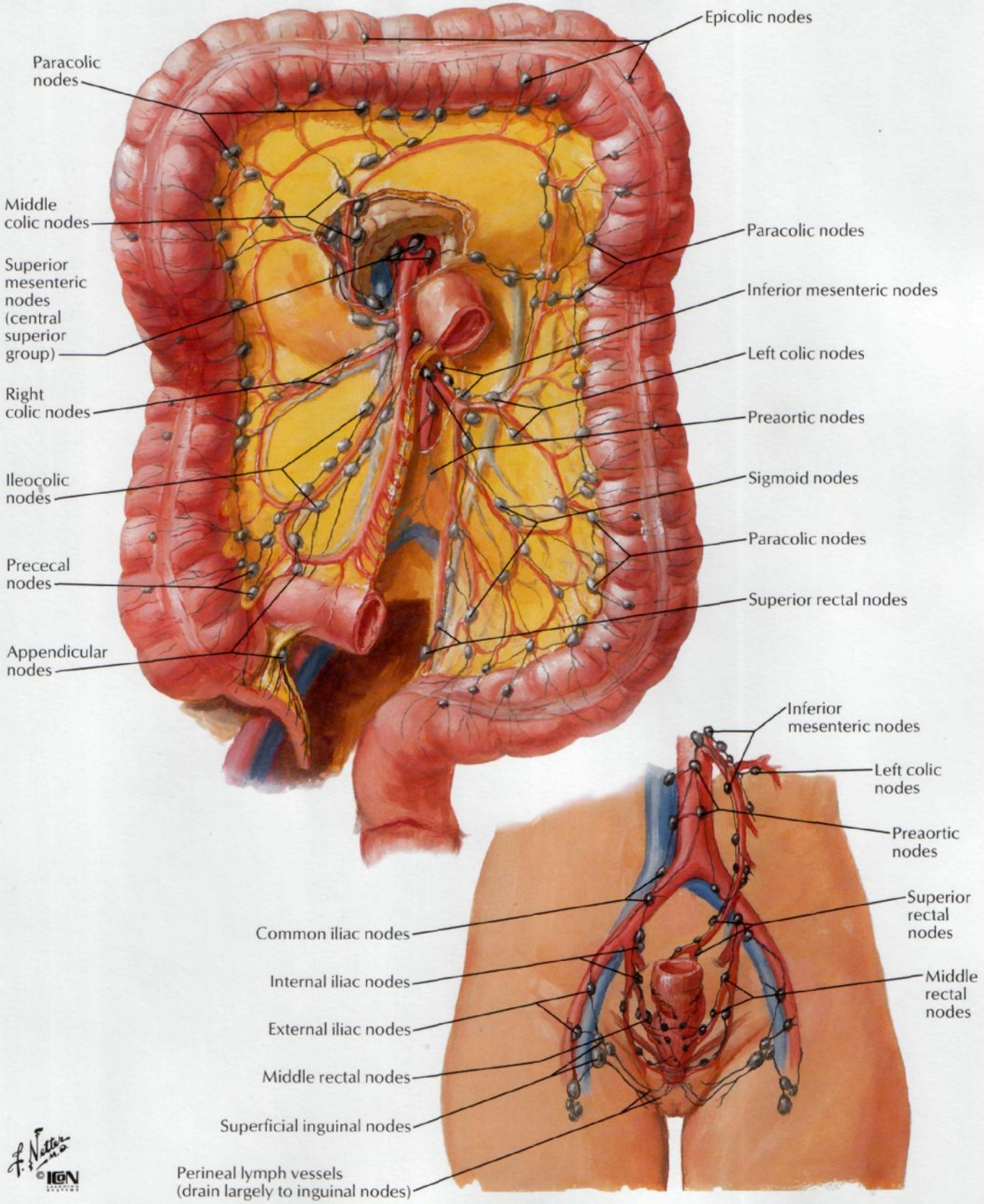

Lymph Vessels and Nodes of Pancreas

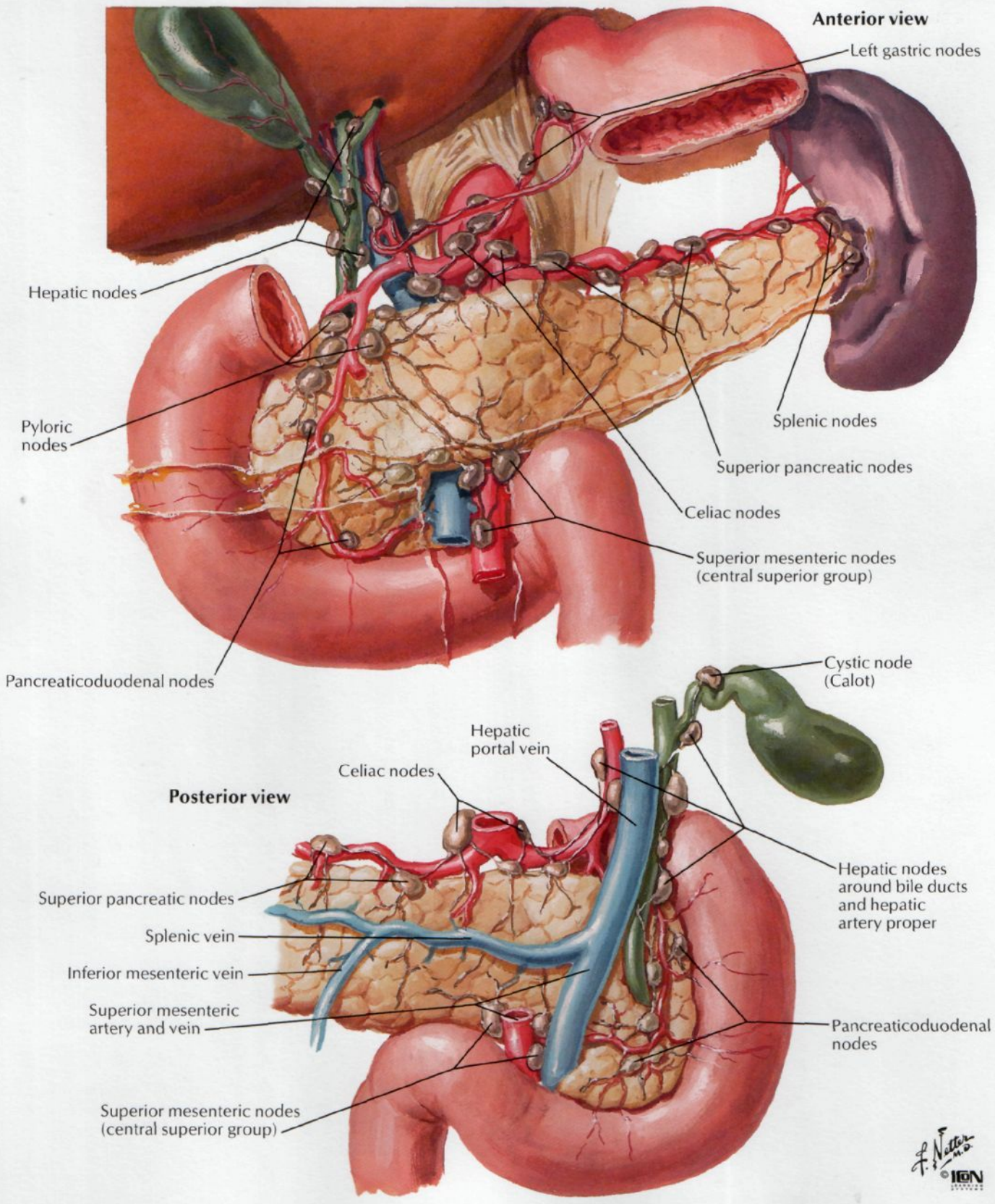

Autonomic Nerves and Ganglia of Abdomen

SEE ALSO PLATE 159

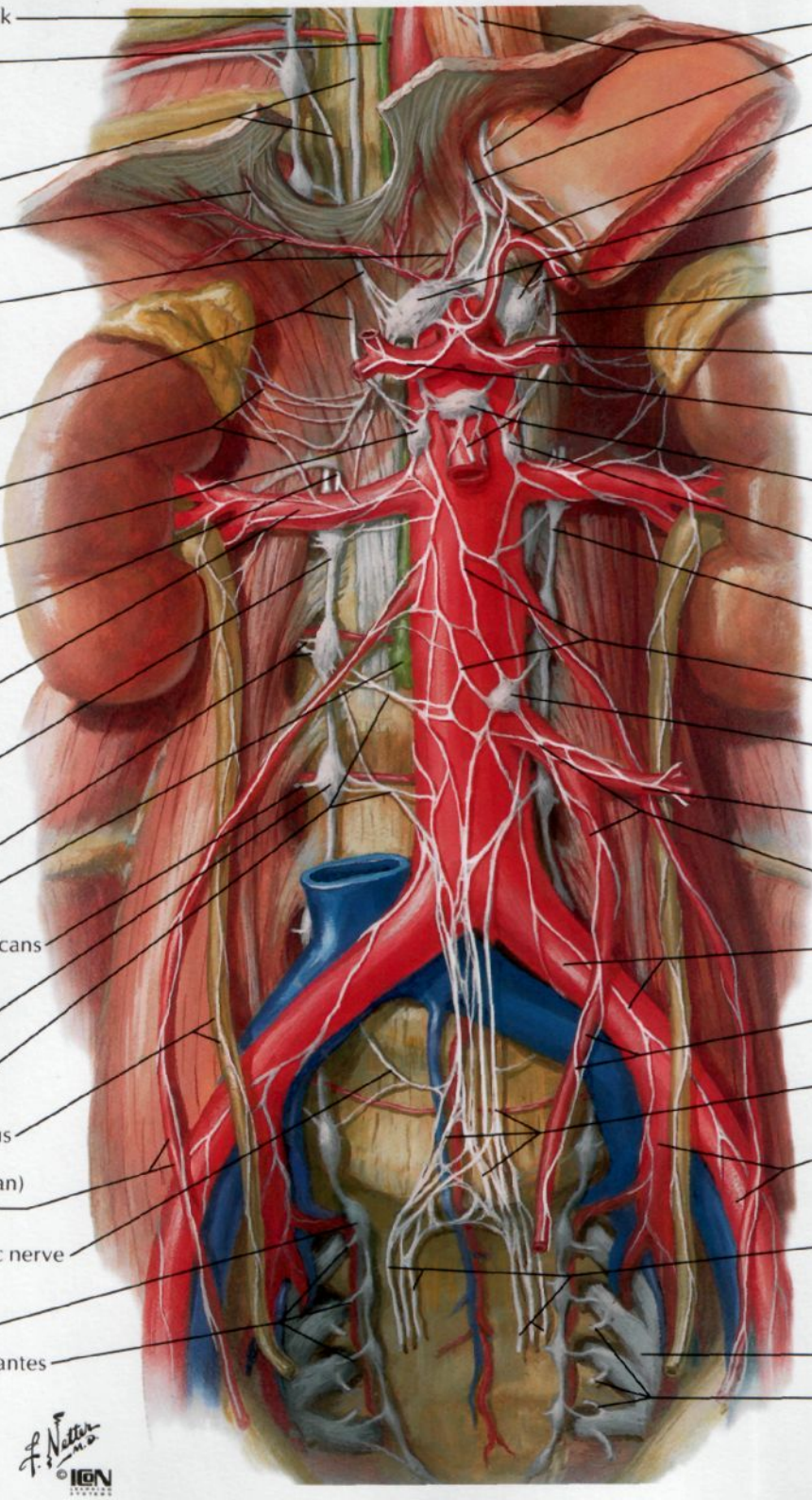

Nerves of Stomach and Duodenum

SEE ALSO PLATE 159

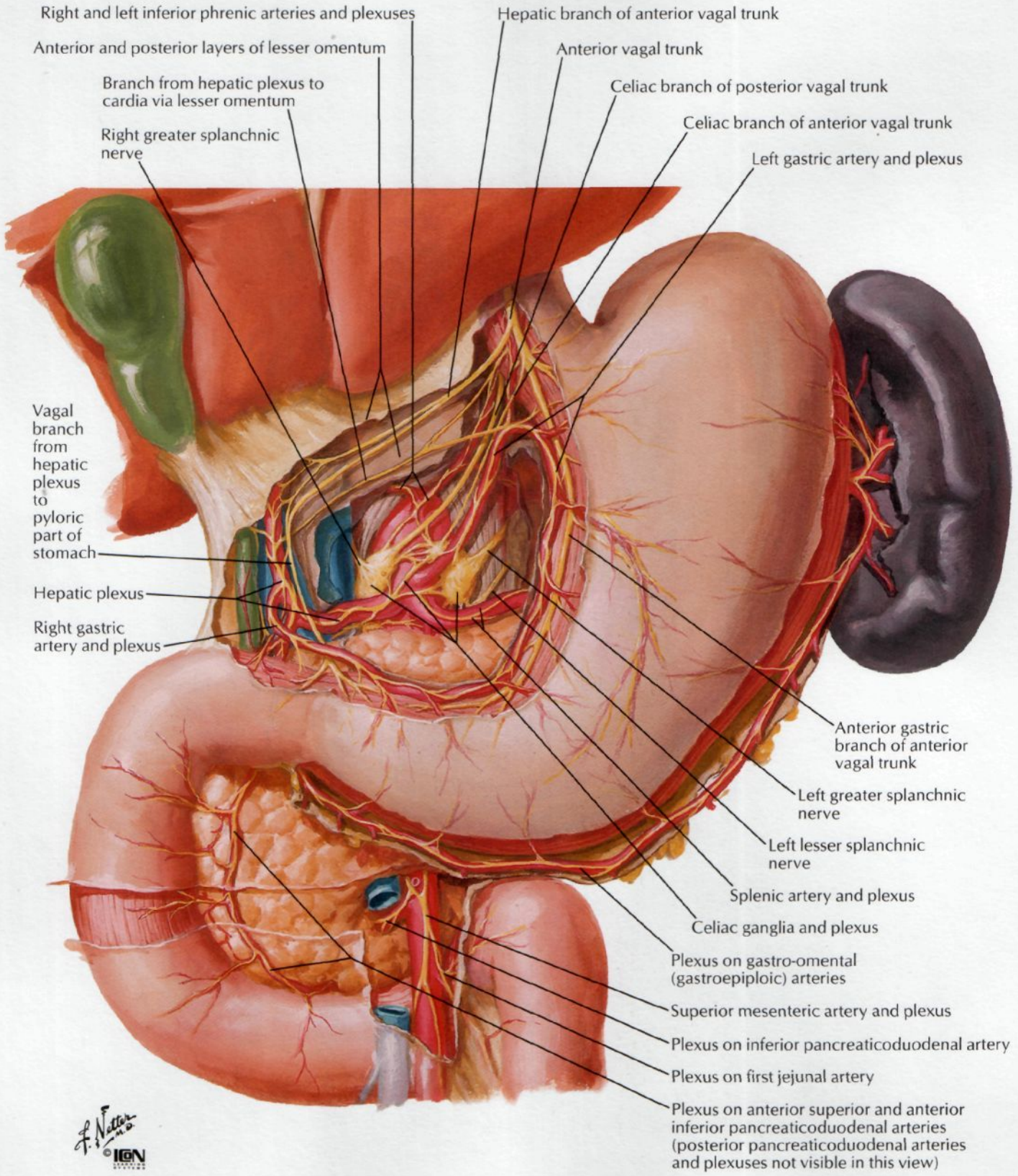

Nerves of Stomach and Duodenum (continued)

SEE ALSO PLATE 159

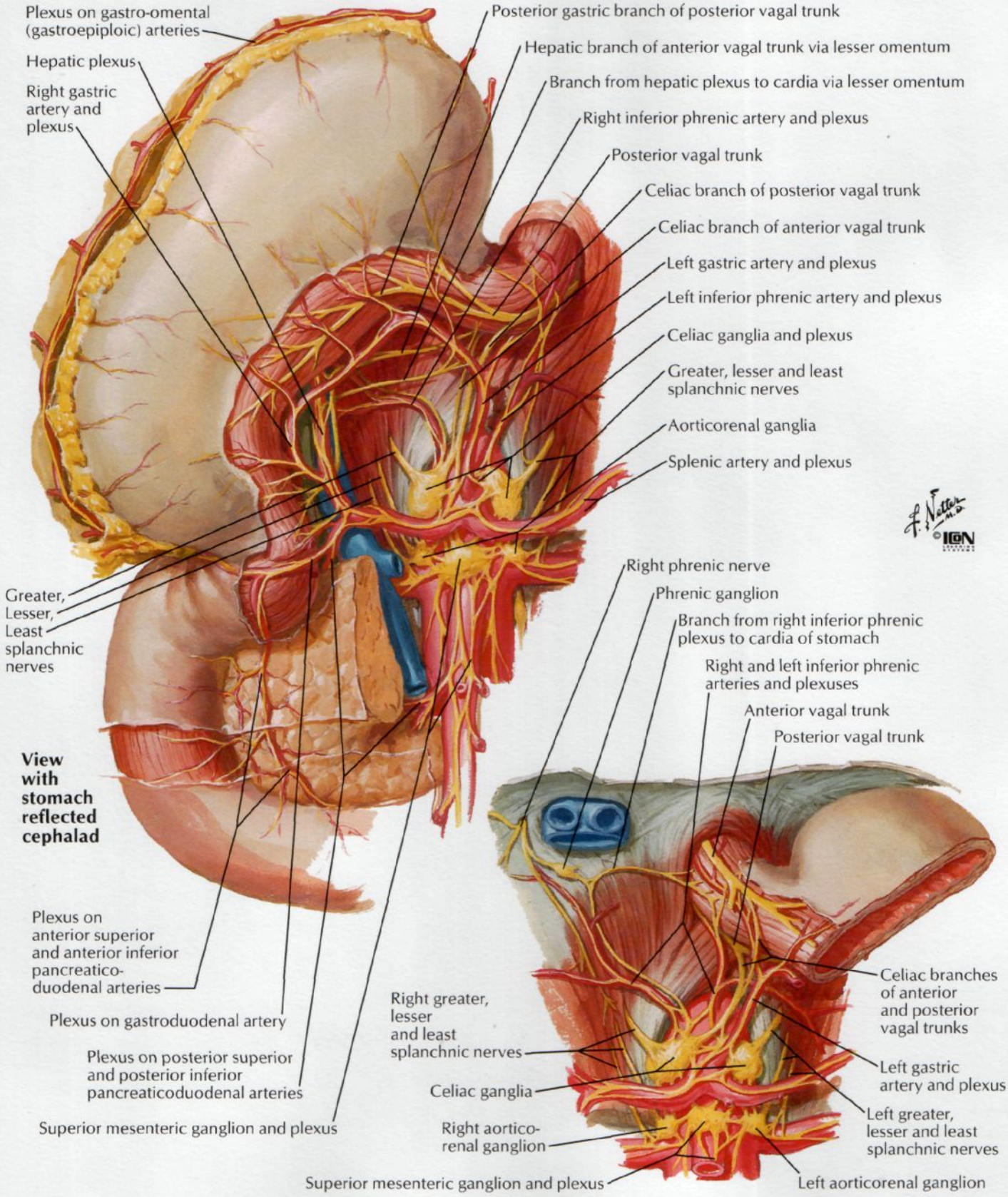

Innervation of Stomach and Duodenum: Schema

SEE ALSO PLATE 160

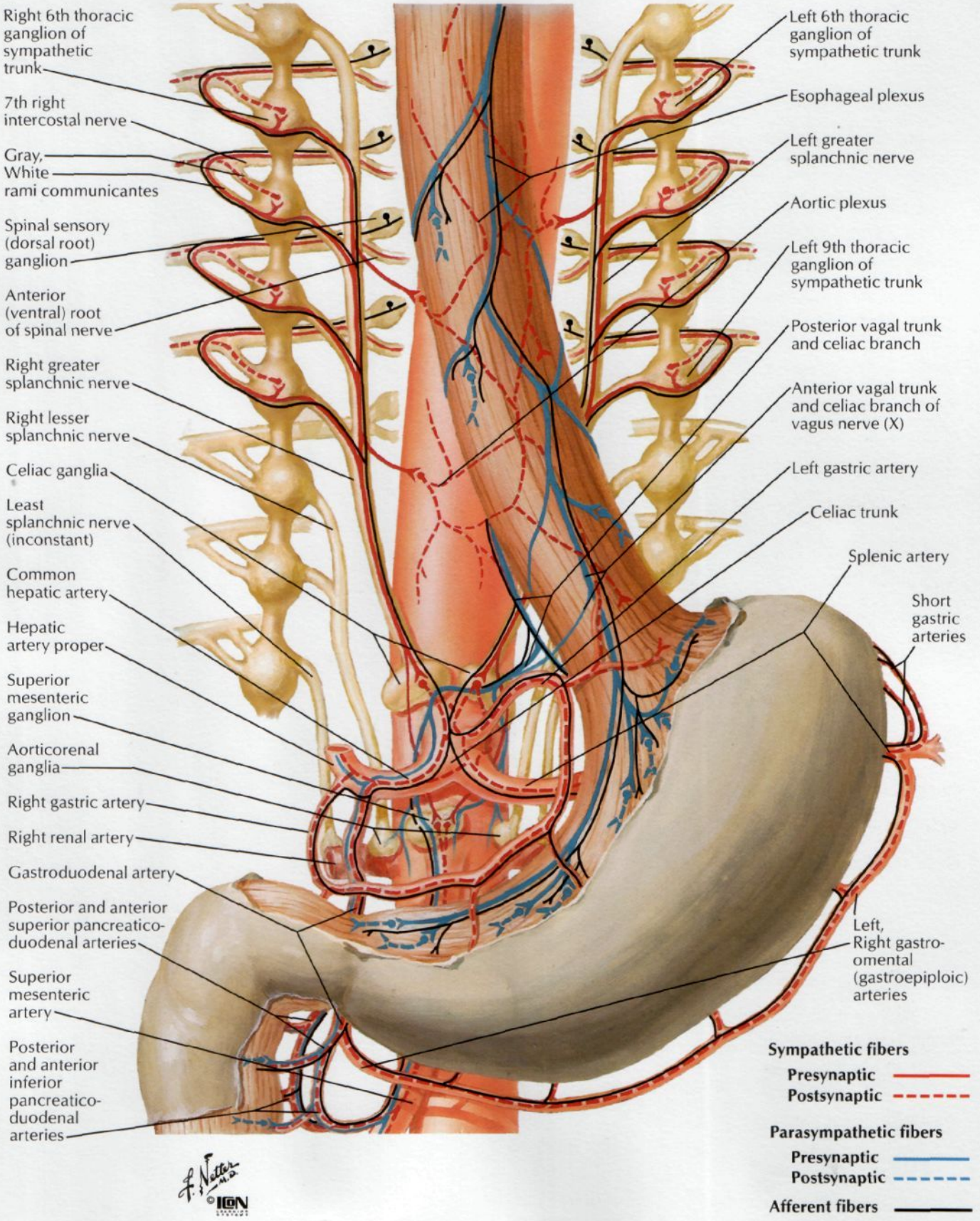

©IGN

Nerves of Small Intestine

SEE ALSO PLATE 159

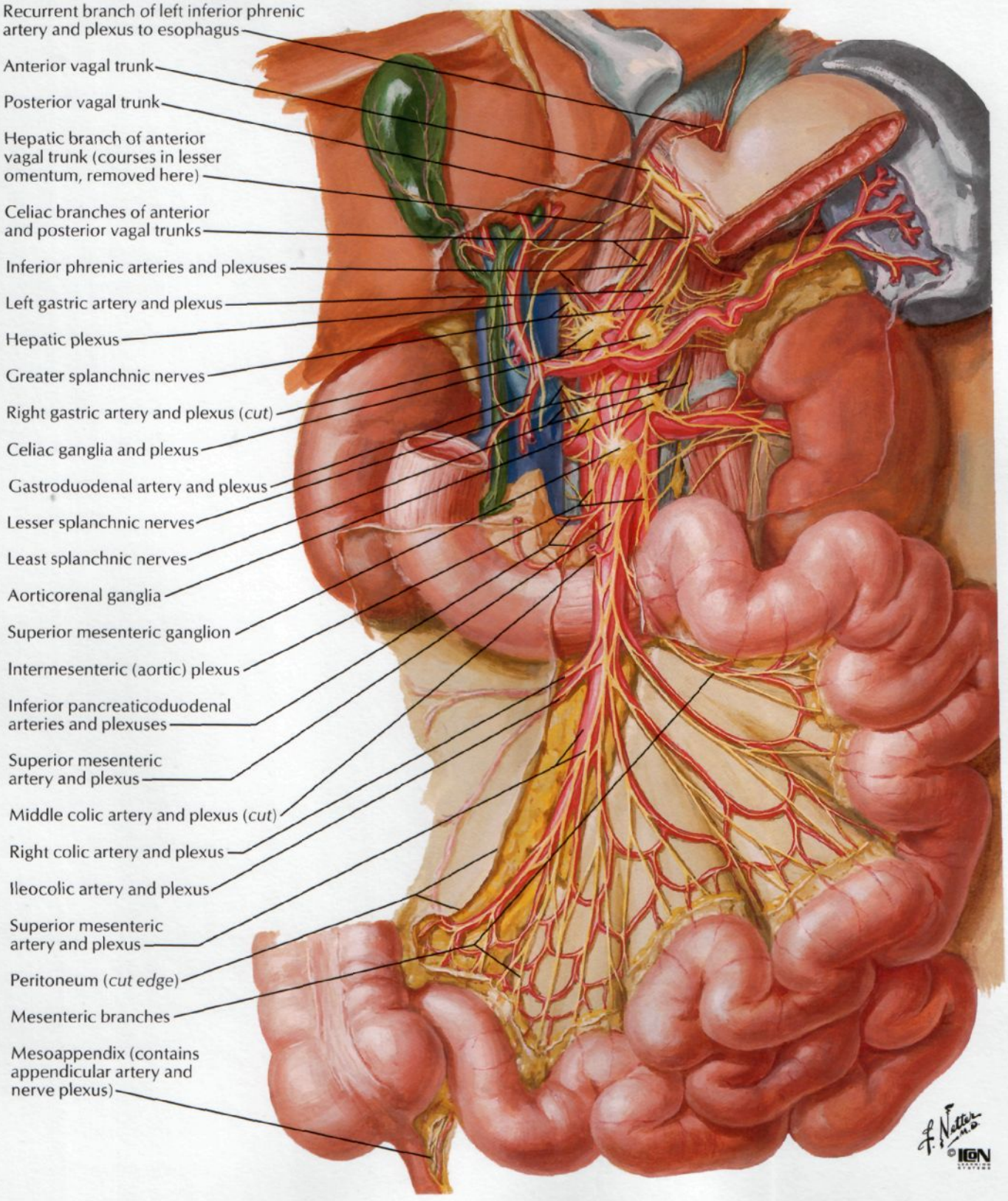

Nerves of Large Intestine

FOR NERVES OF RECTUM SEE PLATES 159, 390–393

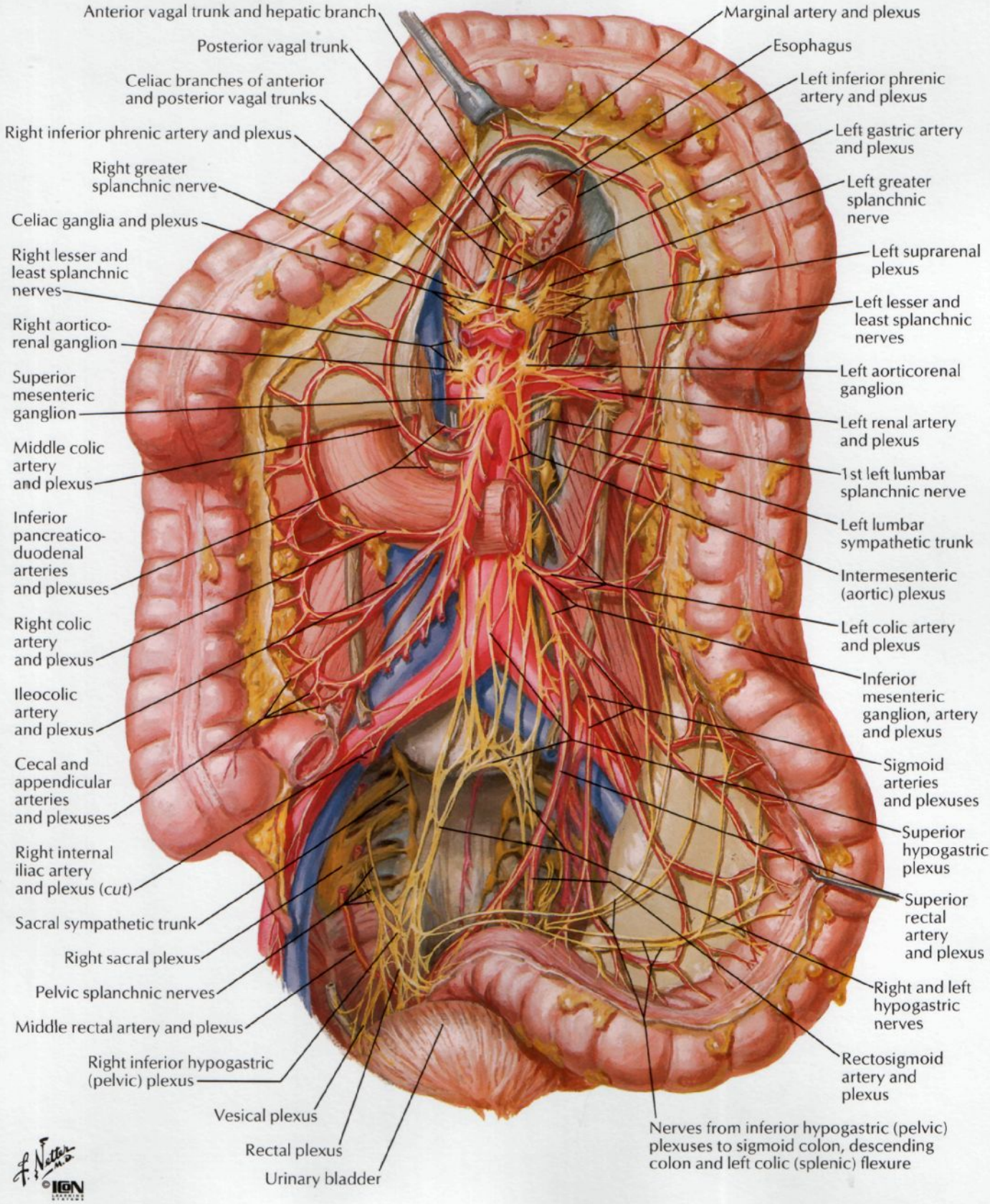

F. Netter M.D. ©IGN

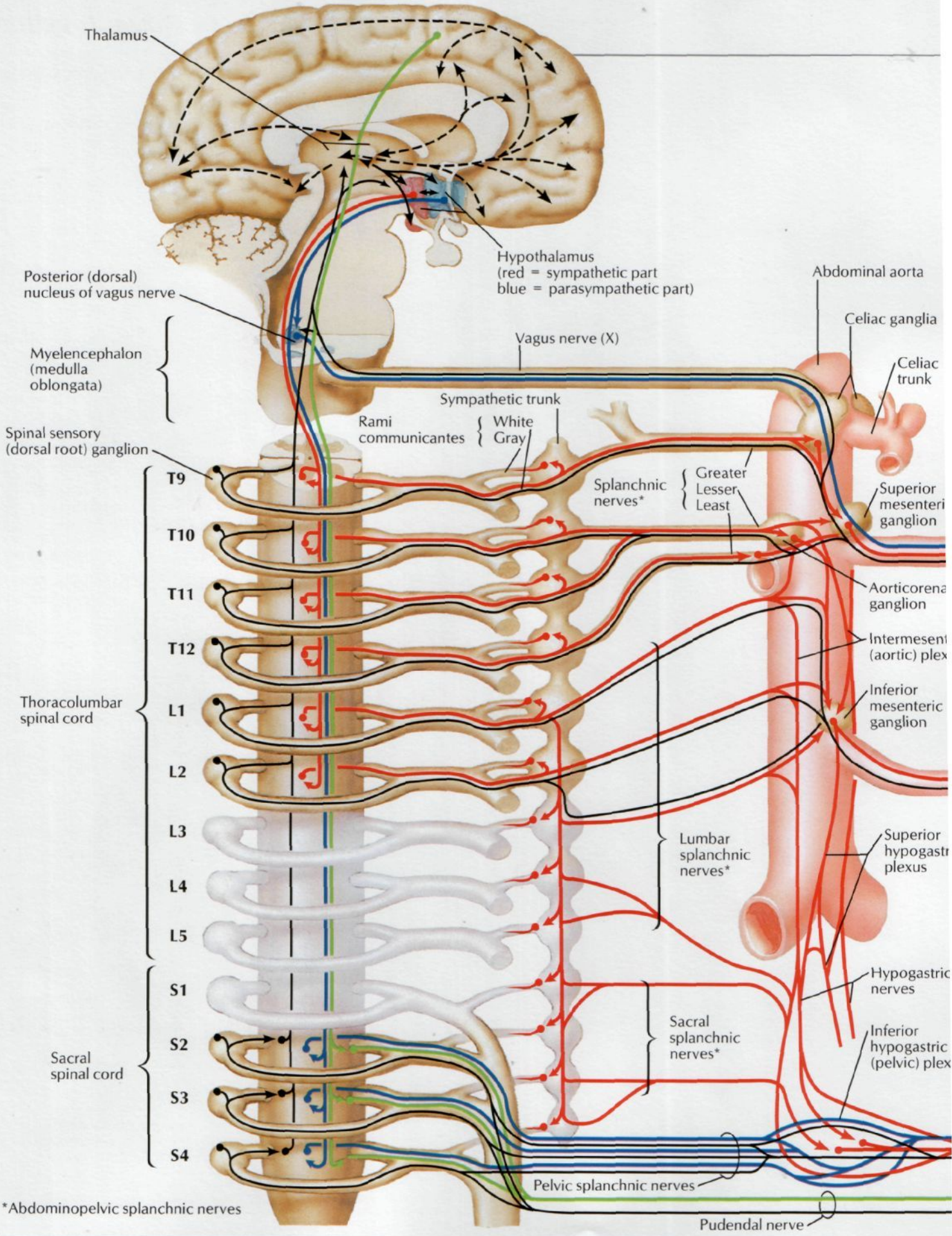
Thalamus
Hypothalamus
(red = sympathetic part
blue = parasympathetic part)
Posterior (dorsal)
nucleus of vagus nerve
Myelencephalon
(medulla
oblongata)
Vagus nerve (X)
Abdominal aorta
Celiac ganglia
Celiac
trunk
Sympathetic trunk
Rami
communicantes
White
Gray
Spinal sensory
(dorsal root) ganglion
T9
T10
T11
T12
L1
L2
L3
L4
L5
S1
S2
S3
S4
Thoracolumbar
spinal cord
Sacral
spinal cord
Splanchnic
nerves*
Greater
Lesser
Least
Superior
mesenteri
ganglion
Aorticorena
ganglion
Intermesent
(aortic) plex
Inferior
mesenteric
ganglion
Lumbar
splanchnic
nerves*
Superior
hypogastr
plexus
Hypogastric
nerves
Sacral
splanchnic
nerves*
Inferior
hypogastric
(pelvic) plex
Pelvic splanchnic nerves
Pudendal nerve
*Abdominopelvic splanchnic nerves

Innervation of Small and Large Intestines: Schema

SEE ALSO PLATE 160

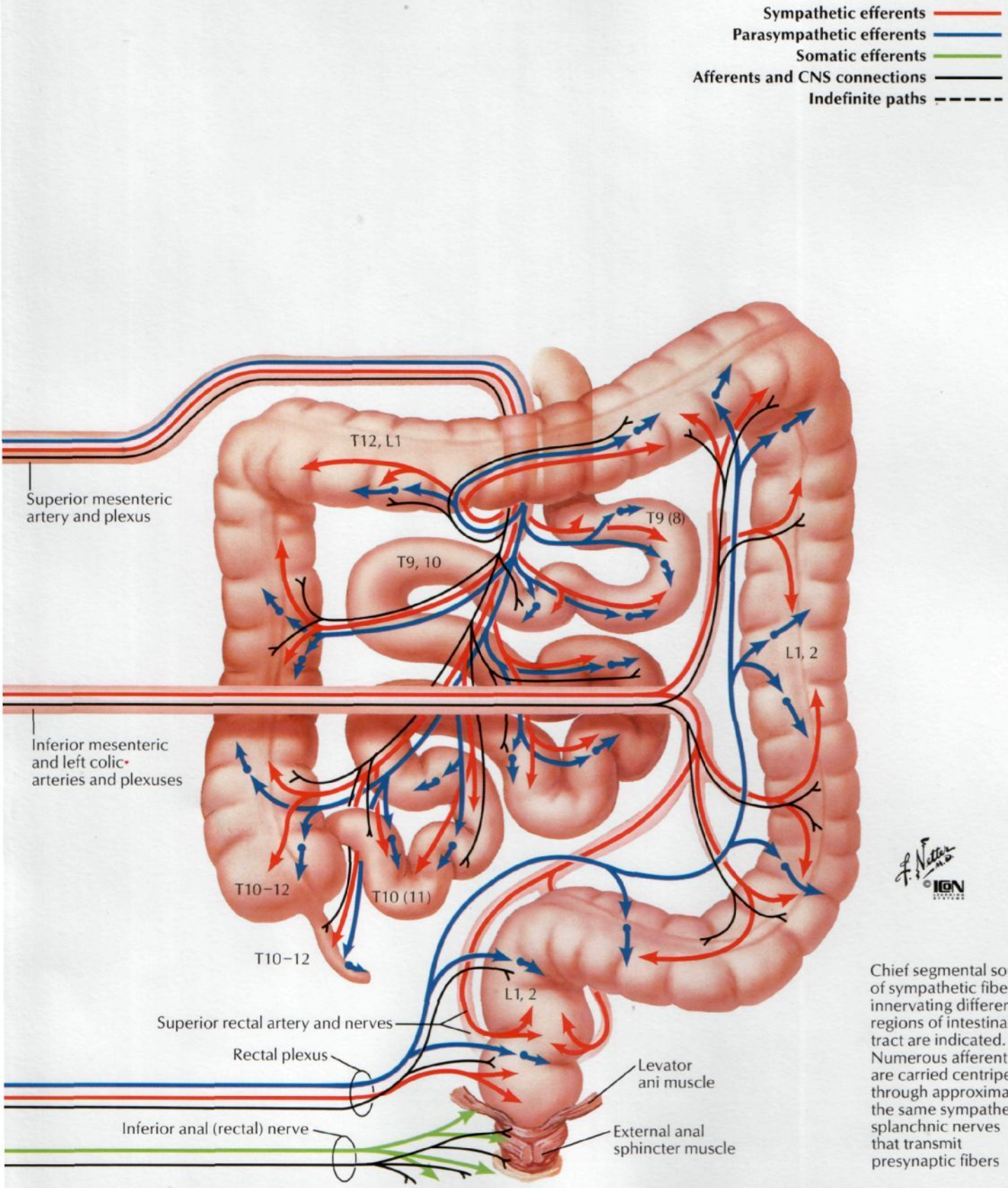

Chief segmental sources of sympathetic fibers innervating different regions of intestinal tract are indicated. Numerous afferent fibers are carried centripetally through approximately the same sympathetic splanchnic nerves that transmit presynaptic fibers

Autonomic Reflex Pathways: Schema

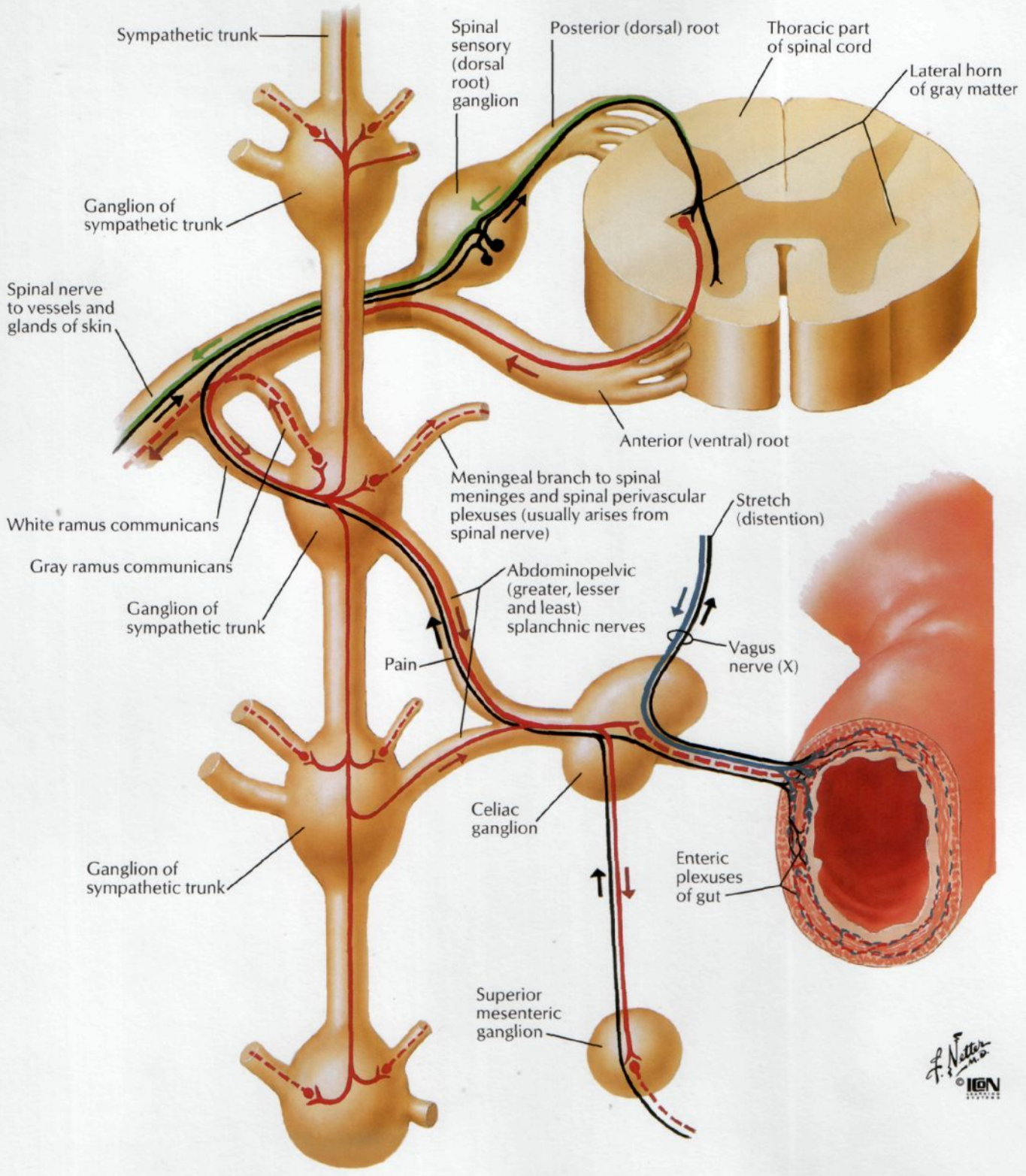

Sympathetic fibers { **Presynaptic** —— / **Postsynaptic** - - - -

Parasympathetic fibers { **Presynaptic** —— / **Postsynaptic** - - - -

Afferent fibers ——

Antidromic conduction ——

Intrinsic Autonomic Plexuses of Intestine: Schema

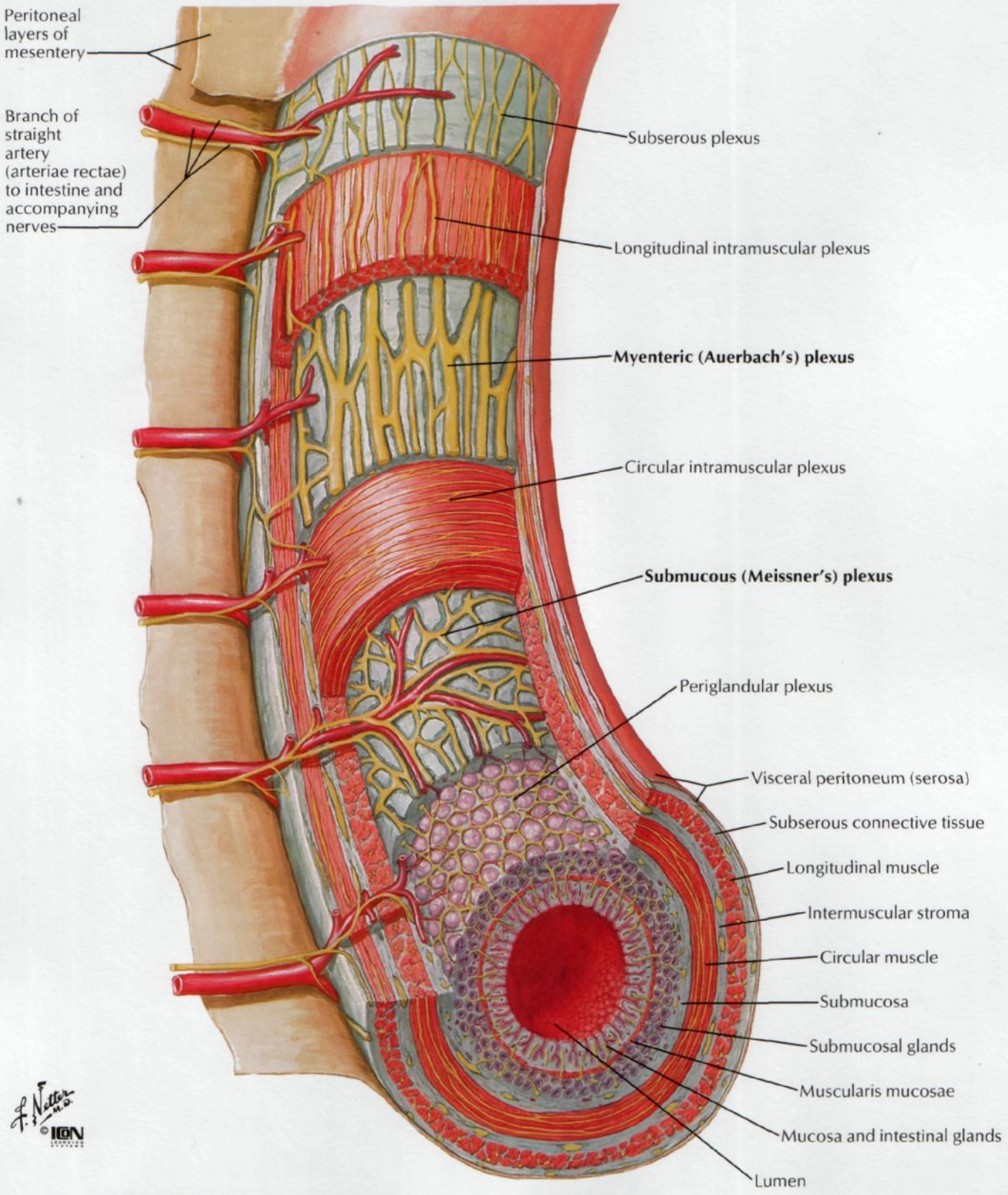

Note: Intestinal wall is shown much thicker than in actuality

Innervation of Liver and Biliary Tract: Schema

SEE ALSO PLATE 160

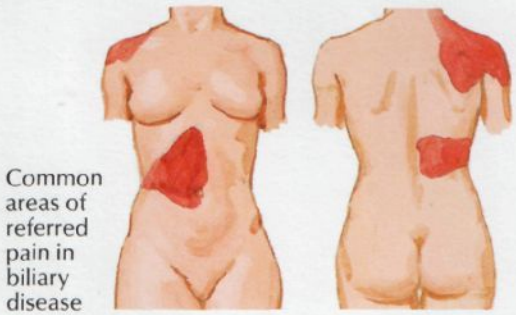

Common areas of referred pain in biliary disease

Sympathetic trunk

Spinal sensory (dorsal root) ganglion

Thoracic part of spinal cord

Left greater splanchnic nerve

Anterior vagal trunk

Right greater splanchnic nerve

Posterior vagal trunk

Right phrenic nerve to diaphragmatic part of parietal (and visceral?) peritoneum

T7 T8 T9 T10

Hepatic branch of anterior vagal trunk

Diaphragm

Phrenic ganglion

Celiac ganglia

Common hepatic artery

Splenic artery

Anterior hepatic plexus

Posterior hepatic plexus

Aorta

Gastroduodenal artery and plexus

Sphincter of hepatopancreatic ampulla

Sympathetic fibers

Presynaptic

Postsynaptic

Parasympathetic fibers

Presynaptic

Postsynaptic

Afferent fibers

Ramification of nerve fibers around fine branch of hepatic artery

Innervation of Pancreas: Schema

SEE ALSO PLATE 160

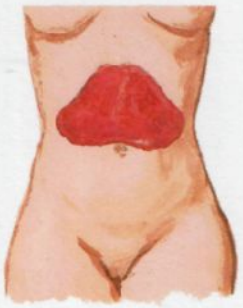

Common areas of pancreatic pain

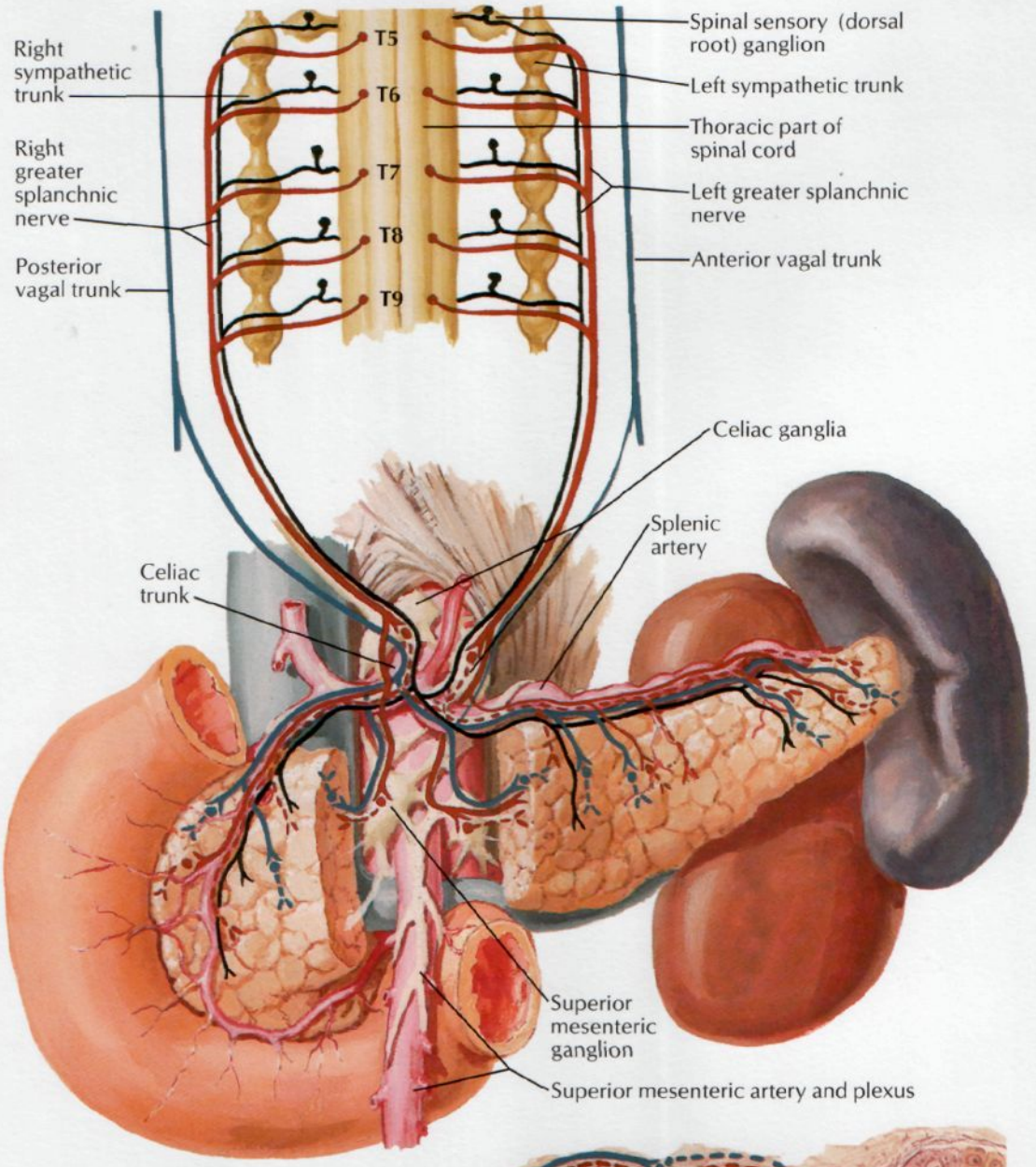

F. Netter M.D.
©IGN

Sympathetic fibers
- **Presynaptic**
- **Postsynaptic**

Parasympathetic fibers
- **Presynaptic**
- **Postsynaptic**

Afferent fibers

Schema of intrinsic nerve supply

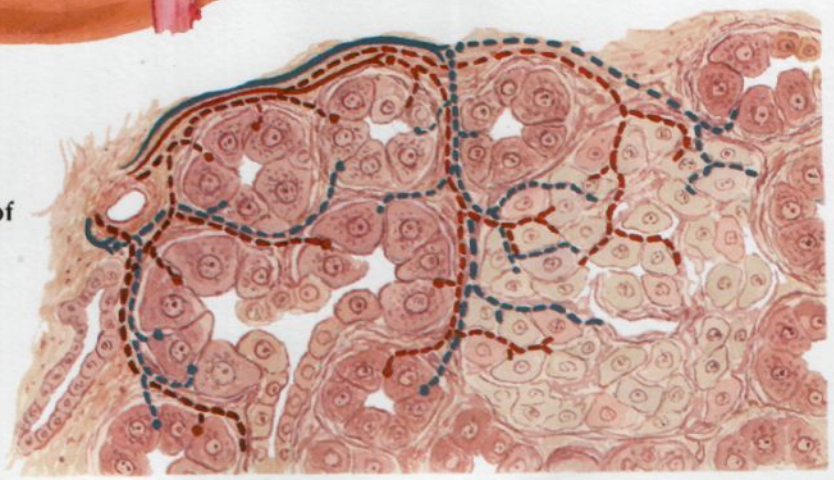

Kidneys In Situ: Anterior Views

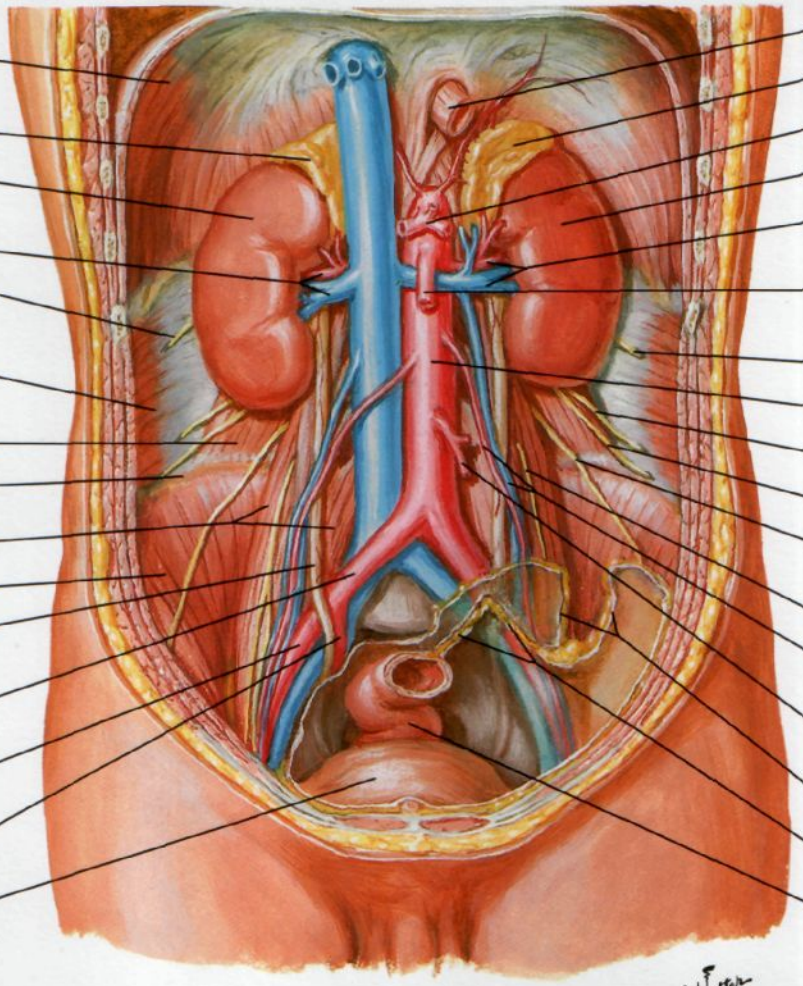

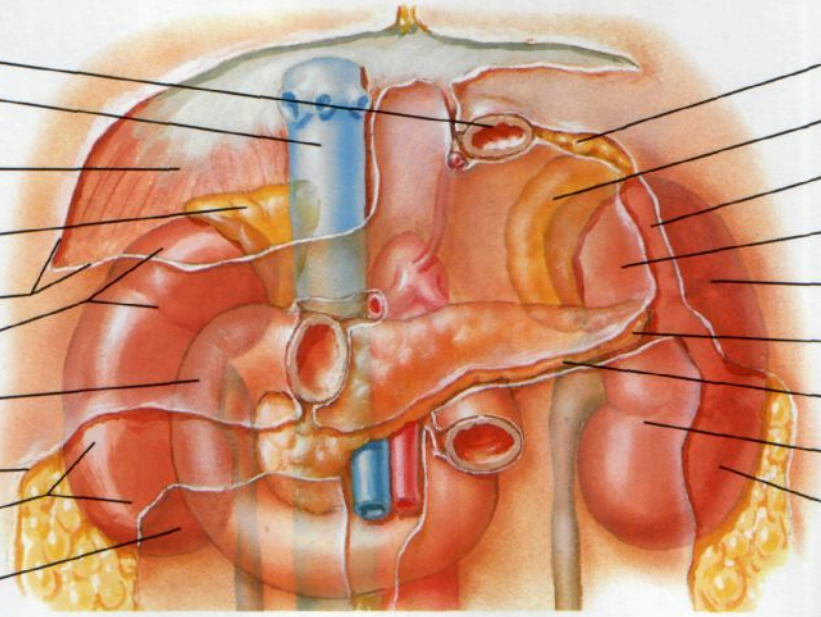

Anterior relations of kidneys

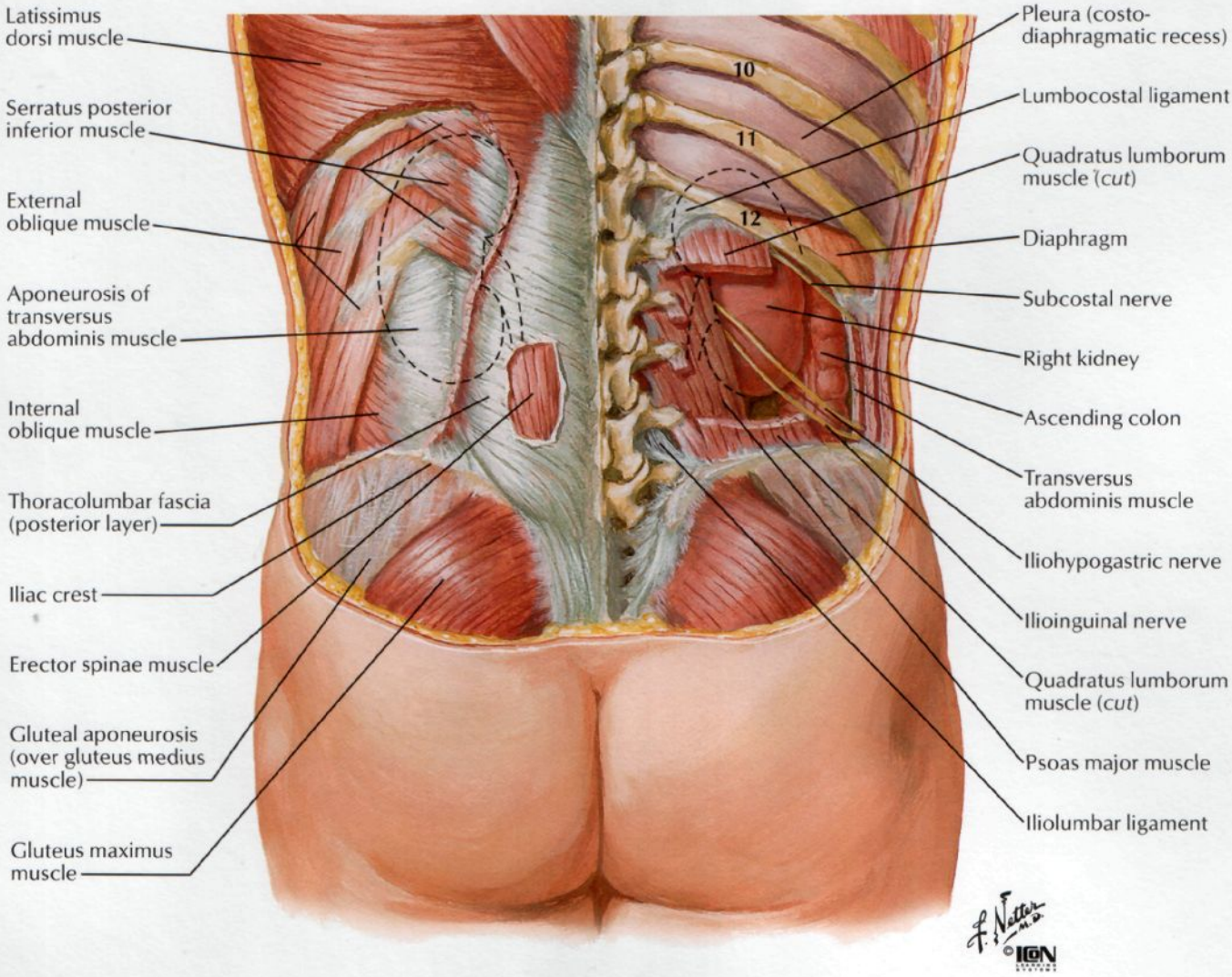
Latissimus dorsi muscle
Serratus posterior inferior muscle
External oblique muscle
Aponeurosis of transversus abdominis muscle
Internal oblique muscle
Thoracolumbar fascia (posterior layer)
Iliac crest
Erector spinae muscle
Gluteal aponeurosis (over gluteus medius muscle)
Gluteus maximus muscle
10
11
12
Pleura (costo-diaphragmatic recess)
Lumbocostal ligament
Quadratus lumborum muscle (cut)
Diaphragm
Subcostal nerve
Right kidney
Ascending colon
Transversus abdominis muscle
Iliohypogastric nerve
Ilioinguinal nerve
Quadratus lumborum muscle (cut)
Psoas major muscle
Iliolumbar ligament
F. Netter M.D.
©IGN

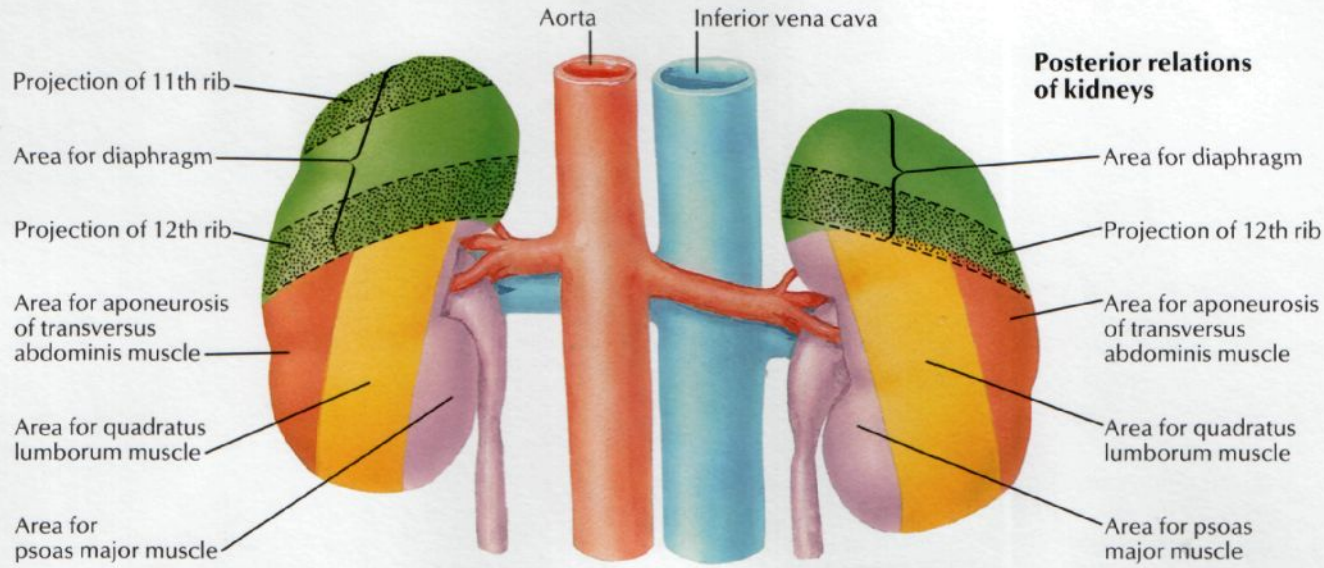
Aorta
Inferior vena cava
Posterior relations of kidneys
Projection of 11th rib
Area for diaphragm
Projection of 12th rib
Area for aponeurosis of transversus abdominis muscle
Area for quadratus lumborum muscle
Area for psoas major muscle
Area for diaphragm
Projection of 12th rib
Area for aponeurosis of transversus abdominis muscle
Area for quadratus lumborum muscle
Area for psoas major muscle

Gross Structure of Kidney

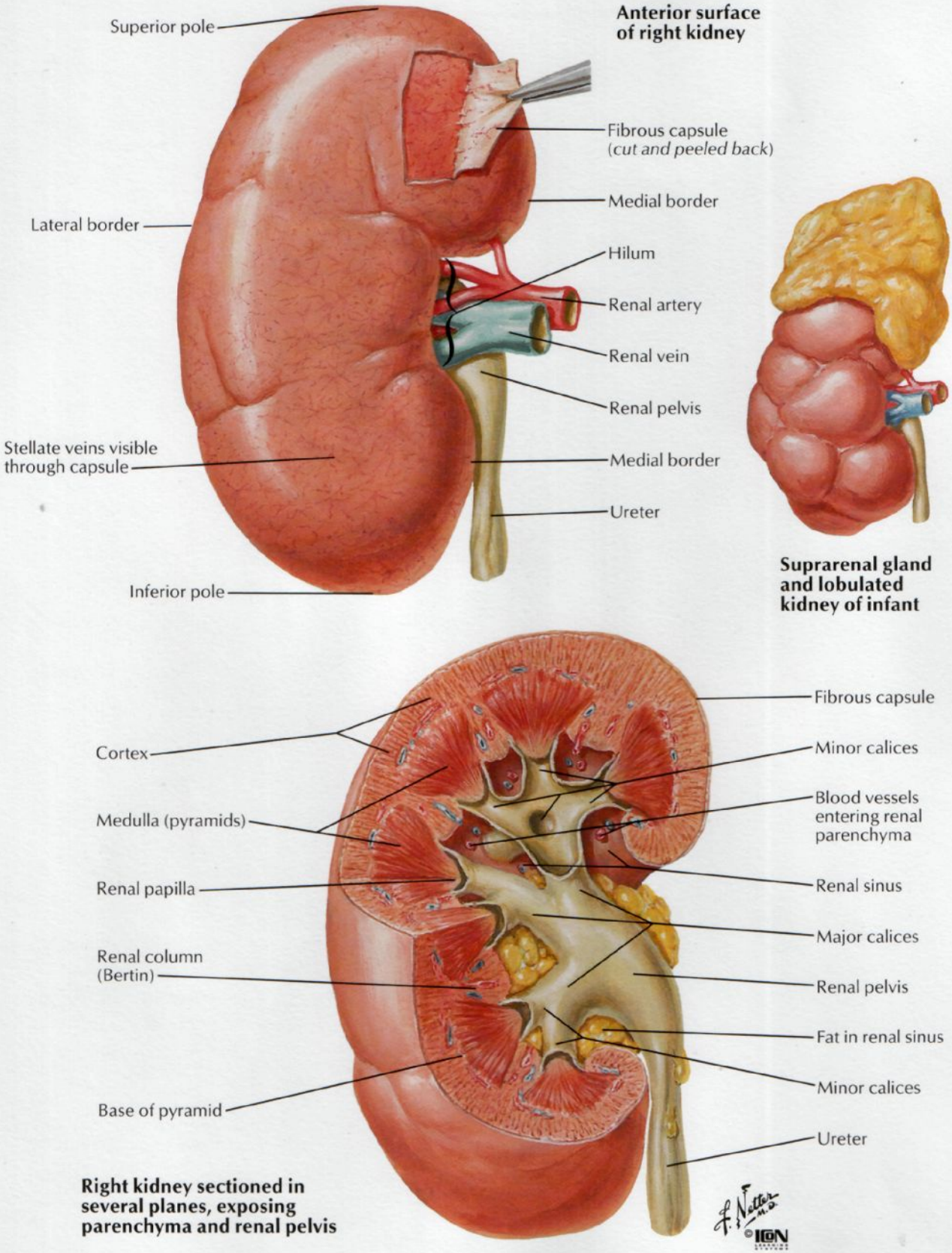

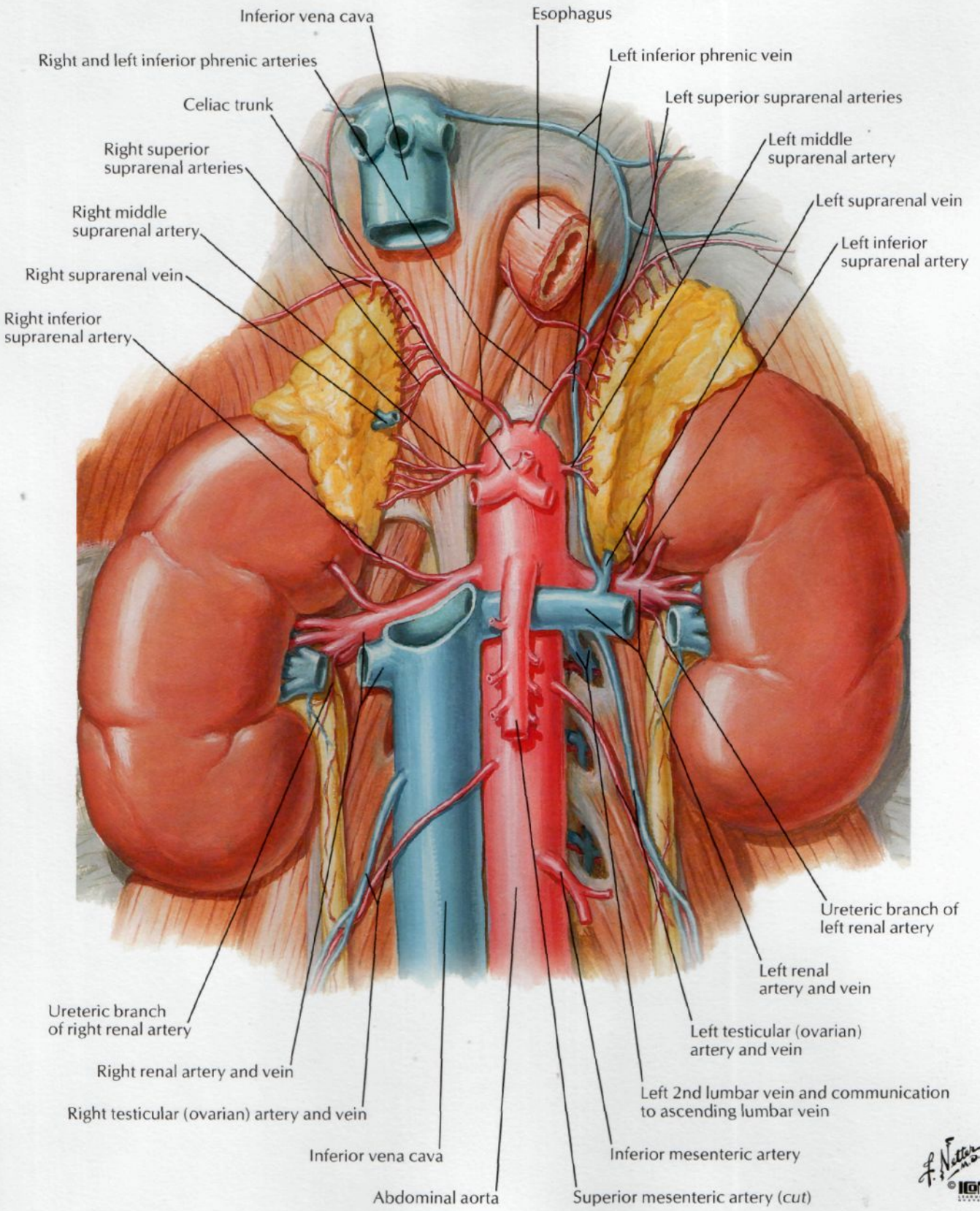
Inferior vena cava
Esophagus
Right and left inferior phrenic arteries
Left inferior phrenic vein
Celiac trunk
Left superior suprarenal arteries
Right superior suprarenal arteries
Left middle suprarenal artery
Right middle suprarenal artery
Left suprarenal vein
Right suprarenal vein
Left inferior suprarenal artery
Right inferior suprarenal artery
Ureteric branch of left renal artery
Left renal artery and vein
Ureteric branch of right renal artery
Left testicular (ovarian) artery and vein
Right renal artery and vein
Left 2nd lumbar vein and communication to ascending lumbar vein
Right testicular (ovarian) artery and vein
Inferior vena cava
Inferior mesenteric artery
Abdominal aorta
Superior mesenteric artery (cut)

Intrarenal Arteries and Renal Segments

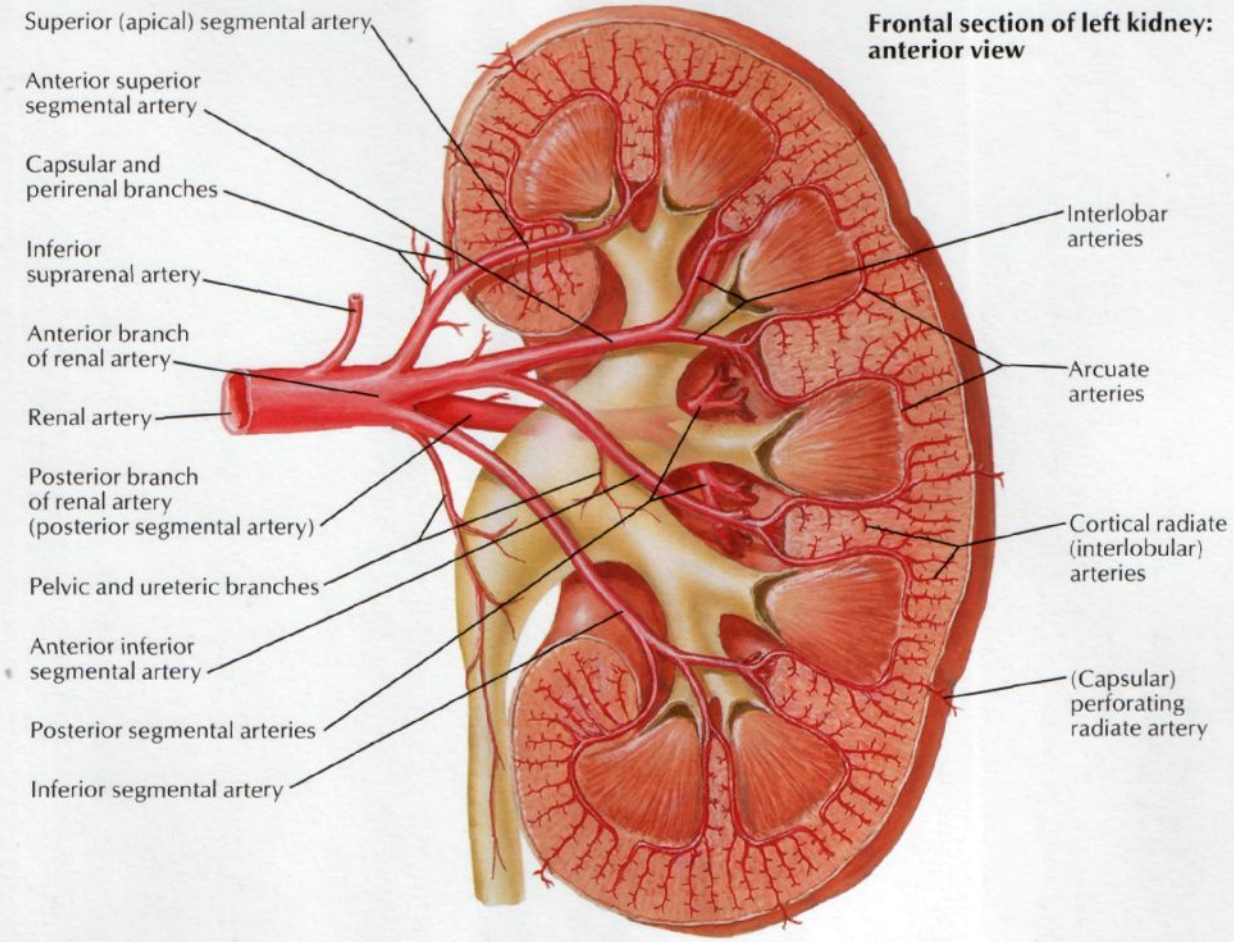

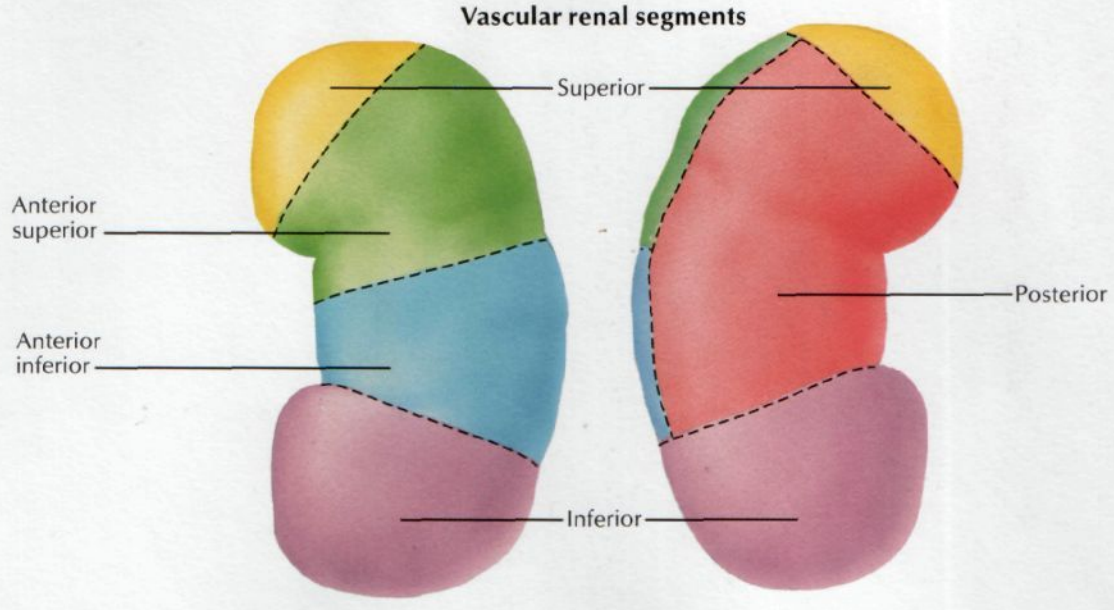

Variations in Renal Artery and Vein

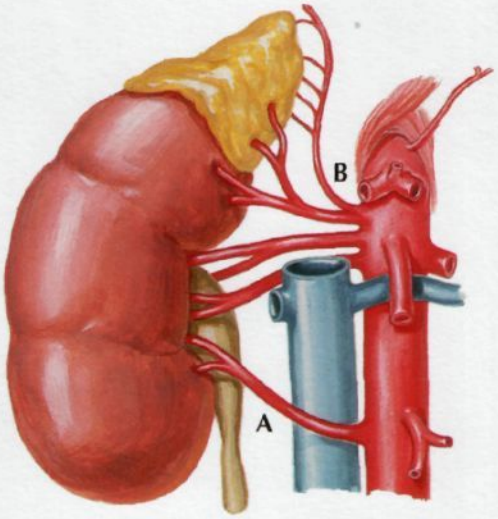

A Low accessory right renal artery may pass anterior to inferior vena cava instead of posterior to it

B Inferior phrenic artery with superior suprarenal arteries may arise from renal artery (middle suprarenal artery absent)

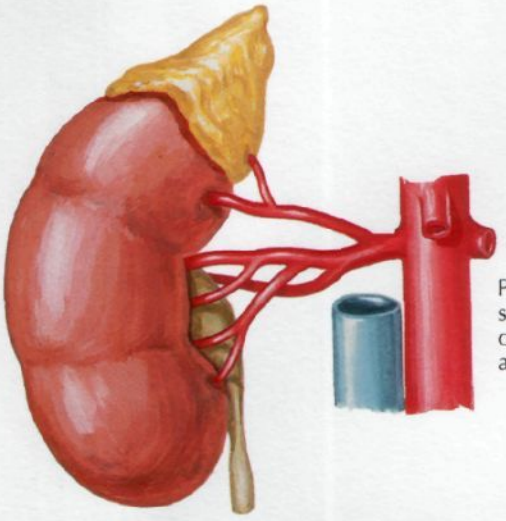

Proximal subdivision of renal artery

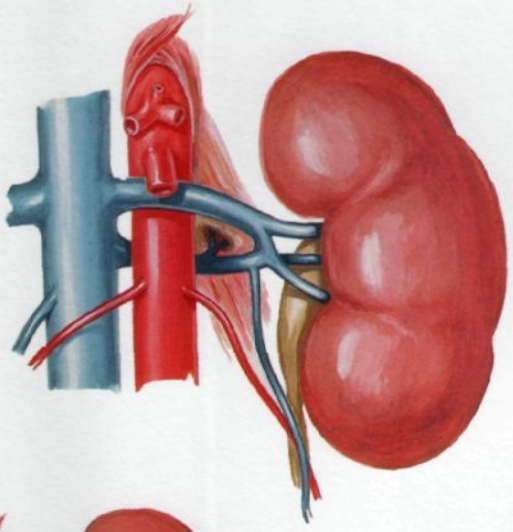

Double left renal vein may form ring around abdominal aorta

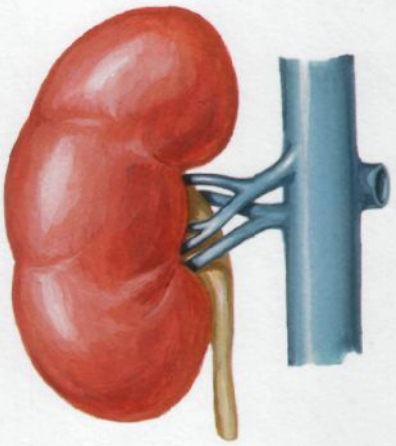

Multiple renal veins

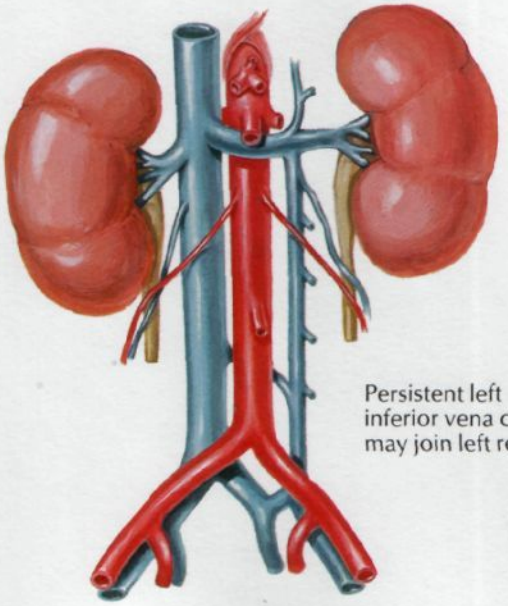

Persistent left inferior vena cava may join left renal vein

F. Netter M.D.
©IGN

Nephron and Collecting Tubule: Schema

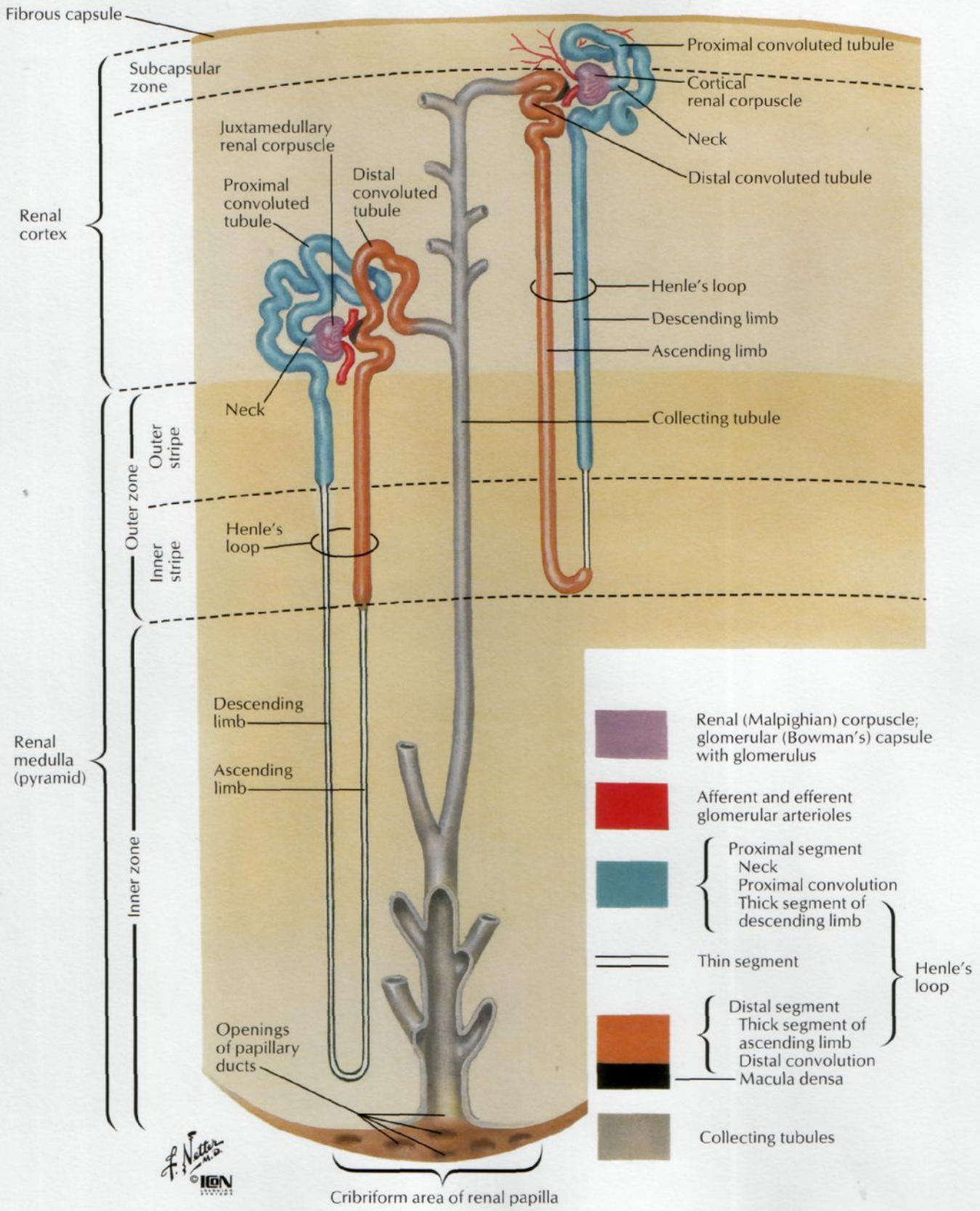

Blood Vessels in Parenchyma of Kidney: Schema

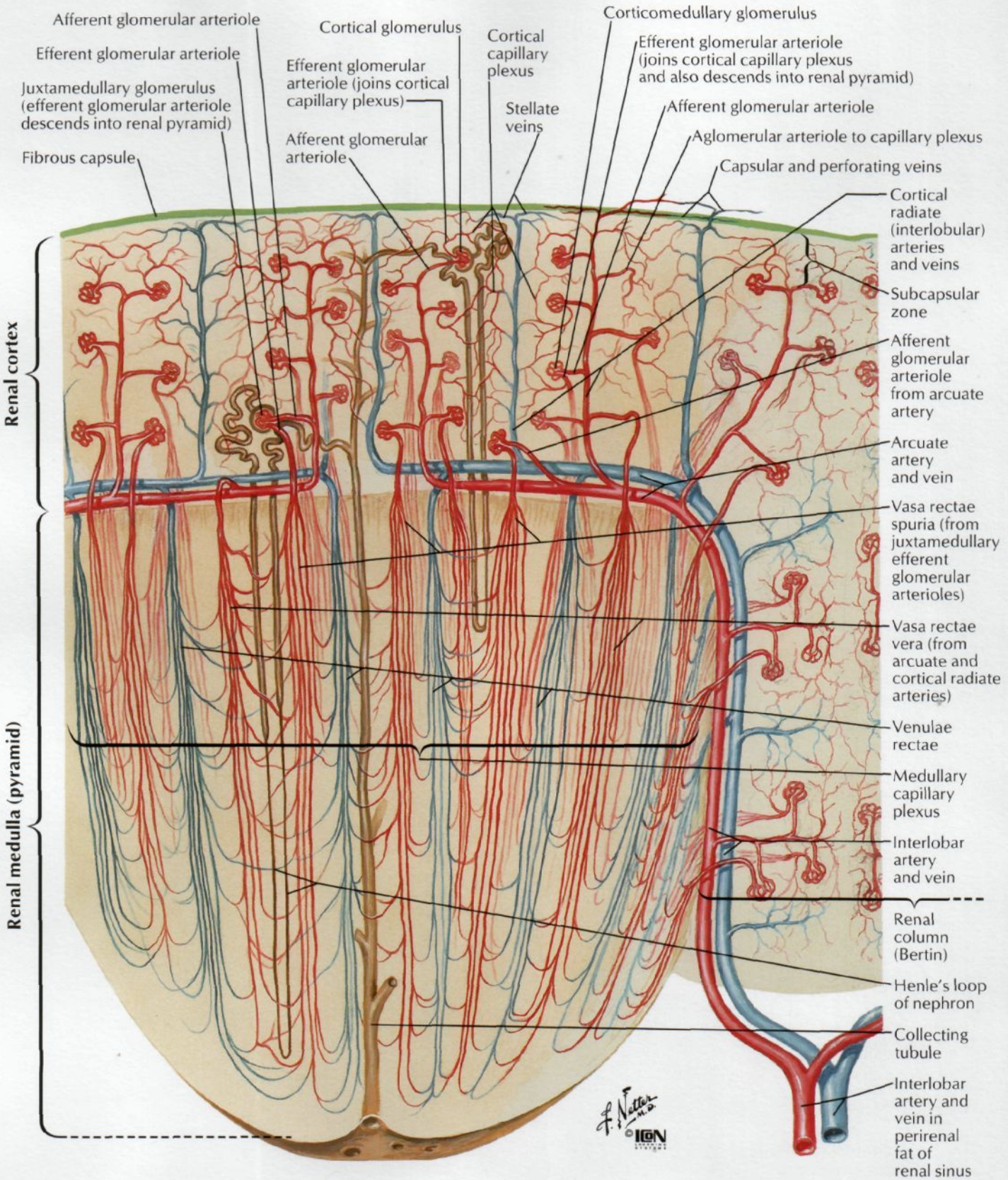

Ureters

SEE ALSO PLATES 349, 350, 354

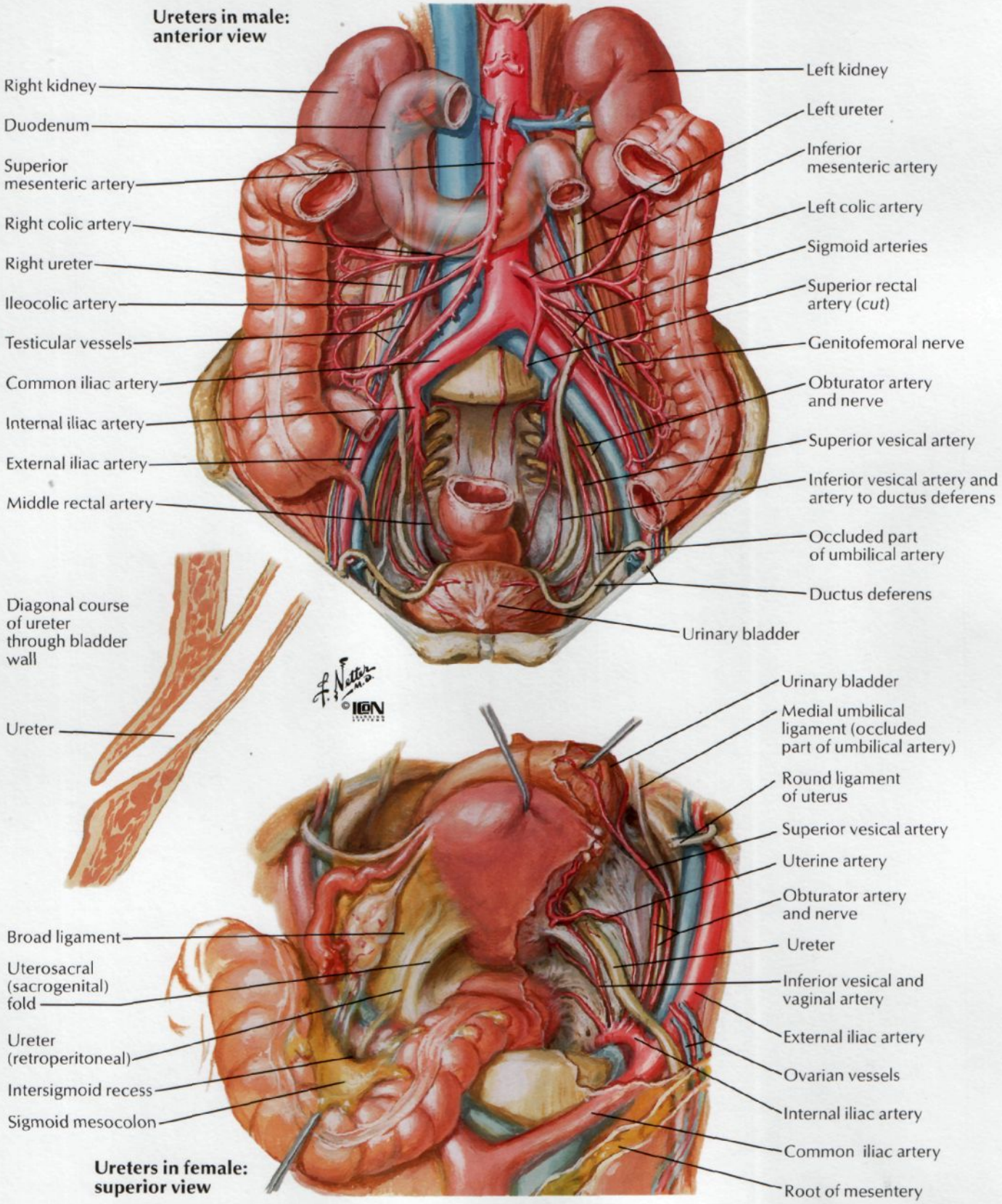

Arteries of Ureters and Urinary Bladder

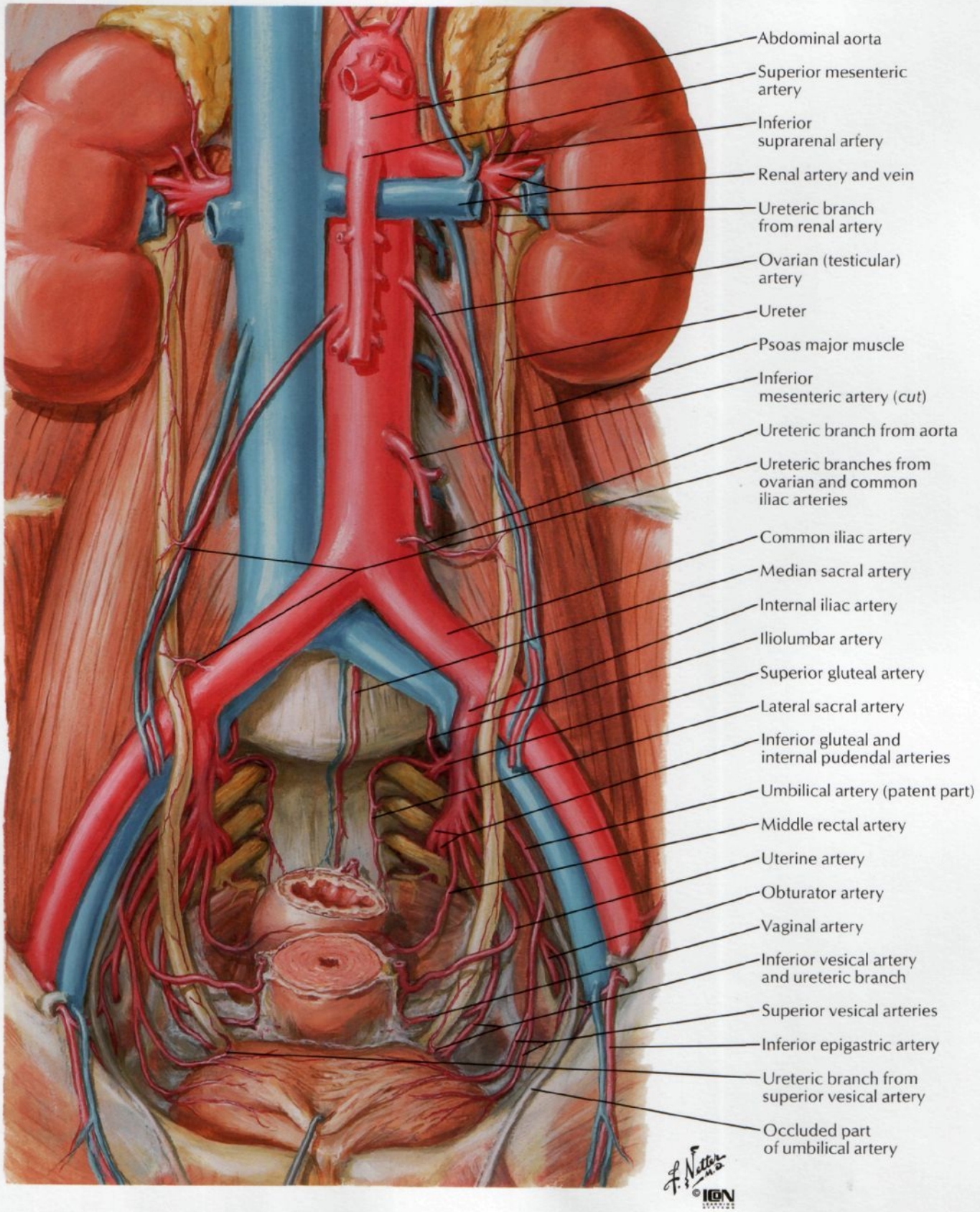

Lymph Vessels and Nodes of Kidneys and Urinary Bladder

SEE ALSO PLATES 386, 388

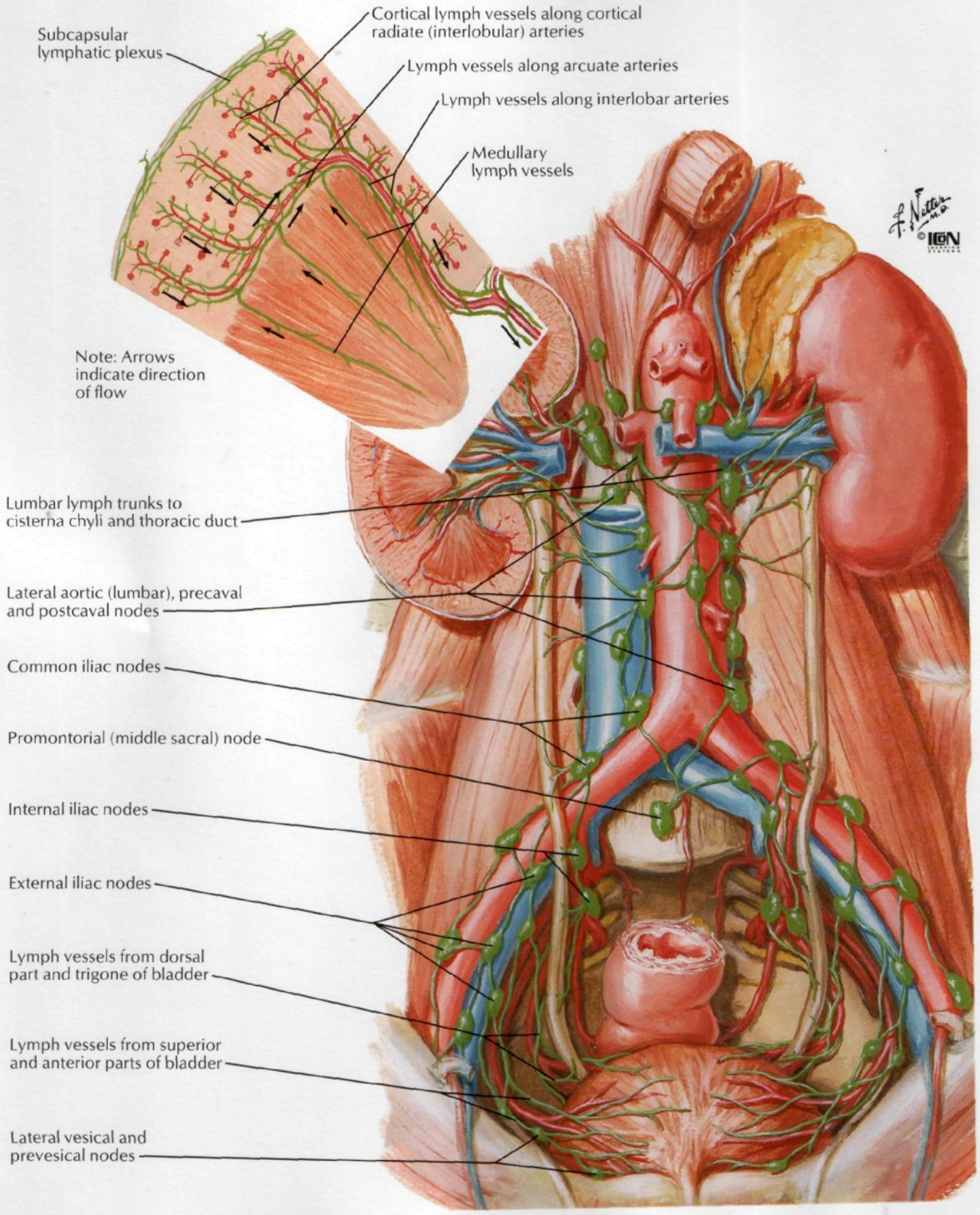

Nerves of Kidneys, Ureters and Urinary Bladder

SEE ALSO PLATE 159

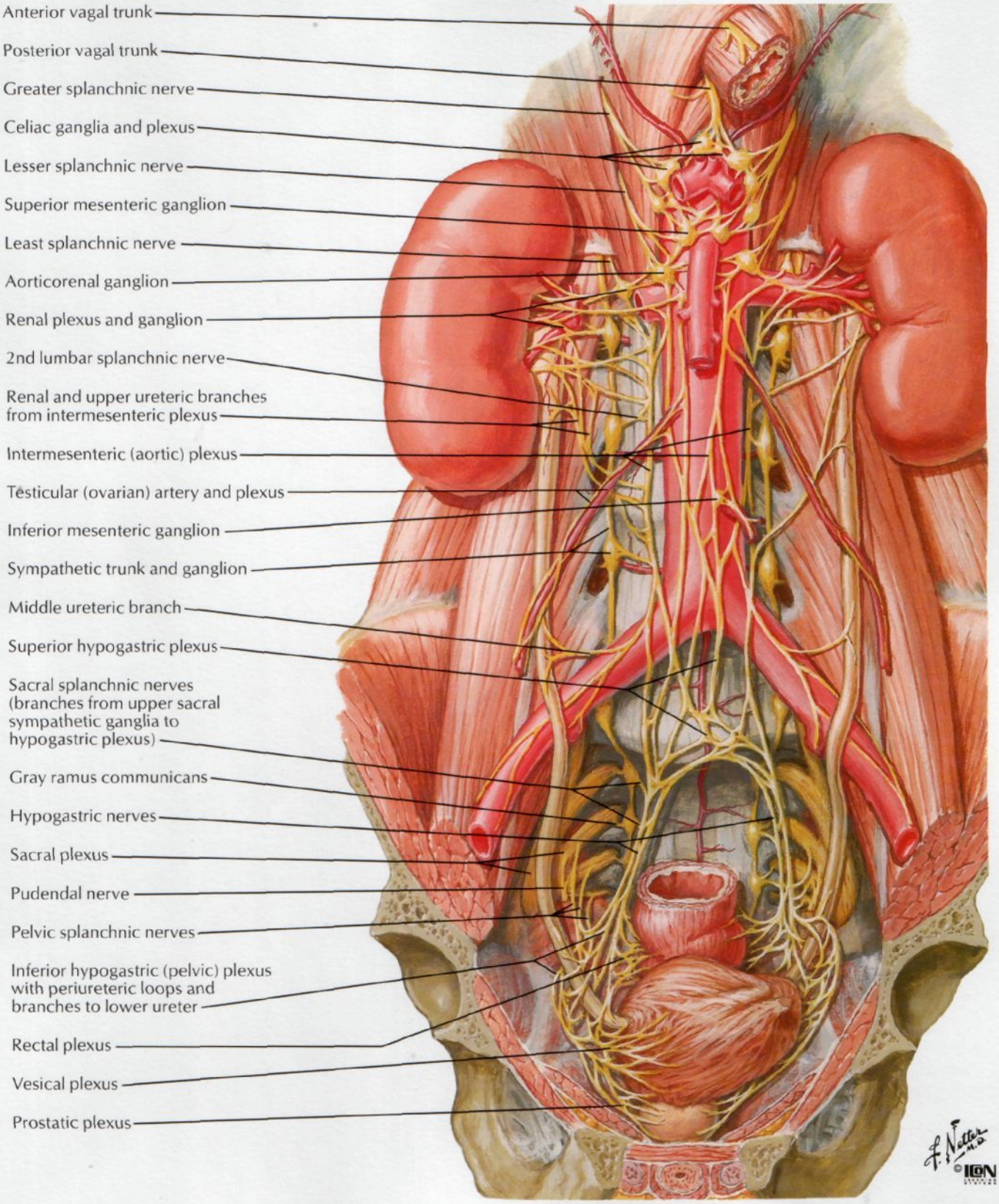

Innervation of Kidneys and Upper Ureters: Schema

SEE ALSO PLATES 160, 397

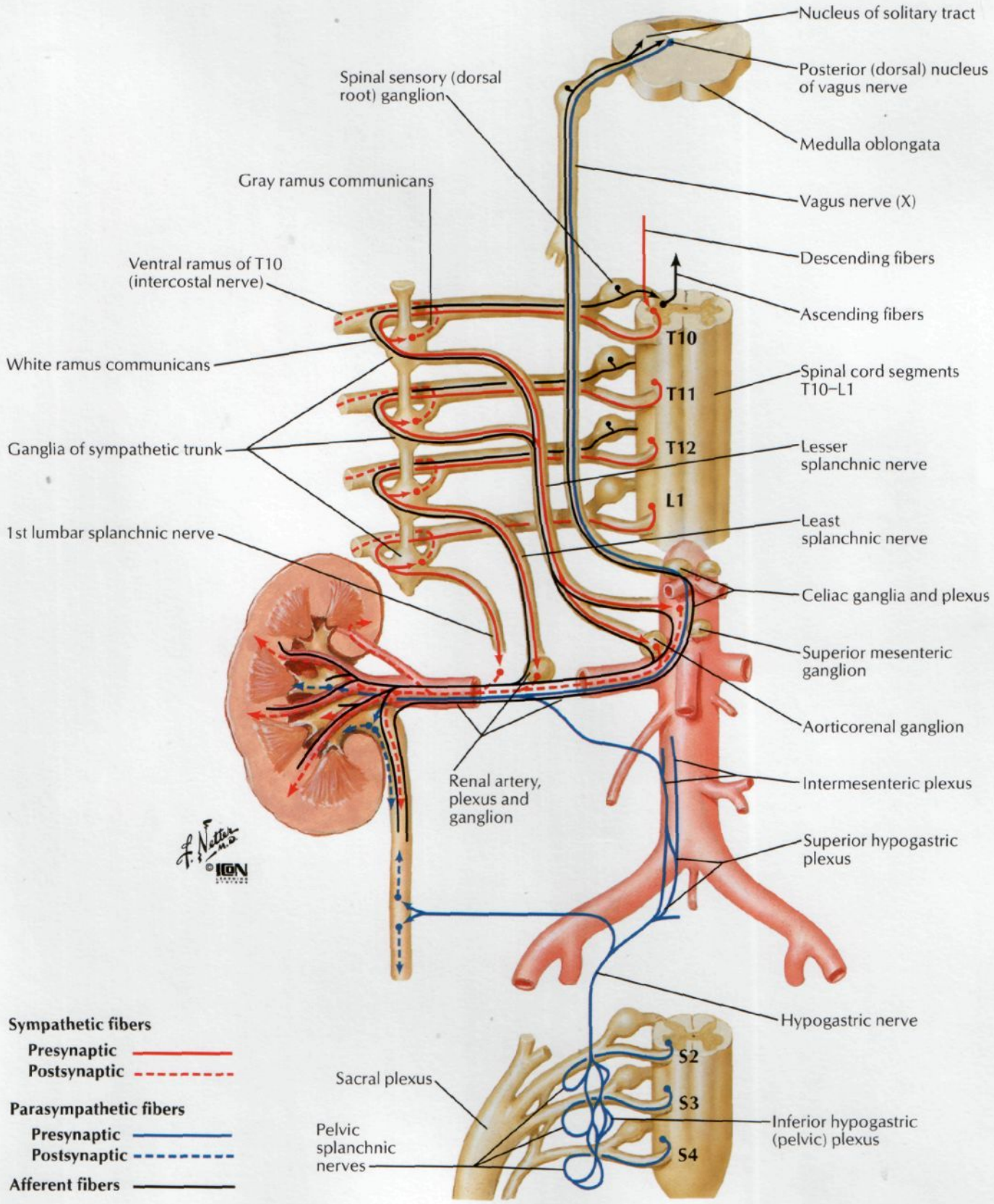

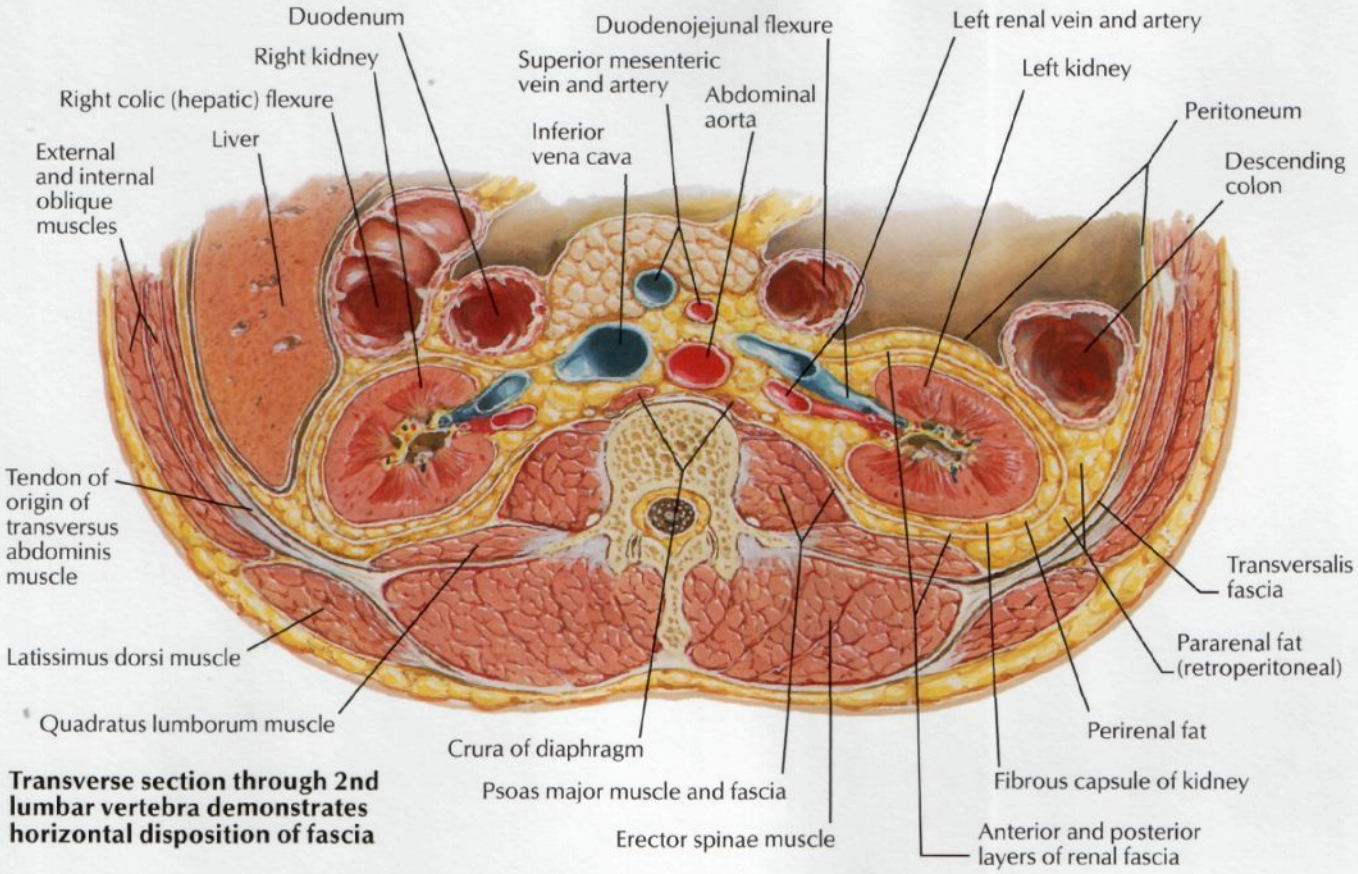

Transverse section through 2nd lumbar vertebra demonstrates horizontal disposition of fascia

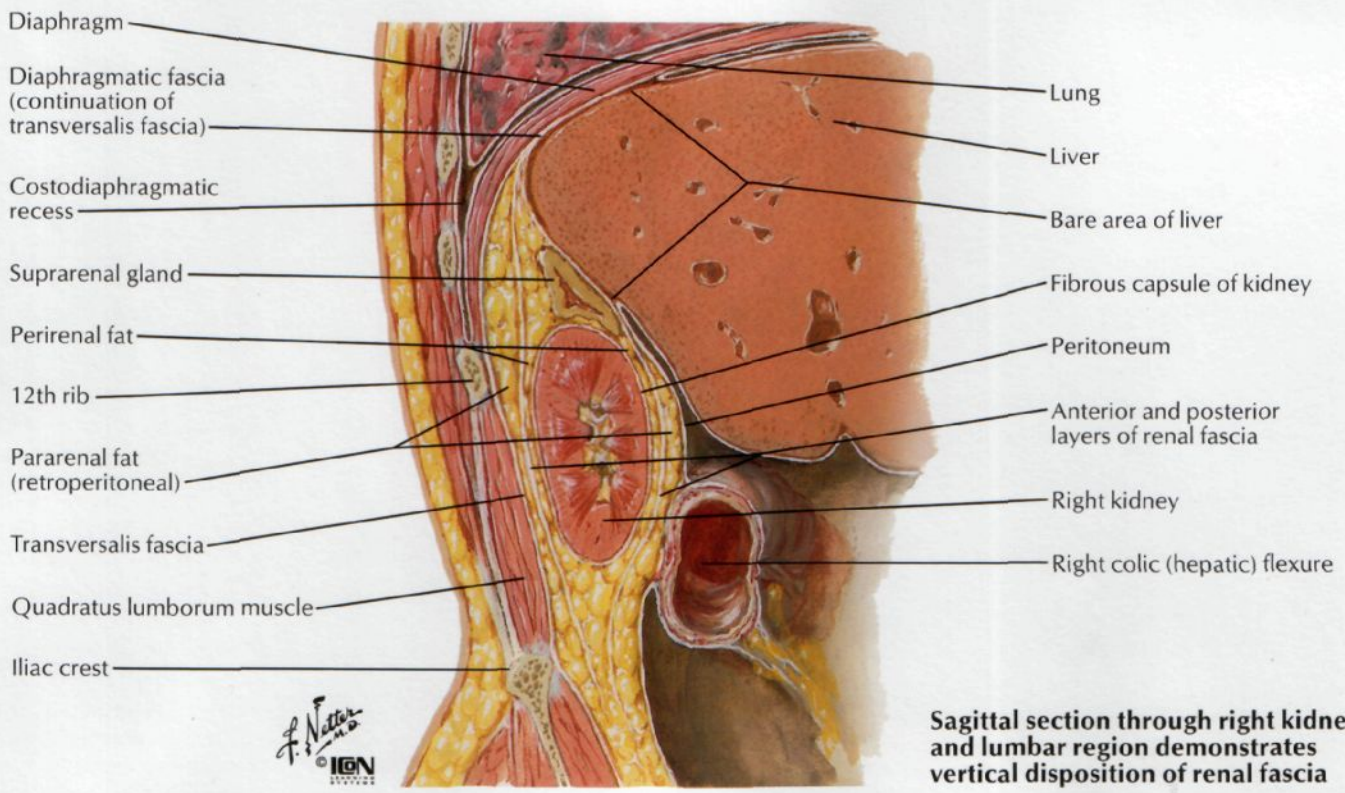

Sagittal section through right kidney and lumbar region demonstrates vertical disposition of renal fascia

Arteries and Veins of Suprarenal Glands In Situ

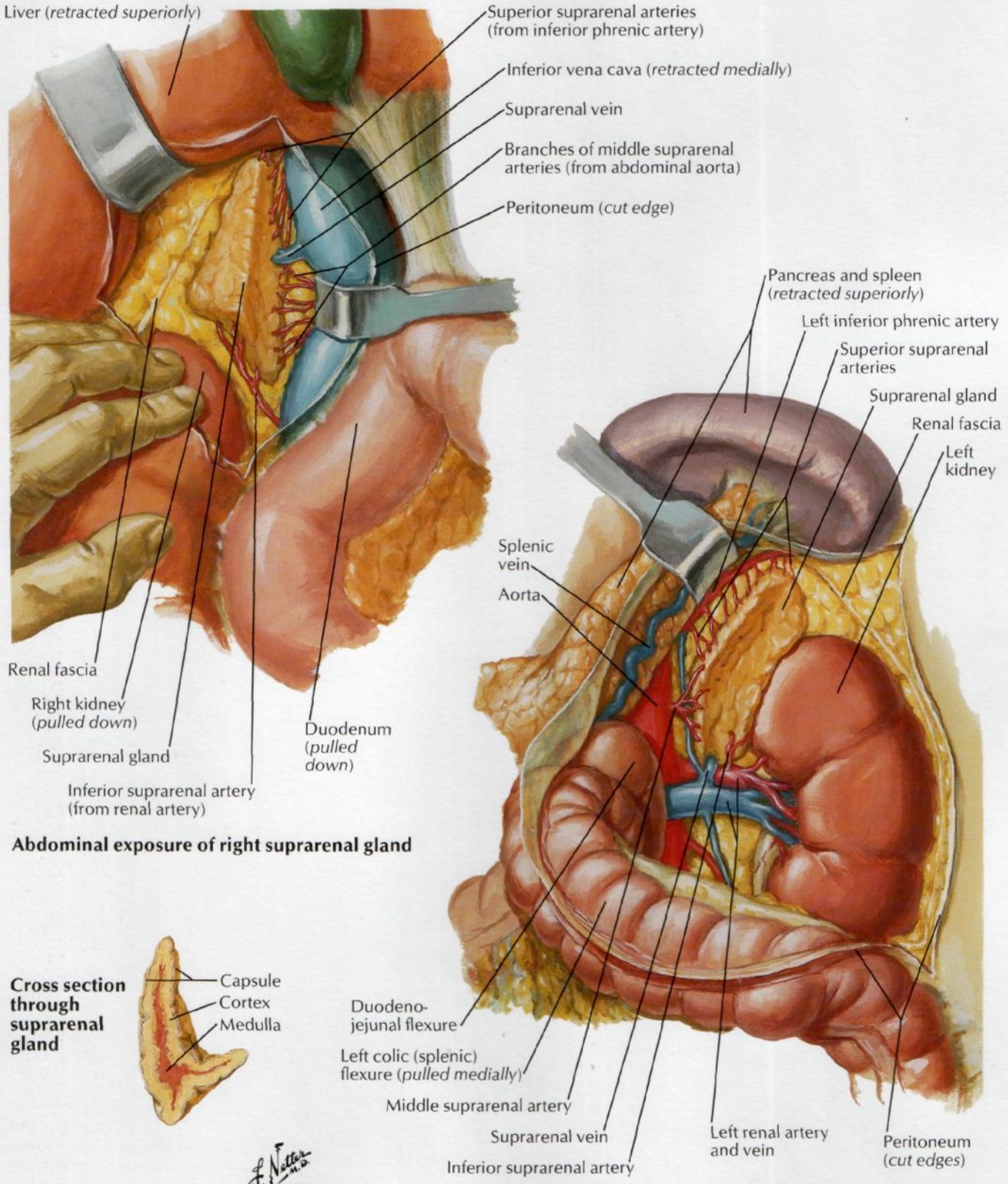

Abdominal exposure of right suprarenal gland

Abdominal exposure of left suprarenal gland

Cross section through suprarenal gland

F. Netter M.D.
©ICON

Nerves of Suprarenal Glands: Dissection and Schema

SEE ALSO PLATES 159, 160

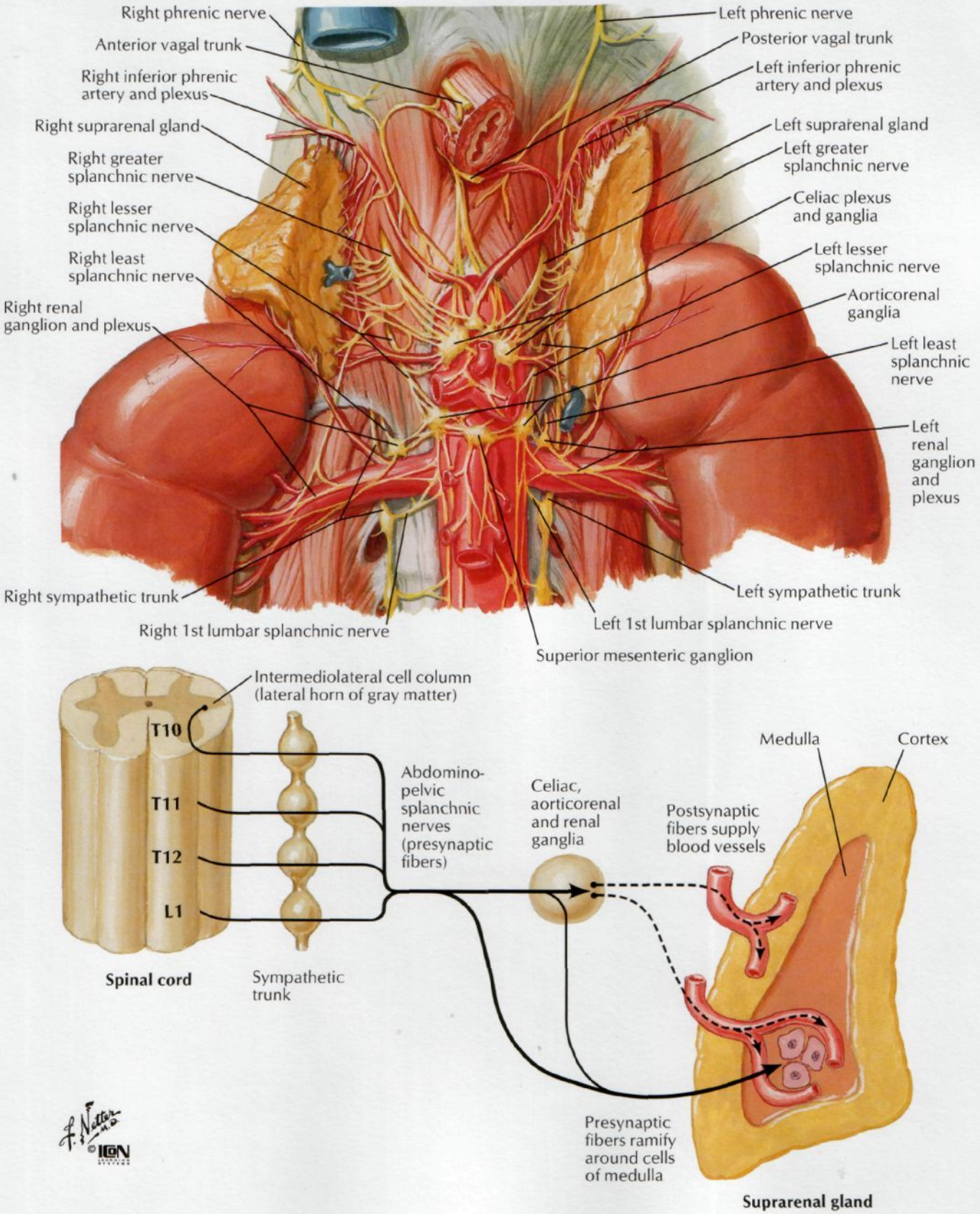

F. Netter M.D.
©IGN

Abdominal Wall and Viscera: Median (Sagittal) Section

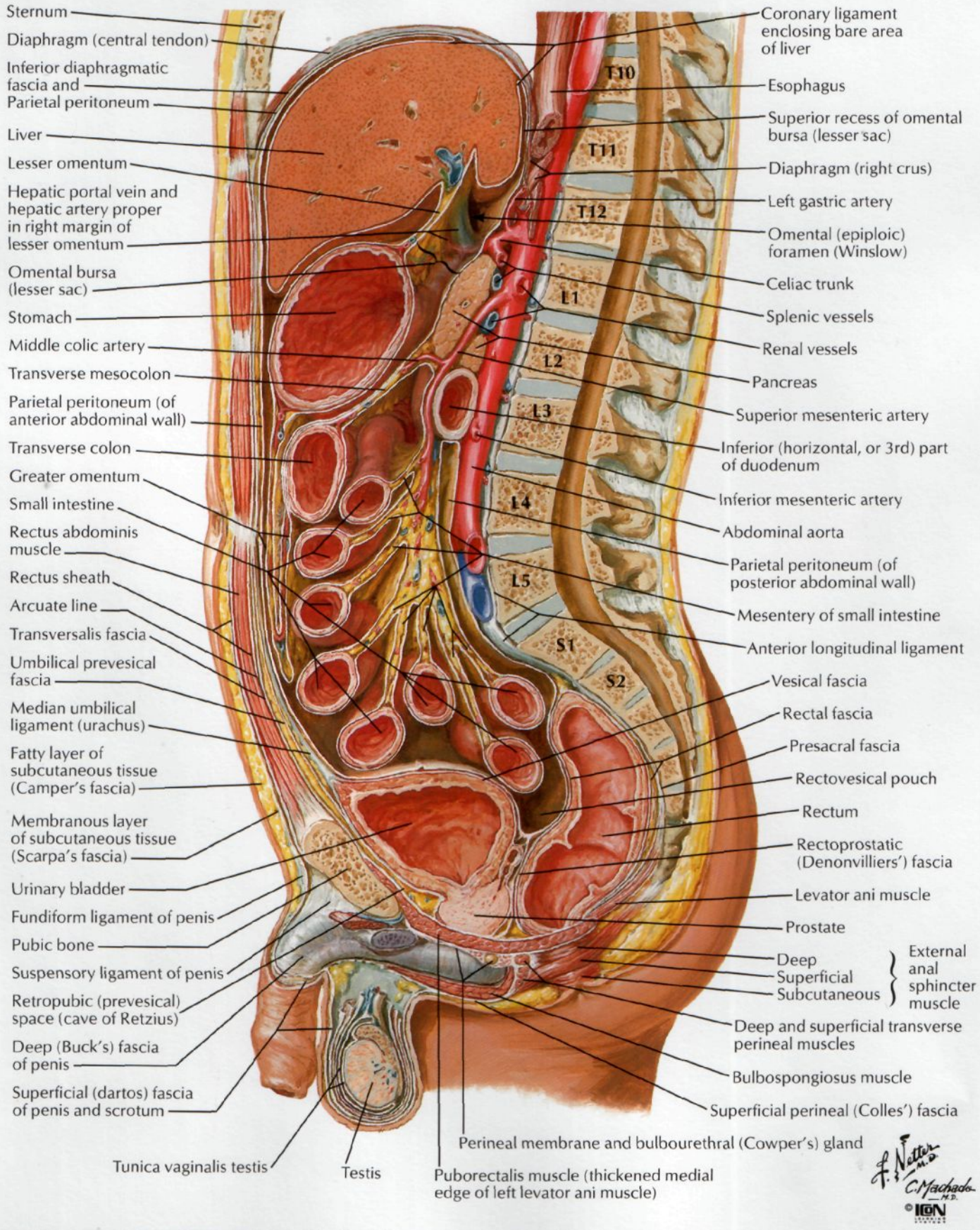

Schematic Cross Section of Abdomen at T12

SEE ALSO PLATES 534–537

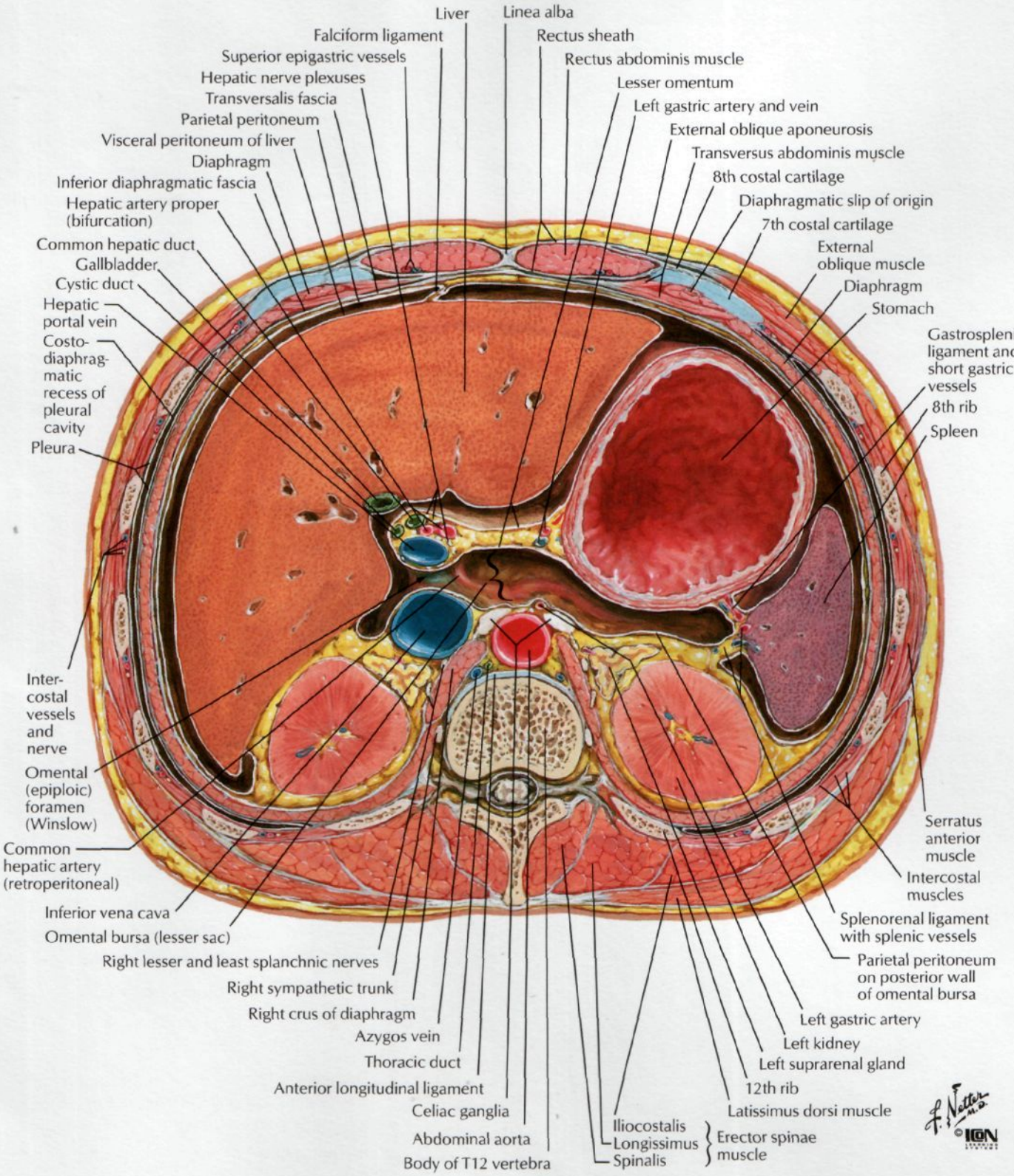

Schematic Cross Section of Abdomen at L3, 4

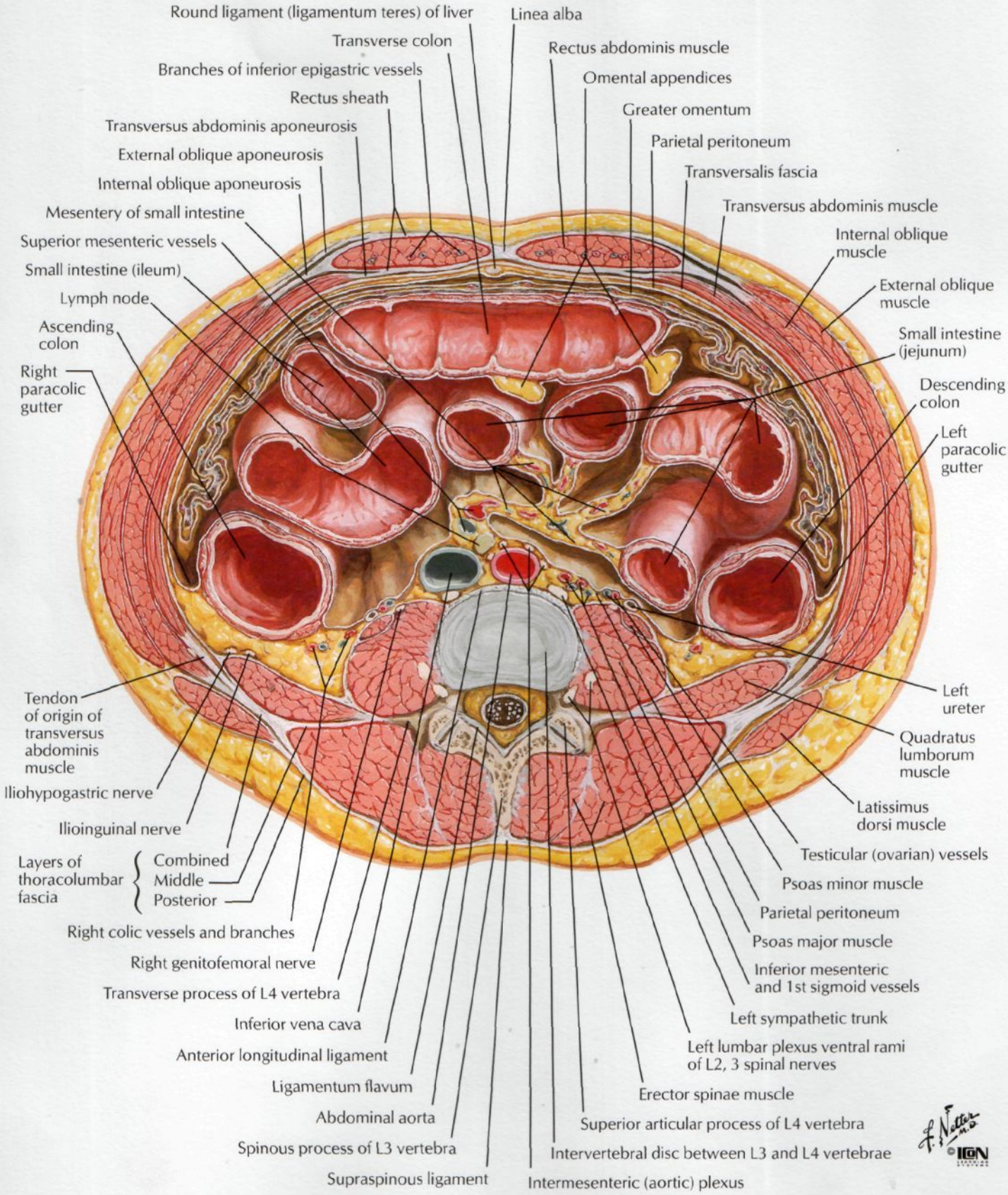

Series of abdominal axial CT images from superior (A) to inferior (D)

A

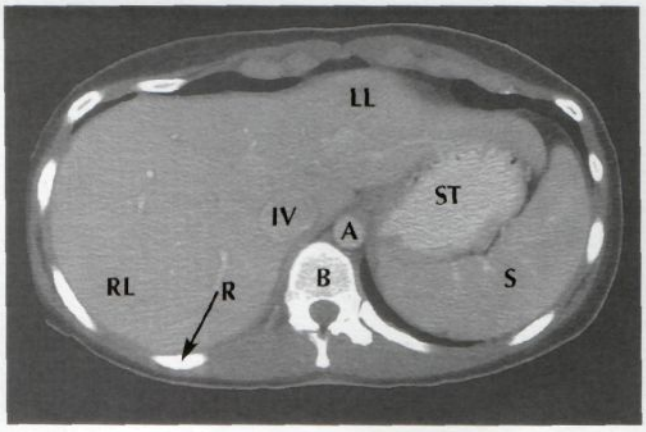

B

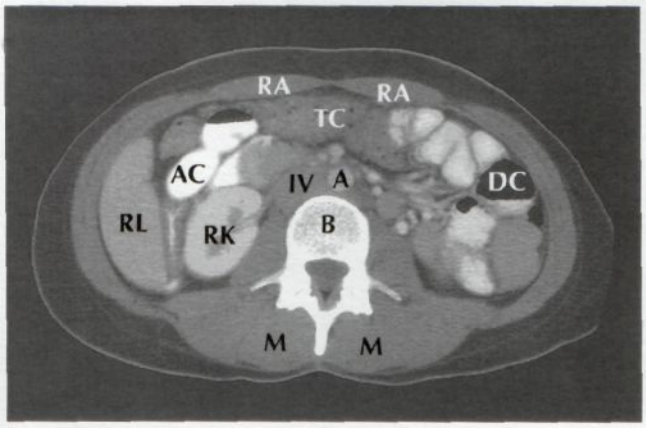

C

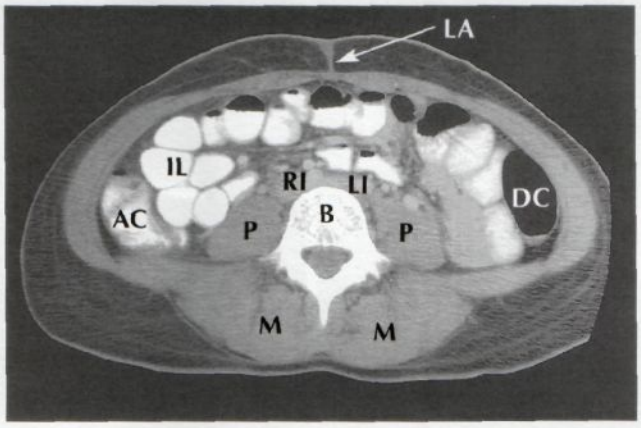

D

A	Aorta
AC	Ascending colon
B	Body of vertebra
DC	Descending colon
IL	Ileum
IV	Inferior vena cava
LA	Linea alba
LI	Left common iliac artery
LK	Left kidney
LL	Left lobe of liver
M	Deep back muscles
P	Psoas muscle
R	Rib
RA	Rectus abdominis muscle
RI	Right common iliac artery
RL	Right lobe of liver
S	Spleen
ST	Stomach
TC	Transverse colon

Section V

PELVIS AND PERINEUM

SURFACE ANATOMY
Plate 339
339. Pelvis and Perineum

BONES AND LIGAMENTS
Plates 340–342
340. Bones and Ligaments of Pelvis
341. Bones and Ligaments of Pelvis (*continued*)
342. Sex Differences of Pelvis: Measurements

PELVIC FLOOR AND CONTENTS
Plates 343–353
343. Pelvic Diaphragm: Female
344. Pelvic Diaphragm: Female (*continued*)
345. Pelvic Diaphragm: Male
346. Pelvic Diaphragm: Male (*continued*)
347. Pelvic Viscera and Perineum: Female
348. Pelvic Viscera and Perineum: Male
349. Pelvic Contents: Female
350. Pelvic Contents: Male
351. Endopelvic Fascia and Potential Spaces
352. Urinary Bladder: Orientation and Supports
353. Urinary Bladder: Female and Male

FEMALE STRUCTURES
Plates 354–362
354. Pelvic Viscera: Female
355. Uterus, Vagina and Supporting Structures
356. Uterus and Adnexa
357. Uterus: Age Changes and Muscle Pattern
358. Uterus: Variations in Position
359. Perineum and External Genitalia (Pudendum or Vulva)
360. Perineum (Superficial Dissection)

361. Perineum and Deep Perineum
362. Female Urethra

MALE STRUCTURES
Plates 363–371
363. Perineum and External Genitalia (Superficial Dissection)
364. Perineum and External Genitalia (Deeper Dissection)
365. Penis
366. Perineal Spaces
367. Prostate and Seminal Vesicles
368. Urethra
369. Descent of Testis
370. Scrotum and Contents
371. Testis, Epididymis and Ductus Deferens

RECTUM
Plates 372–377
372. Rectum In Situ: Female and Male
373. Ischioanal Fossae
374. Rectum and Anal Canal
375. Anorectal Musculature
376. External Anal Sphincter Muscle: Perineal Views
377. Actual and Potential Perineopelvic Spaces

VASCULATURE
Plates 378–388
378. Arteries of Rectum and Anal Canal
379. Veins of Rectum and Anal Canal
380. Arteries and Veins of Pelvic Organs: Female
381. Arteries and Veins of Testis
382. Arteries and Veins of Pelvis: Female
383. Arteries and Veins of Pelvis: Male
384. Arteries and Veins of Perineum and Uterus
385. Arteries and Veins of Perineum: Male
386. Lymph Vessels and Nodes of Pelvis and Genitalia: Female
387. Lymph Vessels and Nodes of Perineum: Female
388. Lymph Vessels and Nodes of Pelvis and Genitalia: Male

INNERVATION
Plates 389–397
389. Nerves of External Genitalia: Male
390. Nerves of Pelvic Viscera: Male
391. Nerves of Perineum: Male
392. Nerves of Pelvic Viscera: Female
393. Nerves of Perineum and External Genitalia: Female
394. Neuropathways in Parturition
395. Innervation of Female Reproductive Organs: Schema
396. Innervation of Male Reproductive Organs: Schema
397. Innervation of Urinary Bladder and Lower Ureter: Schema

HOMOLOGUES OF GENITALIA
Plates 398–399
398. Homologues of External Genitalia
399. Homologues of Internal Genitalia

REGIONAL SCANS
Plate 400
400. Pelvic Scans: Sagittal MR Images

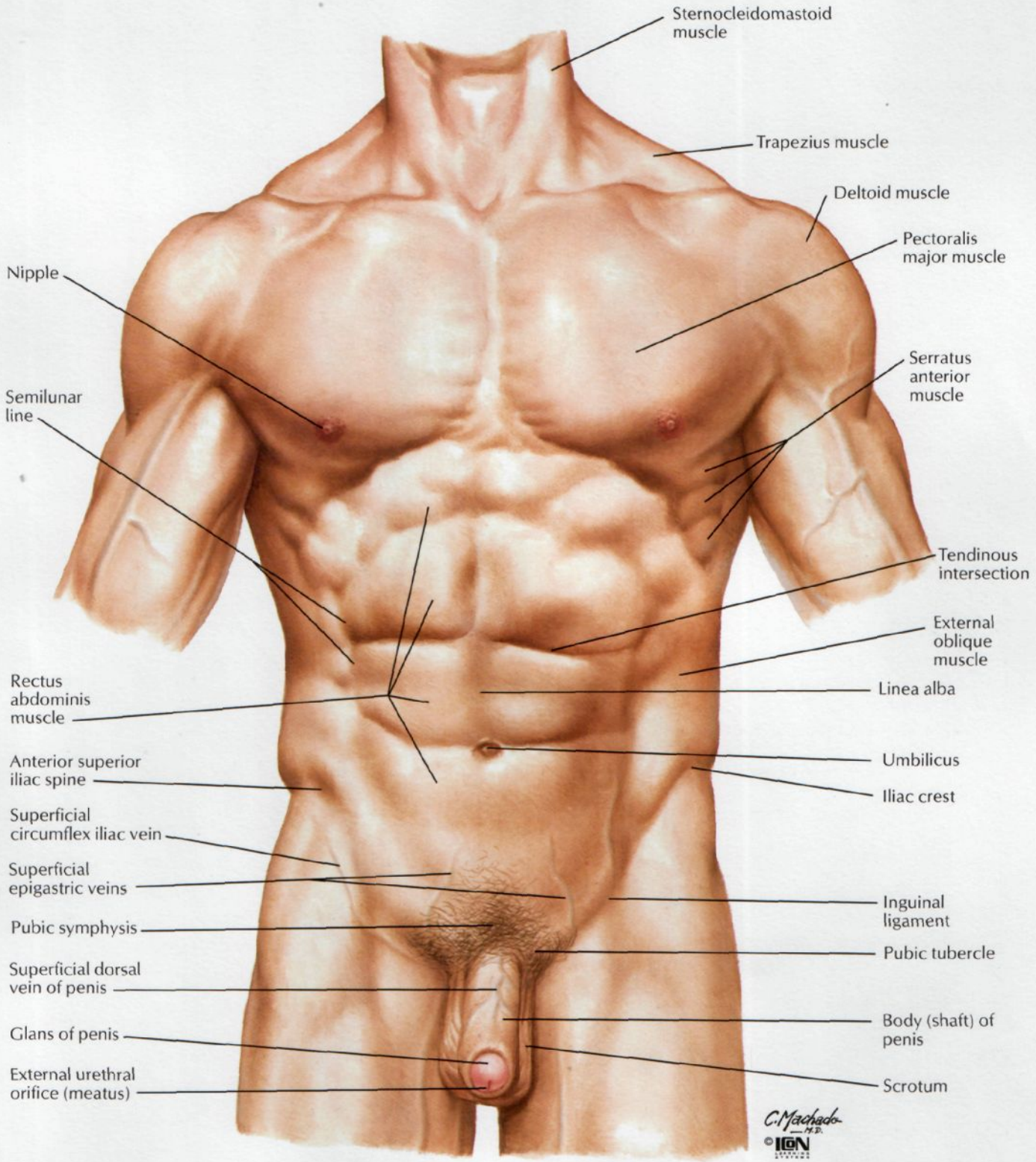
Sternocleidomastoid muscle
Trapezius muscle
Deltoid muscle
Pectoralis major muscle
Nipple
Serratus anterior muscle
Semilunar line
Tendinous intersection
External oblique muscle
Rectus abdominis muscle
Linea alba
Umbilicus
Anterior superior iliac spine
Iliac crest
Superficial circumflex iliac vein
Superficial epigastric veins
Inguinal ligament
Pubic symphysis
Pubic tubercle
Superficial dorsal vein of penis
Body (shaft) of penis
Glans of penis
Scrotum
External urethral orifice (meatus)
C. Machado M.D.
©ICON

Bones and Ligaments of Pelvis

SEE ALSO PLATE 468

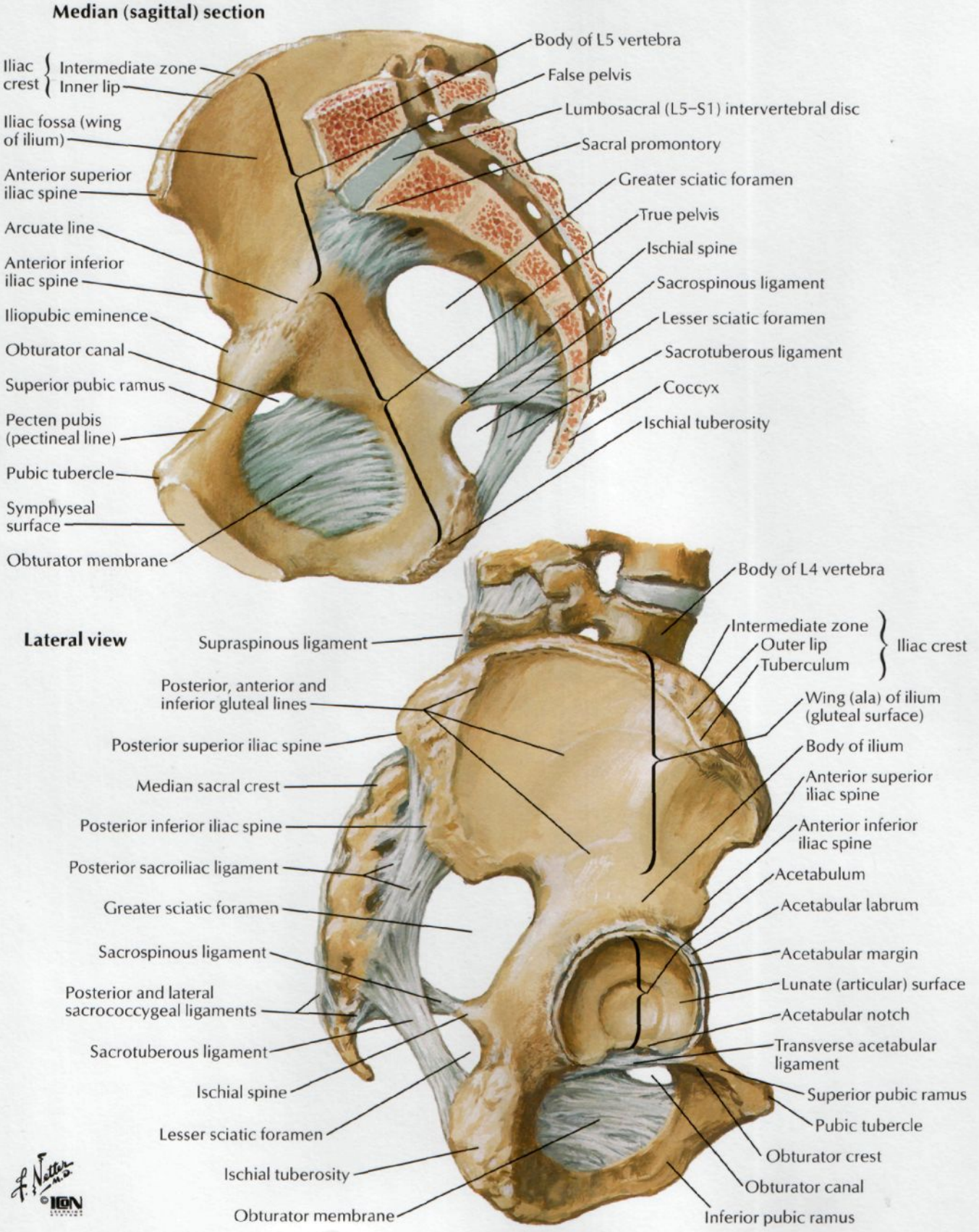

SEE ALSO PLATE 150

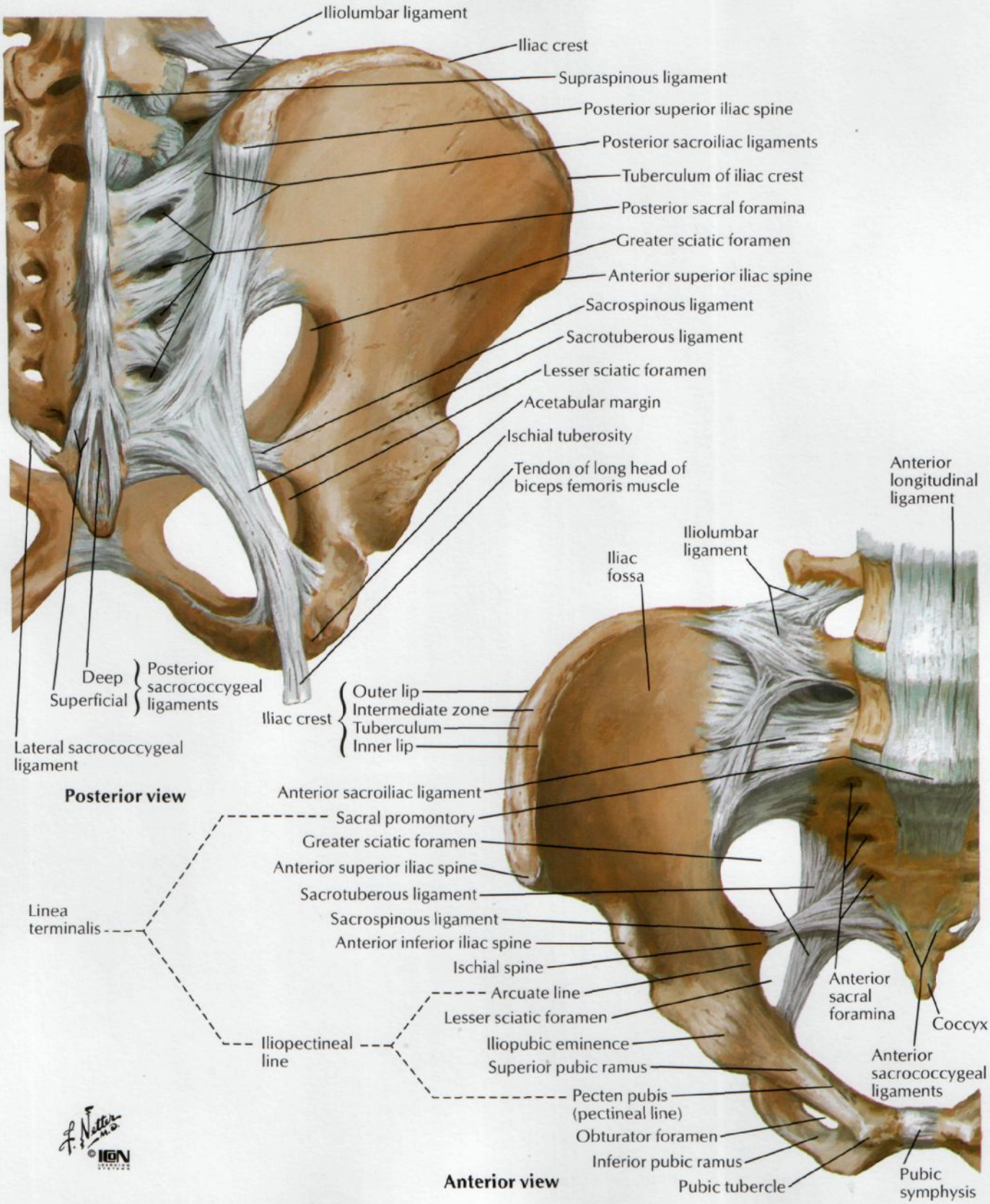

Sex Differences of Pelvis: Measurements

SEE ALSO PLATE 240

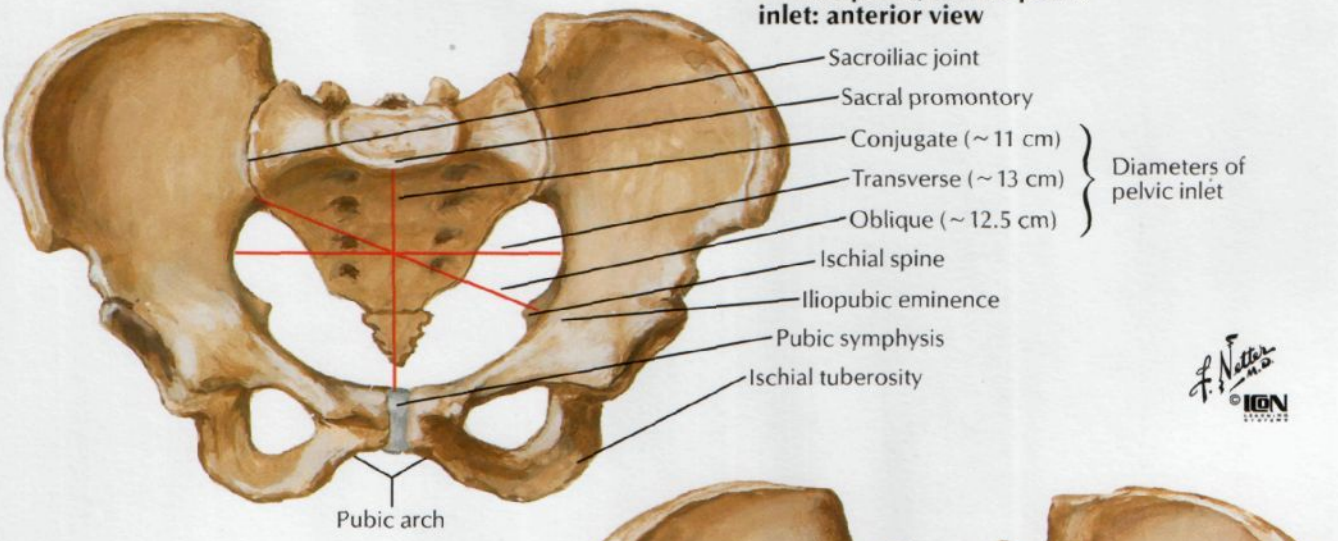

Female pelvis/female pelvic inlet: anterior view

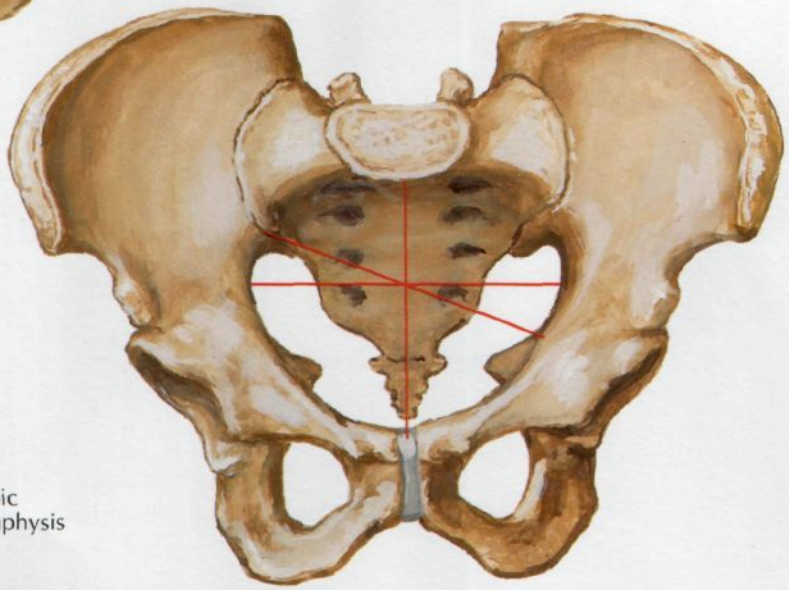

Male pelvis/male pelvic inlet: anterior view

All measurements slightly shorter in relation to body size than in female
Pelvic inlet oriented more antero-posteriorly than in female, where it tends to be transversely oval
Pubic symphysis deeper (taller)
Pubic arch (subpubic angle) narrower
Ischial tuberosities less far apart
Iliac wings less flared

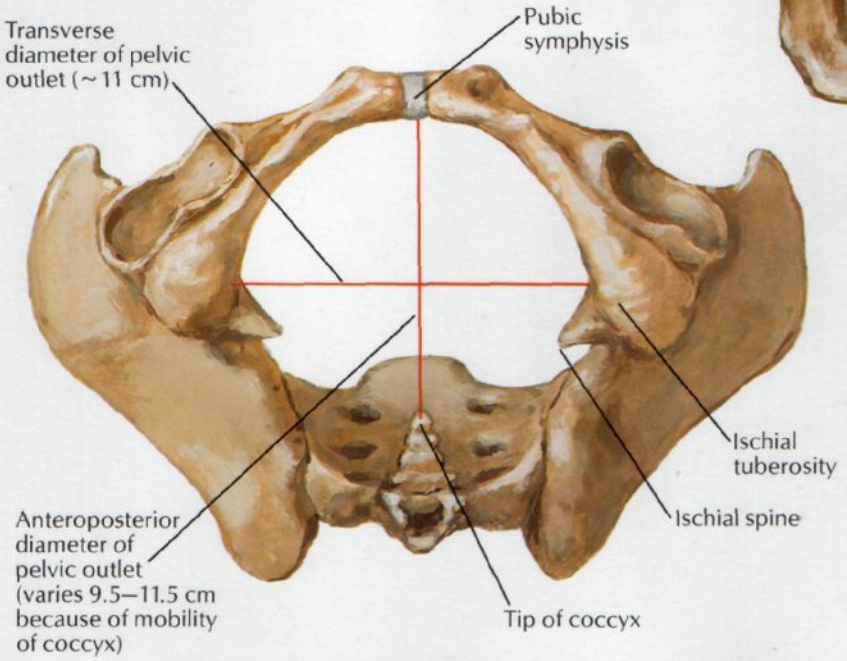

Female pelvis/female pelvic outlet: inferior view

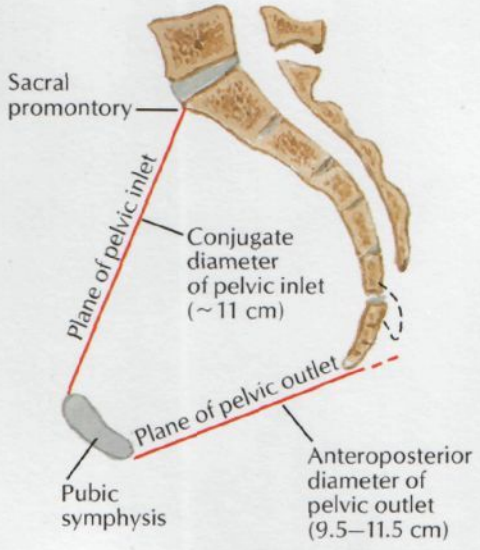

Female: sagittal section

SEE ALSO PLATES 255, 353, 355, 373

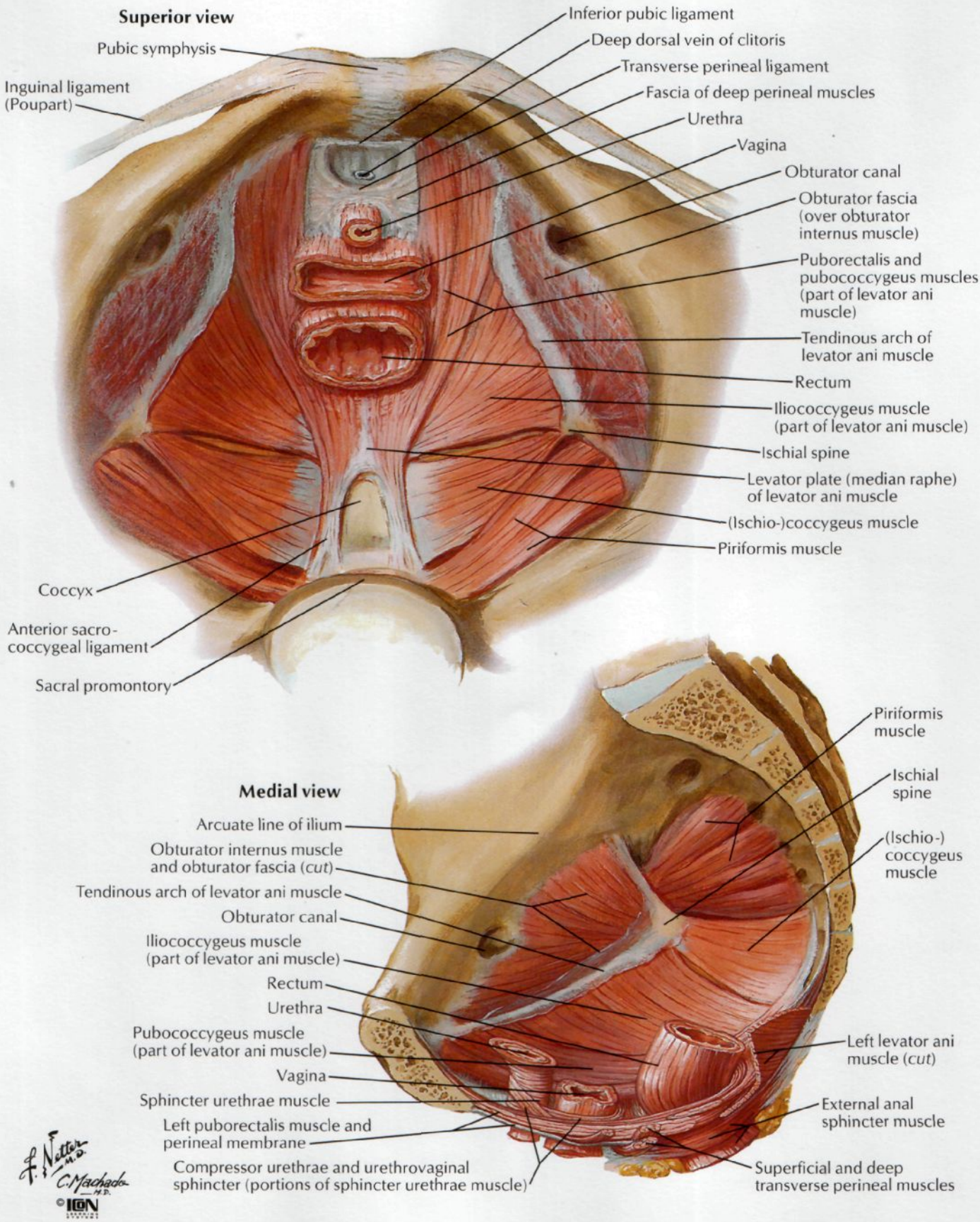

Pelvic Diaphragm: Female (continued)

FOR UROGENITAL DIAPHRAGM SEE PLATE 361

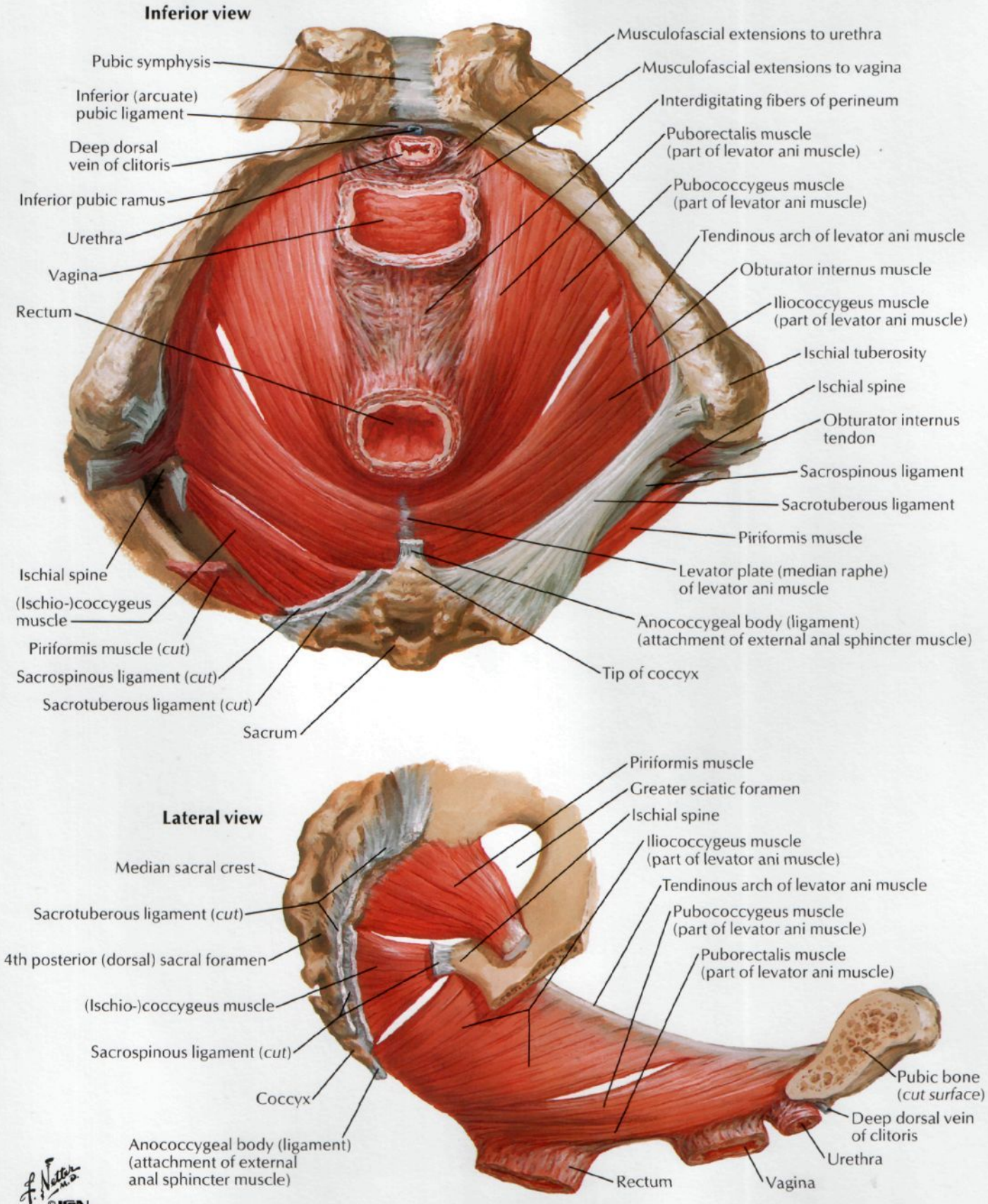

©IGN

SEE ALSO PLATES 255, 353, 373

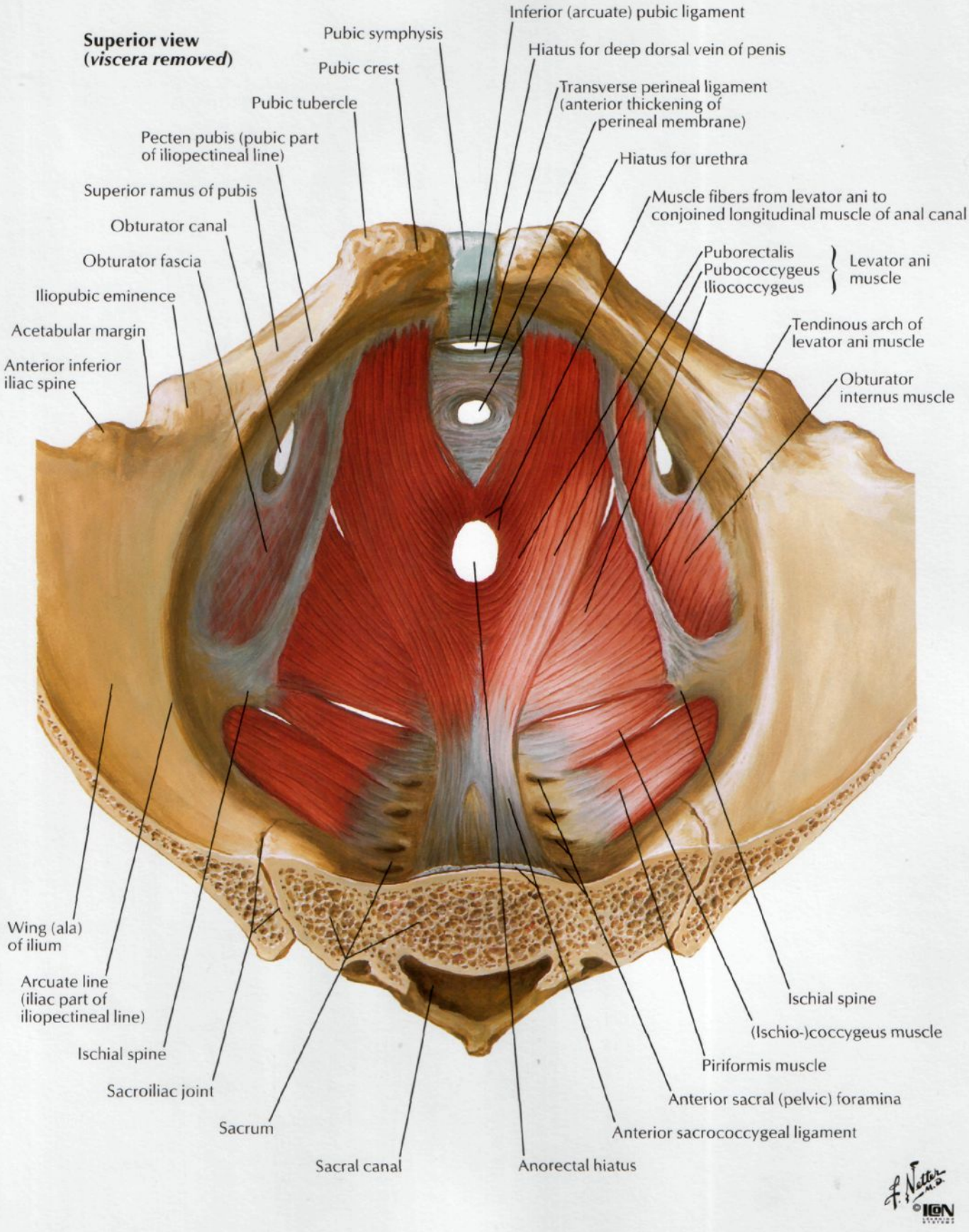

Pelvic Diaphragm: Male (continued)

FOR UROGENITAL DIAPHRAGM SEE PLATE 366

Inferior view

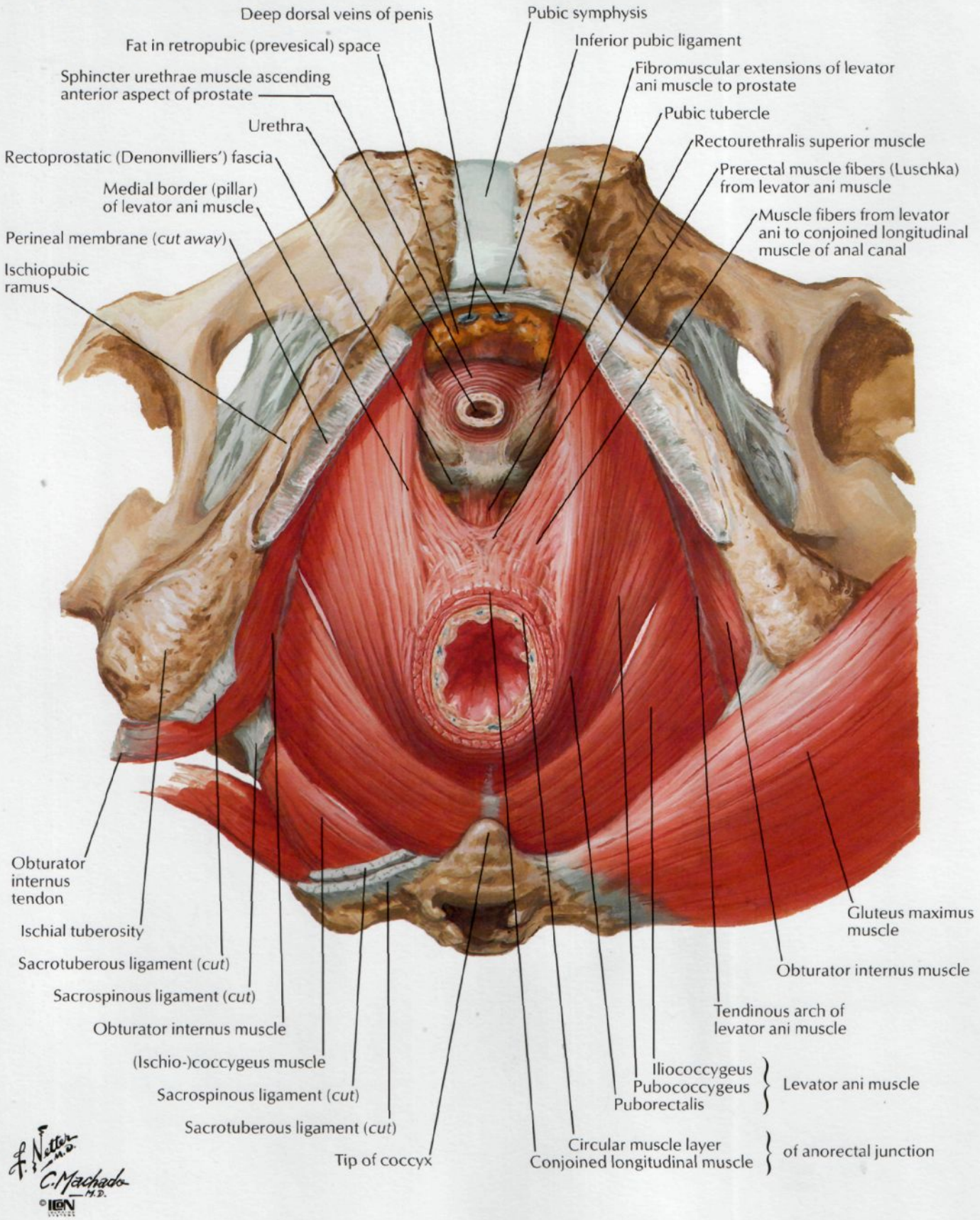

F. Netter, M.D.
C. Machado, M.D.
©ICON

Median (sagittal) section

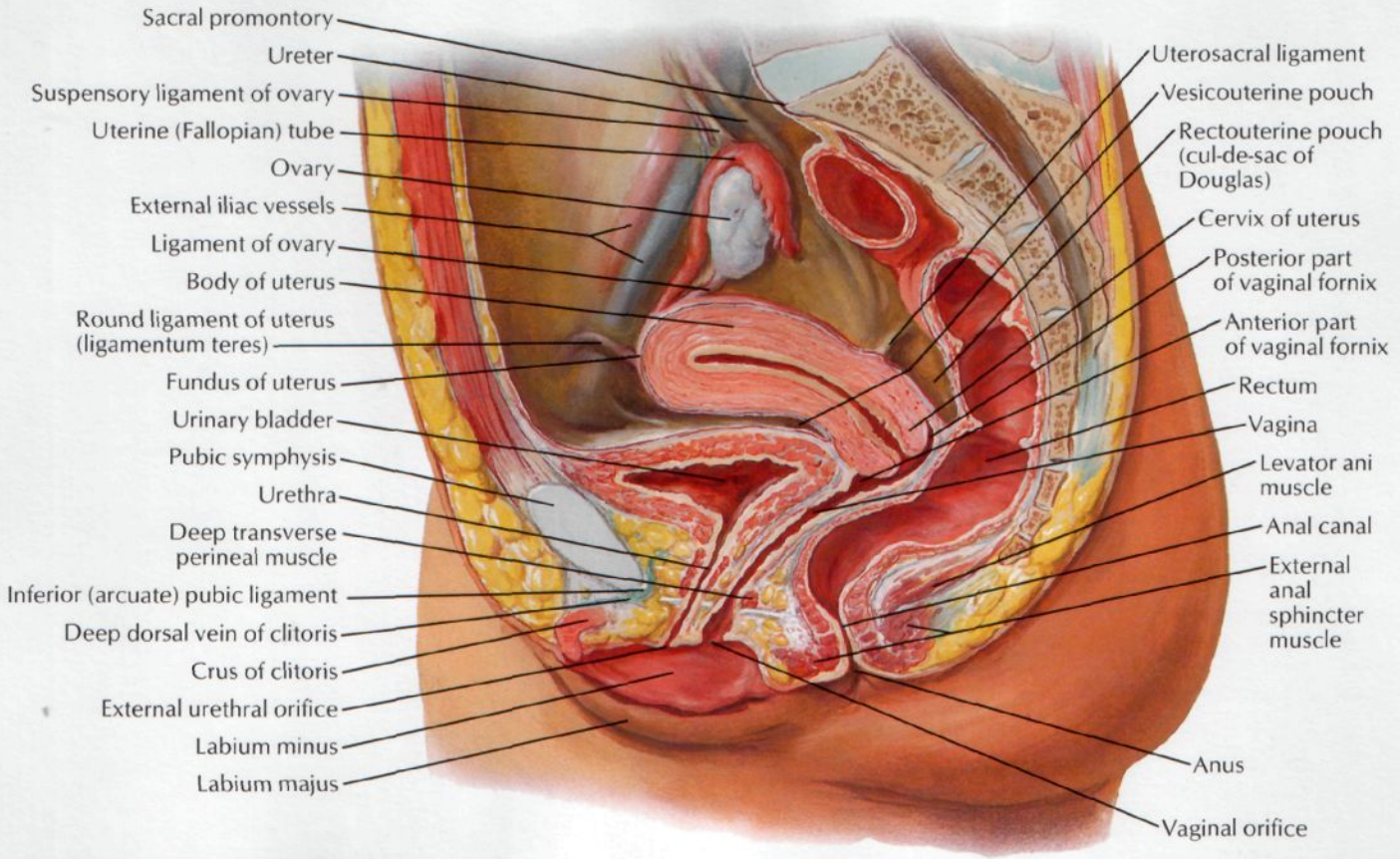

Paramedian (sagittal) dissection

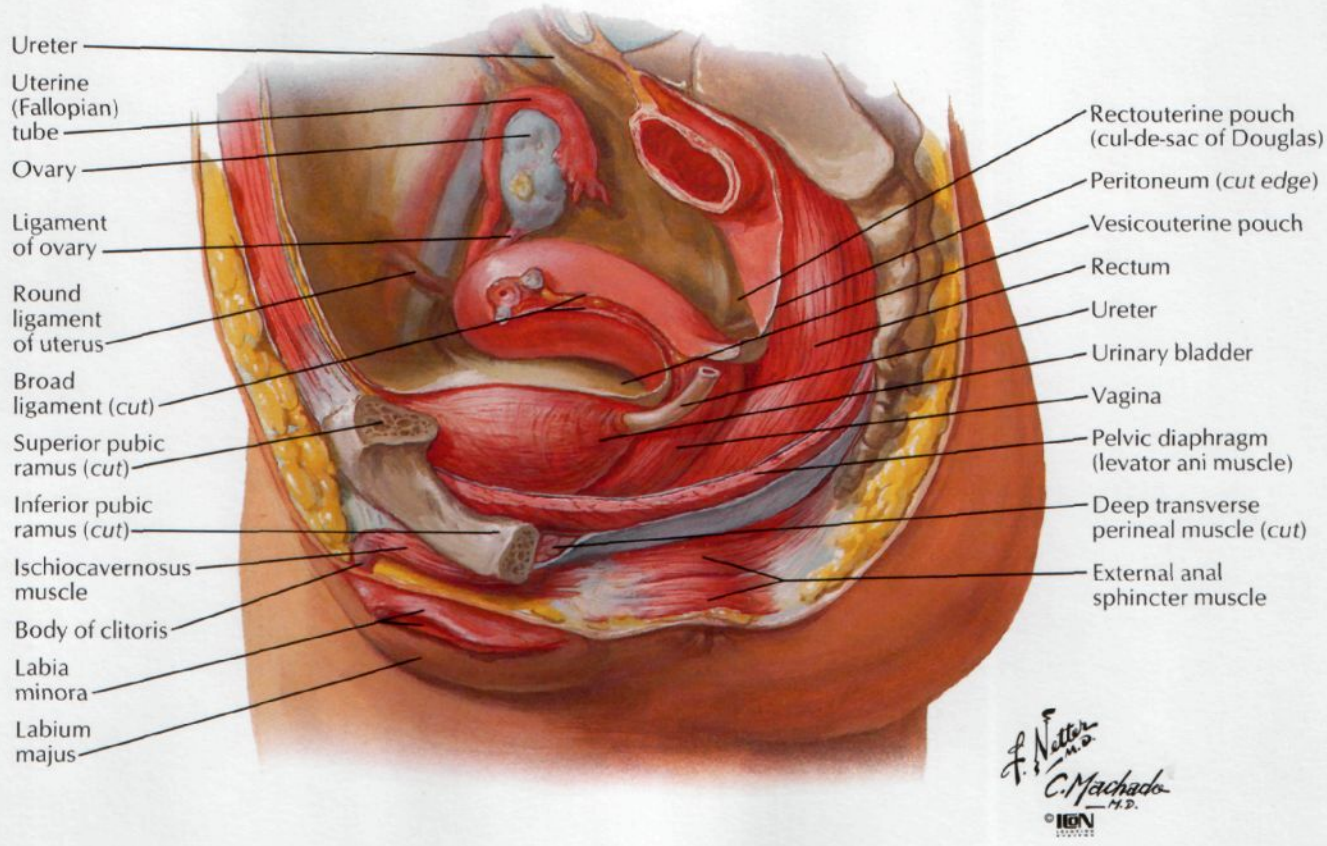

Pelvic Viscera and Perineum: Male

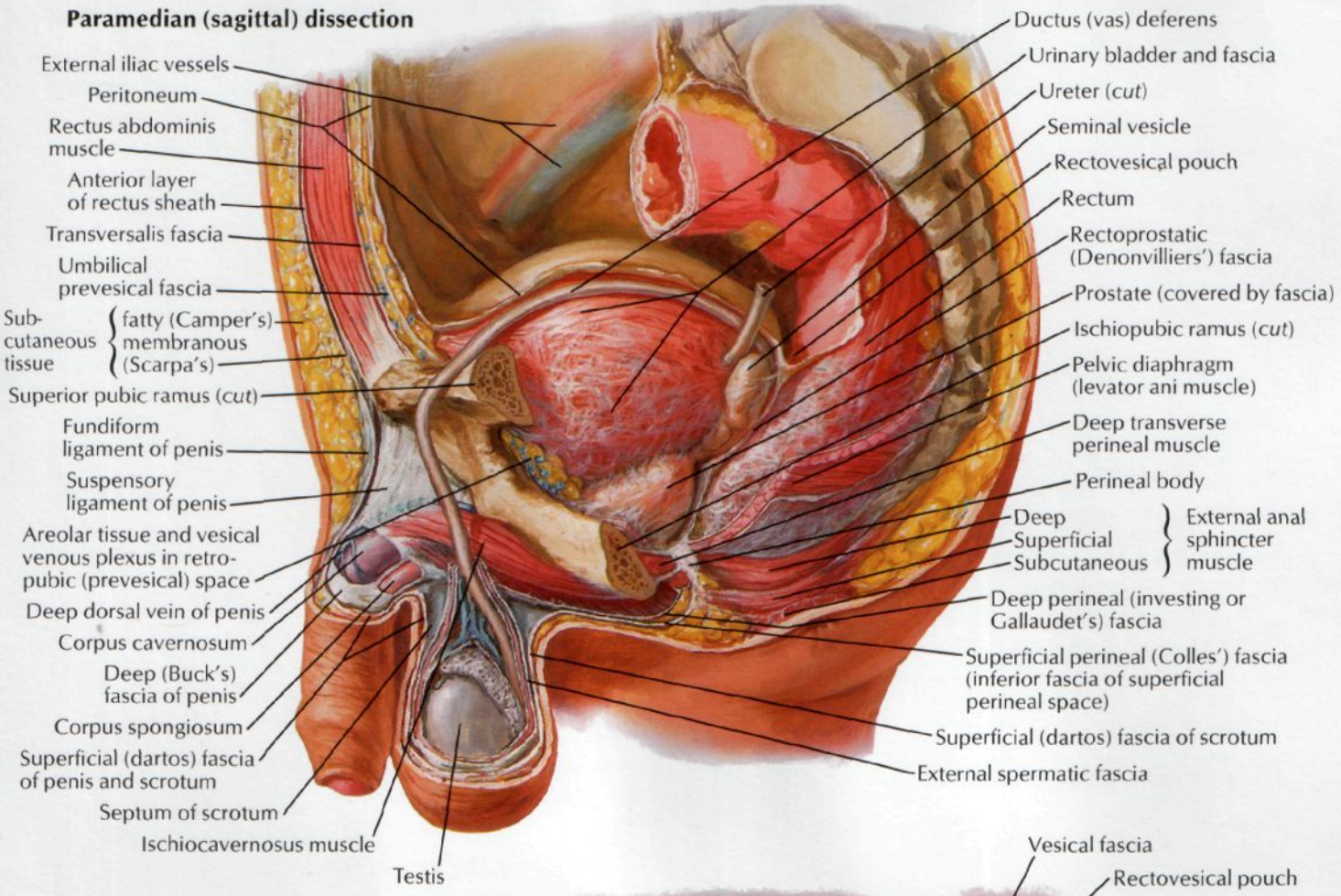

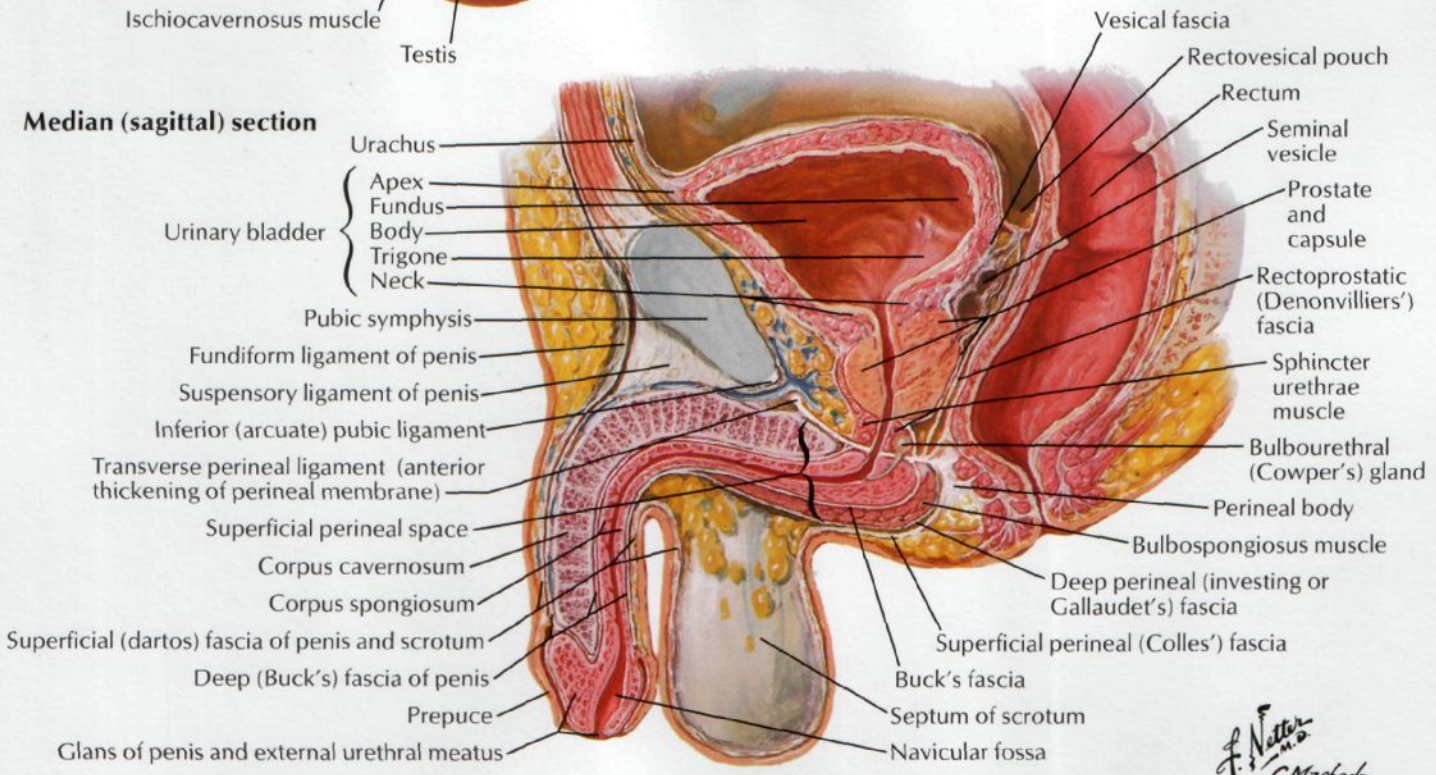

F. Netter M.D.
C. Machado M.D.
©IGN

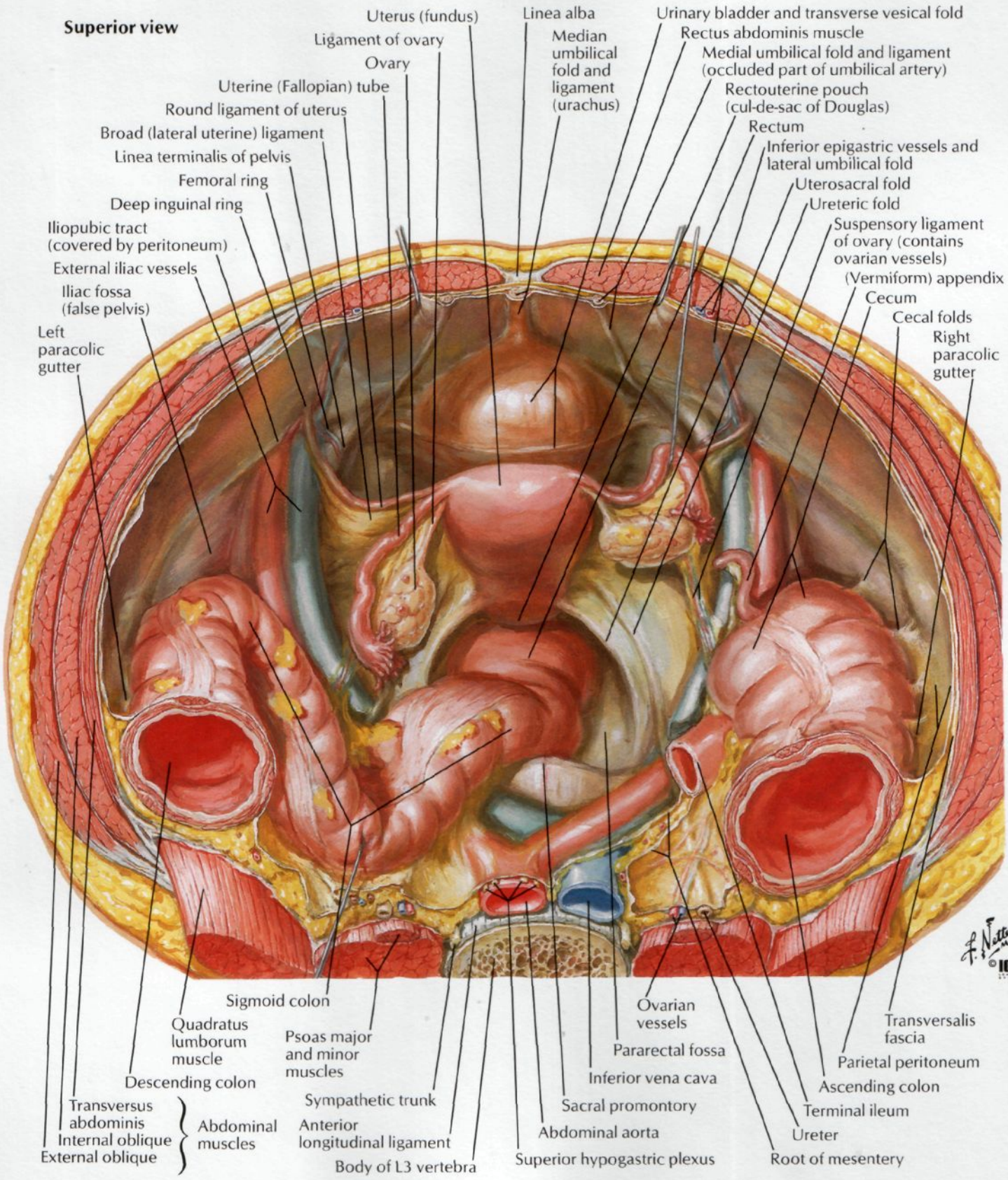
Superior view
Uterus (fundus)
Ligament of ovary
Ovary
Uterine (Fallopian) tube
Round ligament of uterus
Broad (lateral uterine) ligament
Linea terminalis of pelvis
Femoral ring
Deep inguinal ring
Iliopubic tract (covered by peritoneum)
External iliac vessels
Iliac fossa (false pelvis)
Left paracolic gutter
Linea alba
Median umbilical fold and ligament (urachus)
Urinary bladder and transverse vesical fold
Rectus abdominis muscle
Medial umbilical fold and ligament (occluded part of umbilical artery)
Rectouterine pouch (cul-de-sac of Douglas)
Rectum
Inferior epigastric vessels and lateral umbilical fold
Uterosacral fold
Ureteric fold
Suspensory ligament of ovary (contains ovarian vessels)
(Vermiform) appendix
Cecum
Cecal folds
Right paracolic gutter
Sigmoid colon
Quadratus lumborum muscle
Psoas major and minor muscles
Descending colon
Transversus abdominis
Internal oblique
External oblique
Abdominal muscles
Sympathetic trunk
Anterior longitudinal ligament
Body of L3 vertebra
Ovarian vessels
Pararectal fossa
Inferior vena cava
Sacral promontory
Abdominal aorta
Superior hypogastric plexus
Transversalis fascia
Parietal peritoneum
Ascending colon
Terminal ileum
Ureter
Root of mesentery

Pelvic Contents: Male

Superior view

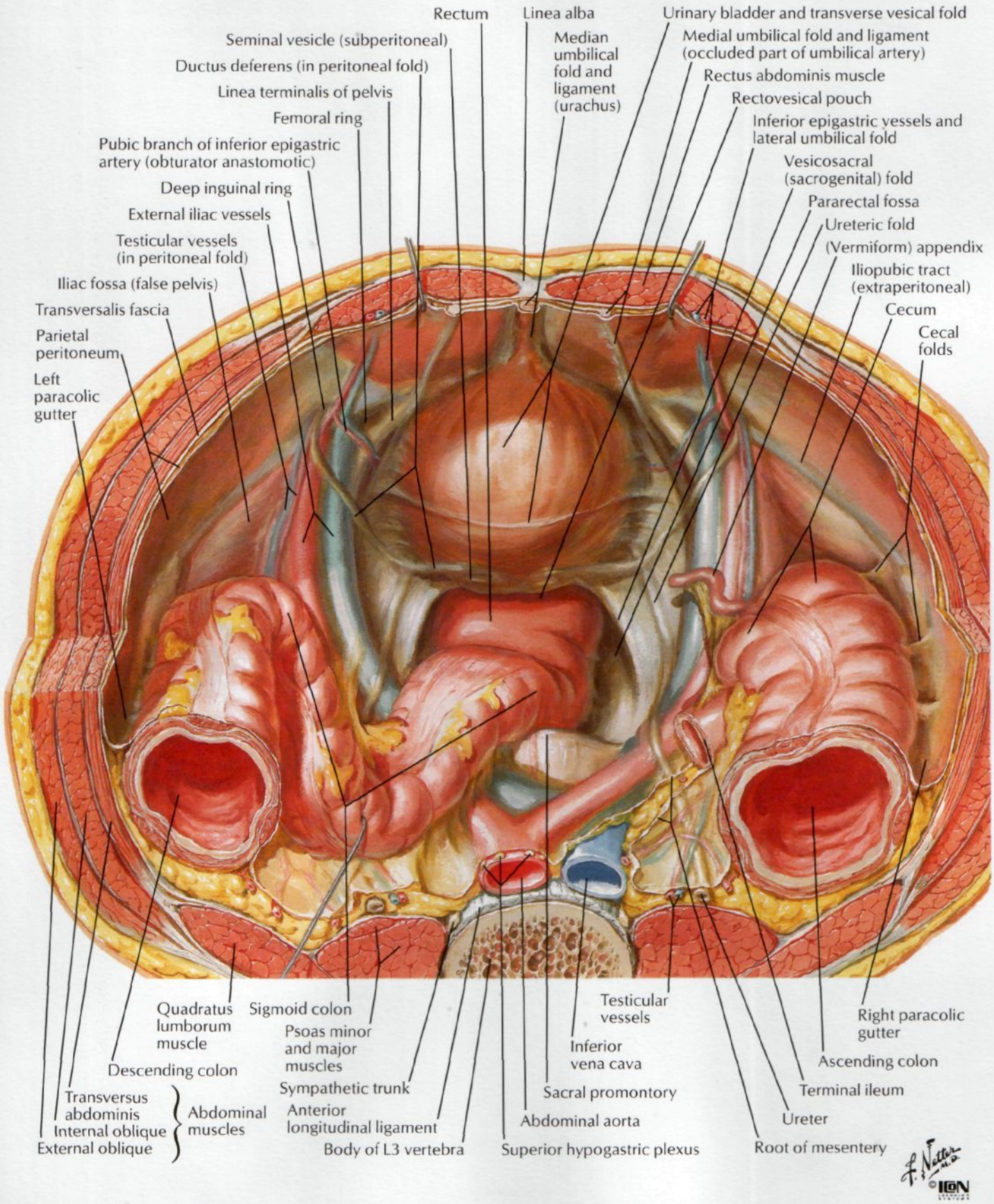

Female: superior view (peritoneum and loose areolar tissue removed)

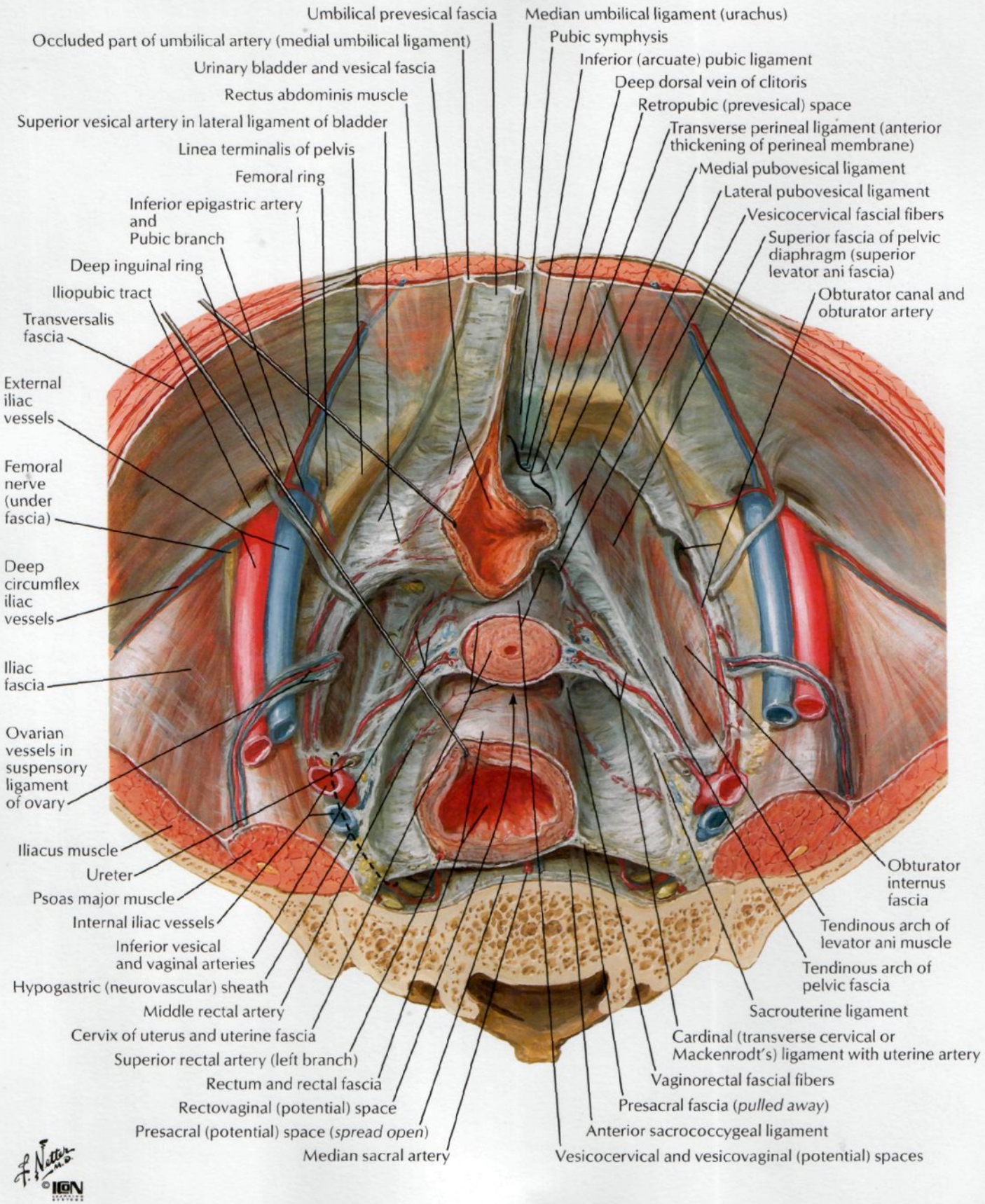

F. Netter M.D. ©IGN

Urinary Bladder: Orientation and Supports

Female: midsagittal section

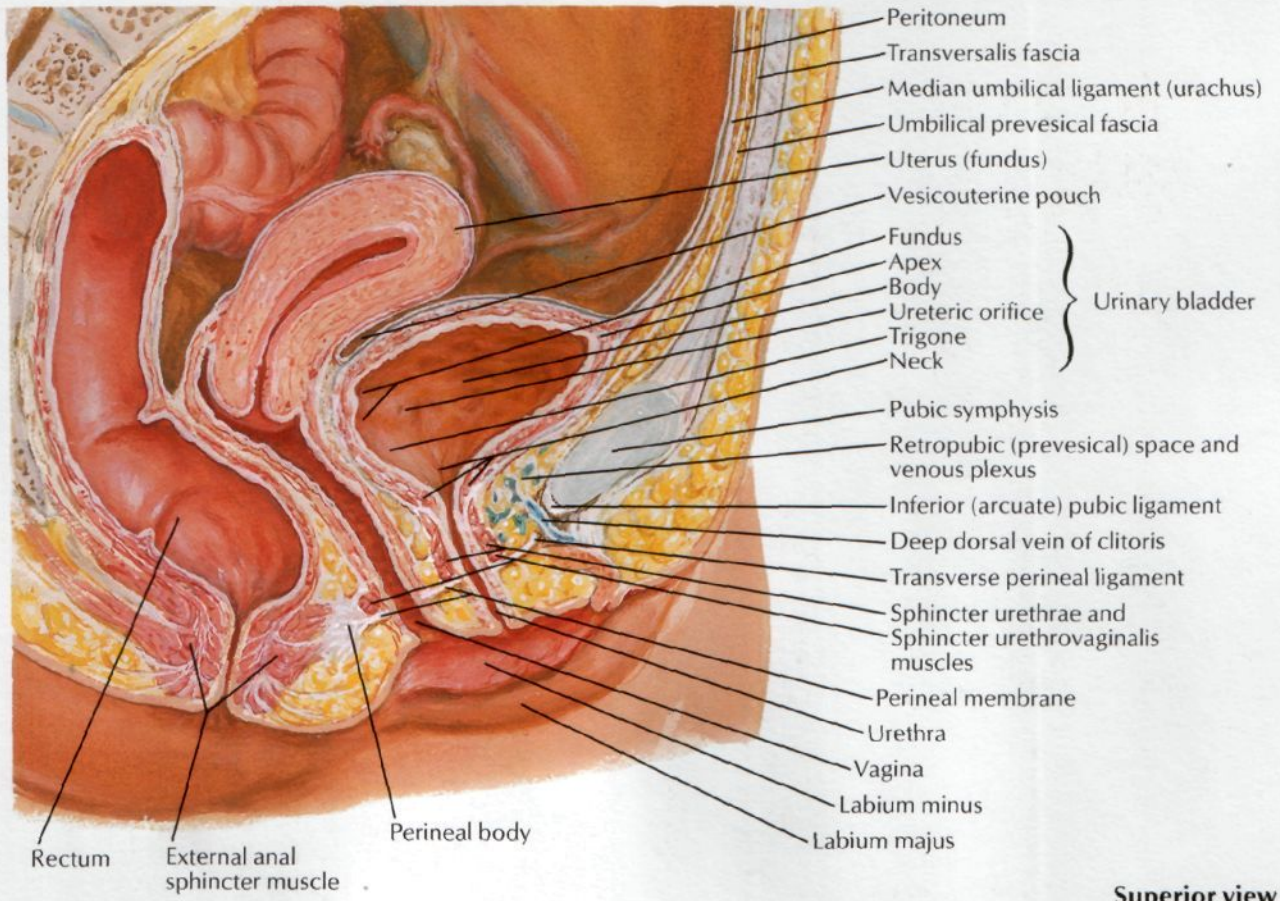

Superior view with peritoneum and vesical fascia removed

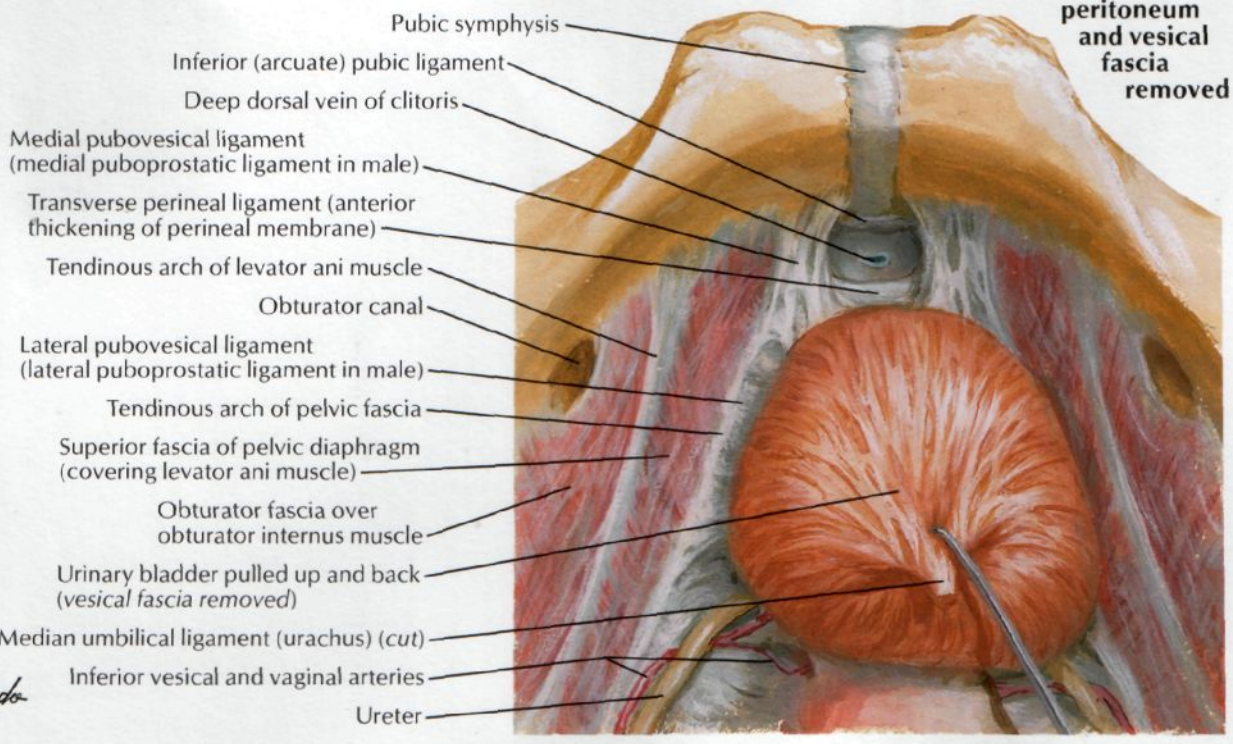

F. Netter M.D.
C. Machado M.D.
©IGN

Urinary Bladder: Female and Male

SEE ALSO PLATES 329, 347, 348, 352, 380, 382, 383, 397

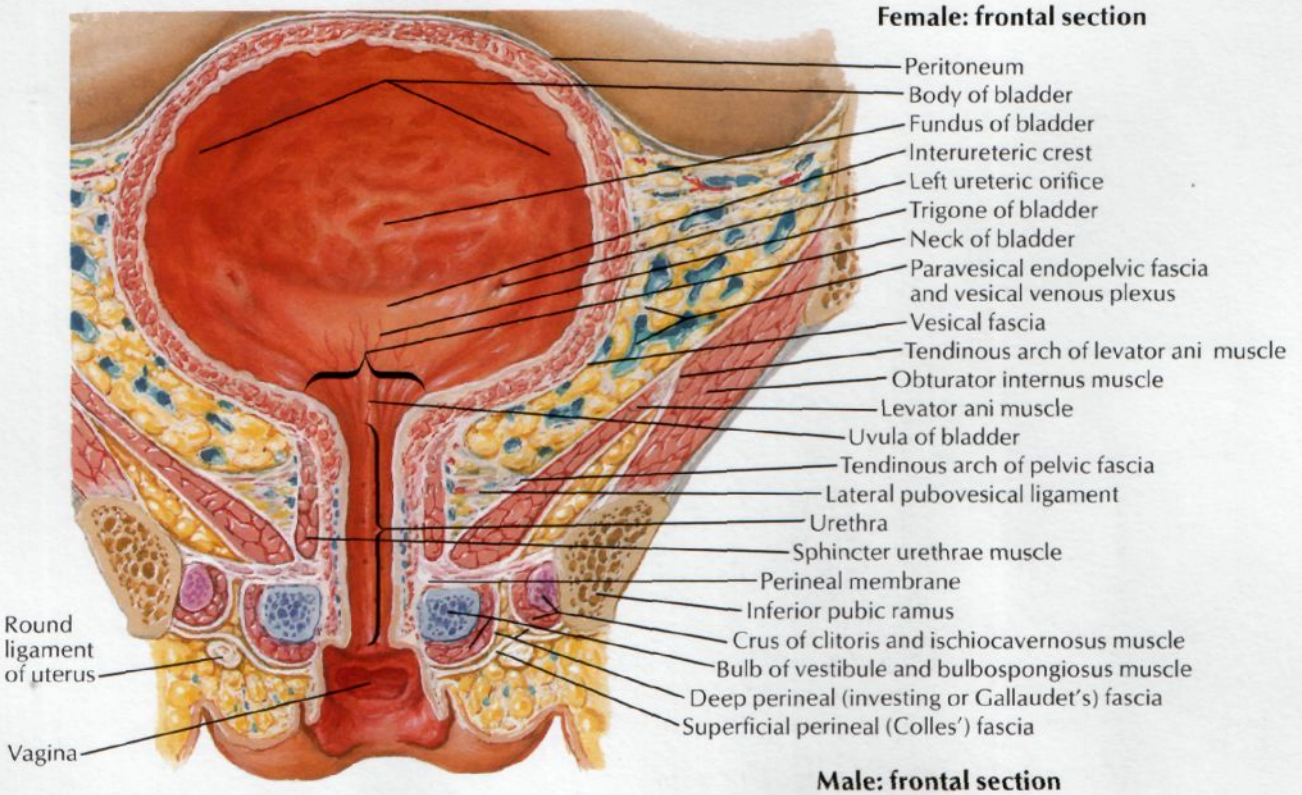

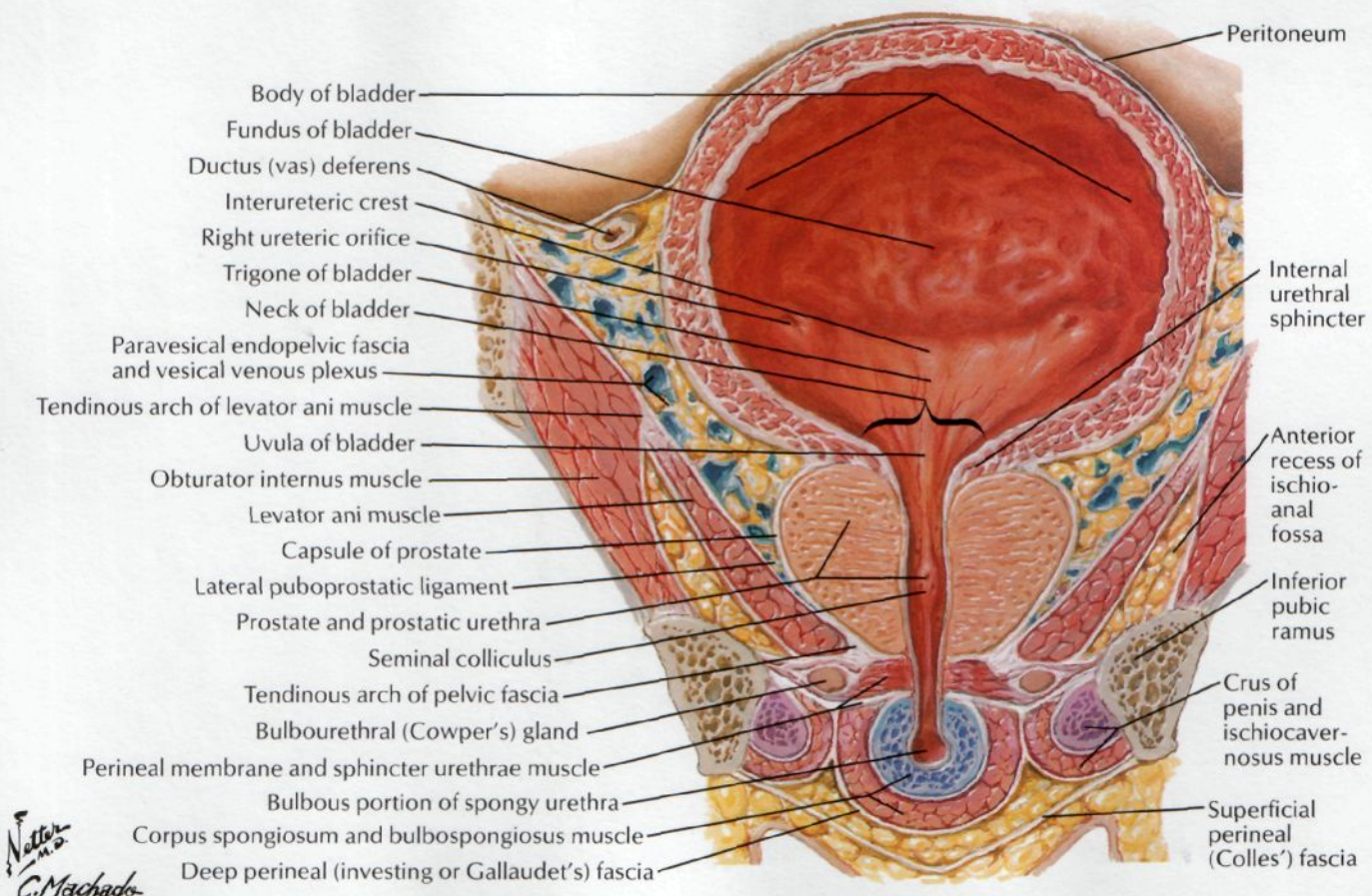

F. Netter, M.D.
C. Machado, M.D.
©ICON

Superior view with peritoneum intact

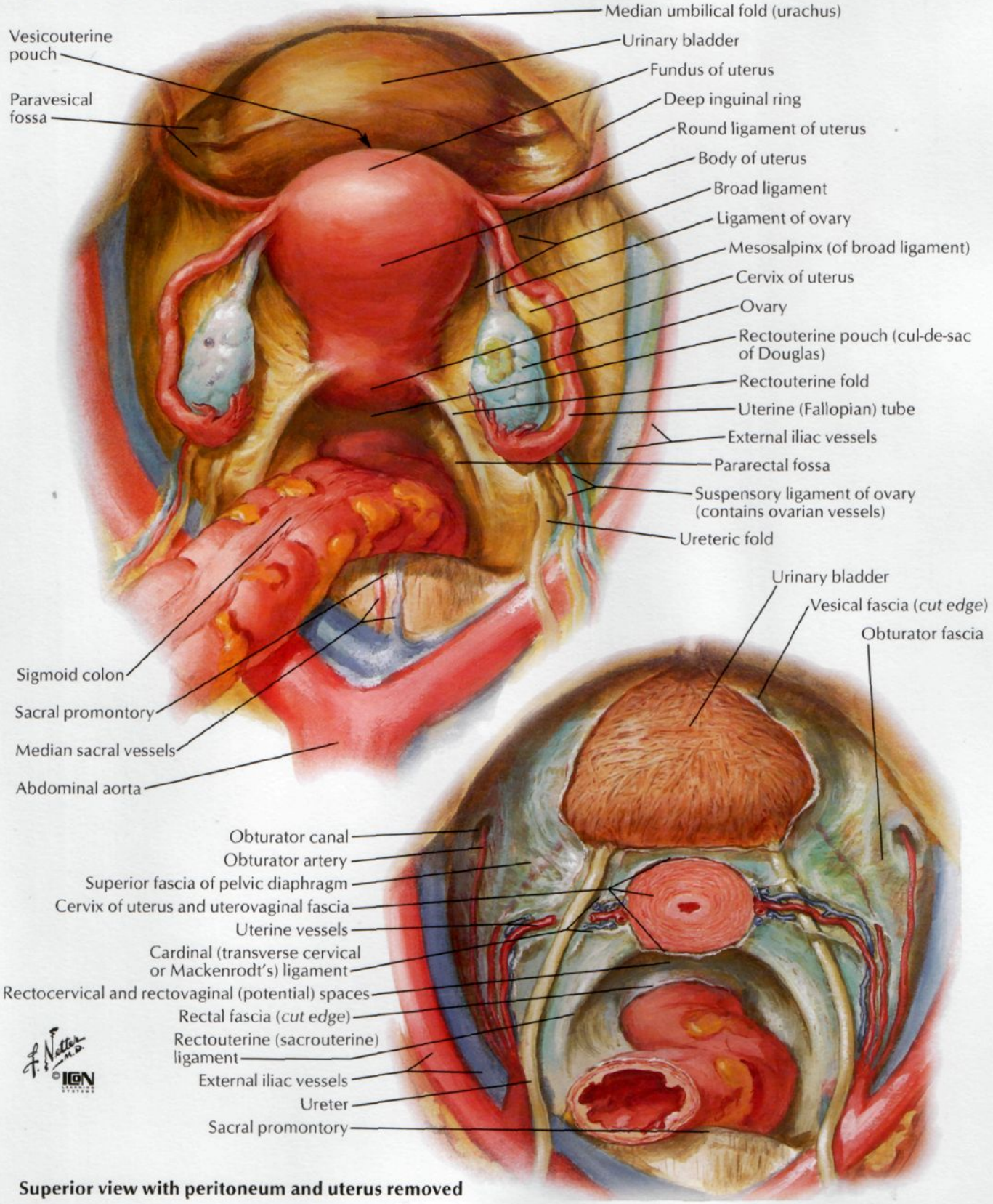

Superior view with peritoneum and uterus removed

Uterus and Adnexa

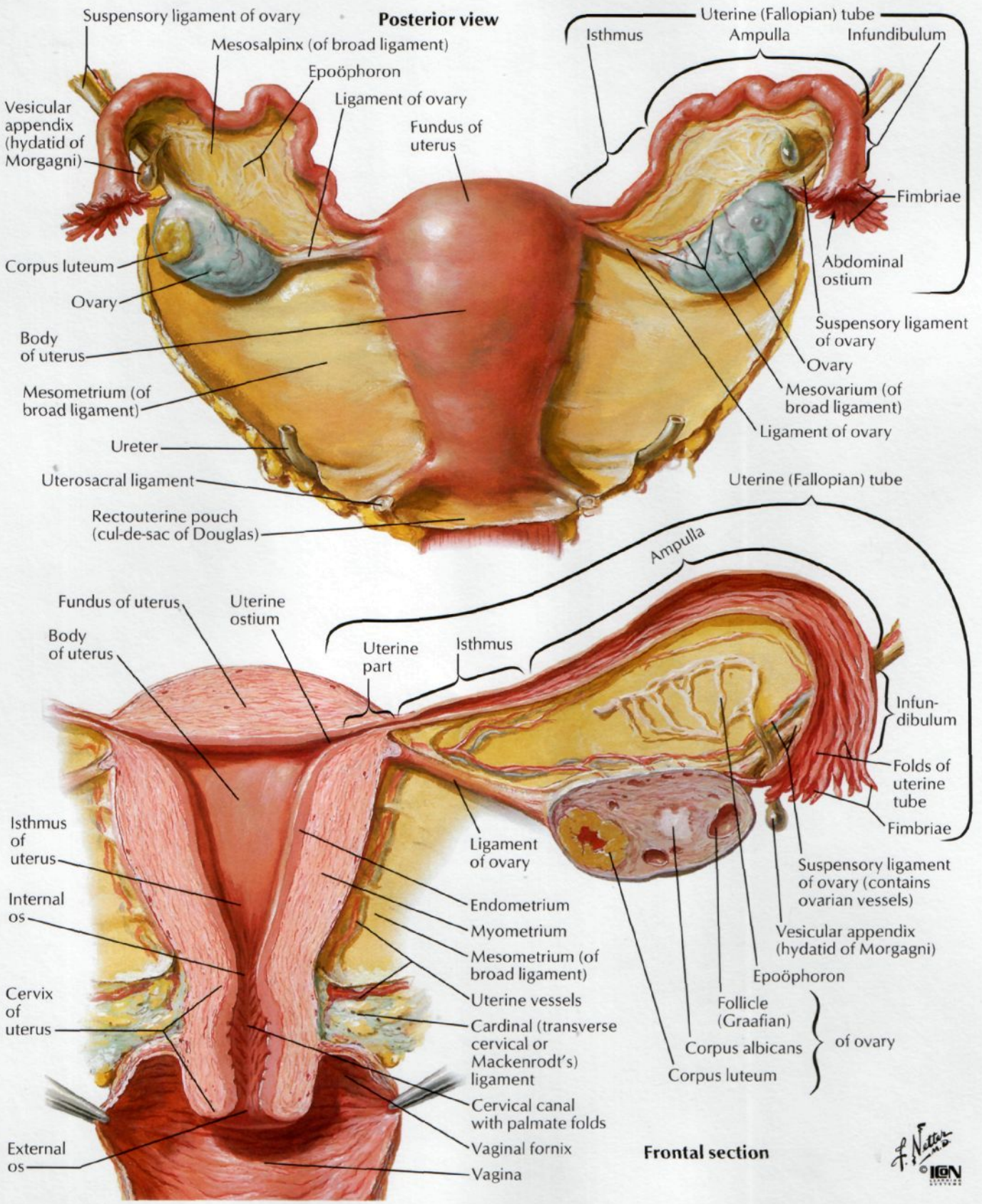

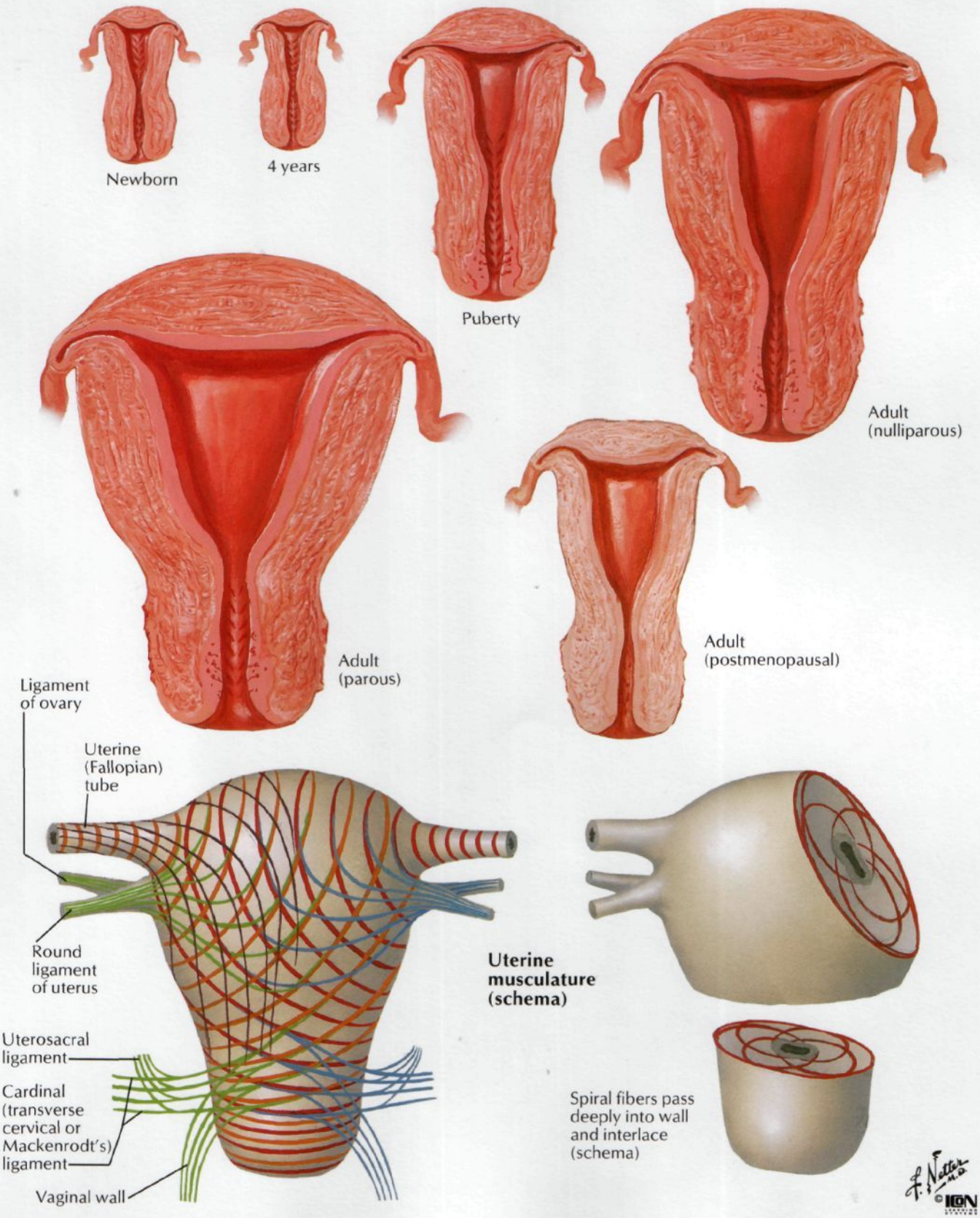
Newborn
4 years
Puberty
Adult (nulliparous)
Adult (parous)
Adult (postmenopausal)
Ligament of ovary
Uterine (Fallopian) tube
Round ligament of uterus
Uterosacral ligament
Cardinal (transverse cervical or Mackenrodt's) ligament
Vaginal wall
Uterine musculature (schema)
Spiral fibers pass deeply into wall and interlace (schema)
F. Netter M.D.
© ICON

Uterus: Variations in Position

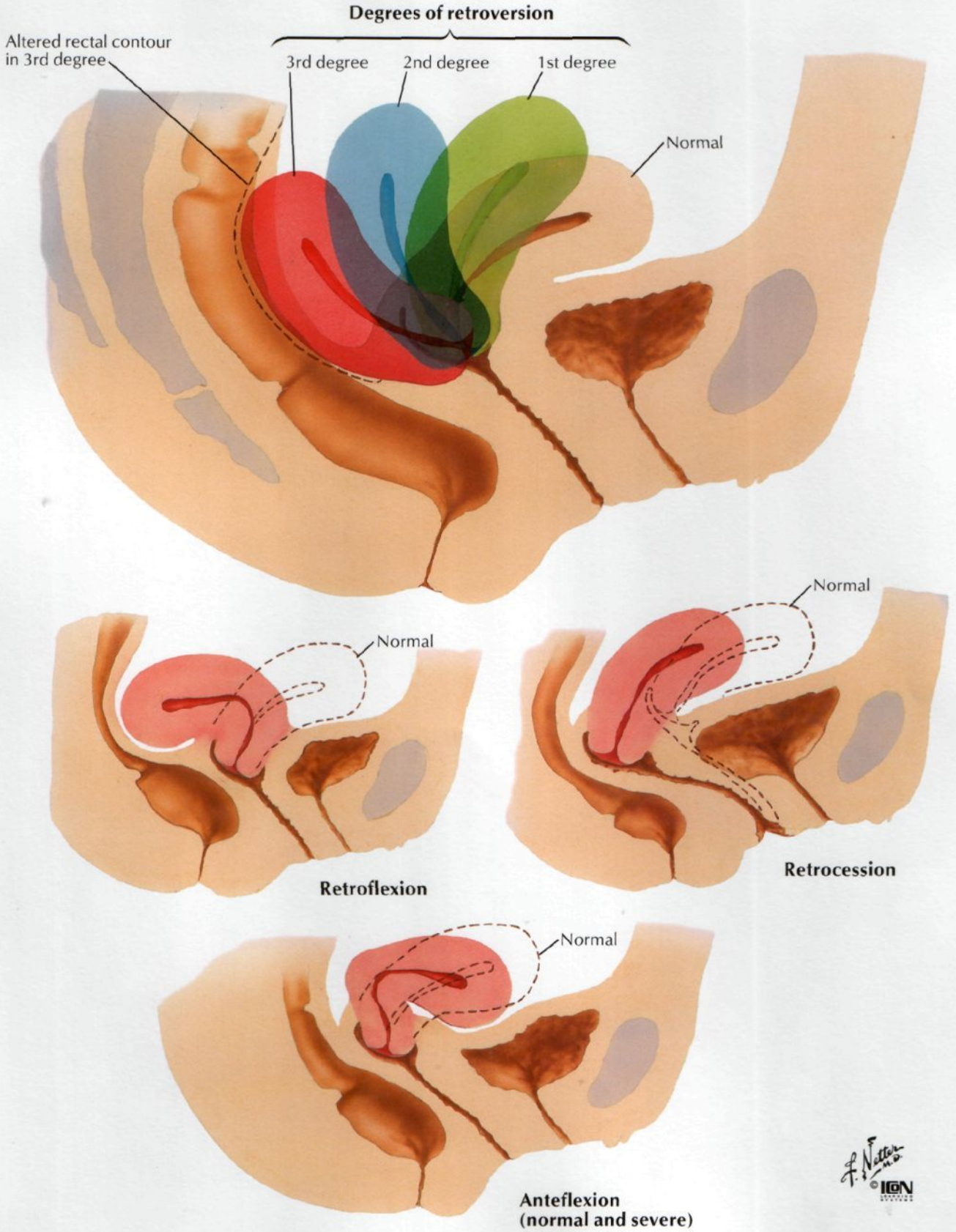

Perineum and External Genitalia (Pudendum or Vulva)

SEE ALSO PLATES 384, 386, 387, 393

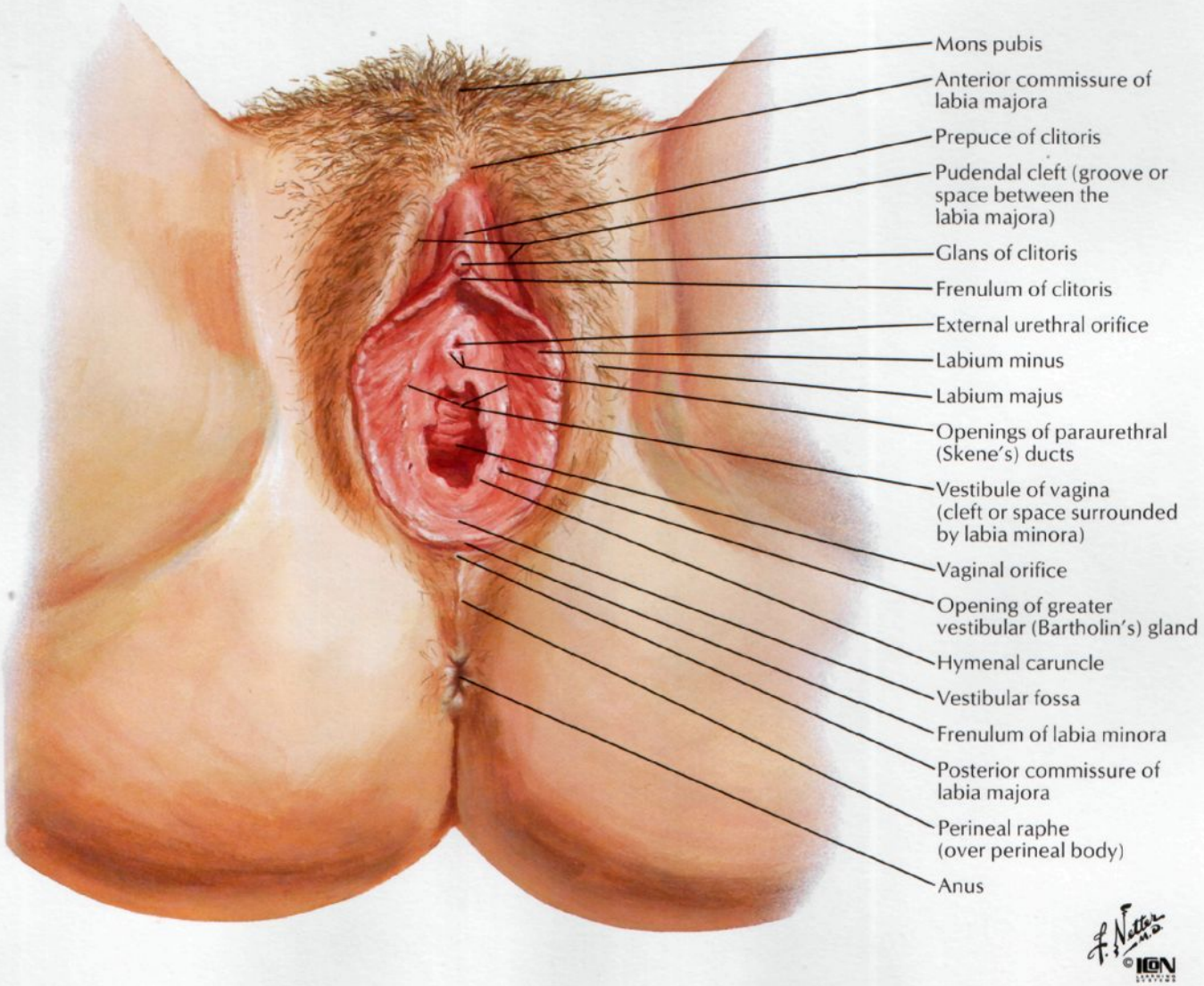

Anular hymen | Septate hymen | Cribriform hymen | Parous introitus

Perineum (Superficial Dissection)

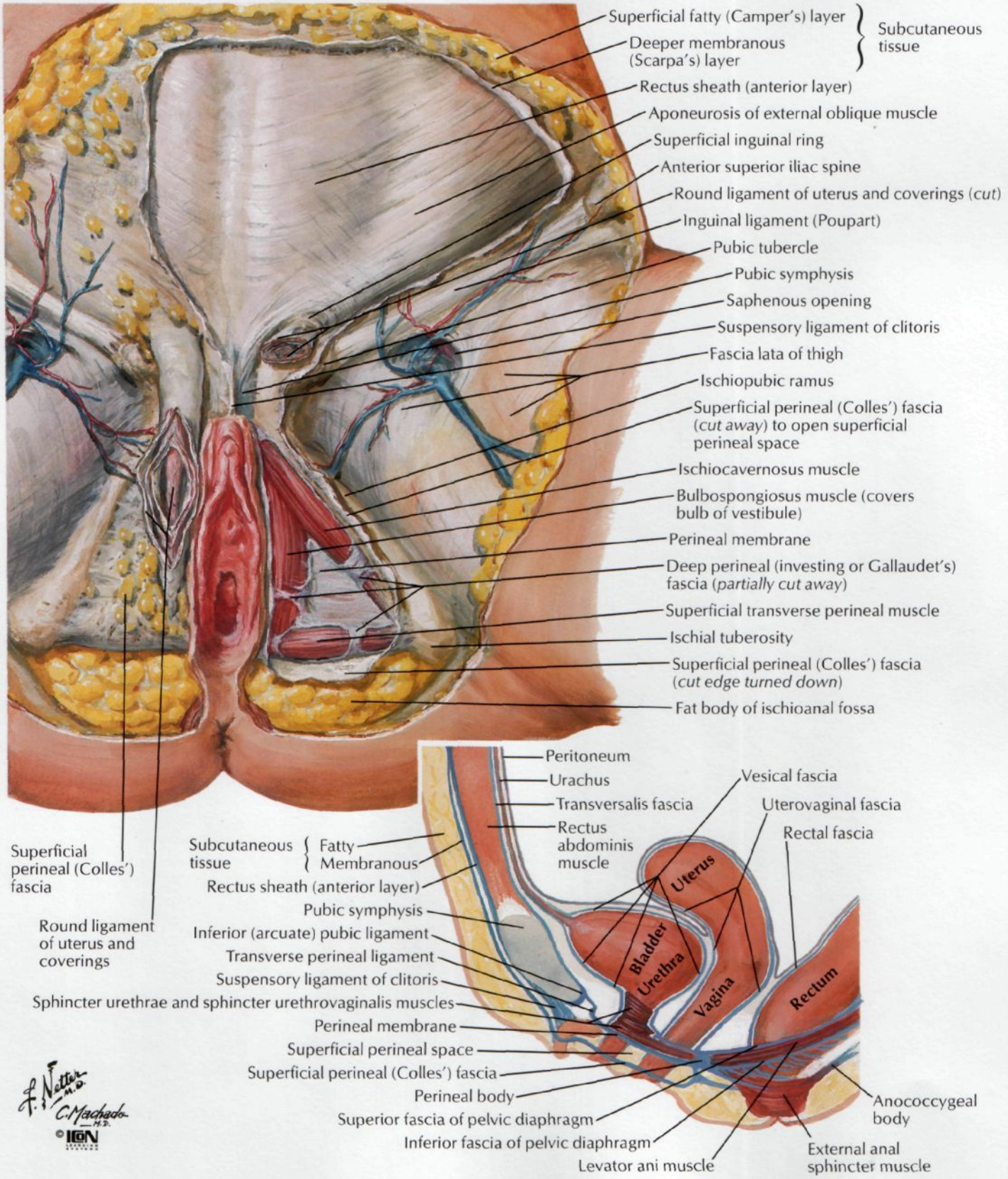

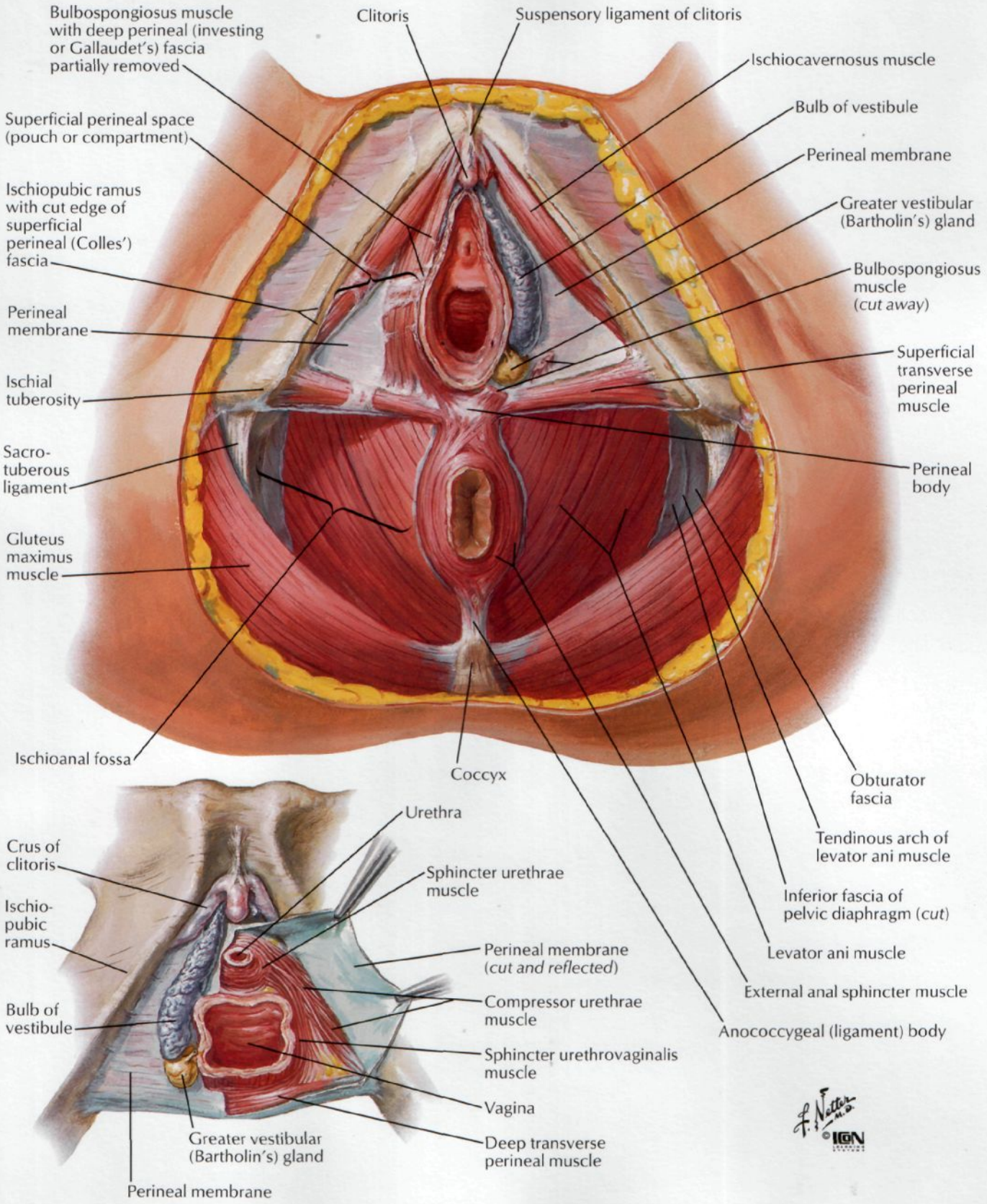
Bulbospongiosus muscle with deep perineal (investing or Gallaudet's) fascia partially removed
Clitoris
Suspensory ligament of clitoris
Ischiocavernosus muscle
Superficial perineal space (pouch or compartment)
Bulb of vestibule
Perineal membrane
Ischiopubic ramus with cut edge of superficial perineal (Colles') fascia
Greater vestibular (Bartholin's) gland
Bulbospongiosus muscle (cut away)
Perineal membrane
Superficial transverse perineal muscle
Ischial tuberosity
Sacro-tuberous ligament
Perineal body
Gluteus maximus muscle
Ischioanal fossa
Coccyx
Obturator fascia
Urethra
Tendinous arch of levator ani muscle
Crus of clitoris
Sphincter urethrae muscle
Inferior fascia of pelvic diaphragm (cut)
Ischio-pubic ramus
Perineal membrane (cut and reflected)
Levator ani muscle
External anal sphincter muscle
Compressor urethrae muscle
Bulb of vestibule
Anococcygeal (ligament) body
Sphincter urethrovaginalis muscle
Vagina
Greater vestibular (Bartholin's) gland
Deep transverse perineal muscle
Perineal membrane

Female Urethra

SEE ALSO PLATES 347, 352

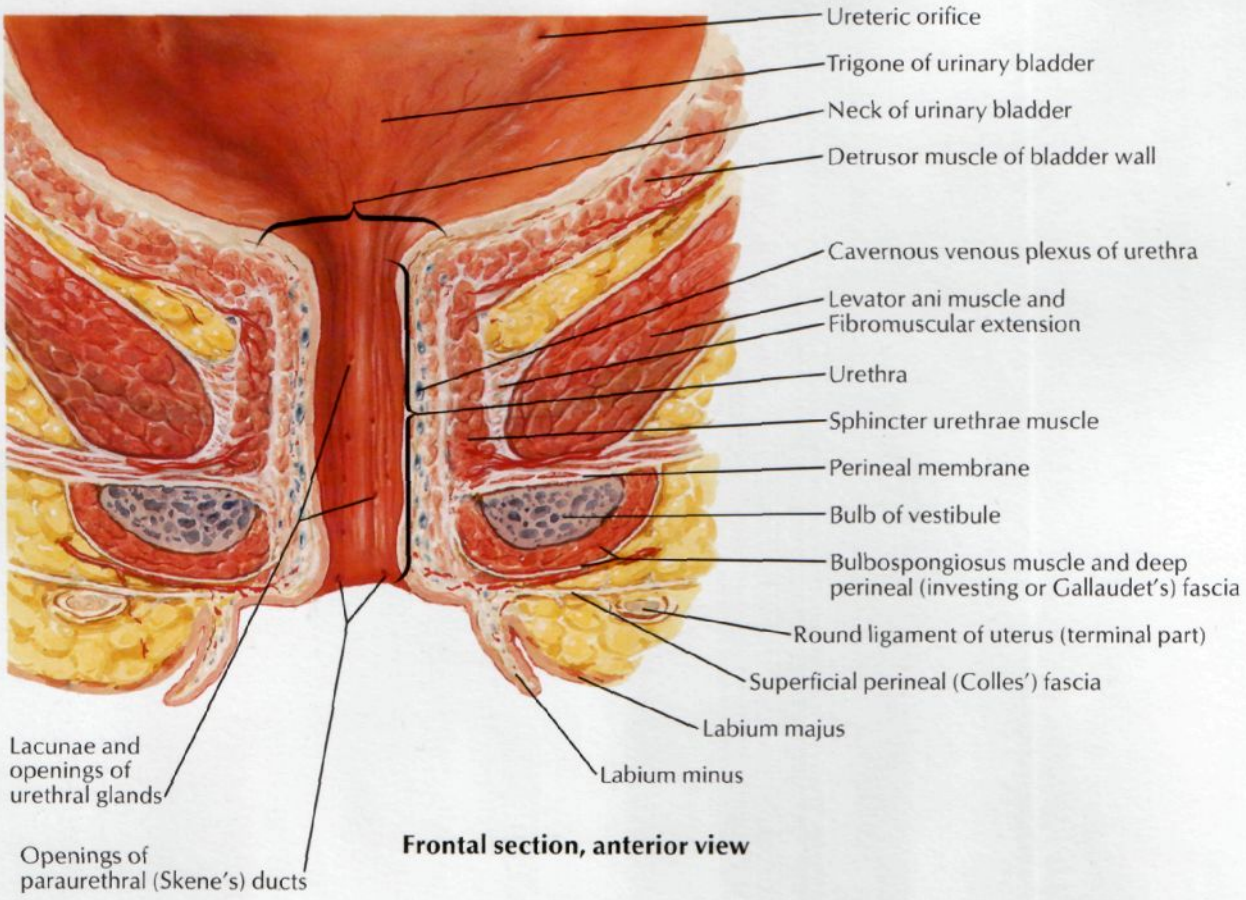

Frontal section, anterior view

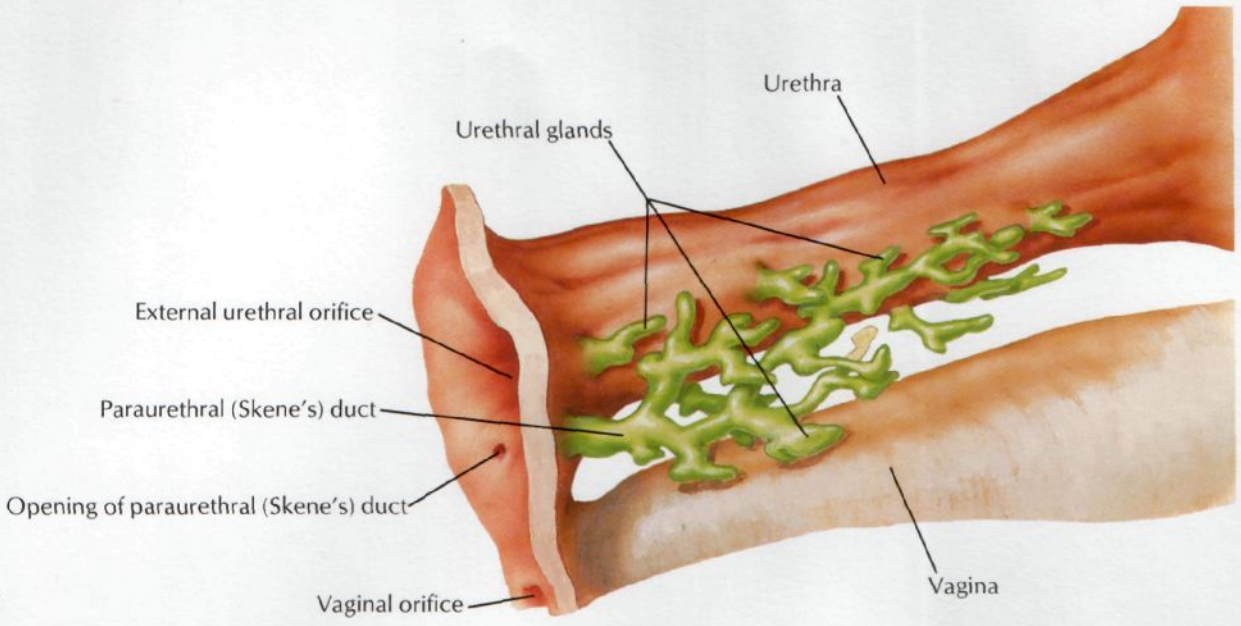

F. Netter, M.D.
C. Machado, M.D.
©IGN

Schematic reconstruction

Perineum and External Genitalia (Superficial Dissection)

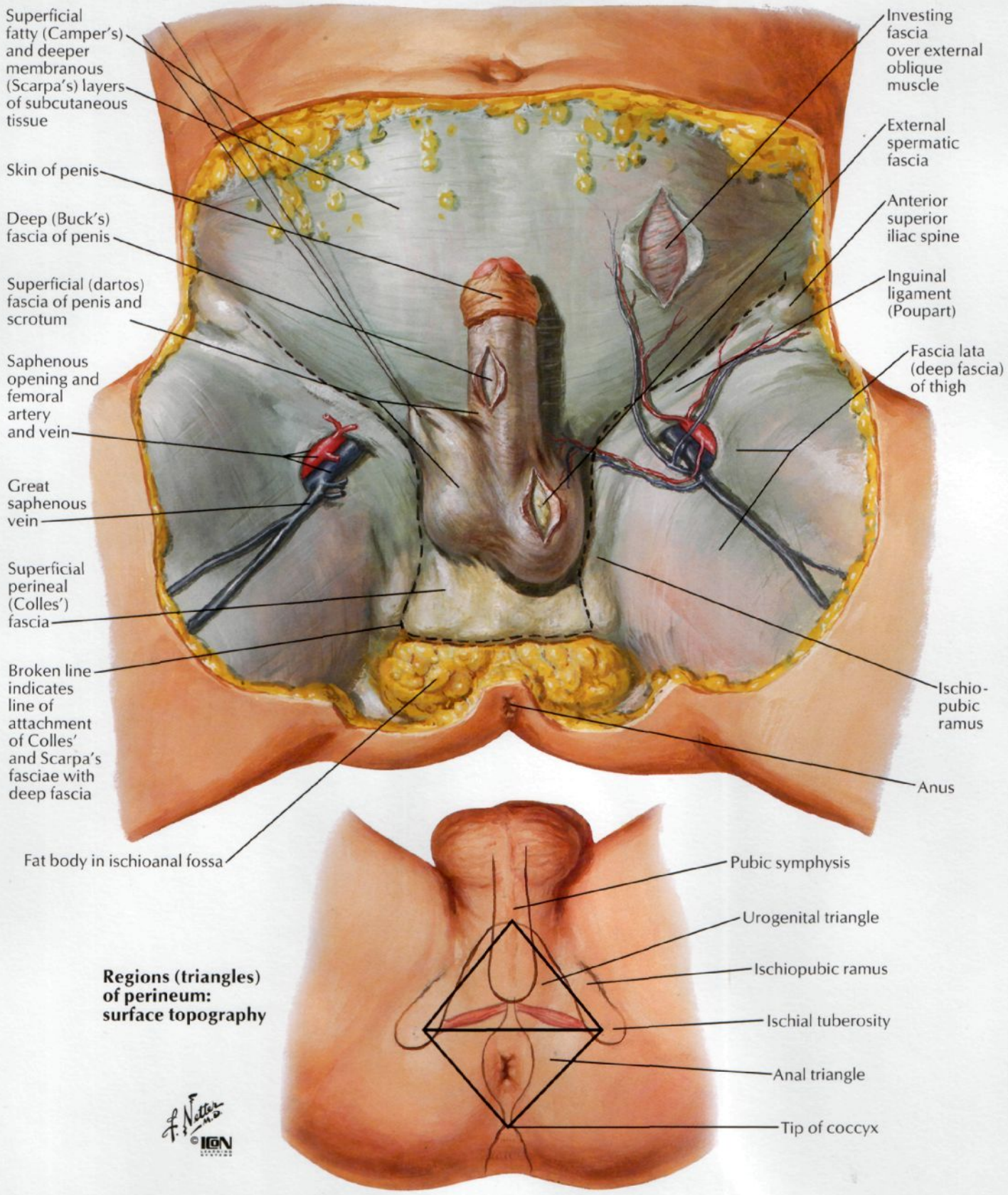

Regions (triangles) of perineum: surface topography

F. H. Netter, M.D.
©IGN

Perineum and External Genitalia (Deeper Dissection)

SEE ALSO PLATES 383, 385, 388–391, 396

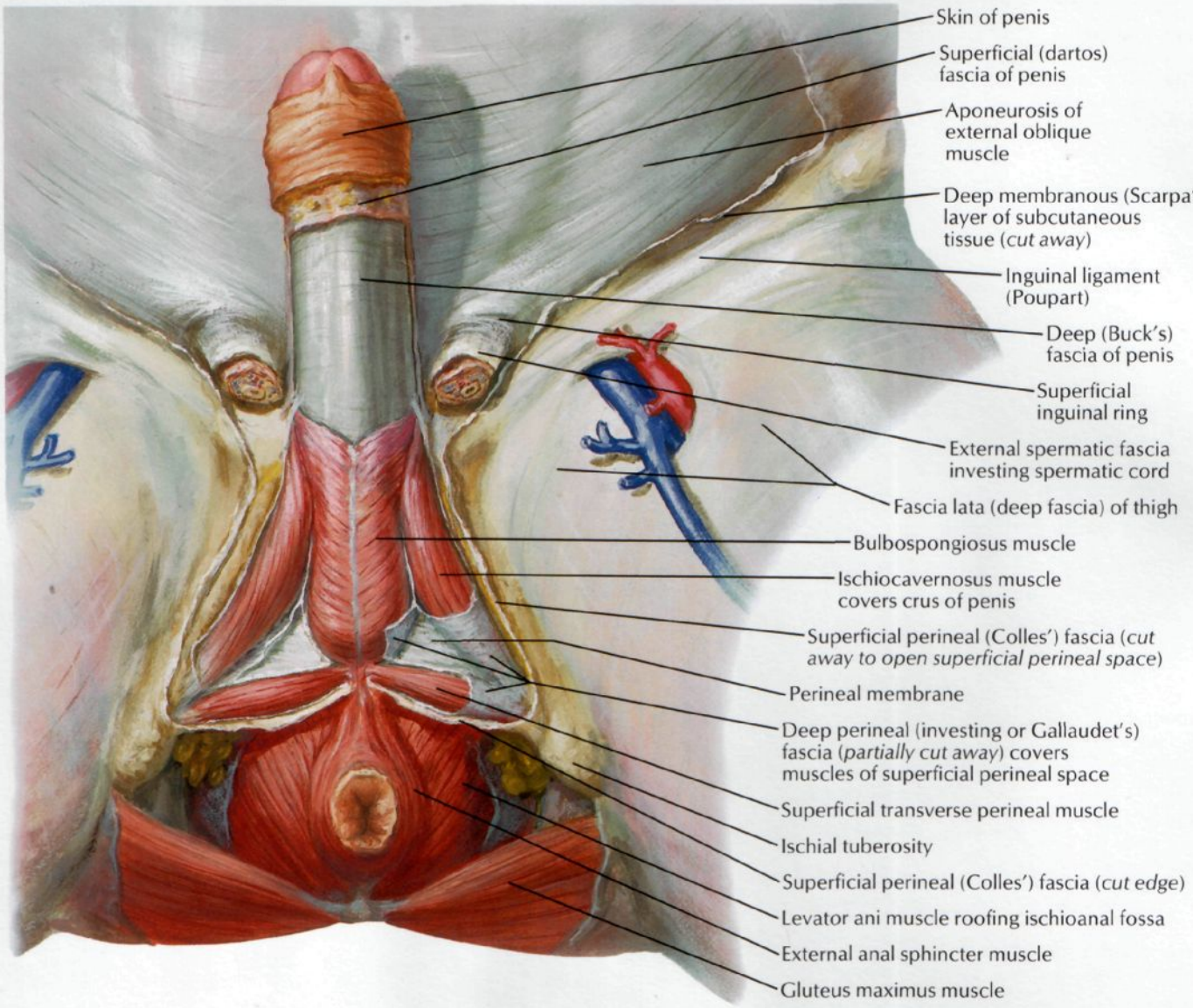

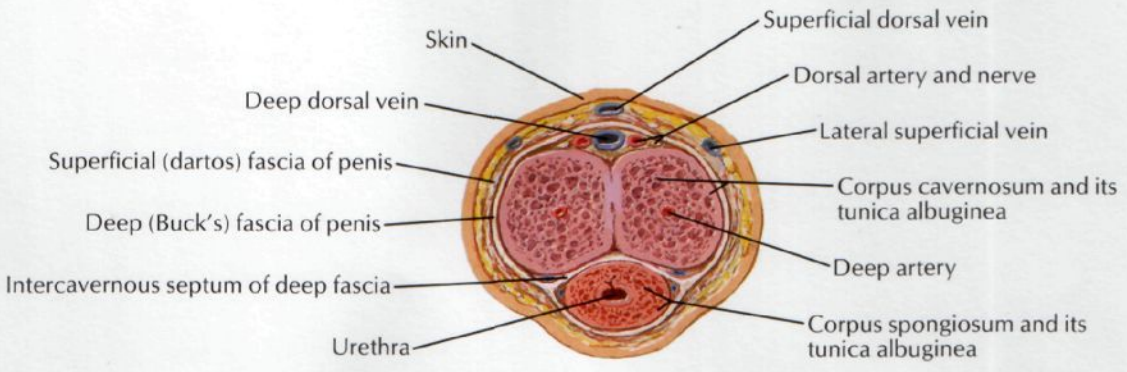

Section through body of penis

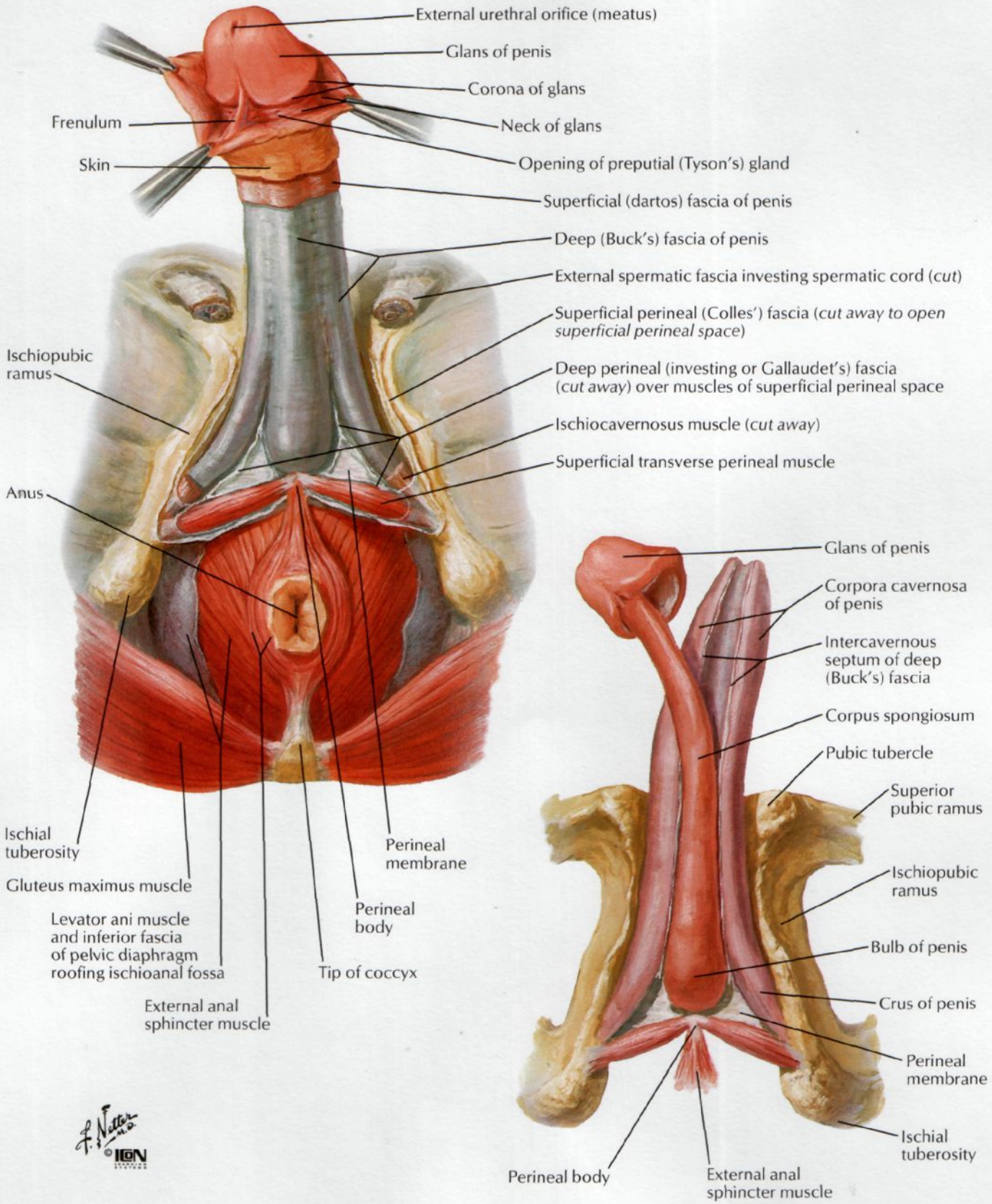
External urethral orifice (meatus)
Glans of penis
Corona of glans
Frenulum
Neck of glans
Skin
Opening of preputial (Tyson's) gland
Superficial (dartos) fascia of penis
Deep (Buck's) fascia of penis
External spermatic fascia investing spermatic cord (cut)
Superficial perineal (Colles') fascia (cut away to open superficial perineal space)
Ischiopubic ramus
Deep perineal (investing or Gallaudet's) fascia (cut away) over muscles of superficial perineal space
Ischiocavernosus muscle (cut away)
Superficial transverse perineal muscle
Anus
Ischial tuberosity
Perineal membrane
Gluteus maximus muscle
Perineal body
Levator ani muscle and inferior fascia of pelvic diaphragm roofing ischioanal fossa
Tip of coccyx
External anal sphincter muscle
Glans of penis
Corpora cavernosa of penis
Intercavernous septum of deep (Buck's) fascia
Corpus spongiosum
Pubic tubercle
Superior pubic ramus
Ischiopubic ramus
Bulb of penis
Crus of penis
Perineal membrane
Ischial tuberosity
Perineal body
External anal sphincter muscle

Perineal Spaces

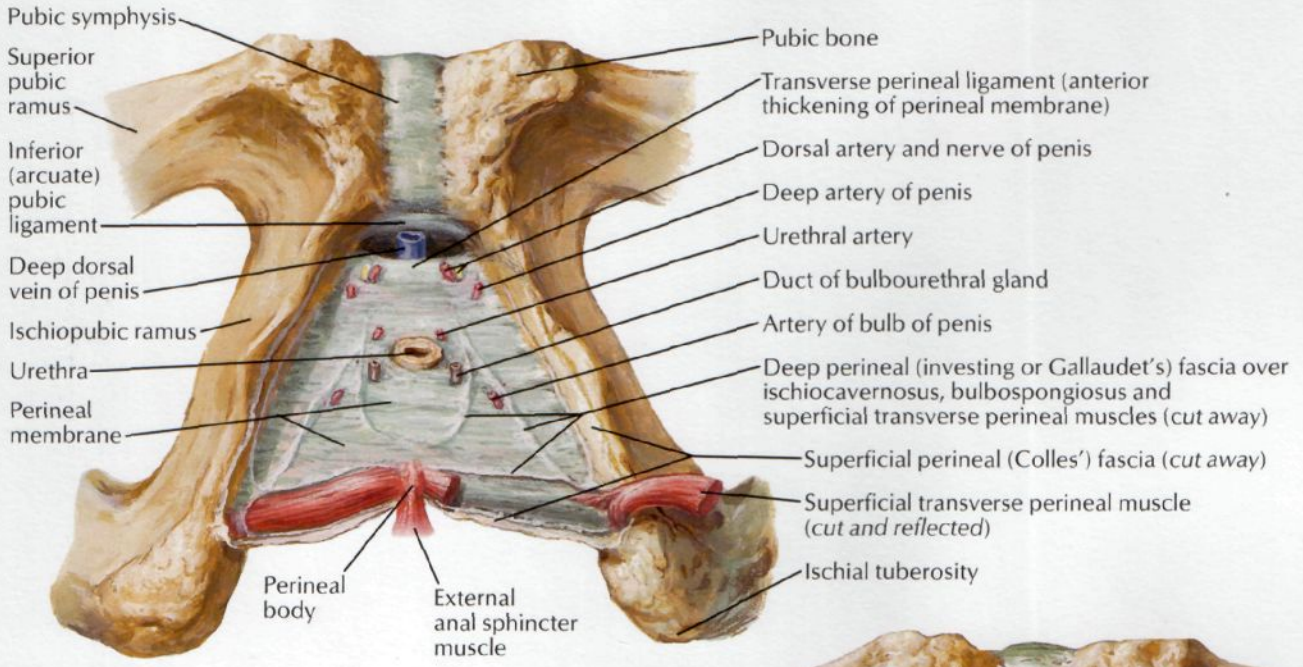

Inferior views

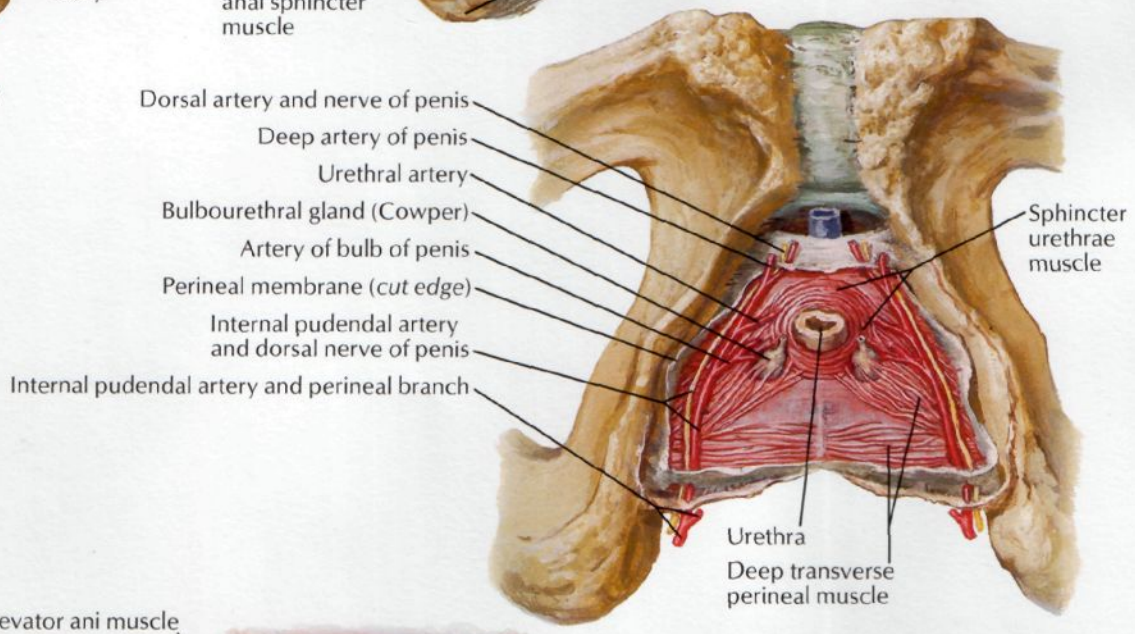

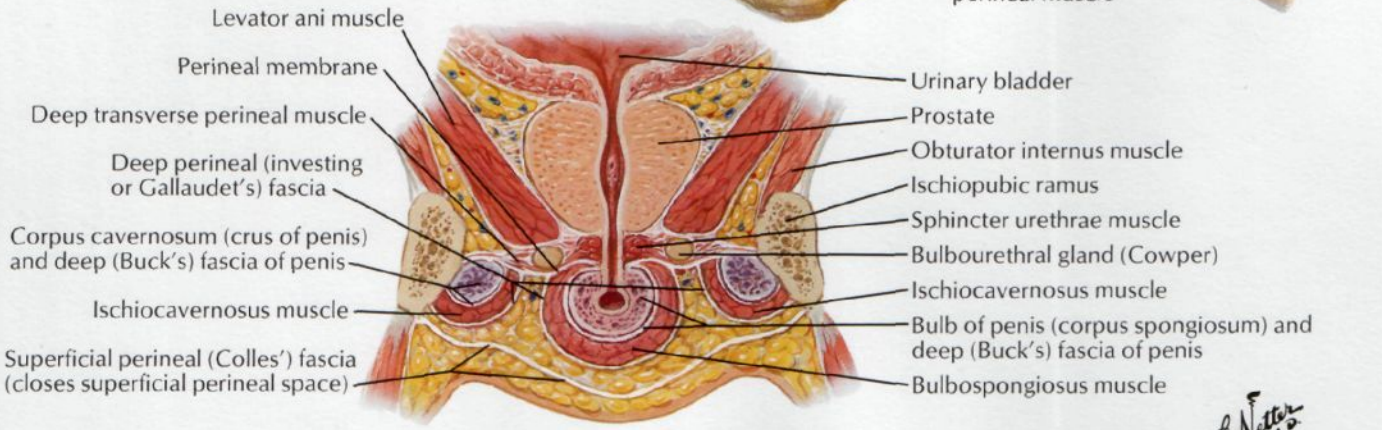

Frontal section, anterior view of perineum: schema

F. Netter M.D. C. Machado M.D.

©ICON

SEE ALSO PLATES 348, 350, 353, 383, 390

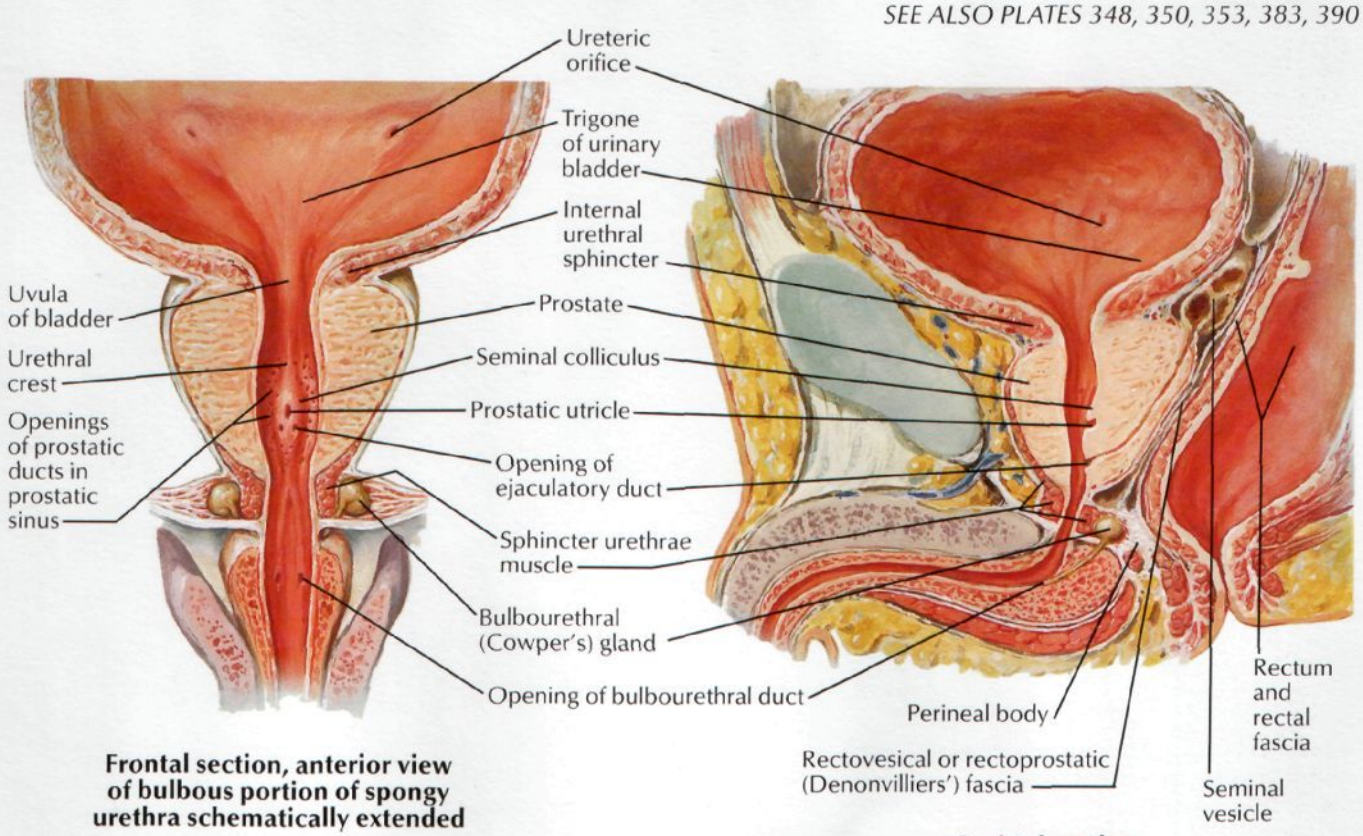

Frontal section, anterior view of bulbous portion of spongy urethra schematically extended

Sagittal section

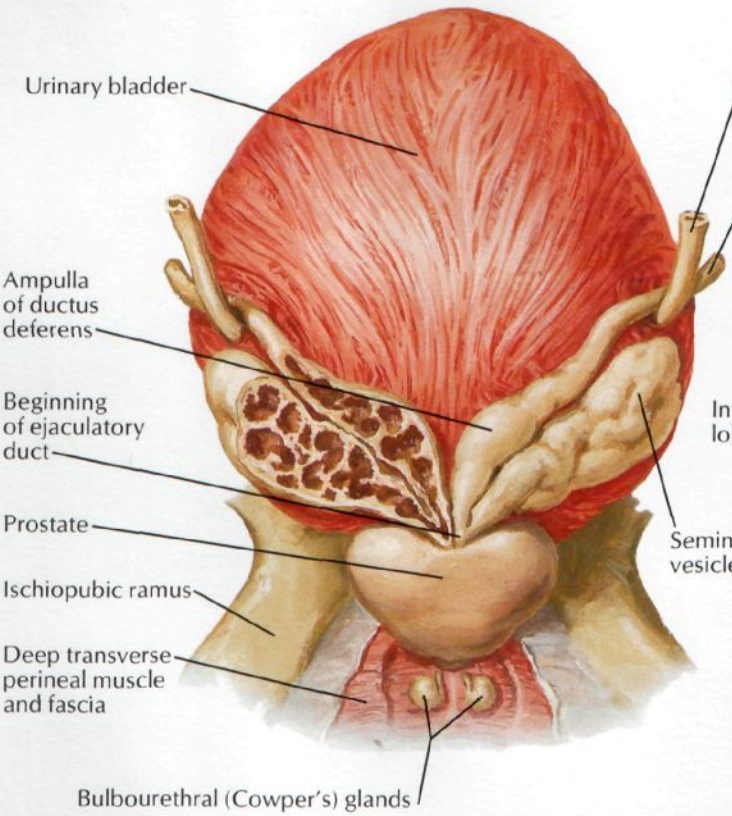

Posterior view

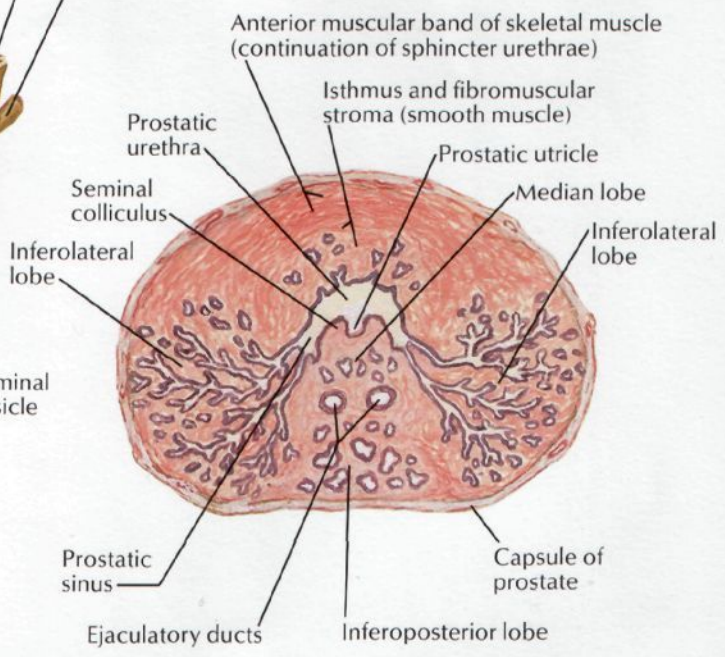

Cross section through prostate

Urethra

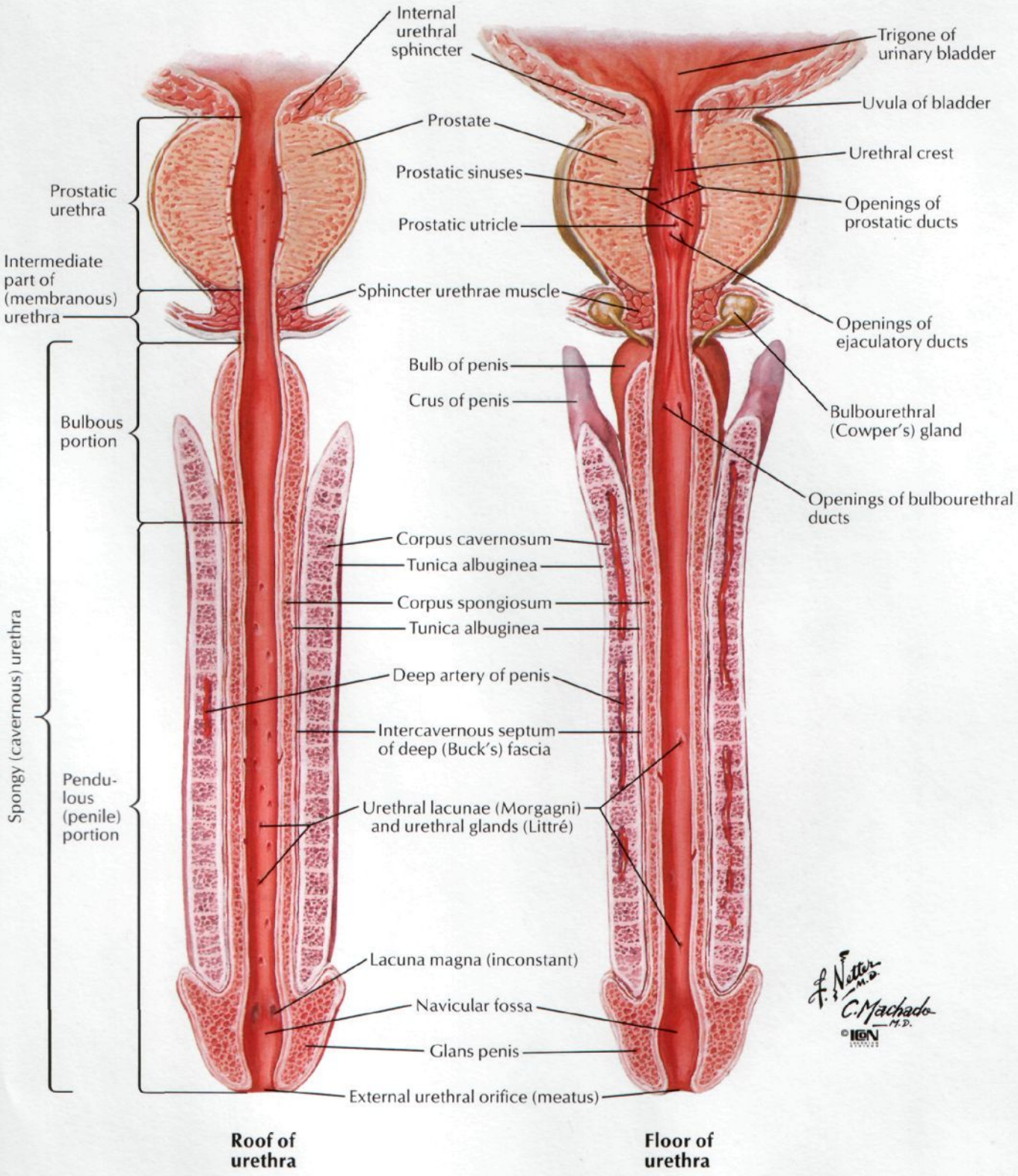
Internal urethral sphincter
Prostate
Prostatic sinuses
Prostatic utricle
Sphincter urethrae muscle
Bulb of penis
Crus of penis
Corpus cavernosum
Tunica albuginea
Corpus spongiosum
Tunica albuginea
Deep artery of penis
Intercavernous septum of deep (Buck's) fascia
Urethral lacunae (Morgagni) and urethral glands (Littré)
Lacuna magna (inconstant)
Navicular fossa
Glans penis
External urethral orifice (meatus)
Trigone of urinary bladder
Uvula of bladder
Urethral crest
Openings of prostatic ducts
Openings of ejaculatory ducts
Bulbourethral (Cowper's) gland
Openings of bulbourethral ducts
Prostatic urethra
Intermediate part of (membranous) urethra
Bulbous portion
Pendulous (penile) portion
Spongy (cavernous) urethra
Roof of urethra
Floor of urethra
F. Netter M.D.
C. Machado M.D.
©ICON

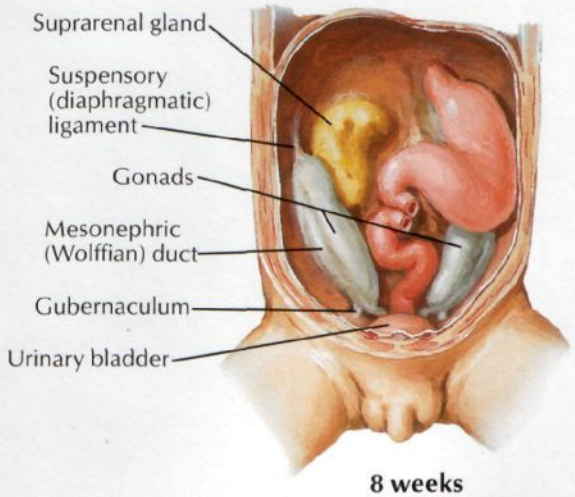

8 weeks
(22.5-mm crown rump)

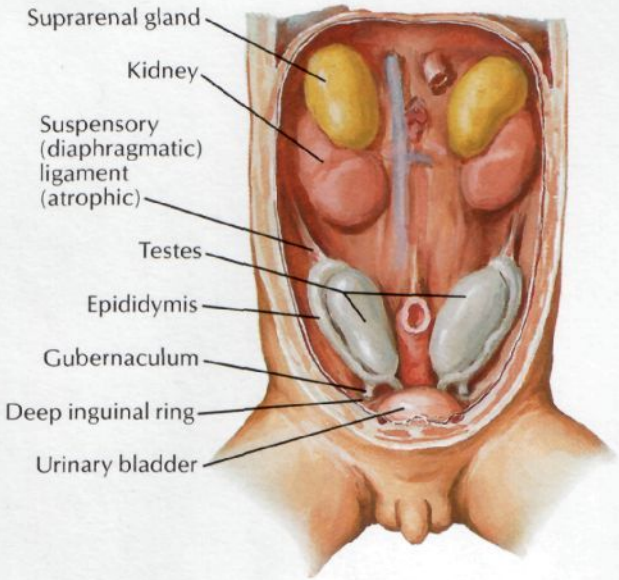

11 weeks
(43-mm crown rump)

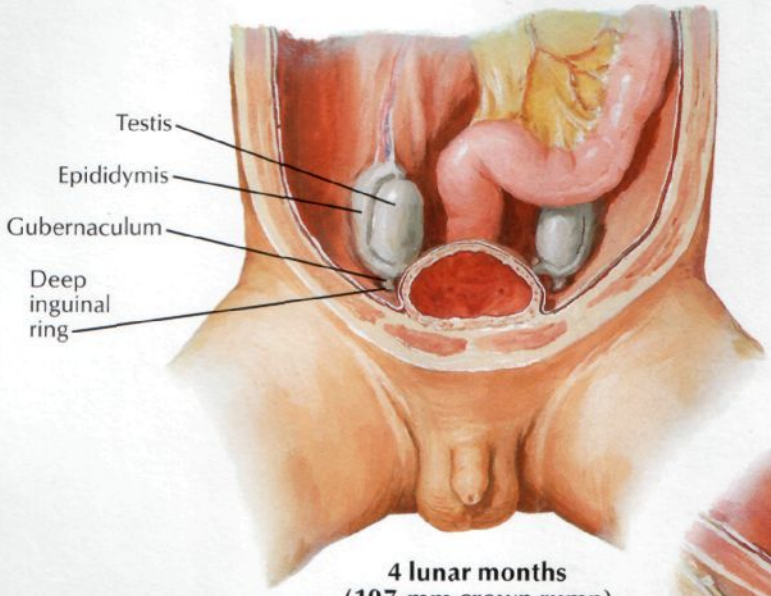

4 lunar months
(107-mm crown rump)

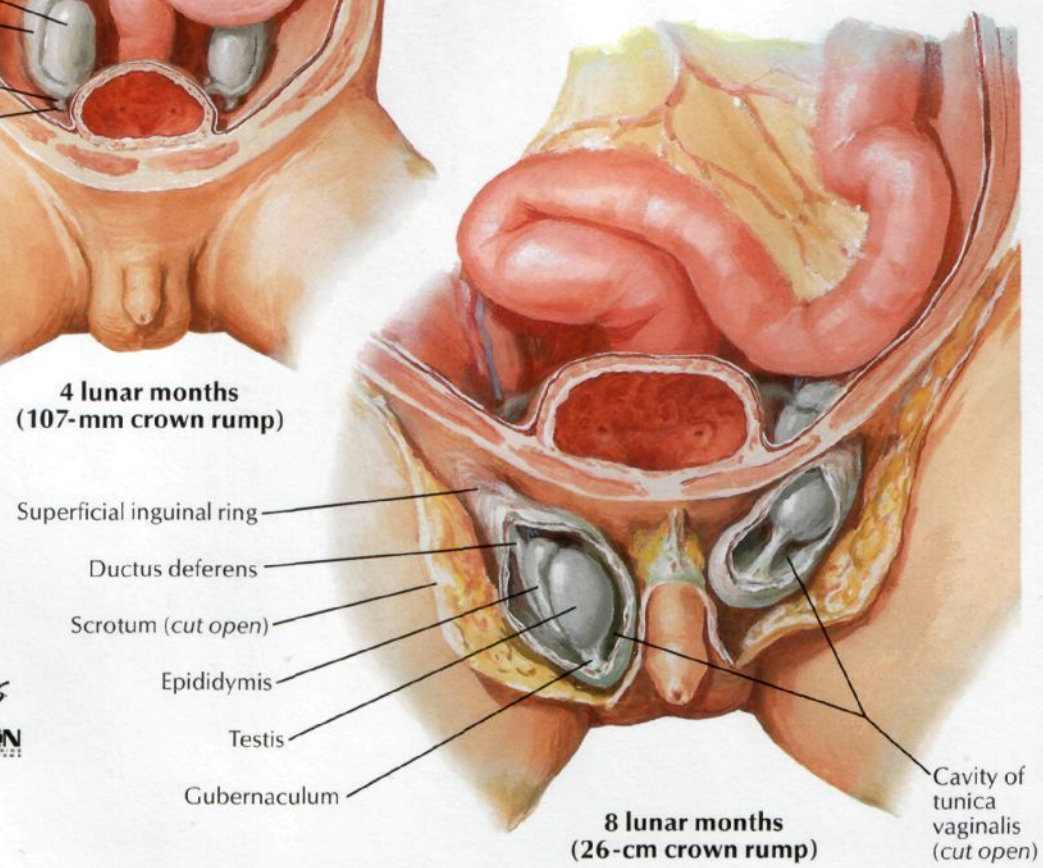

8 lunar months
(26-cm crown rump)

Scrotum and Contents

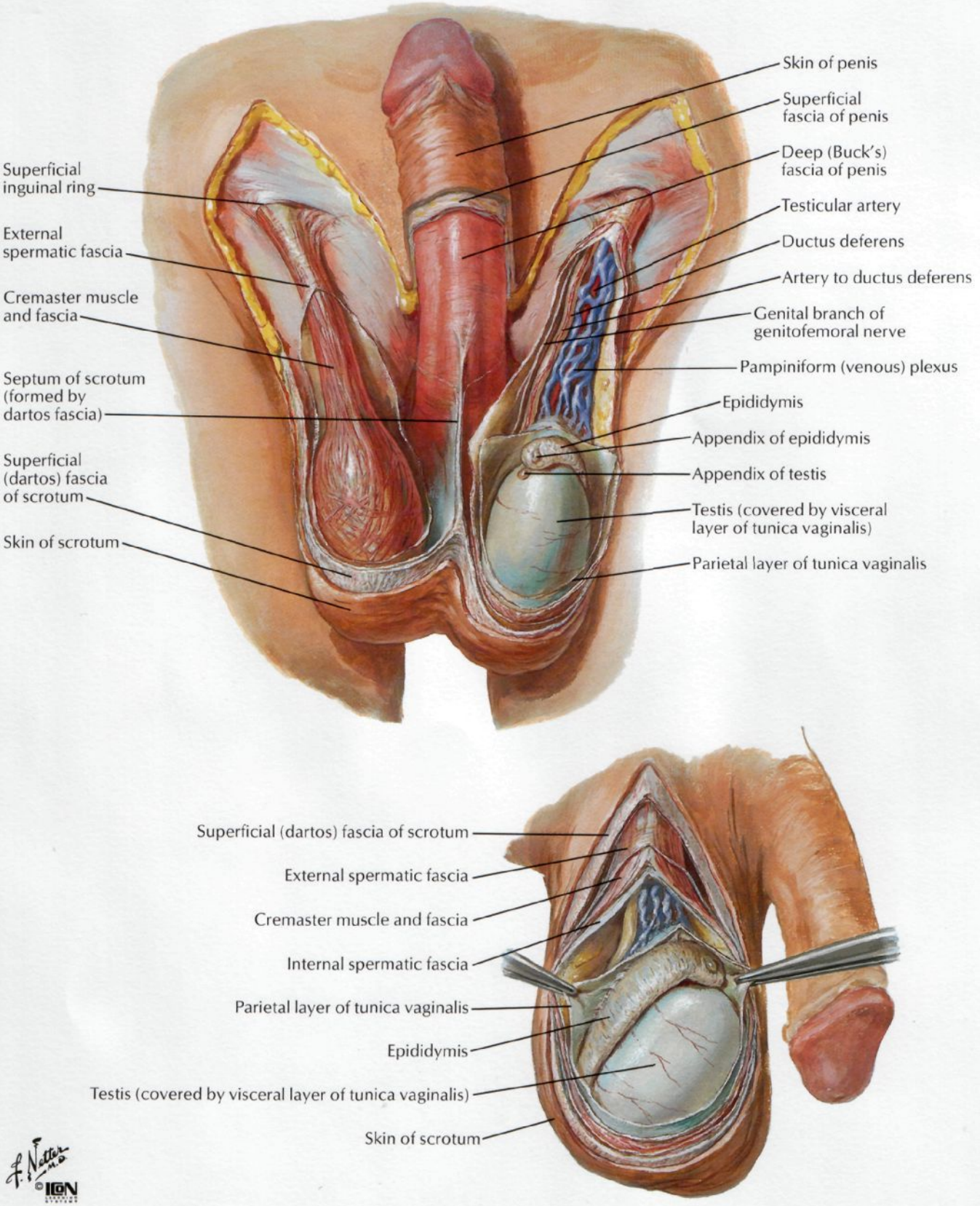

©IGN

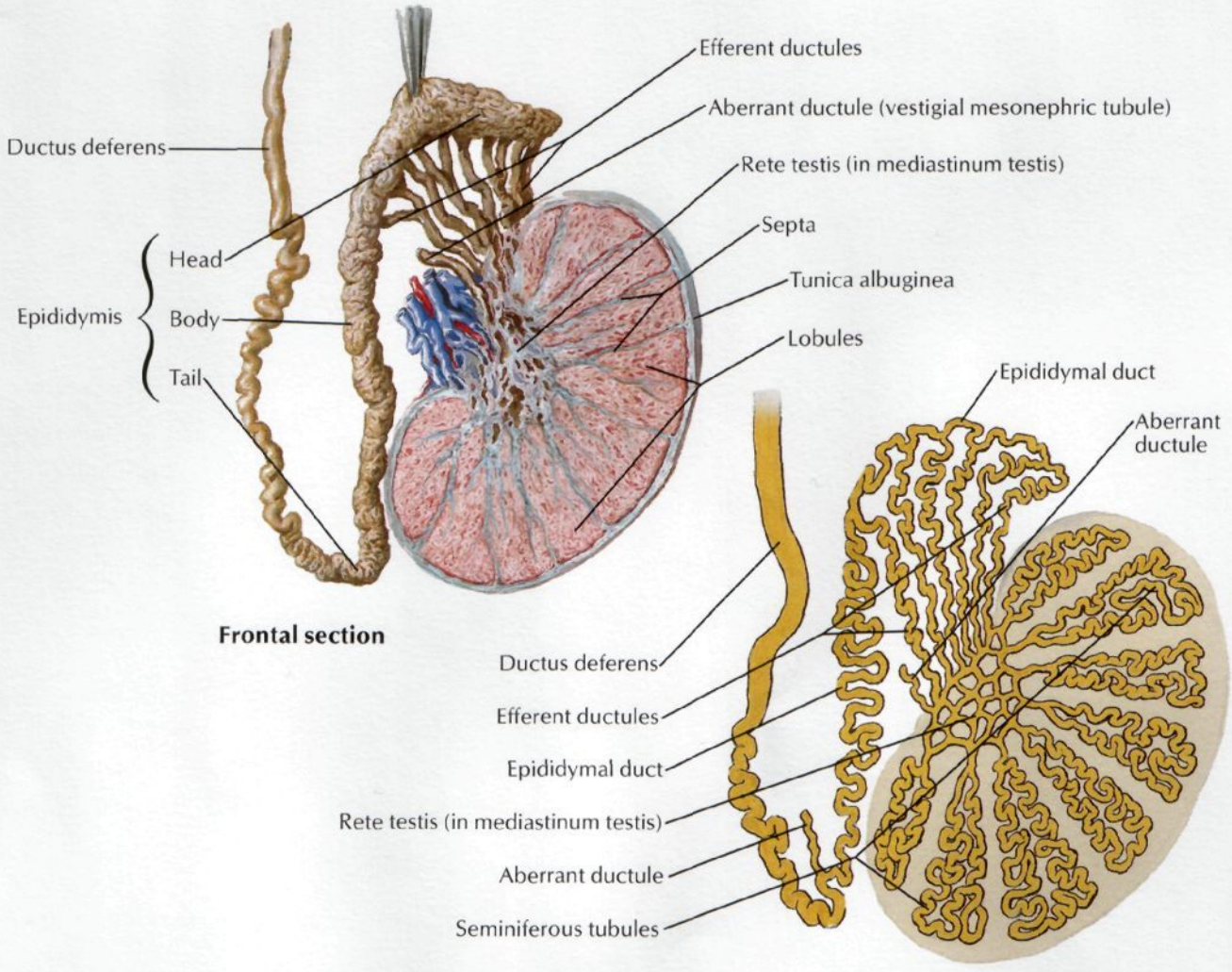

Frontal section

Schema

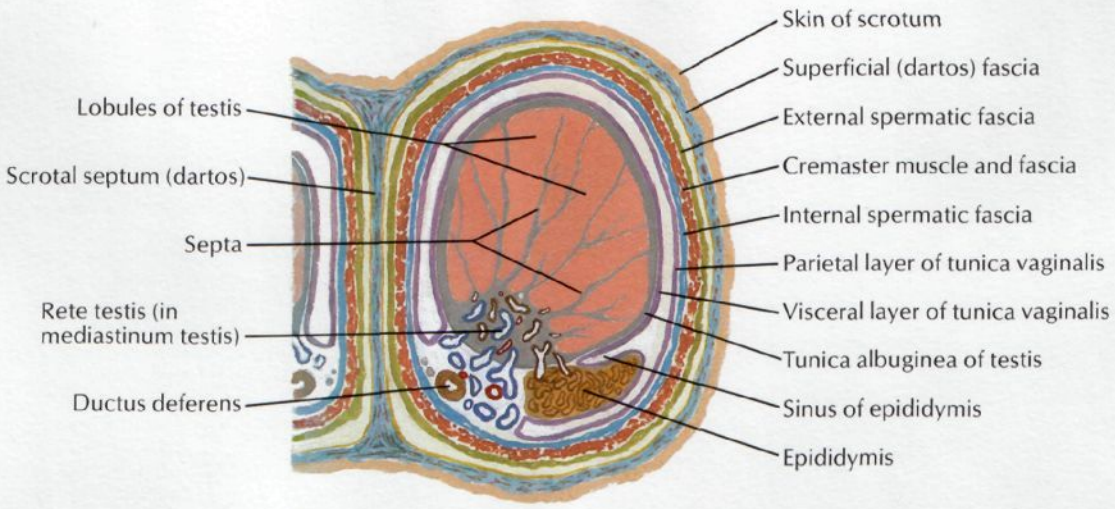

Cross section through scrotum and testis

F. Netter M.D.
©ICON

Rectum In Situ: Female and Male

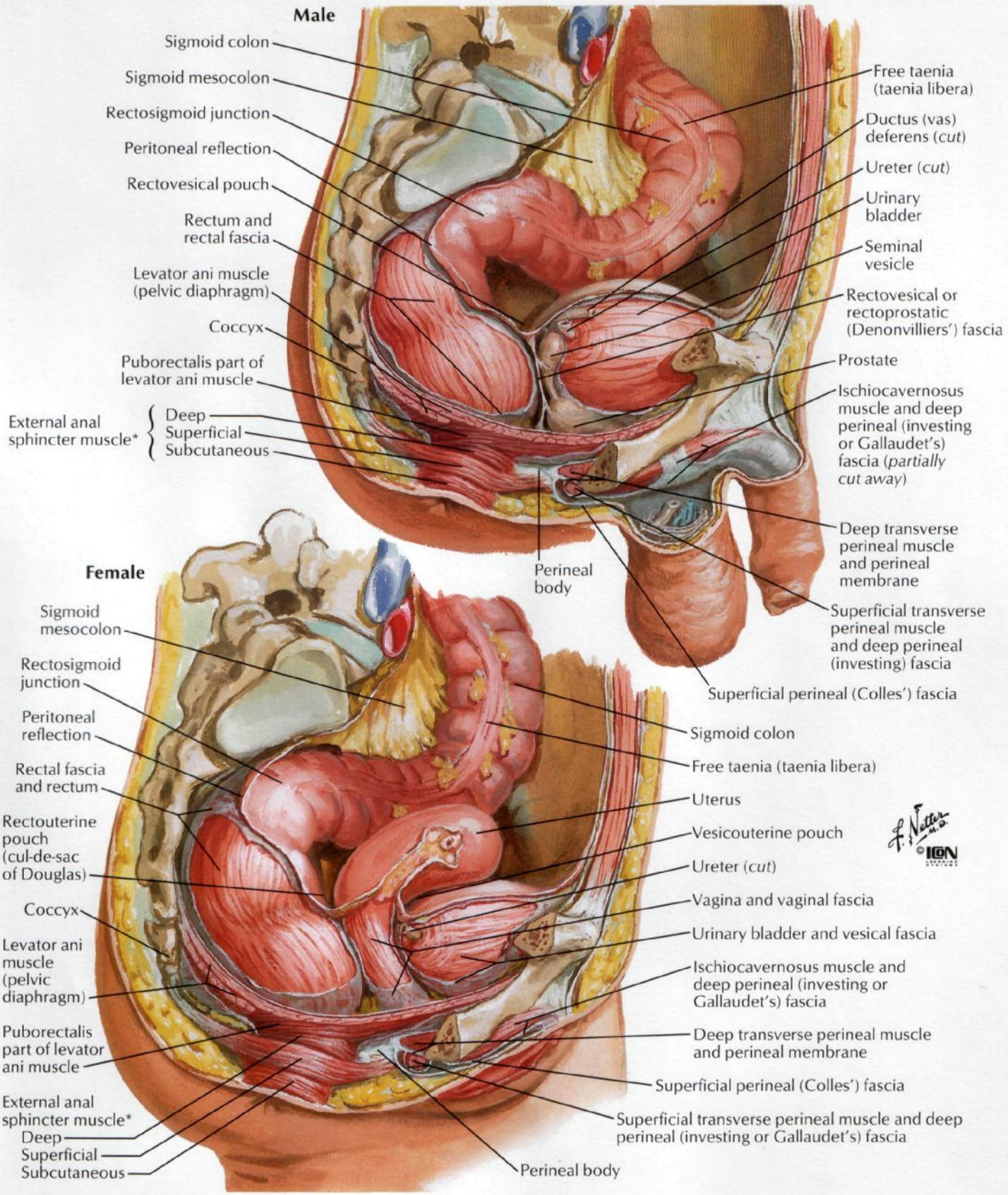

*Parts variable and often indistinct

SEE ALSO PLATES 306, 390–393

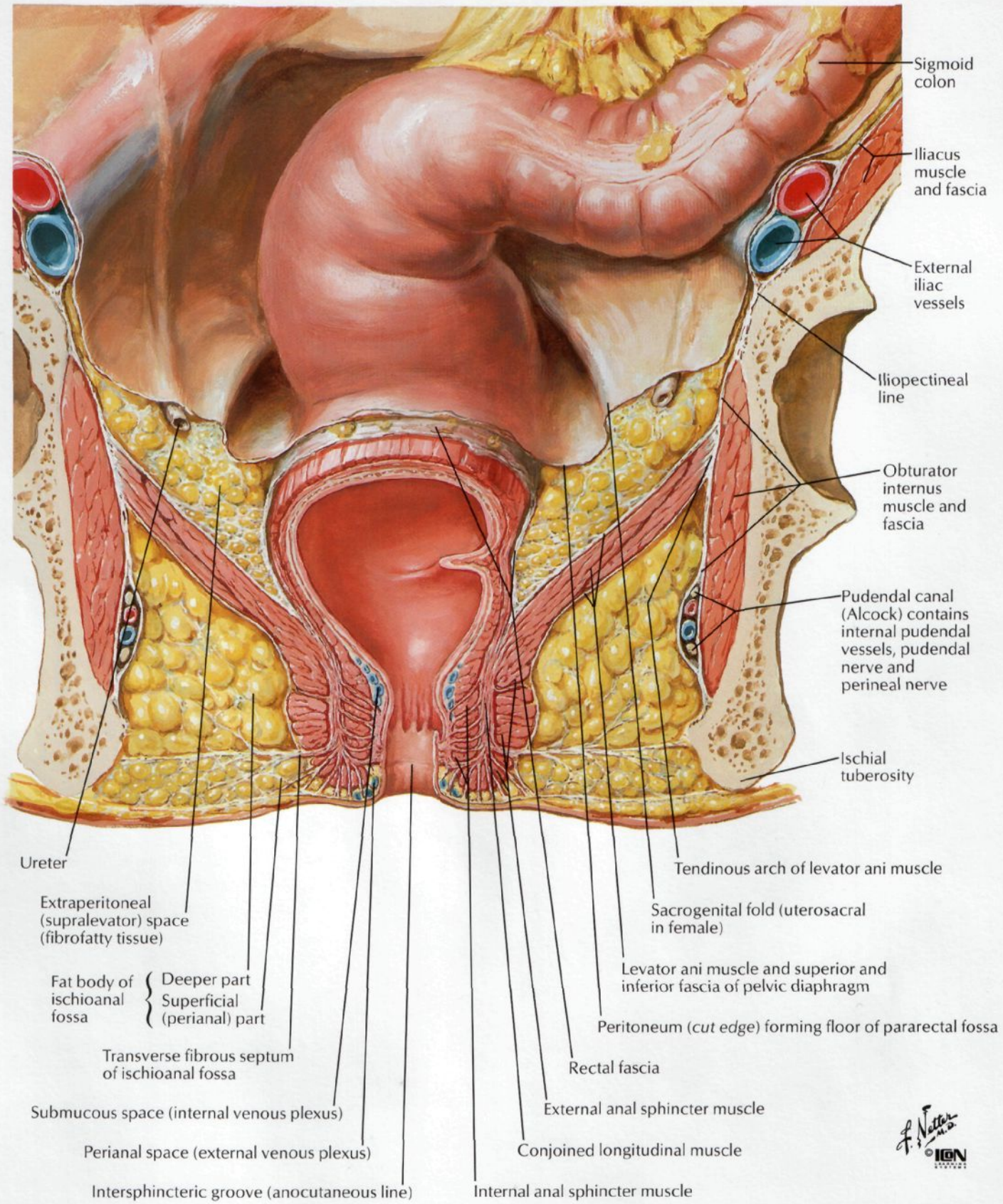

Rectum and Anal Canal

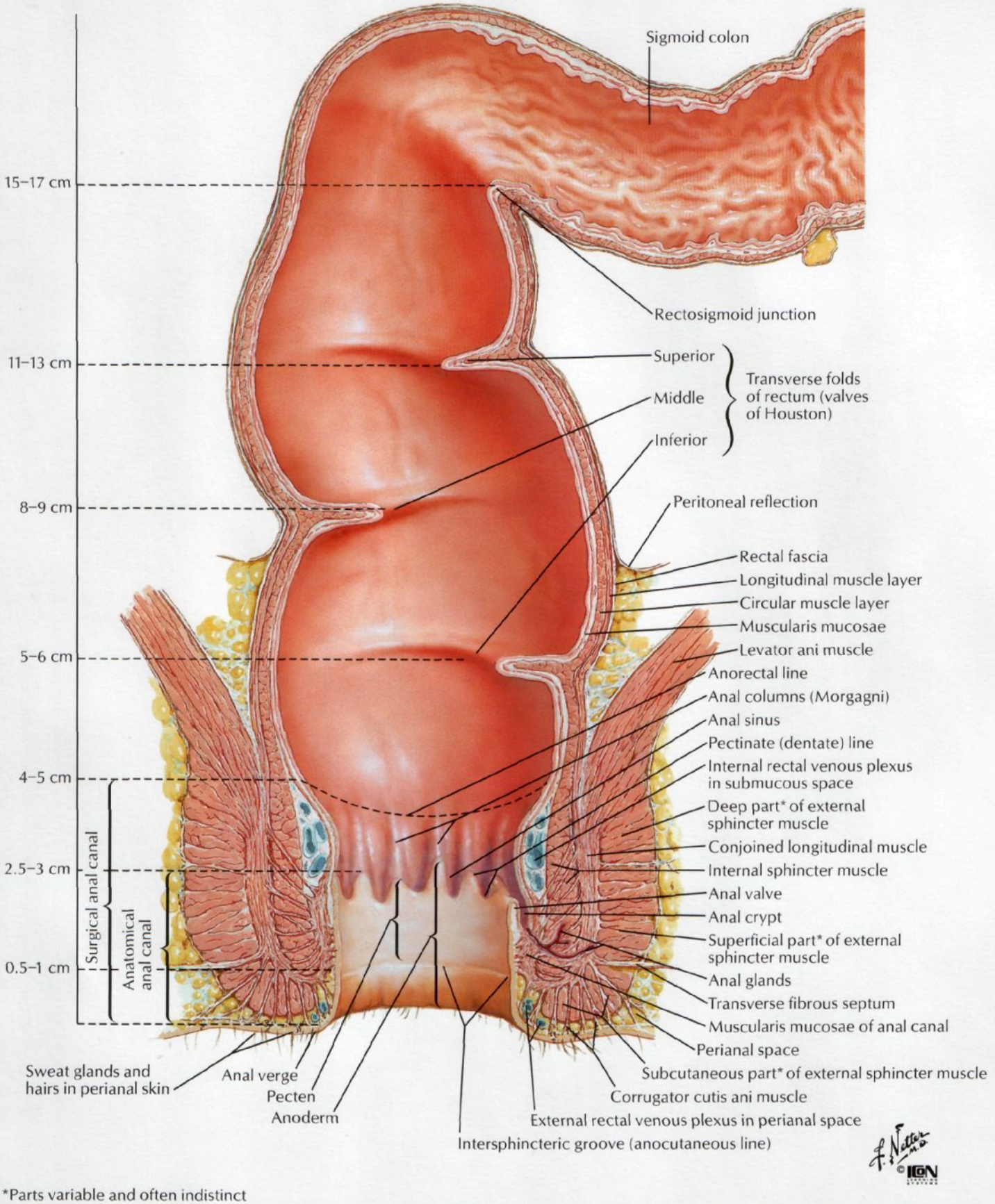

*Parts variable and often indistinct

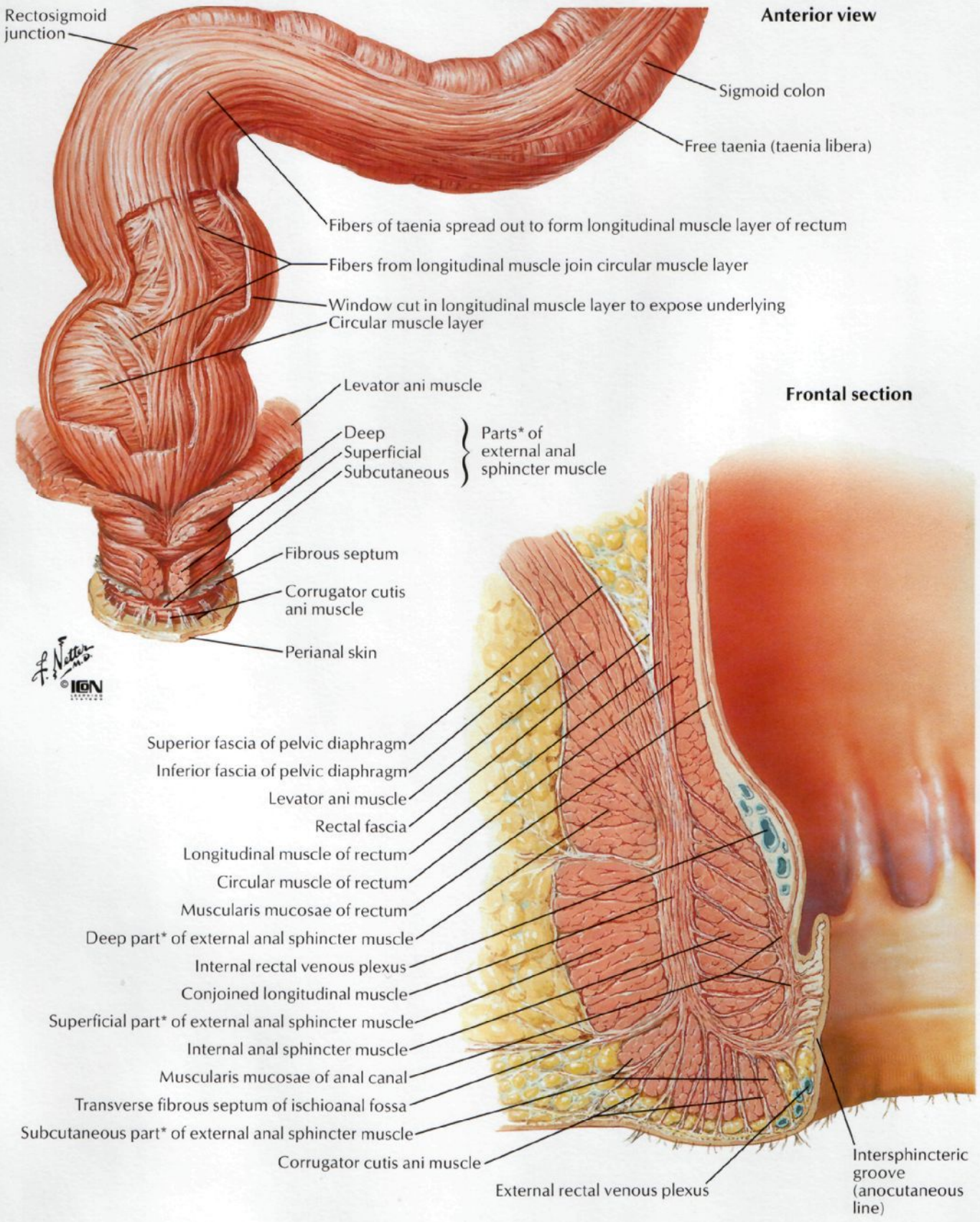

*Parts variable and often indistinct

External Anal Sphincter Muscle: Perineal Views

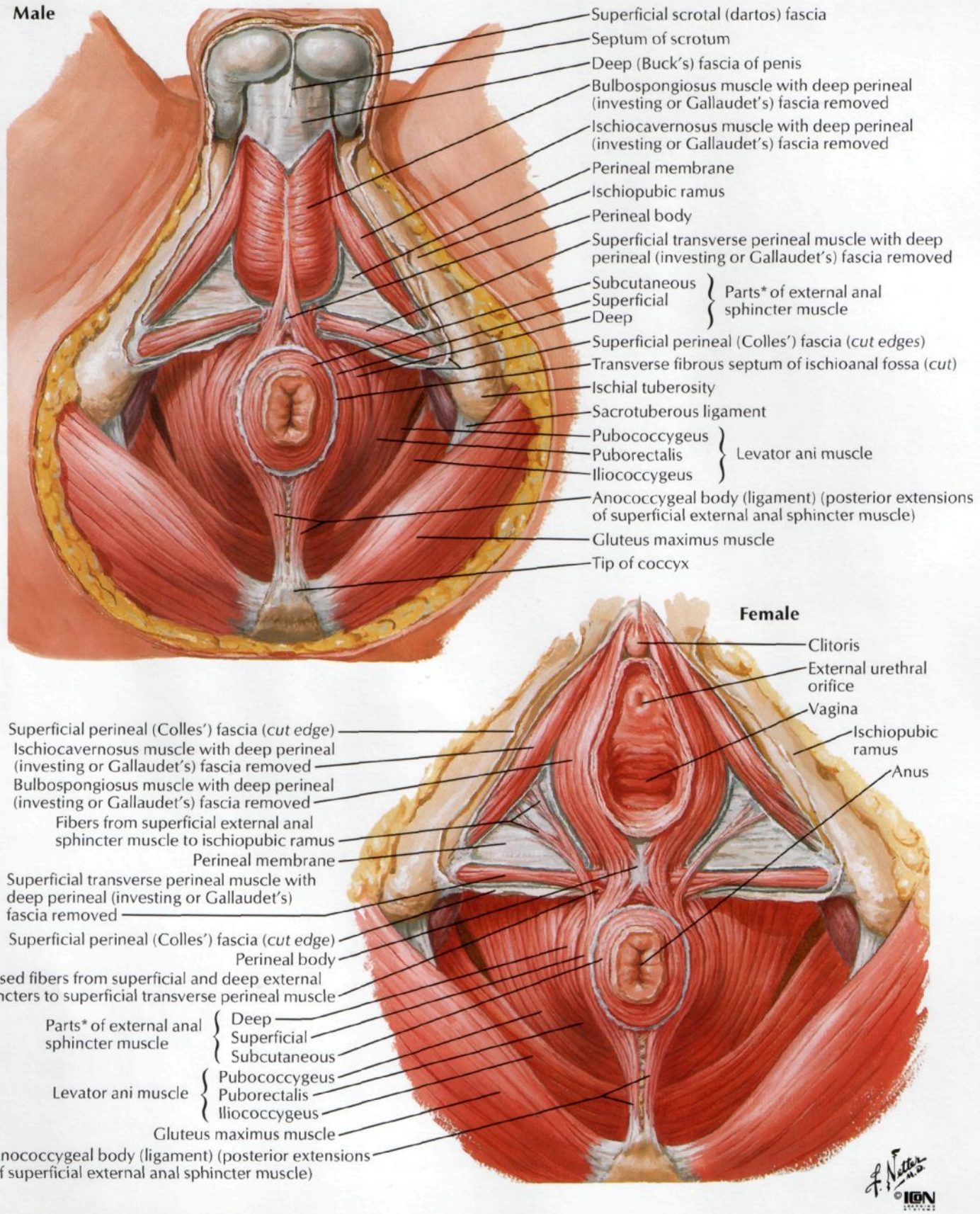

*Parts variable and often indistinct

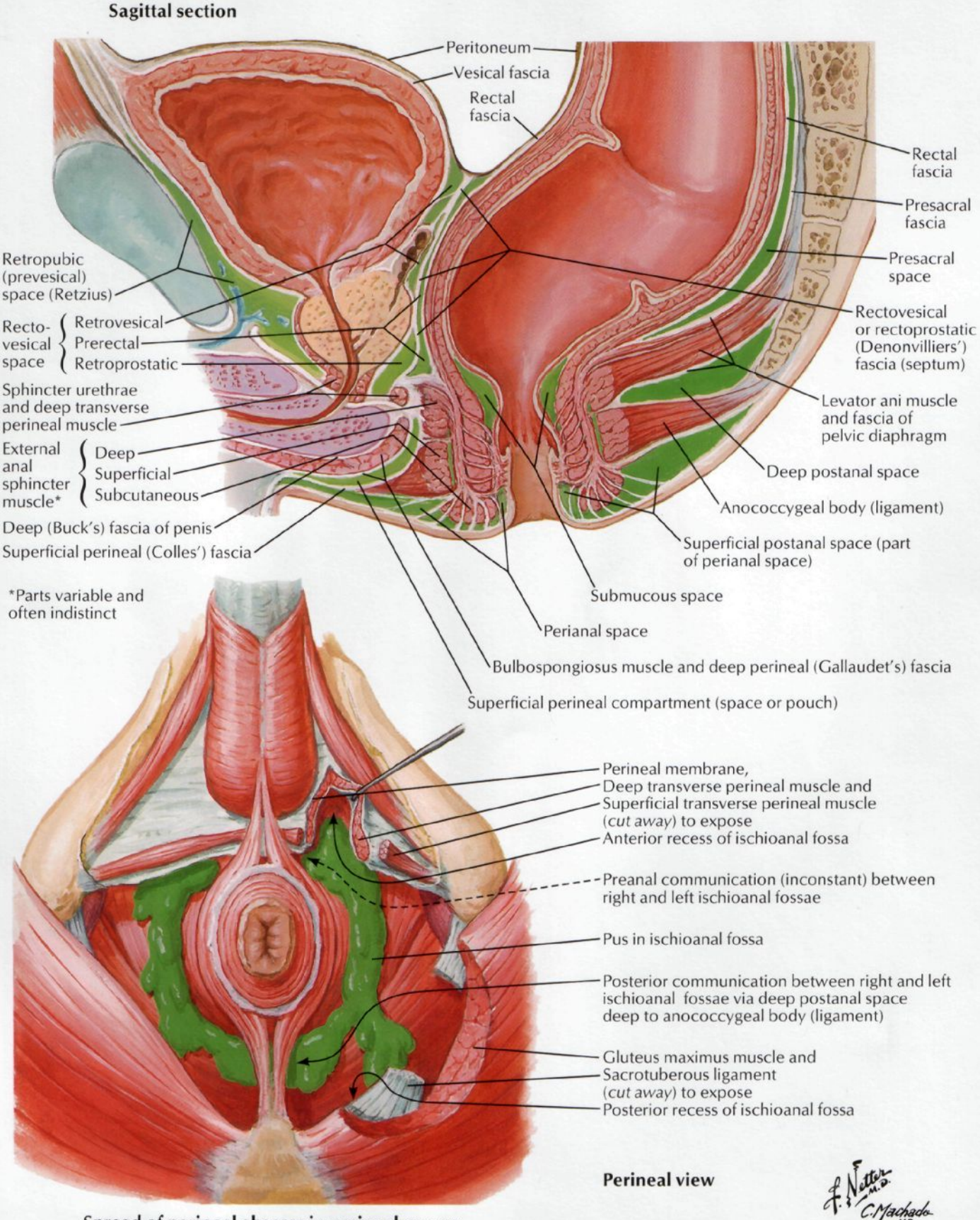

Spread of perineal abscess in perineal spaces

Arteries of Rectum and Anal Canal

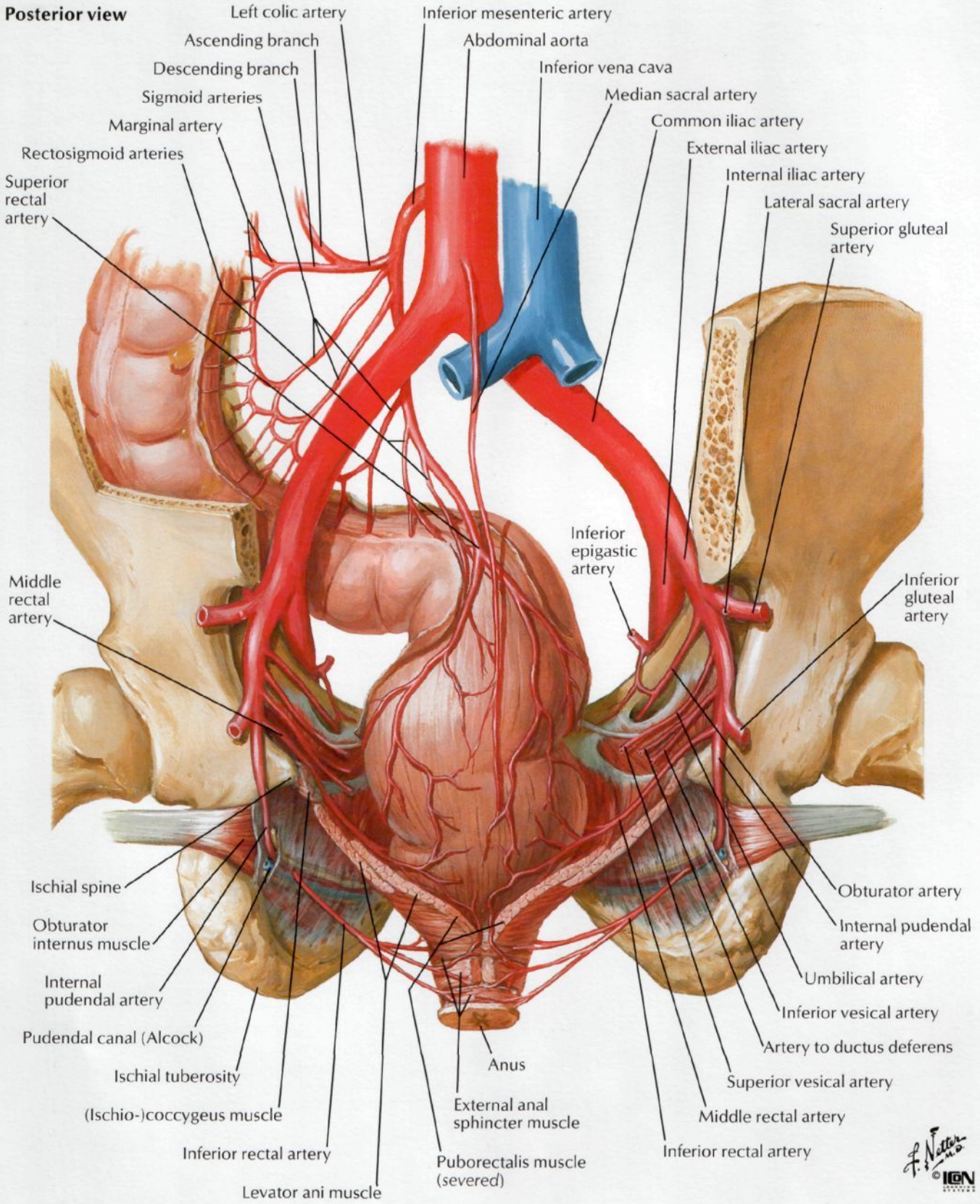

Anterior view

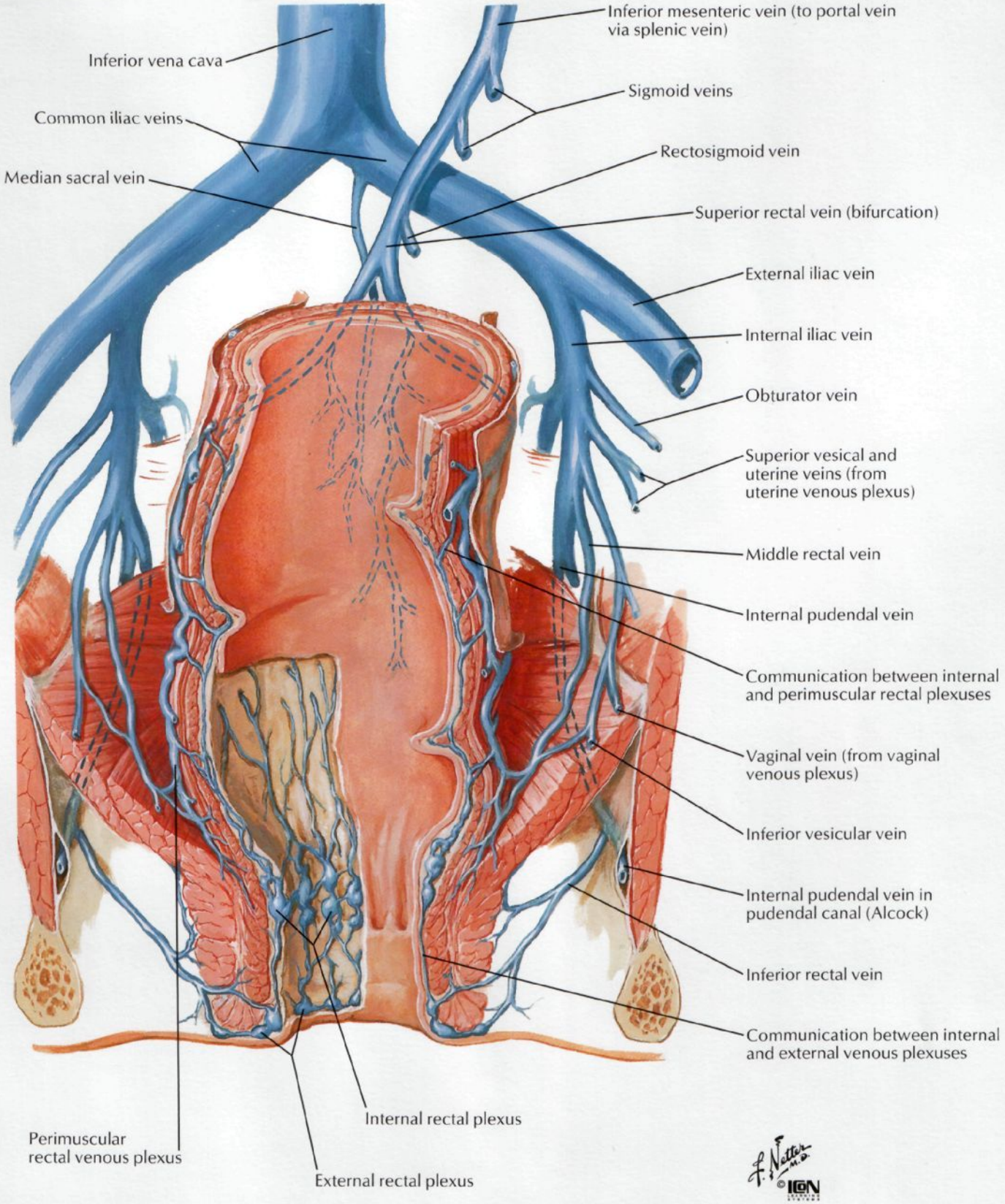

Arteries and Veins of Pelvic Organs: Female

Anterior view

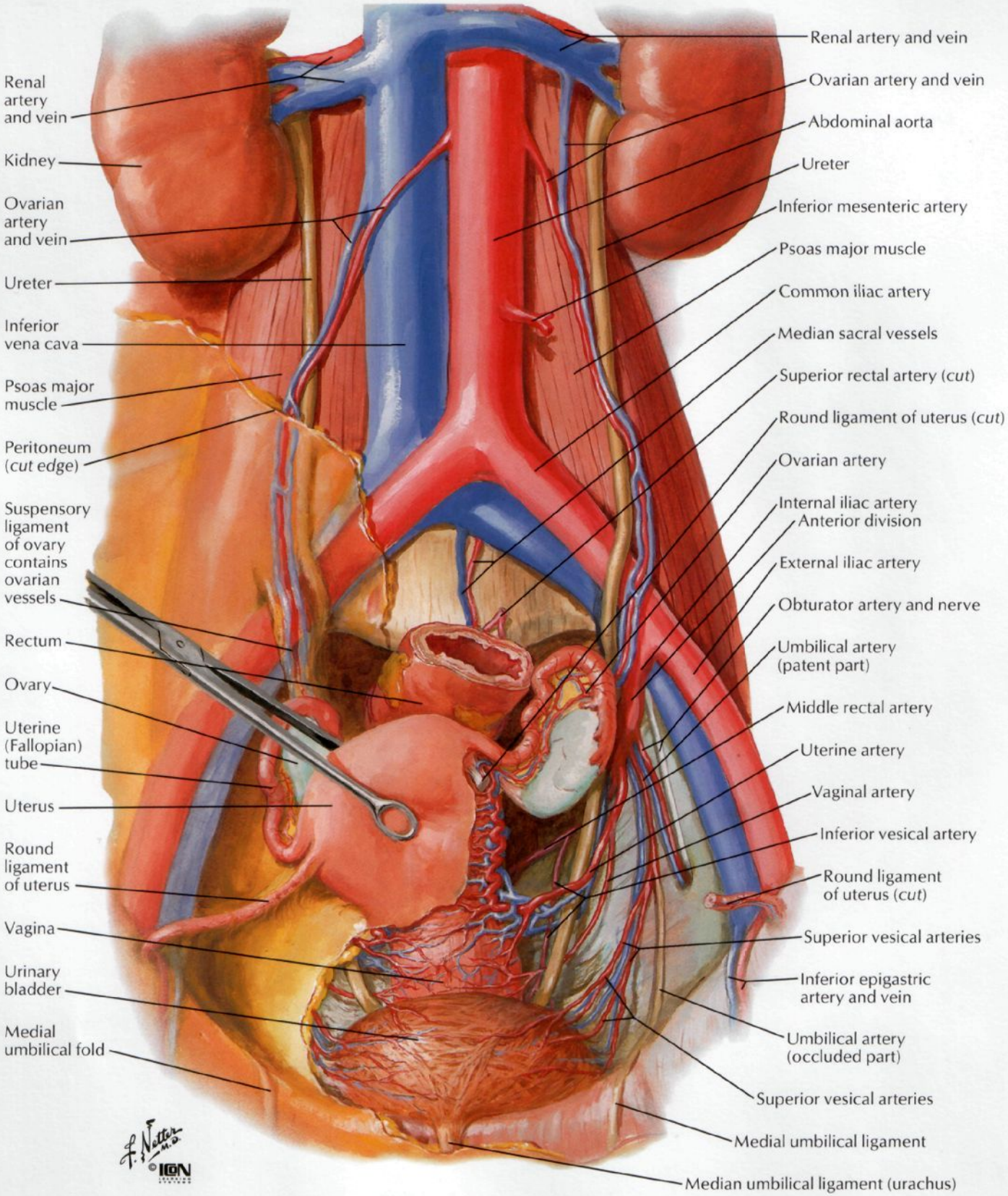

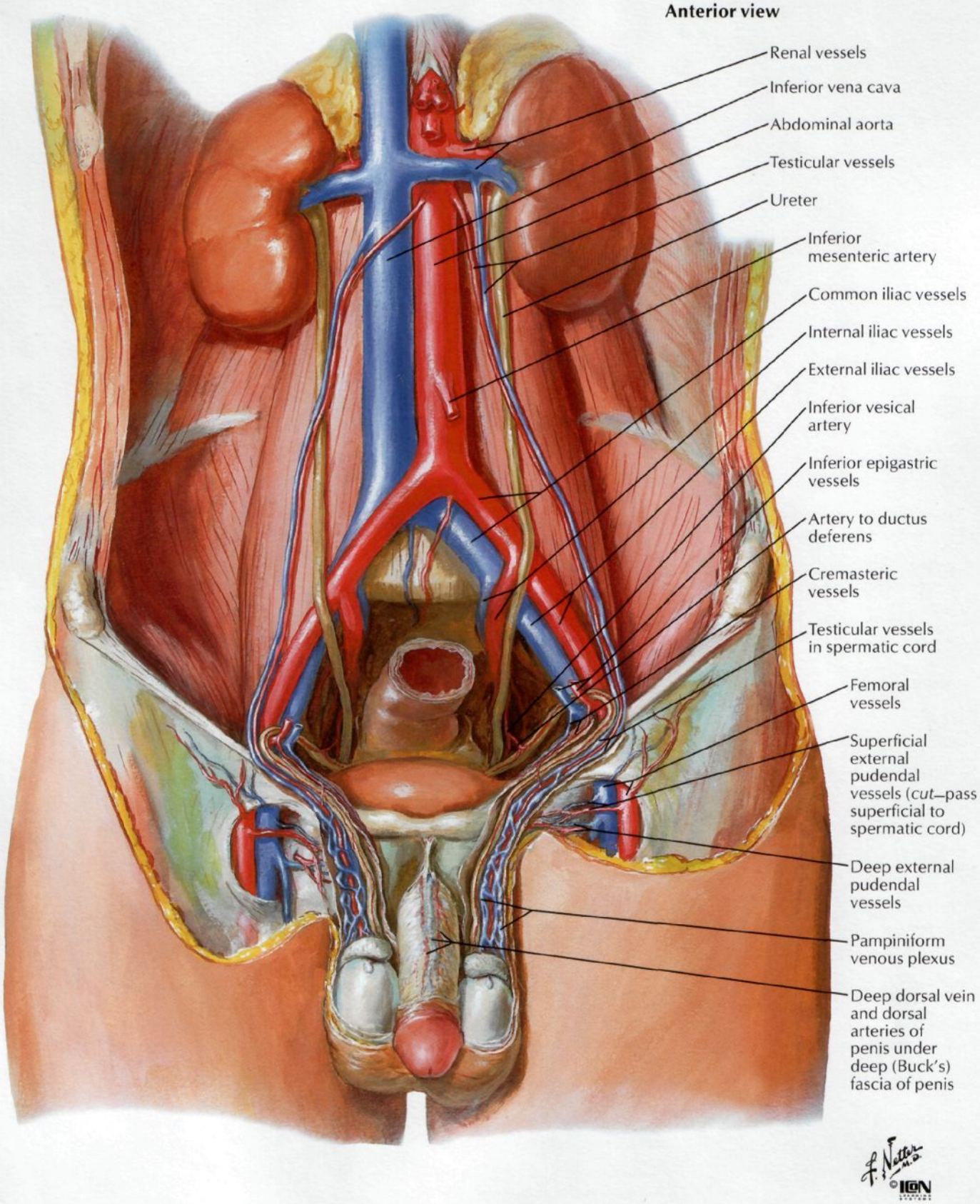
Anterior view
Renal vessels
Inferior vena cava
Abdominal aorta
Testicular vessels
Ureter
Inferior mesenteric artery
Common iliac vessels
Internal iliac vessels
External iliac vessels
Inferior vesical artery
Inferior epigastric vessels
Artery to ductus deferens
Cremasteric vessels
Testicular vessels in spermatic cord
Femoral vessels
Superficial external pudendal vessels (*cut*—pass superficial to spermatic cord)
Deep external pudendal vessels
Pampiniform venous plexus
Deep dorsal vein and dorsal arteries of penis under deep (Buck's) fascia of penis

Arteries and Veins of Pelvis: Female

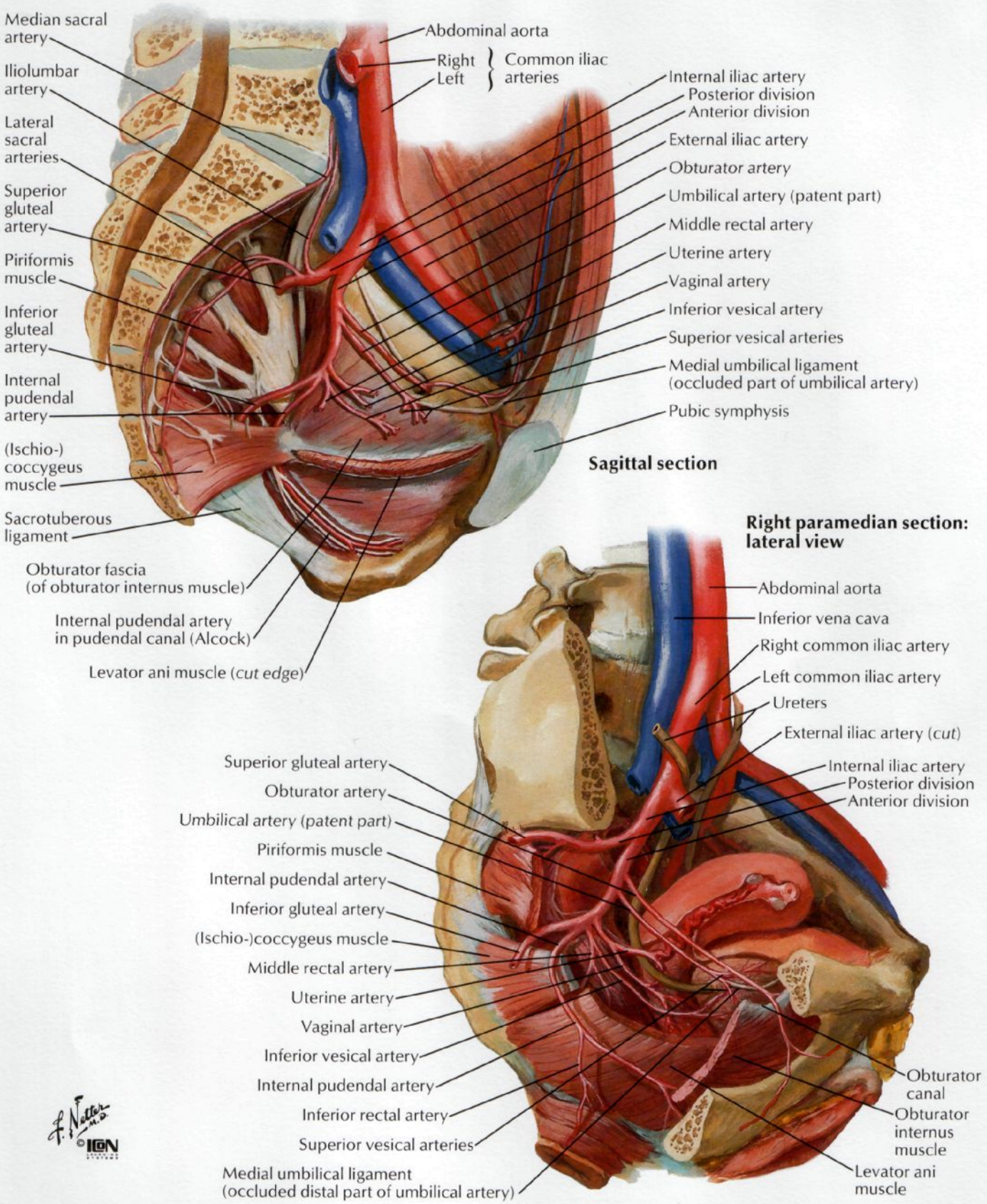

Left paramedian section: lateral view

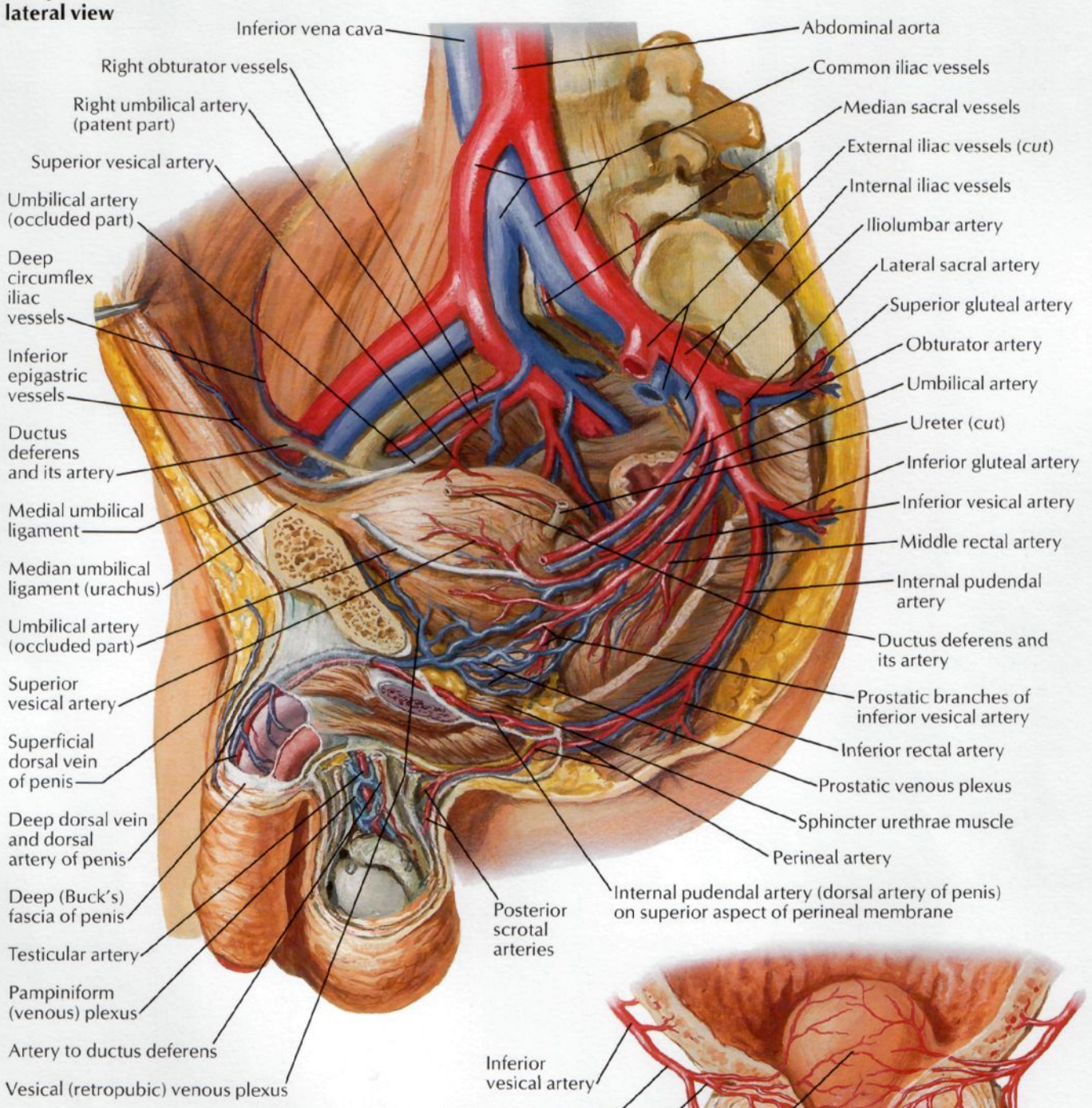

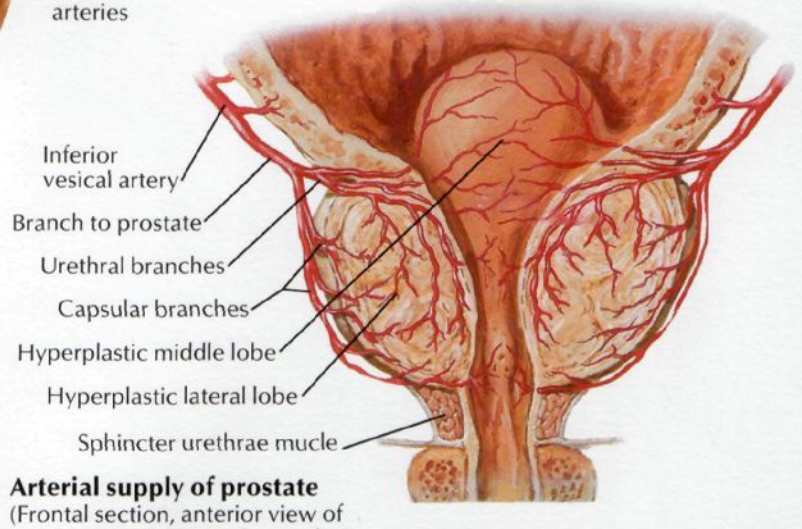

Arterial supply of prostate
(Frontal section, anterior view of specimen with benign hyperplasia)

F. Netter, M.D. C. Machado, M.D. ©ICON

Arteries and Veins of Perineum and Uterus

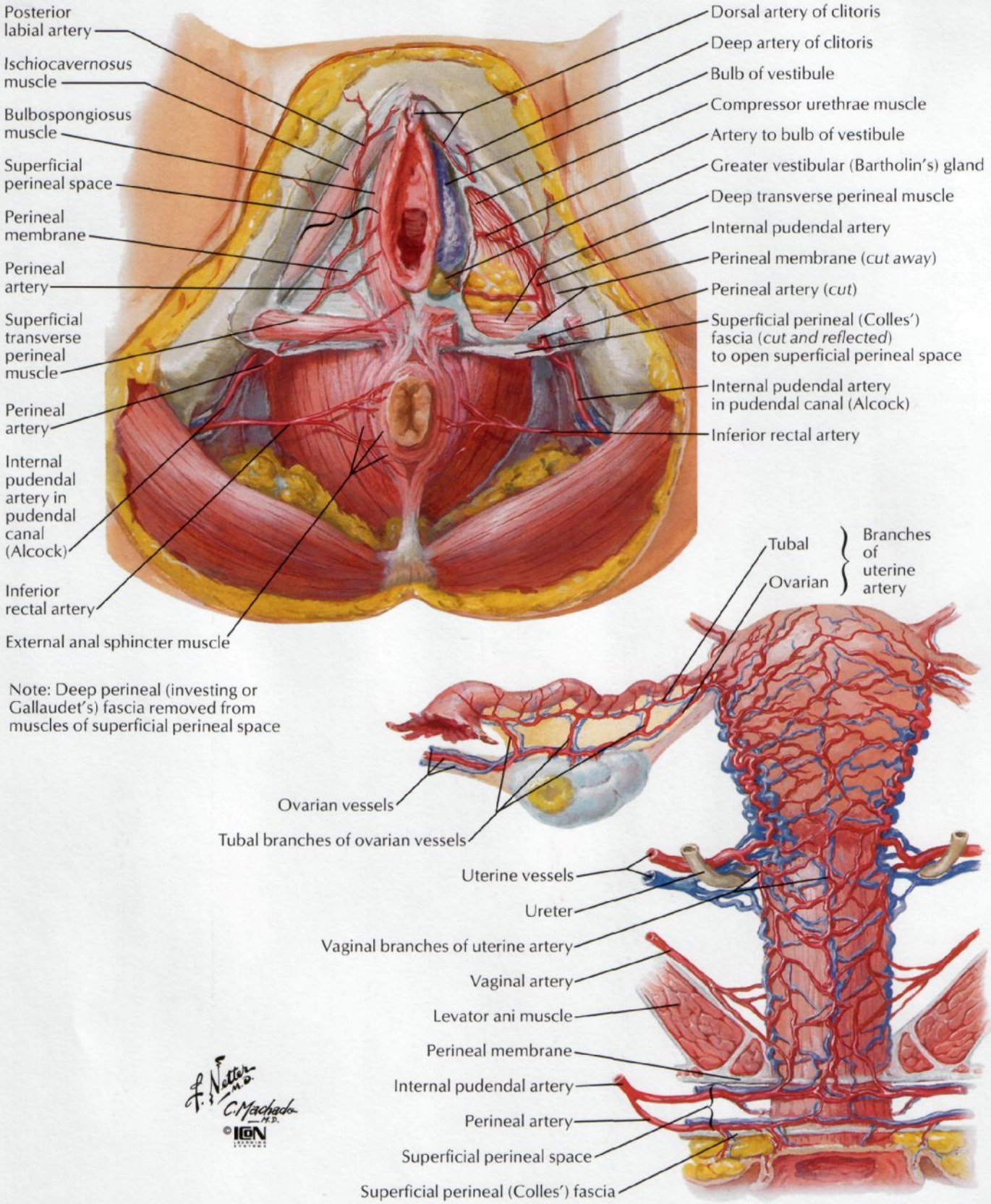

Note: Deep perineal (investing or Gallaudet's) fascia removed from muscles of superficial perineal space

F. Netter M.D.
C. Machado M.D.
©ICON LEARNING SYSTEMS

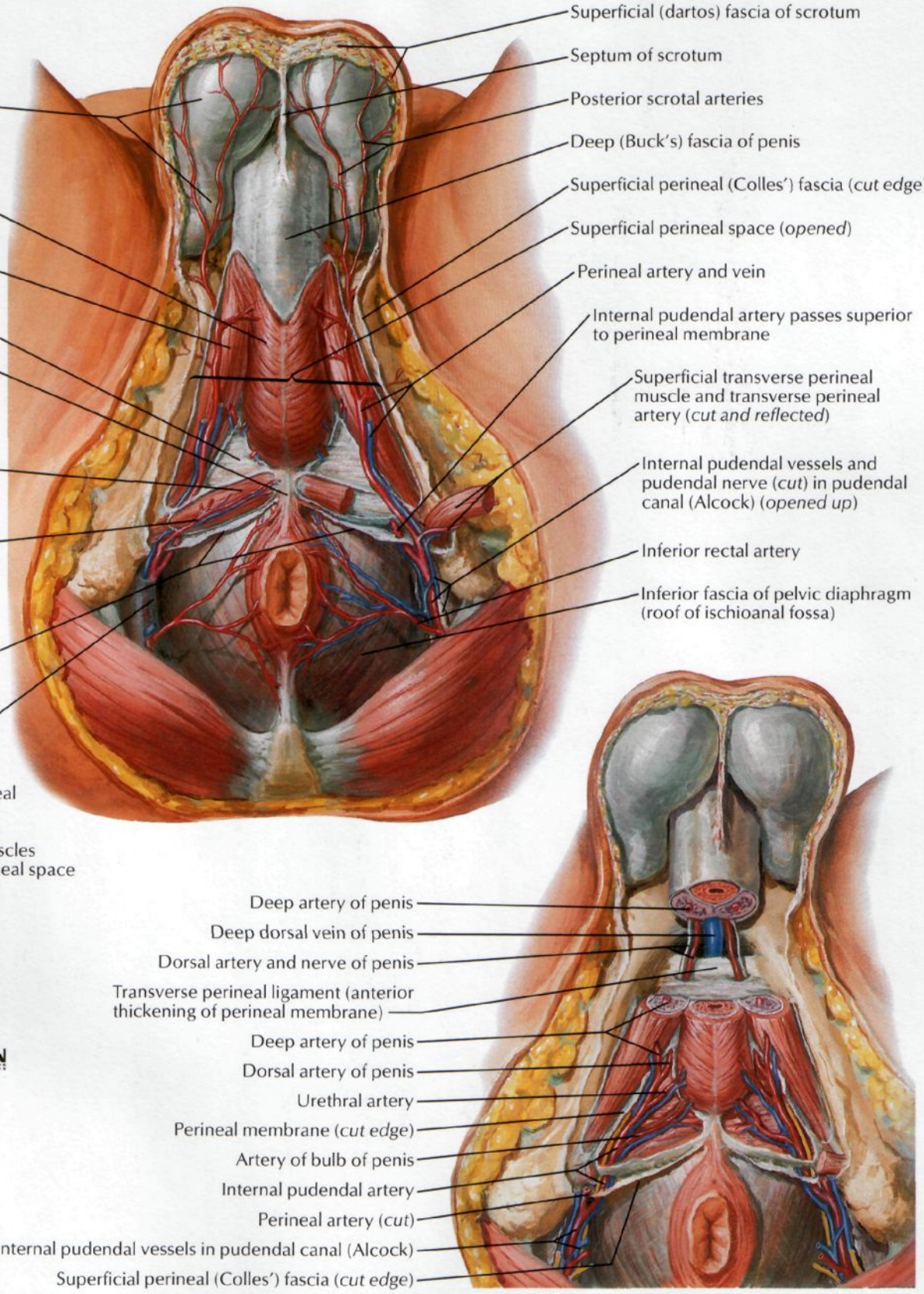
External spermatic fascia over testis and spermatic cord
Bulbospongiosus muscle
Ischiocavernosus muscle
Perineal membrane
Perineal body
Superficial transverse perineal muscle
Transverse perineal artery
Superficial perineal (Colles') fascia (cut edge)
Pudendal canal (Alcock)
Note: Deep perineal (investing or Gallaudet's) fascia removed from muscles of superficial perineal space
Superficial (dartos) fascia of scrotum
Septum of scrotum
Posterior scrotal arteries
Deep (Buck's) fascia of penis
Superficial perineal (Colles') fascia (cut edge)
Superficial perineal space (opened)
Perineal artery and vein
Internal pudendal artery passes superior to perineal membrane
Superficial transverse perineal muscle and transverse perineal artery (cut and reflected)
Internal pudendal vessels and pudendal nerve (cut) in pudendal canal (Alcock) (opened up)
Inferior rectal artery
Inferior fascia of pelvic diaphragm (roof of ischioanal fossa)
Deep artery of penis
Deep dorsal vein of penis
Dorsal artery and nerve of penis
Transverse perineal ligament (anterior thickening of perineal membrane)
Deep artery of penis
Dorsal artery of penis
Urethral artery
Perineal membrane (cut edge)
Artery of bulb of penis
Internal pudendal artery
Perineal artery (cut)
Internal pudendal vessels in pudendal canal (Alcock)
Superficial perineal (Colles') fascia (cut edge)

Lymph Vessels and Nodes of Pelvis and Genitalia: Female

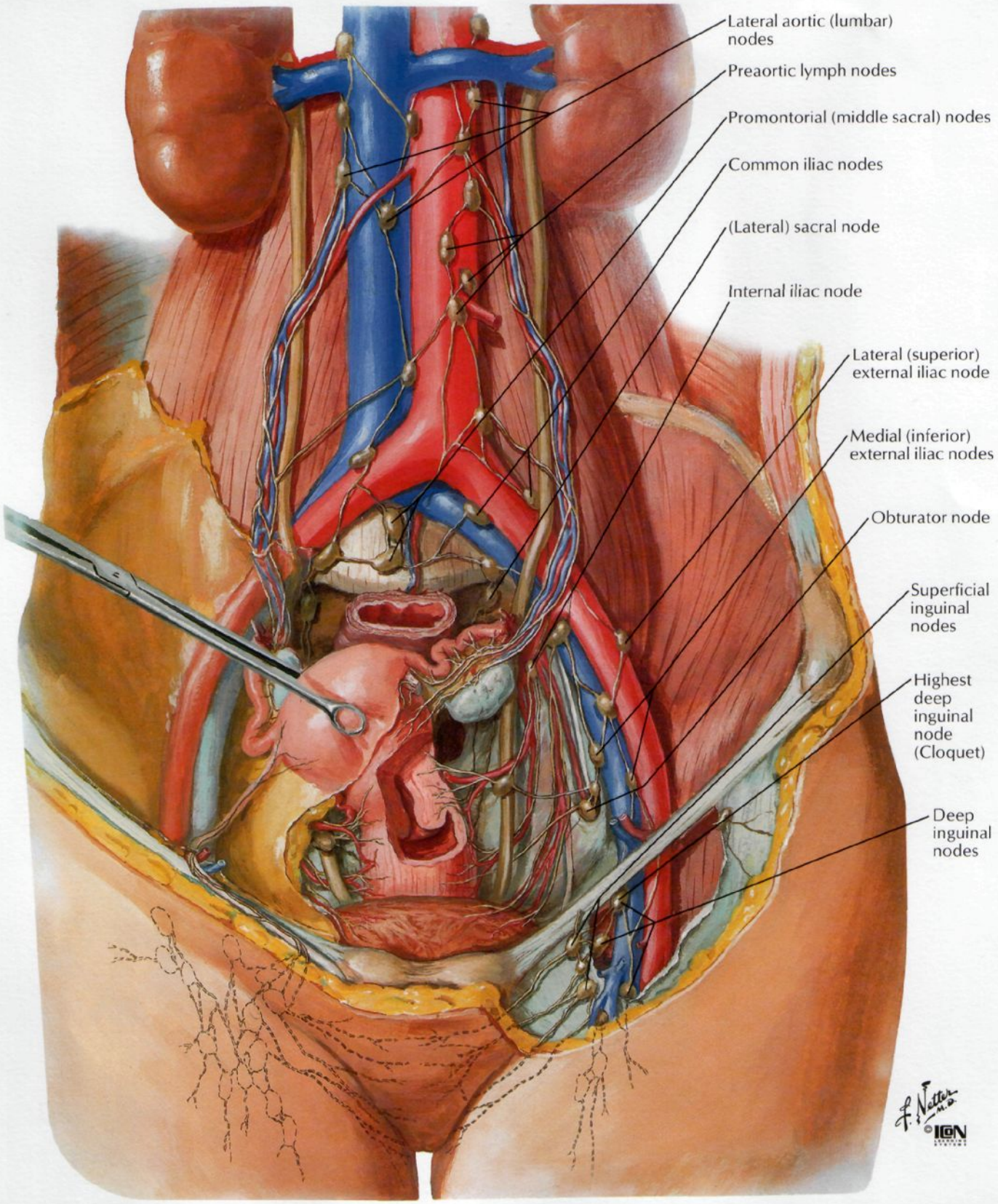

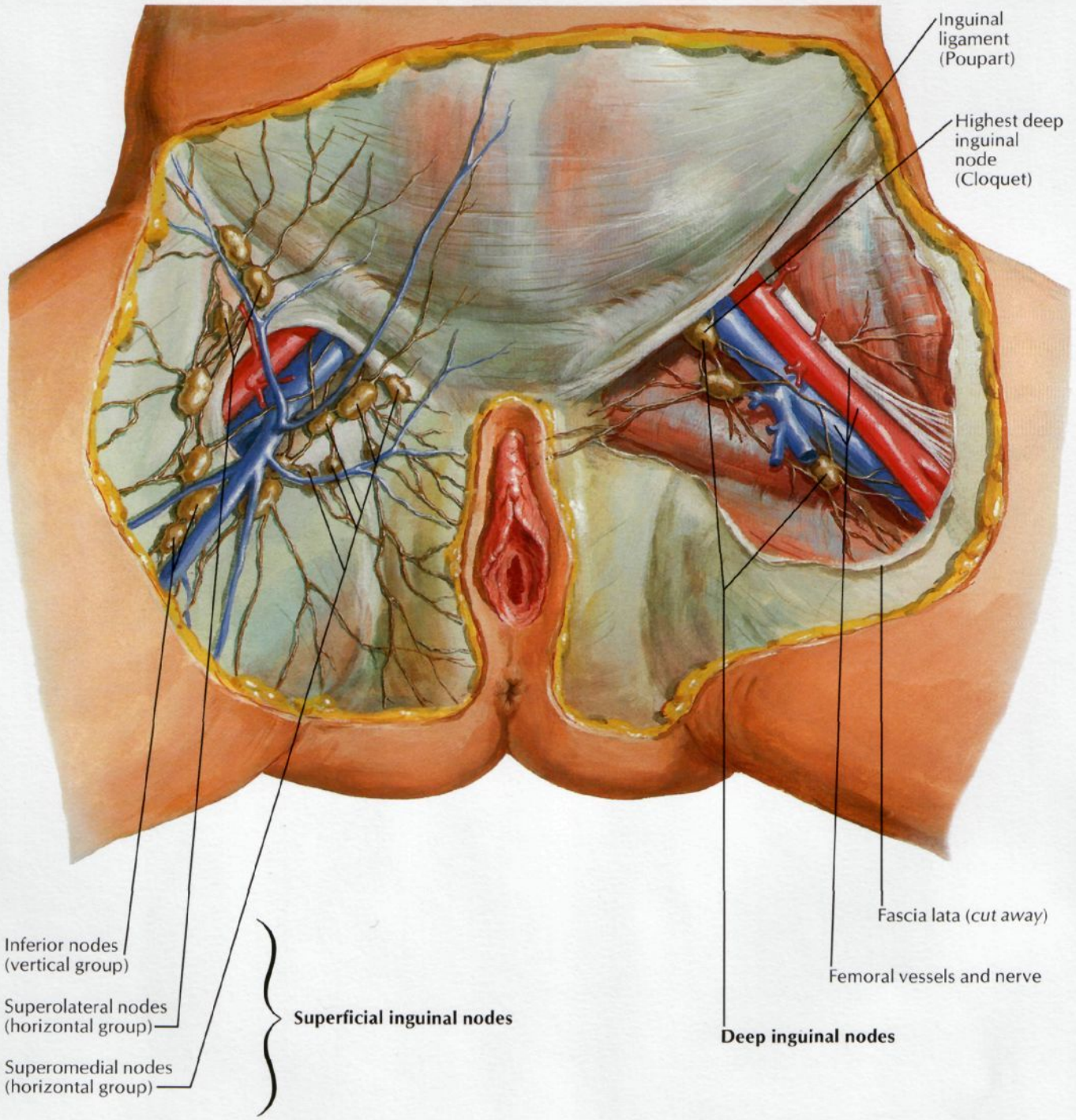
Inguinal ligament (Poupart)
Highest deep inguinal node (Cloquet)
Inferior nodes (vertical group)
Superolateral nodes (horizontal group)
Superomedial nodes (horizontal group)
Superficial inguinal nodes
Deep inguinal nodes
Fascia lata (cut away)
Femoral vessels and nerve

Lymph Vessels and Nodes of Pelvis and Genitalia: Male

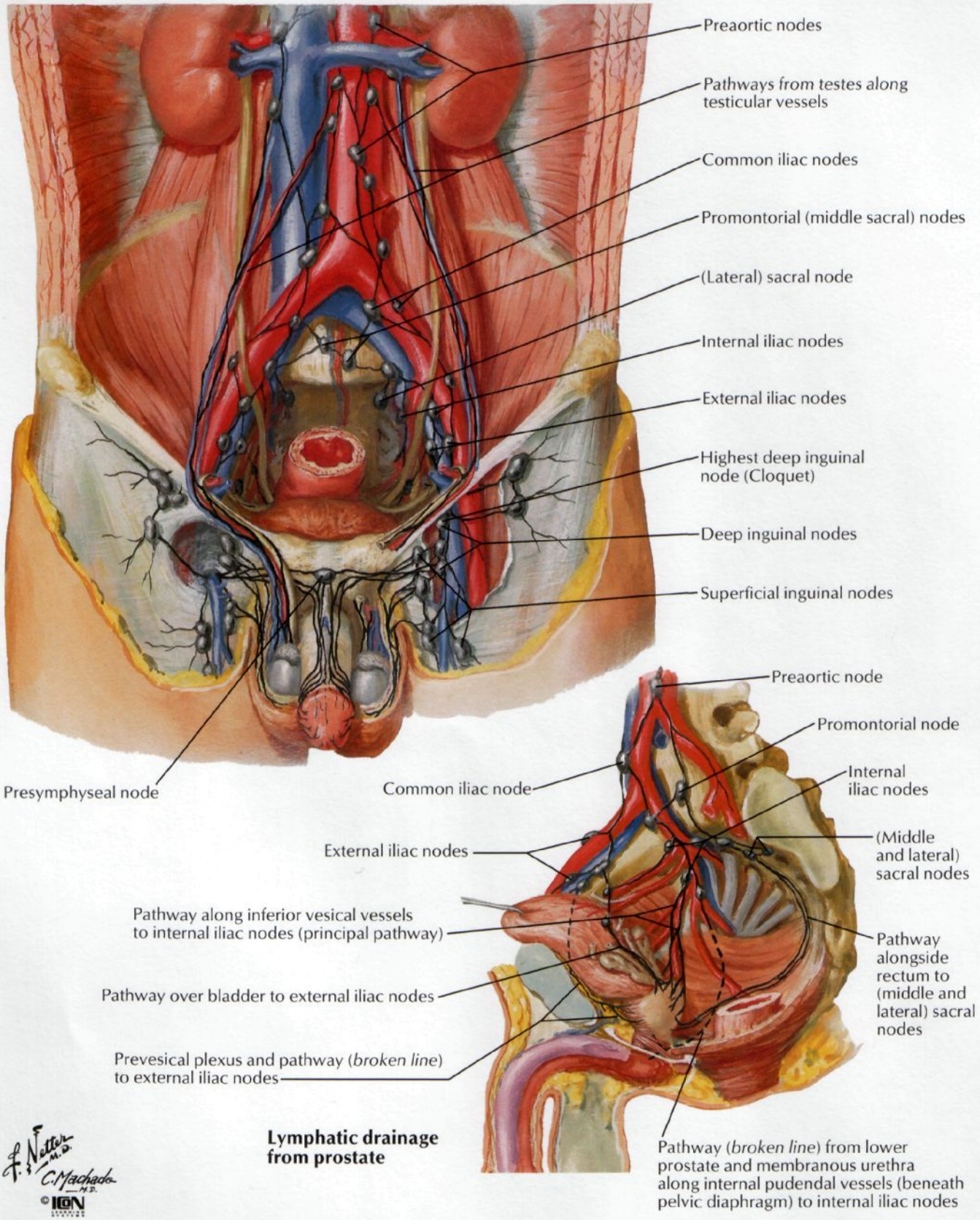

Lymphatic drainage from prostate

F. Netter, M.D.
C. Machado, M.D.
©ICON

Nerves of External Genitalia: Male

SEE ALSO PLATES 159, 308

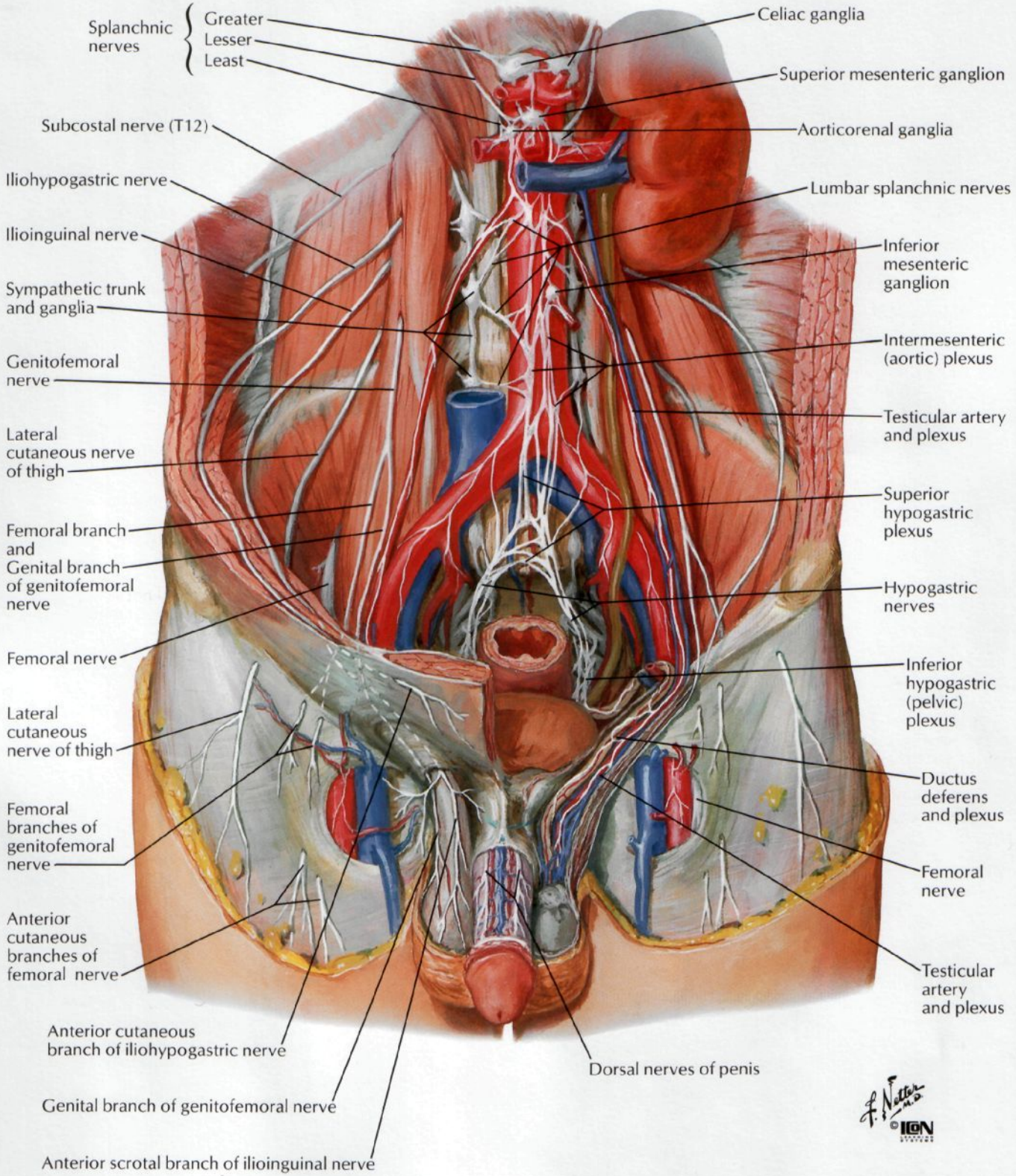

Nerves of Pelvic Viscera: Male

SEE ALSO PLATES 159, 308

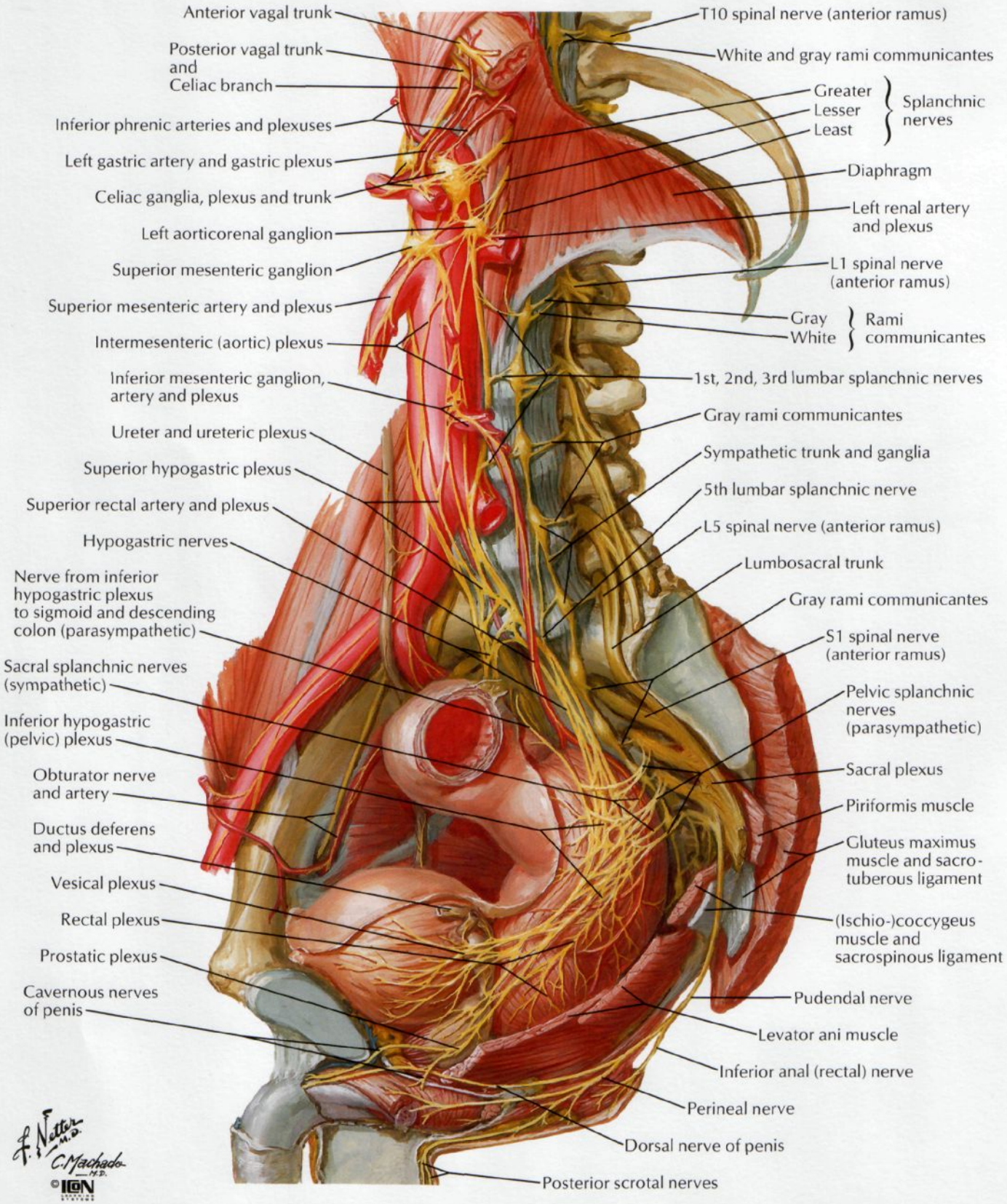

SEE ALSO PLATE 396

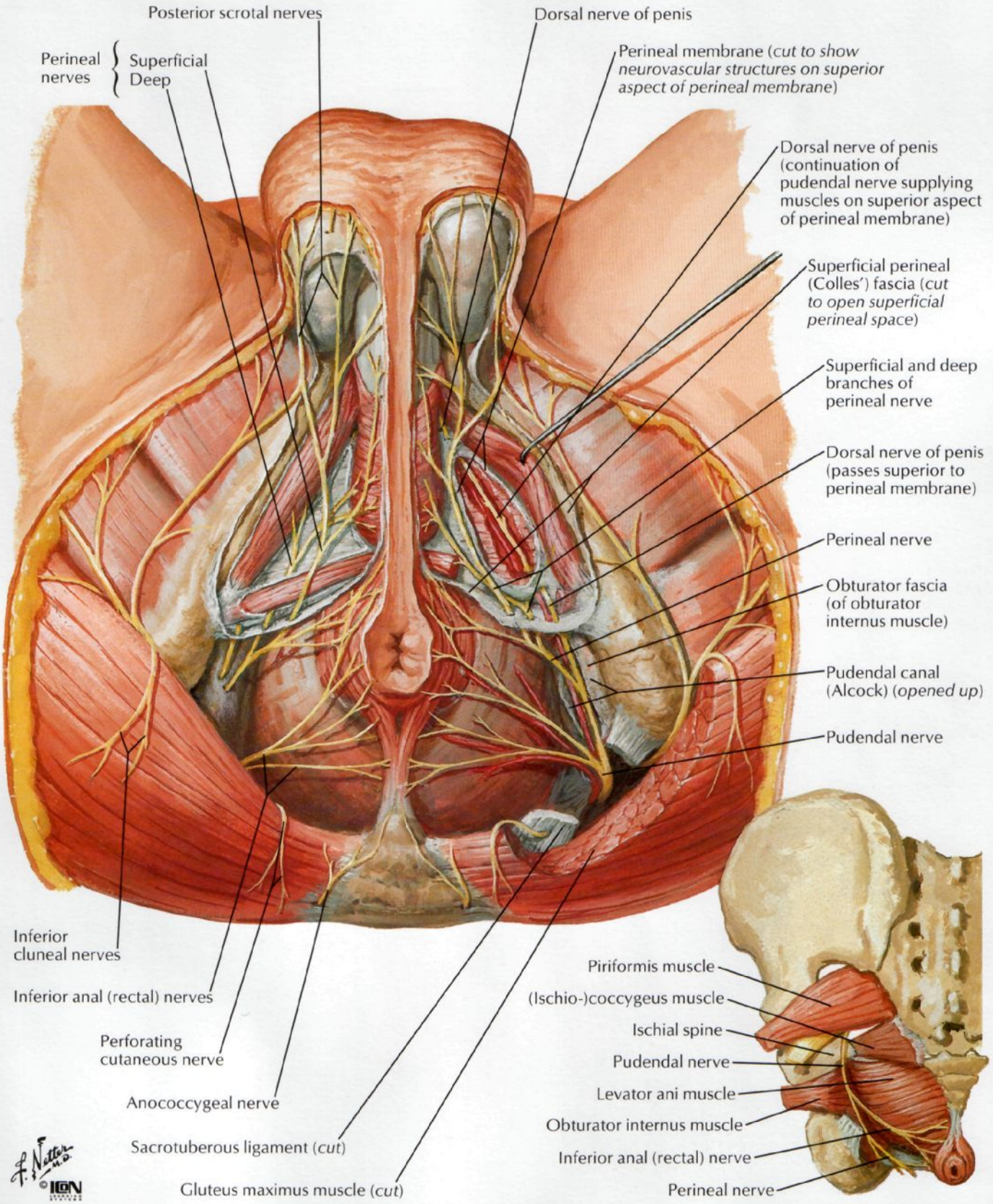

Nerves of Pelvic Viscera: Female

SEE ALSO PLATES 159, 308

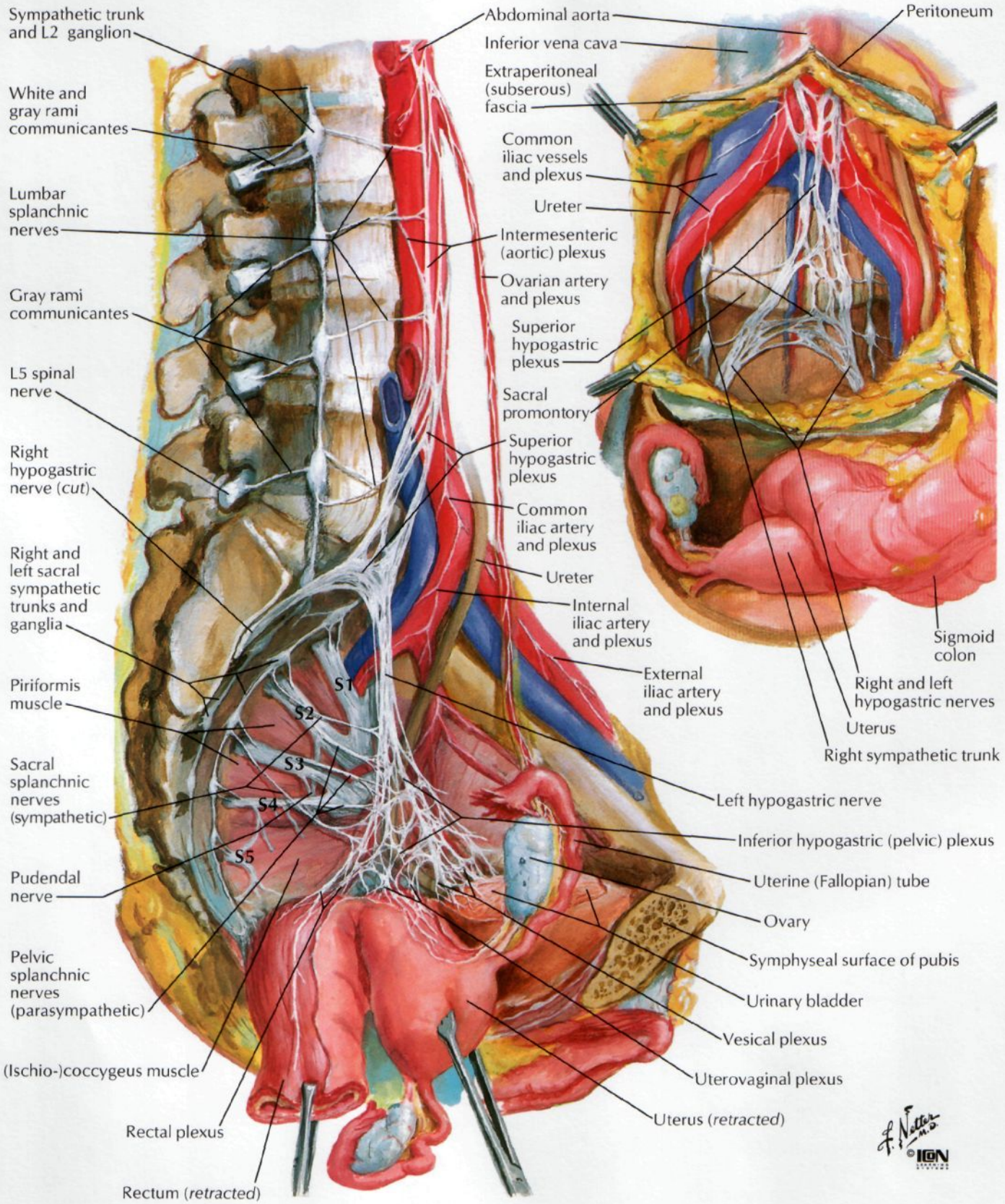

Nerves of Perineum and External Genitalia: Female

SEE ALSO PLATE 395

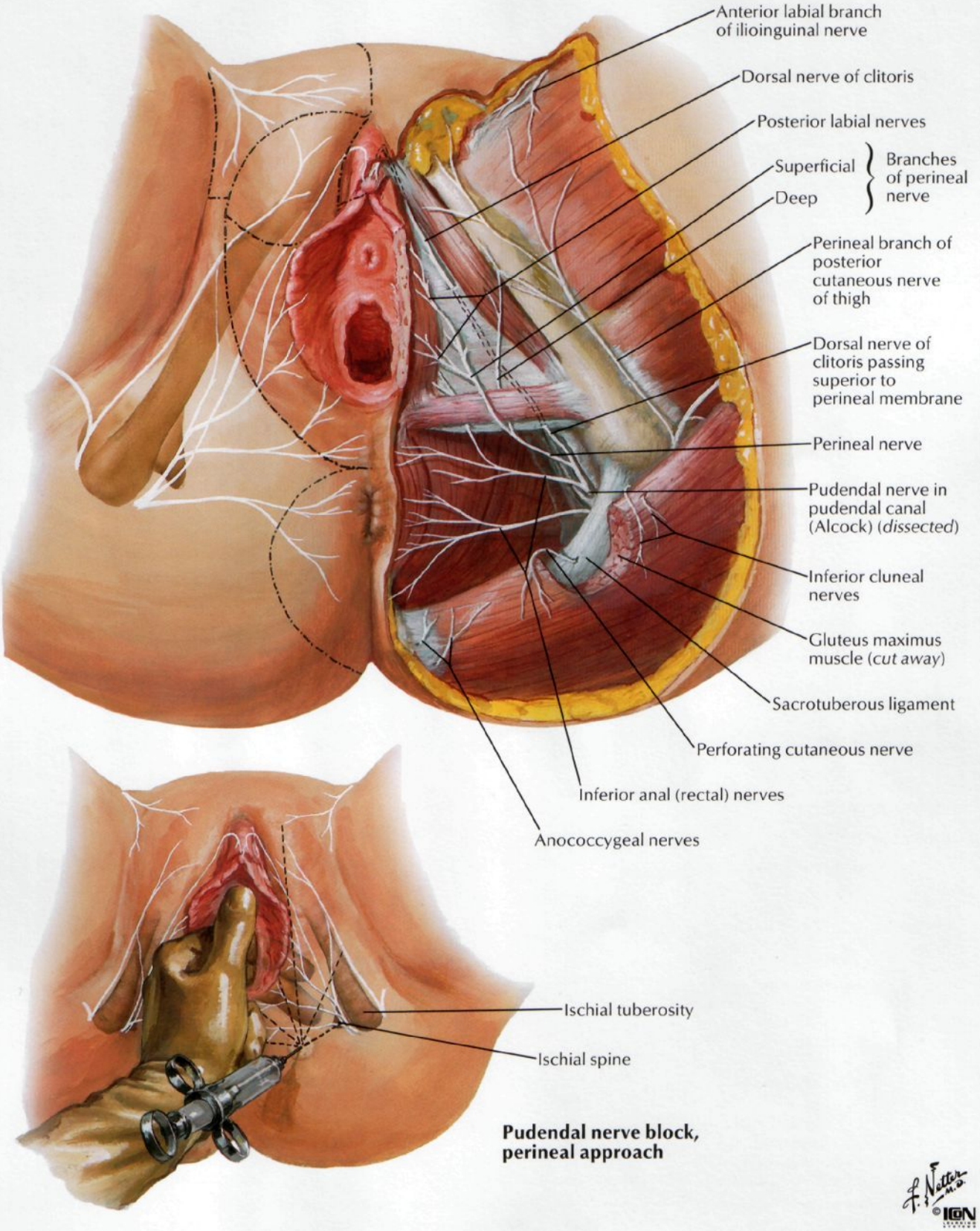

Pudendal nerve block, perineal approach

Neuropathways in Parturition

SEE ALSO PLATE 159

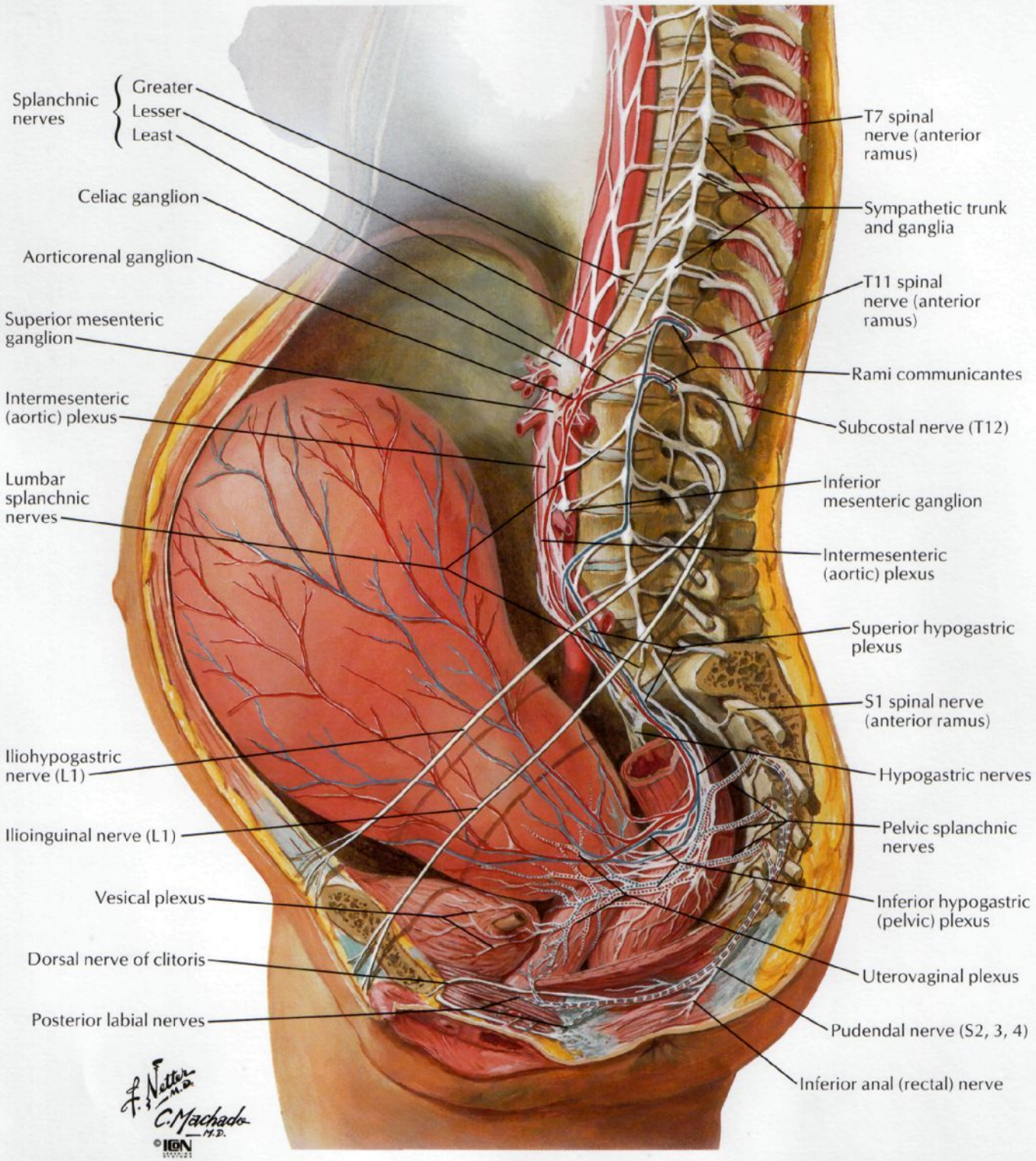

Sensory fibers from uterine body and fundus accompany sympathetic fibers via hypogastric plexuses to T11, 12 (L1?)

Motor fibers to uterine body and fundus (sympathetic)

Sensory fibers from cervix and upper vagina accompany pelvic splanchnic nerves (parasympathetic) to S2, 3, 4

Motor fibers to lower uterine segment, cervix and upper vagina (parasympathetic)

Sensory fibers from lower vagina and perineum accompany somatic fibers via pudendal nerve to S2, 3, 4

Motor fibers to lower vagina and perineum via pudendal nerve (somatic)

Innervation of Female Reproductive Organs: Schema

SEE ALSO PLATE 160

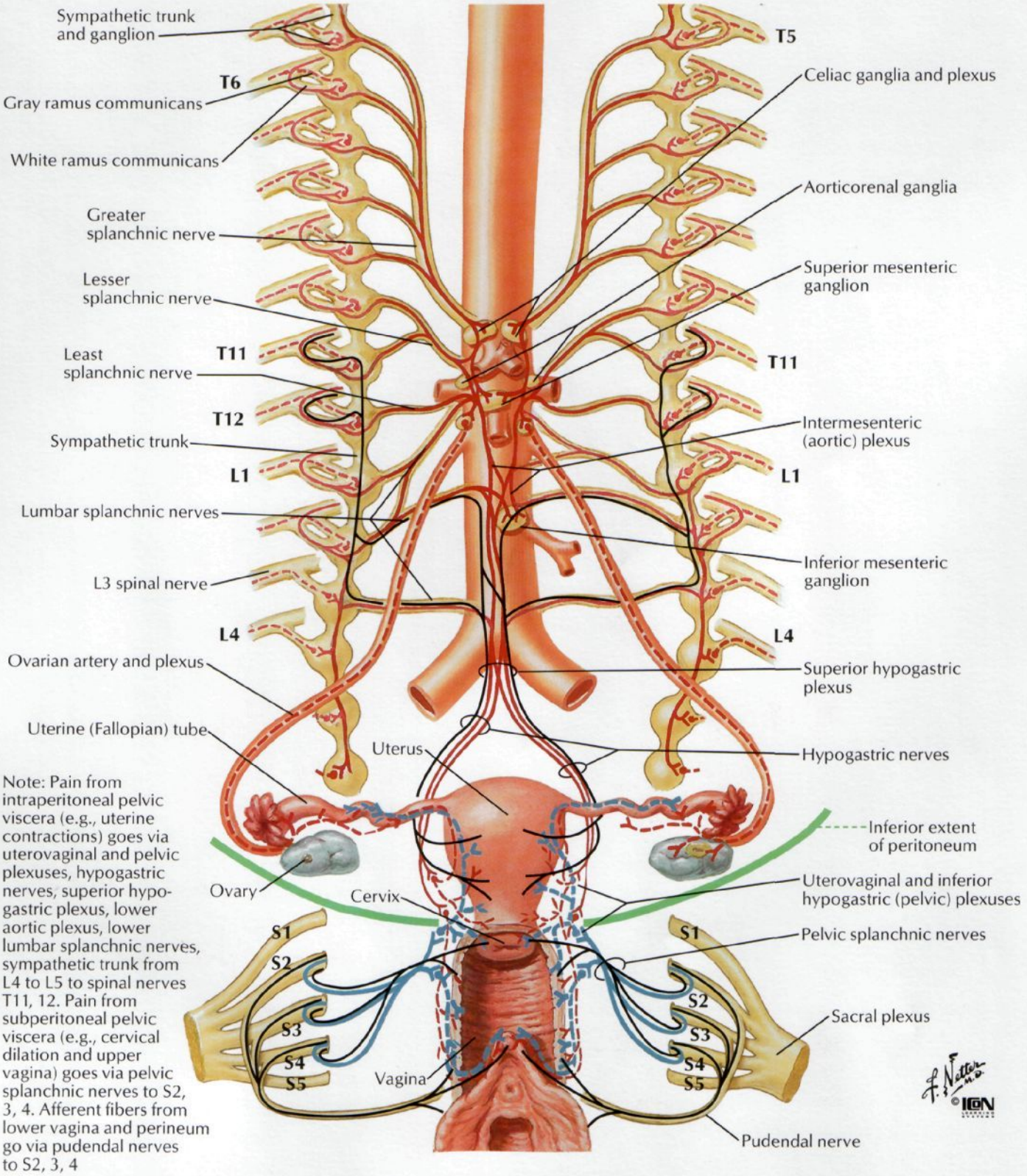

Note: Pain from intraperitoneal pelvic viscera (e.g., uterine contractions) goes via uterovaginal and pelvic plexuses, hypogastric nerves, superior hypogastric plexus, lower aortic plexus, lower lumbar splanchnic nerves, sympathetic trunk from L4 to L5 to spinal nerves T11, 12. Pain from subperitoneal pelvic viscera (e.g., cervical dilation and upper vagina) goes via pelvic splanchnic nerves to S2, 3, 4. Afferent fibers from lower vagina and perineum go via pudendal nerves to S2, 3, 4

Sympathetic fibers { **Presynaptic** ——— **Postsynaptic** - - - -

Parasympathetic fibers { **Presynaptic** ——— **Postsynaptic** - - - -

Afferent fibers ———

Innervation of Male Reproductive Organs: Schema

SEE ALSO PLATE 160

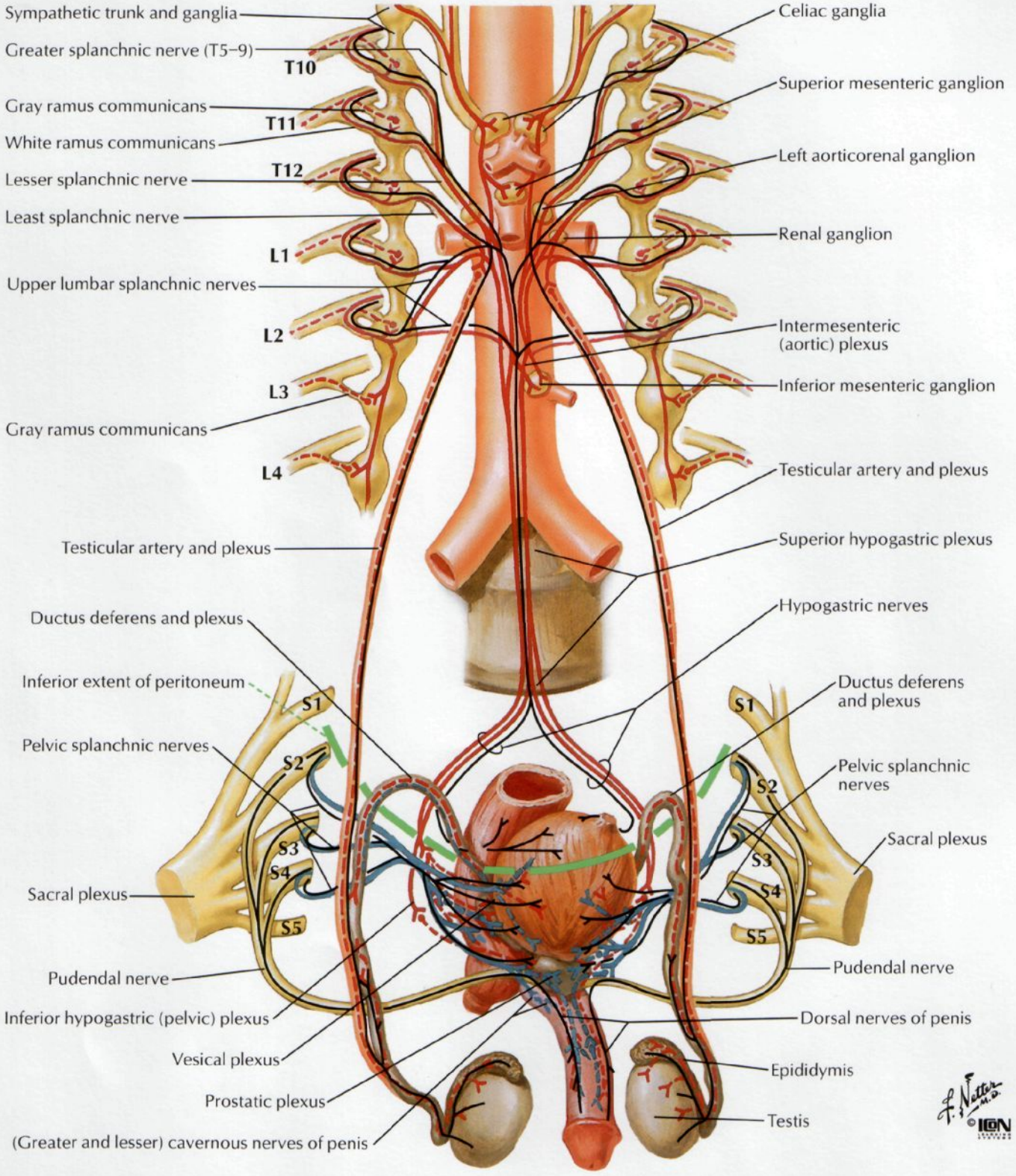

Sympathetic fibers { **Presynaptic** ——— **Postsynaptic** - - - - -

Parasympathetic fibers { **Presynaptic** ——— **Postsynaptic** - - - - -

Afferent fibers ———

Innervation of Urinary Bladder and Lower Ureter: Schema

SEE ALSO PLATE 160

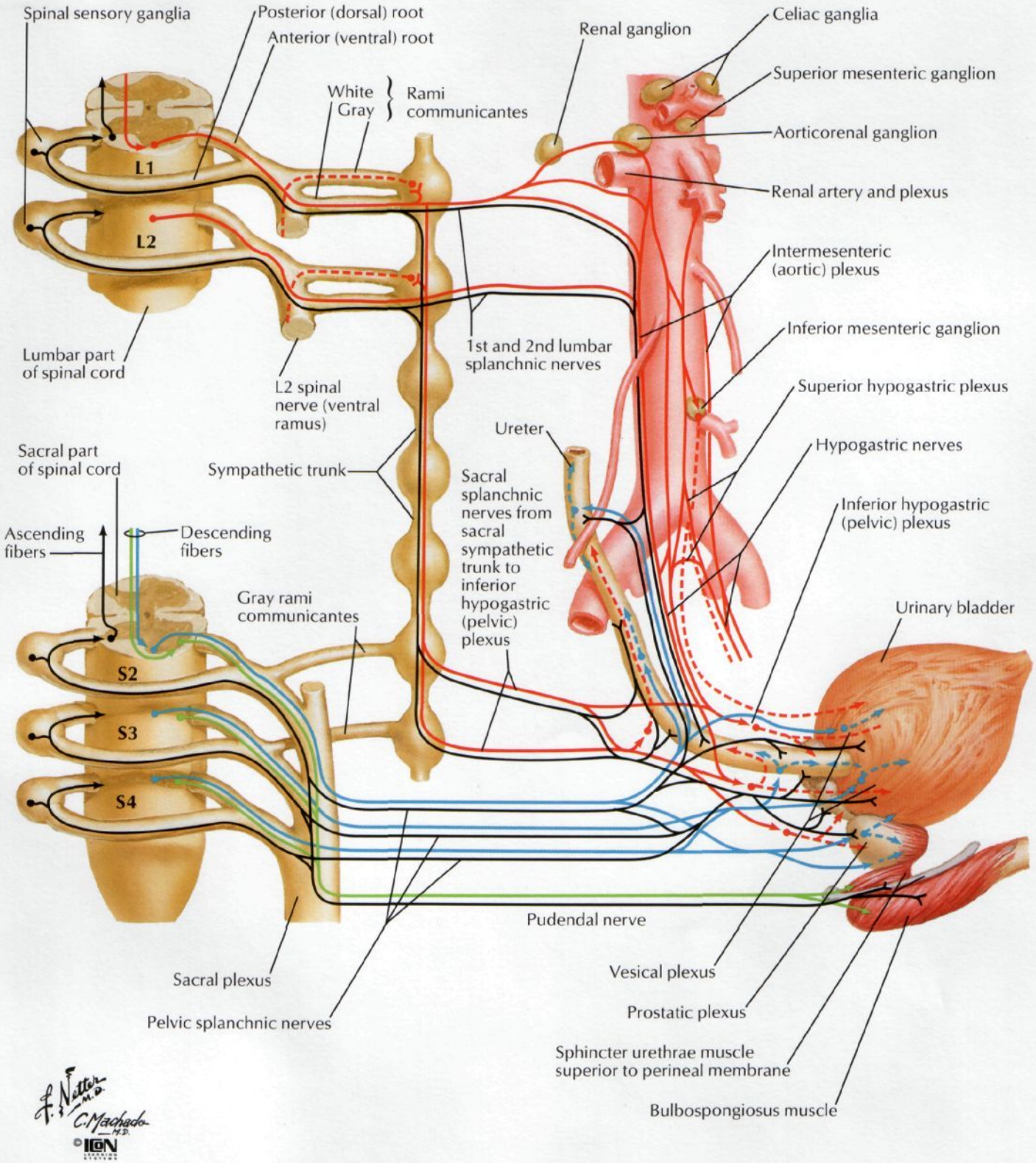

Sympathetic fibers { **Presynaptic** ——— **Postsynaptic** - - - -

Parasympathetic fibers { **Presynaptic** ——— **Postsynaptic** - - - -

Somatic efferent fibers ———

Afferent fibers ———

Homologues of External Genitalia

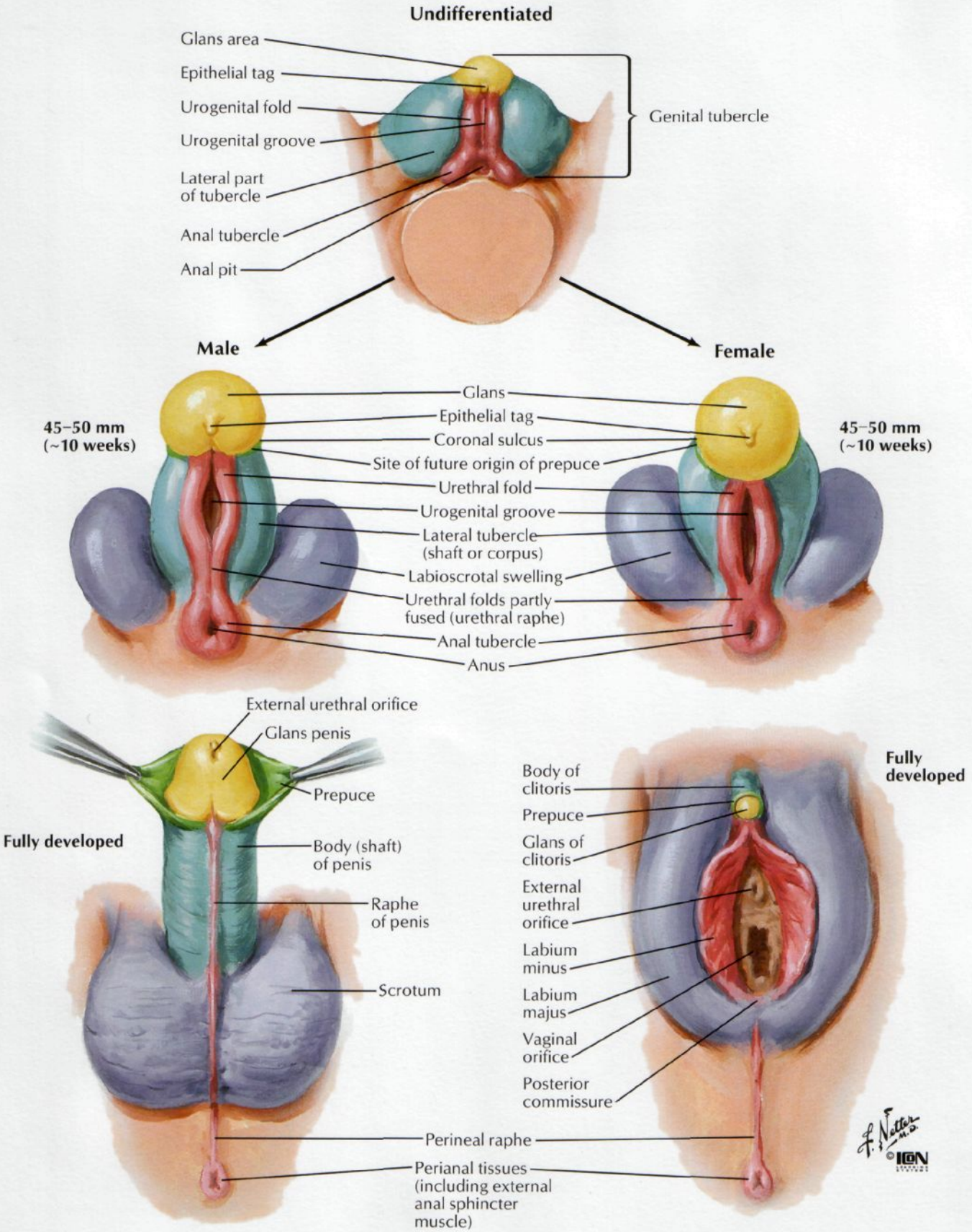

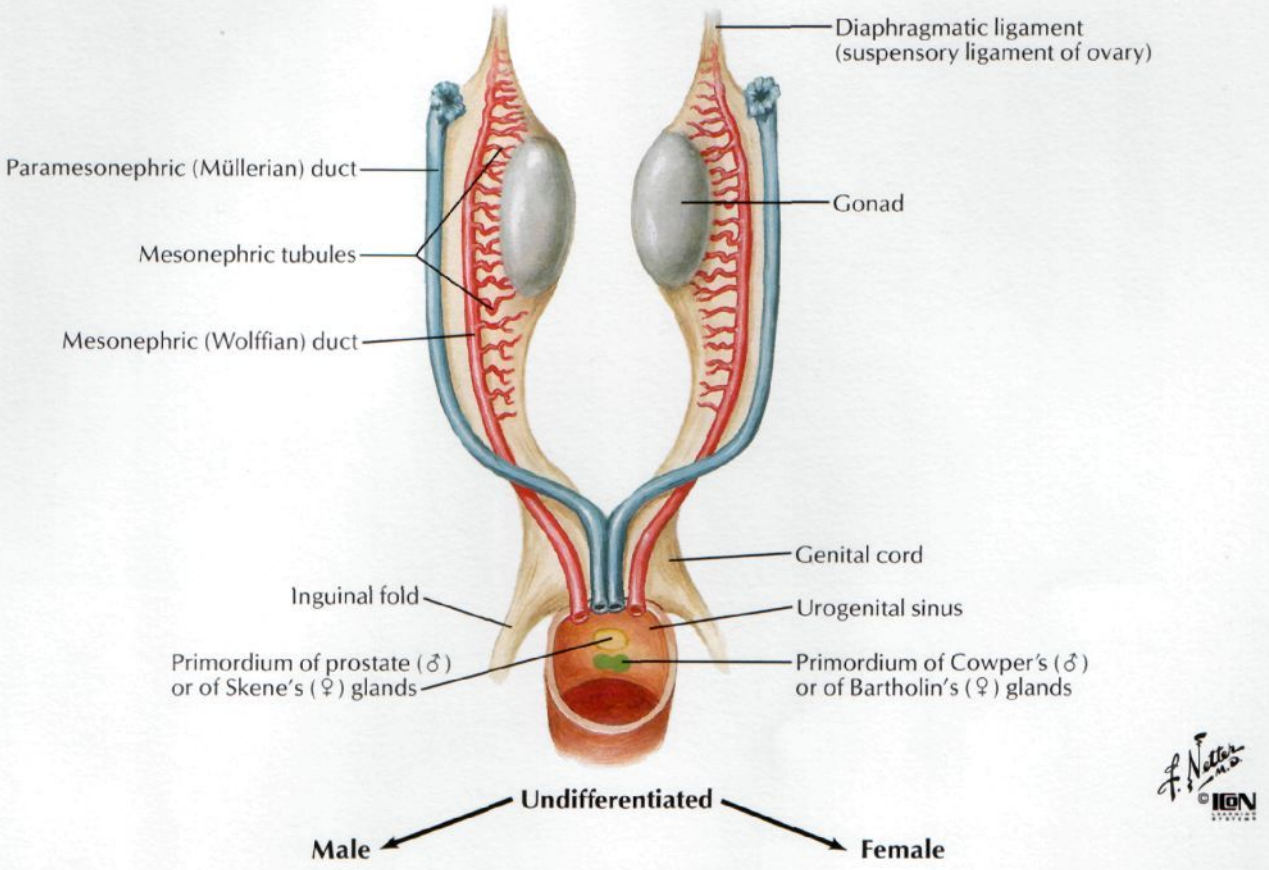
Diaphragmatic ligament
(suspensory ligament of ovary)
Paramesonephric (Müllerian) duct
Gonad
Mesonephric tubules
Mesonephric (Wolffian) duct
Genital cord
Inguinal fold
Urogenital sinus
Primordium of prostate (♂)
or of Skene's (♀) glands
Primordium of Cowper's (♂)
or of Bartholin's (♀) glands
Undifferentiated
Male
Female

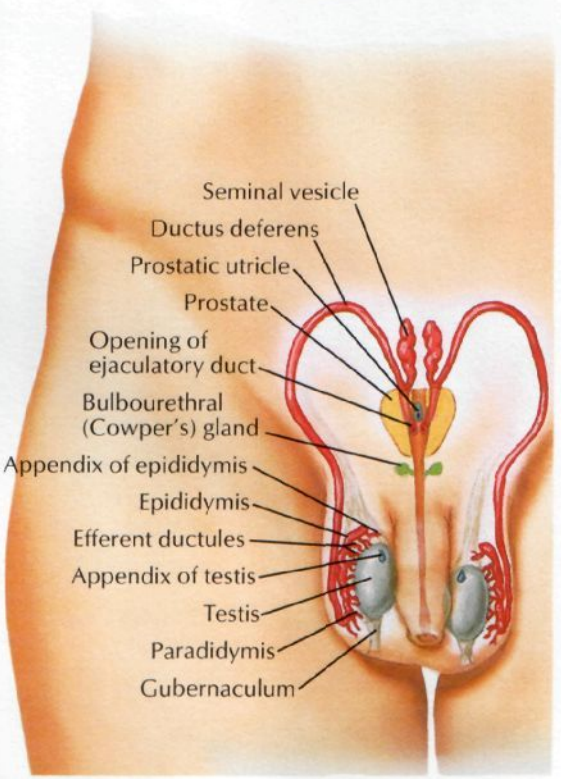
Seminal vesicle
Ductus deferens
Prostatic utricle
Prostate
Opening of
ejaculatory duct
Bulbourethral
(Cowper's) gland
Appendix of epididymis
Epididymis
Efferent ductules
Appendix of testis
Testis
Paradidymis
Gubernaculum

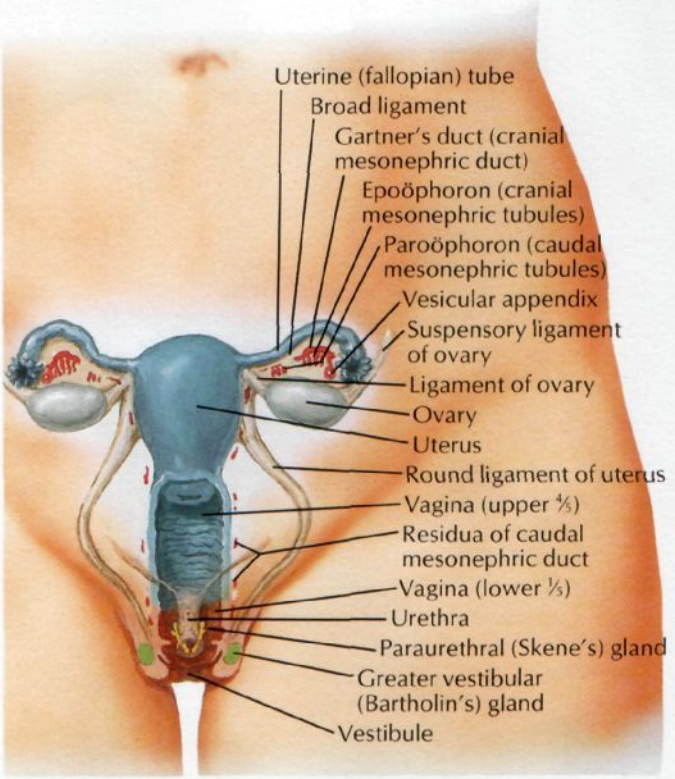
Uterine (fallopian) tube
Broad ligament
Gartner's duct (cranial
mesonephric duct)
Epoöphoron (cranial
mesonephric tubules)
Paroöphoron (caudal
mesonephric tubules)
Vesicular appendix
Suspensory ligament
of ovary
Ligament of ovary
Ovary
Uterus
Round ligament of uterus
Vagina (upper ⅘)
Residua of caudal
mesonephric duct
Vagina (lower ⅕)
Urethra
Paraurethral (Skene's) gland
Greater vestibular
(Bartholin's) gland
Vestibule

Pelvic Scans: Sagittal MR Images

Median (A) and paramedian (B) sagittal MR images of female pelvis

A

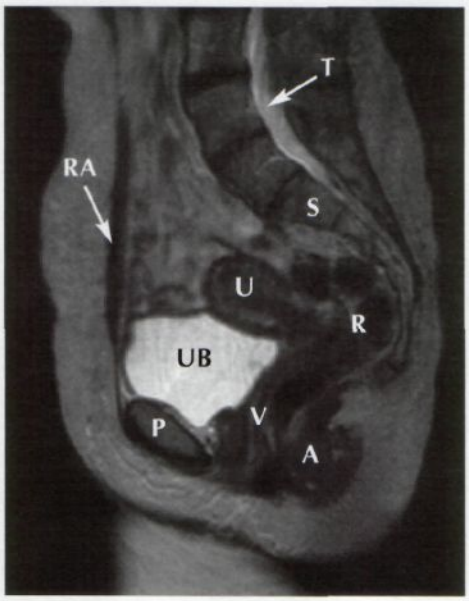

B

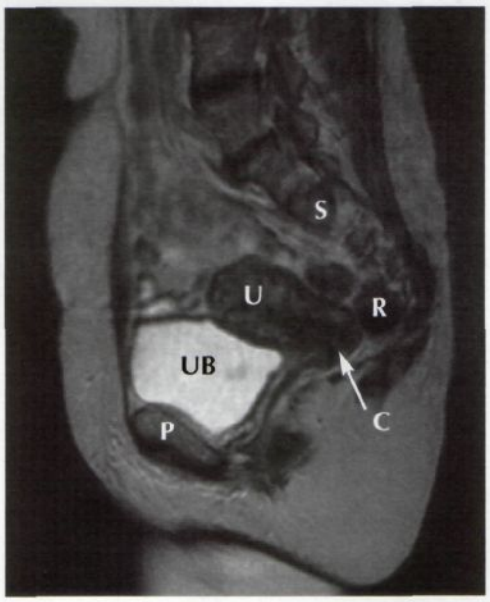

A	Anal canal	**S**	Sacrum
C	External os of cervix	**T**	Thecal sac
P	Pubic symphysis	**U**	Uterus
R	Rectum	**UB**	Urinary bladder
RA	Rectus abdominis muscle	**V**	Vagina

Median (C) and paramedian (D) sagittal MR images of male pelvis

C

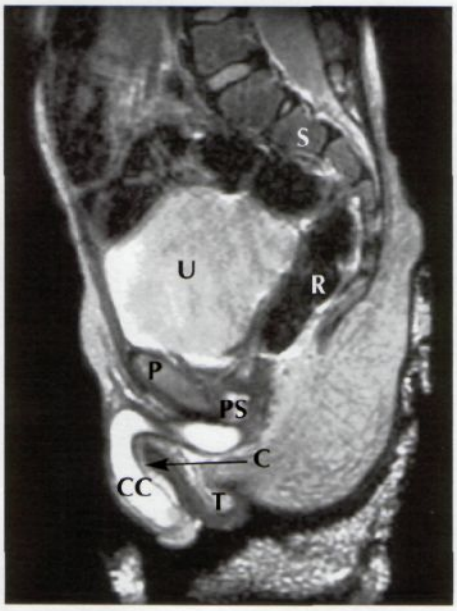

D

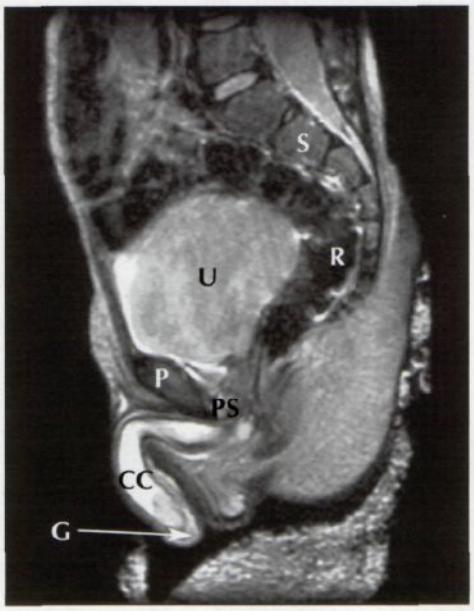

C	Corpus spongiosum	**R**	Rectum
CC	Corpus cavernosum	**S**	Sacrum
G	Glans of penis	**T**	Testis
P	Pubic symphysis	**U**	Urinary bladder
PS	Prostate		

Section VI
UPPER LIMB

SURFACE ANATOMY
Plate 401
401. Upper Limb

SHOULDER AND AXILLA
Plates 402–413
402. Clavicle and Sternoclavicular Joint
403. Humerus and Scapula: Anterior Views
404. Humerus and Scapula: Posterior Views
405. Shoulder: Anteroposterior Radiograph
406. Shoulder (Glenohumeral) Joint
407. Muscles of Shoulder
408. Muscles of Rotator Cuff
409. Scapulohumeral Dissection
410. Axillary Artery and Anastomoses Around Scapula
411. Pectoral, Clavipectoral and Axillary Fasciae
412. Axilla (Dissection): Anterior View
413. Brachial Plexus: Schema

ARM
Plates 414–418
414. Muscles of Arm: Anterior Views
415. Muscles of Arm: Posterior Views
416. Brachial Artery In Situ
417. Brachial Artery and Anastomoses Around Elbow
418. Arm: Serial Cross Sections

ELBOW AND FOREARM
Plates 419–434
419. Bones of Elbow
420. Elbow: Radiographs
421. Ligaments of Elbow
422. Bones of Forearm
423. Individual Muscles of Forearm: Rotators of Radius
424. Individual Muscles of Forearm: Extensors of Wrist and Digits
425. Individual Muscles of Forearm: Flexors of Wrist

426. Individual Muscles of Forearm: Flexors of Digits
427. Muscles of Forearm (Superficial Layer): Posterior View
428. Muscles of Forearm (Deep Layer): Posterior View
429. Muscles of Forearm (Superficial Layer): Anterior View
430. Muscles of Forearm (Intermediate Layer): Anterior View
431. Muscles of Forearm (Deep Layer): Anterior View
432. Forearm: Serial Cross Sections
433. Attachments of Muscles of Forearm: Anterior View
434. Attachments of Muscles of Forearm: Posterior View

WRIST AND HAND
Plates 435–454

435. Carpal Bones
436. Movements of Wrist
437. Ligaments of Wrist
438. Ligaments of Wrist (*continued*)
439. Bones of Wrist and Hand
440. Wrist and Hand: Anteroposterior Radiograph
441. Metacarpophalangeal and Interphalangeal Ligaments
442. Wrist and Hand: Superficial Palmar Dissections
443. Wrist and Hand: Deeper Palmar Dissections
444. Flexor Tendons, Arteries and Nerves at Wrist
445. Bursae, Spaces and Tendon Sheaths of Hand
446. Lumbrical Muscles and Bursae, Spaces and Sheaths: Schema
447. Flexor and Extensor Tendons in Fingers
448. Intrinsic Muscles of Hand
449. Arteries and Nerves of Hand: Palmar Views
450. Wrist and Hand: Superficial Radial Dissection
451. Wrist and Hand: Superficial Dorsal Dissection
452. Wrist and Hand: Deep Dorsal Dissection
453. Extensor Tendons at Wrist
454. Fingers

NEUROVASCULATURE
Plates 455–466

455. Cutaneous Innervation of Wrist and Hand
456. Arteries and Nerves of Upper Limb
457. Musculocutaneous Nerve
458. Median Nerve
459. Ulnar Nerve
460. Radial Nerve in Arm and Nerves of Posterior Shoulder
461. Radial Nerve in Forearm
462. Cutaneous Nerves and Superficial Veins of Shoulder and Arm
463. Cutaneous Nerves and Superficial Veins of Forearm
464. Cutaneous Innervation of Upper Limb
465. Dermatomes of Upper Limb
466. Lymph Vessels and Nodes of Upper Limb

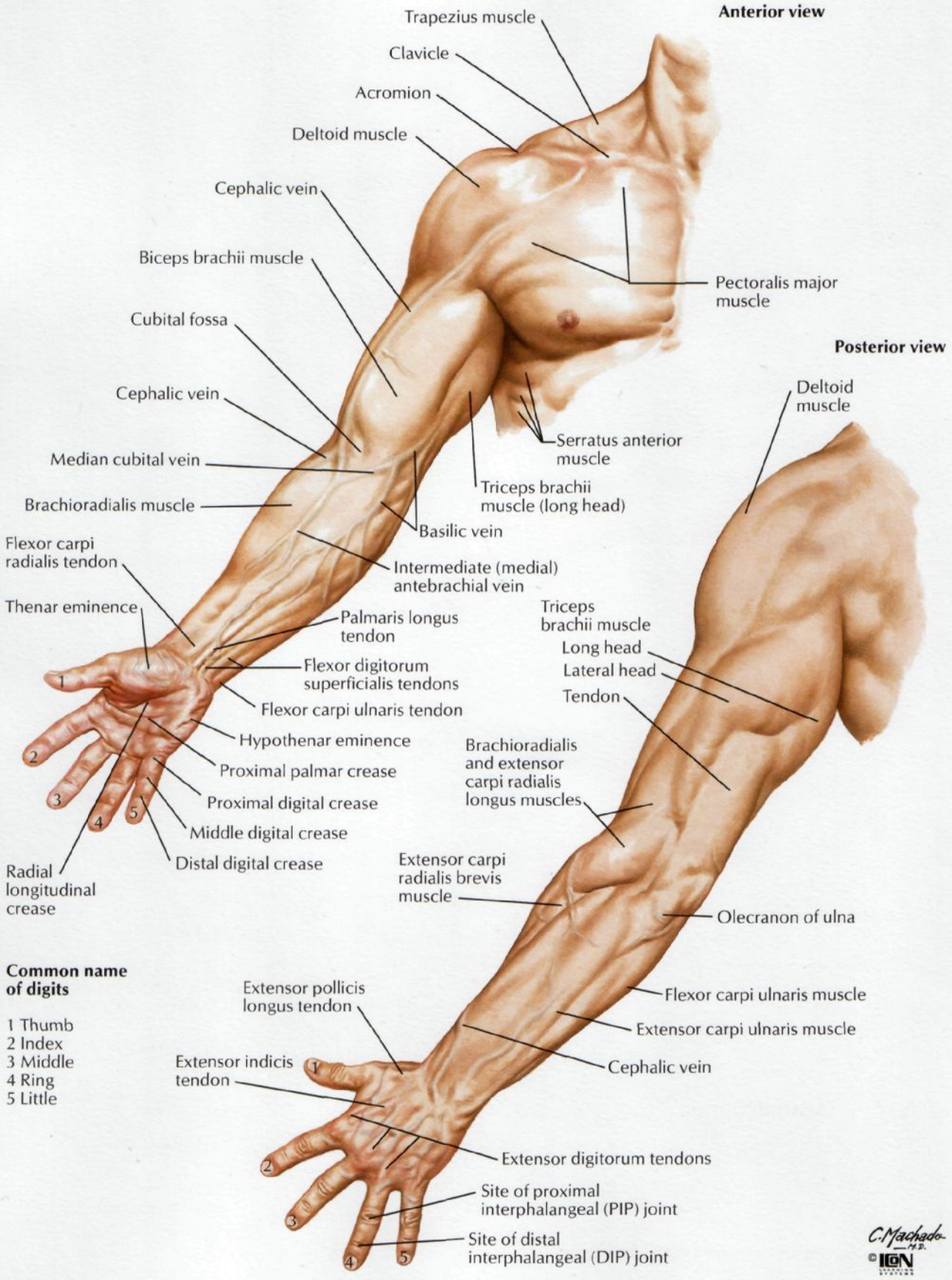
Anterior view
Trapezius muscle
Clavicle
Acromion
Deltoid muscle
Cephalic vein
Biceps brachii muscle
Pectoralis major muscle
Cubital fossa
Cephalic vein
Median cubital vein
Brachioradialis muscle
Serratus anterior muscle
Triceps brachii muscle (long head)
Basilic vein
Intermediate (medial) antebrachial vein
Flexor carpi radialis tendon
Thenar eminence
Palmaris longus tendon
Flexor digitorum superficialis tendons
Flexor carpi ulnaris tendon
Hypothenar eminence
Proximal palmar crease
Proximal digital crease
Middle digital crease
Distal digital crease
Radial longitudinal crease
Posterior view
Deltoid muscle
Triceps brachii muscle
Long head
Lateral head
Tendon
Brachioradialis and extensor carpi radialis longus muscles
Extensor carpi radialis brevis muscle
Olecranon of ulna
Flexor carpi ulnaris muscle
Extensor carpi ulnaris muscle
Cephalic vein
Extensor pollicis longus tendon
Extensor indicis tendon
Extensor digitorum tendons
Site of proximal interphalangeal (PIP) joint
Site of distal interphalangeal (DIP) joint
1
2
3
4
5
Common name of digits
1 Thumb
2 Index
3 Middle
4 Ring
5 Little
C. Machado, M.D.
©IGN

Clavicle and Sternoclavicular Joint

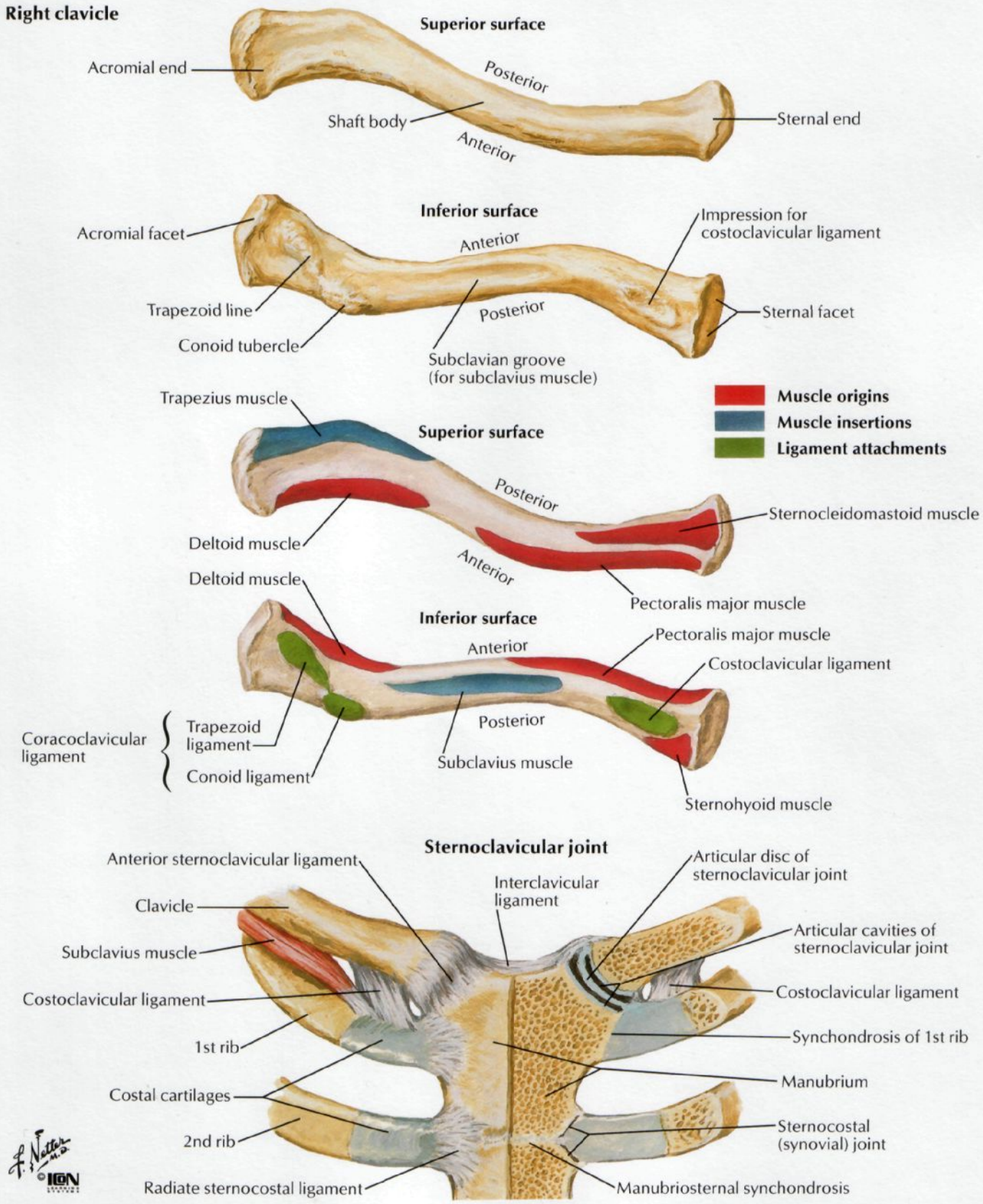

Humerus and Scapula: Anterior Views

SEE ALSO PLATE 178

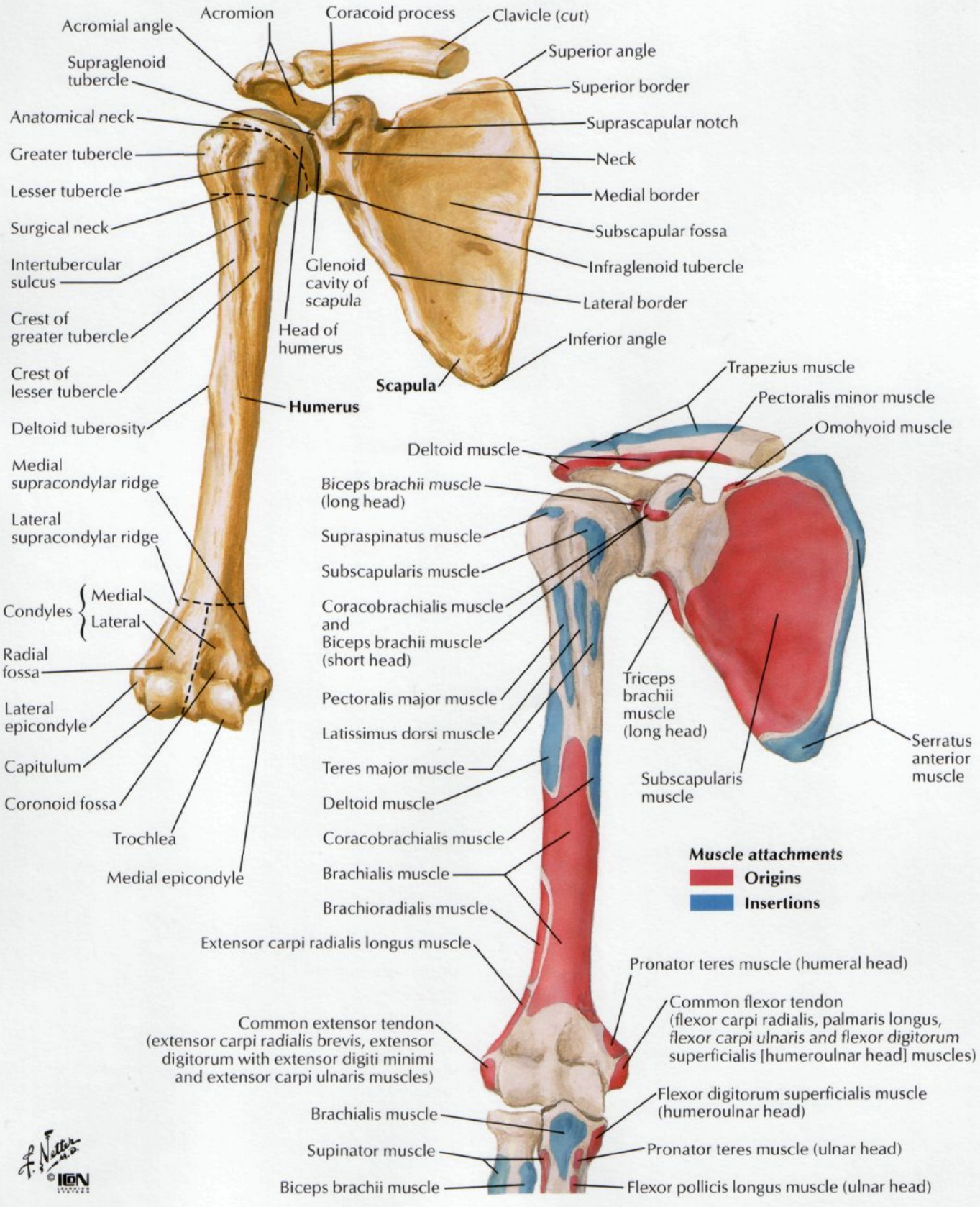

Humerus and Scapula: Posterior Views

SEE ALSO PLATE 178

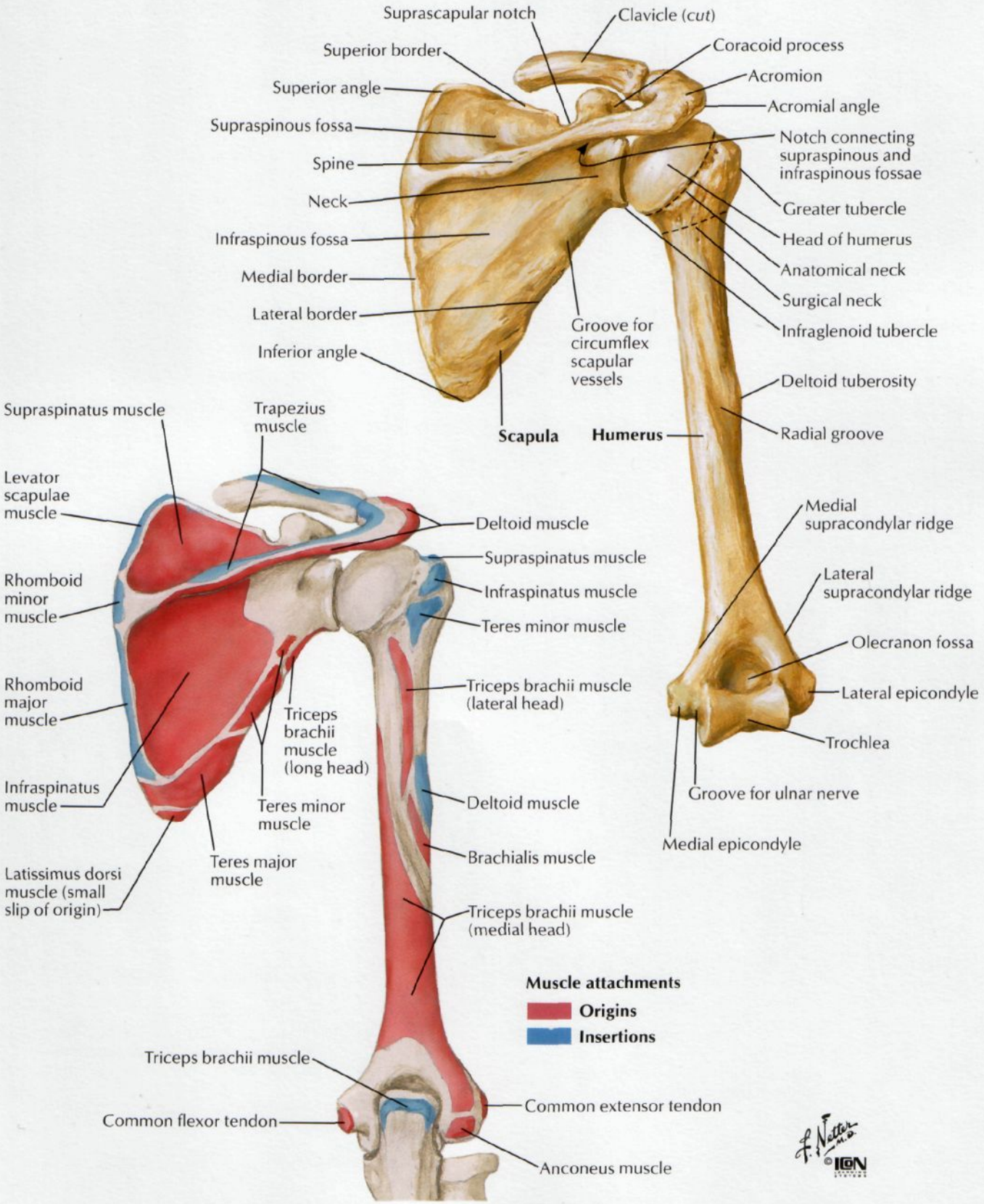

Shoulder: Anteroposterior Radiograph

SEE ALSO PLATE 403

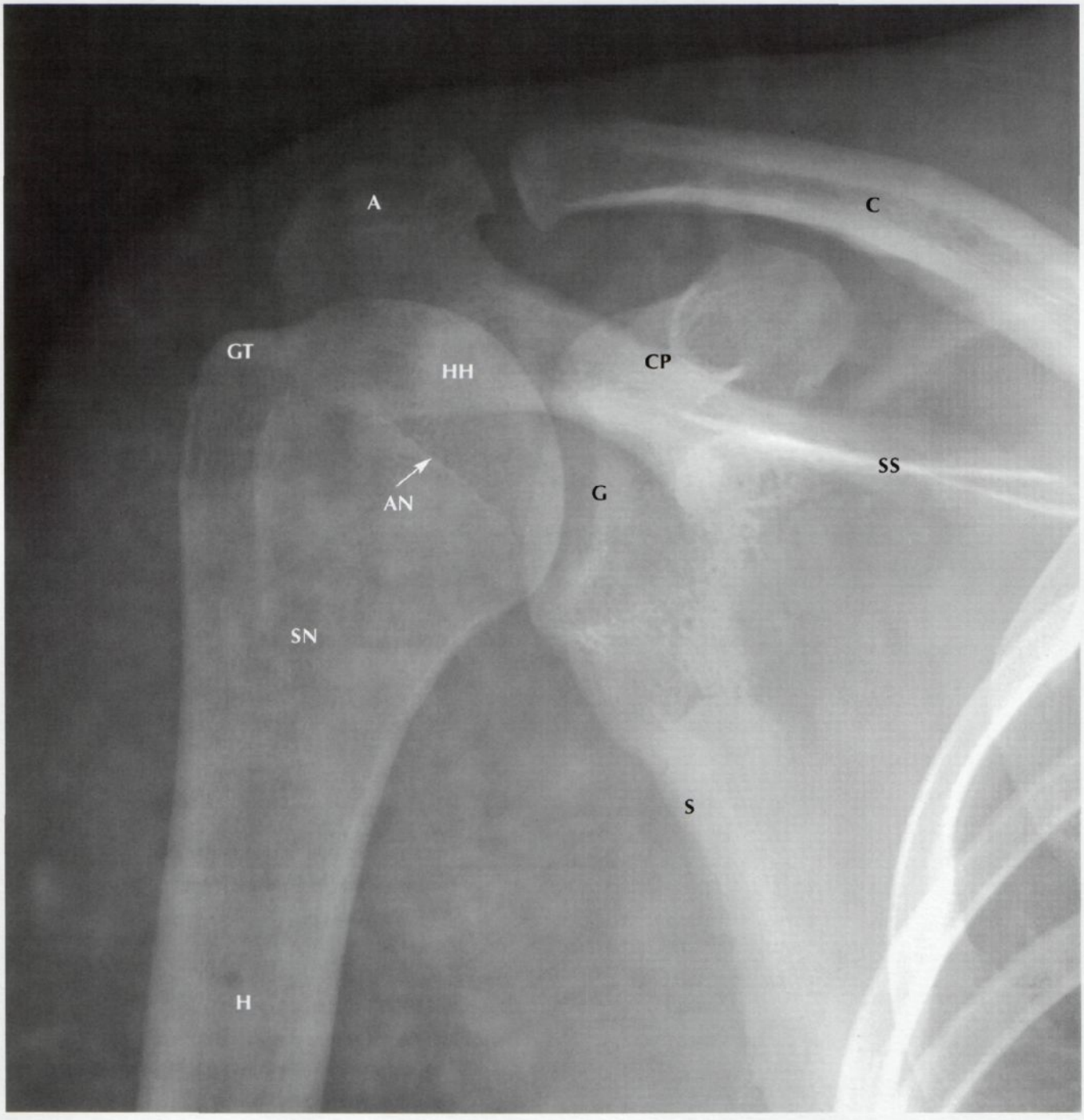

A	Acromion
AN	Anatomical neck of humerus
C	Clavicle
CP	Coracoid process
G	Glenoid cavity of scapula
GT	Greater tubercle
H	Humerus
HH	Head of humerus
S	Scapula (lateral border)
SN	Surgical neck of humerus
SS	Spine of scapula

Shoulder (Glenohumeral) Joint

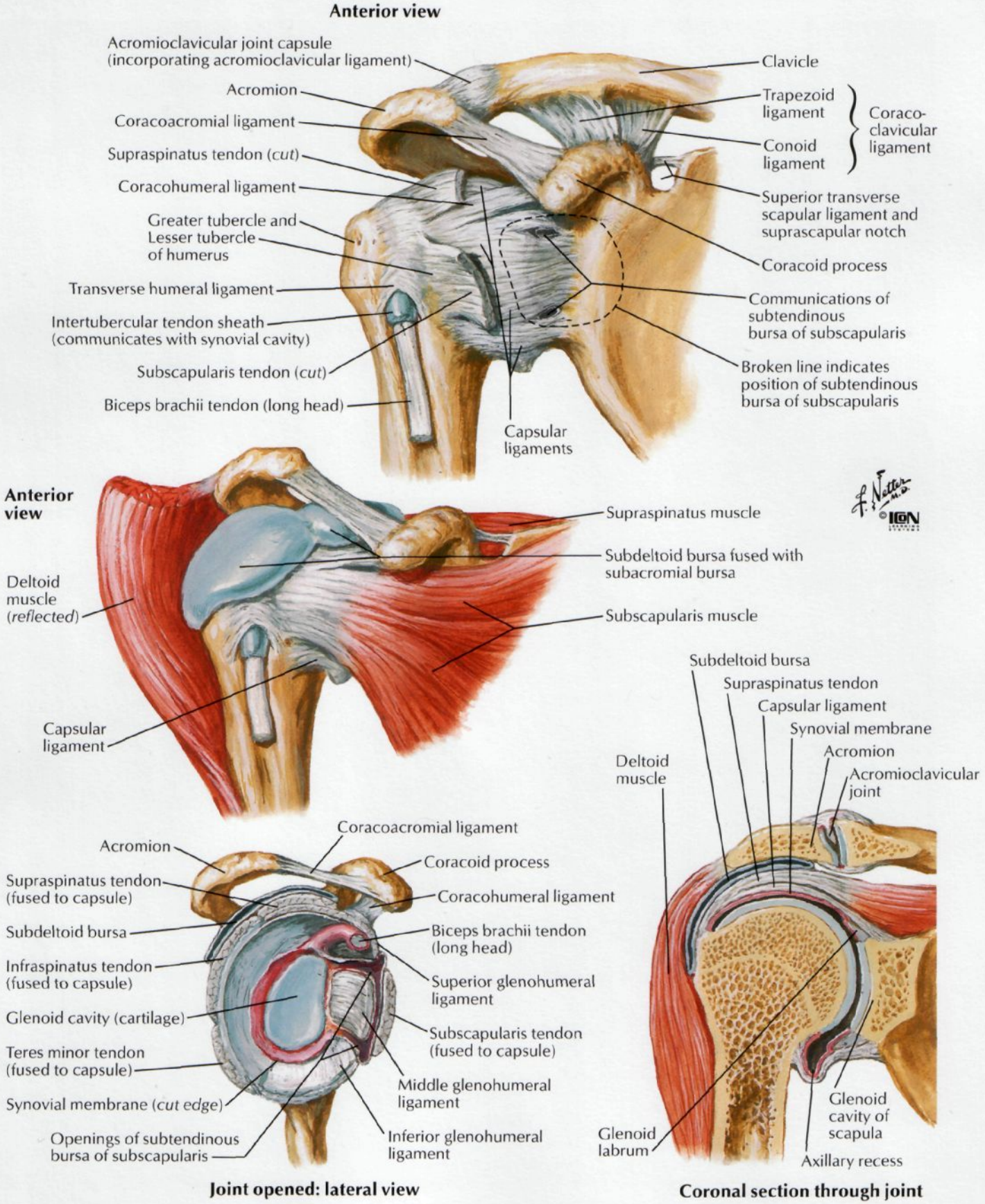

SEE ALSO PLATES 23, 167, 182, 183, 185, 186

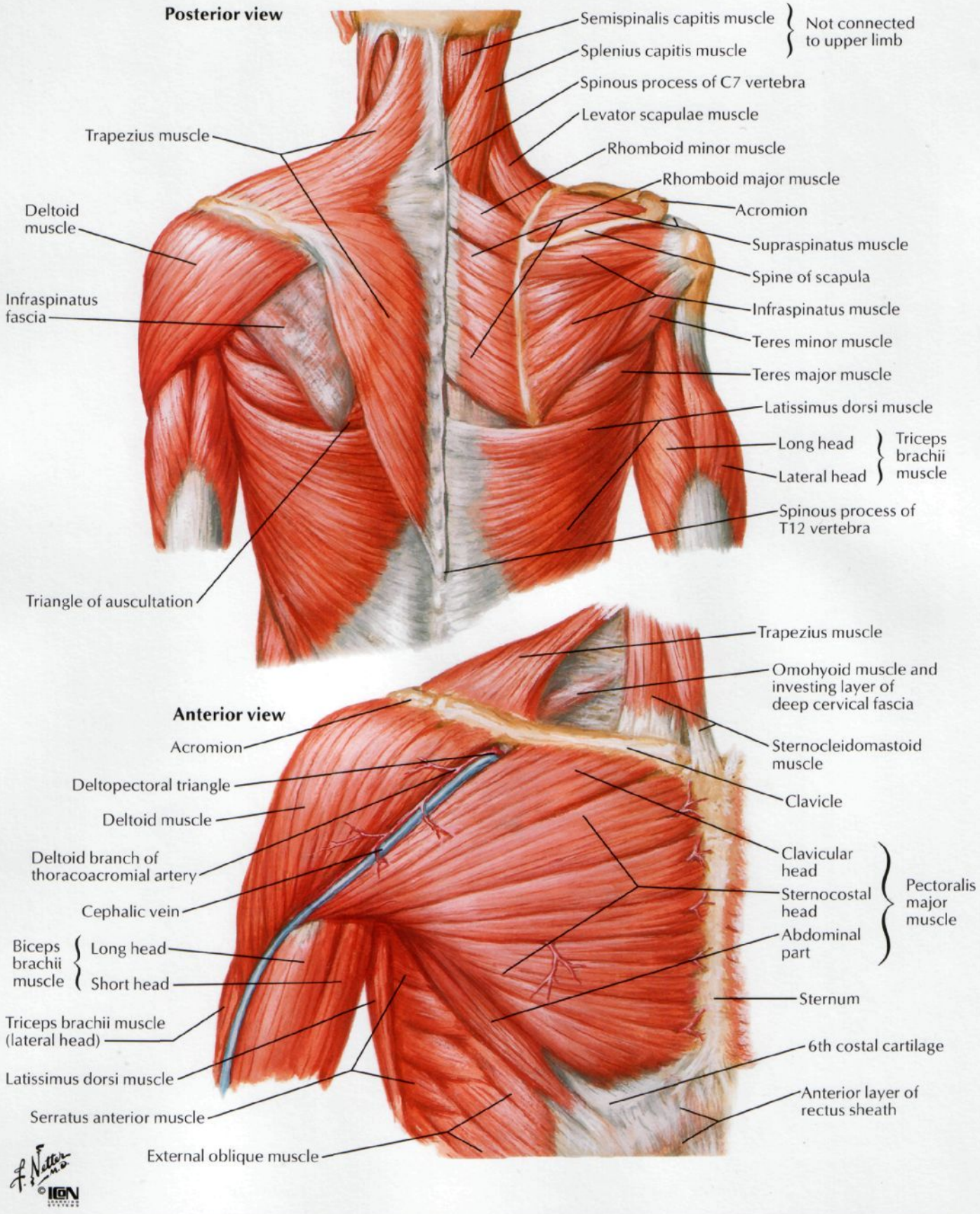

Muscles of Rotator Cuff

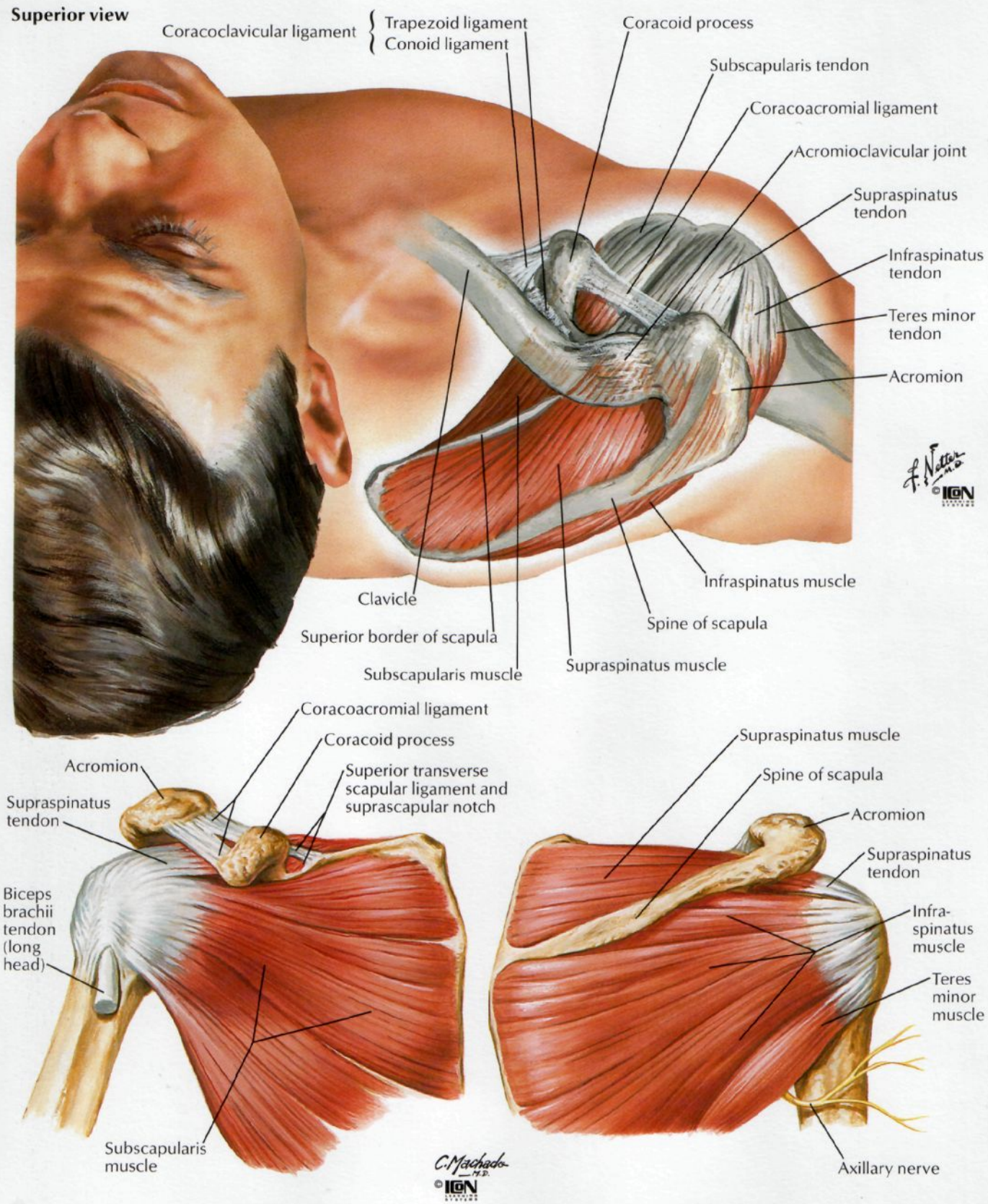

SEE ALSO PLATE 460

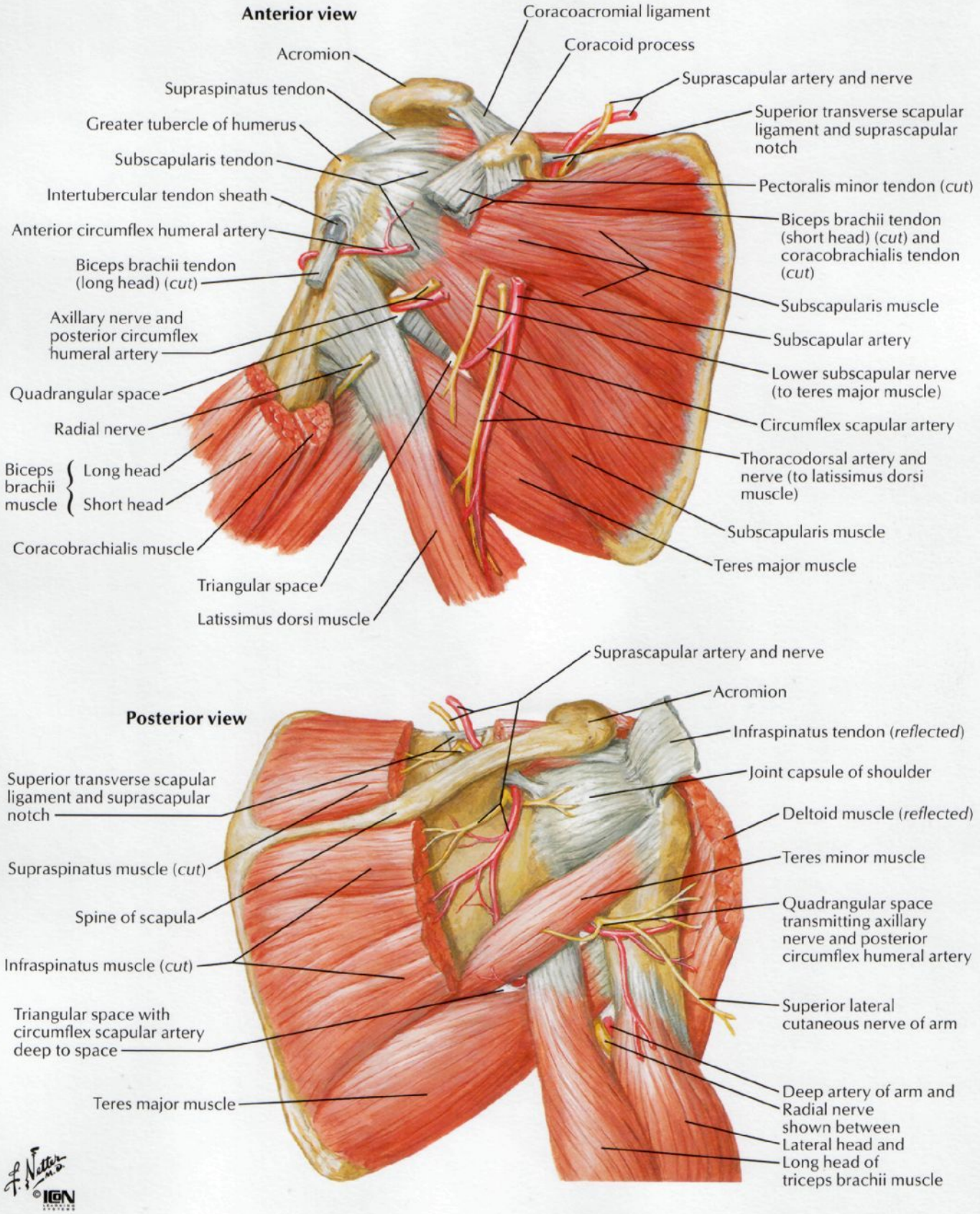

F. Netter M.D.
©IGN

Axillary Artery and Anastomoses Around Scapula

SEE ALSO PLATES 29, 417

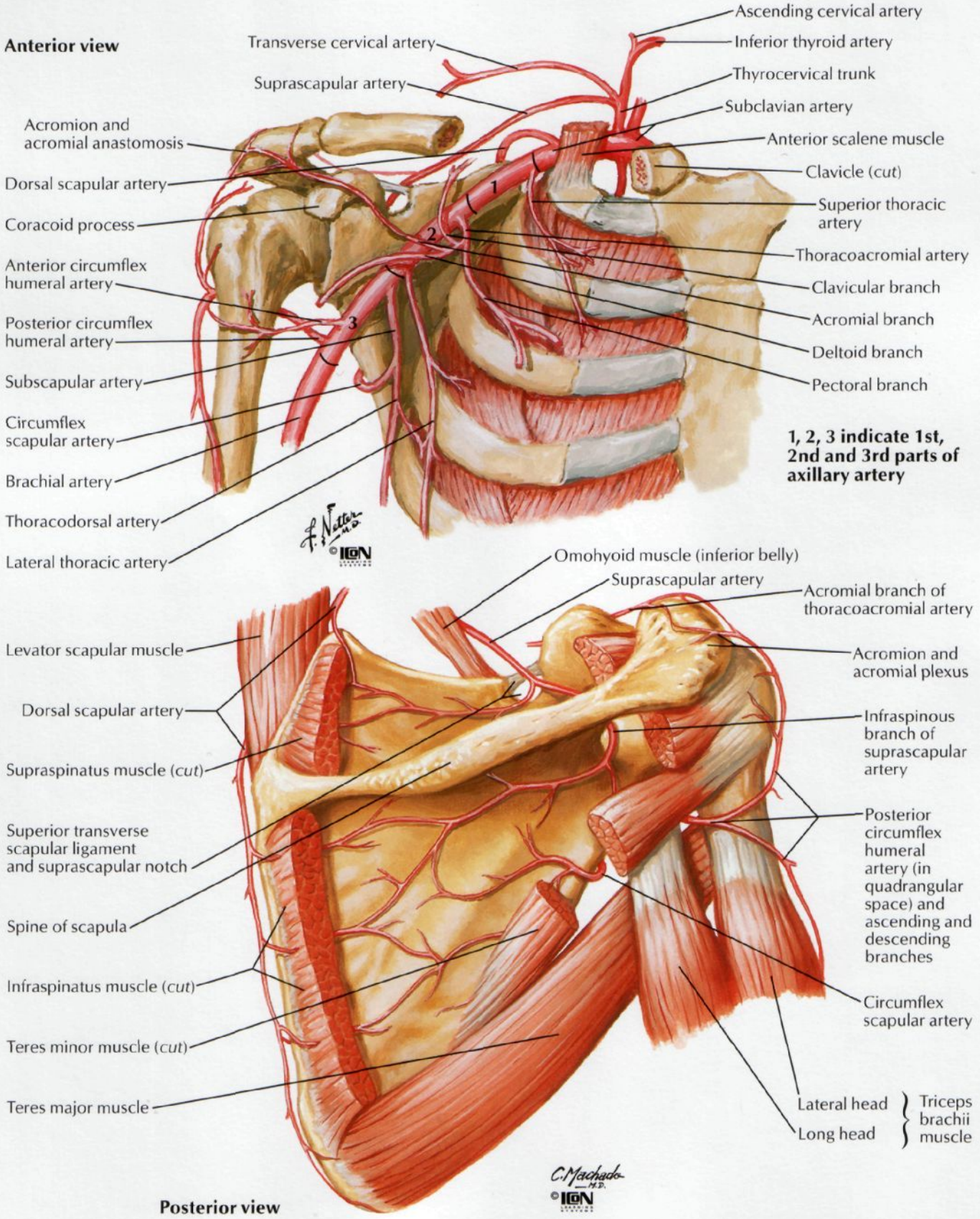

Pectoral, Clavipectoral and Axillary Fasciae

SEE ALSO PLATE 182

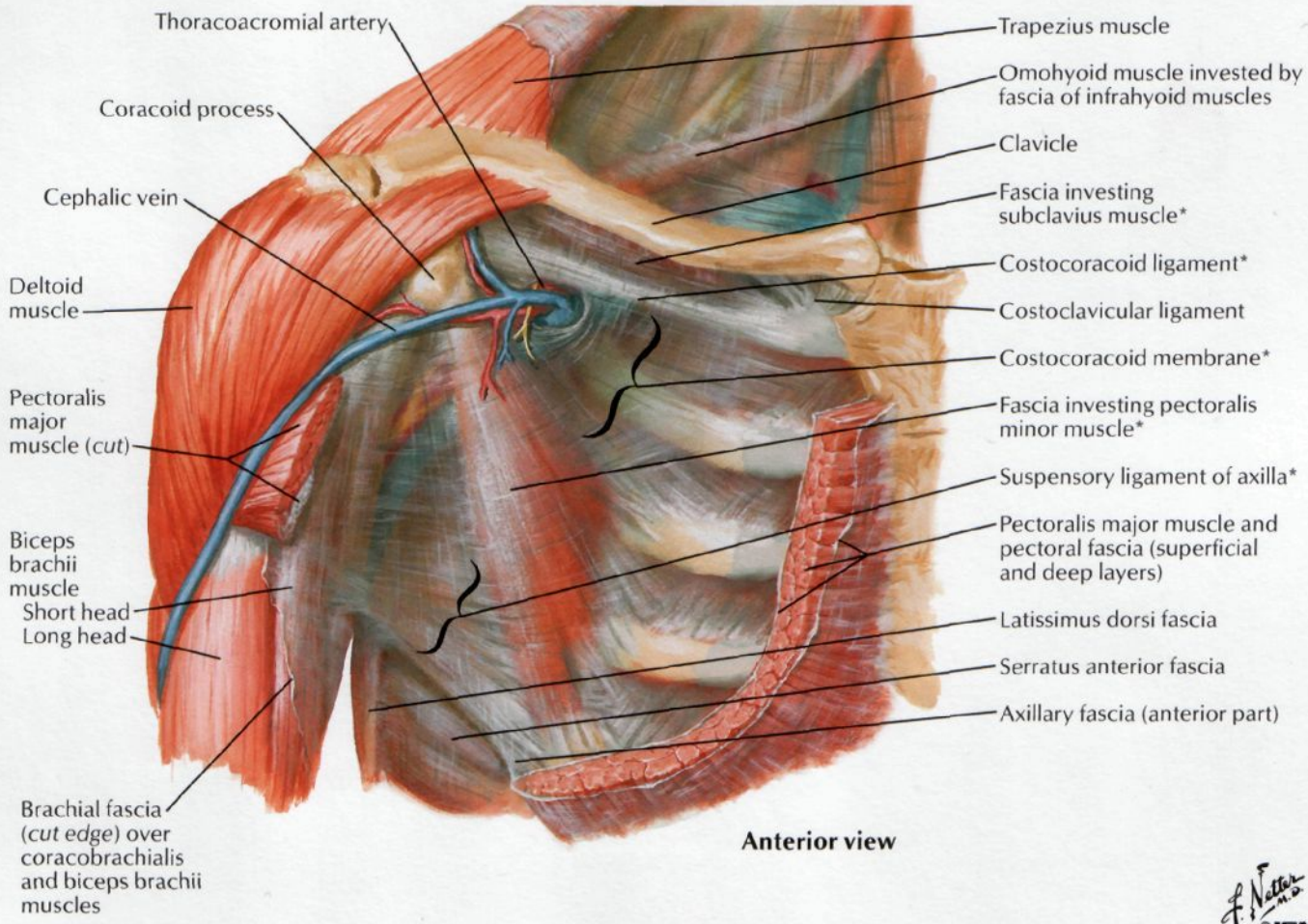

Anterior view

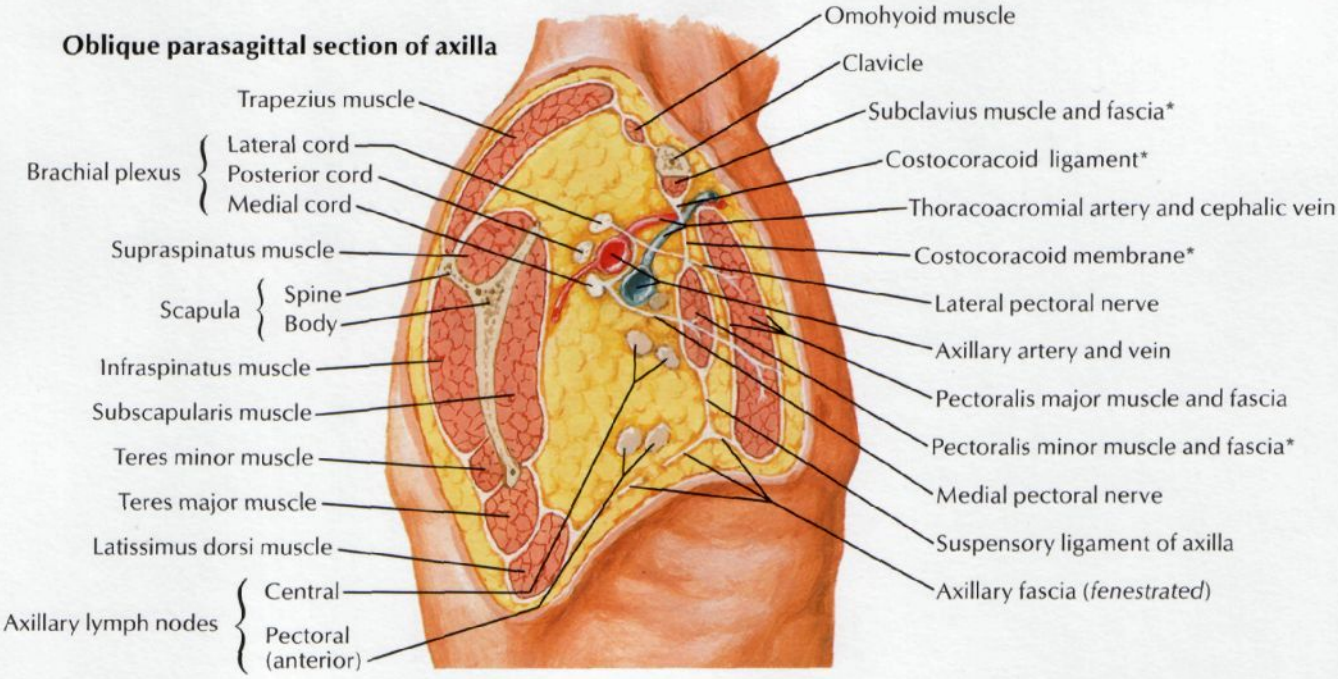

*Components of clavipectoral fascia

Axilla (Dissection): Anterior View

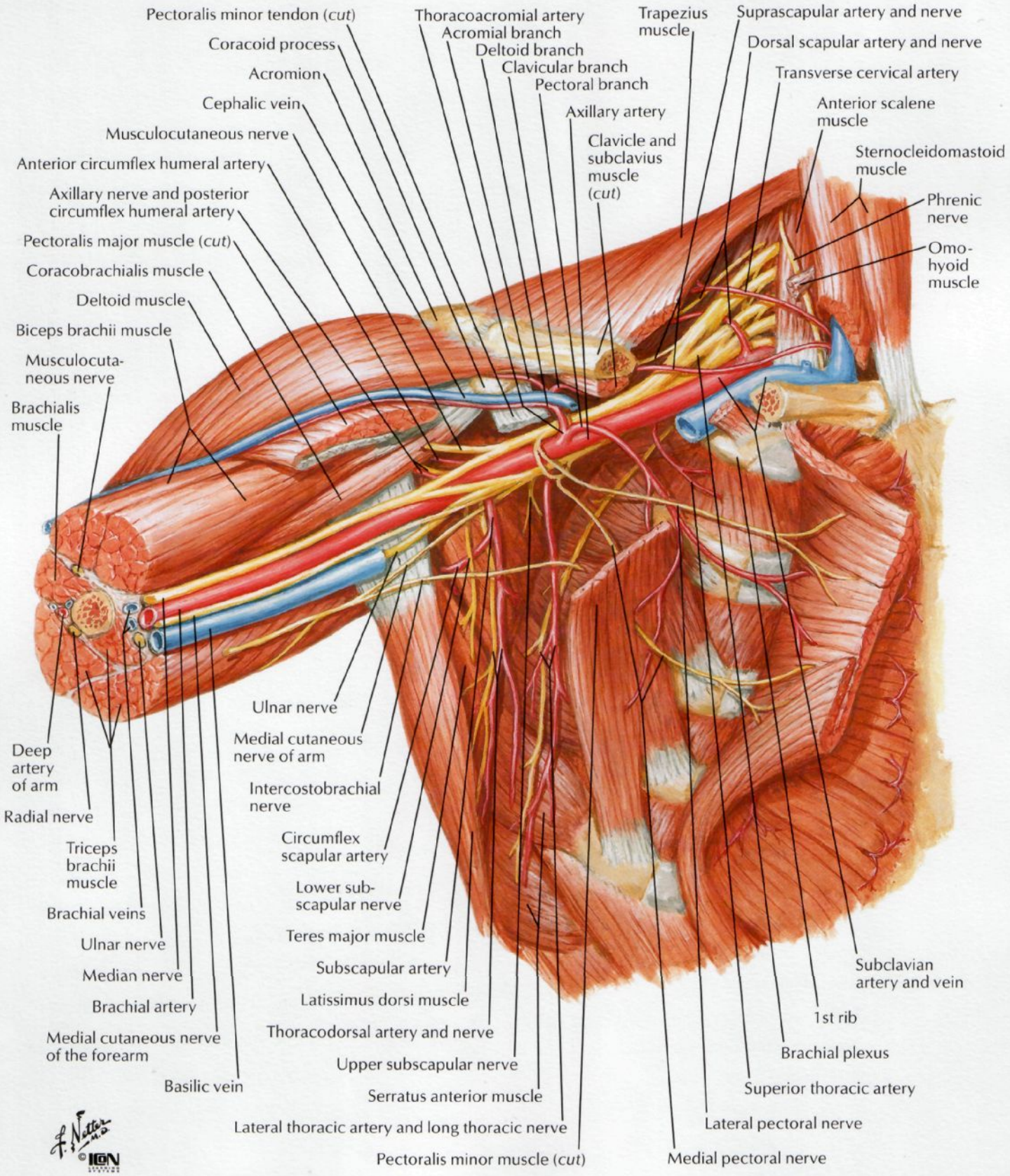

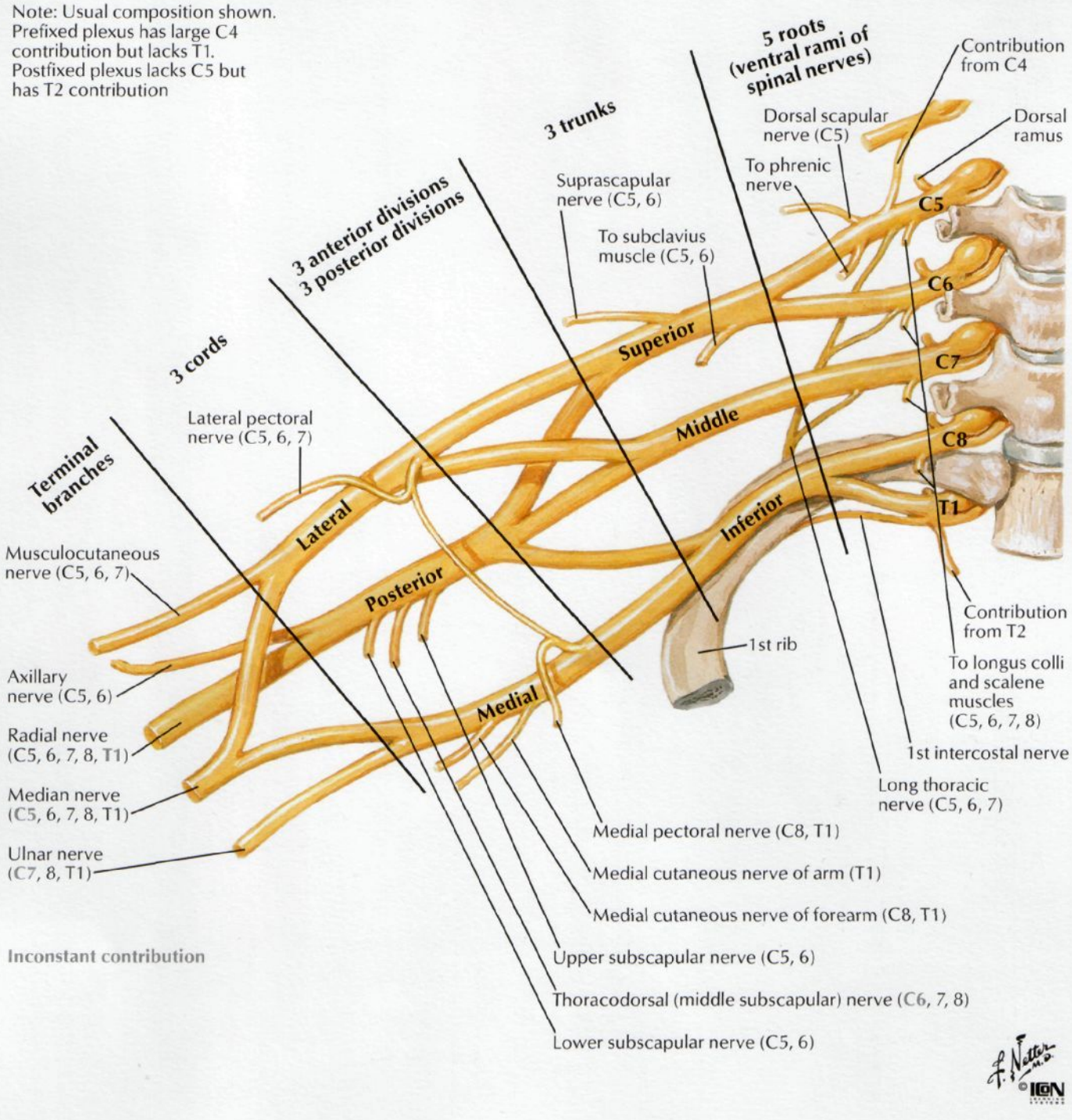
Note: Usual composition shown. Prefixed plexus has large C4 contribution but lacks T1. Postfixed plexus lacks C5 but has T2 contribution
5 roots (ventral rami of spinal nerves)
3 trunks
3 anterior divisions
3 posterior divisions
3 cords
Terminal branches
Contribution from C4
Dorsal scapular nerve (C5)
Dorsal ramus
To phrenic nerve
Suprascapular nerve (C5, 6)
To subclavius muscle (C5, 6)
C5
C6
C7
C8
T1
Superior
Middle
Inferior
Lateral
Posterior
Medial
Lateral pectoral nerve (C5, 6, 7)
Musculocutaneous nerve (C5, 6, 7)
Axillary nerve (C5, 6)
Radial nerve (C5, 6, 7, 8, T1)
Median nerve (C5, 6, 7, 8, T1)
Ulnar nerve (C7, 8, T1)
1st rib
Contribution from T2
To longus colli and scalene muscles (C5, 6, 7, 8)
1st intercostal nerve
Long thoracic nerve (C5, 6, 7)
Medial pectoral nerve (C8, T1)
Medial cutaneous nerve of arm (T1)
Medial cutaneous nerve of forearm (C8, T1)
Upper subscapular nerve (C5, 6)
Thoracodorsal (middle subscapular) nerve (C6, 7, 8)
Lower subscapular nerve (C5, 6)
Inconstant contribution

Muscles of Arm: Anterior Views

SEE ALSO PLATE 457

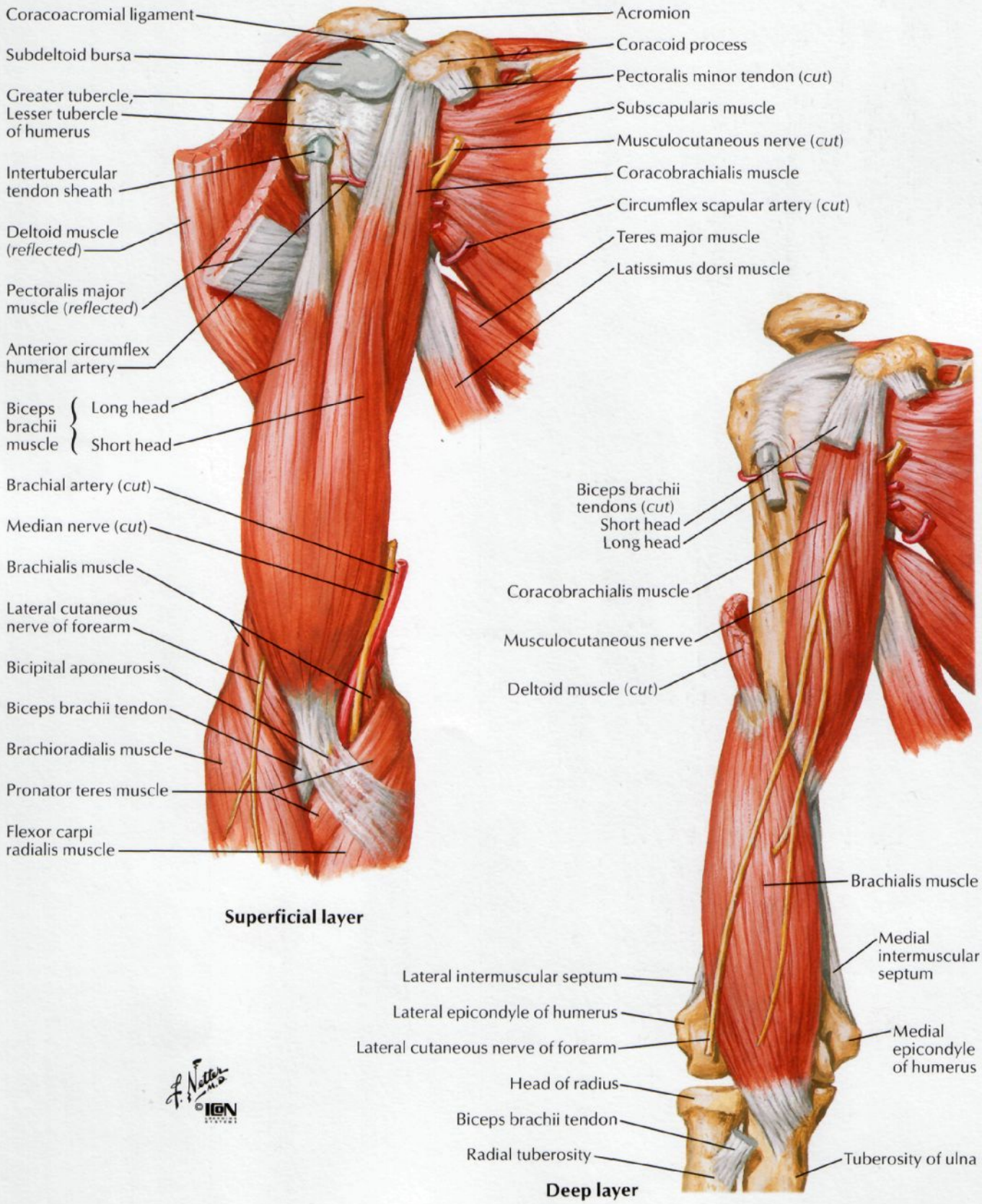

Superficial layer

Deep layer

SEE ALSO PLATE 460

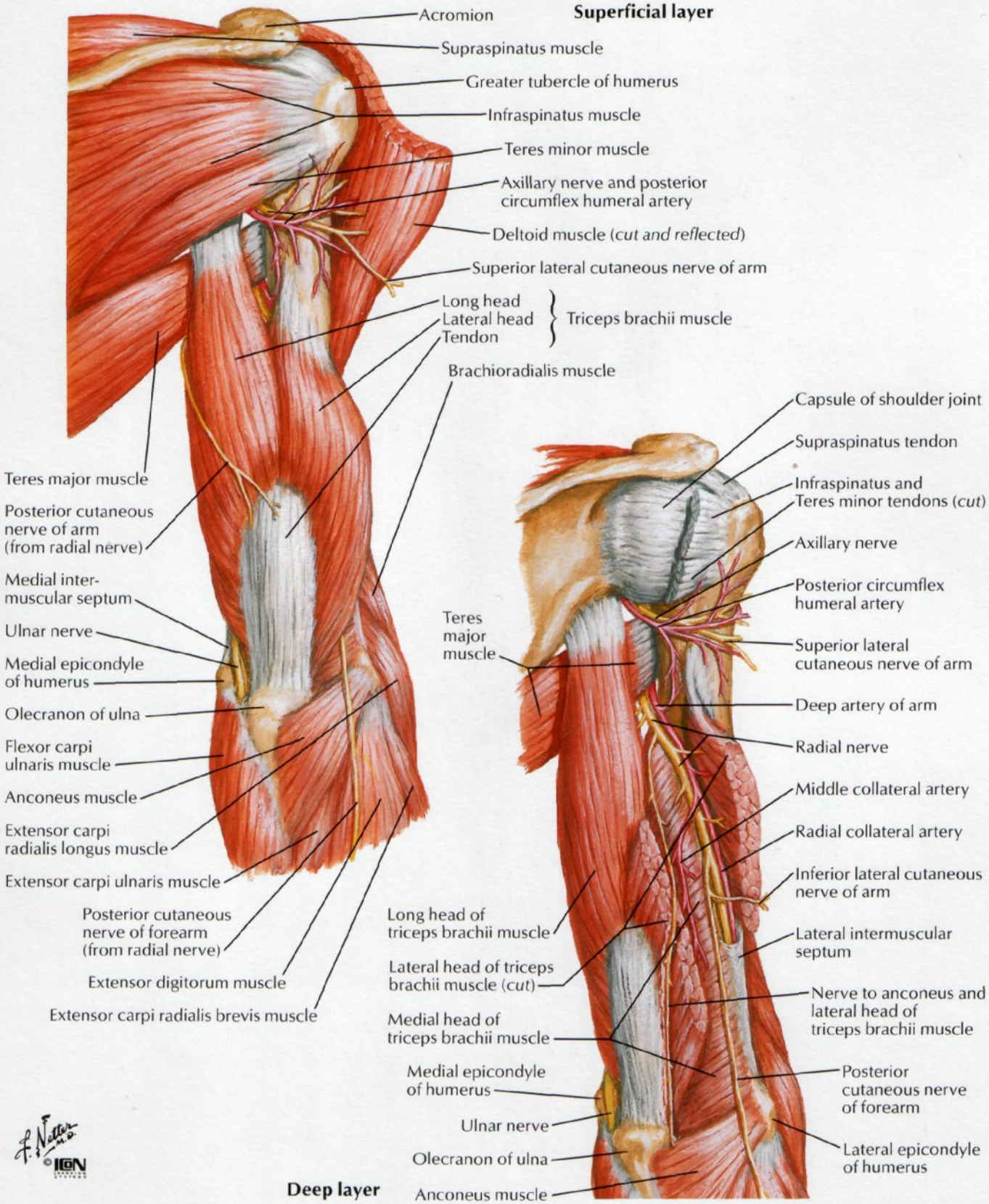

Brachial Artery In Situ

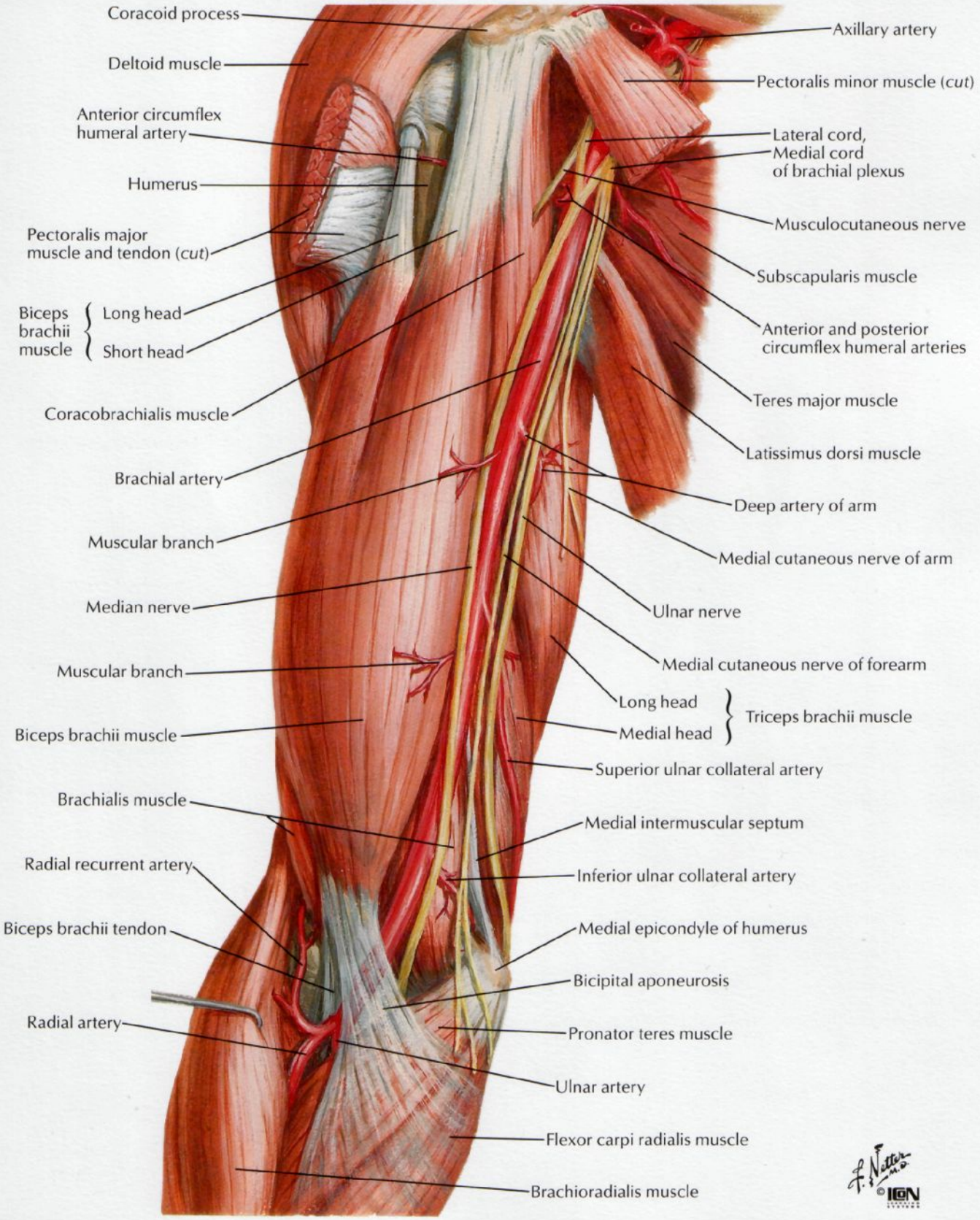

Brachial Artery and Anastomoses Around Elbow

SEE ALSO PLATE 410

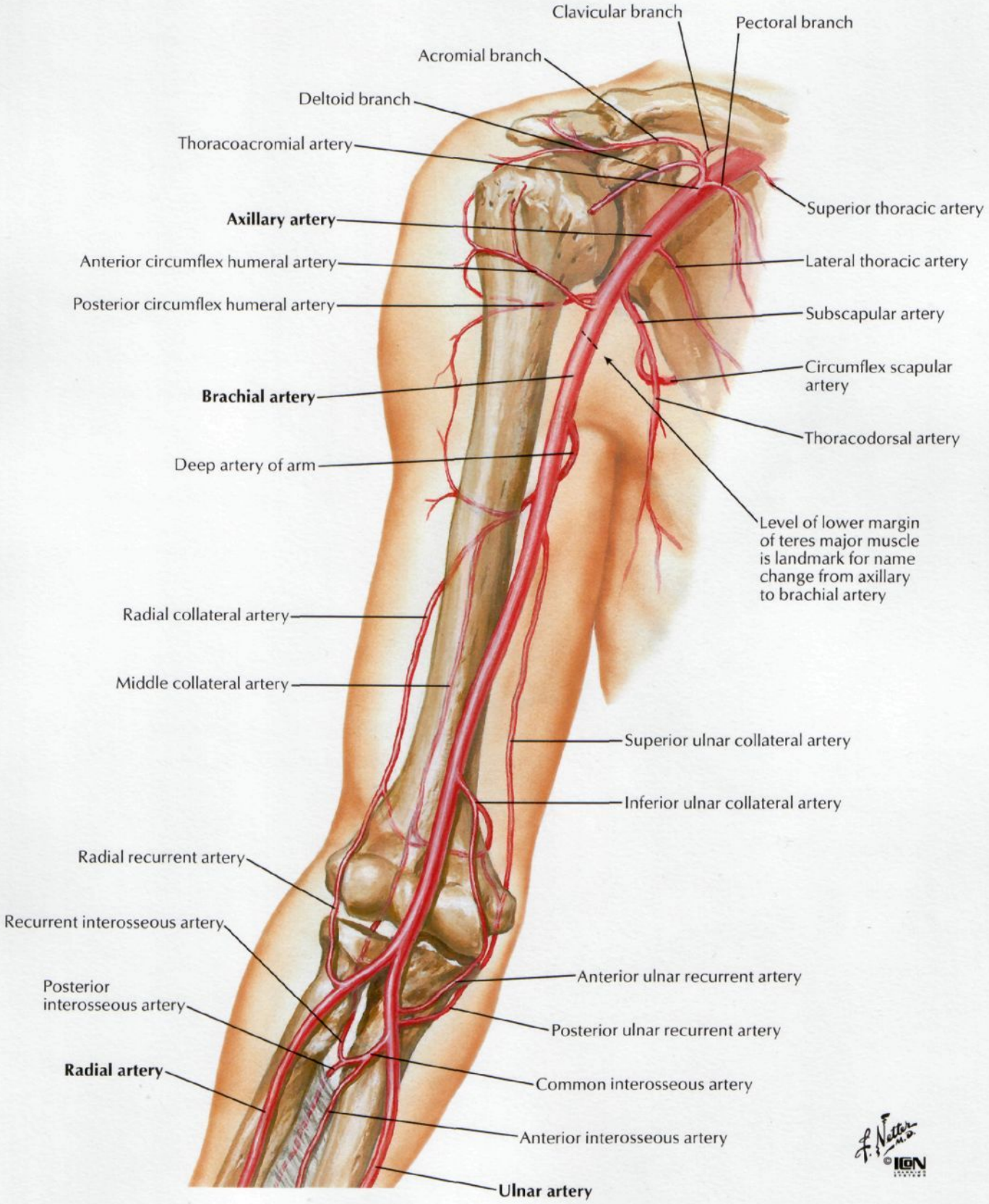

Arm: Serial Cross Sections

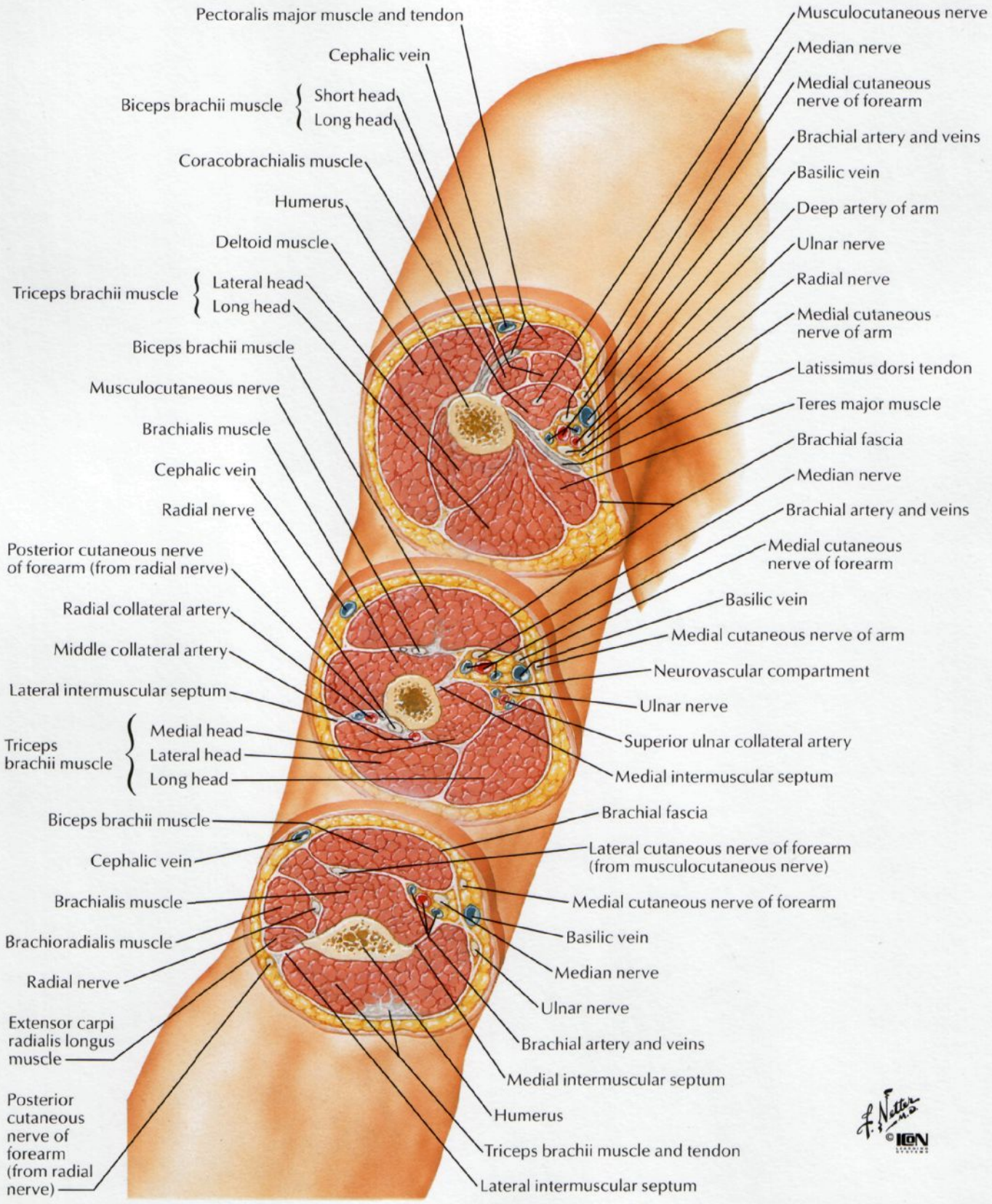

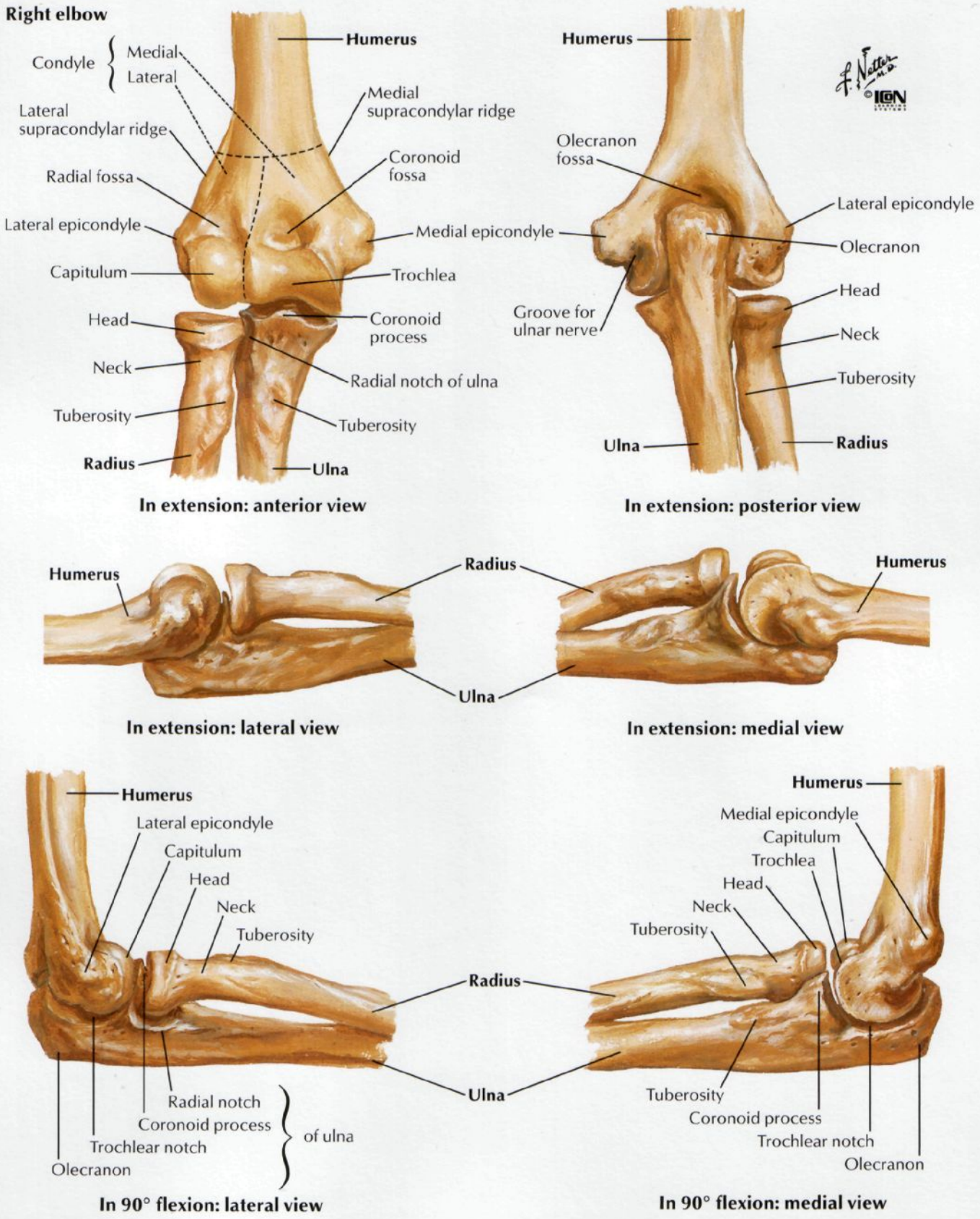
Right elbow
Humerus
Condyle
Medial
Lateral
Medial supracondylar ridge
Lateral supracondylar ridge
Coronoid fossa
Radial fossa
Lateral epicondyle
Medial epicondyle
Capitulum
Trochlea
Head
Coronoid process
Neck
Radial notch of ulna
Tuberosity
Tuberosity
Radius
Ulna
In extension: anterior view
Humerus
Olecranon fossa
Lateral epicondyle
Olecranon
Groove for ulnar nerve
Head
Neck
Tuberosity
Ulna
Radius
In extension: posterior view
Humerus
Radius
Ulna
In extension: lateral view
Humerus
In extension: medial view
Humerus
Lateral epicondyle
Capitulum
Head
Neck
Tuberosity
Radius
Ulna
Radial notch
Coronoid process
of ulna
Trochlear notch
Olecranon
In 90° flexion: lateral view
Humerus
Medial epicondyle
Capitulum
Trochlea
Head
Neck
Tuberosity
Tuberosity
Coronoid process
Trochlear notch
Olecranon
In 90° flexion: medial view

Elbow: Radiographs

SEE ALSO PLATE 419

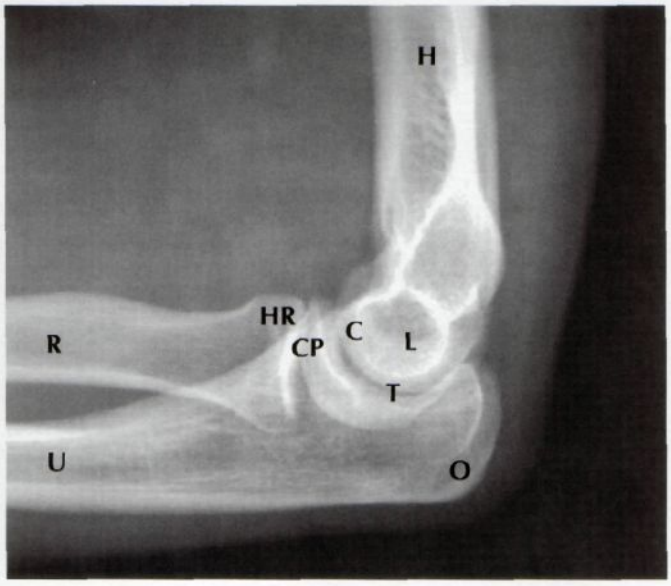

Lateral radiograph

C	Capitulum
CP	Coronoid process of ulna
H	Humerus
HR	Head of radius
L	Lateral epicondyle
O	Olecranon
R	Radius
T	Trochlear notch
U	Ulna

Anteroposterior radiograph

C	Capitulum
CP	Coronoid process of ulna
H	Humerus
HR	Head of radius
L	Lateral epicondyle
M	Medial of epicondyle
NR	Neck of radius
O	Olecranon
OF	Olecranon fossa
R	Radius
T	Trochlea of humerus
RT	Radial tuberosity
U	Ulna

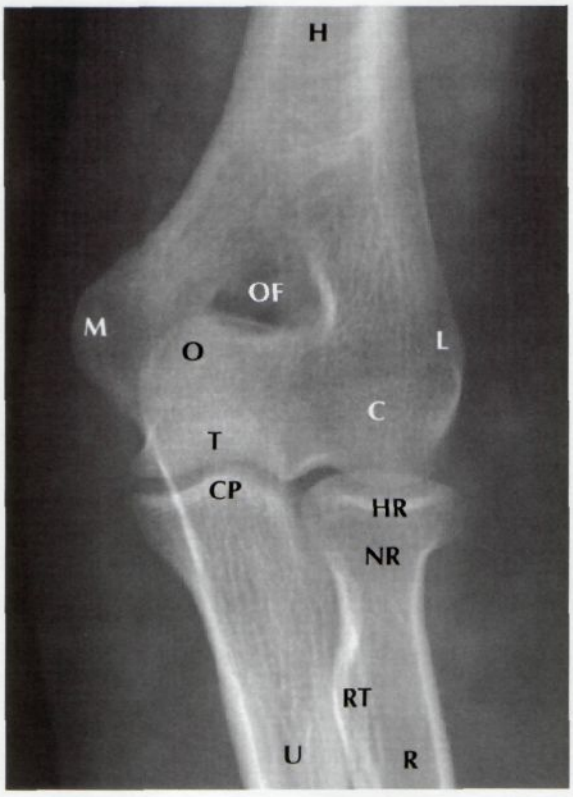

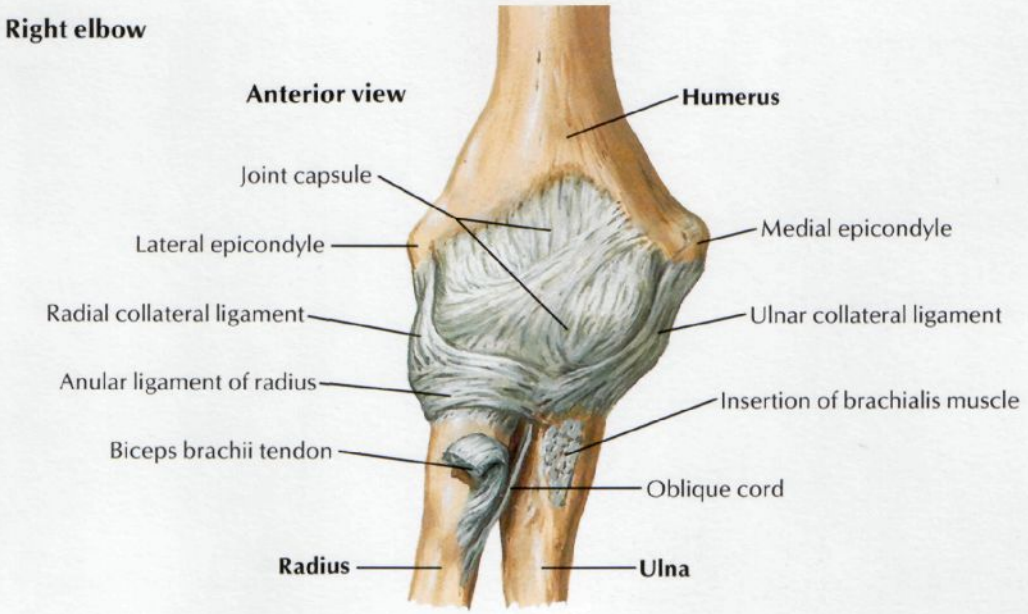

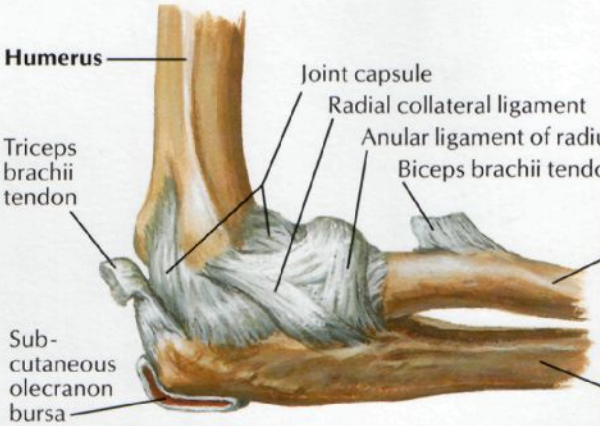

In 90° flexion: lateral view

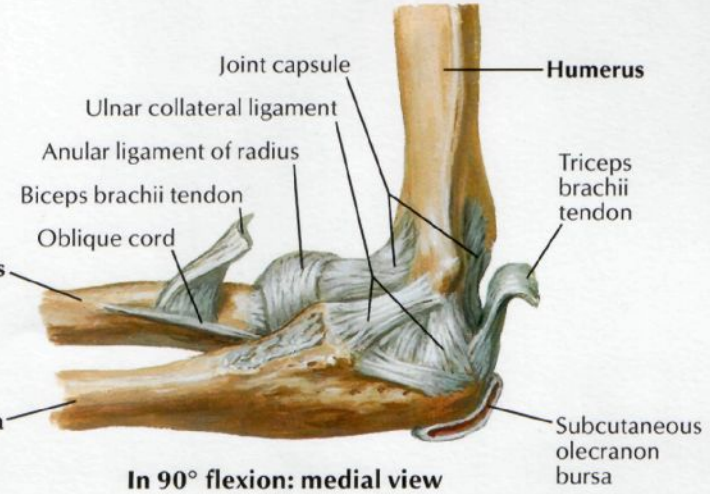

In 90° flexion: medial view

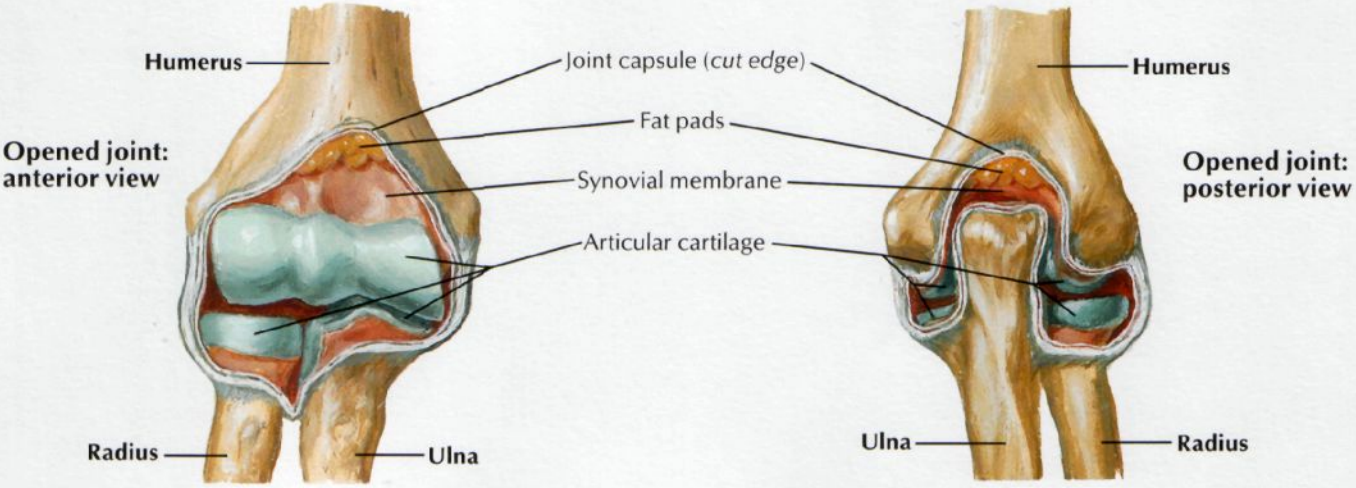

Bones of Forearm

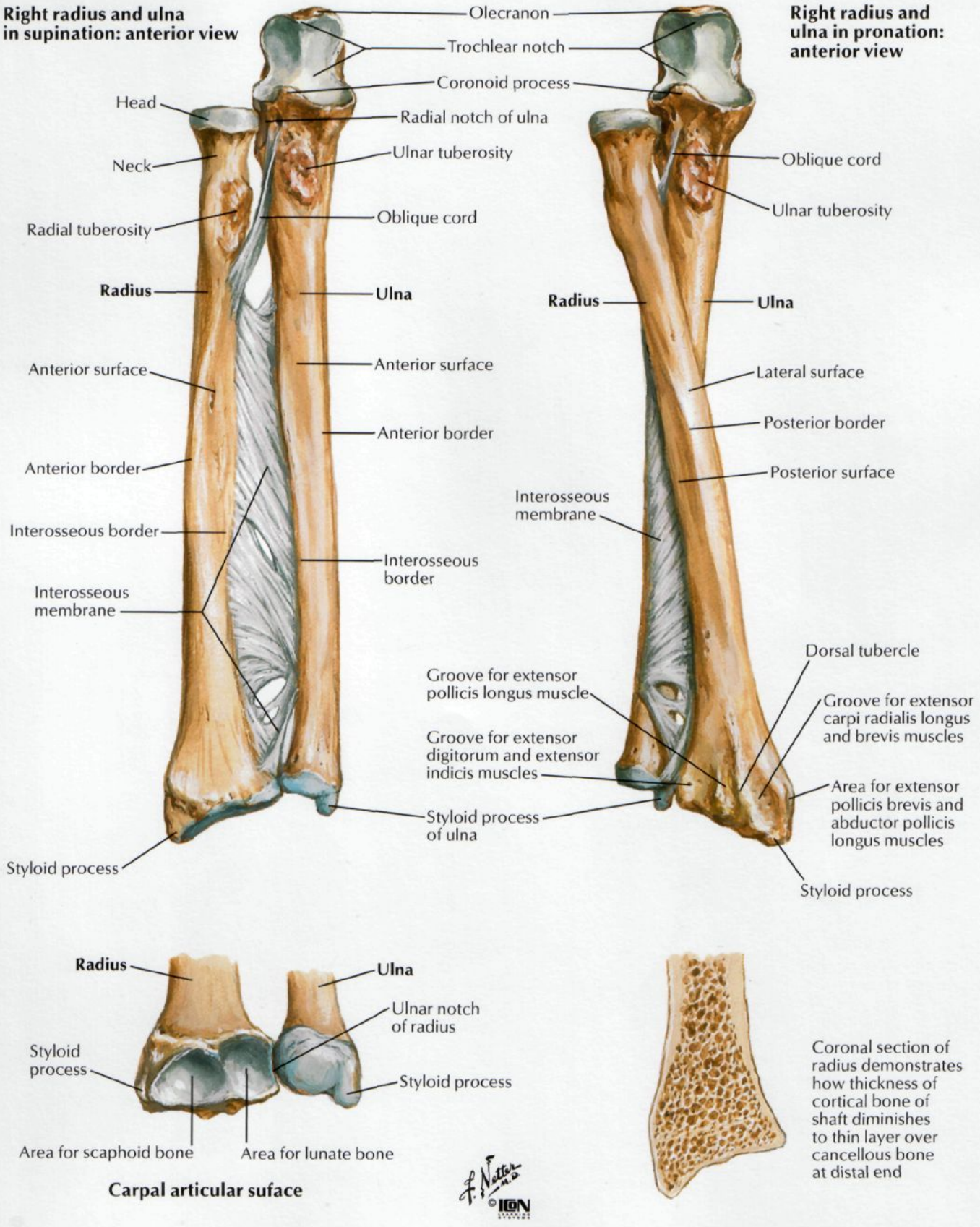

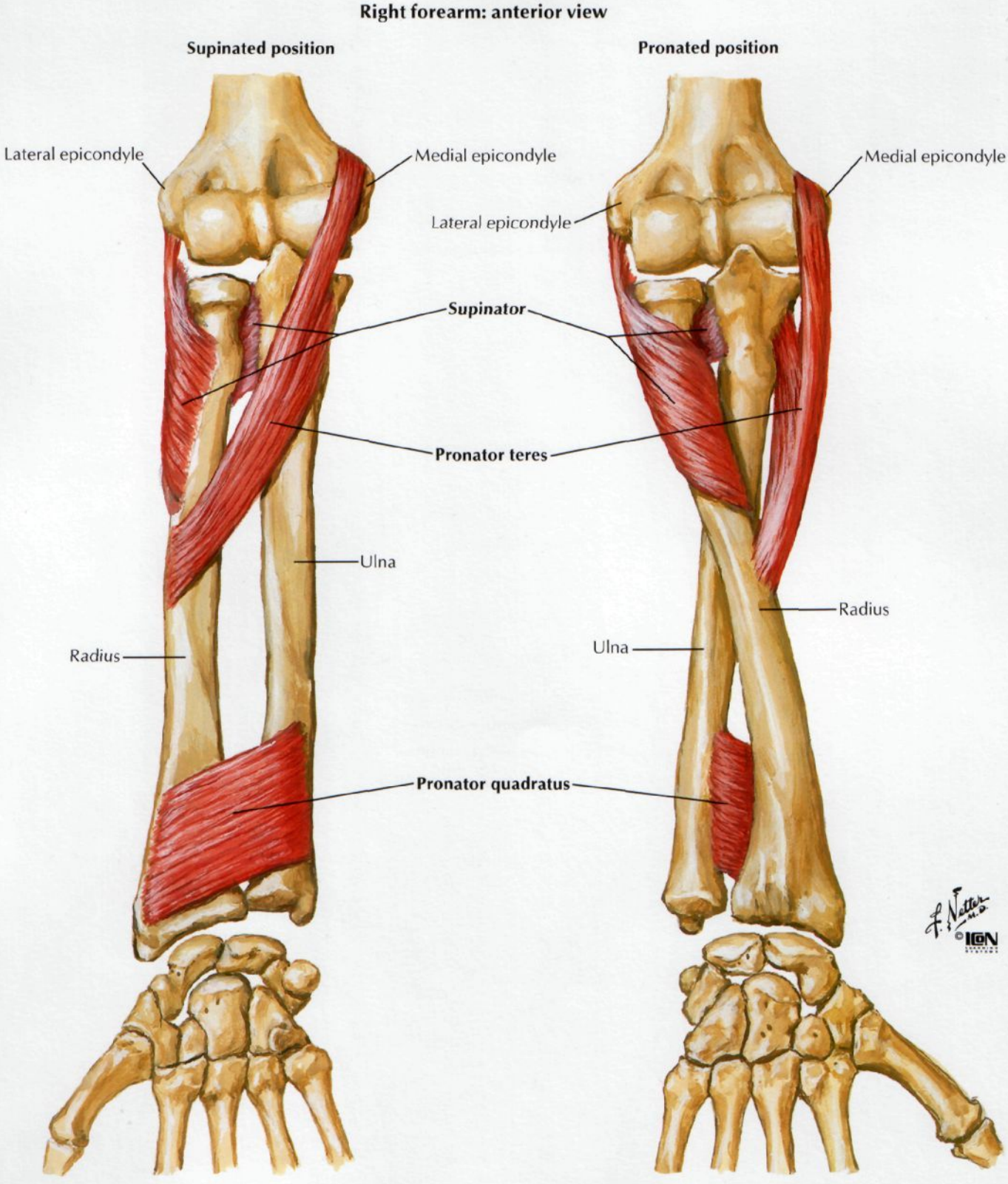
Right forearm: anterior view
Supinated position
Pronated position
Lateral epicondyle
Medial epicondyle
Lateral epicondyle
Medial epicondyle
Supinator
Pronator teres
Ulna
Radius
Radius
Ulna
Pronator quadratus
F. Netter M.D.
©IGN

Individual Muscles of Forearm: Extensors of Wrist and Digits

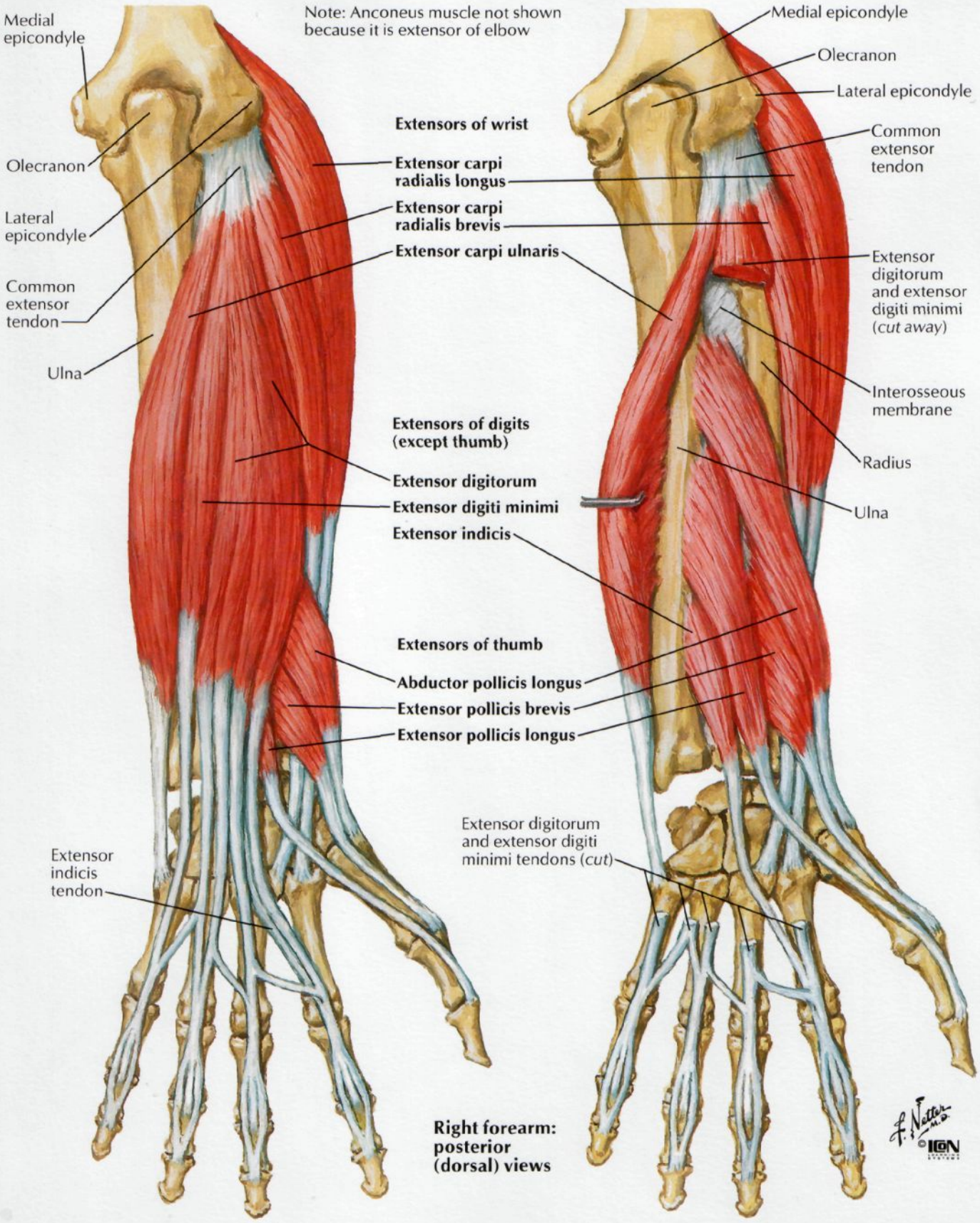

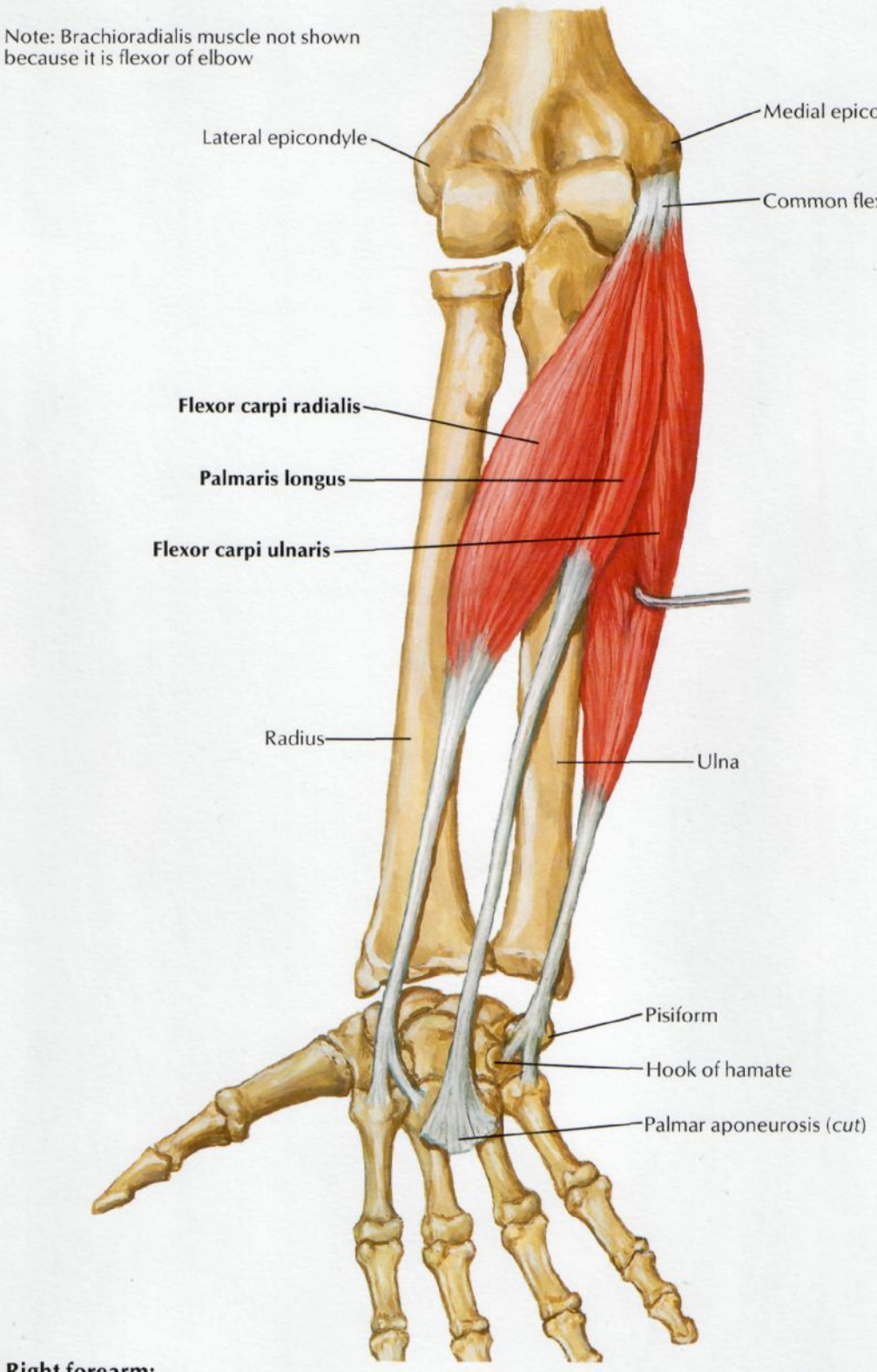

Right forearm: anterior (palmar) view

Individual Muscles of Forearm: Flexors of Digits

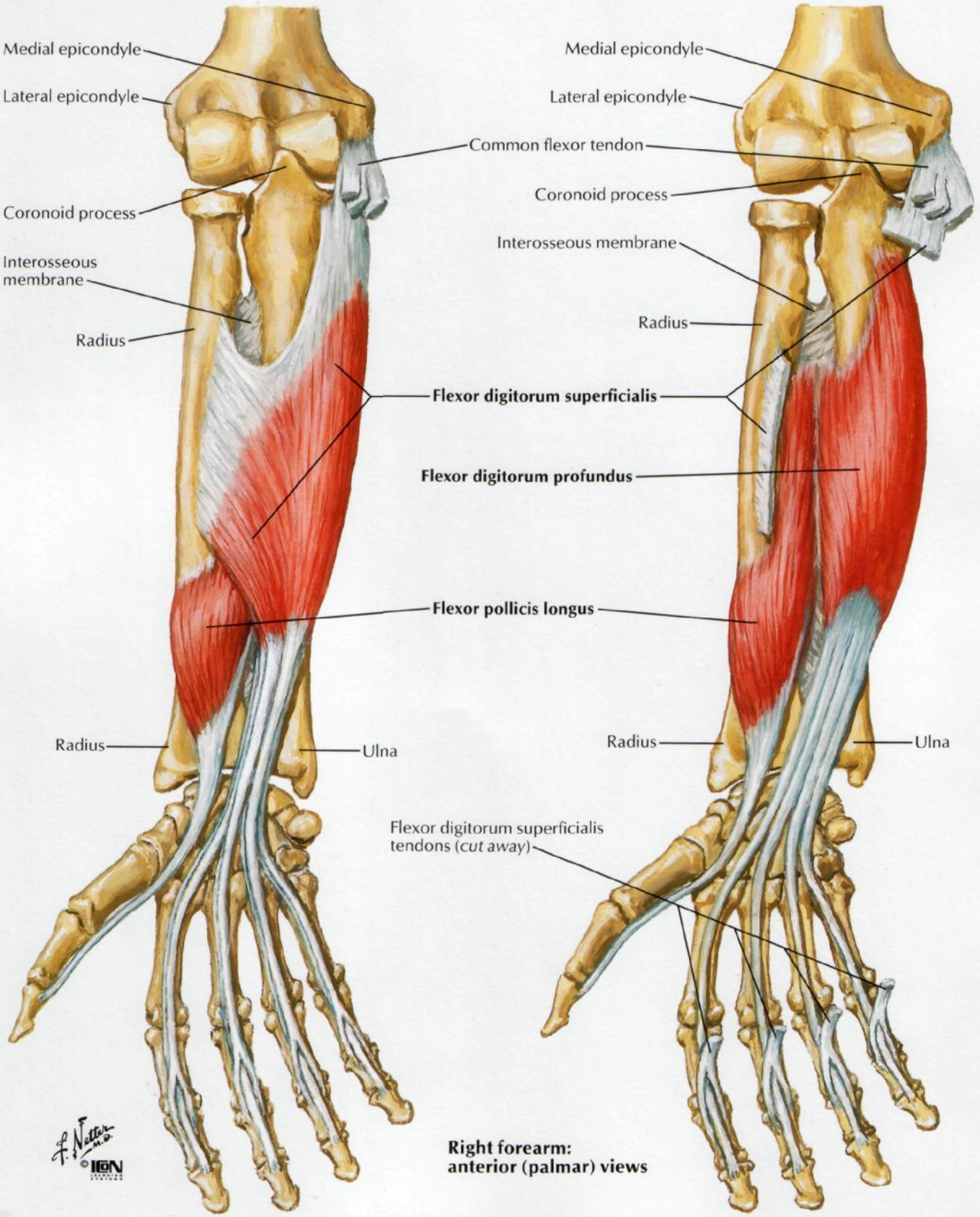

Right forearm: anterior (palmar) views

Muscles of Forearm (Superficial Layer): Posterior View

SEE ALSO PLATES 453, 461

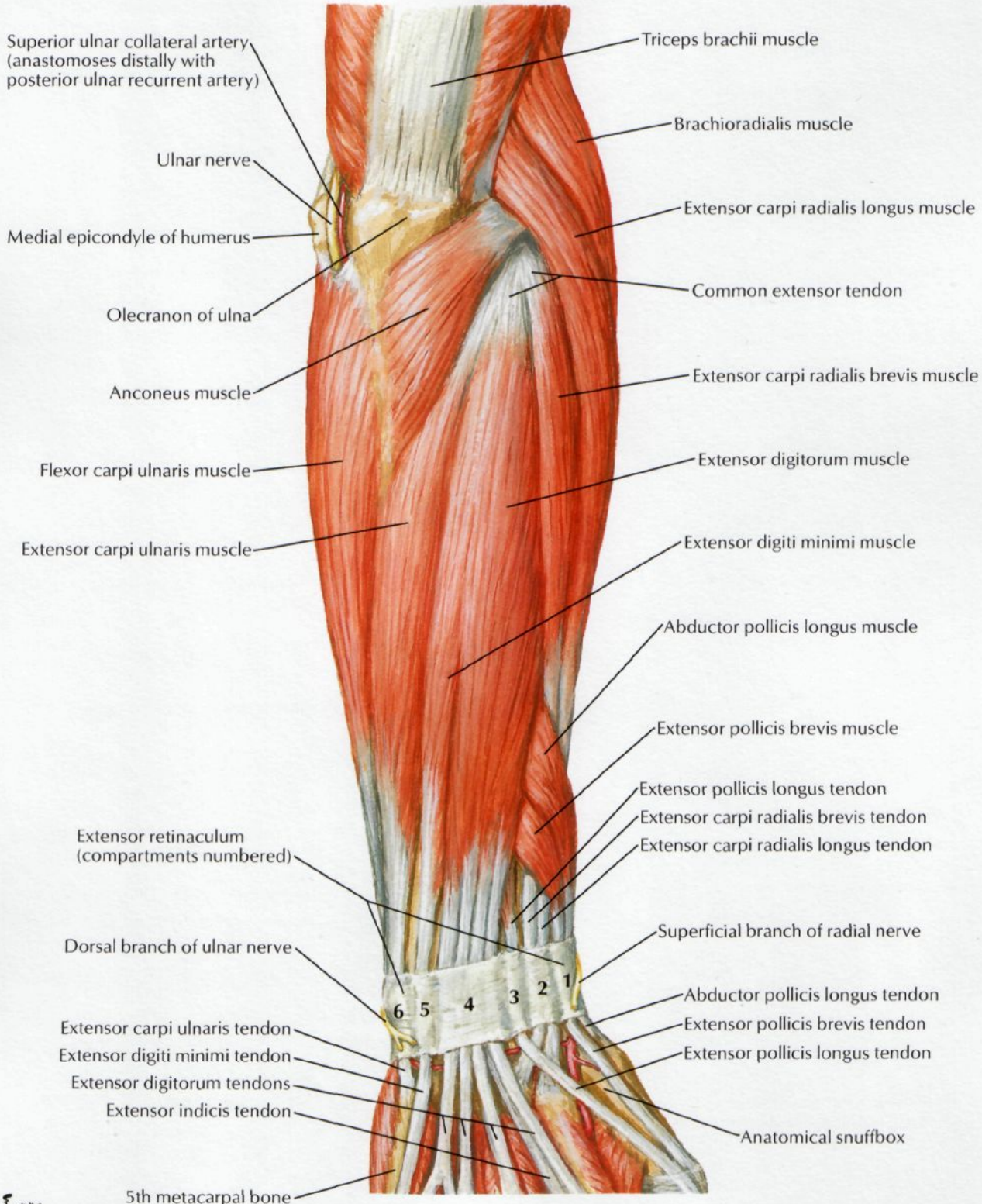

F. Netter M.D.
©ICON

Muscles of Forearm (Deep Layer): Posterior View

SEE ALSO PLATES 453, 461

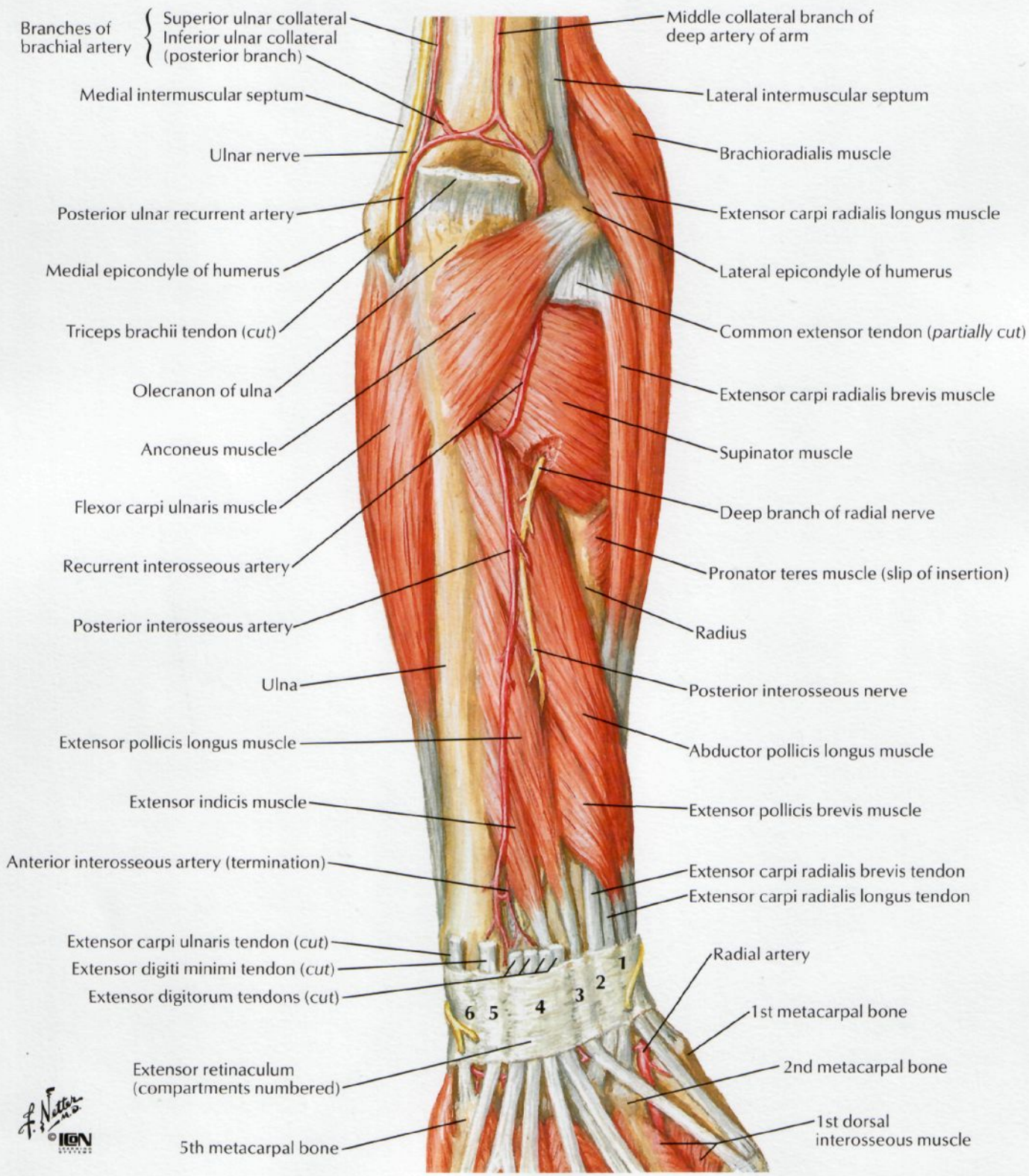

Muscles of Forearm (Superficial Layer): Anterior View

SEE ALSO PLATES 458, 459

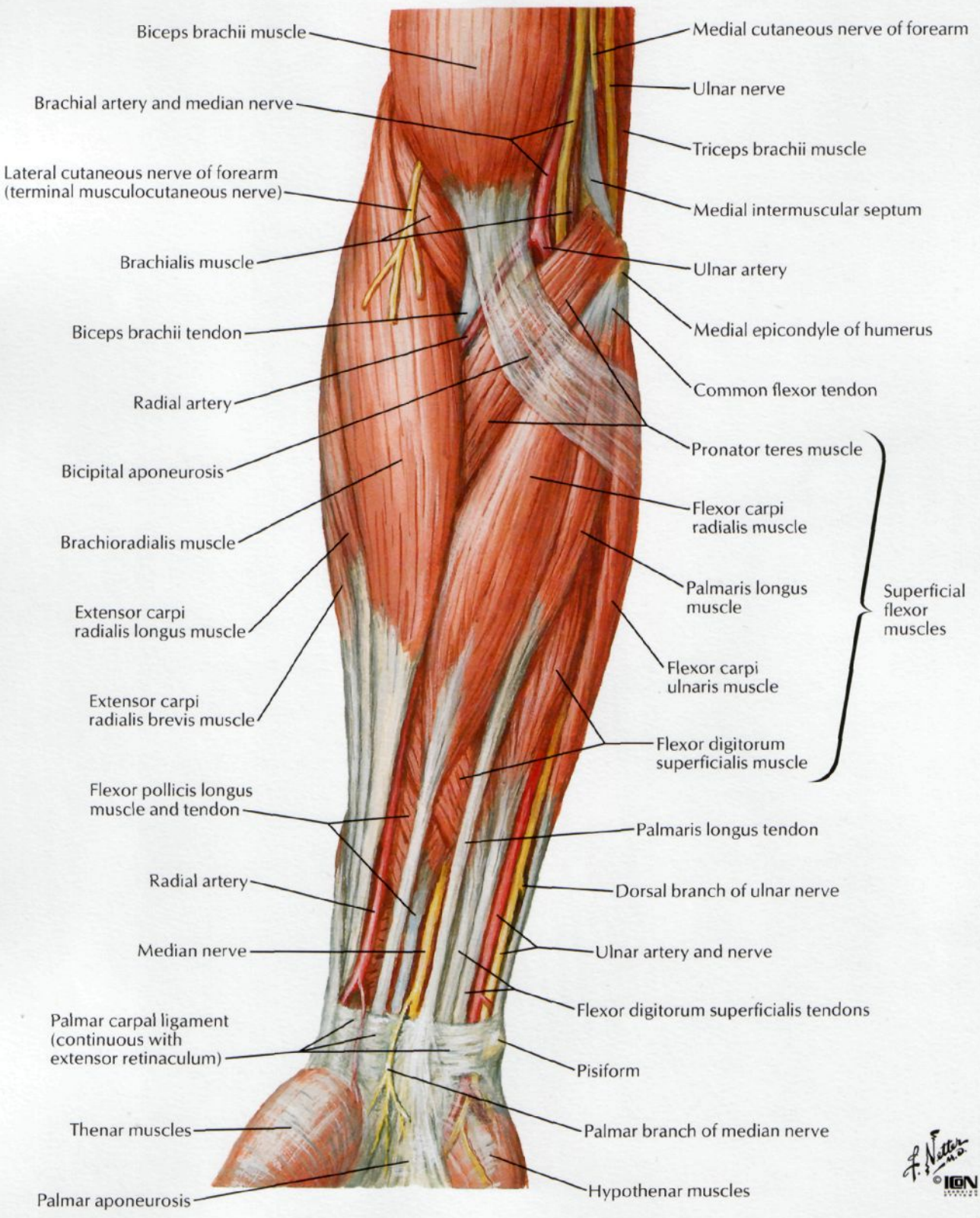

Muscles of Forearm (Intermediate Layer): Anterior View

SEE ALSO PLATES 458, 459

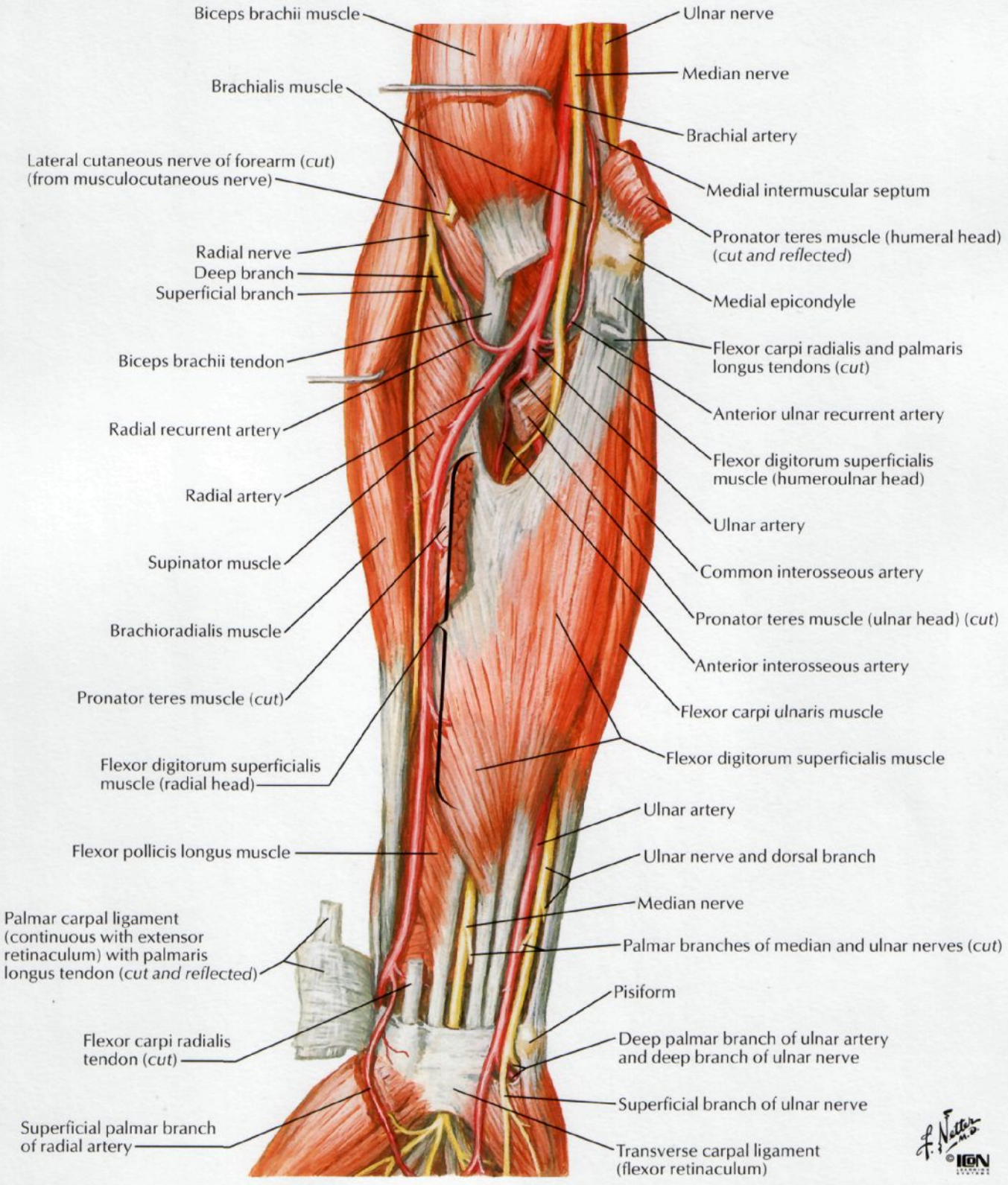

Muscles of Forearm (Deep Layer): Anterior View

SEE ALSO PLATES 458, 459

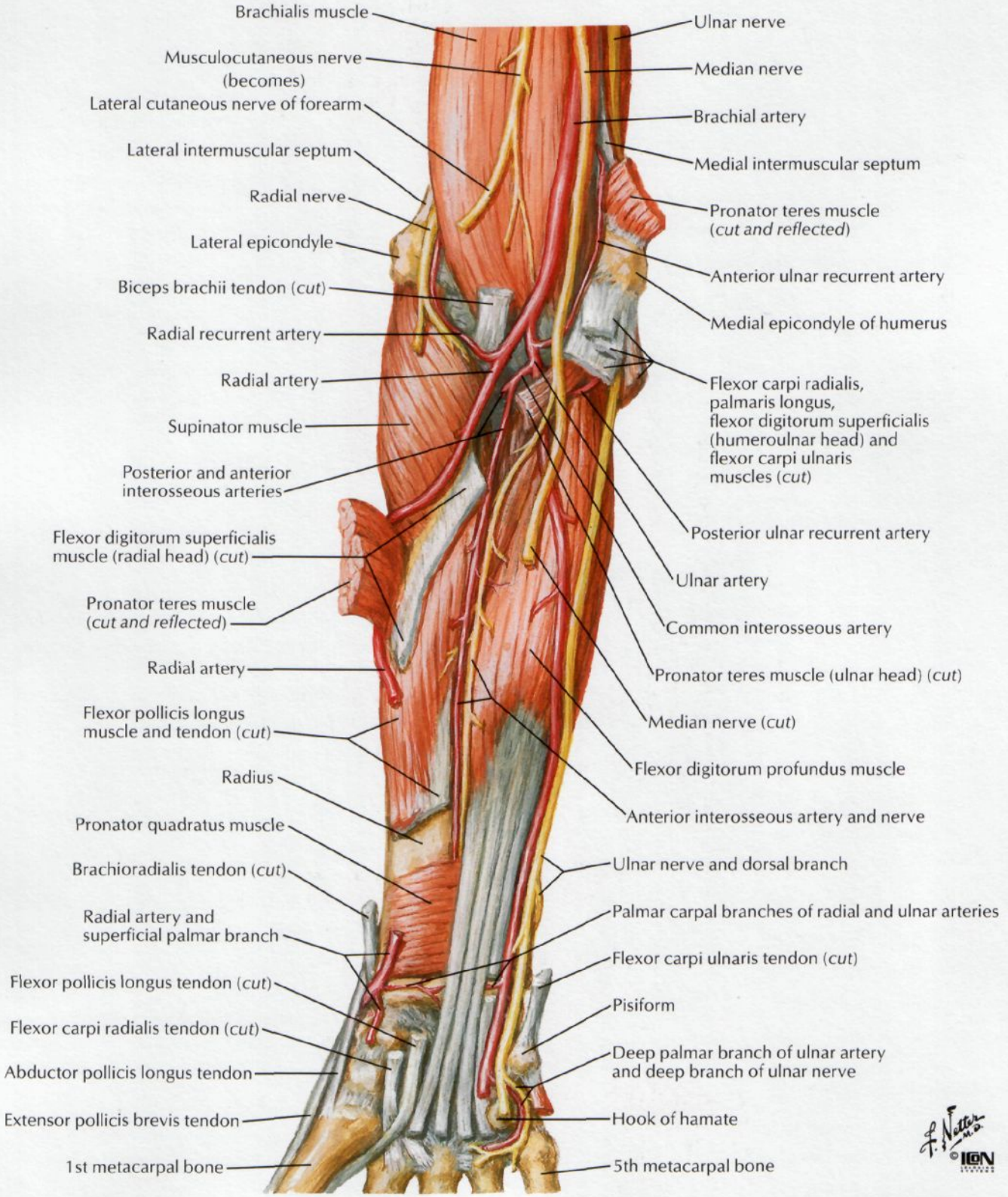

Forearm: Serial Cross Sections

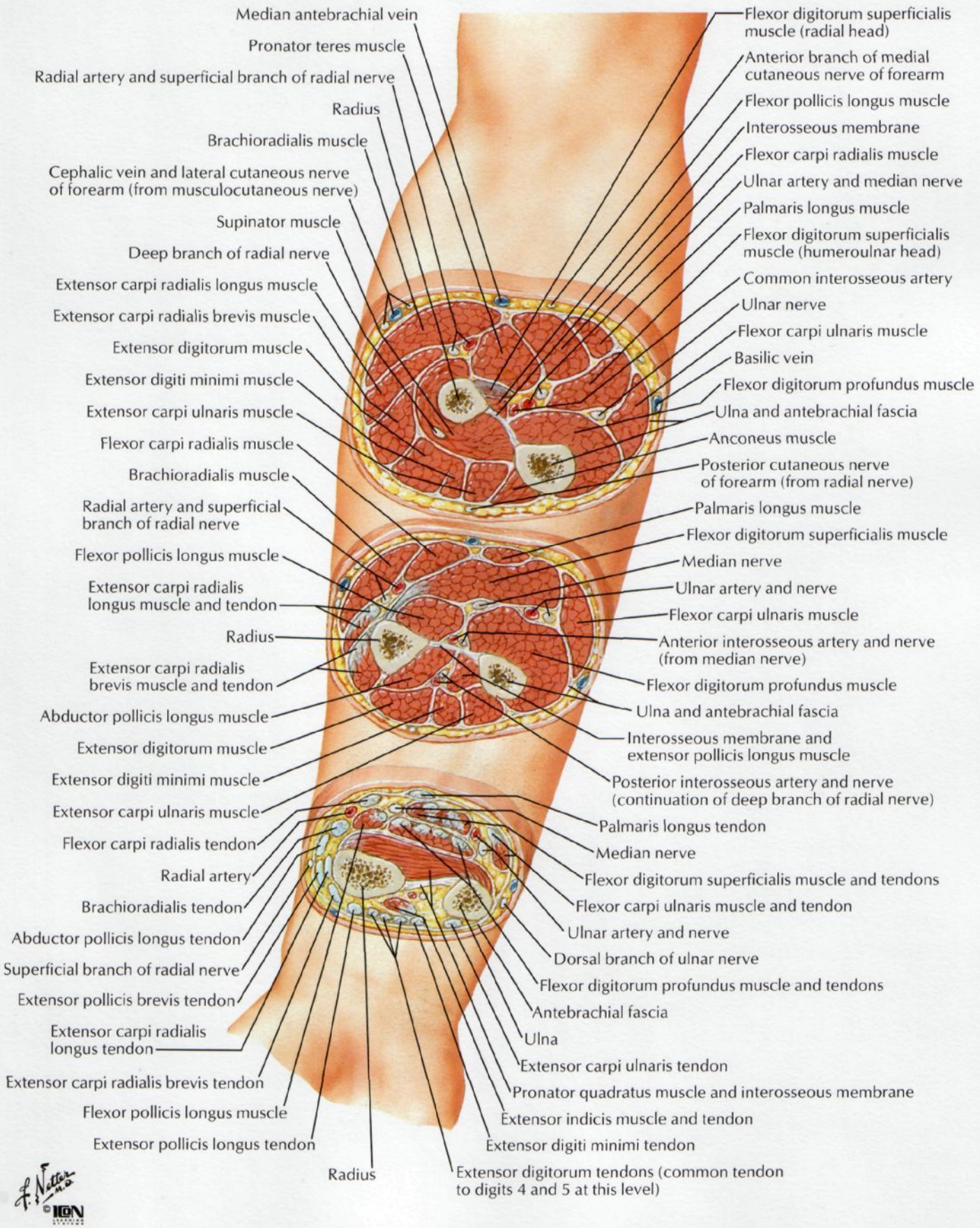

©IGN

Attachments of Muscles of Forearm: Anterior View

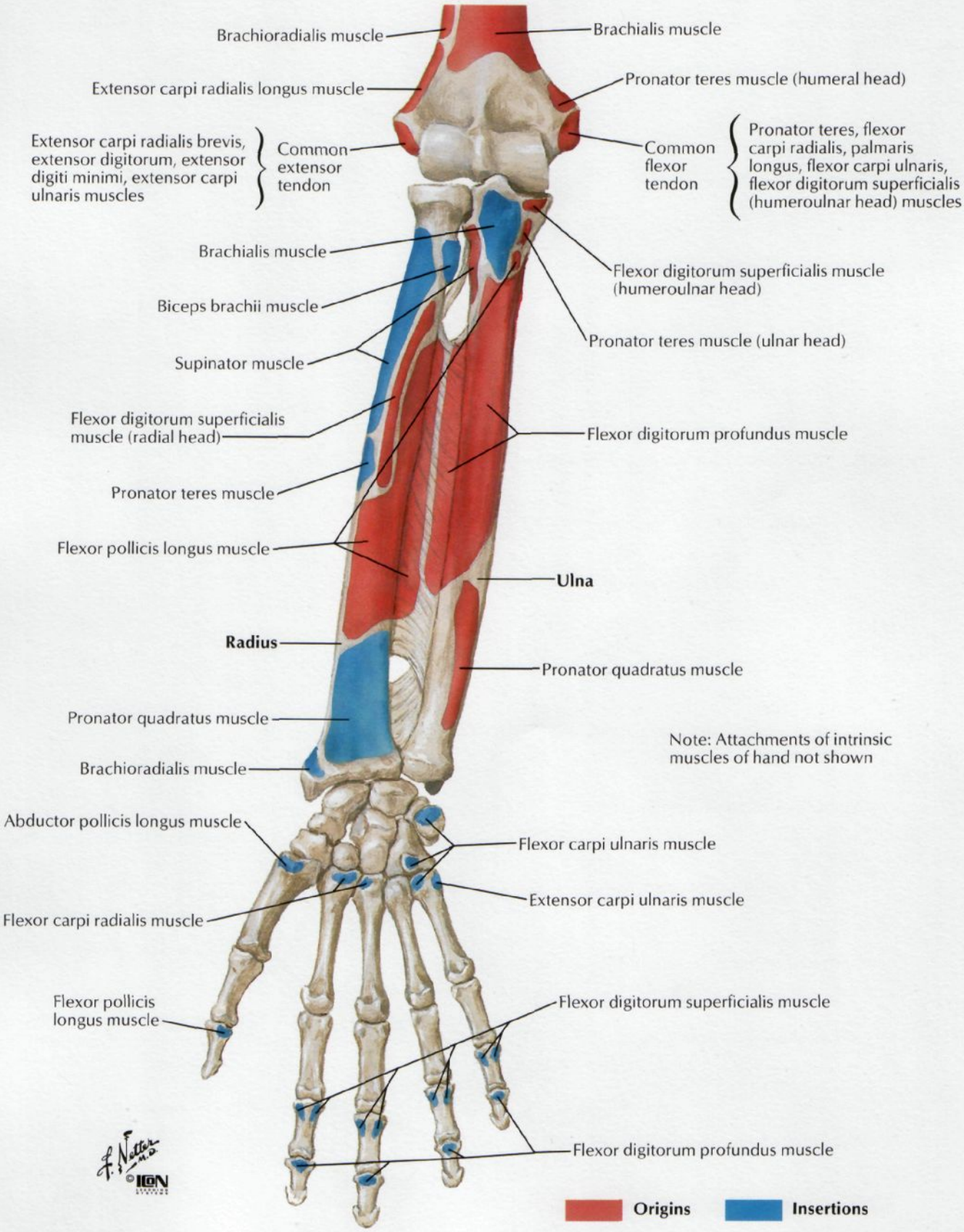

Attachments of Muscles of Forearm: Posterior View

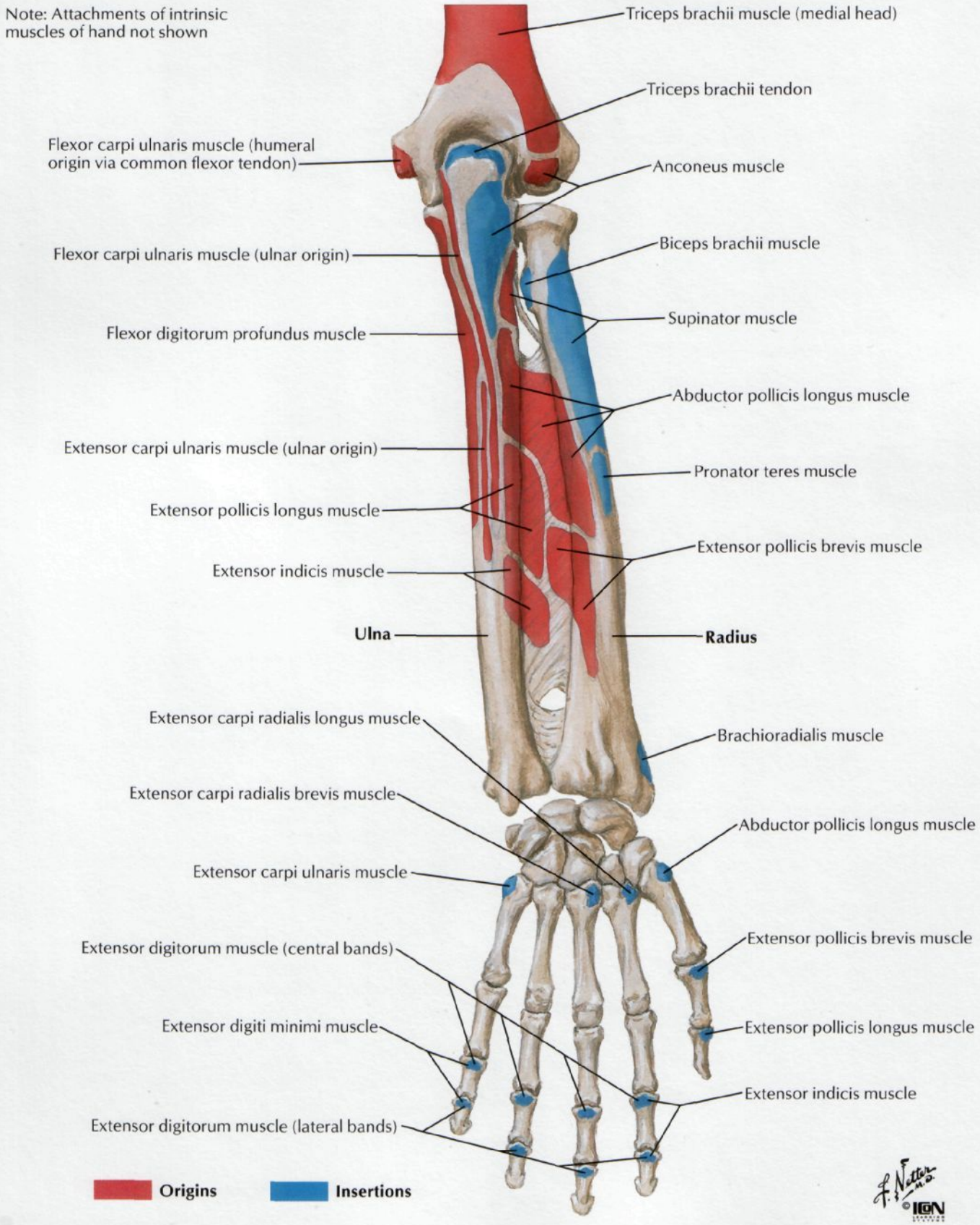

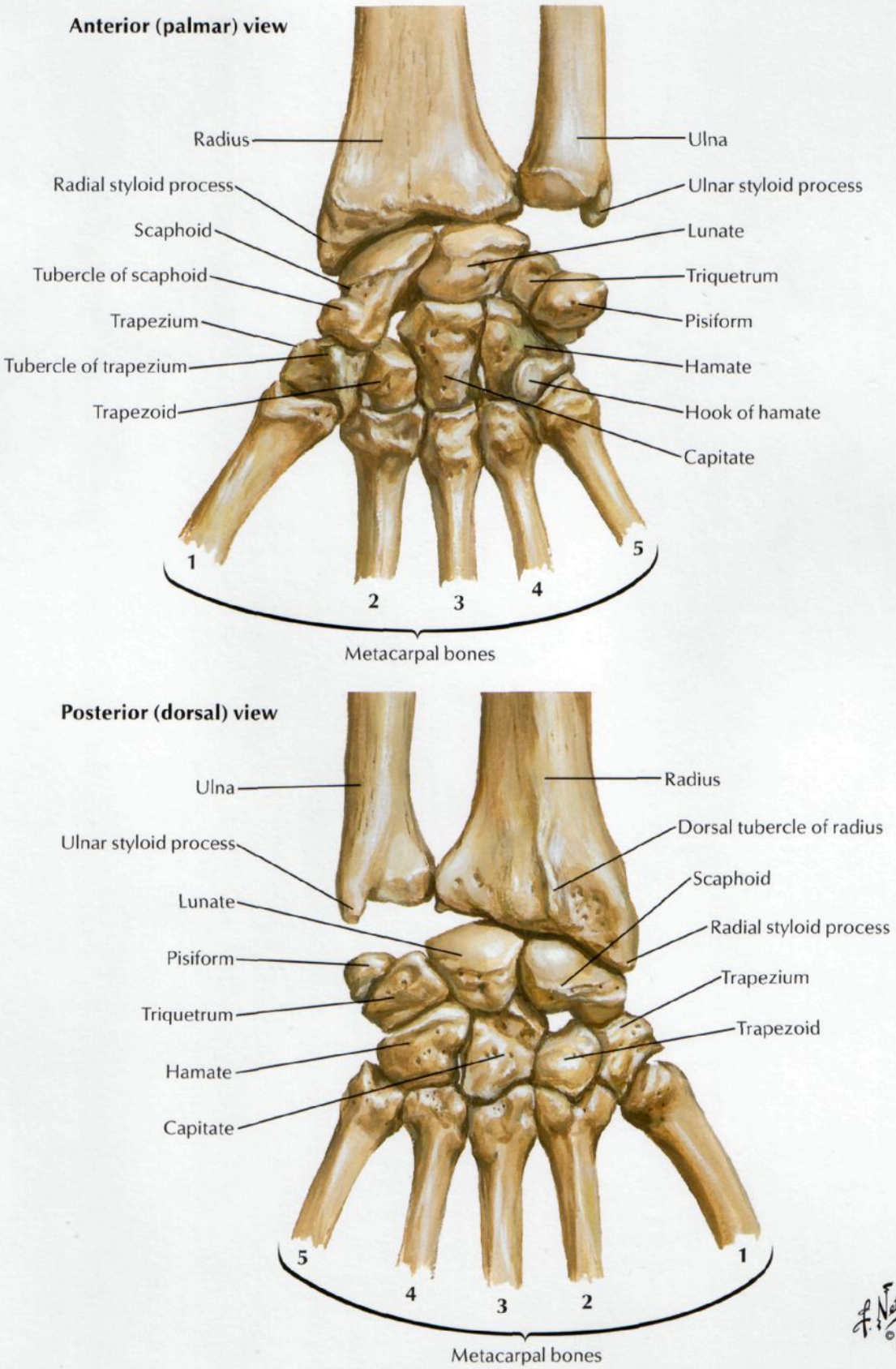
Anterior (palmar) view
Radius
Ulna
Radial styloid process
Ulnar styloid process
Scaphoid
Lunate
Tubercle of scaphoid
Triquetrum
Trapezium
Pisiform
Tubercle of trapezium
Hamate
Trapezoid
Hook of hamate
Capitate
1
2
3
4
5
Metacarpal bones
Posterior (dorsal) view
Ulna
Radius
Ulnar styloid process
Dorsal tubercle of radius
Lunate
Scaphoid
Pisiform
Radial styloid process
Triquetrum
Trapezium
Hamate
Trapezoid
Capitate
5
4
3
2
1
Metacarpal bones

Movements of Wrist

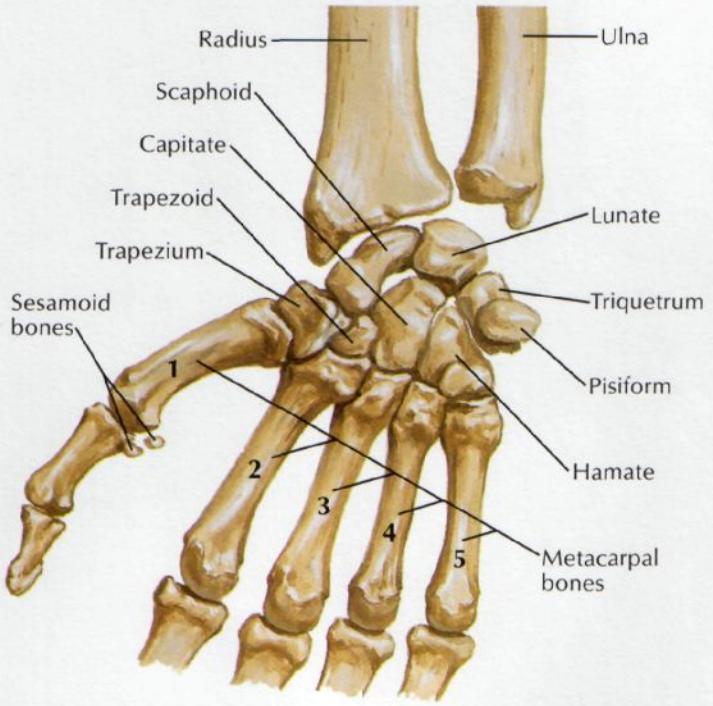

Position of carpal bones with hand in abduction: anterior (palmar) view

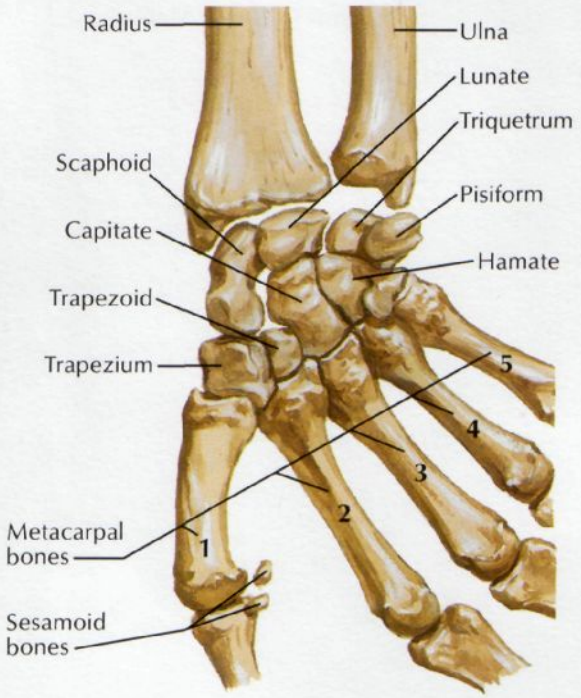

Position of carpal bones with hand in adduction: anterior (palmar) view

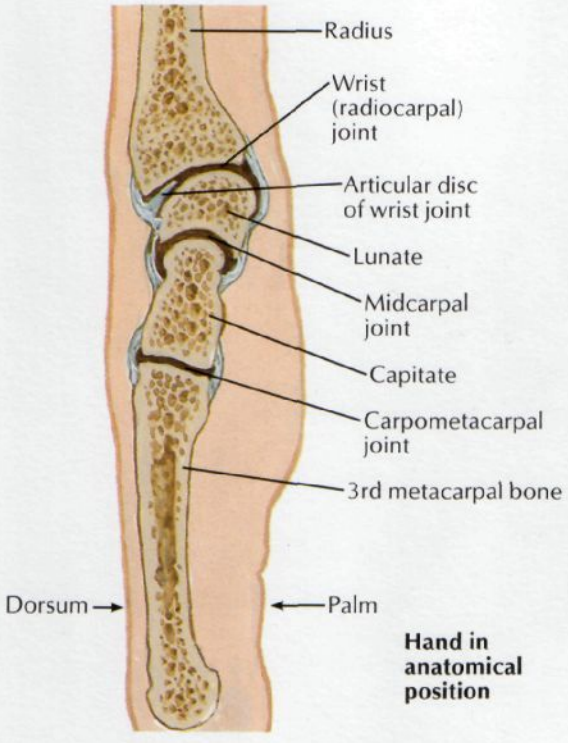

Sagittal sections through wrist and middle finger

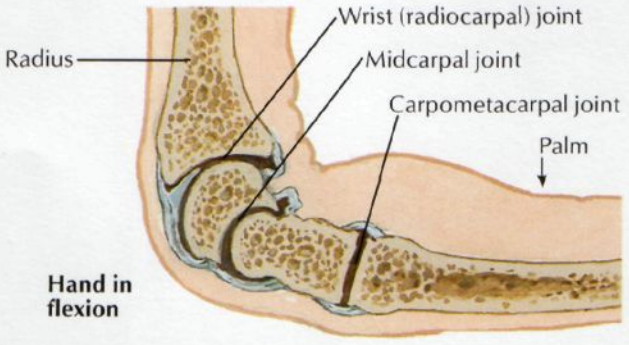

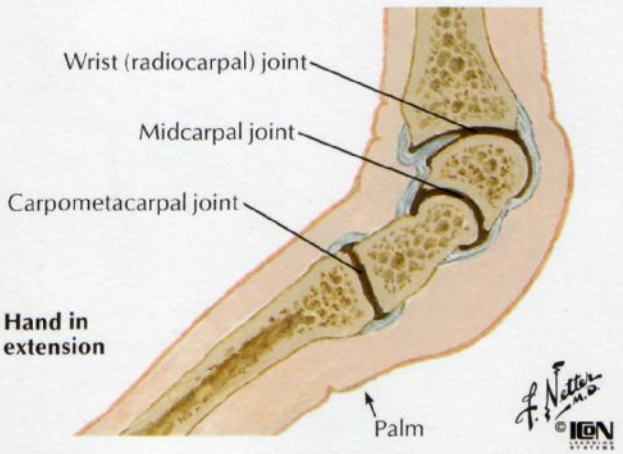

Carpal tunnel: palmar view

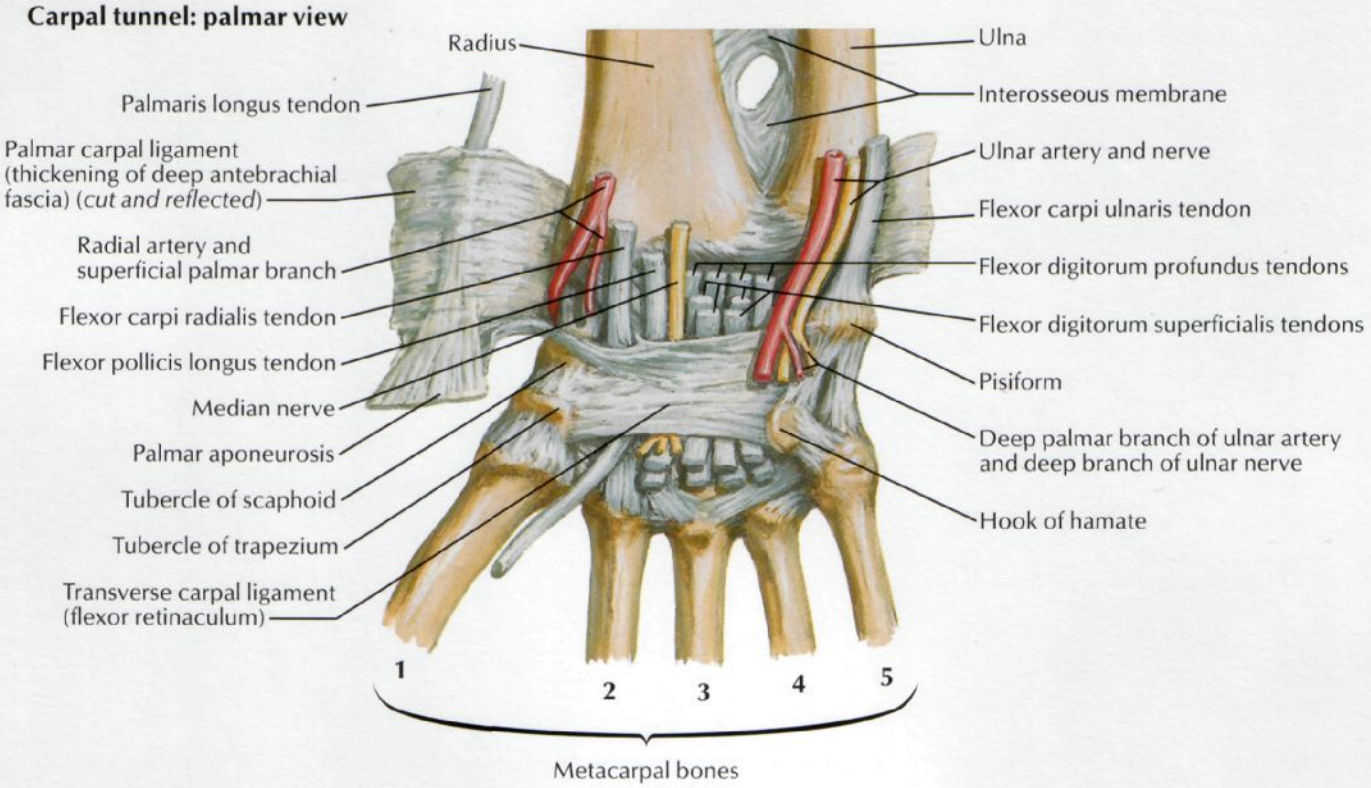

Flexor retinaculum removed: palmar view

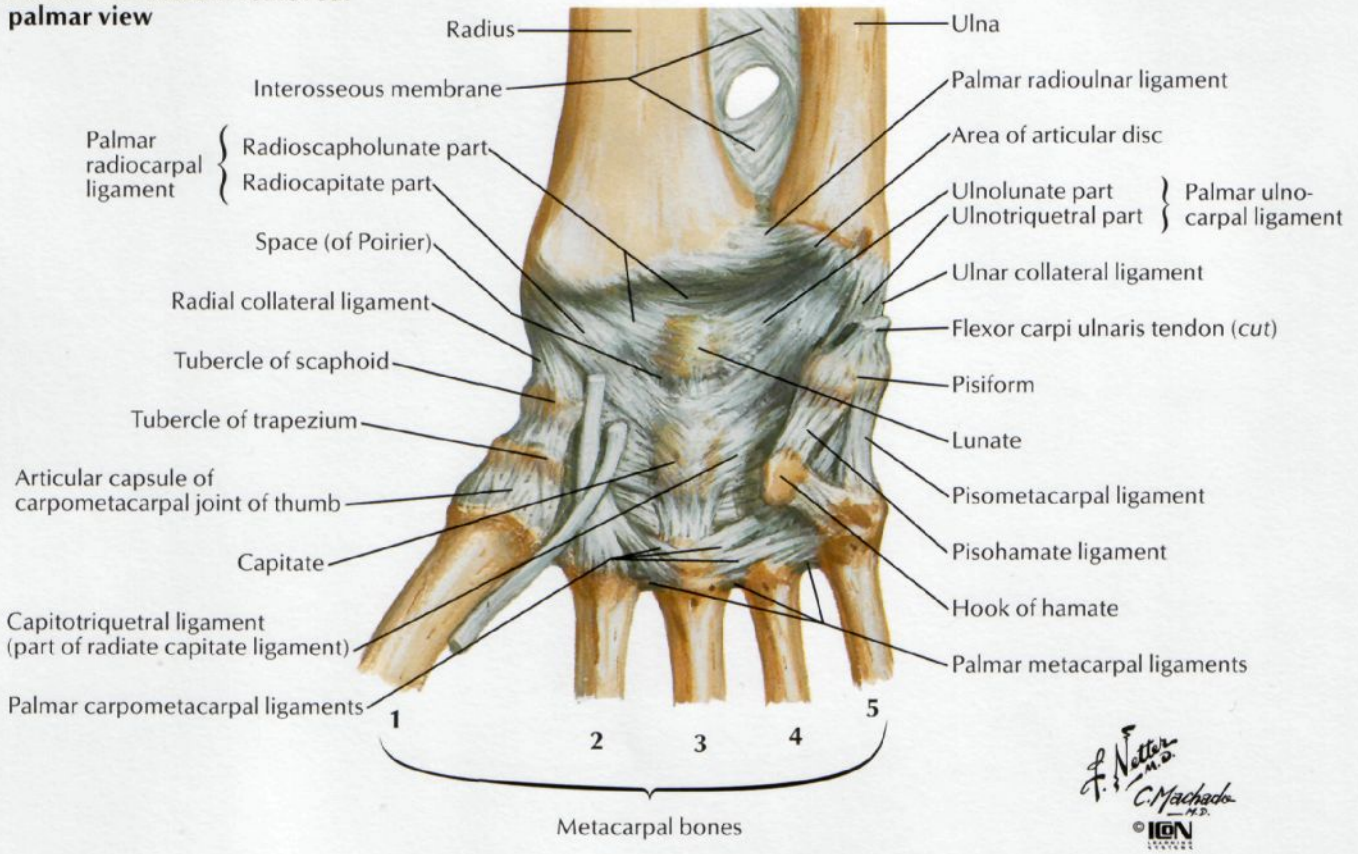

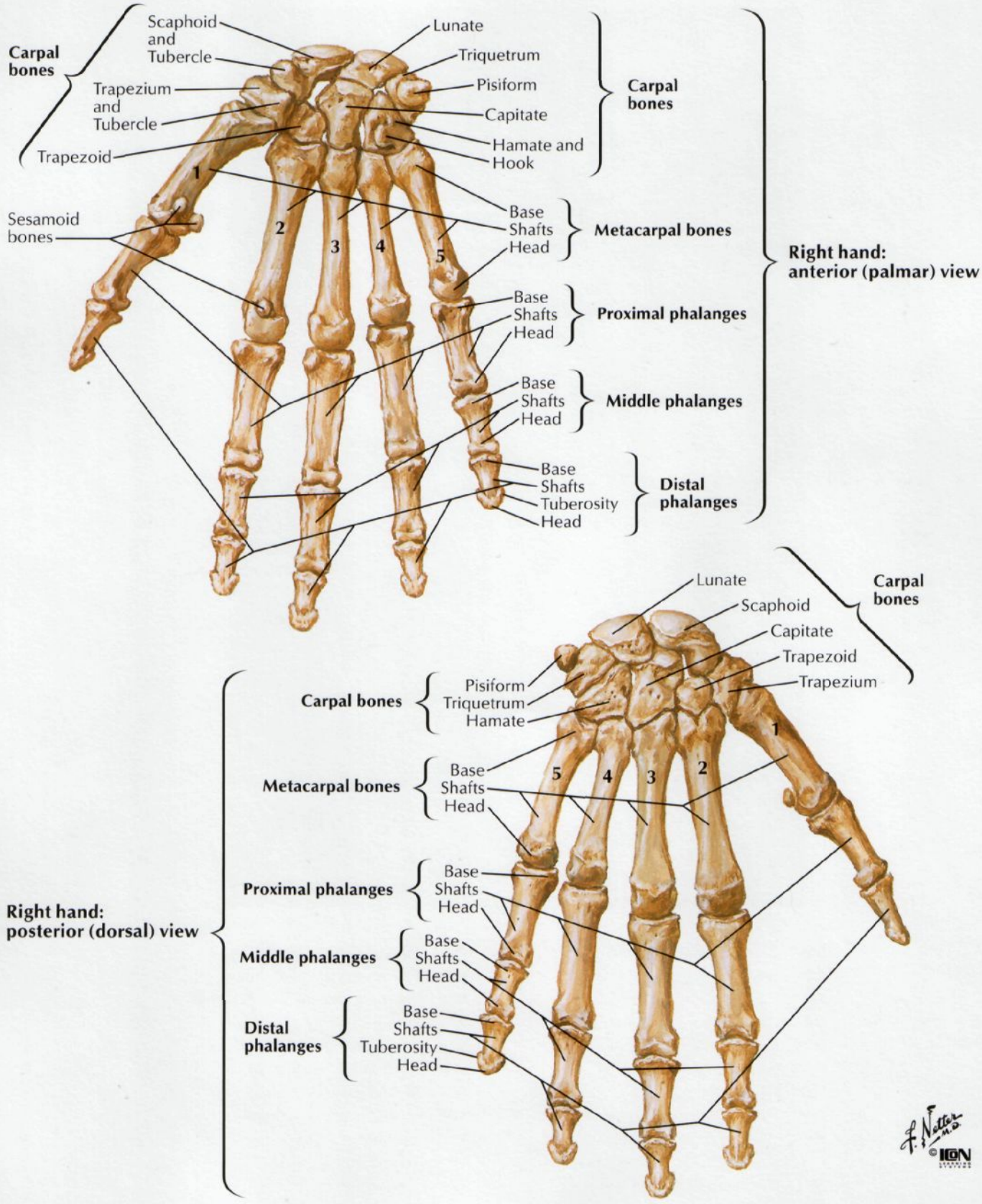
Carpal bones
Scaphoid and Tubercle
Trapezium and Tubercle
Trapezoid
Lunate
Triquetrum
Pisiform
Capitate
Hamate and Hook
Carpal bones
Sesamoid bones
1
2
3
4
5
Base
Shafts
Head
Metacarpal bones
Proximal phalanges
Middle phalanges
Base
Shafts
Tuberosity
Head
Distal phalanges
Right hand: anterior (palmar) view
Right hand: posterior (dorsal) view
Lunate
Scaphoid
Capitate
Trapezoid
Trapezium
Carpal bones
Pisiform
Triquetrum
Hamate
Metacarpal bones
Proximal phalanges
Middle phalanges
Distal phalanges
F. Netter M.D.
©IGN

Wrist and Hand: Anteroposterior Radiograph

SEE ALSO PLATE 439

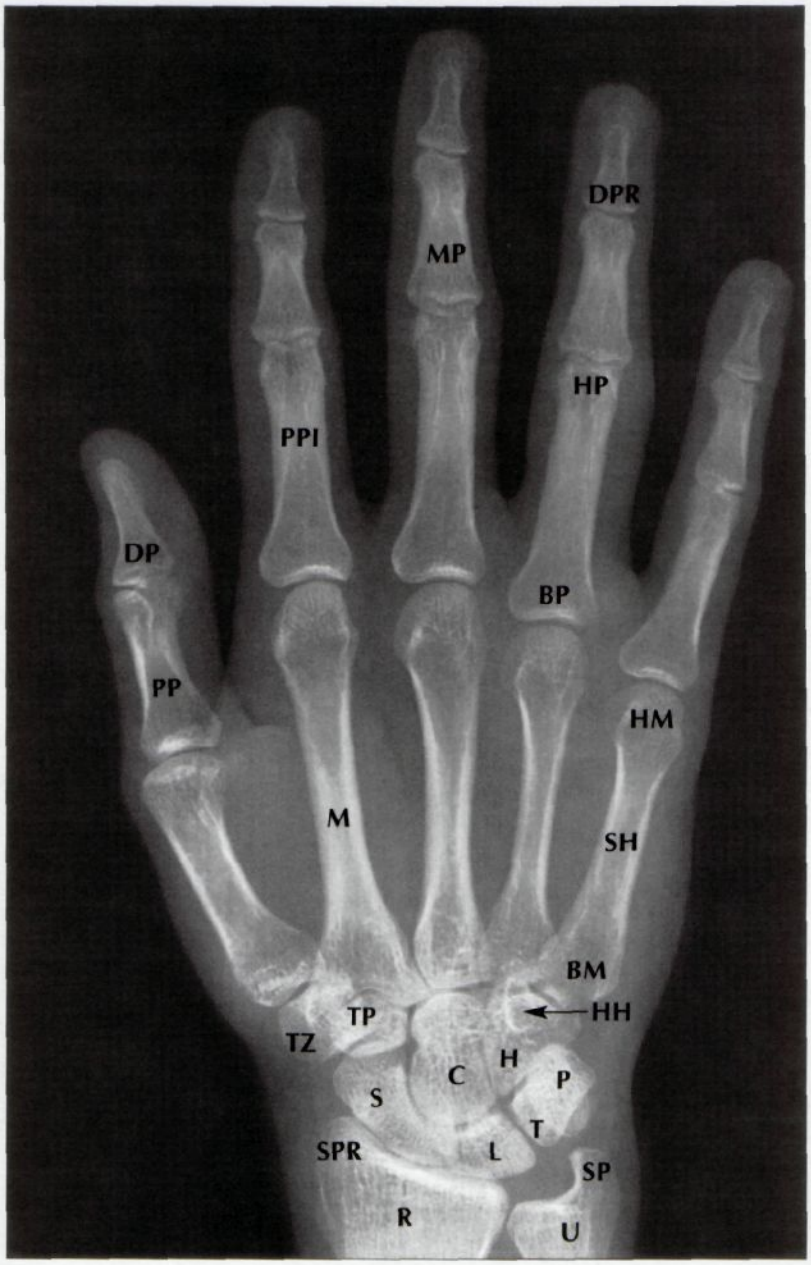

BM	Base of 5th metacarpal	**P**	Pisiform
BP	Base of 4th proximal phalanx	**PP**	Proximal phalanx of thumb
C	Capitate	**PPI**	Proximal phalanx of index finger
DP	Distal phalanx of thumb	**R**	Radius
DPR	Distal phalanx of ring finger	**S**	Scaphoid
H	Hamate	**SH**	Shaft of 5th metacarpal
HH	Hook of hamate	**SP**	Styloid process of ulna
HM	Head of 5th metacarpal	**SPR**	Styloid process of radius
HP	Head of proximal phalanx	**T**	Triquetrum
L	Lunate	**TP**	Trapezoid
M	Metacarpal of index finger	**TZ**	Trapezium
MP	Middle phalanx of middle finger	**U**	Ulna

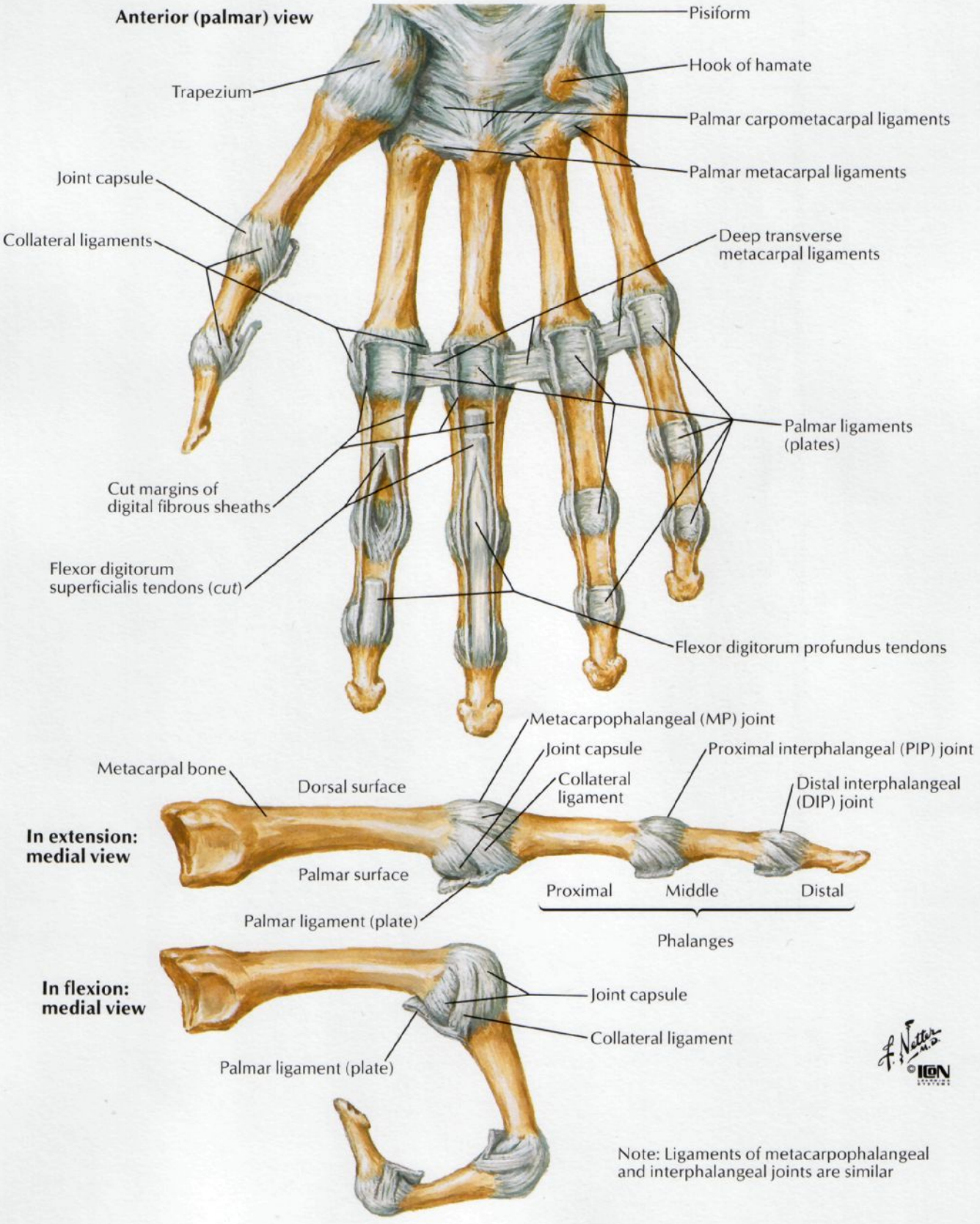
Anterior (palmar) view
Pisiform
Hook of hamate
Trapezium
Palmar carpometacarpal ligaments
Palmar metacarpal ligaments
Joint capsule
Collateral ligaments
Deep transverse metacarpal ligaments
Palmar ligaments (plates)
Cut margins of digital fibrous sheaths
Flexor digitorum superficialis tendons (cut)
Flexor digitorum profundus tendons
Metacarpophalangeal (MP) joint
Joint capsule
Proximal interphalangeal (PIP) joint
Metacarpal bone
Dorsal surface
Collateral ligament
Distal interphalangeal (DIP) joint
In extension: medial view
Palmar surface
Proximal
Middle
Distal
Palmar ligament (plate)
Phalanges
In flexion: medial view
Joint capsule
Collateral ligament
Palmar ligament (plate)
Note: Ligaments of metacarpophalangeal and interphalangeal joints are similar

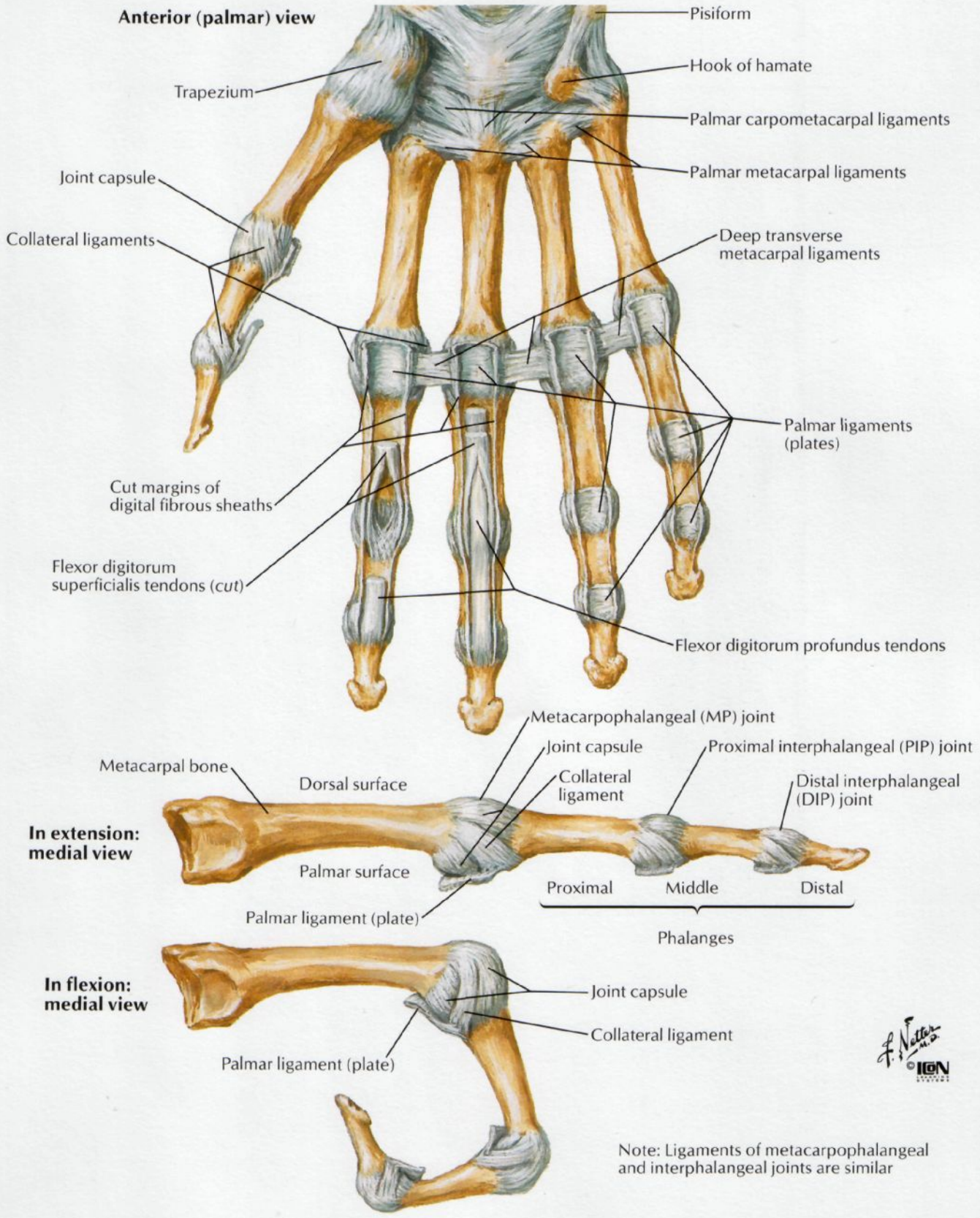

Note: Ligaments of metacarpophalangeal and interphalangeal joints are similar

Wrist and Hand: Superficial Palmar Dissections

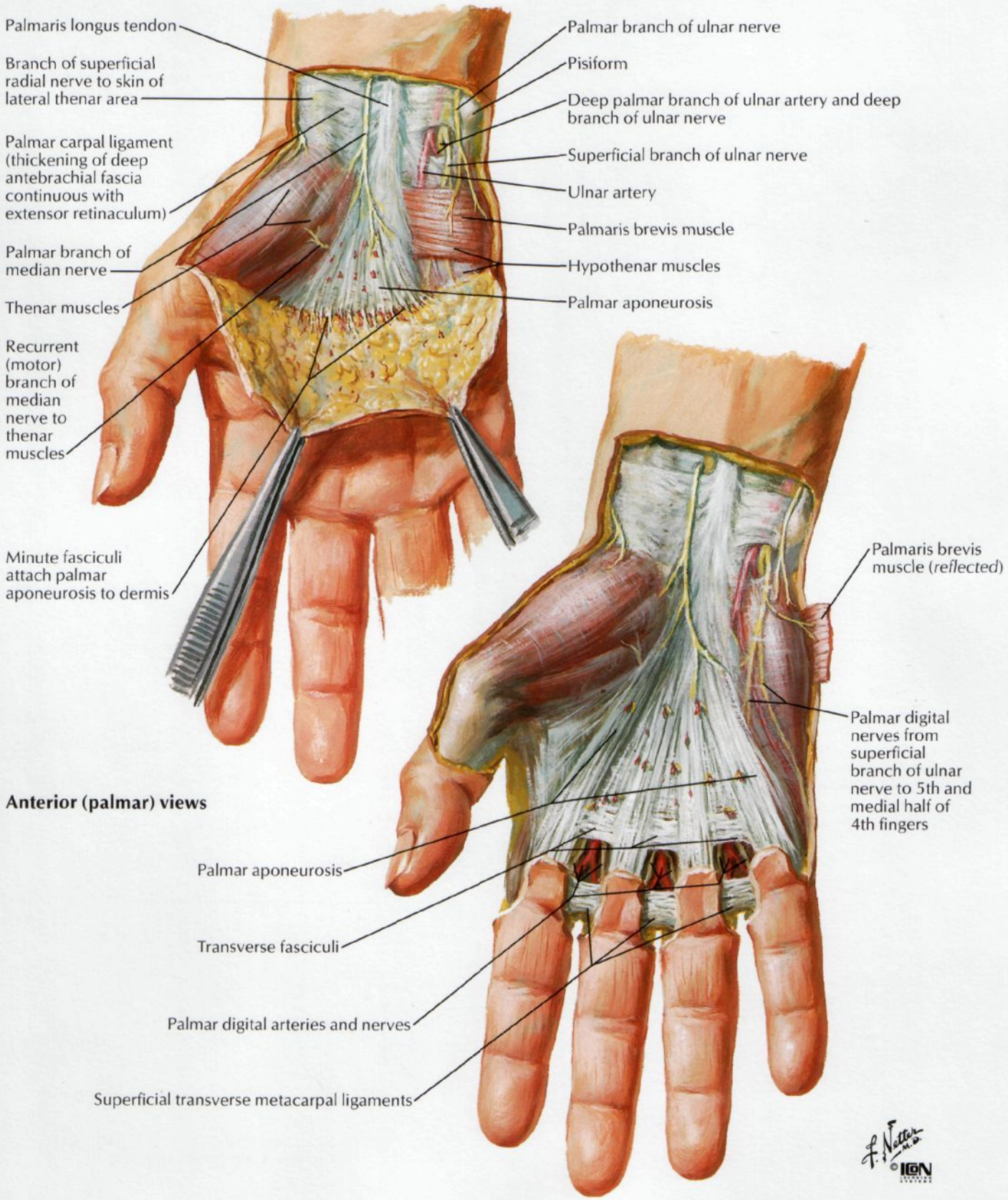

Anterior (palmar) views

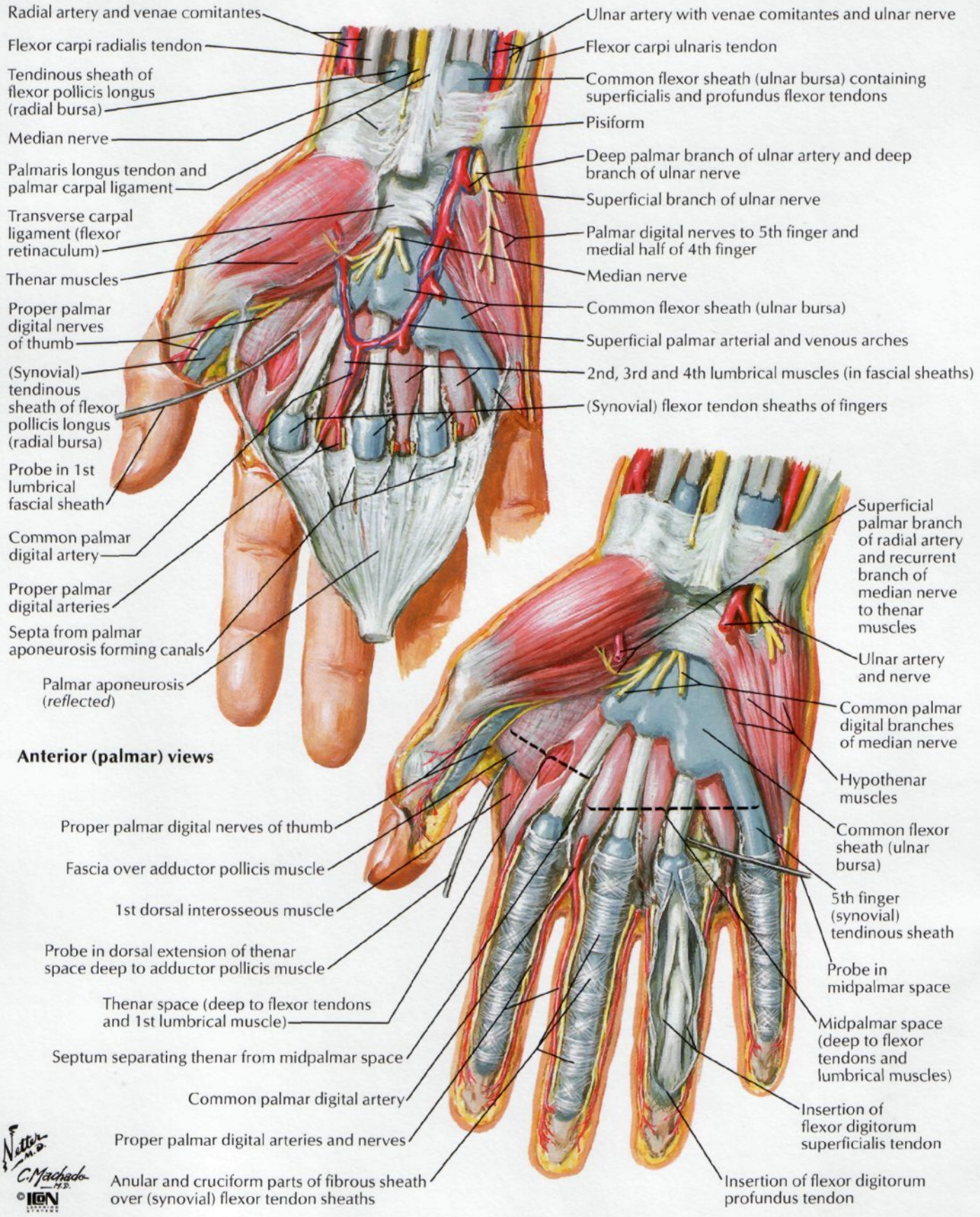

Anterior (palmar) views

F. Netter, M.D.
C. Machado, M.D.
©IGN

Flexor Tendons, Arteries and Nerves at Wrist

Palmar view

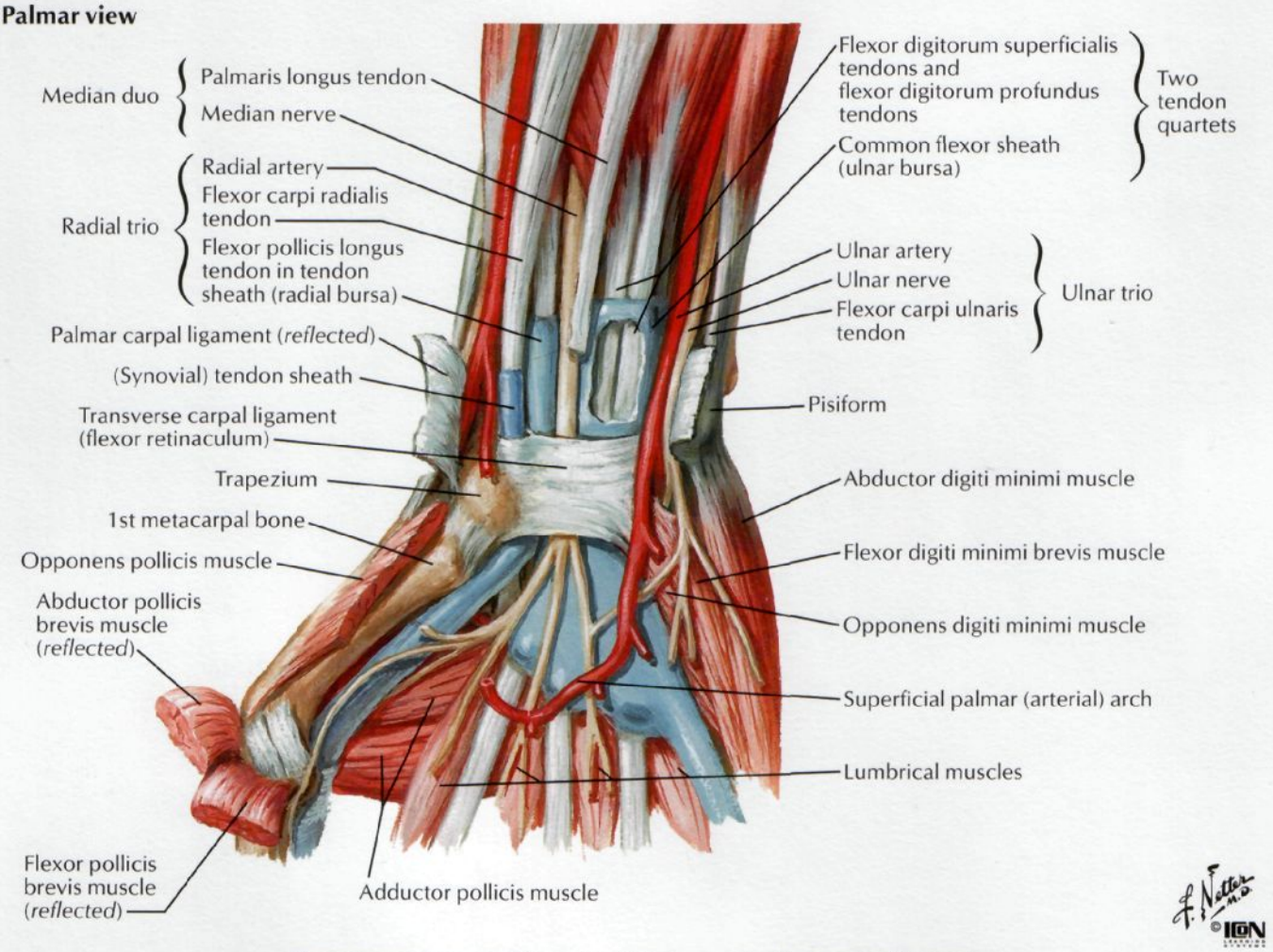

Transverse cross section of wrist demonstrating carpal tunnel

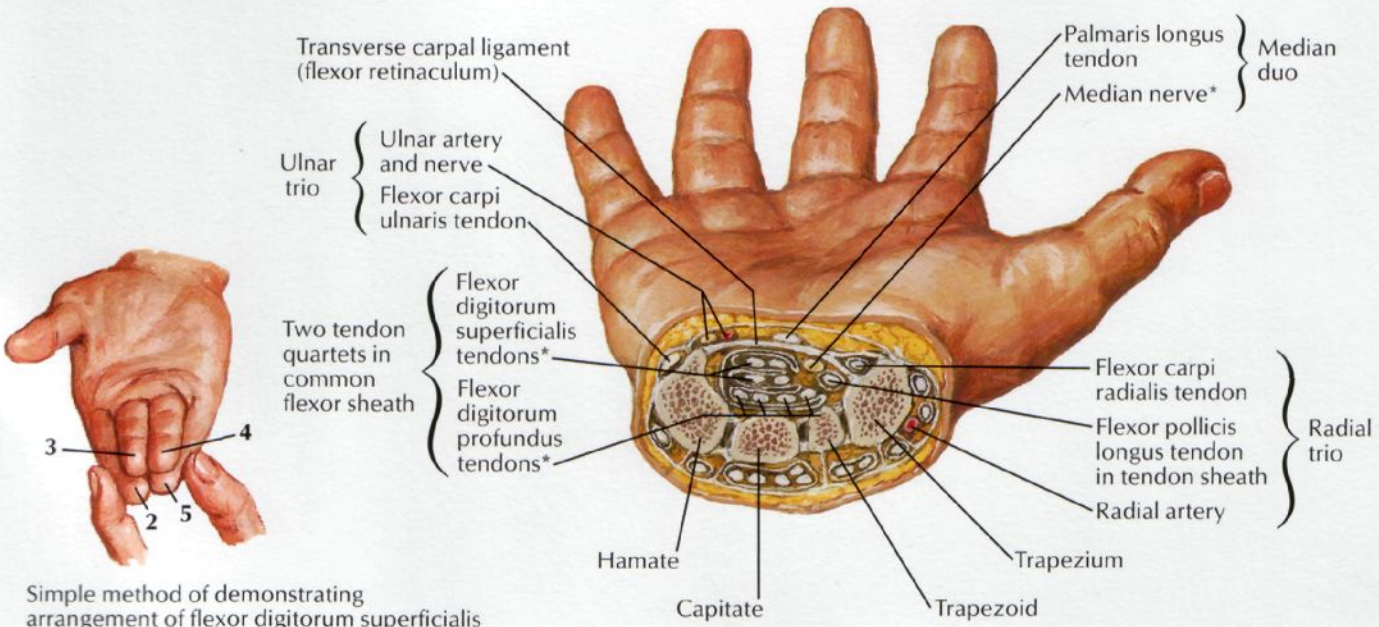

Simple method of demonstrating arrangement of flexor digitorum superficialis tendon quartet within carpal tunnel

*Contents of carpal tunnel

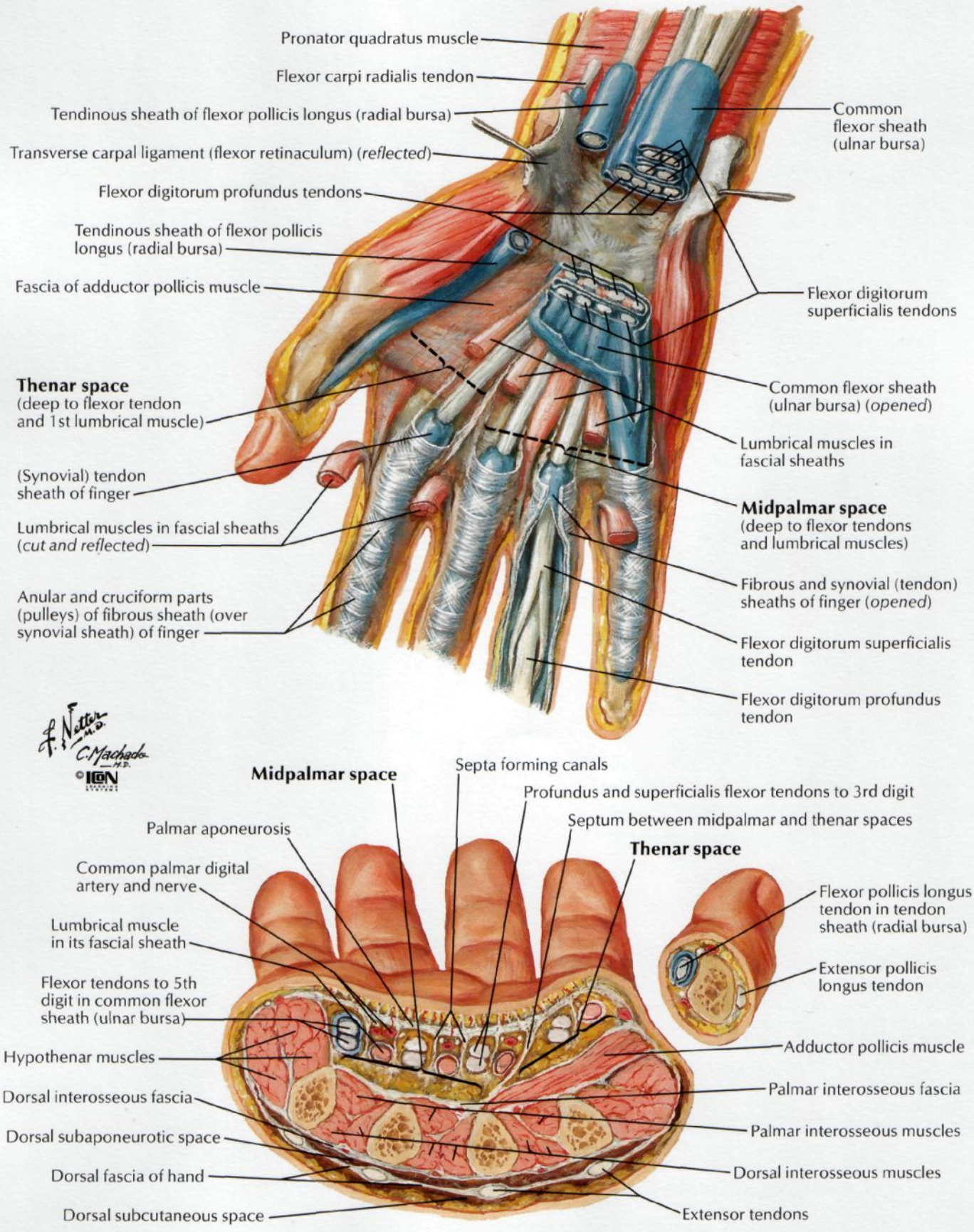
Pronator quadratus muscle
Flexor carpi radialis tendon
Tendinous sheath of flexor pollicis longus (radial bursa)
Transverse carpal ligament (flexor retinaculum) (reflected)
Flexor digitorum profundus tendons
Tendinous sheath of flexor pollicis longus (radial bursa)
Fascia of adductor pollicis muscle
Thenar space
(deep to flexor tendon and 1st lumbrical muscle)
(Synovial) tendon sheath of finger
Lumbrical muscles in fascial sheaths (cut and reflected)
Anular and cruciform parts (pulleys) of fibrous sheath (over synovial sheath) of finger
Common flexor sheath (ulnar bursa)
Flexor digitorum superficialis tendons
Common flexor sheath (ulnar bursa) (opened)
Lumbrical muscles in fascial sheaths
Midpalmar space
(deep to flexor tendons and lumbrical muscles)
Fibrous and synovial (tendon) sheaths of finger (opened)
Flexor digitorum superficialis tendon
Flexor digitorum profundus tendon
F. Netter, M.D.
C. Machado, M.D.
Midpalmar space
Septa forming canals
Profundus and superficialis flexor tendons to 3rd digit
Septum between midpalmar and thenar spaces
Thenar space
Palmar aponeurosis
Common palmar digital artery and nerve
Lumbrical muscle in its fascial sheath
Flexor tendons to 5th digit in common flexor sheath (ulnar bursa)
Hypothenar muscles
Dorsal interosseous fascia
Dorsal subaponeurotic space
Dorsal fascia of hand
Dorsal subcutaneous space
Flexor pollicis longus tendon in tendon sheath (radial bursa)
Extensor pollicis longus tendon
Adductor pollicis muscle
Palmar interosseous fascia
Palmar interosseous muscles
Dorsal interosseous muscles
Extensor tendons

Lumbrical Muscles and Bursae, Spaces and Sheaths: Schema

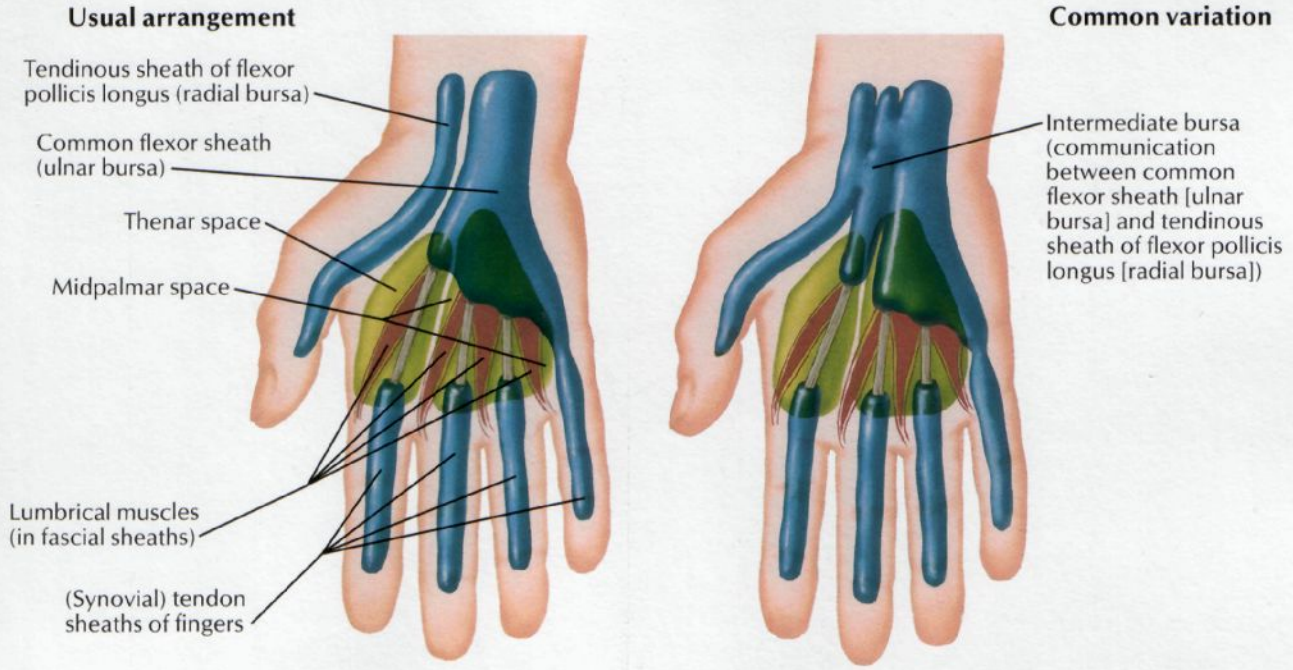

Lumbrical muscles: schema

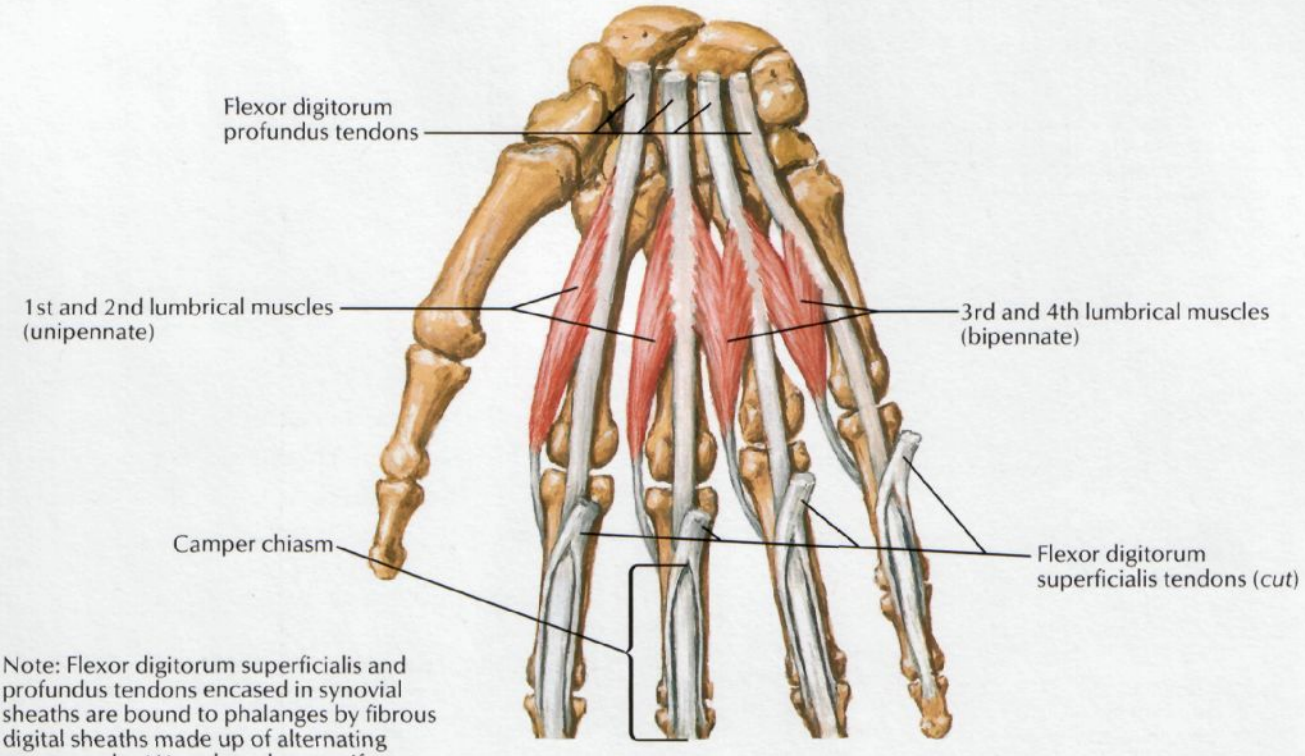

Note: Flexor digitorum superficialis and profundus tendons encased in synovial sheaths are bound to phalanges by fibrous digital sheaths made up of alternating strong anular (A) and weaker cruciform (C) parts (pulleys)

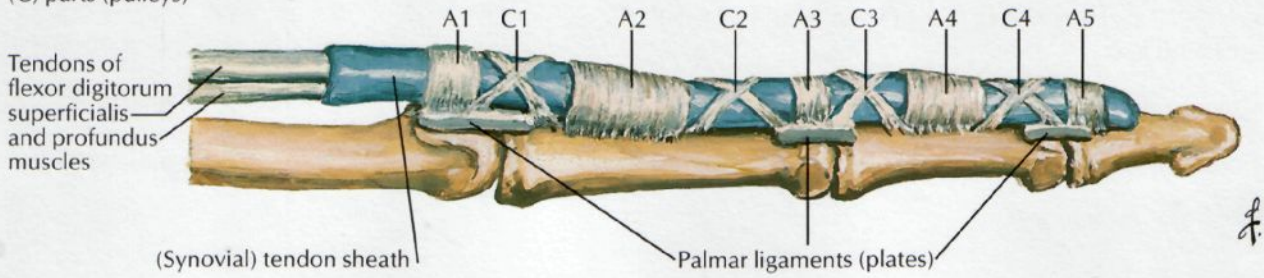

F. Netter M.D.
©IGN

Flexor and Extensor Tendons in Fingers

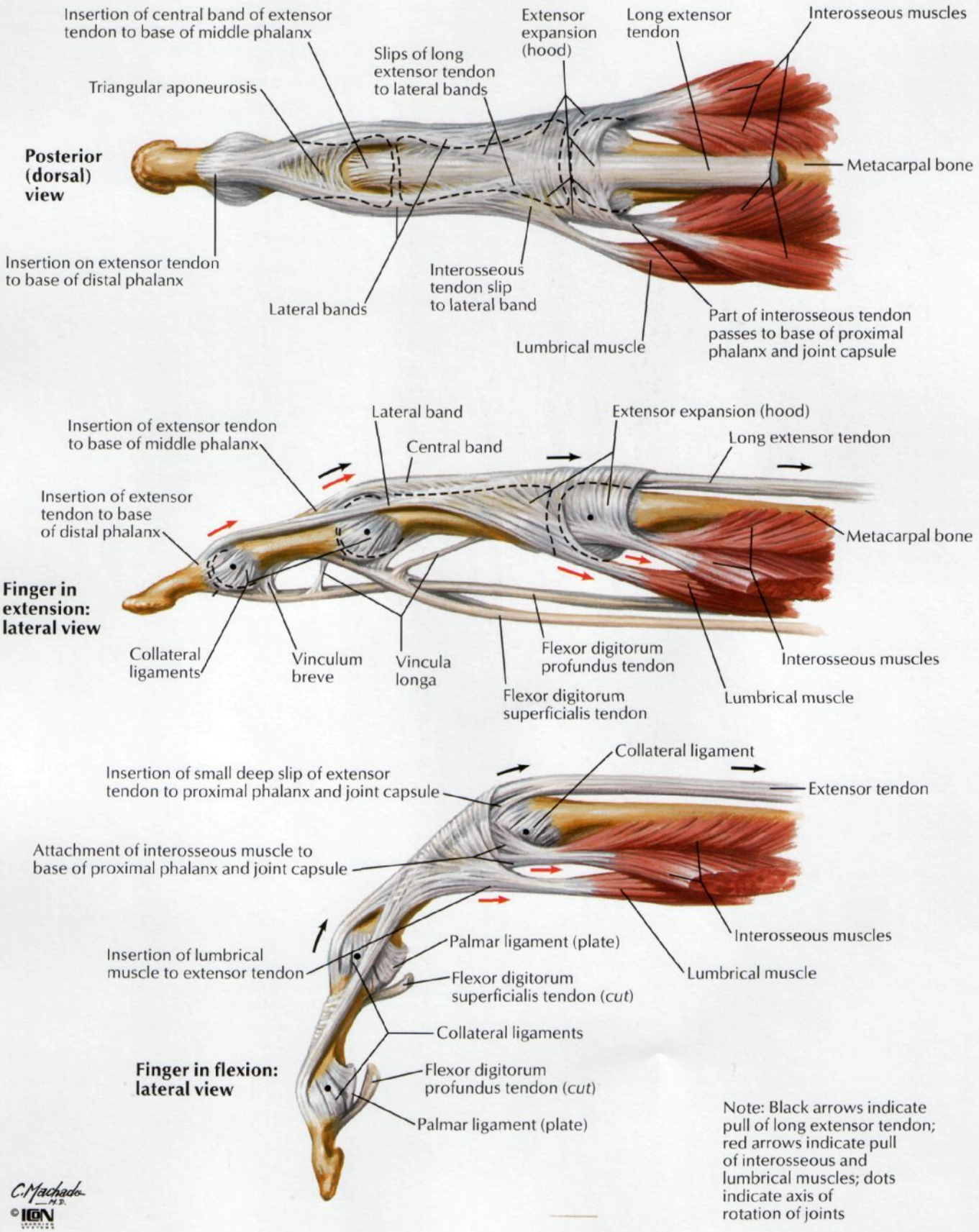

Intrinsic Muscles of Hand

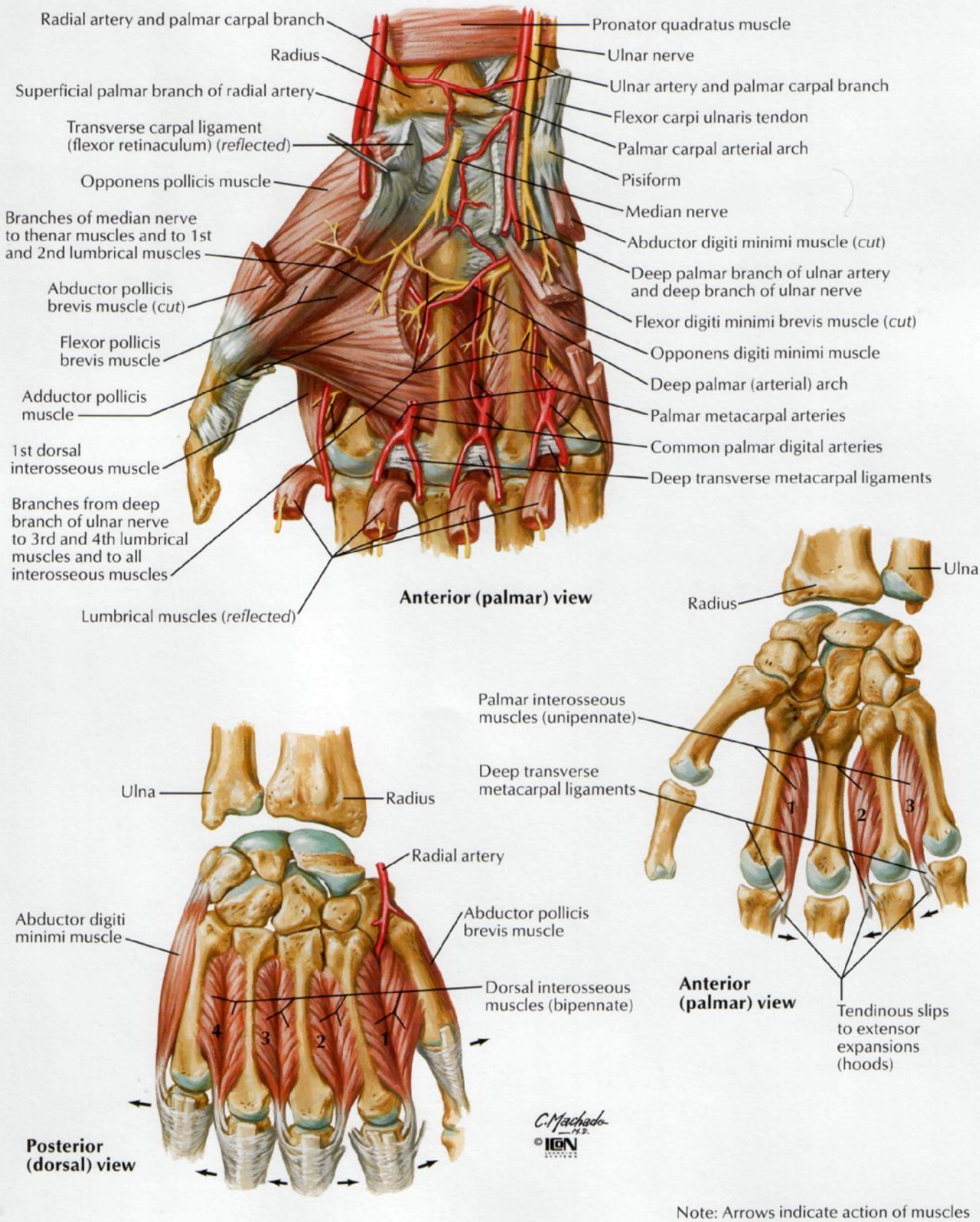

Note: Arrows indicate action of muscles

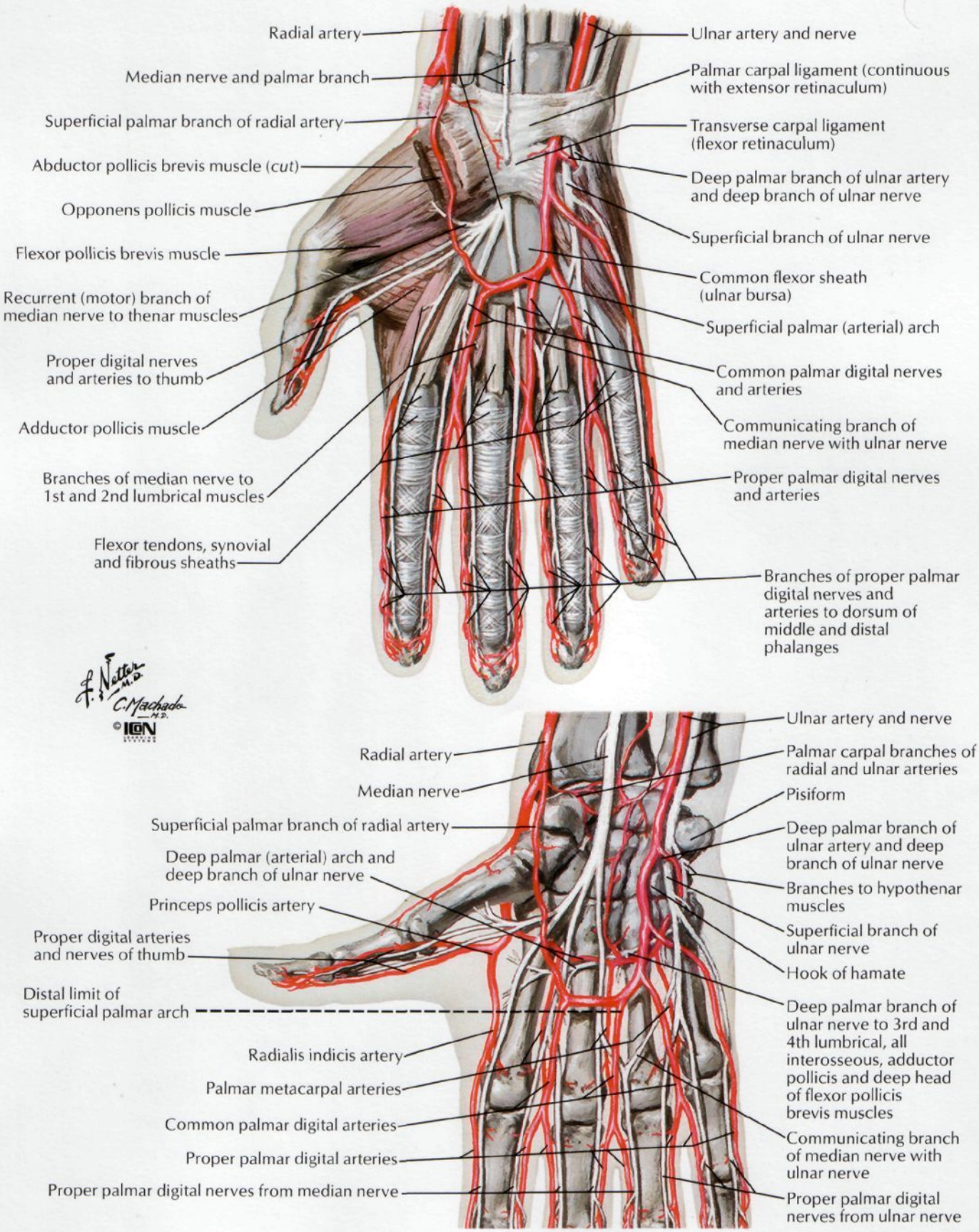
Radial artery
Median nerve and palmar branch
Superficial palmar branch of radial artery
Abductor pollicis brevis muscle (cut)
Opponens pollicis muscle
Flexor pollicis brevis muscle
Recurrent (motor) branch of median nerve to thenar muscles
Proper digital nerves and arteries to thumb
Adductor pollicis muscle
Branches of median nerve to 1st and 2nd lumbrical muscles
Flexor tendons, synovial and fibrous sheaths
Ulnar artery and nerve
Palmar carpal ligament (continuous with extensor retinaculum)
Transverse carpal ligament (flexor retinaculum)
Deep palmar branch of ulnar artery and deep branch of ulnar nerve
Superficial branch of ulnar nerve
Common flexor sheath (ulnar bursa)
Superficial palmar (arterial) arch
Common palmar digital nerves and arteries
Communicating branch of median nerve with ulnar nerve
Proper palmar digital nerves and arteries
Branches of proper palmar digital nerves and arteries to dorsum of middle and distal phalanges
F. Netter M.D.
C. Machado M.D.
©ICON
Ulnar artery and nerve
Radial artery
Median nerve
Superficial palmar branch of radial artery
Deep palmar (arterial) arch and deep branch of ulnar nerve
Princeps pollicis artery
Proper digital arteries and nerves of thumb
Distal limit of superficial palmar arch
Radialis indicis artery
Palmar metacarpal arteries
Common palmar digital arteries
Proper palmar digital arteries
Proper palmar digital nerves from median nerve
Palmar carpal branches of radial and ulnar arteries
Pisiform
Deep palmar branch of ulnar artery and deep branch of ulnar nerve
Branches to hypothenar muscles
Superficial branch of ulnar nerve
Hook of hamate
Deep palmar branch of ulnar nerve to 3rd and 4th lumbrical, all interosseous, adductor pollicis and deep head of flexor pollicis brevis muscles
Communicating branch of median nerve with ulnar nerve
Proper palmar digital nerves from ulnar nerve

Wrist and Hand: Superficial Radial Dissection

Lateral (radial) view

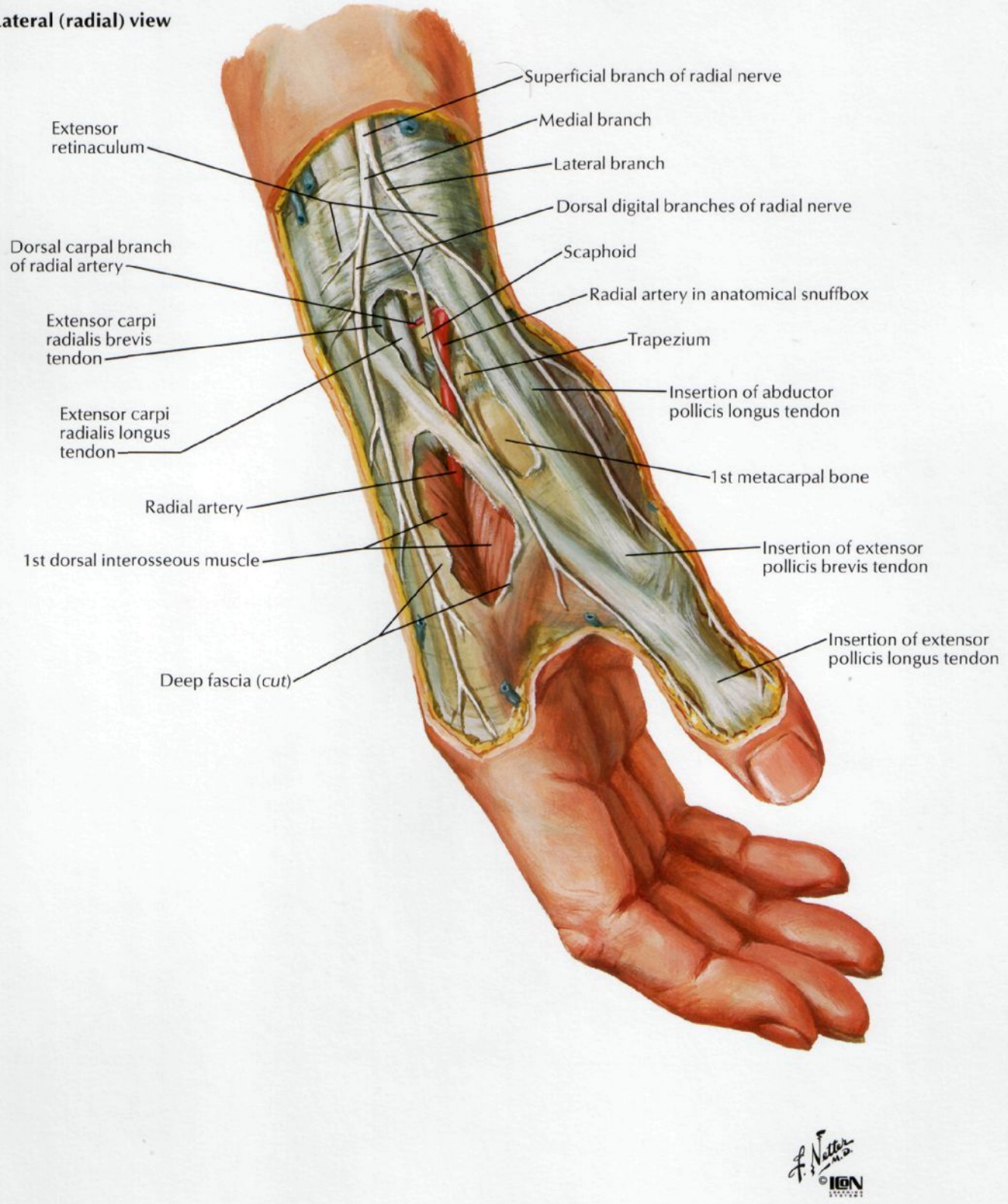

F. Netter M.D.
©IGN

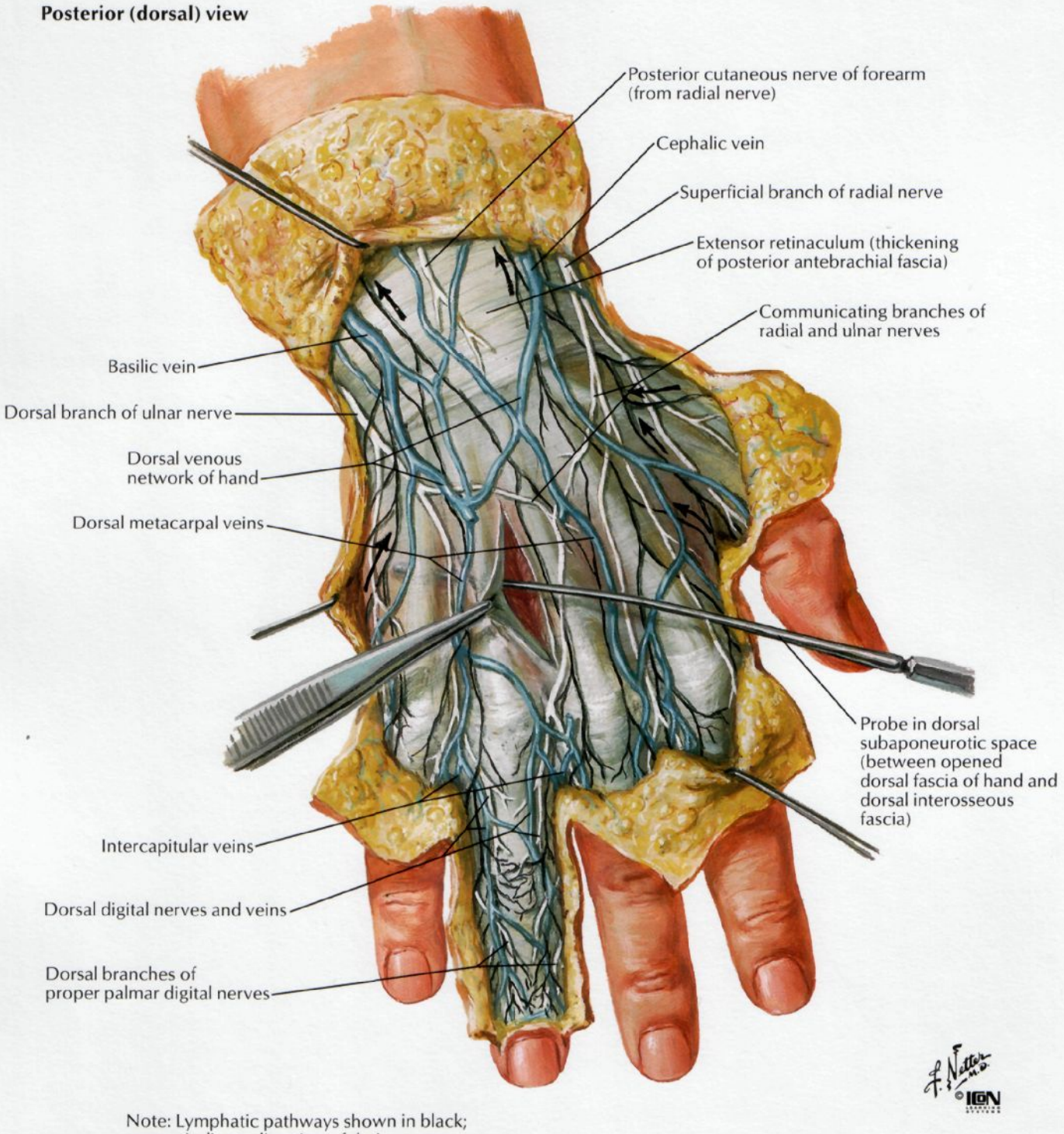

Note: Lymphatic pathways shown in black; arrows indicate direction of drainage

Wrist and Hand: Deep Dorsal Dissection

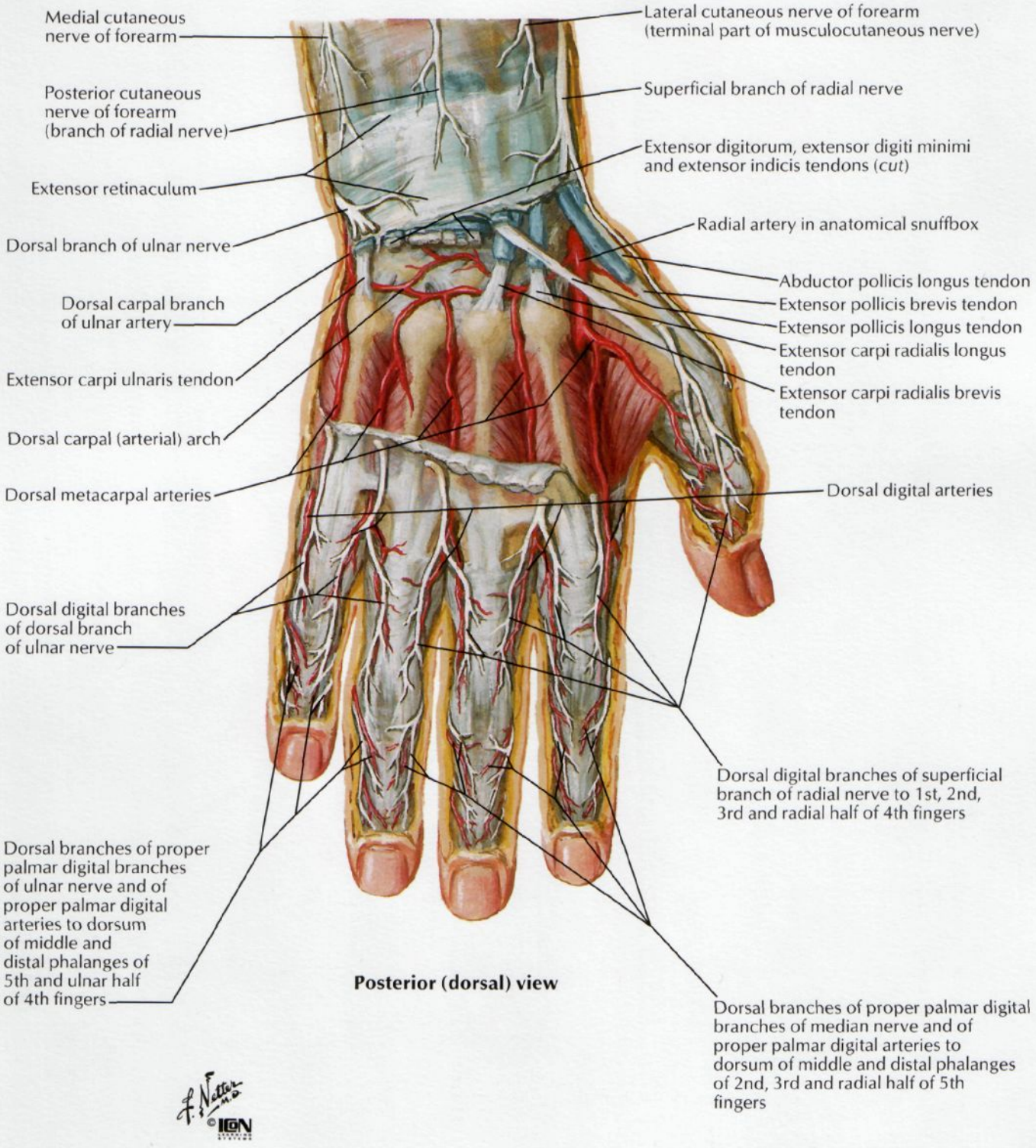

Posterior (dorsal) view

Posterior (dorsal) view

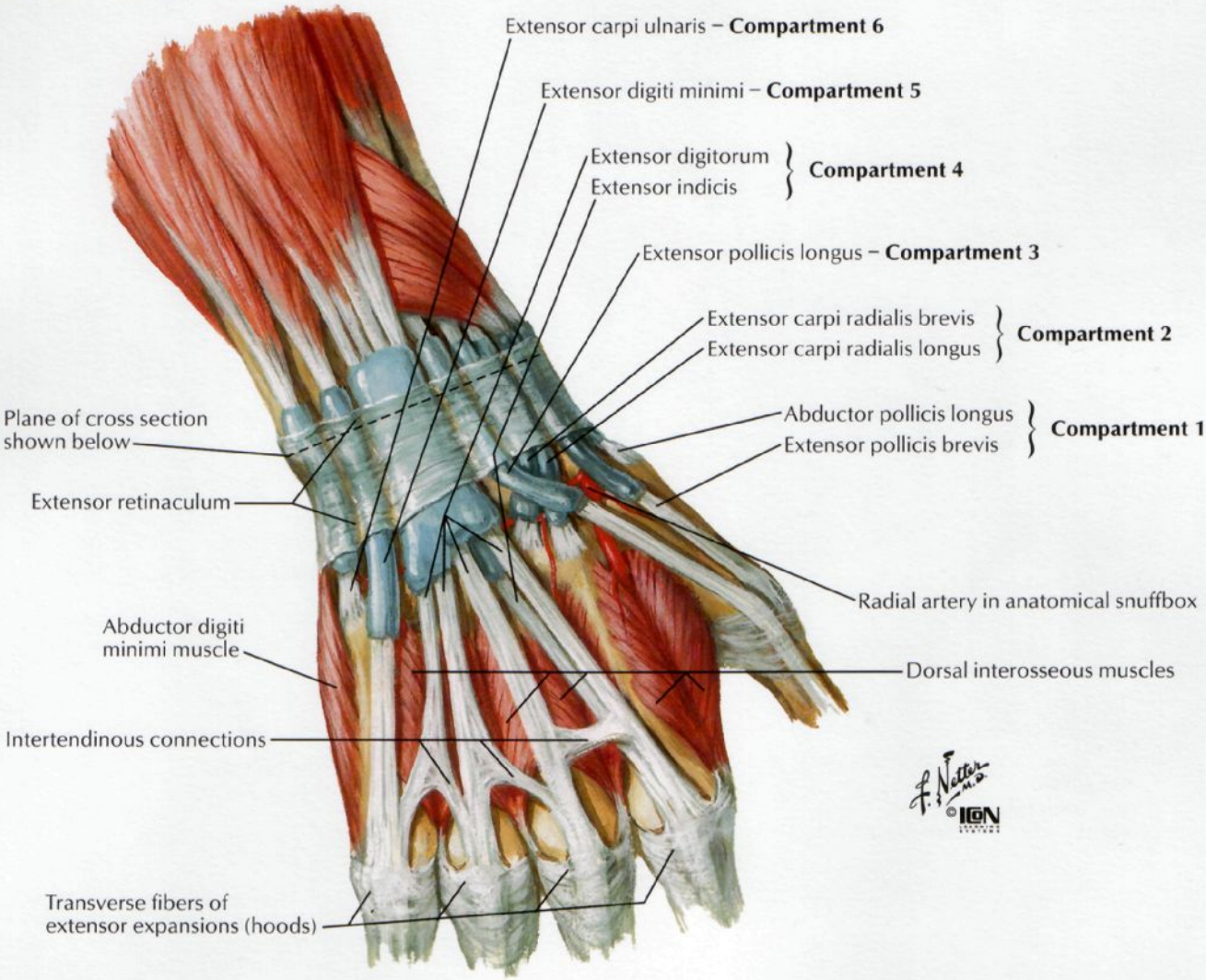

Cross section of most distal portion of forearm

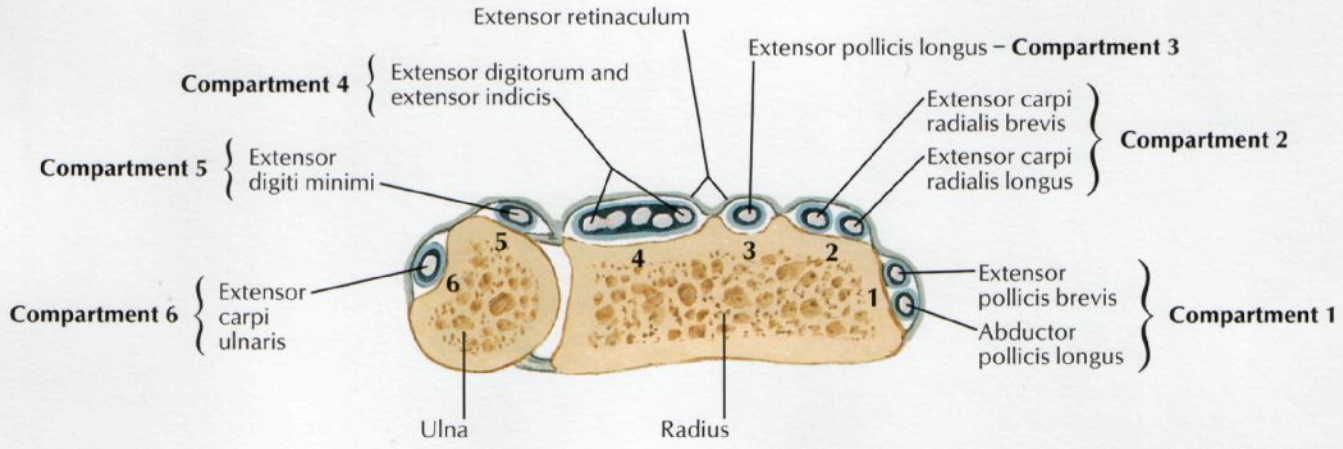

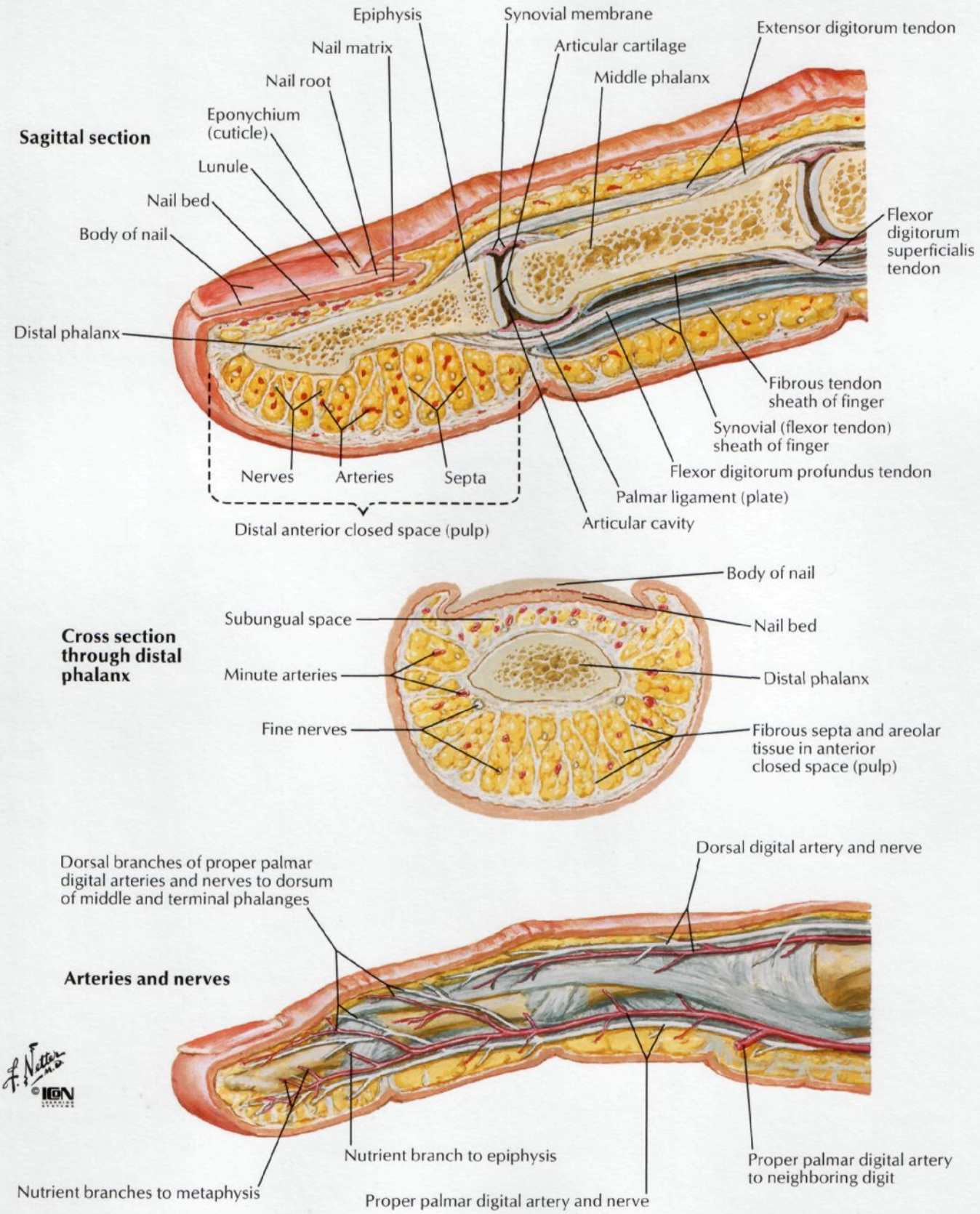
Sagittal section
Epiphysis
Synovial membrane
Extensor digitorum tendon
Nail matrix
Articular cartilage
Nail root
Middle phalanx
Eponychium (cuticle)
Lunule
Nail bed
Body of nail
Flexor digitorum superficialis tendon
Distal phalanx
Fibrous tendon sheath of finger
Synovial (flexor tendon) sheath of finger
Flexor digitorum profundus tendon
Nerves
Arteries
Septa
Palmar ligament (plate)
Articular cavity
Distal anterior closed space (pulp)
Cross section through distal phalanx
Body of nail
Subungual space
Nail bed
Minute arteries
Distal phalanx
Fine nerves
Fibrous septa and areolar tissue in anterior closed space (pulp)
Dorsal branches of proper palmar digital arteries and nerves to dorsum of middle and terminal phalanges
Dorsal digital artery and nerve
Arteries and nerves
Nutrient branch to epiphysis
Proper palmar digital artery to neighboring digit
Nutrient branches to metaphysis
Proper palmar digital artery and nerve

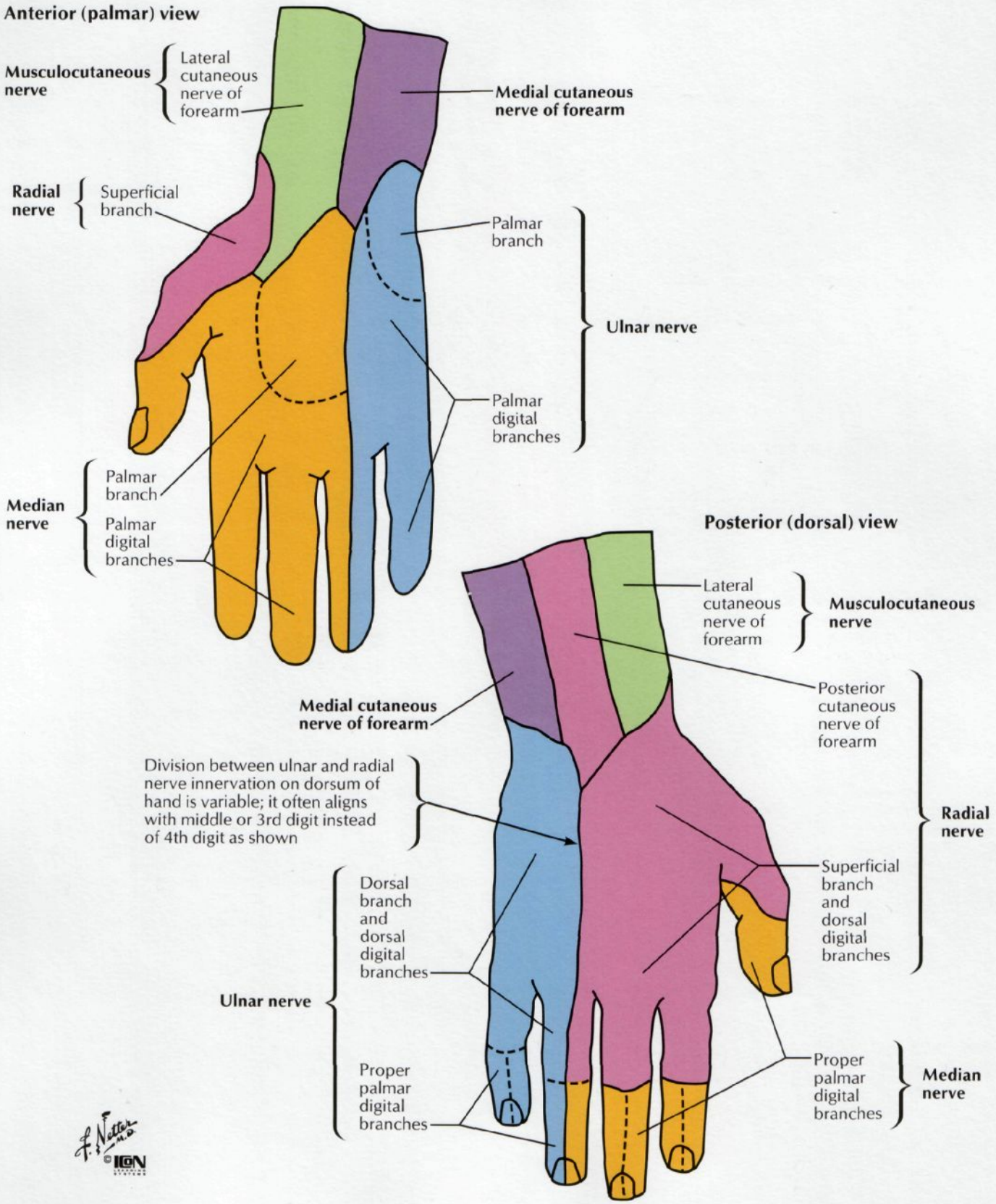
Anterior (palmar) view
Musculocutaneous nerve
Lateral cutaneous nerve of forearm
Medial cutaneous nerve of forearm
Radial nerve
Superficial branch
Palmar branch
Ulnar nerve
Palmar digital branches
Median nerve
Palmar branch
Palmar digital branches
Posterior (dorsal) view
Lateral cutaneous nerve of forearm
Musculocutaneous nerve
Medial cutaneous nerve of forearm
Posterior cutaneous nerve of forearm
Division between ulnar and radial nerve innervation on dorsum of hand is variable; it often aligns with middle or 3rd digit instead of 4th digit as shown
Radial nerve
Superficial branch and dorsal digital branches
Dorsal branch and dorsal digital branches
Ulnar nerve
Proper palmar digital branches
Proper palmar digital branches
Median nerve
F. Netter M.D.
©ICON

Arteries and Nerves of Upper Limb

Anterior view

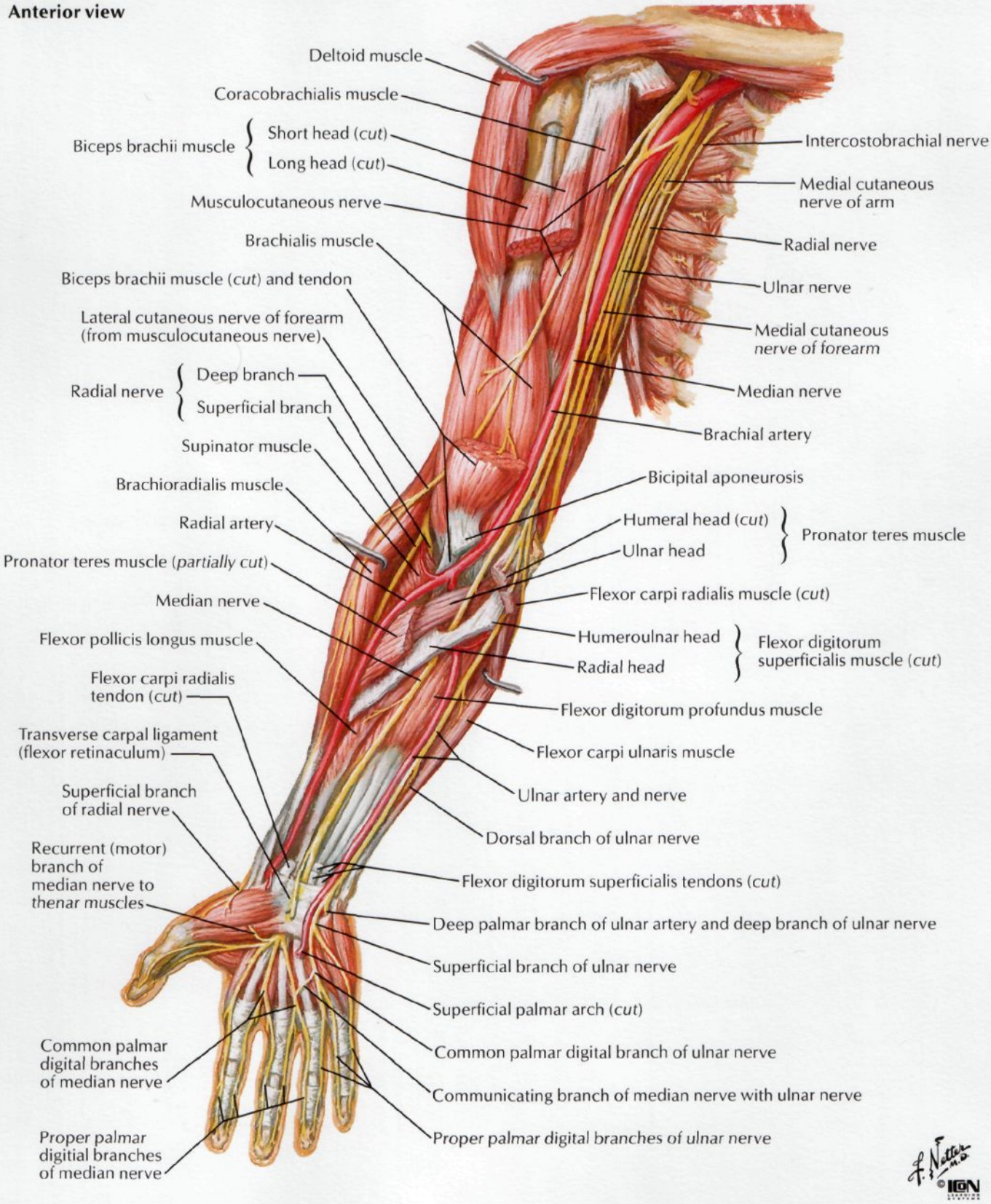

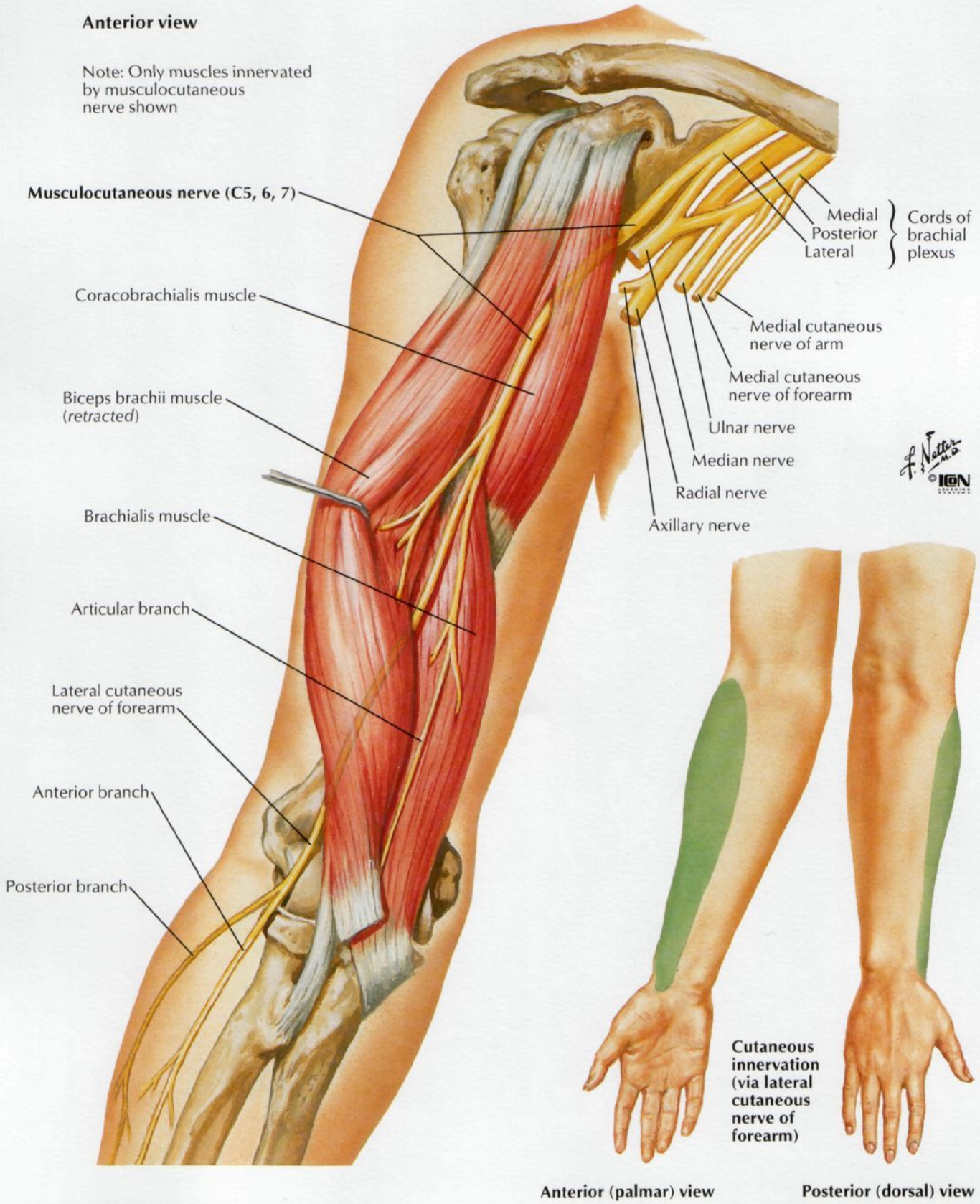
Anterior view
Note: Only muscles innervated by musculocutaneous nerve shown
Musculocutaneous nerve (C5, 6, 7)
Coracobrachialis muscle
Biceps brachii muscle (retracted)
Brachialis muscle
Articular branch
Lateral cutaneous nerve of forearm
Anterior branch
Posterior branch
Medial
Posterior
Lateral
Cords of brachial plexus
Medial cutaneous nerve of arm
Medial cutaneous nerve of forearm
Ulnar nerve
Median nerve
Radial nerve
Axillary nerve
Cutaneous innervation (via lateral cutaneous nerve of forearm)
Anterior (palmar) view
Posterior (dorsal) view

Median Nerve

Anterior view

Note: Only muscles innervated by median nerve shown

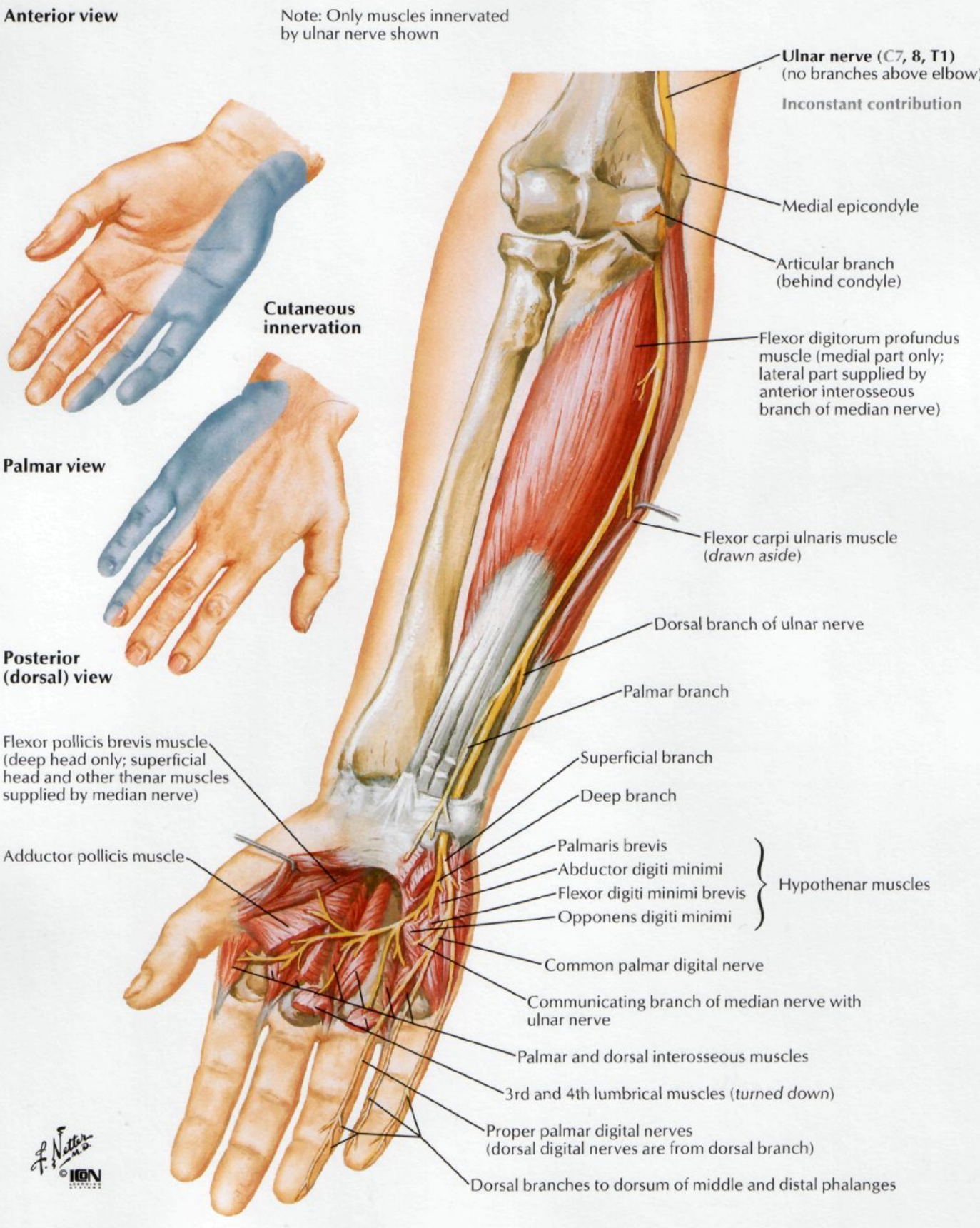
Anterior view
Note: Only muscles innervated by ulnar nerve shown
Ulnar nerve (C7, 8, T1)
(no branches above elbow)
Inconstant contribution
Medial epicondyle
Articular branch
(behind condyle)
Cutaneous innervation
Flexor digitorum profundus muscle (medial part only; lateral part supplied by anterior interosseous branch of median nerve)
Palmar view
Flexor carpi ulnaris muscle
(drawn aside)
Dorsal branch of ulnar nerve
Posterior (dorsal) view
Palmar branch
Flexor pollicis brevis muscle (deep head only; superficial head and other thenar muscles supplied by median nerve)
Superficial branch
Deep branch
Adductor pollicis muscle
Palmaris brevis
Abductor digiti minimi
Flexor digiti minimi brevis
Opponens digiti minimi
Hypothenar muscles
Common palmar digital nerve
Communicating branch of median nerve with ulnar nerve
Palmar and dorsal interosseous muscles
3rd and 4th lumbrical muscles (turned down)
Proper palmar digital nerves
(dorsal digital nerves are from dorsal branch)
Dorsal branches to dorsum of middle and distal phalanges
F. Netter M.D.
©IGN

Radial Nerve in Arm and Nerves of Posterior Shoulder

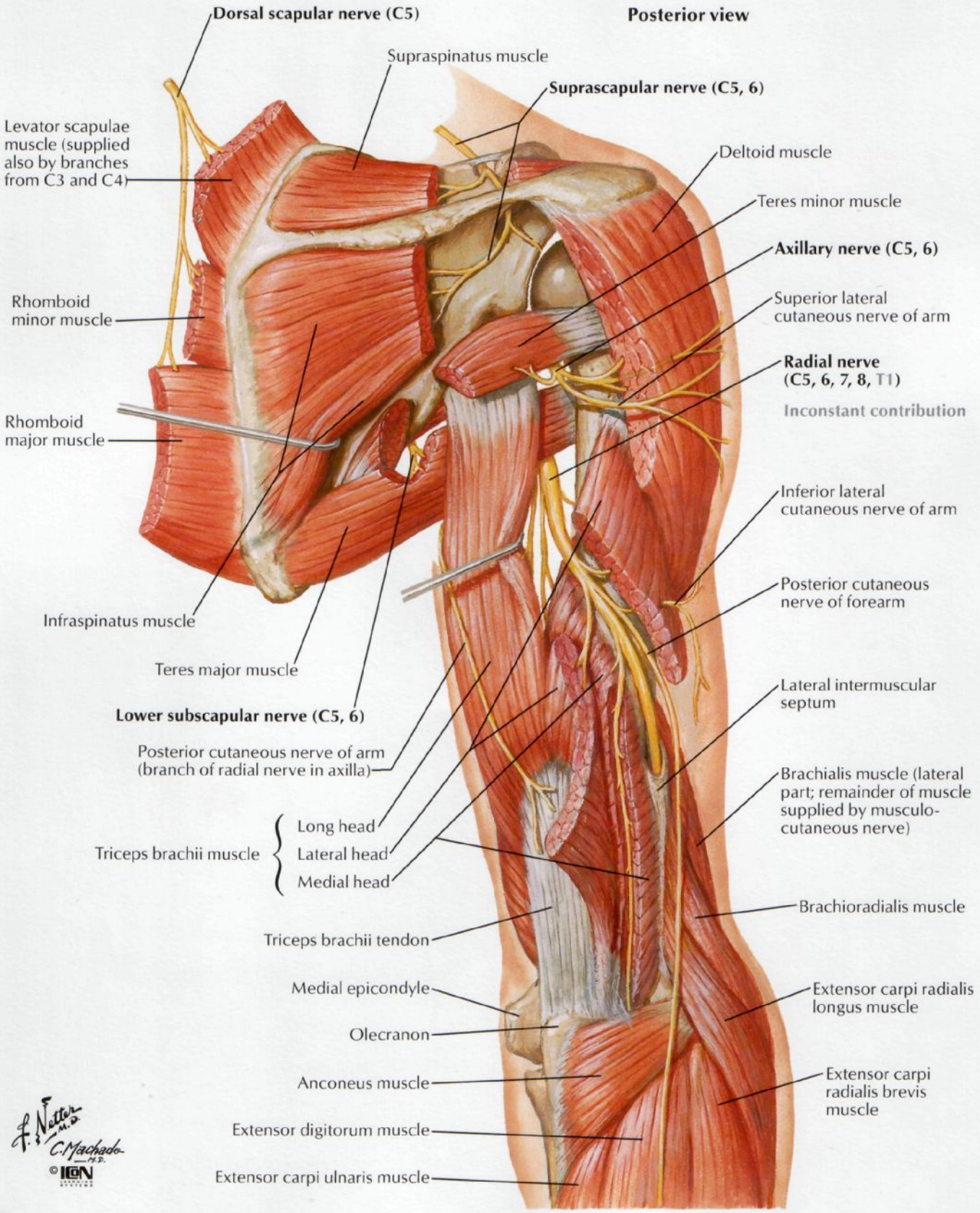

Radial Nerve in Forearm

SEE ALSO PLATE 450

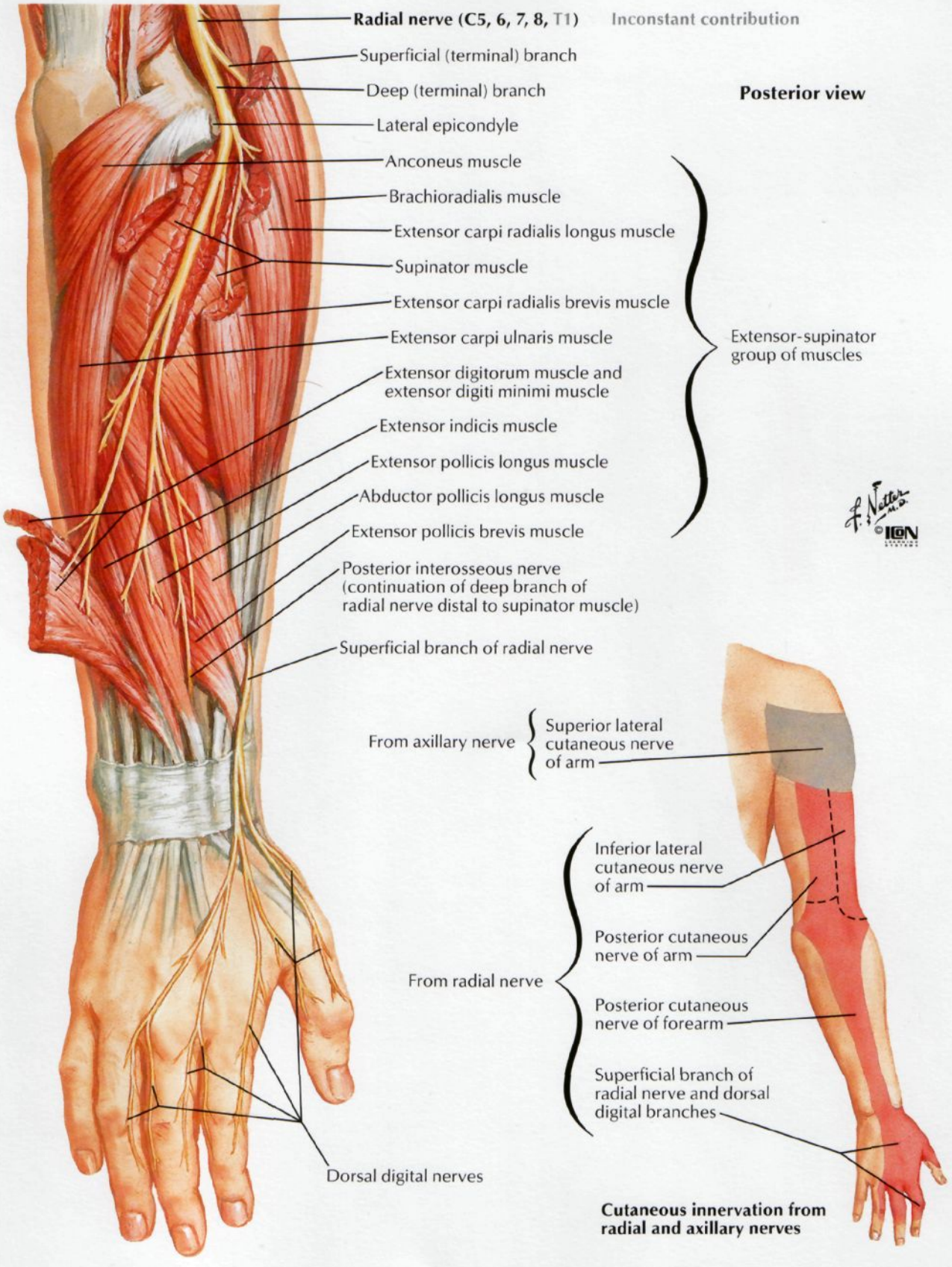

Cutaneous Nerves and Superficial Veins of Shoulder and Arm

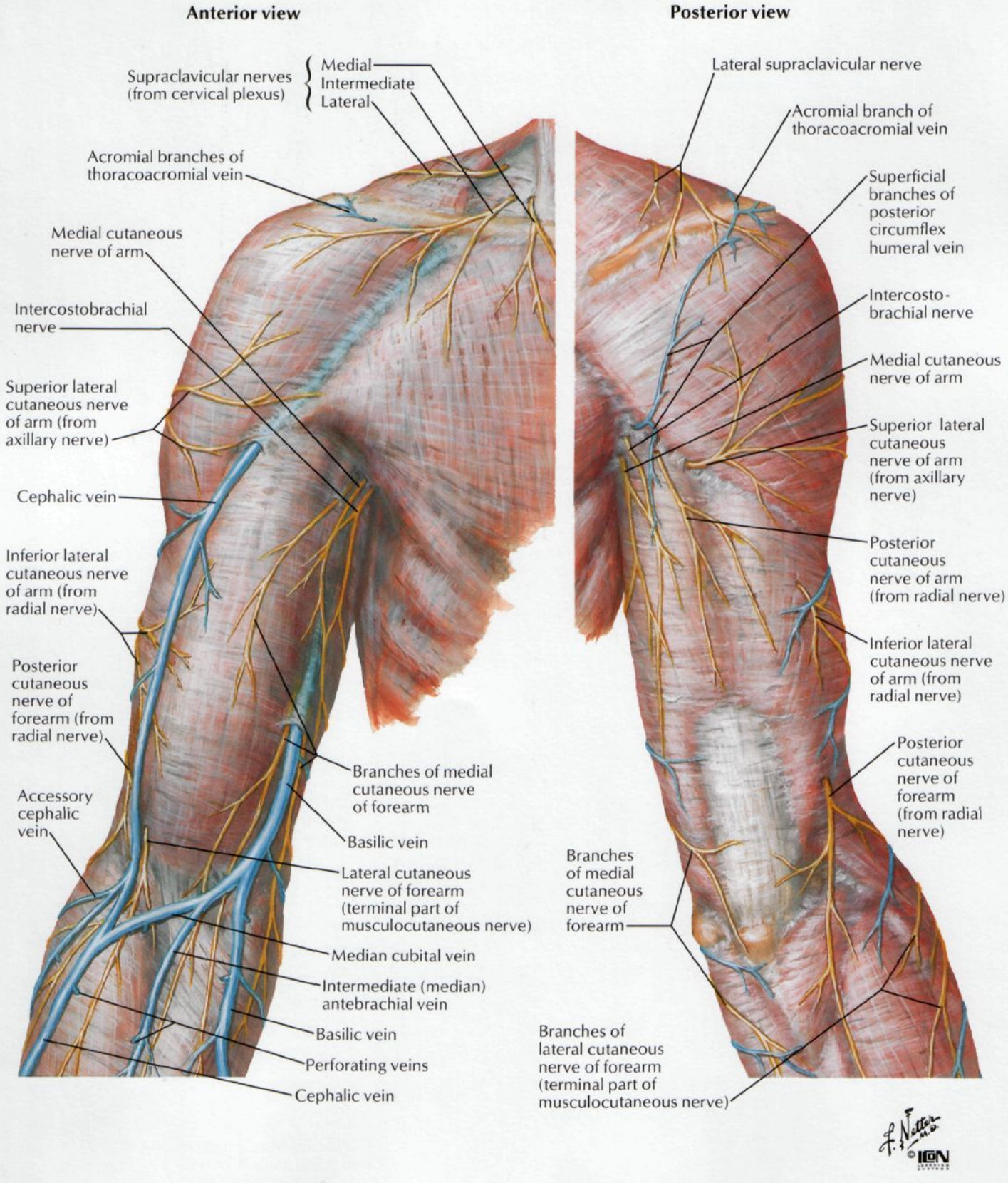

Cutaneous Nerves and Superficial Veins of Forearm

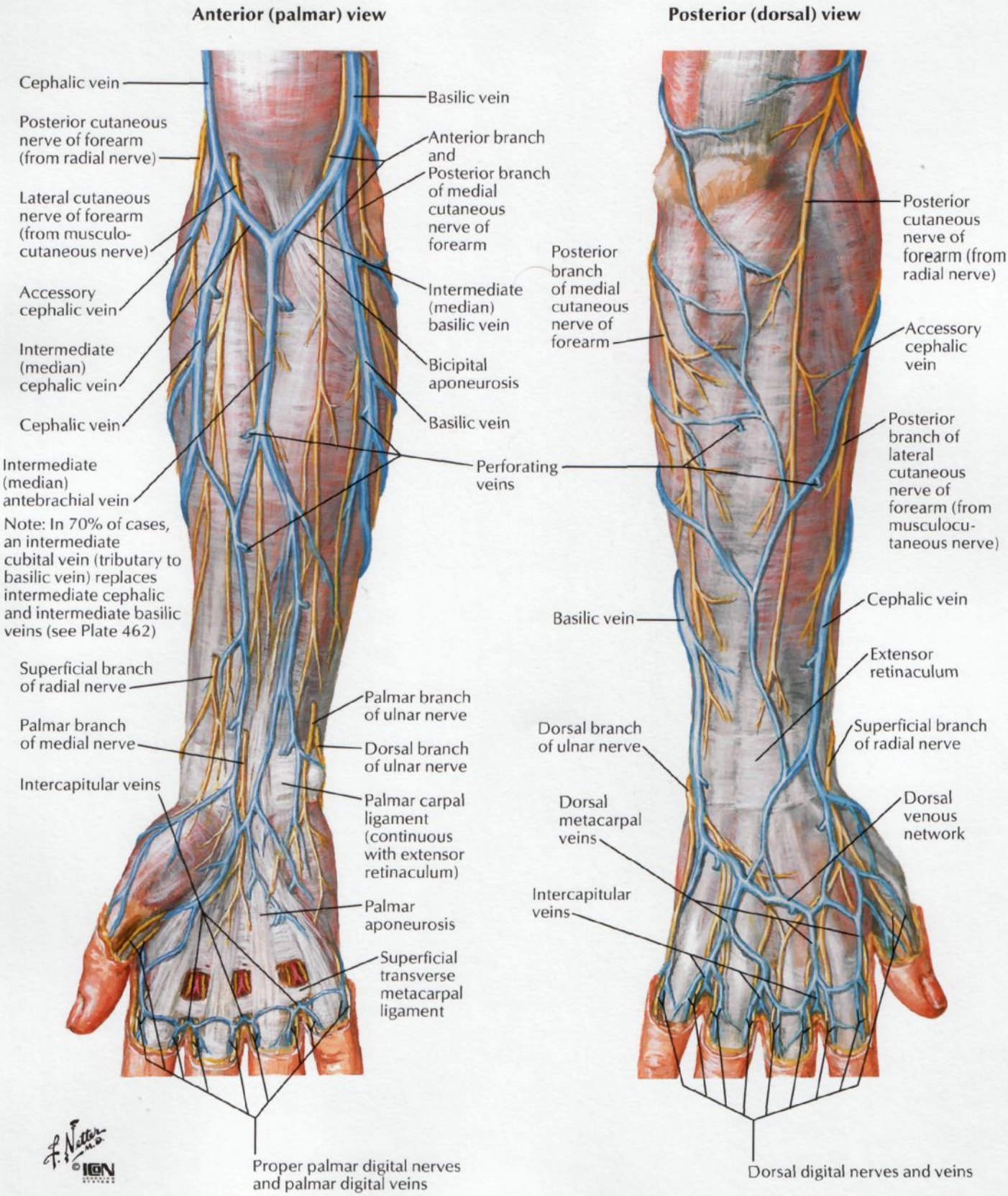

Cutaneous Innervation of Upper Limb

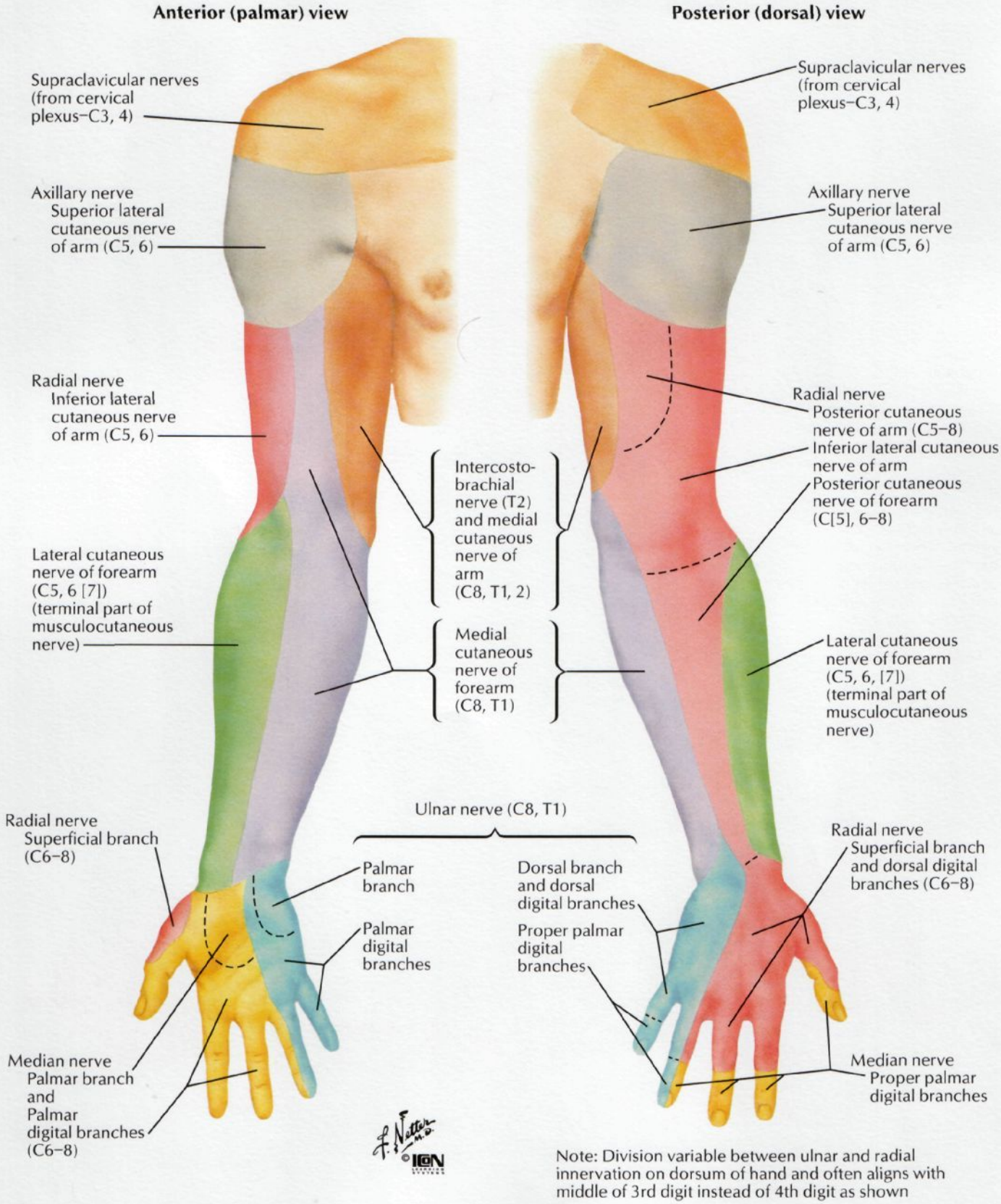

Note: Division variable between ulnar and radial innervation on dorsum of hand and often aligns with middle of 3rd digit instead of 4th digit as shown

Dermatomes of Upper Limb

Note: Schematic demarcation of dermatomes (according to Keegan and Garrett) shown as distinct segments. There is actually considerable overlap between adjacent dermatomes. An alternative dermatome map is that provided by Foerster

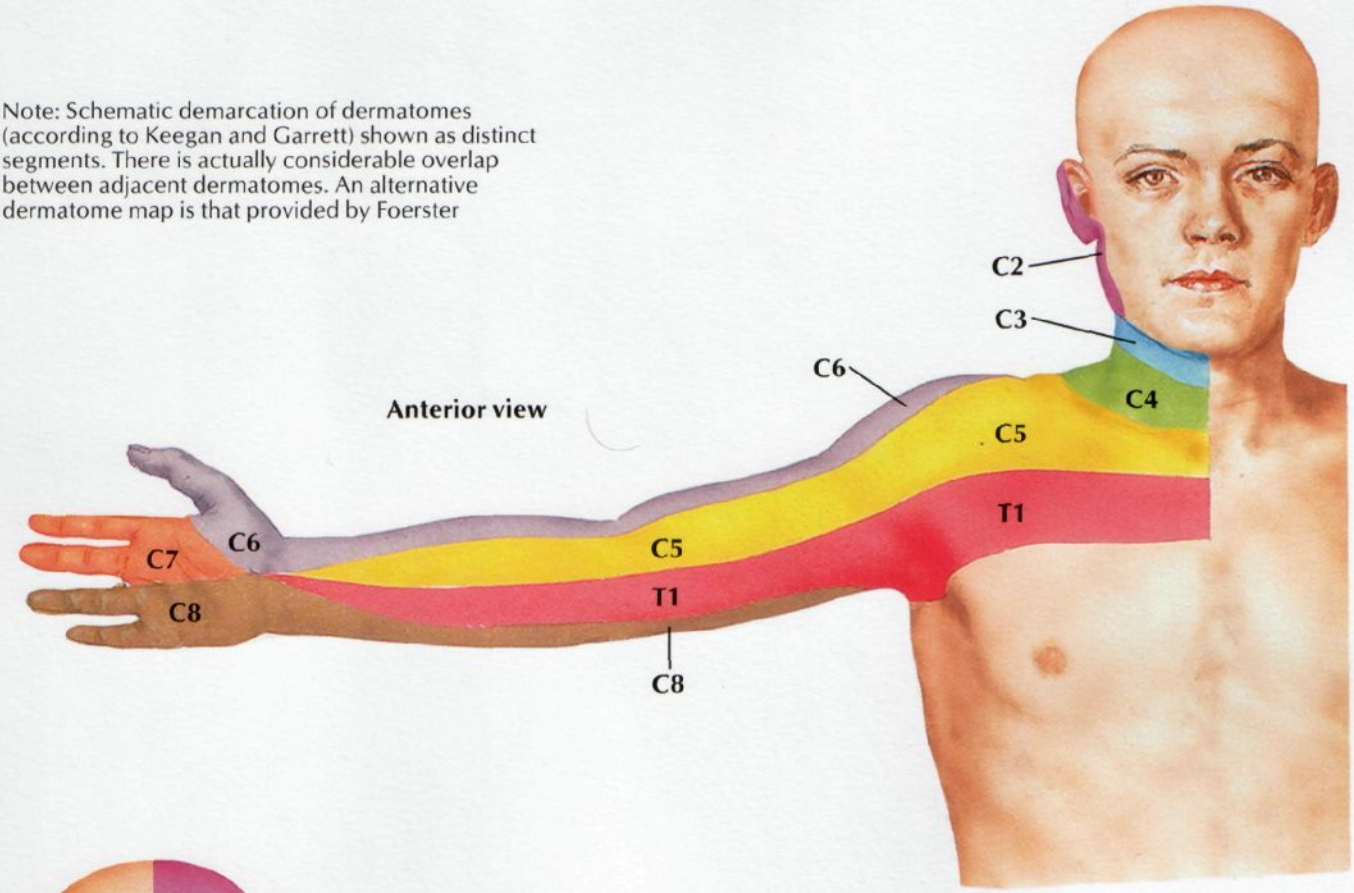

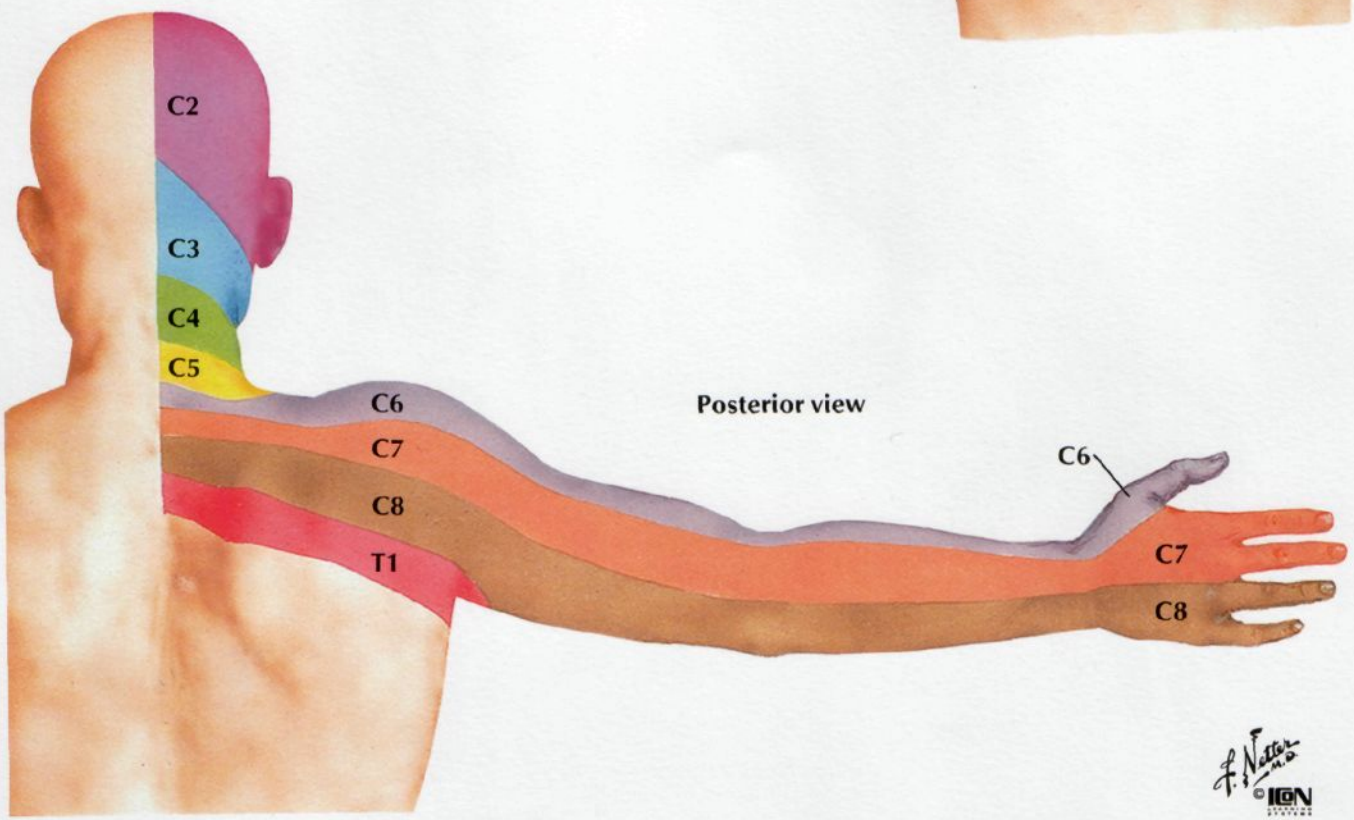

Lymph Vessels and Nodes of Upper Limb

SEE ALSO PLATES 177, 451

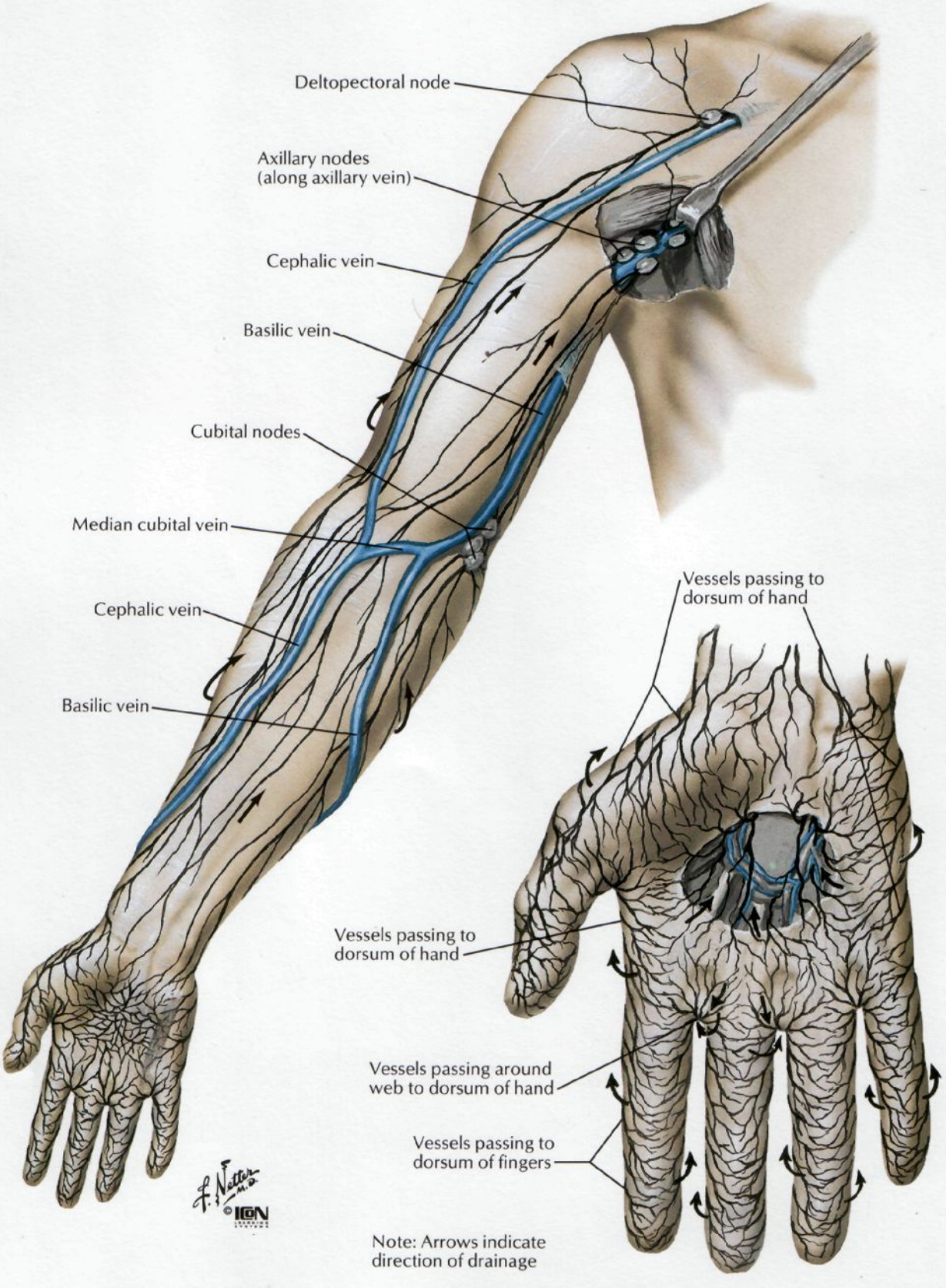

Section VII
LOWER LIMB

SURFACE ANATOMY
Plate 467
467. Lower Limb

HIP AND THIGH
Plates 468–487
468. Hip (Coxal) Bone
469. Hip Joint
470. Hip Joint: Anteroposterior Radiograph
471. Femur
472. Bony Attachments of Muscles of Hip and Thigh: Anterior View
473. Bony Attachments of Muscles of Hip and Thigh: Posterior View
474. Muscles of Thigh: Anterior Views
475. Muscles of Thigh: Anterior Views (*continued*)
476. Muscles of Hip and Thigh: Lateral View
477. Muscles of Hip and Thigh: Posterior Views
478. Psoas and Iliacus Muscles
479. Lumbosacral and Coccygeal Plexuses
480. Lumbar Plexus
481. Sacral and Coccygeal Plexuses
482. Arteries and Nerves of Thigh: Anterior Views
483. Arteries and Nerves of Thigh: Anterior Views (*continued*)
484. Arteries and Nerves of Thigh: Posterior View
485. Nerves of Hip and Buttock
486. Arteries of Femoral Head and Neck
487. Thigh: Serial Cross Sections

KNEE
Plates 488–494

488. Knee: Lateral and Medial Views
489. Knee: Anterior Views
490. Knee: Interior
491. Knee: Cruciate and Collateral Ligaments
492. Knee: Anteroposterior Radiograph
493. Knee: Posterior and Sagittal Views
494. Arteries of Thigh and Knee: Schema

LEG
Plates 495–504

495. Tibia and Fibula
496. Tibia and Fibula (*continued*)
497. Attachments of Muscles of Leg
498. Muscles of Leg (Superficial Dissection): Posterior View
499. Muscles of Leg (Intermediate Dissection): Posterior View
500. Muscles of Leg (Deep Dissection): Posterior View
501. Muscles of Leg (Superficial Dissection): Anterior View
502. Muscles of Leg (Deep Dissection): Anterior View
503. Muscles of Leg: Lateral View
504. Leg: Cross Sections and Fascial Compartments

ANKLE AND FOOT
Plates 505–519

505. Bones of Foot
506. Bones of Foot (*continued*)
507. Calcaneus
508. Ankle: Radiographs
509. Ligaments and Tendons of Ankle
510. Ligaments and Tendons of Foot: Plantar View
511. Tendon Sheaths of Ankle
512. Muscles of Dorsum of Foot: Superficial Dissection
513. Dorsum of Foot: Deep Dissection
514. Sole of Foot: Superficial Dissection
515. Muscles of Sole of Foot: First Layer
516. Muscles of Sole of Foot: Second Layer
517. Muscles of Sole of Foot: Third Layer
518. Interosseous Muscles and Deep Arteries of Foot
519. Interosseous Muscles of Foot

NEUROVASCULATURE
Plates 520–528

520. Femoral Nerve and Lateral Cutaneous Nerve of Thigh
521. Obturator Nerve
522. Sciatic Nerve and Posterior Cutaneous Nerve of Thigh
523. Tibial Nerve
524. Common Fibular (Peroneal) Nerve
525. Dermatomes of Lower Limb
526. Superficial Nerves and Veins of Lower Limb: Anterior View
527. Superficial Nerves and Veins of Lower Limb: Posterior View
528. Lymph Vessels and Nodes of Lower Limb

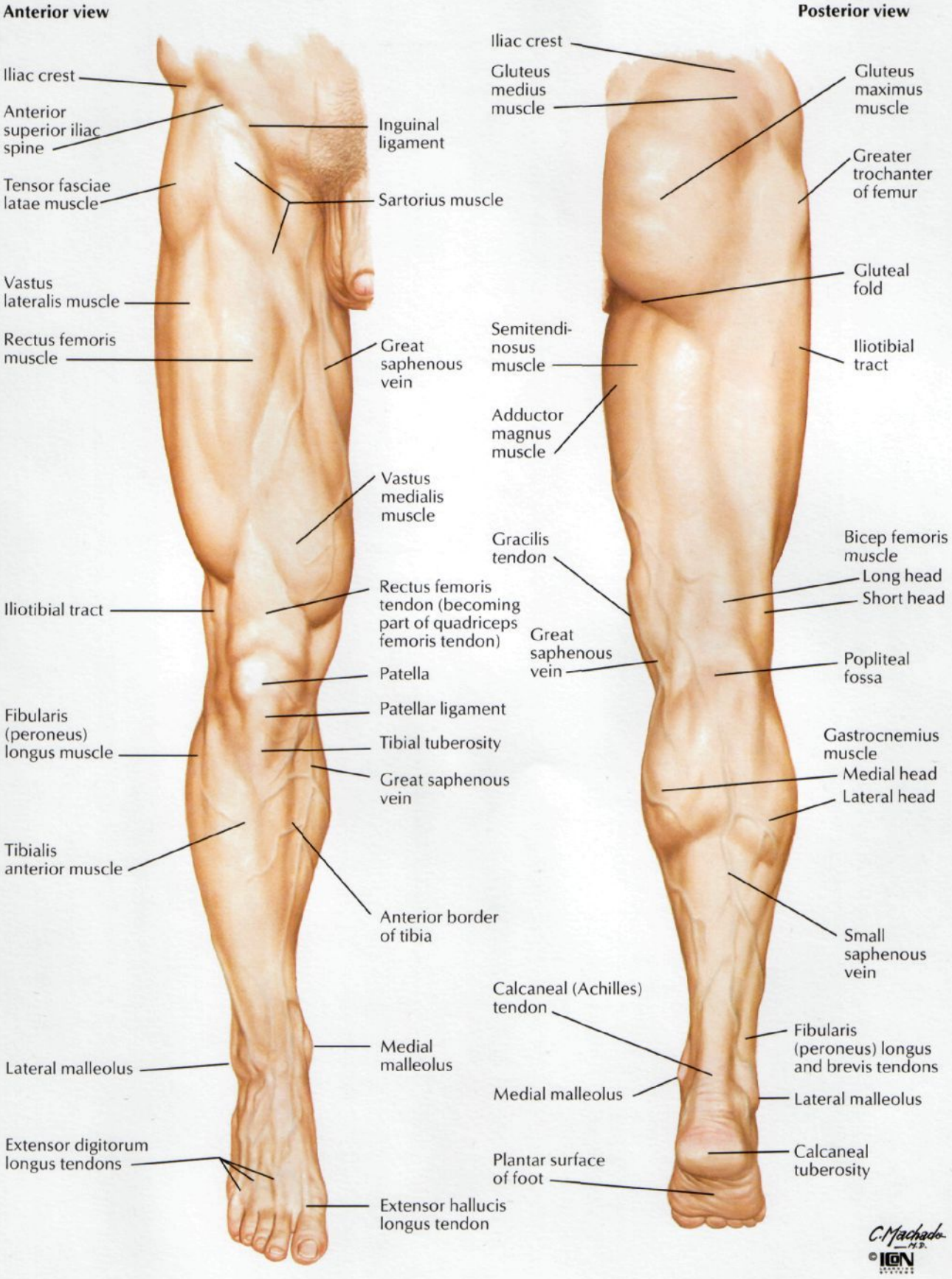
Anterior view
Iliac crest
Anterior superior iliac spine
Tensor fasciae latae muscle
Vastus lateralis muscle
Rectus femoris muscle
Iliotibial tract
Fibularis (peroneus) longus muscle
Tibialis anterior muscle
Lateral malleolus
Extensor digitorum longus tendons
Inguinal ligament
Sartorius muscle
Great saphenous vein
Vastus medialis muscle
Rectus femoris tendon (becoming part of quadriceps femoris tendon)
Patella
Patellar ligament
Tibial tuberosity
Great saphenous vein
Anterior border of tibia
Medial malleolus
Extensor hallucis longus tendon
Posterior view
Iliac crest
Gluteus medius muscle
Semitendinosus muscle
Adductor magnus muscle
Gracilis tendon
Great saphenous vein
Calcaneal (Achilles) tendon
Medial malleolus
Plantar surface of foot
Gluteus maximus muscle
Greater trochanter of femur
Gluteal fold
Iliotibial tract
Bicep femoris muscle
Long head
Short head
Popliteal fossa
Gastrocnemius muscle
Medial head
Lateral head
Small saphenous vein
Fibularis (peroneus) longus and brevis tendons
Lateral malleolus
Calcaneal tuberosity
C. Machado M.D.
©IGN

Hip (Coxal) Bone

SEE ALSO PLATES 240, 340, 341

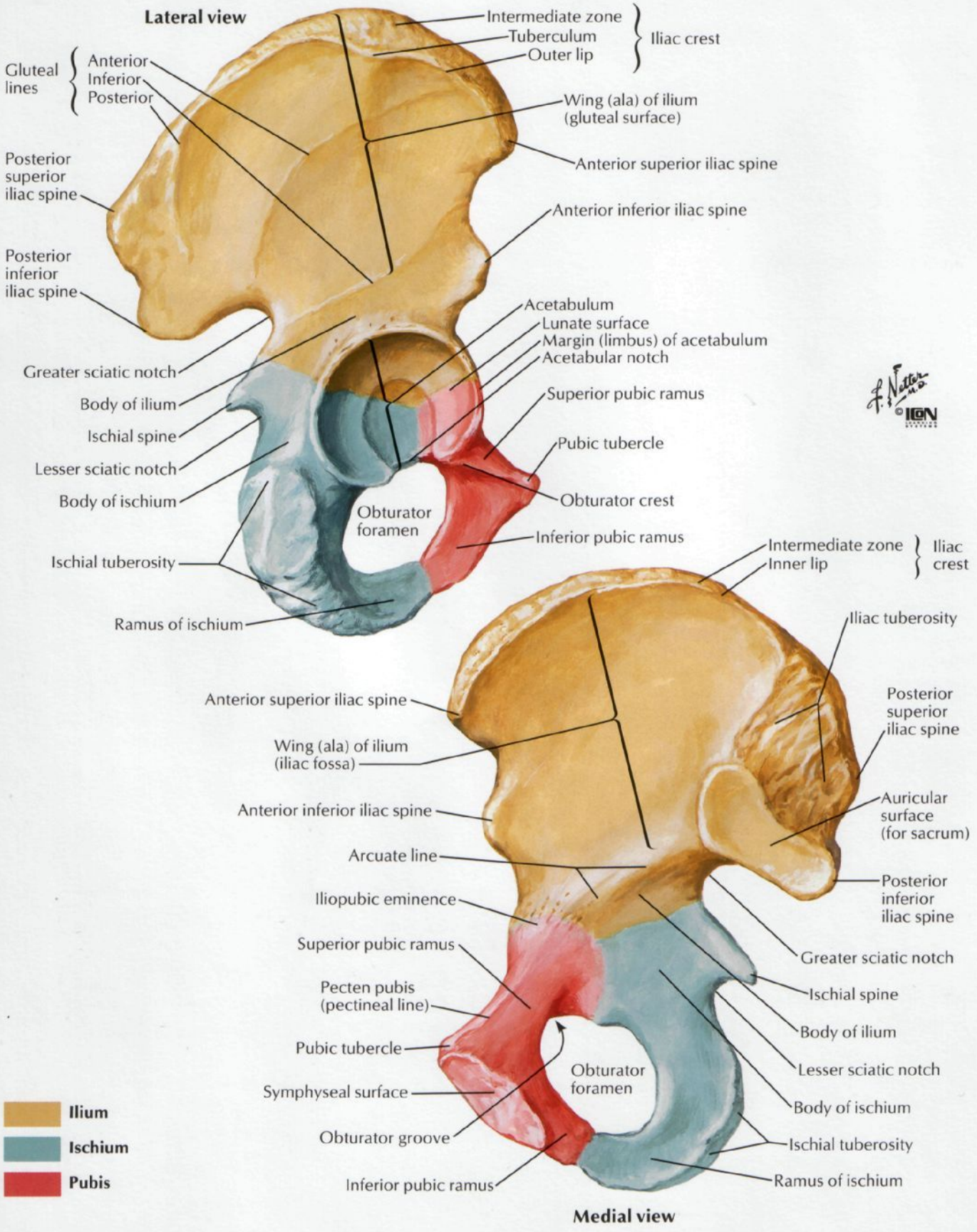

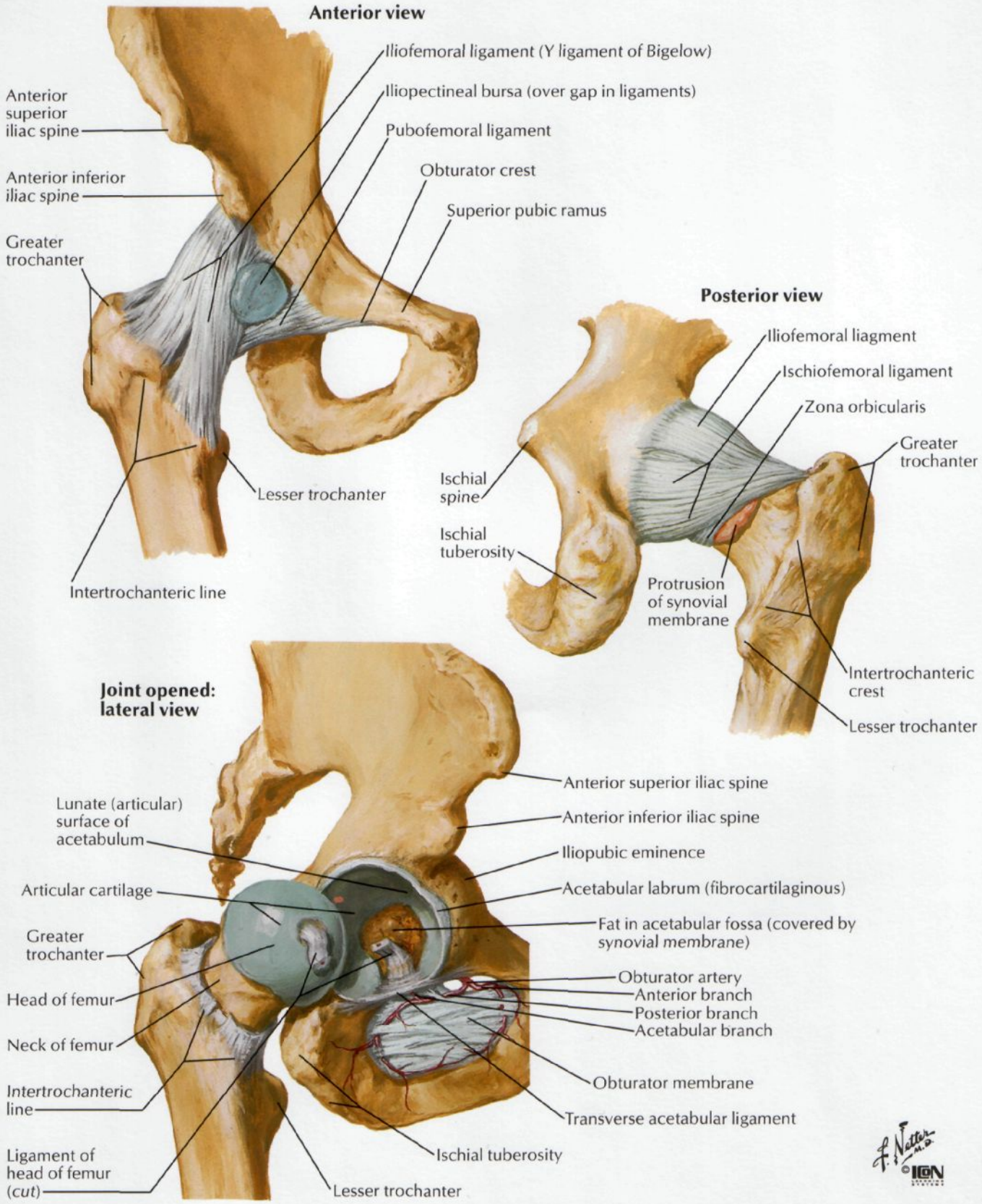
Anterior view
Iliofemoral ligament (Y ligament of Bigelow)
Iliopectineal bursa (over gap in ligaments)
Pubofemoral ligament
Obturator crest
Superior pubic ramus
Anterior superior iliac spine
Anterior inferior iliac spine
Greater trochanter
Lesser trochanter
Intertrochanteric line
Posterior view
Iliofemoral liagment
Ischiofemoral ligament
Zona orbicularis
Greater trochanter
Ischial spine
Ischial tuberosity
Protrusion of synovial membrane
Intertrochanteric crest
Lesser trochanter
Joint opened: lateral view
Anterior superior iliac spine
Anterior inferior iliac spine
Iliopubic eminence
Acetabular labrum (fibrocartilaginous)
Fat in acetabular fossa (covered by synovial membrane)
Obturator artery
Anterior branch
Posterior branch
Acetabular branch
Obturator membrane
Transverse acetabular ligament
Ischial tuberosity
Lesser trochanter
Lunate (articular) surface of acetabulum
Articular cartilage
Greater trochanter
Head of femur
Neck of femur
Intertrochanteric line
Ligament of head of femur (cut)
F. Netter M.D.
©IGN

Hip Joint: Anteroposterior Radiograph

SEE ALSO PLATES 469, 471

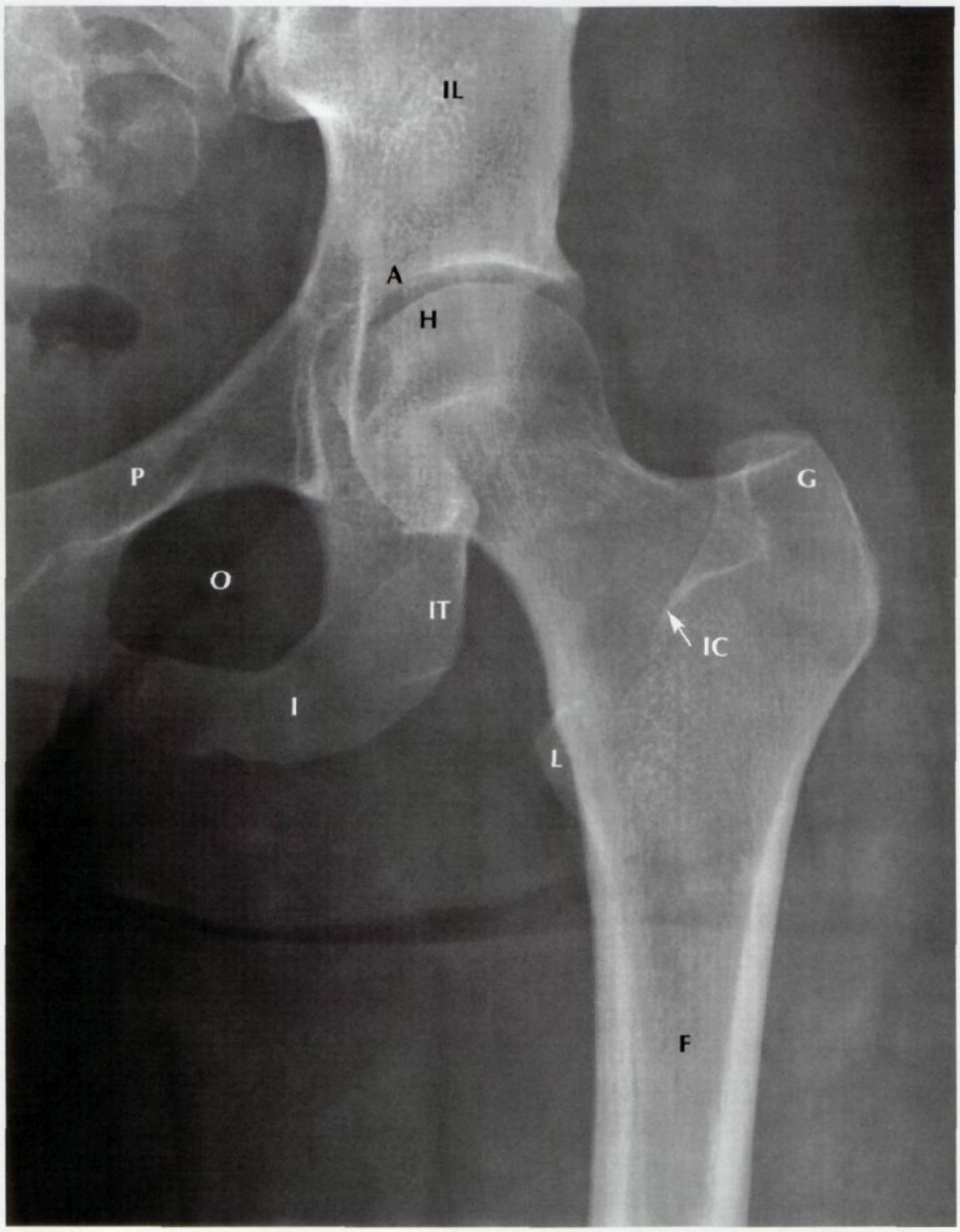

A	Acetabulum
F	Femur
G	Greater trochanter
H	Head of femur
I	Ischium
IC	Intertrochanteric crest
IL	Ileum
IT	Ischial tuberosity
L	Lesser trochanter
O	Obturator foramen
P	Pubis (superior ramus)

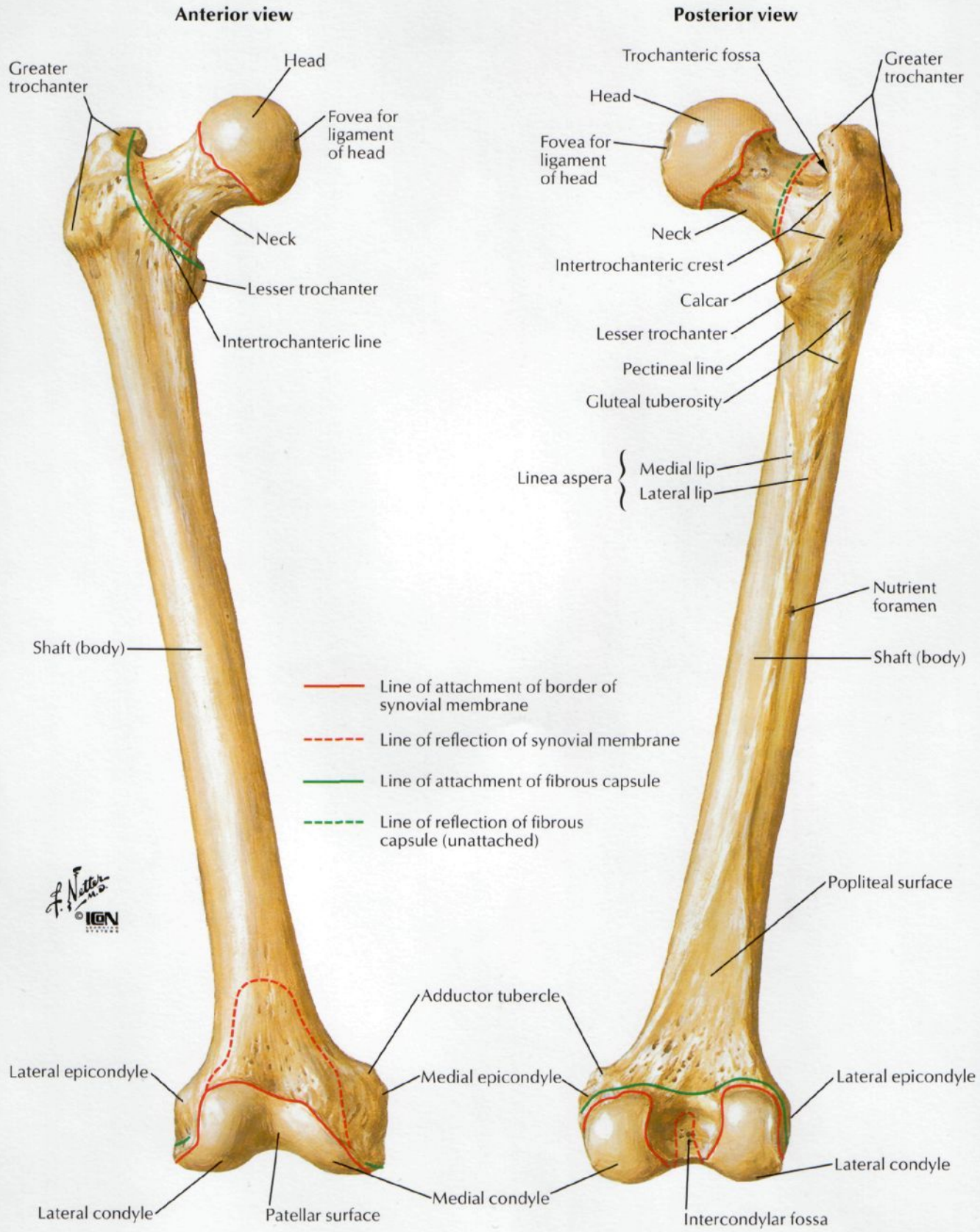
Anterior view
Greater trochanter
Head
Fovea for ligament of head
Neck
Lesser trochanter
Intertrochanteric line
Shaft (body)
Lateral epicondyle
Lateral condyle
Patellar surface
Adductor tubercle
Medial epicondyle
Medial condyle
Posterior view
Trochanteric fossa
Greater trochanter
Head
Fovea for ligament of head
Neck
Intertrochanteric crest
Calcar
Lesser trochanter
Pectineal line
Gluteal tuberosity
Linea aspera
Medial lip
Lateral lip
Nutrient foramen
Shaft (body)
Popliteal surface
Lateral epicondyle
Lateral condyle
Intercondylar fossa
Line of attachment of border of synovial membrane
Line of reflection of synovial membrane
Line of attachment of fibrous capsule
Line of reflection of fibrous capsule (unattached)

Bony Attachments of Muscles of Hip and Thigh: Anterior View

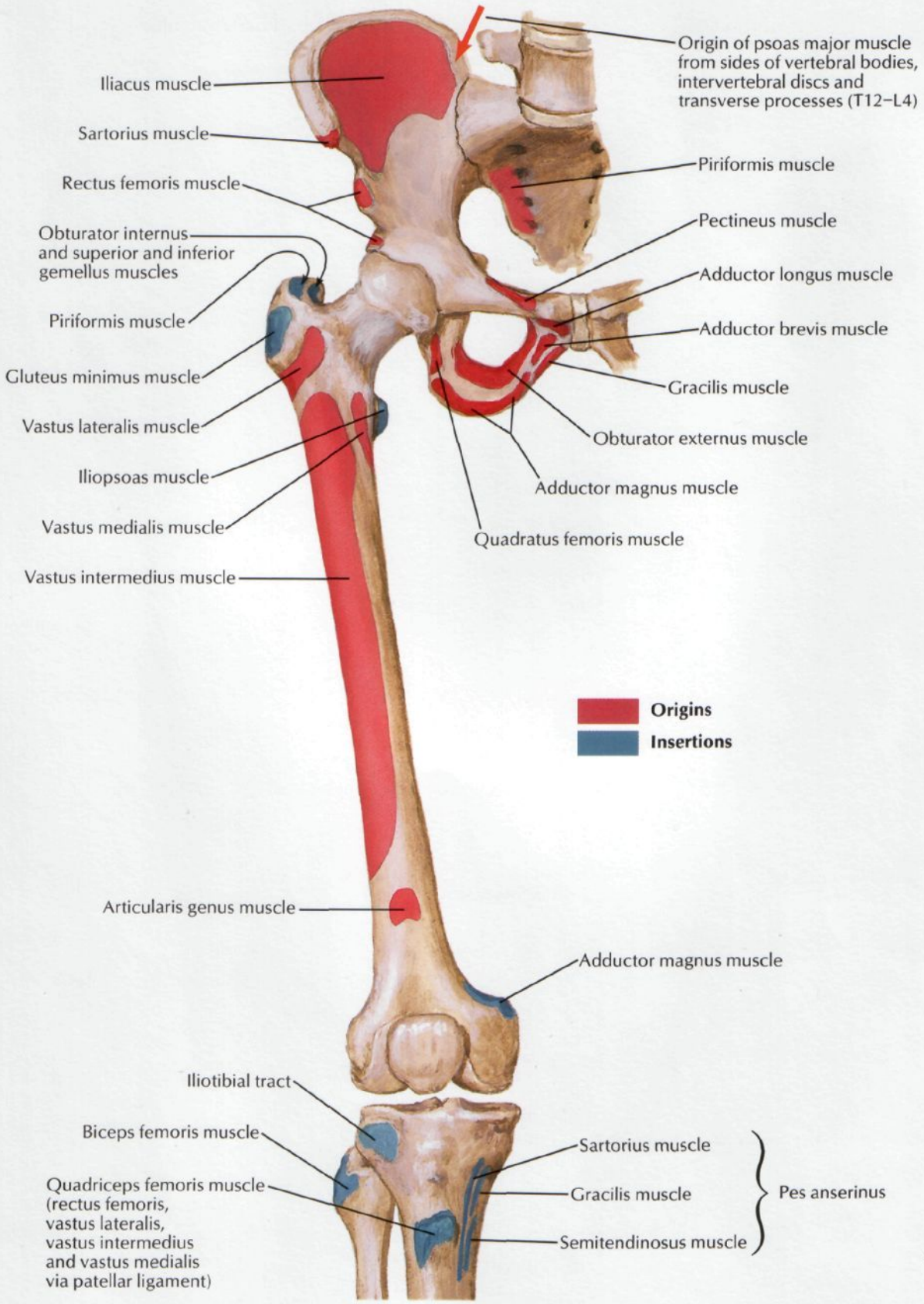

Bony Attachments of Muscles of Hip and Thigh: Posterior View

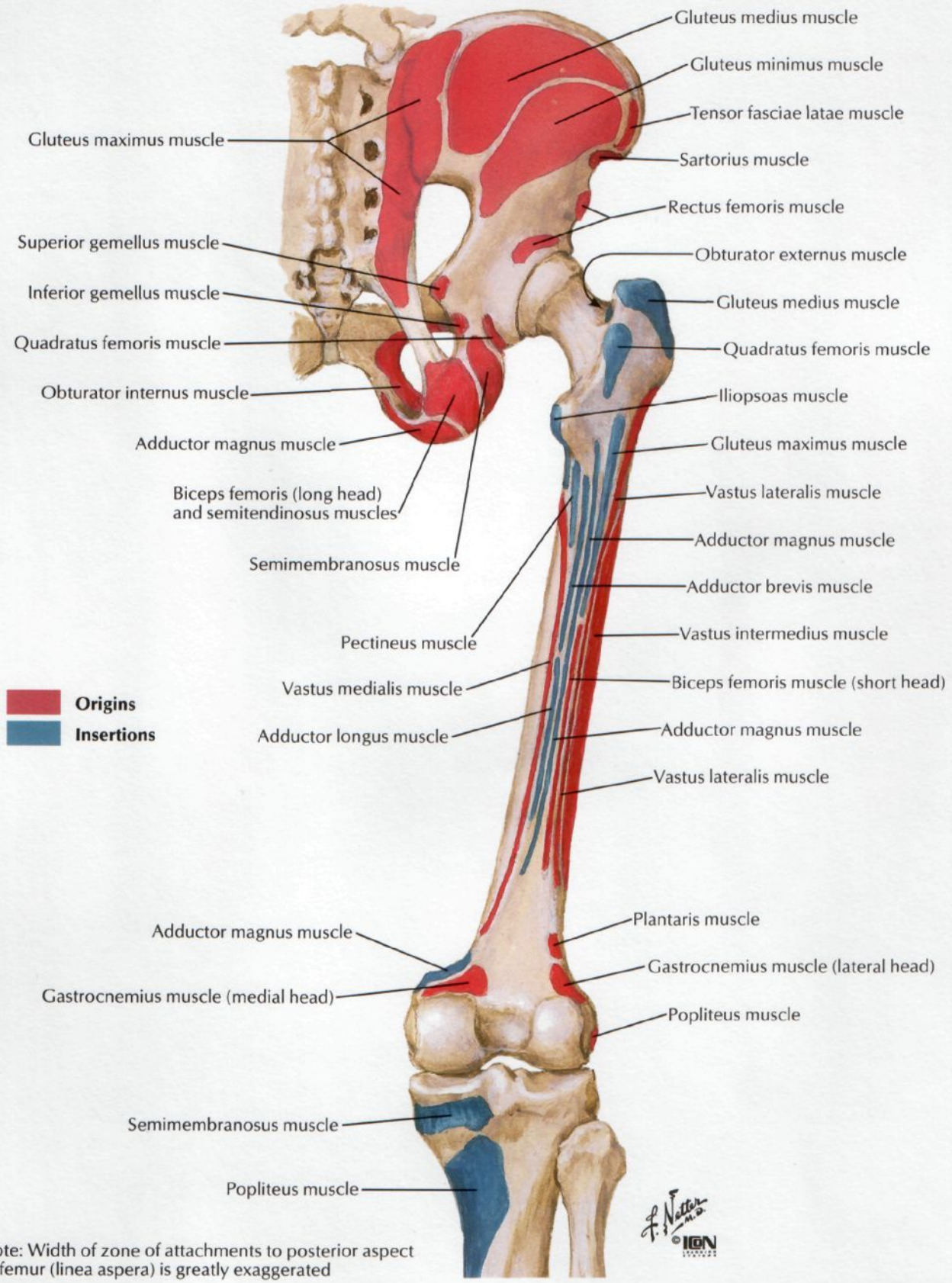

Note: Width of zone of attachments to posterior aspect of femur (linea aspera) is greatly exaggerated

Muscles of Thigh: Anterior Views

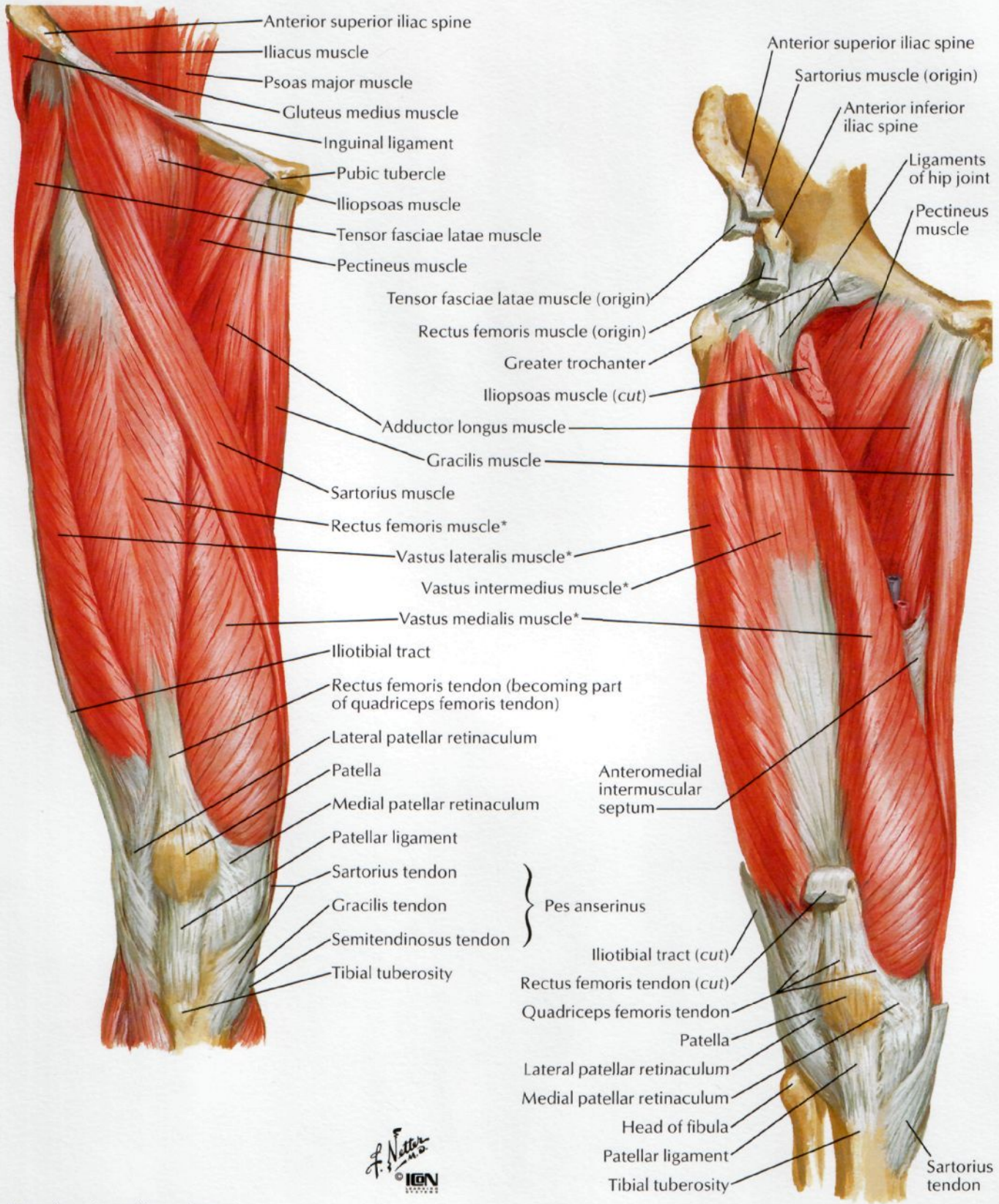

*Muscles of quadriceps femoris

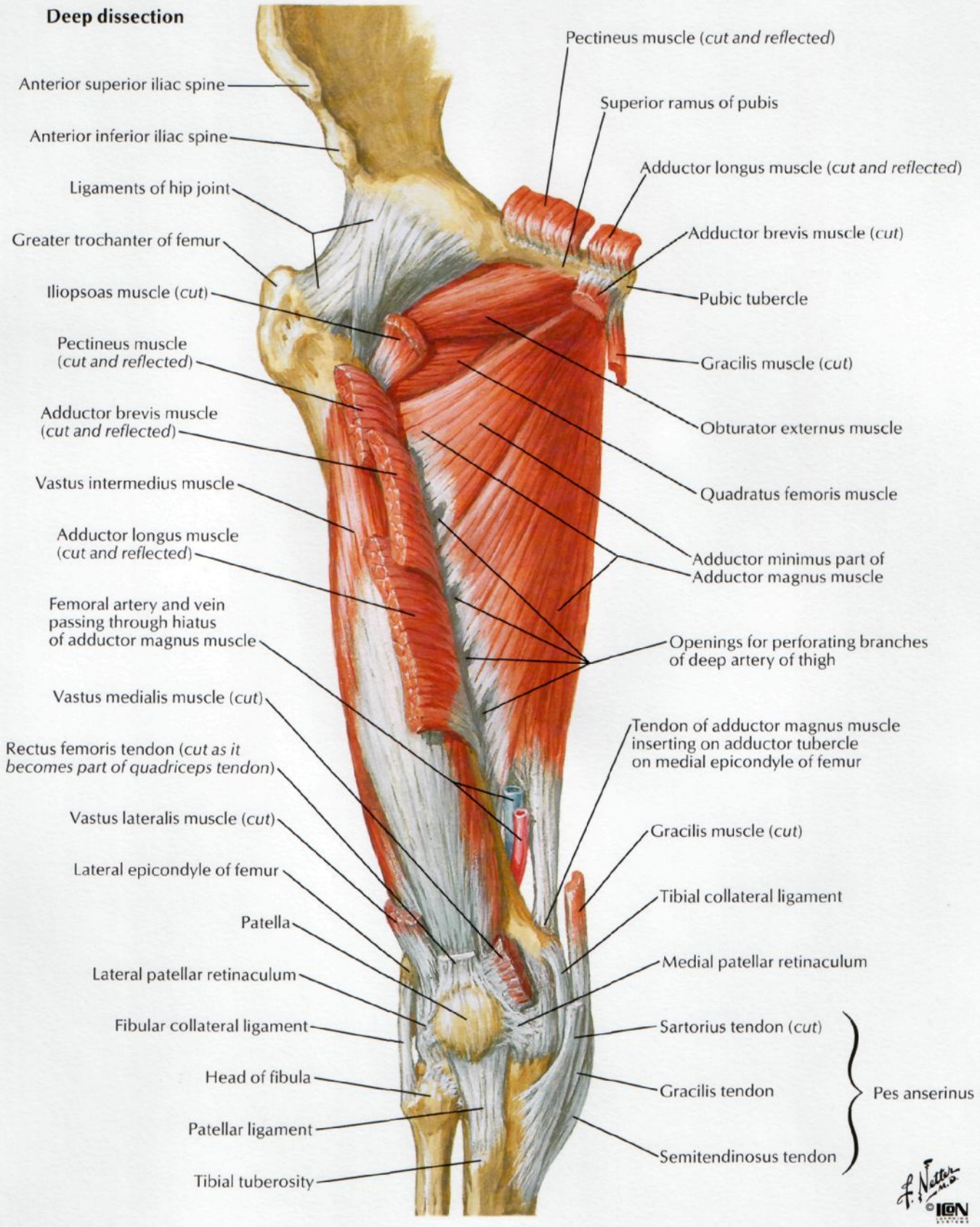
Deep dissection
Anterior superior iliac spine
Anterior inferior iliac spine
Ligaments of hip joint
Greater trochanter of femur
Iliopsoas muscle (cut)
Pectineus muscle (cut and reflected)
Adductor brevis muscle (cut and reflected)
Vastus intermedius muscle
Adductor longus muscle (cut and reflected)
Femoral artery and vein passing through hiatus of adductor magnus muscle
Vastus medialis muscle (cut)
Rectus femoris tendon (cut as it becomes part of quadriceps tendon)
Vastus lateralis muscle (cut)
Lateral epicondyle of femur
Patella
Lateral patellar retinaculum
Fibular collateral ligament
Head of fibula
Patellar ligament
Tibial tuberosity
Pectineus muscle (cut and reflected)
Superior ramus of pubis
Adductor longus muscle (cut and reflected)
Adductor brevis muscle (cut)
Pubic tubercle
Gracilis muscle (cut)
Obturator externus muscle
Quadratus femoris muscle
Adductor minimus part of Adductor magnus muscle
Openings for perforating branches of deep artery of thigh
Tendon of adductor magnus muscle inserting on adductor tubercle on medial epicondyle of femur
Gracilis muscle (cut)
Tibial collateral ligament
Medial patellar retinaculum
Sartorius tendon (cut)
Gracilis tendon
Semitendinosus tendon
Pes anserinus

Muscles of Hip and Thigh: Lateral View

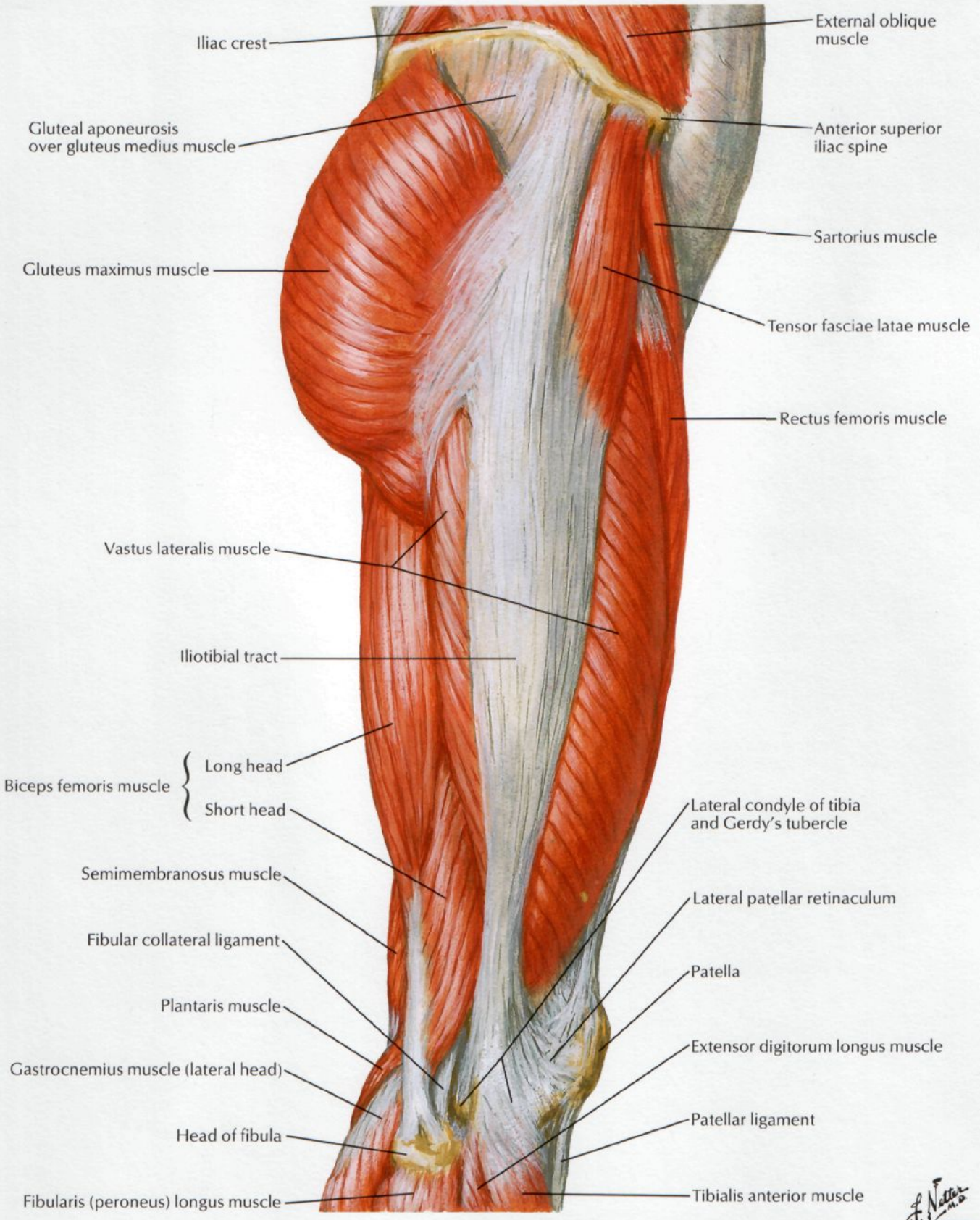

Muscles of Hip and Thigh: Posterior Views

FOR PIRIFORMIS AND OBTURATOR INTERNUS SEE ALSO PLATES 343, 344; FOR OBTURATOR EXTERNUS SEE PLATE 483

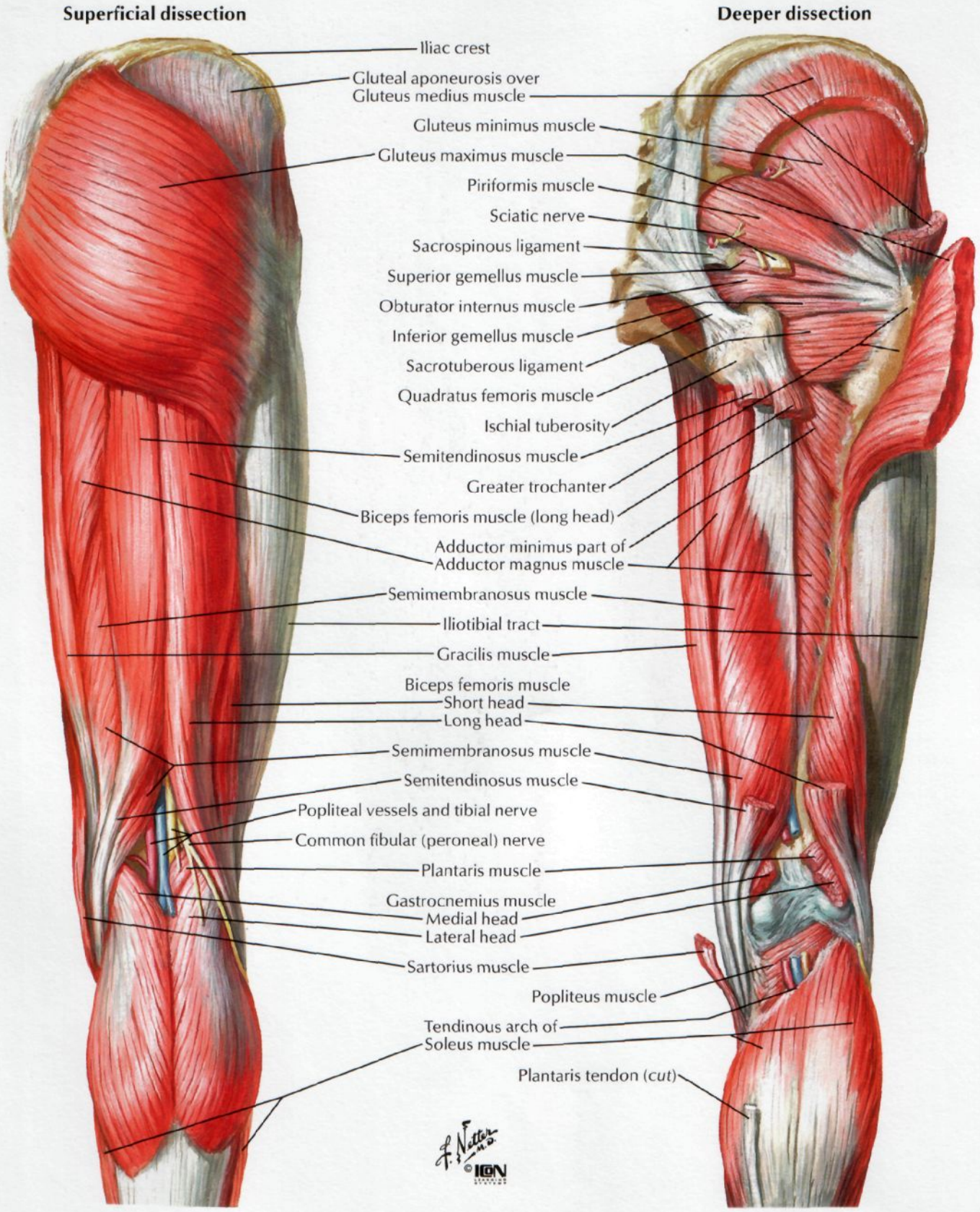

Psoas and Iliacus Muscles

SEE ALSO PLATE 255

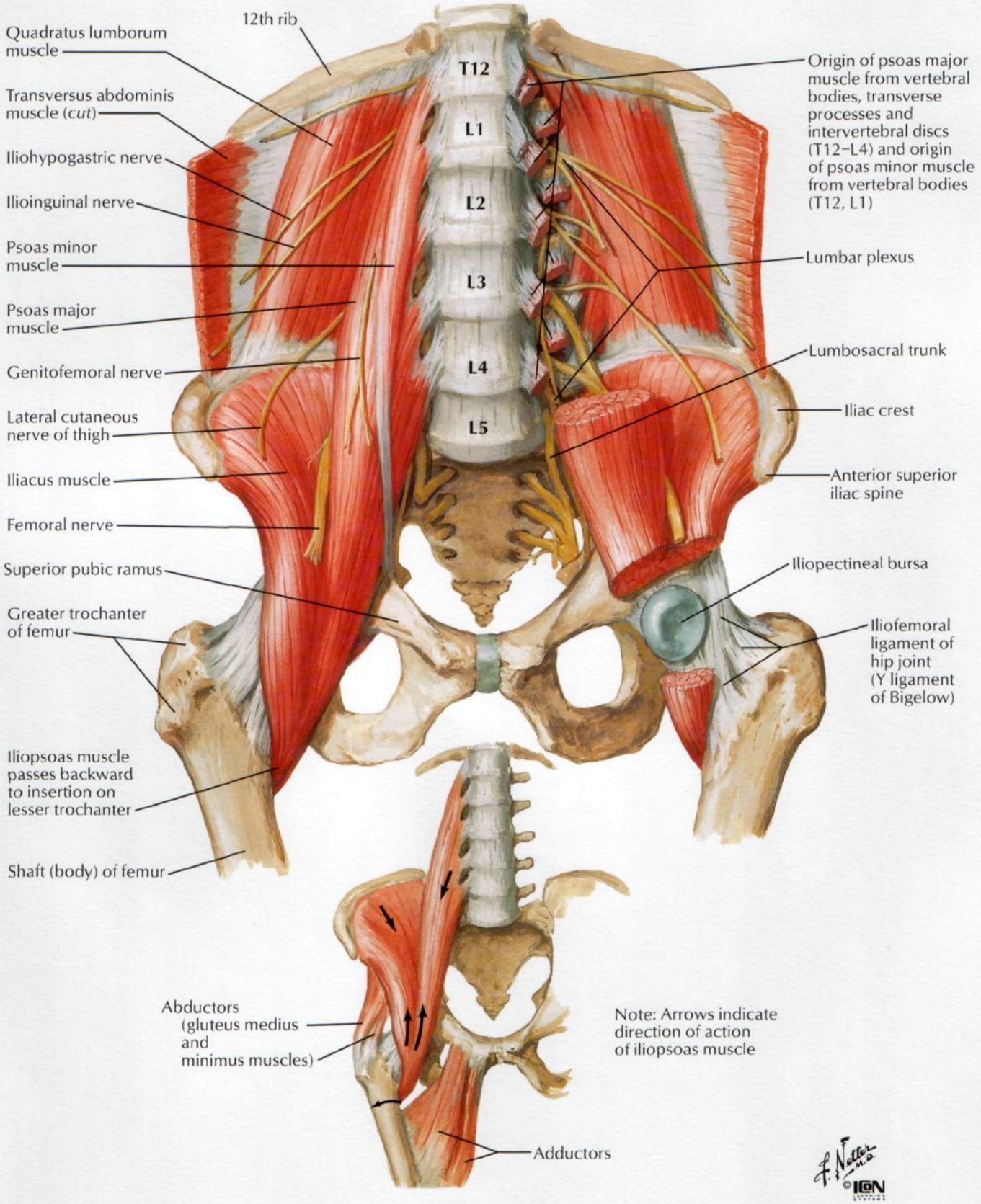

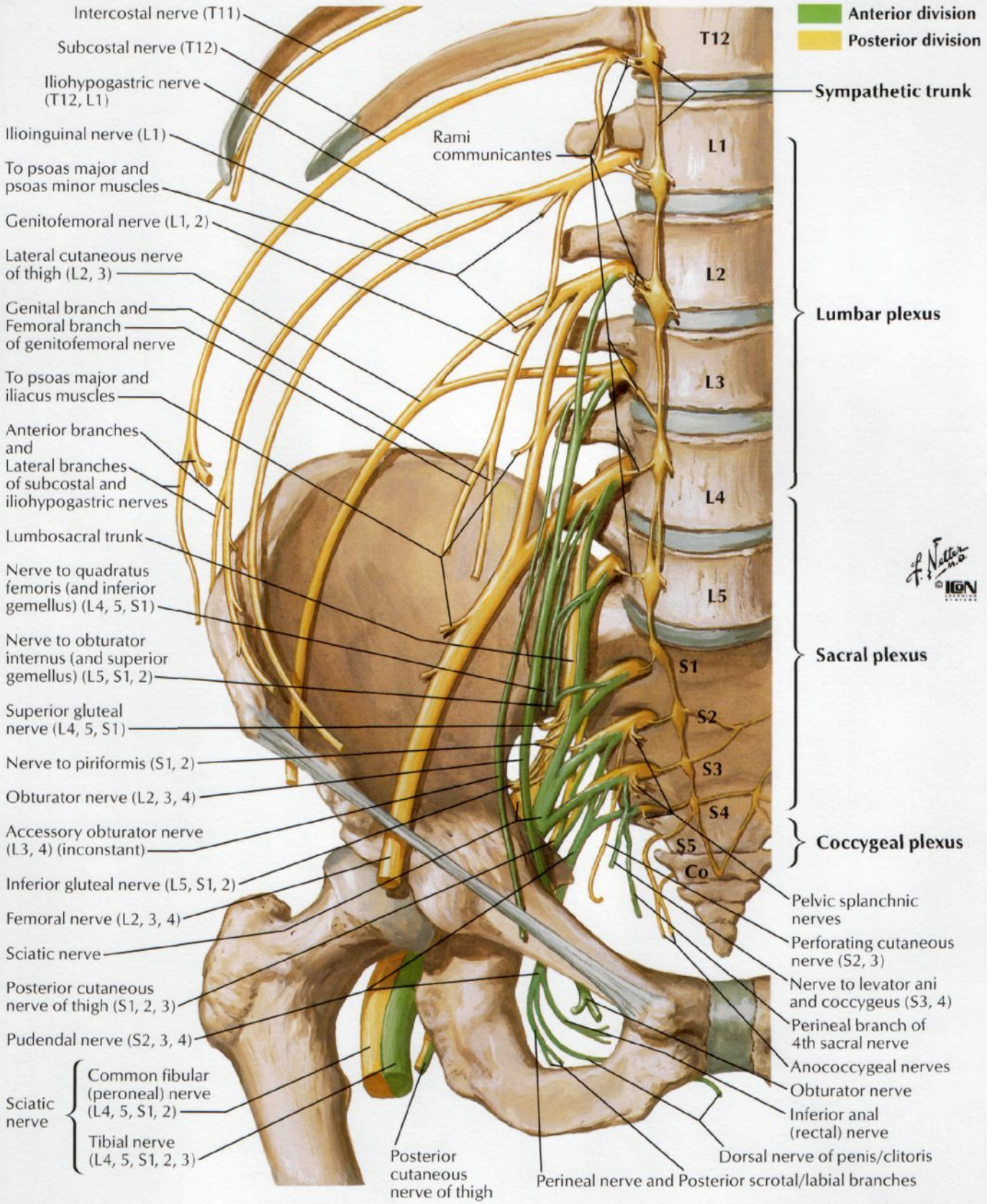
Anterior division
Posterior division
Intercostal nerve (T11)
Subcostal nerve (T12)
Iliohypogastric nerve (T12, L1)
Ilioinguinal nerve (L1)
To psoas major and psoas minor muscles
Genitofemoral nerve (L1, 2)
Lateral cutaneous nerve of thigh (L2, 3)
Genital branch and Femoral branch of genitofemoral nerve
To psoas major and iliacus muscles
Anterior branches and Lateral branches of subcostal and iliohypogastric nerves
Lumbosacral trunk
Nerve to quadratus femoris (and inferior gemellus) (L4, 5, S1)
Nerve to obturator internus (and superior gemellus) (L5, S1, 2)
Superior gluteal nerve (L4, 5, S1)
Nerve to piriformis (S1, 2)
Obturator nerve (L2, 3, 4)
Accessory obturator nerve (L3, 4) (inconstant)
Inferior gluteal nerve (L5, S1, 2)
Femoral nerve (L2, 3, 4)
Sciatic nerve
Posterior cutaneous nerve of thigh (S1, 2, 3)
Pudendal nerve (S2, 3, 4)
Sciatic nerve
Common fibular (peroneal) nerve (L4, 5, S1, 2)
Tibial nerve (L4, 5, S1, 2, 3)
Rami communicantes
T12
L1
L2
L3
L4
L5
S1
S2
S3
S4
S5
Co
Sympathetic trunk
Lumbar plexus
Sacral plexus
Coccygeal plexus
Pelvic splanchnic nerves
Perforating cutaneous nerve (S2, 3)
Nerve to levator ani and coccygeus (S3, 4)
Perineal branch of 4th sacral nerve
Anococcygeal nerves
Obturator nerve
Inferior anal (rectal) nerve
Dorsal nerve of penis/clitoris
Perineal nerve and Posterior scrotal/labial branches
Posterior cutaneous nerve of thigh

Lumbar Plexus

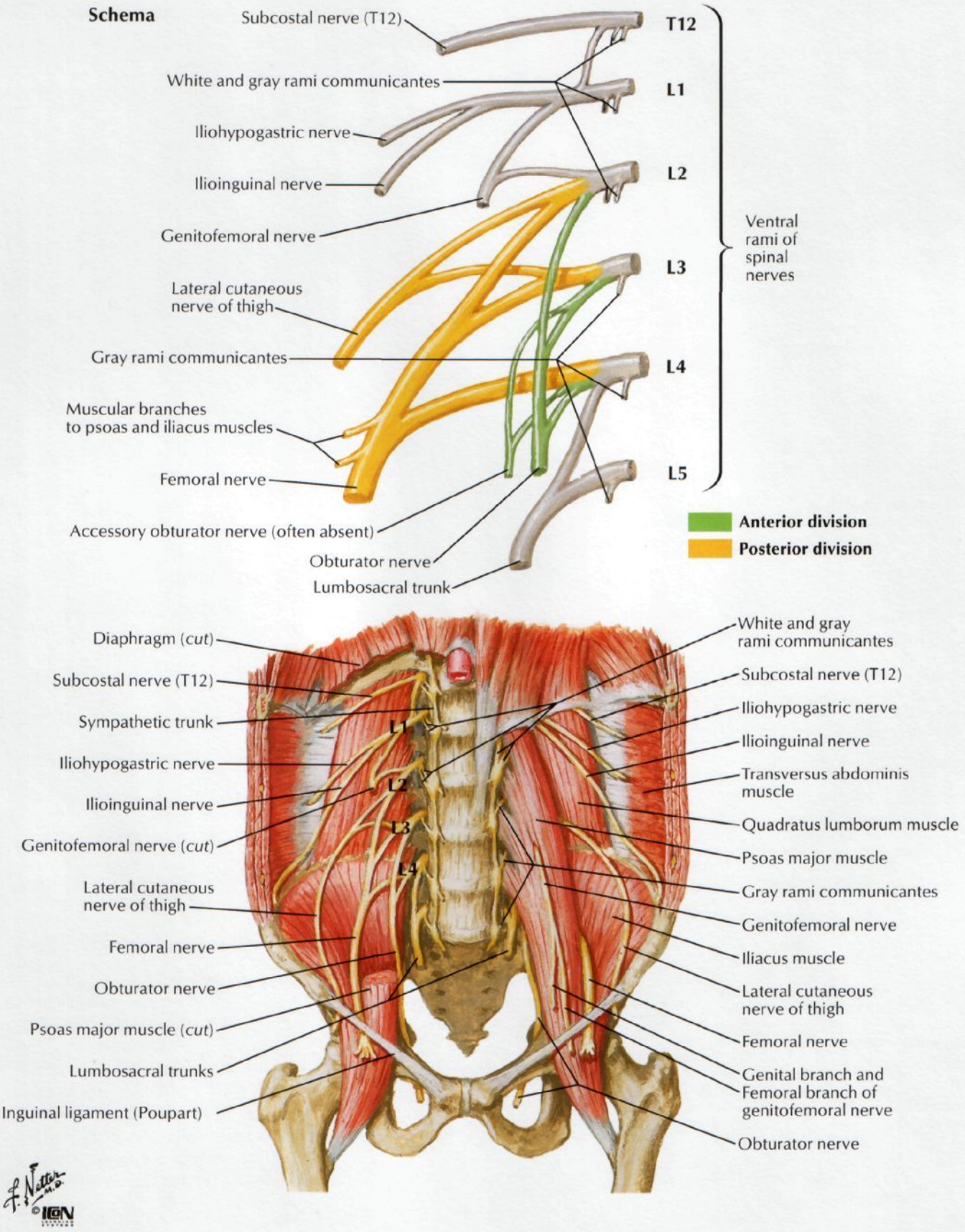

F. Netter M.D.
©IGN

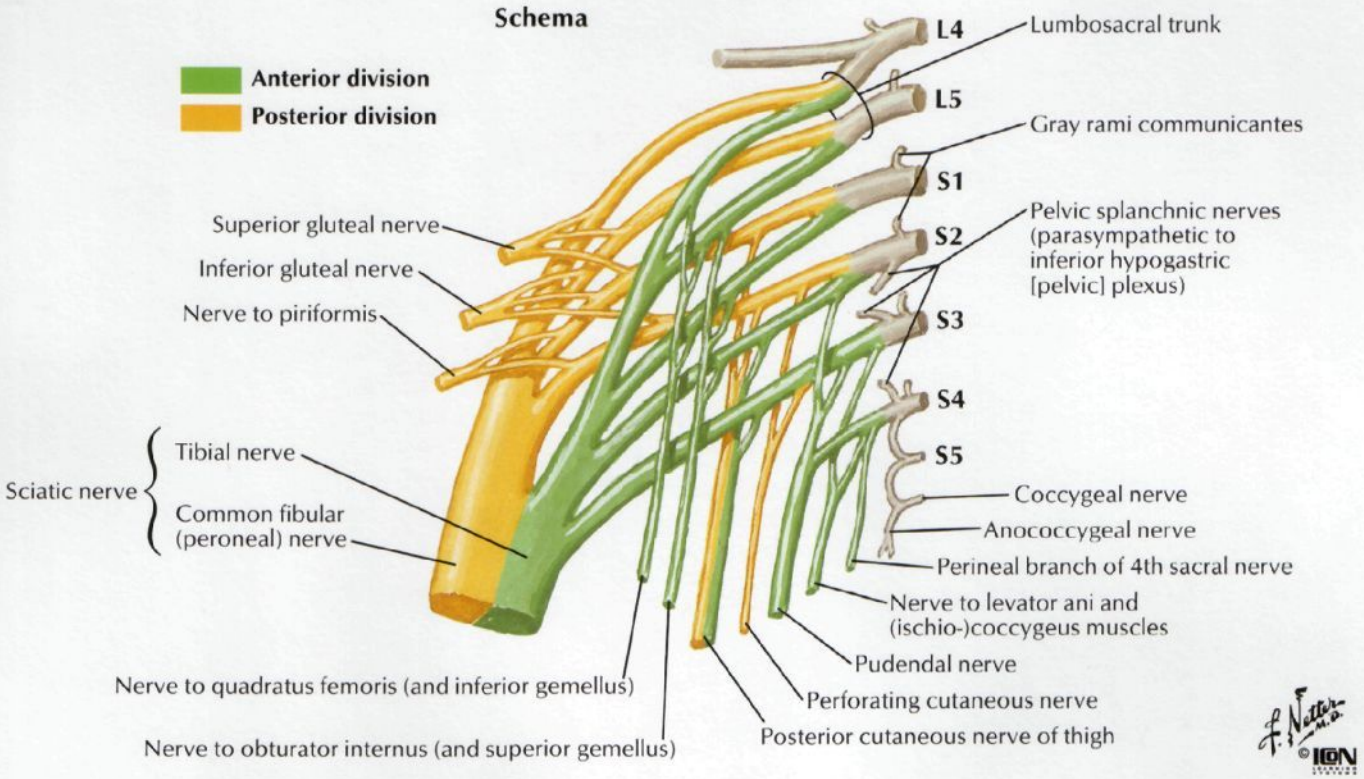

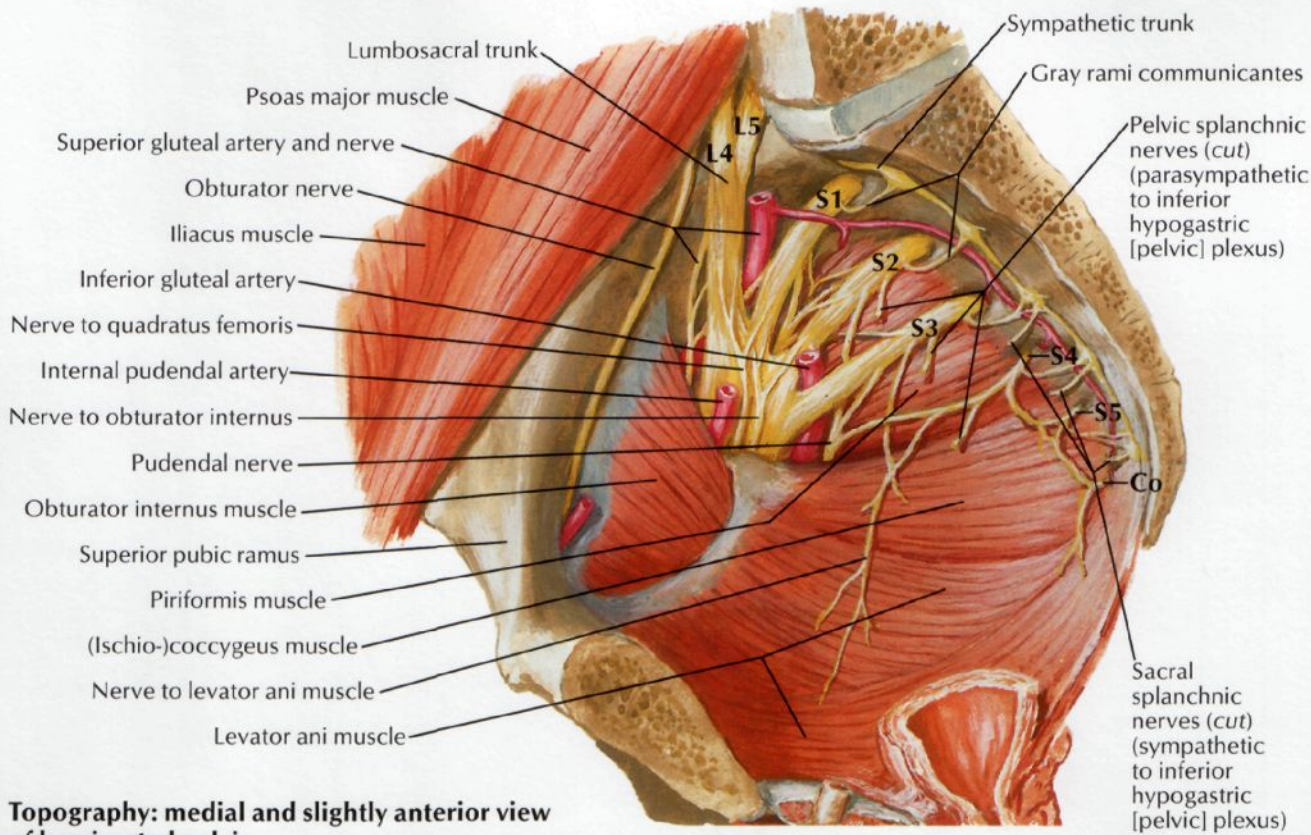

Topography: medial and slightly anterior view of hemisected pelvis

Arteries and Nerves of Thigh: Anterior Views

SEE ALSO PLATE 520

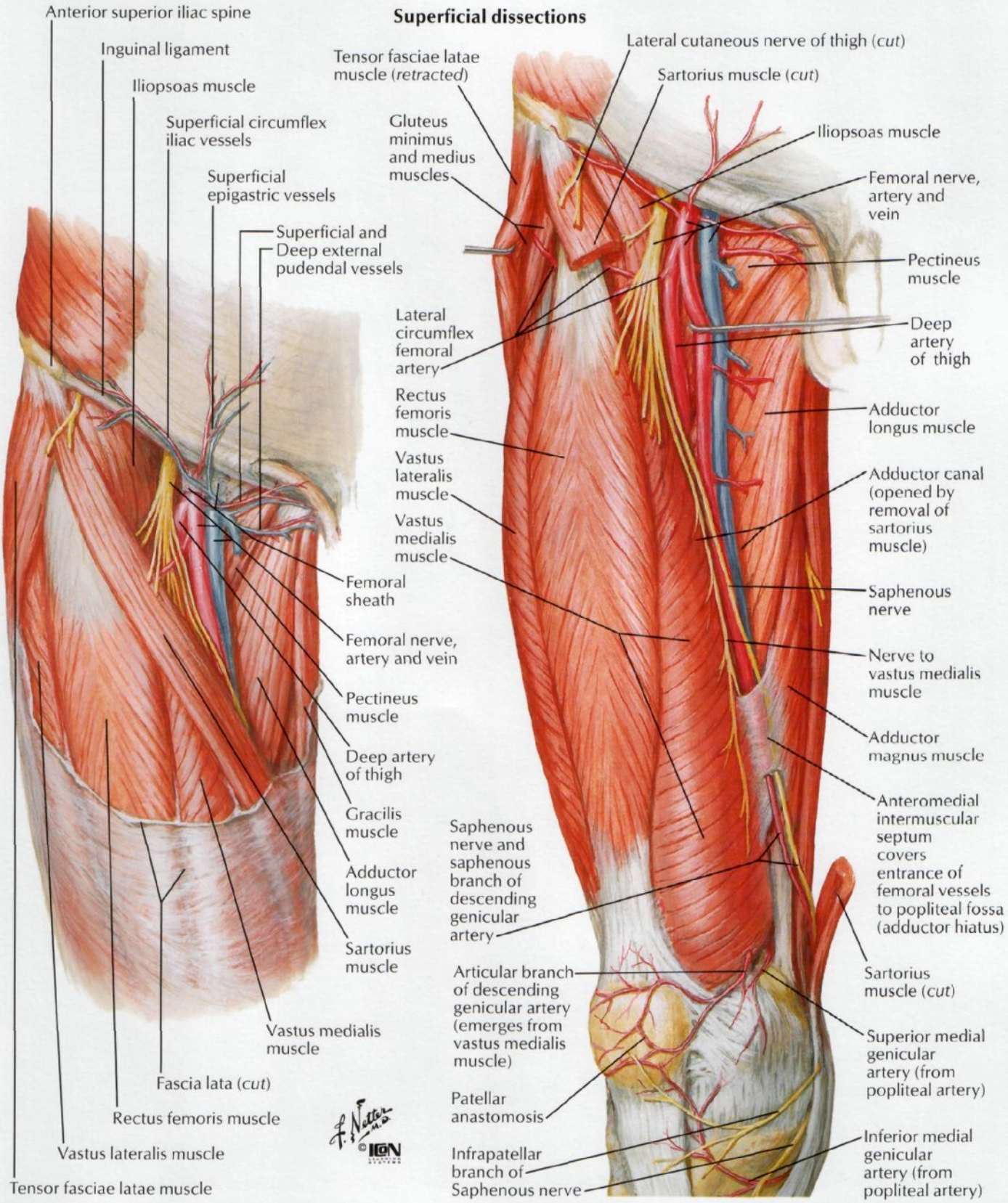

Arteries and Nerves of Thigh: Anterior Views (continued)

SEE ALSO PLATES 520, 521

Deep dissection

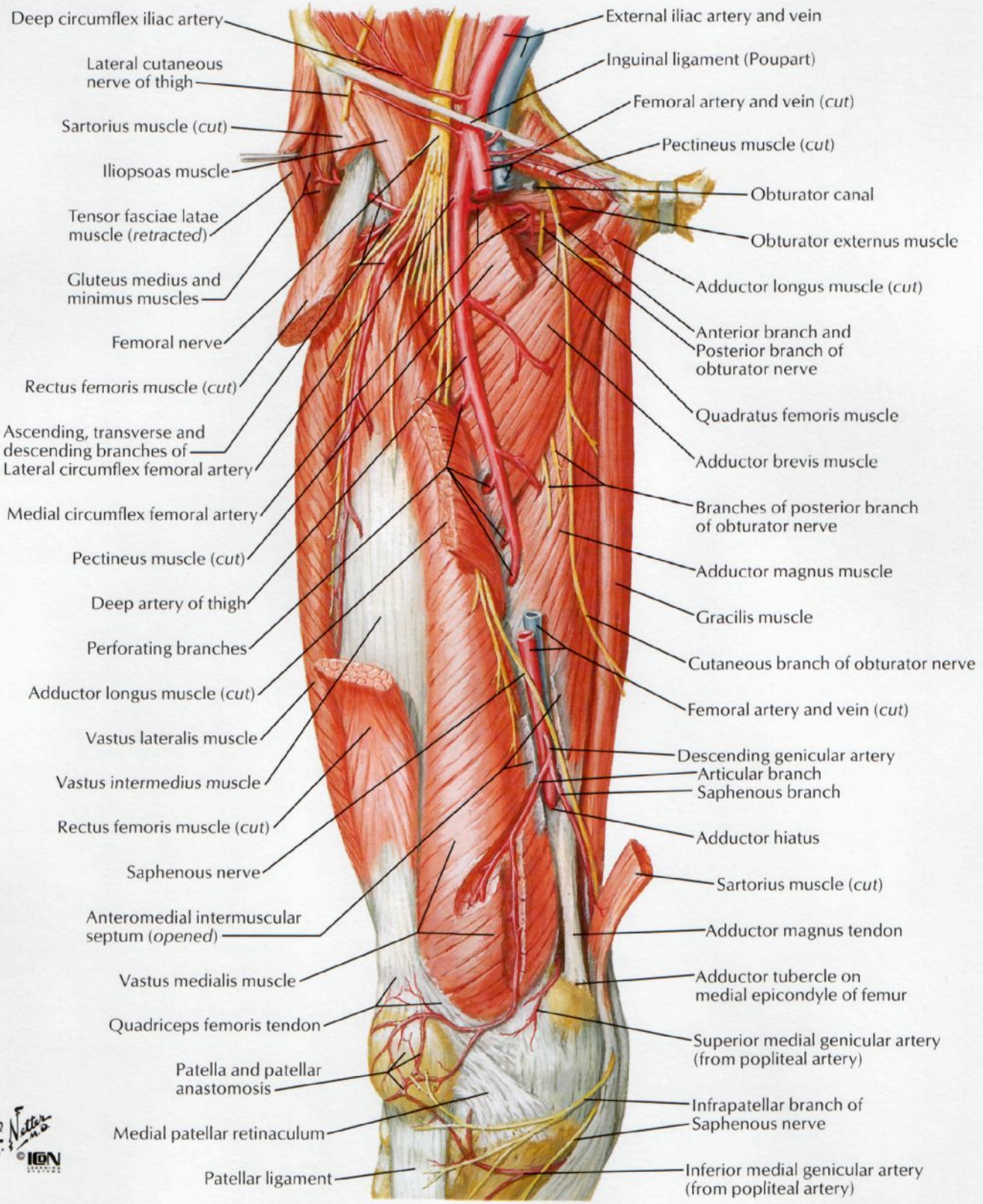

F. Netter M.D.
©IGN

Arteries and Nerves of Thigh: Posterior View

SEE ALSO PLATE 522

Deep dissection

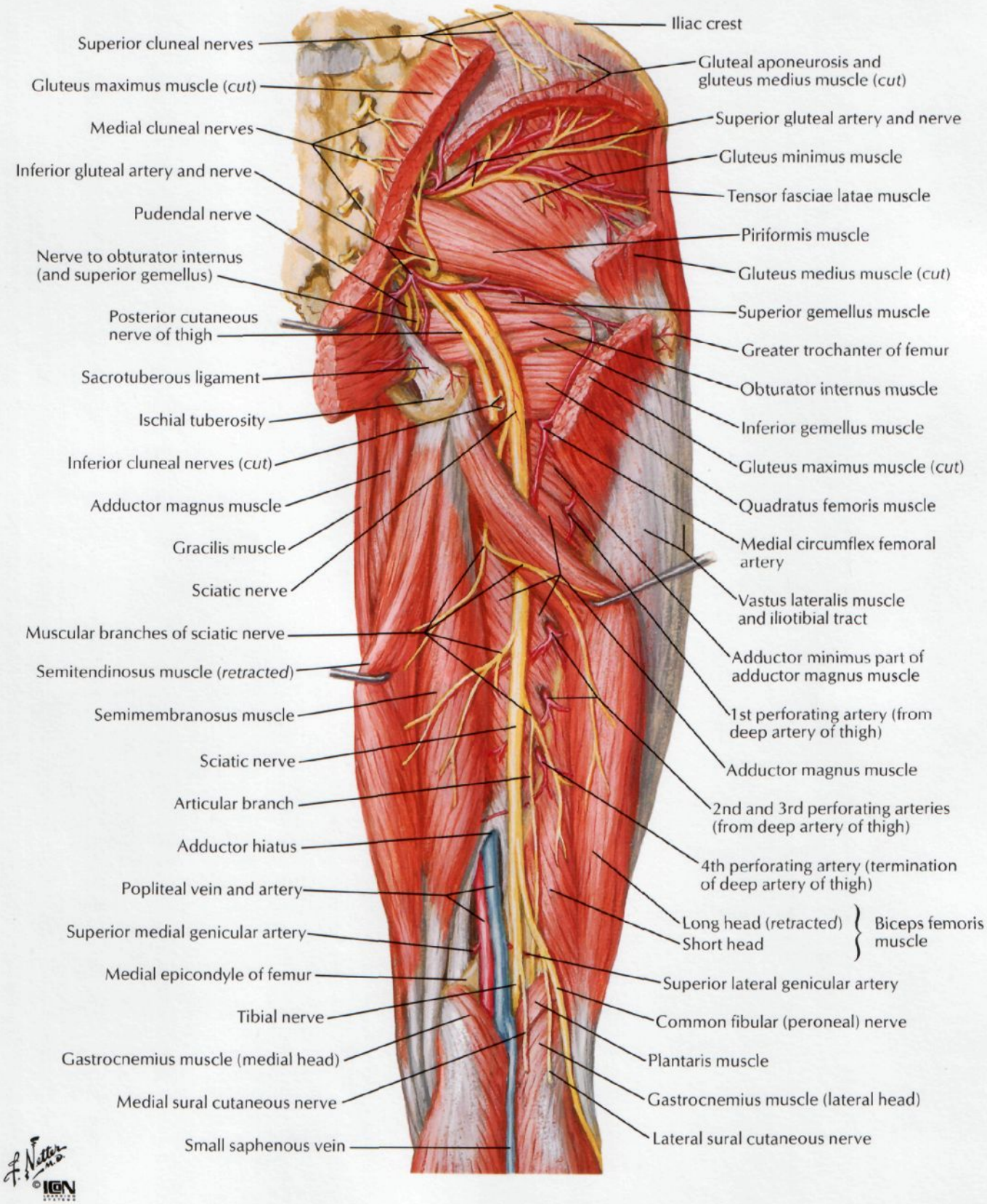

F. Netter M.D.
©IGN

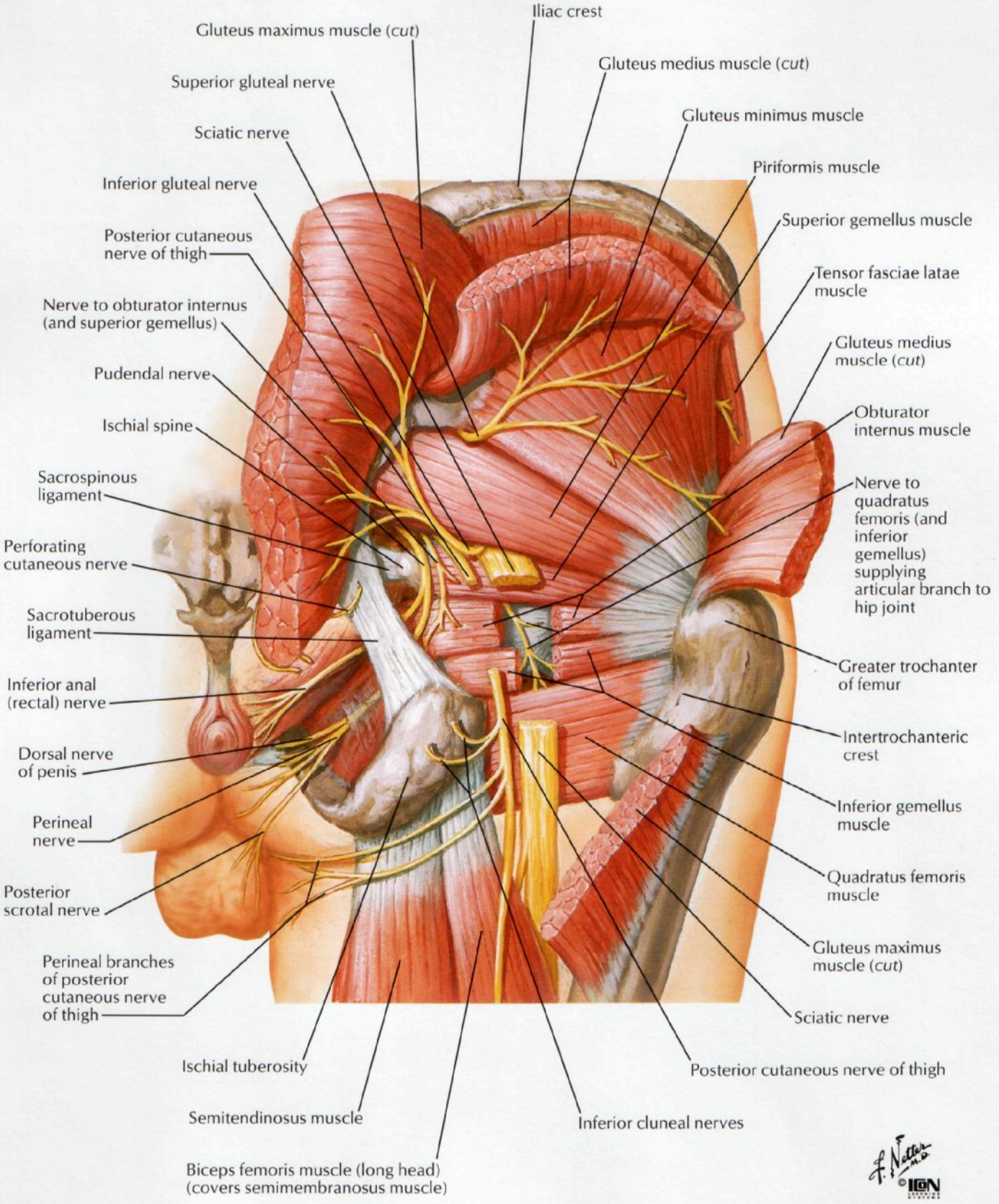
Iliac crest
Gluteus maximus muscle (*cut*)
Gluteus medius muscle (*cut*)
Superior gluteal nerve
Gluteus minimus muscle
Sciatic nerve
Piriformis muscle
Inferior gluteal nerve
Superior gemellus muscle
Posterior cutaneous nerve of thigh
Tensor fasciae latae muscle
Nerve to obturator internus (and superior gemellus)
Gluteus medius muscle (*cut*)
Pudendal nerve
Obturator internus muscle
Ischial spine
Sacrospinous ligament
Nerve to quadratus femoris (and inferior gemellus) supplying articular branch to hip joint
Perforating cutaneous nerve
Sacrotuberous ligament
Greater trochanter of femur
Inferior anal (rectal) nerve
Intertrochanteric crest
Dorsal nerve of penis
Inferior gemellus muscle
Perineal nerve
Quadratus femoris muscle
Posterior scrotal nerve
Gluteus maximus muscle (*cut*)
Perineal branches of posterior cutaneous nerve of thigh
Sciatic nerve
Ischial tuberosity
Posterior cutaneous nerve of thigh
Semitendinosus muscle
Inferior cluneal nerves
Biceps femoris muscle (long head) (covers semimembranosus muscle)

Arteries of Femoral Head and Neck

SEE ALSO PLATE 494

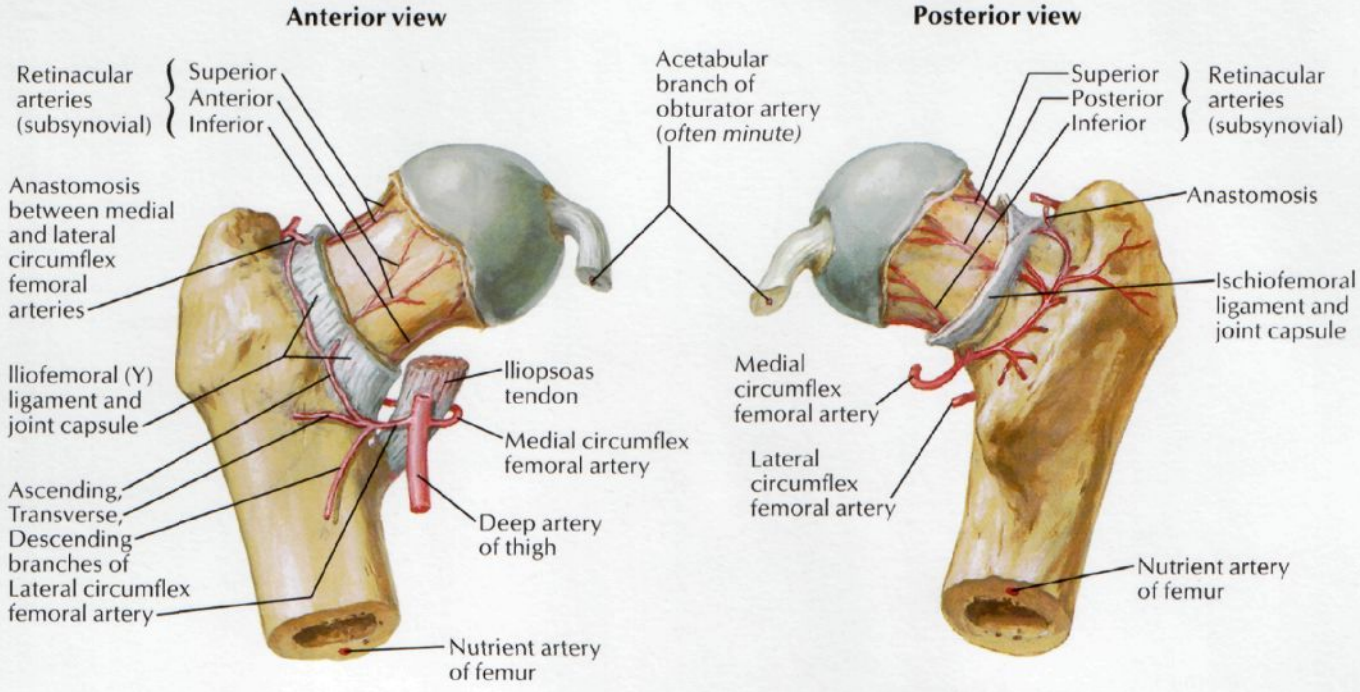

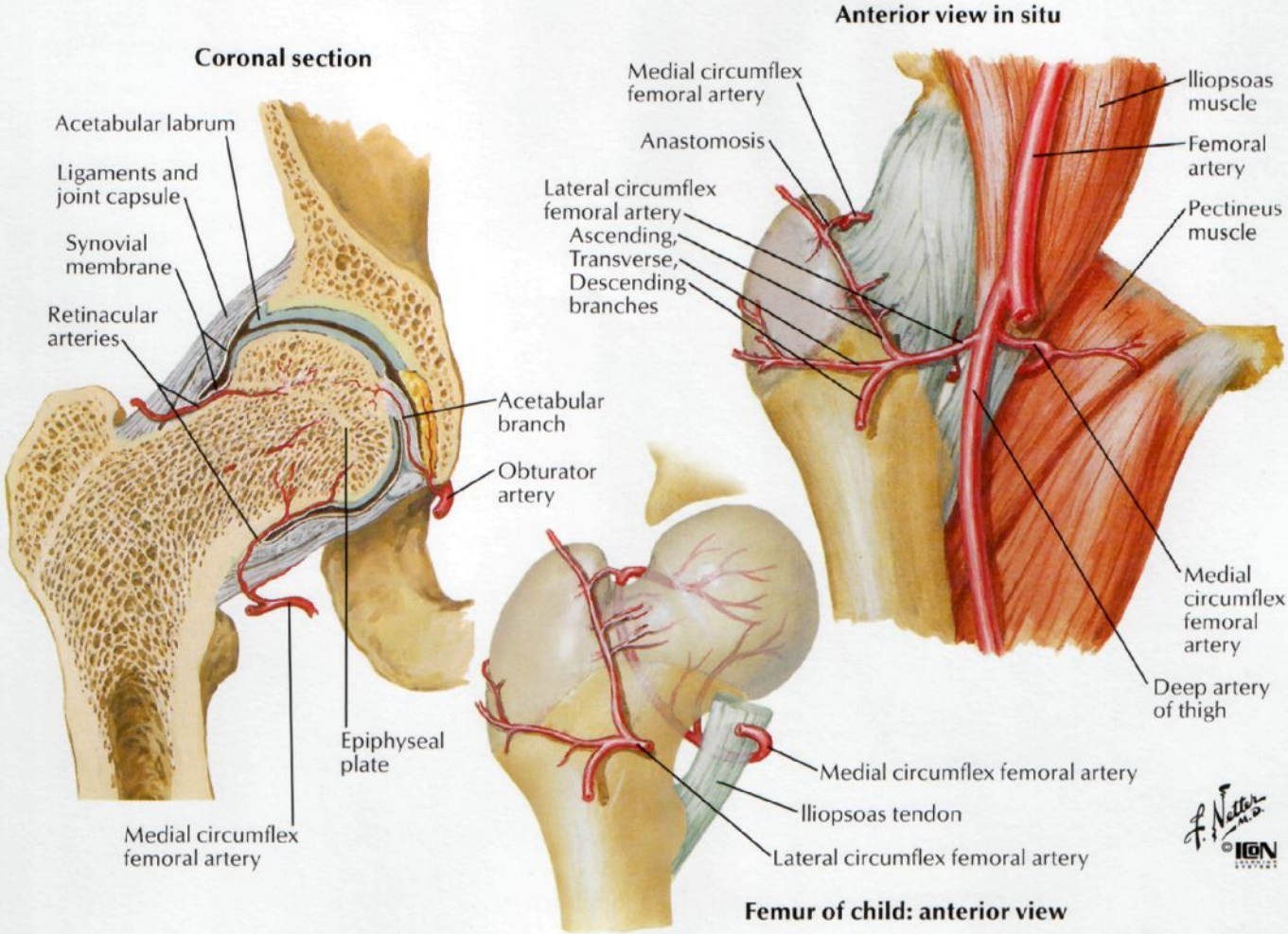

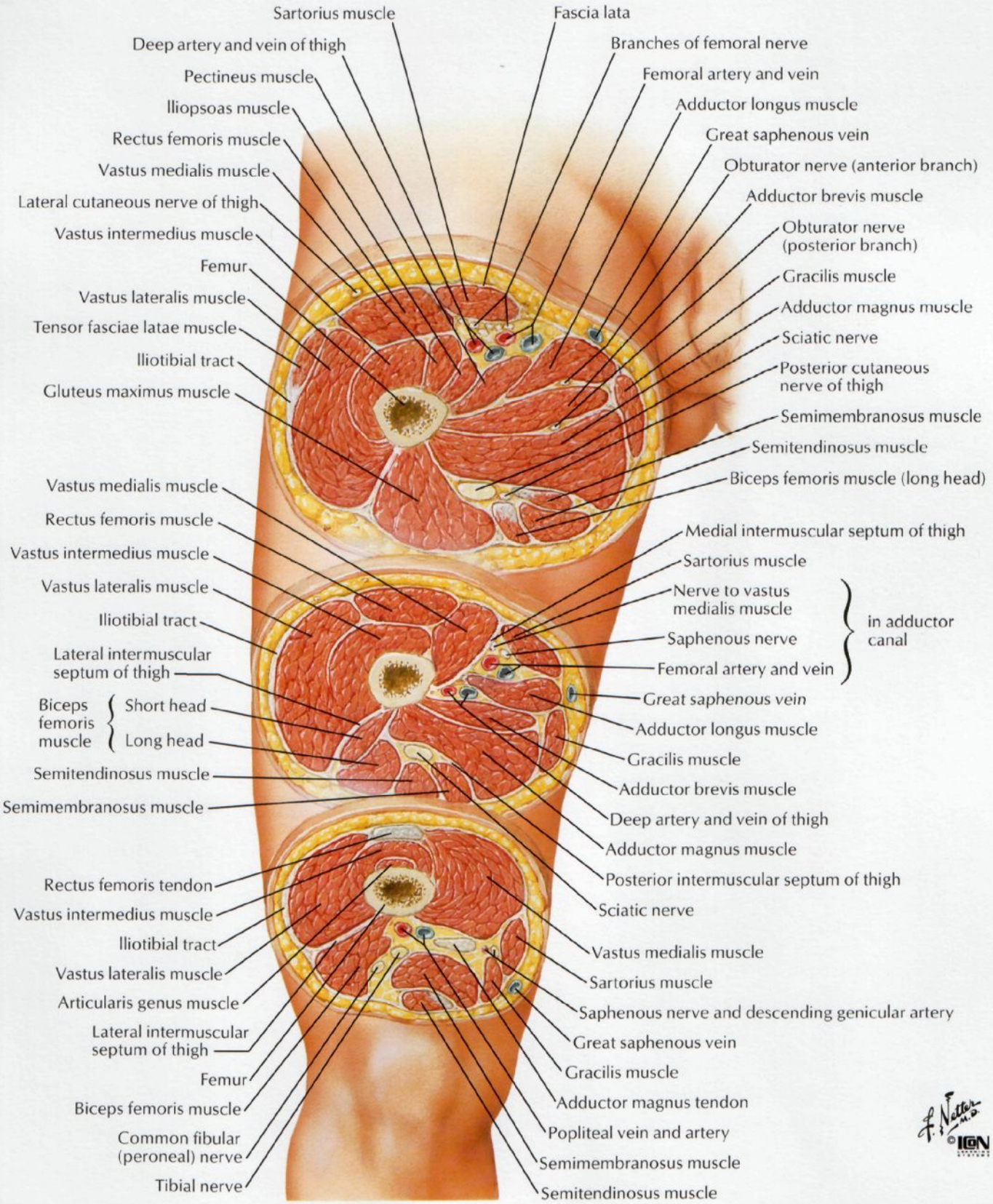
Sartorius muscle
Deep artery and vein of thigh
Pectineus muscle
Iliopsoas muscle
Rectus femoris muscle
Vastus medialis muscle
Lateral cutaneous nerve of thigh
Vastus intermedius muscle
Femur
Vastus lateralis muscle
Tensor fasciae latae muscle
Iliotibial tract
Gluteus maximus muscle
Fascia lata
Branches of femoral nerve
Femoral artery and vein
Adductor longus muscle
Great saphenous vein
Obturator nerve (anterior branch)
Adductor brevis muscle
Obturator nerve (posterior branch)
Gracilis muscle
Adductor magnus muscle
Sciatic nerve
Posterior cutaneous nerve of thigh
Semimembranosus muscle
Semitendinosus muscle
Biceps femoris muscle (long head)
Vastus medialis muscle
Rectus femoris muscle
Vastus intermedius muscle
Vastus lateralis muscle
Iliotibial tract
Lateral intermuscular septum of thigh
Biceps femoris muscle
Short head
Long head
Semitendinosus muscle
Semimembranosus muscle
Medial intermuscular septum of thigh
Sartorius muscle
Nerve to vastus medialis muscle
Saphenous nerve
Femoral artery and vein
in adductor canal
Great saphenous vein
Adductor longus muscle
Gracilis muscle
Adductor brevis muscle
Deep artery and vein of thigh
Adductor magnus muscle
Posterior intermuscular septum of thigh
Sciatic nerve
Rectus femoris tendon
Vastus intermedius muscle
Iliotibial tract
Vastus lateralis muscle
Articularis genus muscle
Lateral intermuscular septum of thigh
Femur
Biceps femoris muscle
Common fibular (peroneal) nerve
Tibial nerve
Vastus medialis muscle
Sartorius muscle
Saphenous nerve and descending genicular artery
Great saphenous vein
Gracilis muscle
Adductor magnus tendon
Popliteal vein and artery
Semimembranosus muscle
Semitendinosus muscle

Knee: Lateral and Medial Views

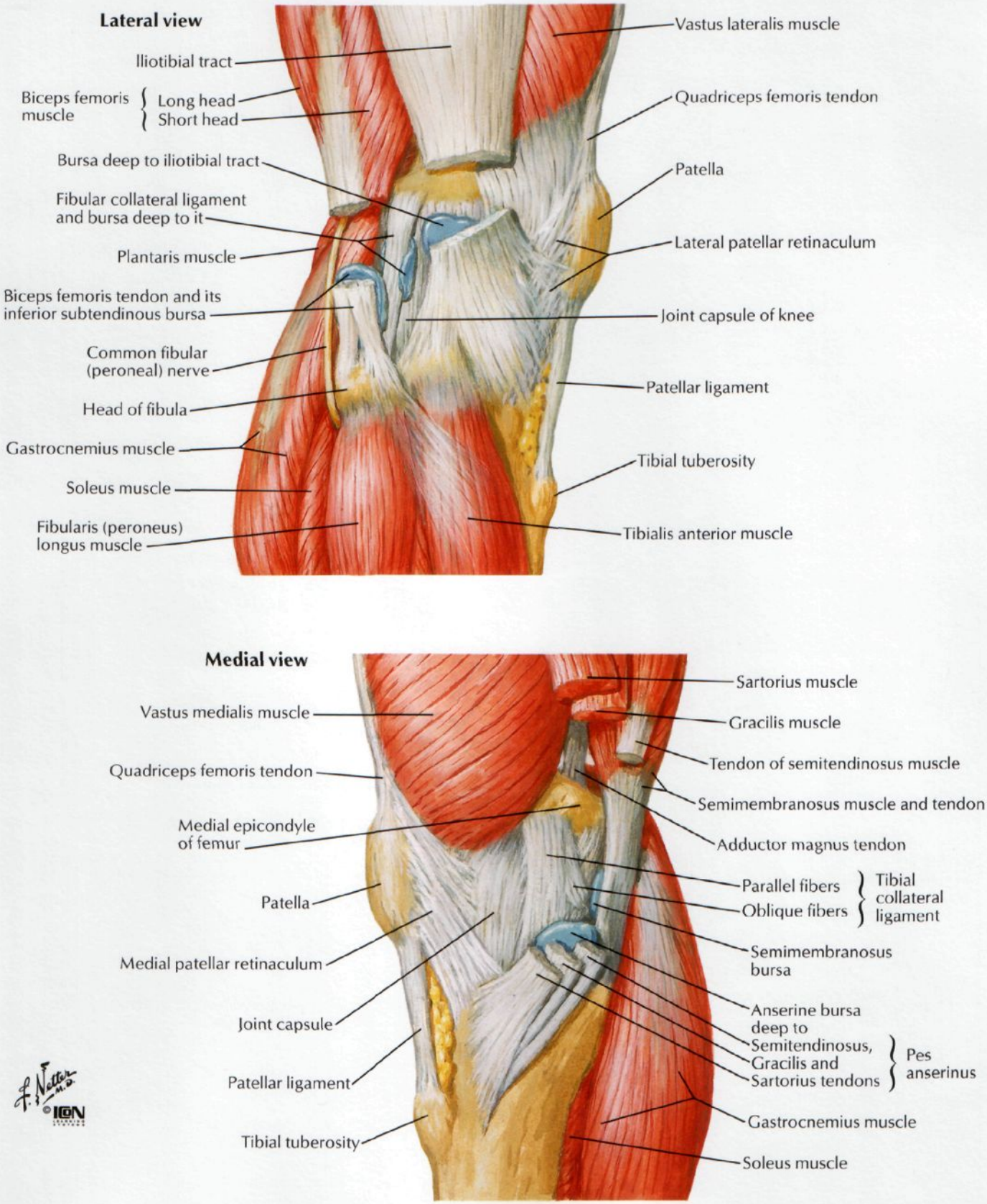

F. Netter M.D. ©IGN

Right knee in extension

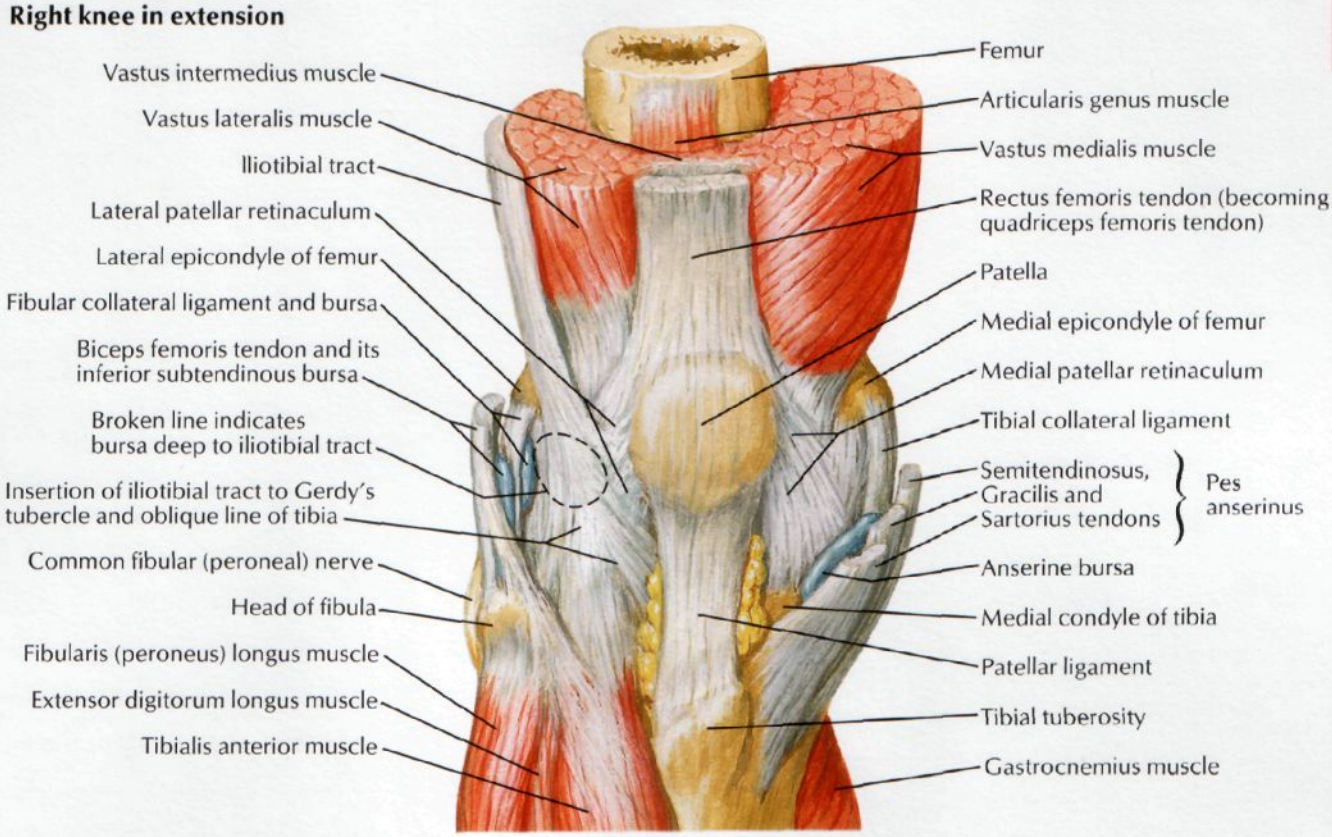

Joint opened, knee slightly in flexion

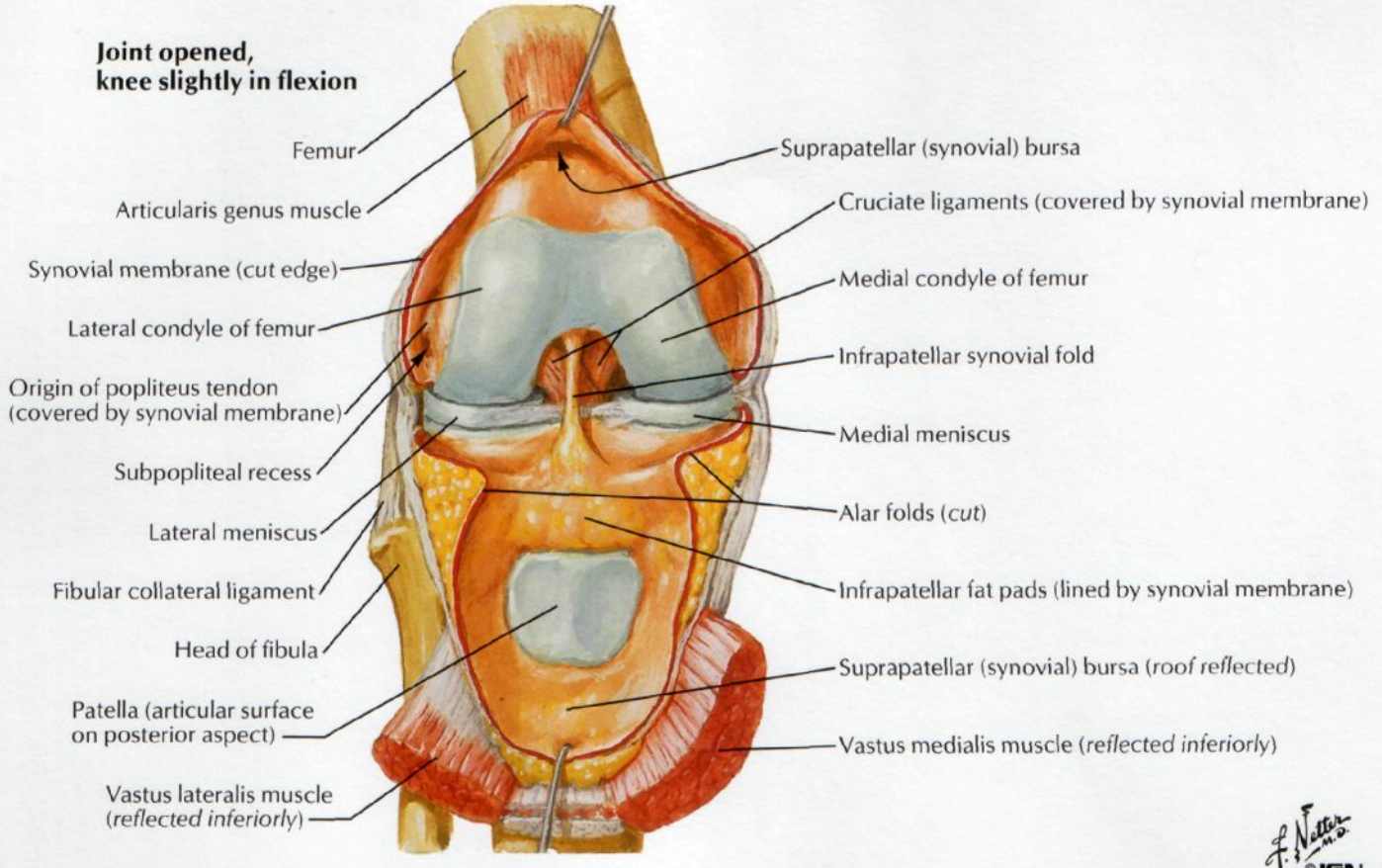

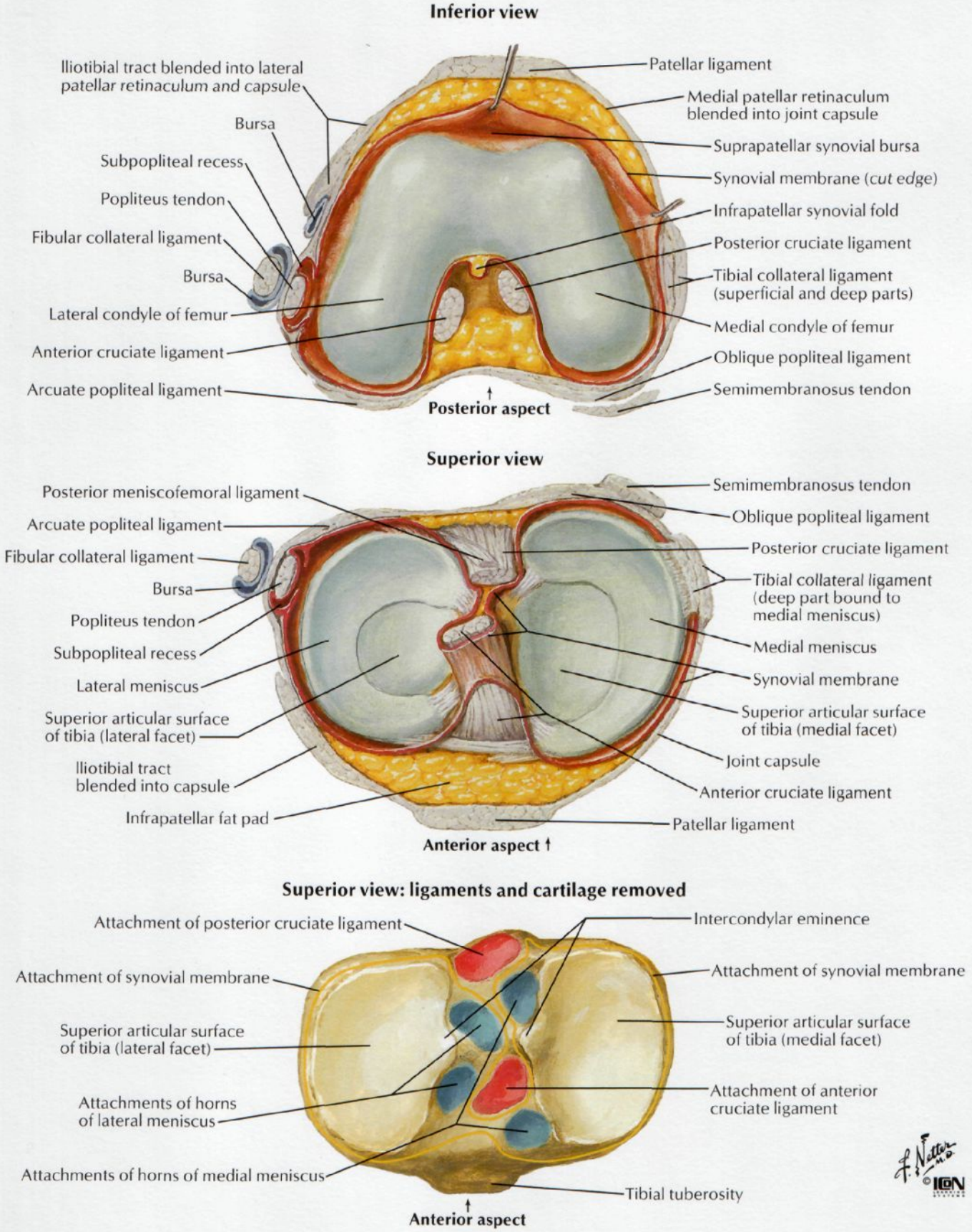
Inferior view
Iliotibial tract blended into lateral patellar retinaculum and capsule
Bursa
Subpopliteal recess
Popliteus tendon
Fibular collateral ligament
Bursa
Lateral condyle of femur
Anterior cruciate ligament
Arcuate popliteal ligament
Posterior aspect
Patellar ligament
Medial patellar retinaculum blended into joint capsule
Suprapatellar synovial bursa
Synovial membrane (cut edge)
Infrapatellar synovial fold
Posterior cruciate ligament
Tibial collateral ligament (superficial and deep parts)
Medial condyle of femur
Oblique popliteal ligament
Semimembranosus tendon
Superior view
Posterior meniscofemoral ligament
Arcuate popliteal ligament
Fibular collateral ligament
Bursa
Popliteus tendon
Subpopliteal recess
Lateral meniscus
Superior articular surface of tibia (lateral facet)
Iliotibial tract blended into capsule
Infrapatellar fat pad
Anterior aspect
Semimembranosus tendon
Oblique popliteal ligament
Posterior cruciate ligament
Tibial collateral ligament (deep part bound to medial meniscus)
Medial meniscus
Synovial membrane
Superior articular surface of tibia (medial facet)
Joint capsule
Anterior cruciate ligament
Patellar ligament
Superior view: ligaments and cartilage removed
Attachment of posterior cruciate ligament
Attachment of synovial membrane
Superior articular surface of tibia (lateral facet)
Attachments of horns of lateral meniscus
Attachments of horns of medial meniscus
Anterior aspect
Intercondylar eminence
Attachment of synovial membrane
Superior articular surface of tibia (medial facet)
Attachment of anterior cruciate ligament
Tibial tuberosity
F. Netter M.D.
©IGN

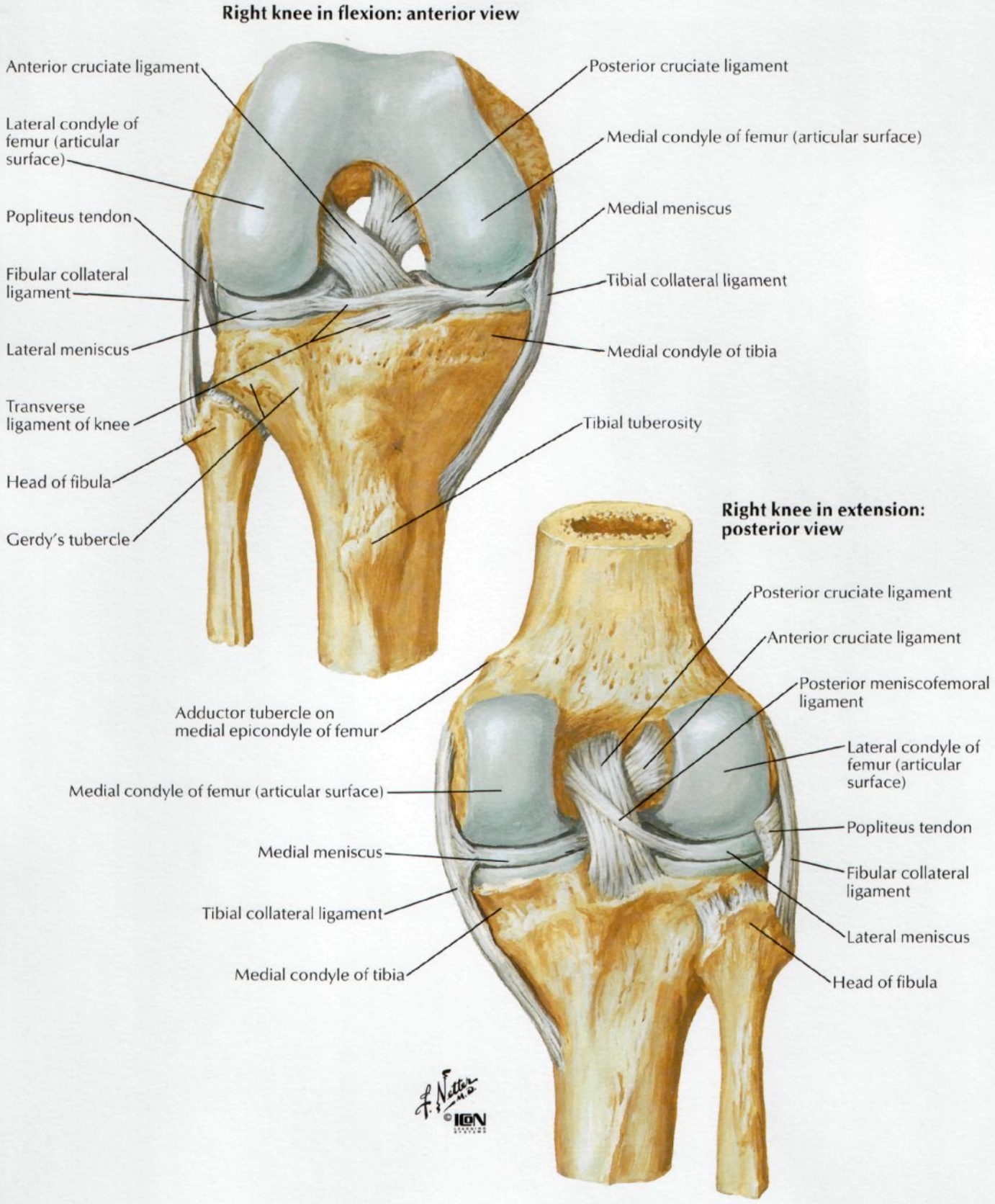
Right knee in flexion: anterior view
Anterior cruciate ligament
Posterior cruciate ligament
Lateral condyle of femur (articular surface)
Medial condyle of femur (articular surface)
Popliteus tendon
Medial meniscus
Fibular collateral ligament
Tibial collateral ligament
Lateral meniscus
Medial condyle of tibia
Transverse ligament of knee
Tibial tuberosity
Head of fibula
Gerdy's tubercle
Right knee in extension: posterior view
Posterior cruciate ligament
Anterior cruciate ligament
Posterior meniscofemoral ligament
Adductor tubercle on medial epicondyle of femur
Lateral condyle of femur (articular surface)
Medial condyle of femur (articular surface)
Popliteus tendon
Medial meniscus
Fibular collateral ligament
Tibial collateral ligament
Lateral meniscus
Medial condyle of tibia
Head of fibula
F. Netter M.D.
©ICON

Knee: Anteroposterior Radiograph

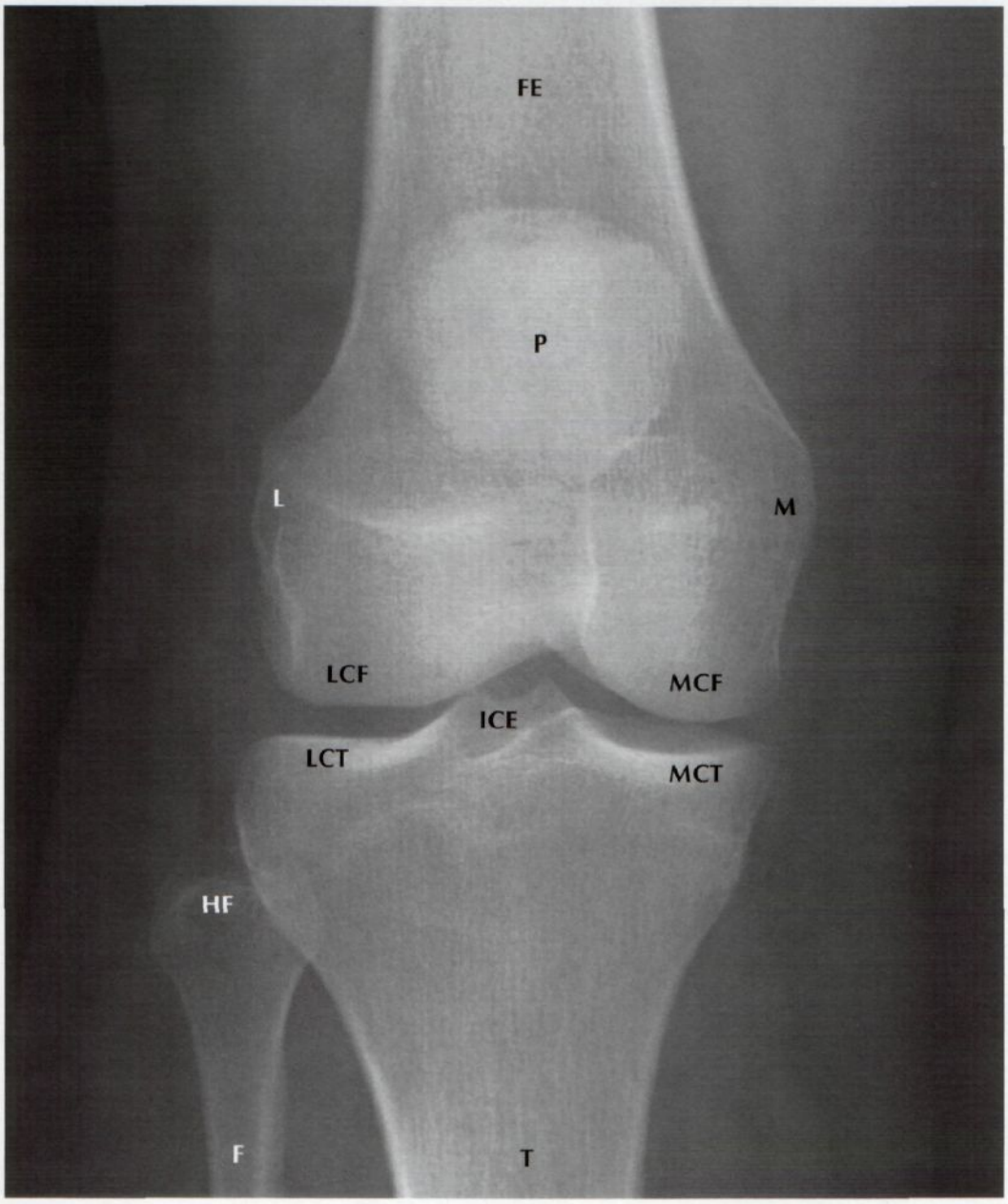

F	Fibula
FE	Femur
HF	Head of fibula
ICE	Intercondylar eminence
L	Lateral epicondyle
LCF	Lateral condyle of femur
LCT	Lateral condyle of tibia
M	Medial epicondyle
MCF	Medial condyle of femur
MCT	Medial condyle of tibia
P	Patella
T	Tibia

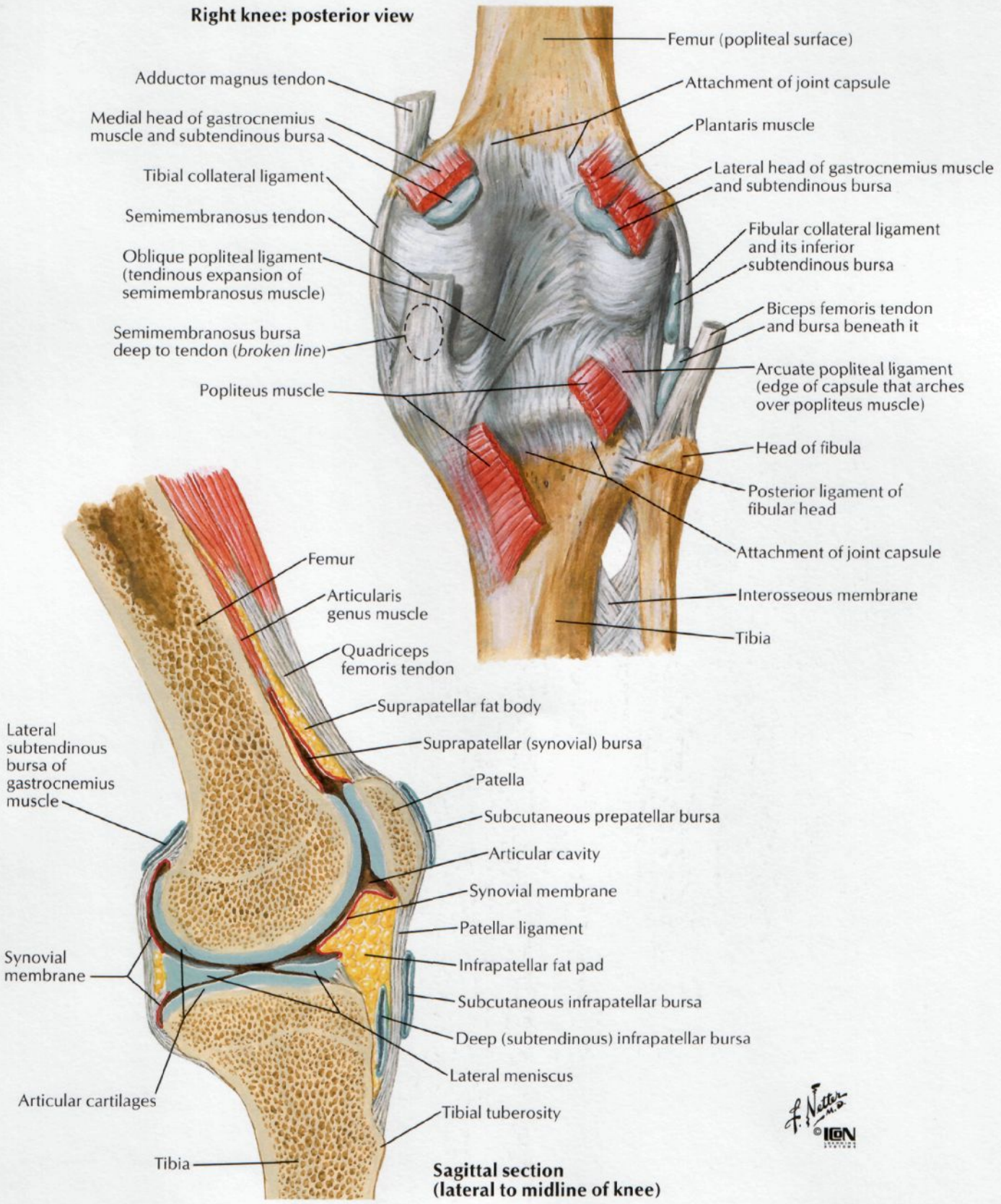
Right knee: posterior view
Femur (popliteal surface)
Adductor magnus tendon
Attachment of joint capsule
Medial head of gastrocnemius muscle and subtendinous bursa
Plantaris muscle
Tibial collateral ligament
Lateral head of gastrocnemius muscle and subtendinous bursa
Semimembranosus tendon
Fibular collateral ligament and its inferior subtendinous bursa
Oblique popliteal ligament (tendinous expansion of semimembranosus muscle)
Biceps femoris tendon and bursa beneath it
Semimembranosus bursa deep to tendon (broken line)
Arcuate popliteal ligament (edge of capsule that arches over popliteus muscle)
Popliteus muscle
Head of fibula
Posterior ligament of fibular head
Attachment of joint capsule
Interosseous membrane
Tibia
Femur
Articularis genus muscle
Quadriceps femoris tendon
Suprapatellar fat body
Lateral subtendinous bursa of gastrocnemius muscle
Suprapatellar (synovial) bursa
Patella
Subcutaneous prepatellar bursa
Articular cavity
Synovial membrane
Patellar ligament
Synovial membrane
Infrapatellar fat pad
Subcutaneous infrapatellar bursa
Deep (subtendinous) infrapatellar bursa
Lateral meniscus
Articular cartilages
Tibial tuberosity
Tibia
Sagittal section (lateral to midline of knee)

Arteries of Thigh and Knee: Schema

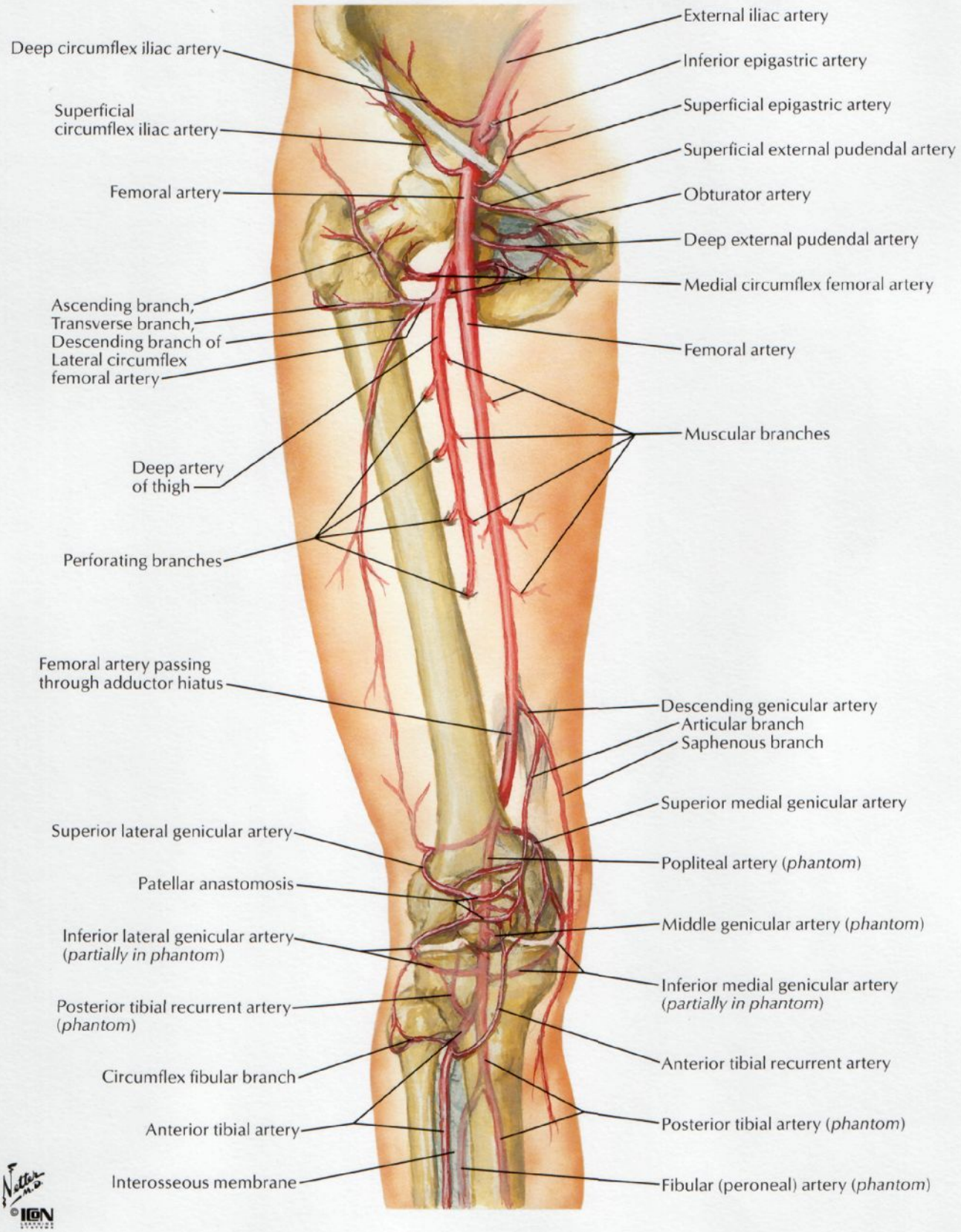

F. Netter M.D.
©IGN

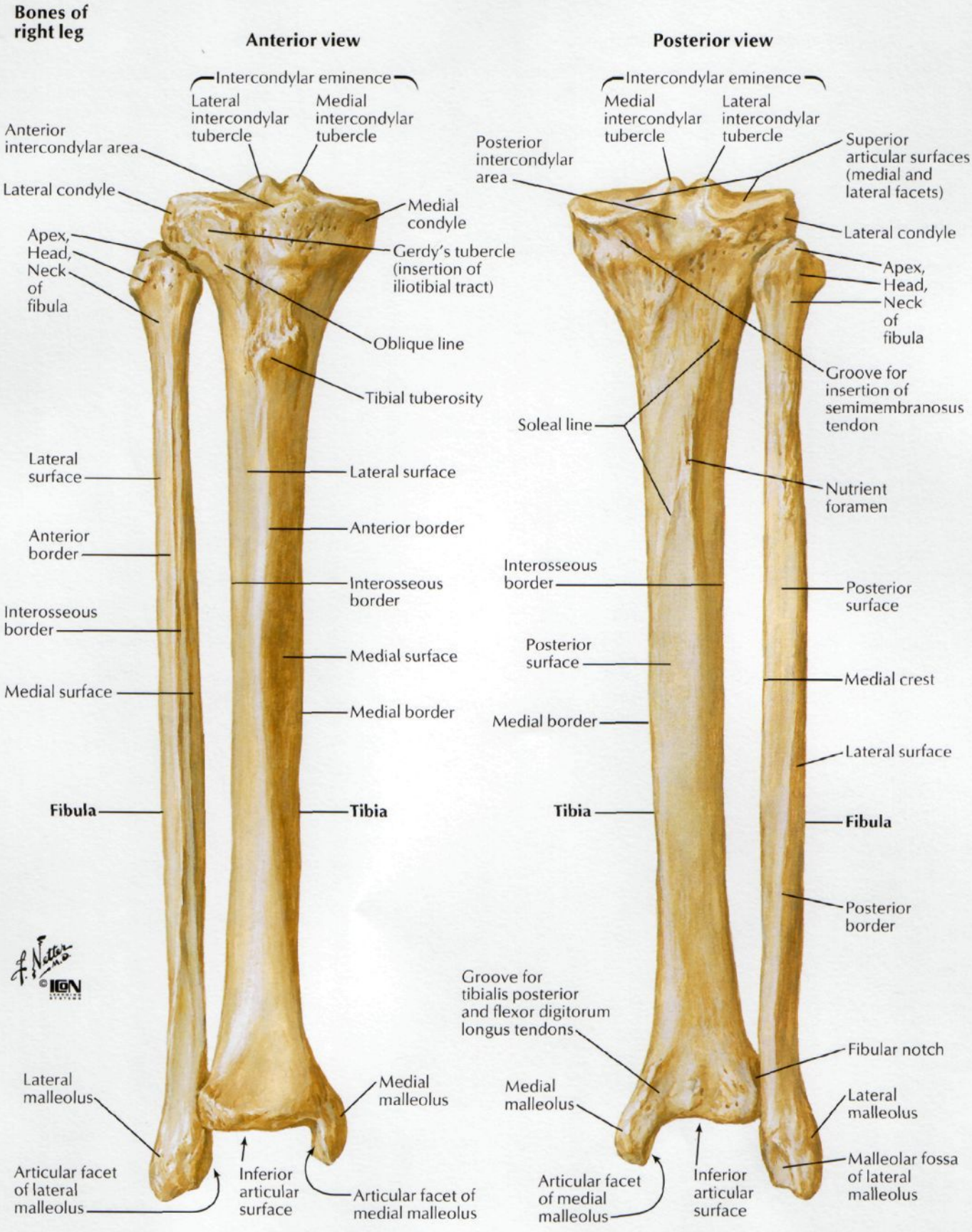
Bones of right leg
Anterior view
Intercondylar eminence
Lateral intercondylar tubercle
Medial intercondylar tubercle
Anterior intercondylar area
Lateral condyle
Medial condyle
Apex, Head, Neck of fibula
Gerdy's tubercle (insertion of iliotibial tract)
Oblique line
Tibial tuberosity
Lateral surface
Lateral surface
Anterior border
Anterior border
Interosseous border
Interosseous border
Medial surface
Medial surface
Medial border
Fibula
Tibia
Lateral malleolus
Medial malleolus
Articular facet of lateral malleolus
Inferior articular surface
Articular facet of medial malleolus
Posterior view
Intercondylar eminence
Medial intercondylar tubercle
Lateral intercondylar tubercle
Posterior intercondylar area
Superior articular surfaces (medial and lateral facets)
Lateral condyle
Apex, Head, Neck of fibula
Groove for insertion of semimembranosus tendon
Soleal line
Nutrient foramen
Interosseous border
Posterior surface
Posterior surface
Medial crest
Medial border
Lateral surface
Tibia
Fibula
Posterior border
Groove for tibialis posterior and flexor digitorum longus tendons
Fibular notch
Medial malleolus
Lateral malleolus
Malleolar fossa of lateral malleolus
Articular facet of medial malleolus
Inferior articular surface

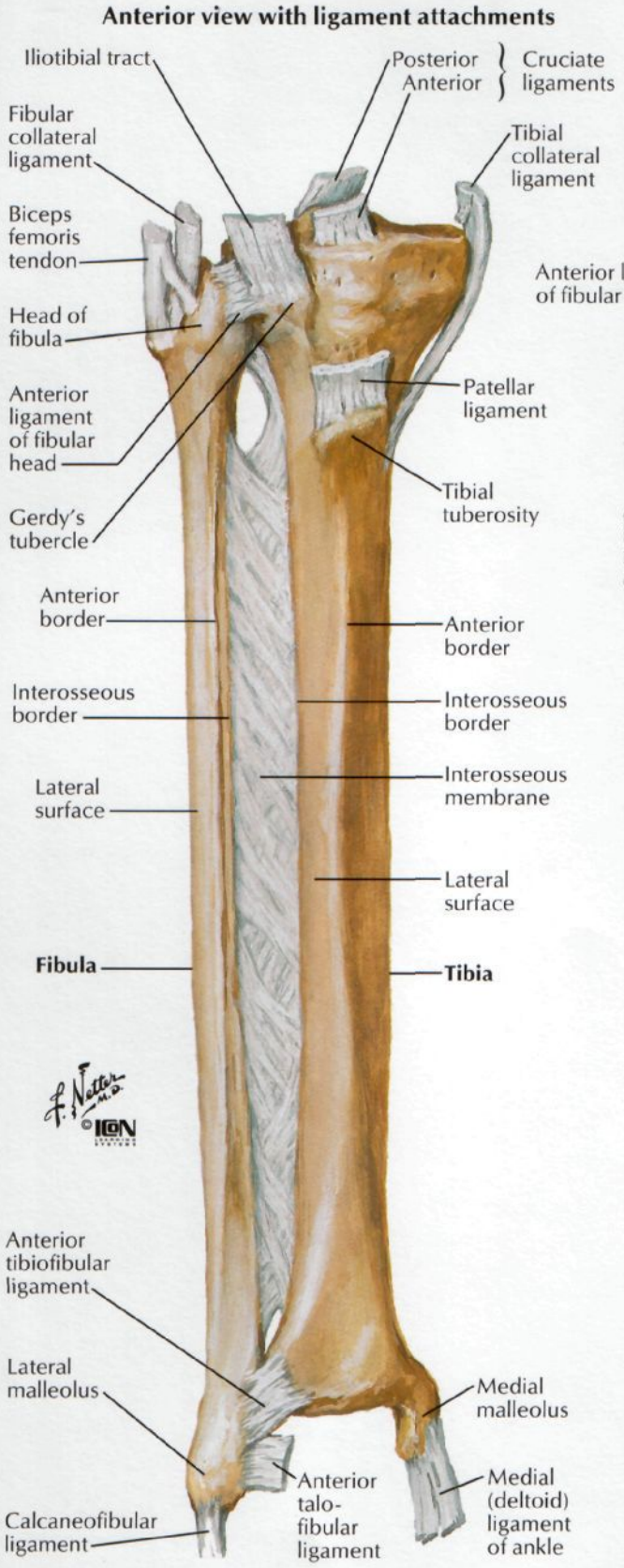
Anterior view with ligament attachments
Iliotibial tract
Posterior
Anterior
Cruciate ligaments
Fibular collateral ligament
Tibial collateral ligament
Biceps femoris tendon
Head of fibula
Anterior ligament of fibular head
Gerdy's tubercle
Patellar ligament
Tibial tuberosity
Anterior border
Anterior border
Interosseous border
Interosseous border
Interosseous membrane
Lateral surface
Lateral surface
Fibula
Tibia
Anterior tibiofibular ligament
Lateral malleolus
Medial malleolus
Anterior talo-fibular ligament
Medial (deltoid) ligament of ankle
Calcaneofibular ligament

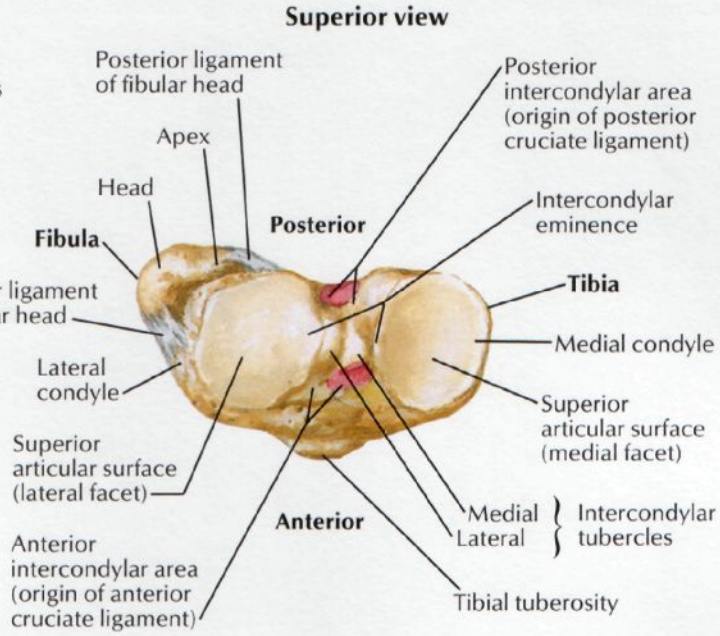
Superior view
Posterior ligament of fibular head
Apex
Head
Fibula
Posterior
Posterior intercondylar area (origin of posterior cruciate ligament)
Intercondylar eminence
Tibia
Anterior ligament of fibular head
Medial condyle
Lateral condyle
Superior articular surface (medial facet)
Superior articular surface (lateral facet)
Anterior
Medial
Lateral
Intercondylar tubercles
Anterior intercondylar area (origin of anterior cruciate ligament)
Tibial tuberosity

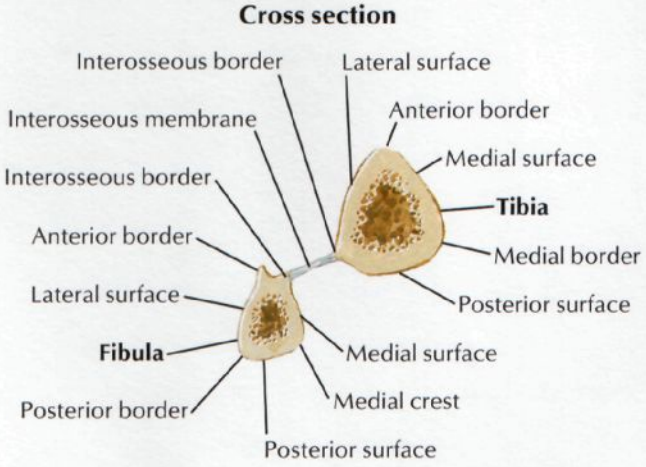
Cross section
Interosseous border
Lateral surface
Interosseous membrane
Anterior border
Medial surface
Interosseous border
Tibia
Anterior border
Medial border
Lateral surface
Posterior surface
Fibula
Medial surface
Medial crest
Posterior border
Posterior surface

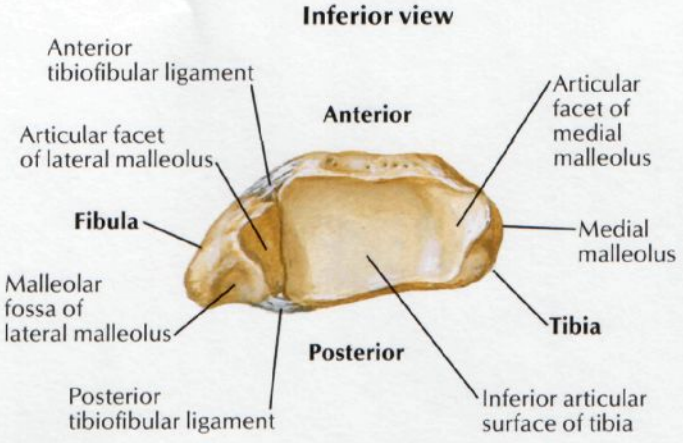
Inferior view
Anterior tibiofibular ligament
Anterior
Articular facet of medial malleolus
Articular facet of lateral malleolus
Fibula
Medial malleolus
Malleolar fossa of lateral malleolus
Tibia
Posterior
Posterior tibiofibular ligament
Inferior articular surface of tibia

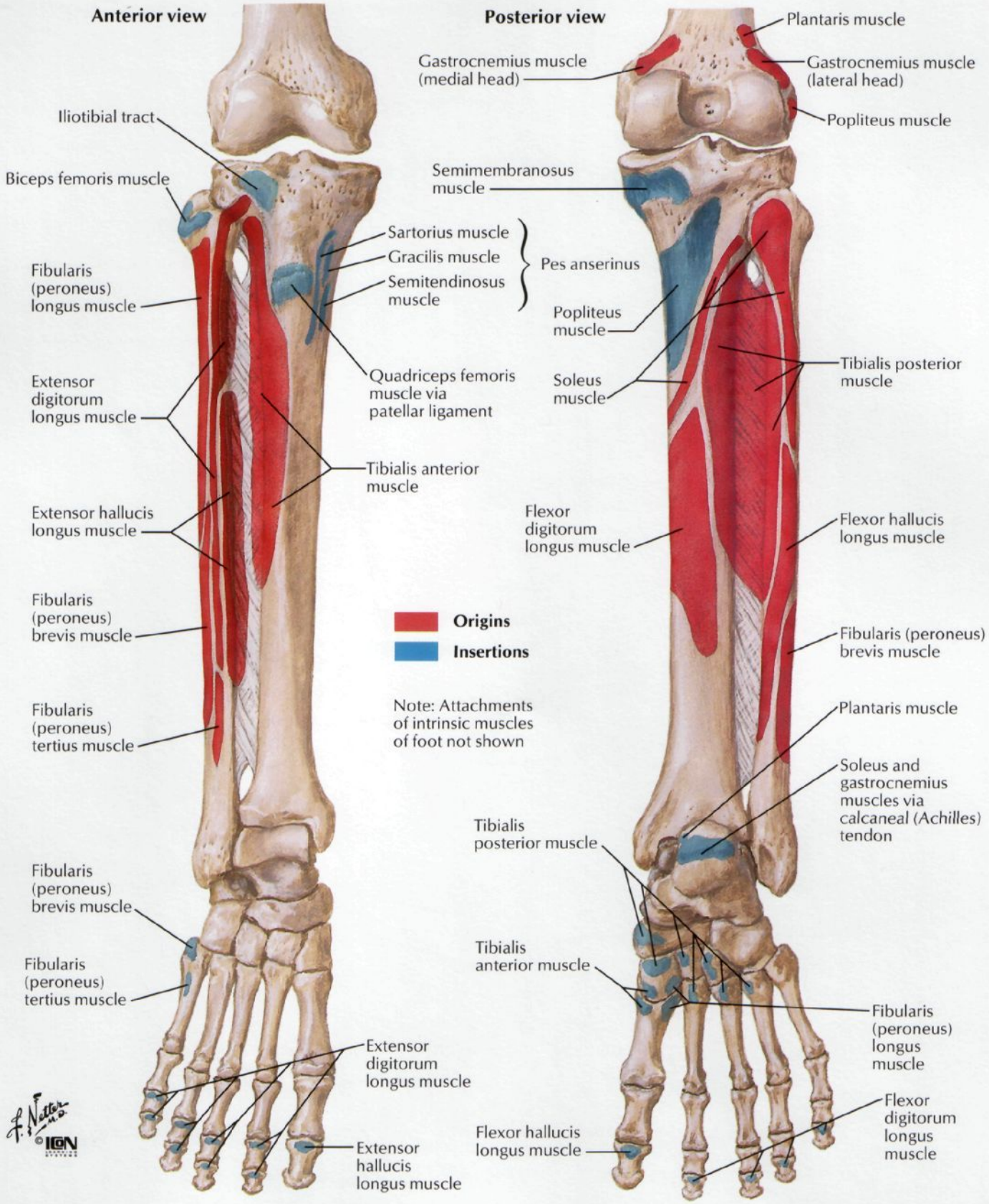
Anterior view
Posterior view
Iliotibial tract
Biceps femoris muscle
Fibularis (peroneus) longus muscle
Extensor digitorum longus muscle
Extensor hallucis longus muscle
Fibularis (peroneus) brevis muscle
Fibularis (peroneus) tertius muscle
Fibularis (peroneus) brevis muscle
Fibularis (peroneus) tertius muscle
Extensor digitorum longus muscle
Extensor hallucis longus muscle
Sartorius muscle
Gracilis muscle
Semitendinosus muscle
Pes anserinus
Quadriceps femoris muscle via patellar ligament
Tibialis anterior muscle
Origins
Insertions
Note: Attachments of intrinsic muscles of foot not shown
Gastrocnemius muscle (medial head)
Plantaris muscle
Gastrocnemius muscle (lateral head)
Popliteus muscle
Semimembranosus muscle
Popliteus muscle
Soleus muscle
Tibialis posterior muscle
Flexor digitorum longus muscle
Flexor hallucis longus muscle
Fibularis (peroneus) brevis muscle
Plantaris muscle
Soleus and gastrocnemius muscles via calcaneal (Achilles) tendon
Tibialis posterior muscle
Tibialis anterior muscle
Fibularis (peroneus) longus muscle
Flexor digitorum longus muscle
Flexor hallucis longus muscle
F. Netter M.D.
©IGN

Muscles of Leg (Superficial Dissection): Posterior View

SEE ALSO PLATE 522

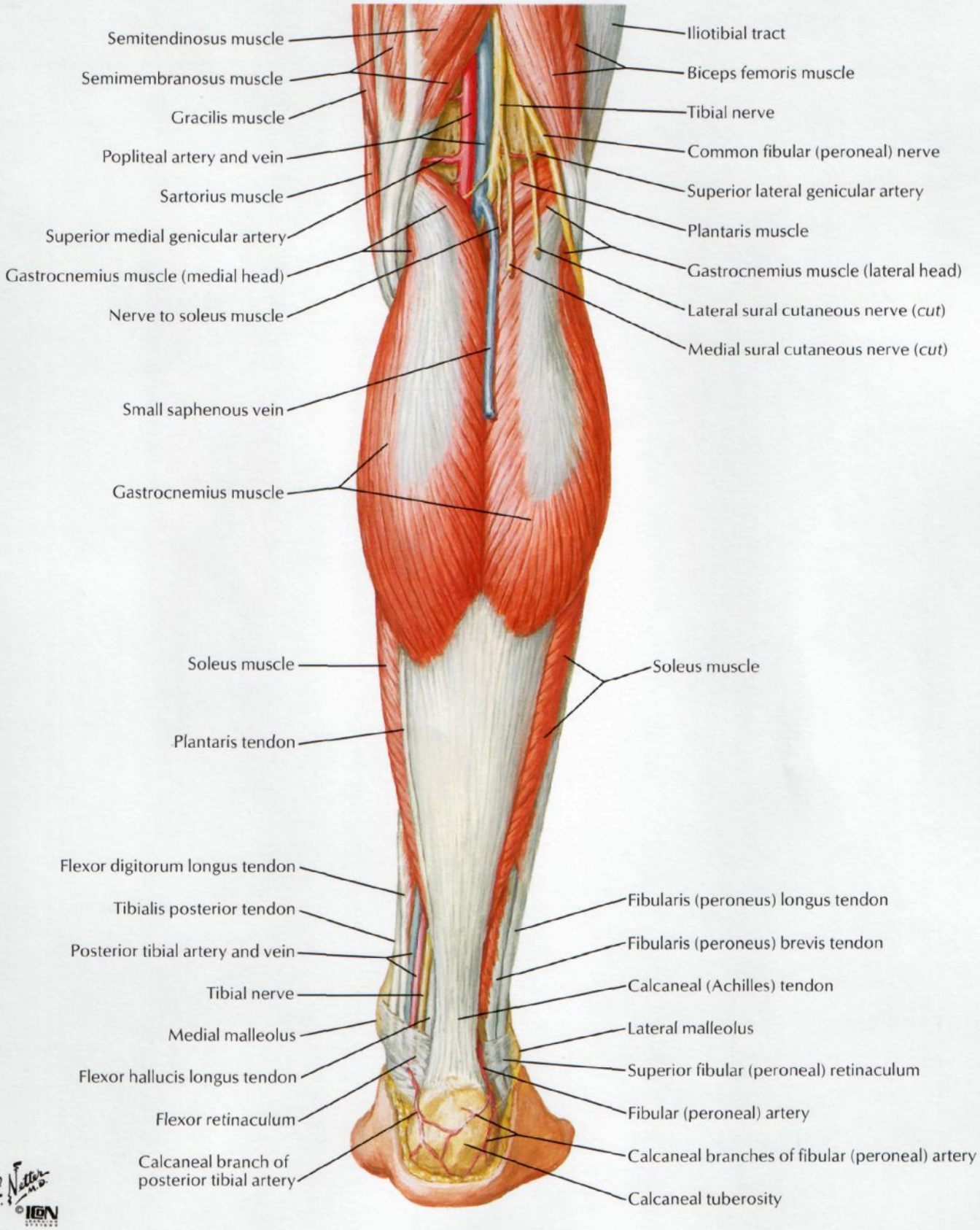

Muscles of Leg (Intermediate Dissection): Posterior View

SEE ALSO PLATE 523

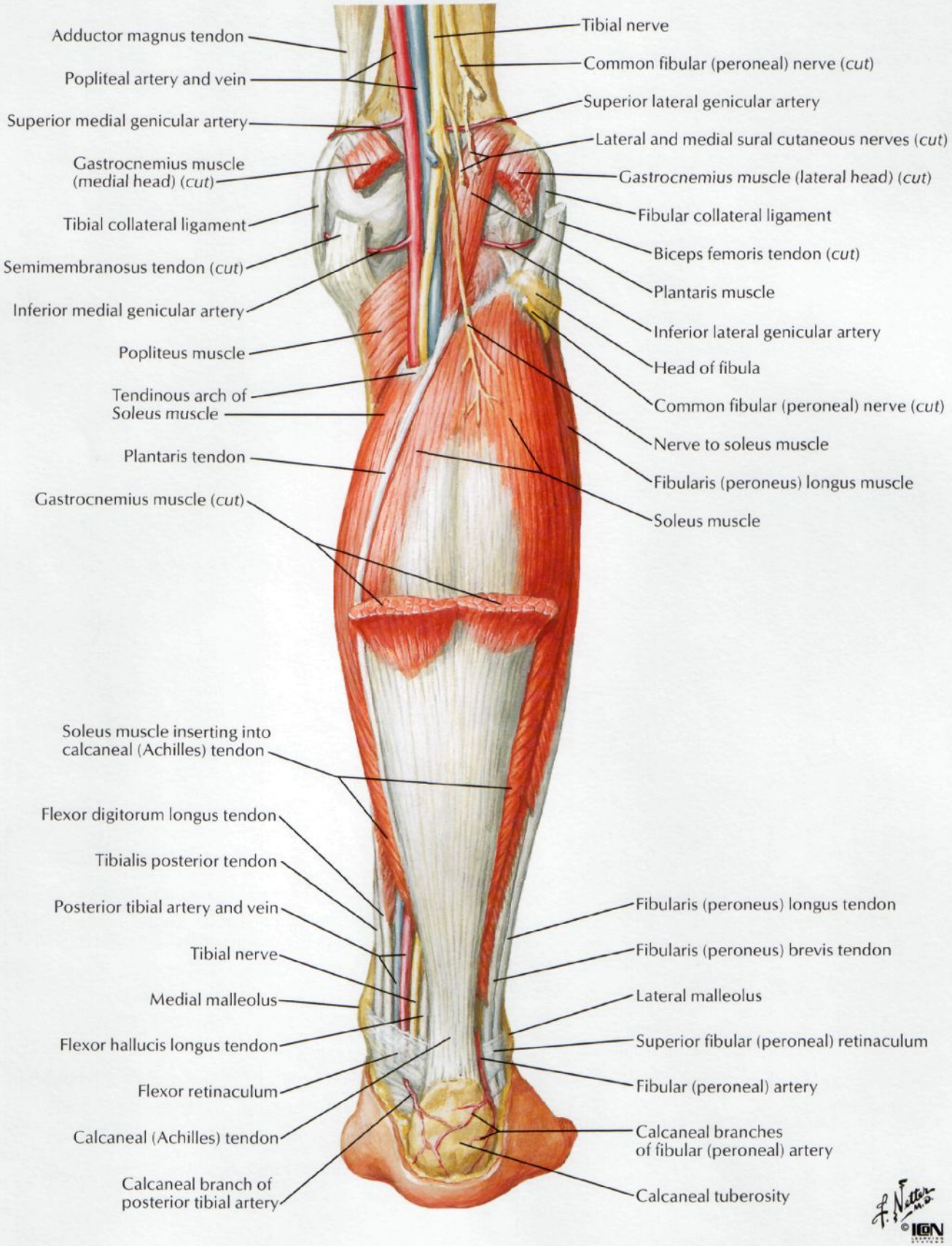

Muscles of Leg (Deep Dissection): Posterior View

SEE ALSO PLATE 523

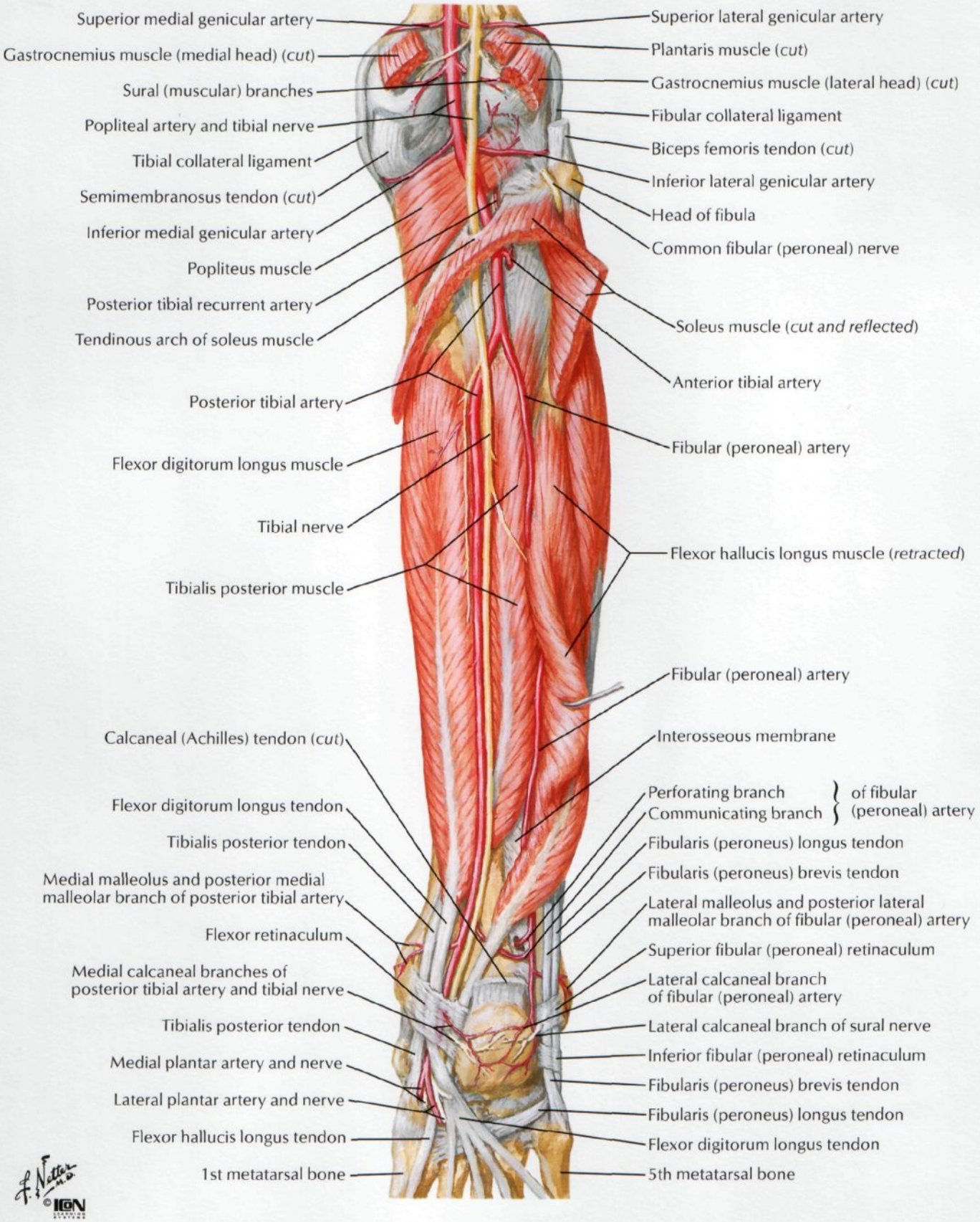

F. Netter M.D.
©IGN

Muscles of Leg (Superficial Dissection): Anterior View

SEE ALSO PLATE 524

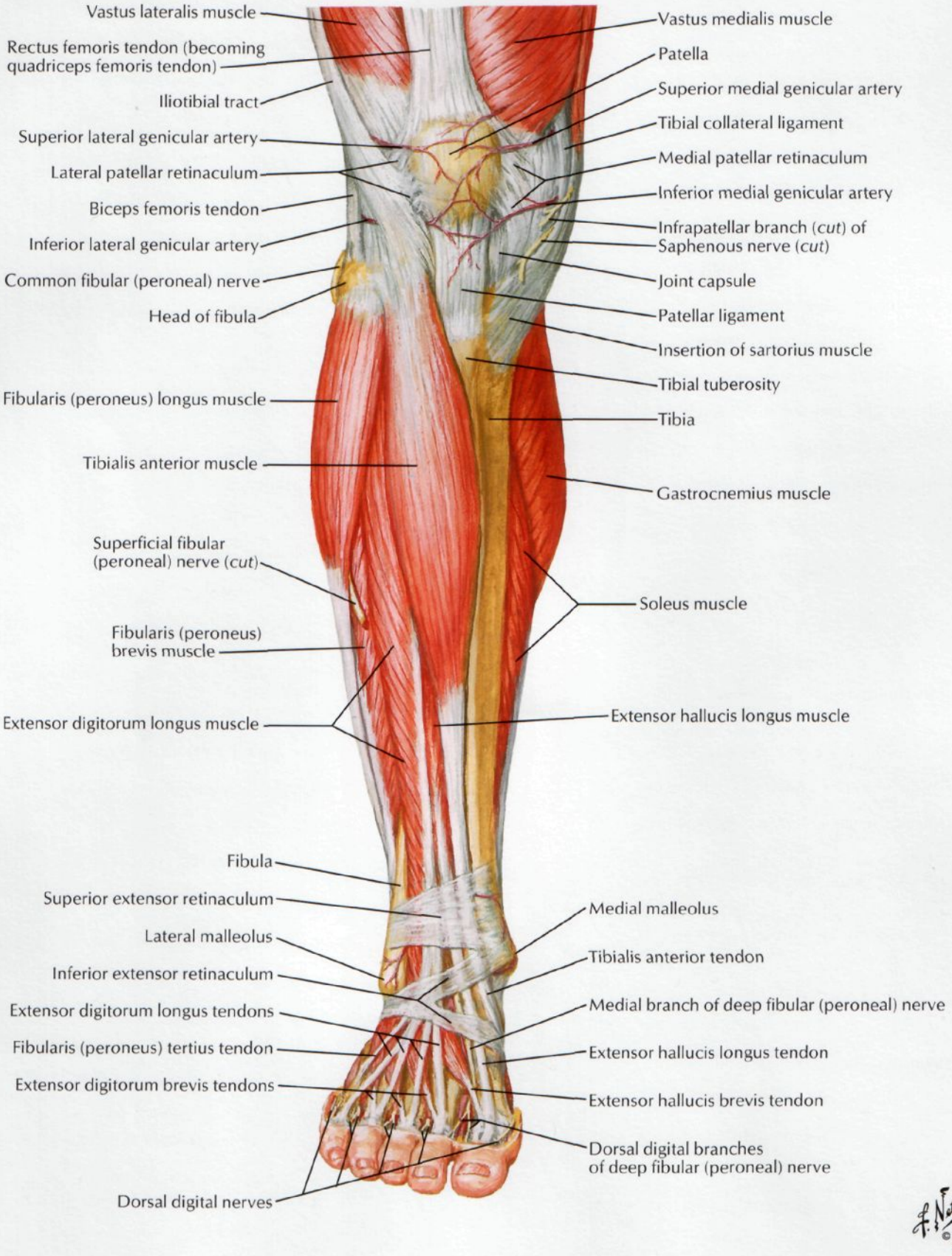

F. Netter M.D.
©IGN

Muscles of Leg (Deep Dissection): Anterior View

SEE ALSO PLATE 524

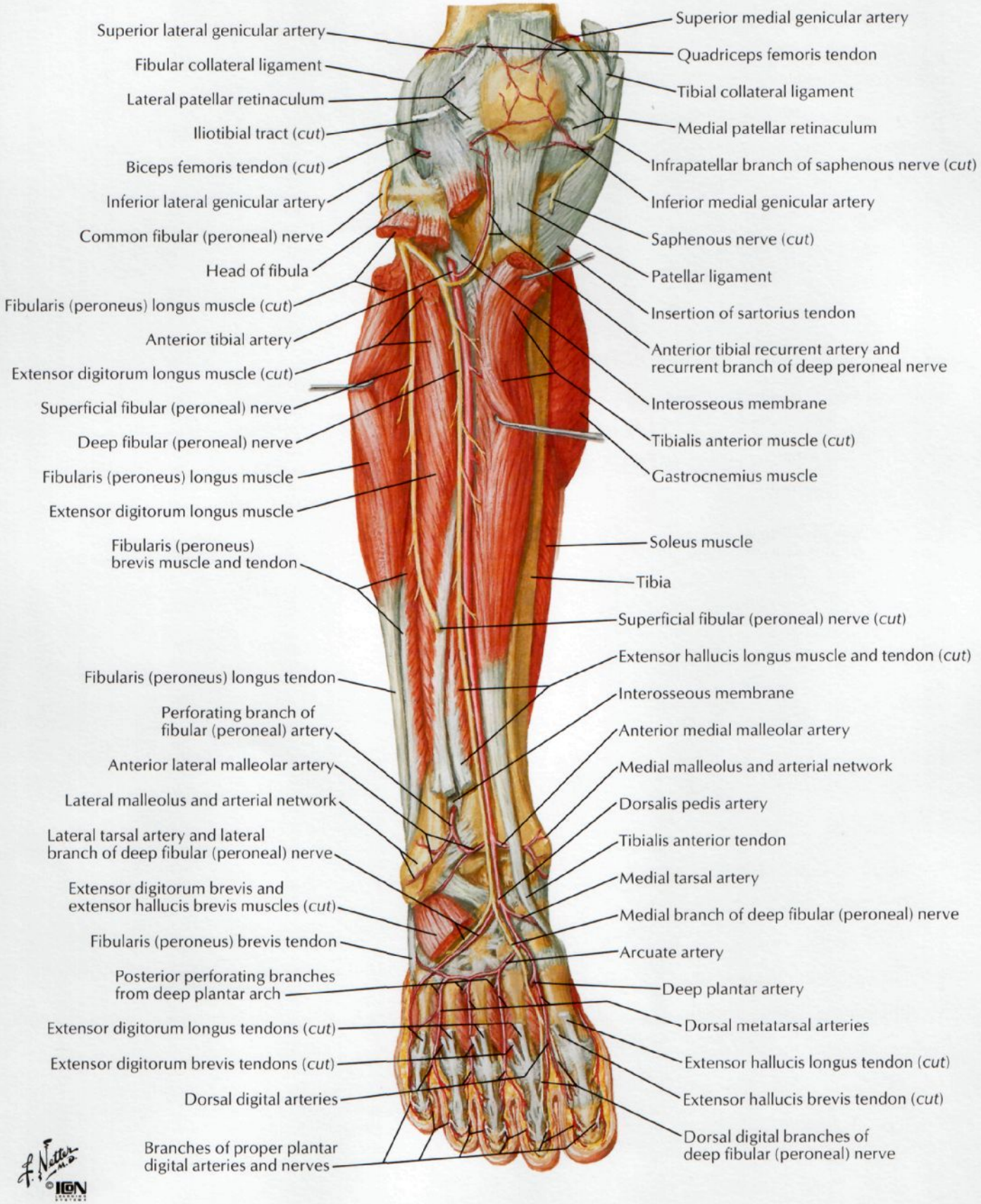

F. Netter M.D.
©IGN

SEE ALSO PLATE 524

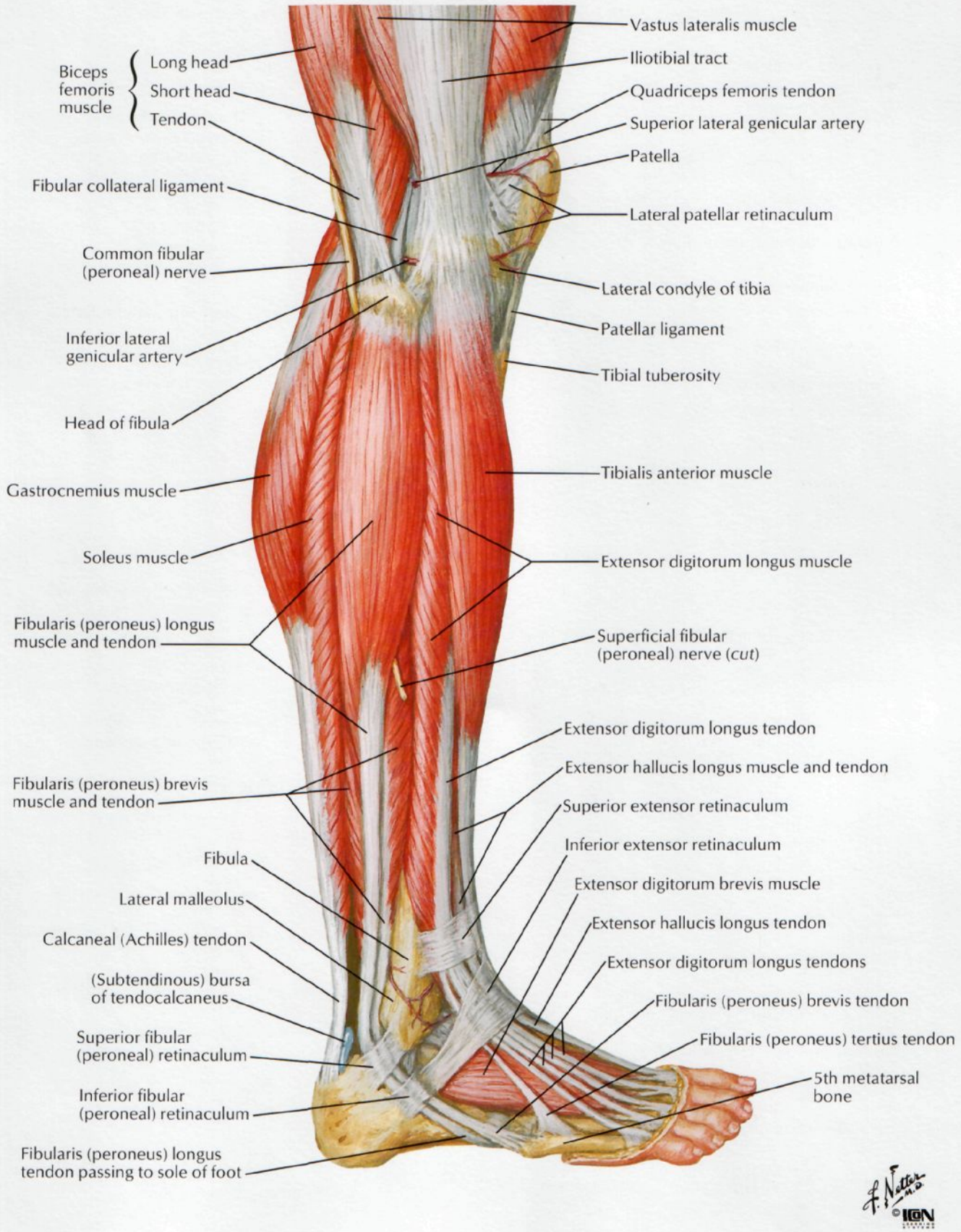

F. Netter M.D.
©IGN

Leg: Cross Sections and Fascial Compartments

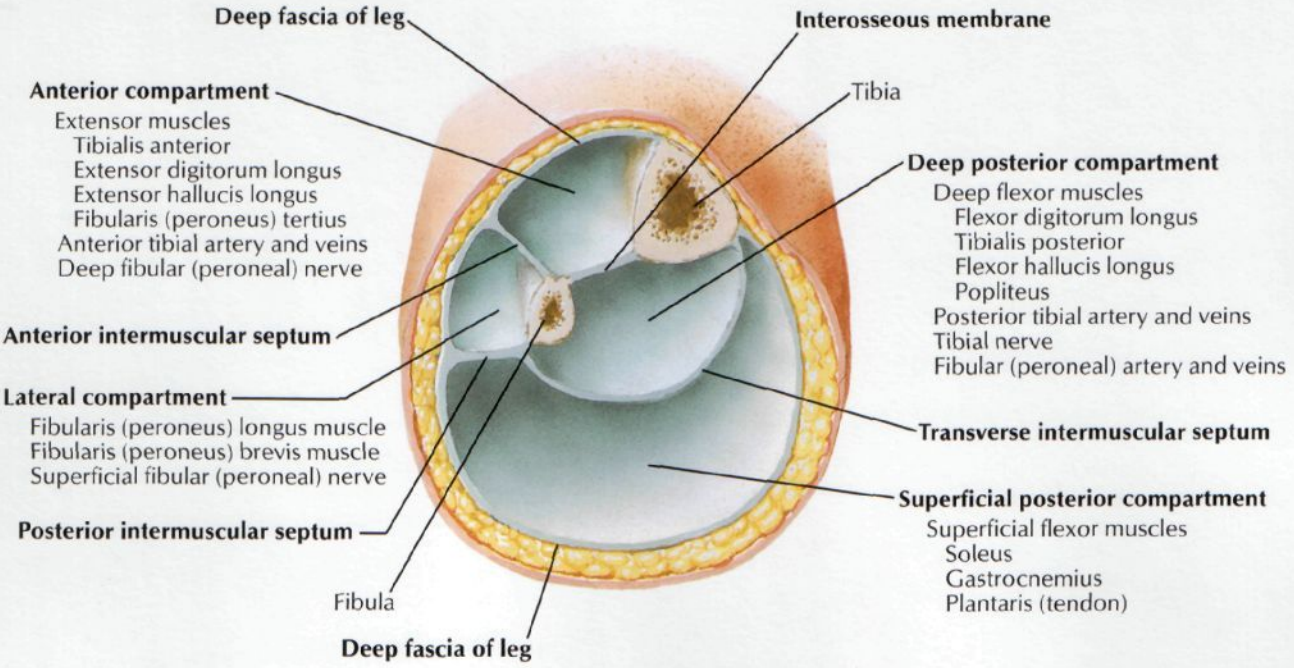

Cross section just above middle of leg

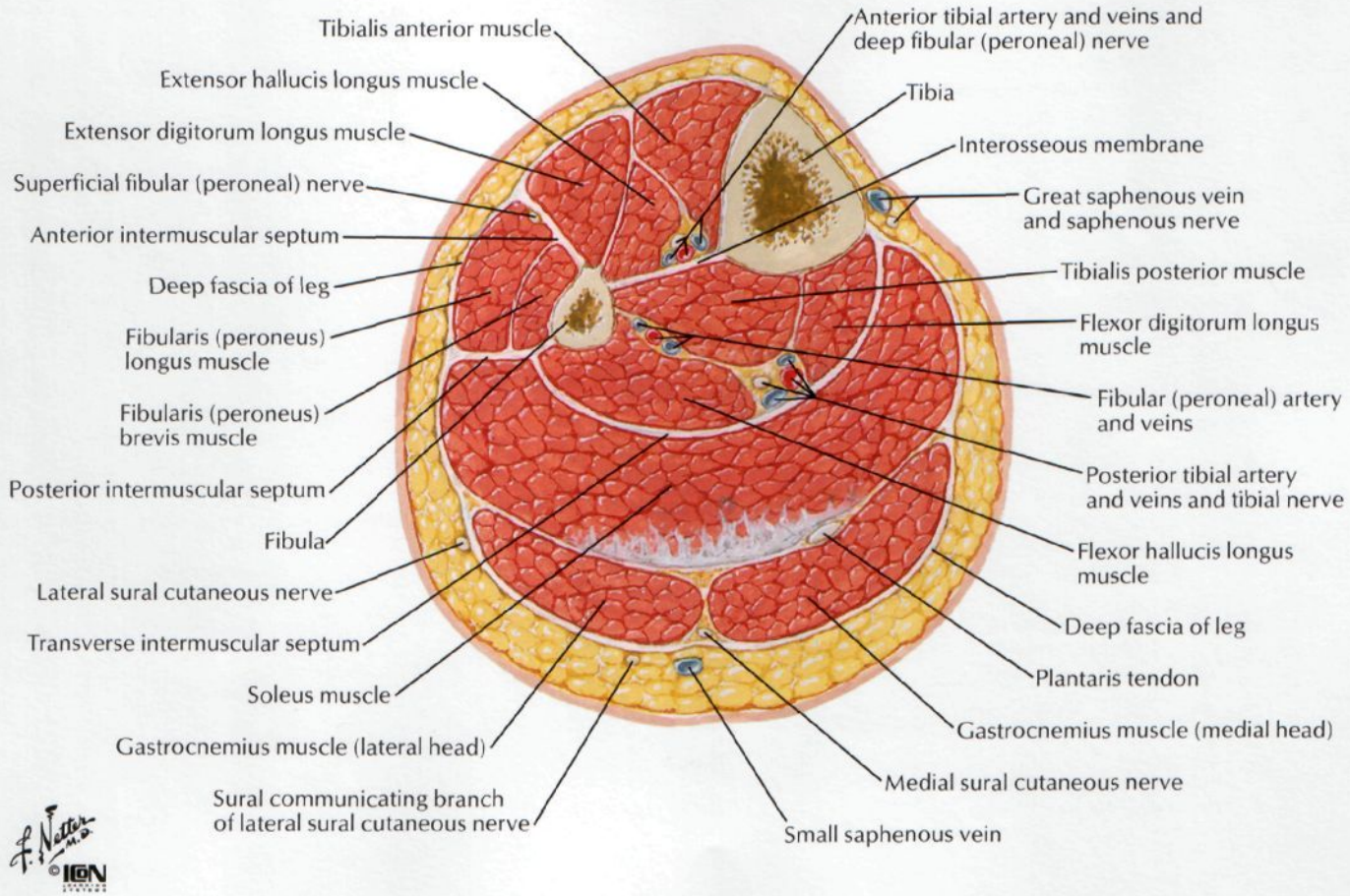

©IGN

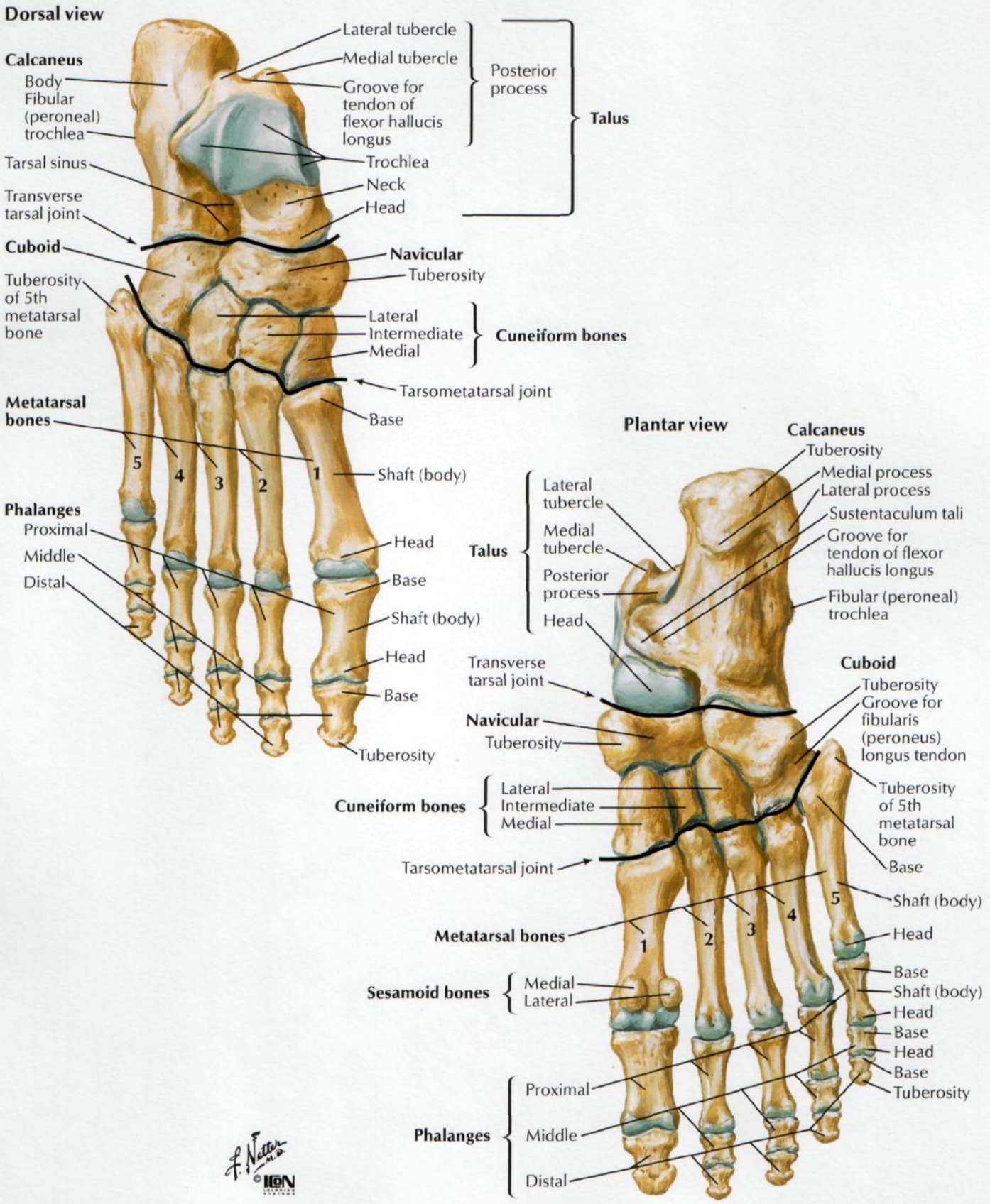
Dorsal view
Calcaneus
Body
Fibular (peroneal) trochlea
Tarsal sinus
Transverse tarsal joint
Cuboid
Tuberosity of 5th metatarsal bone
Metatarsal bones
5
4
3
2
1
Phalanges
Proximal
Middle
Distal
Lateral tubercle
Medial tubercle
Groove for tendon of flexor hallucis longus
Posterior process
Talus
Trochlea
Neck
Head
Navicular
Tuberosity
Lateral
Intermediate
Medial
Cuneiform bones
Tarsometatarsal joint
Base
Shaft (body)
Head
Base
Shaft (body)
Head
Base
Tuberosity
Plantar view
Calcaneus
Tuberosity
Medial process
Lateral process
Sustentaculum tali
Groove for tendon of flexor hallucis longus
Fibular (peroneal) trochlea
Talus
Lateral tubercle
Medial tubercle
Posterior process
Head
Transverse tarsal joint
Cuboid
Tuberosity
Groove for fibularis (peroneus) longus tendon
Navicular
Tuberosity
Cuneiform bones
Lateral
Intermediate
Medial
Tuberosity of 5th metatarsal bone
Base
Tarsometatarsal joint
Shaft (body)
Metatarsal bones
1
2
3
4
5
Head
Base
Sesamoid bones
Medial
Lateral
Shaft (body)
Head
Base
Head
Base
Tuberosity
Phalanges
Proximal
Middle
Distal
F. Netter M.D.
©IGN

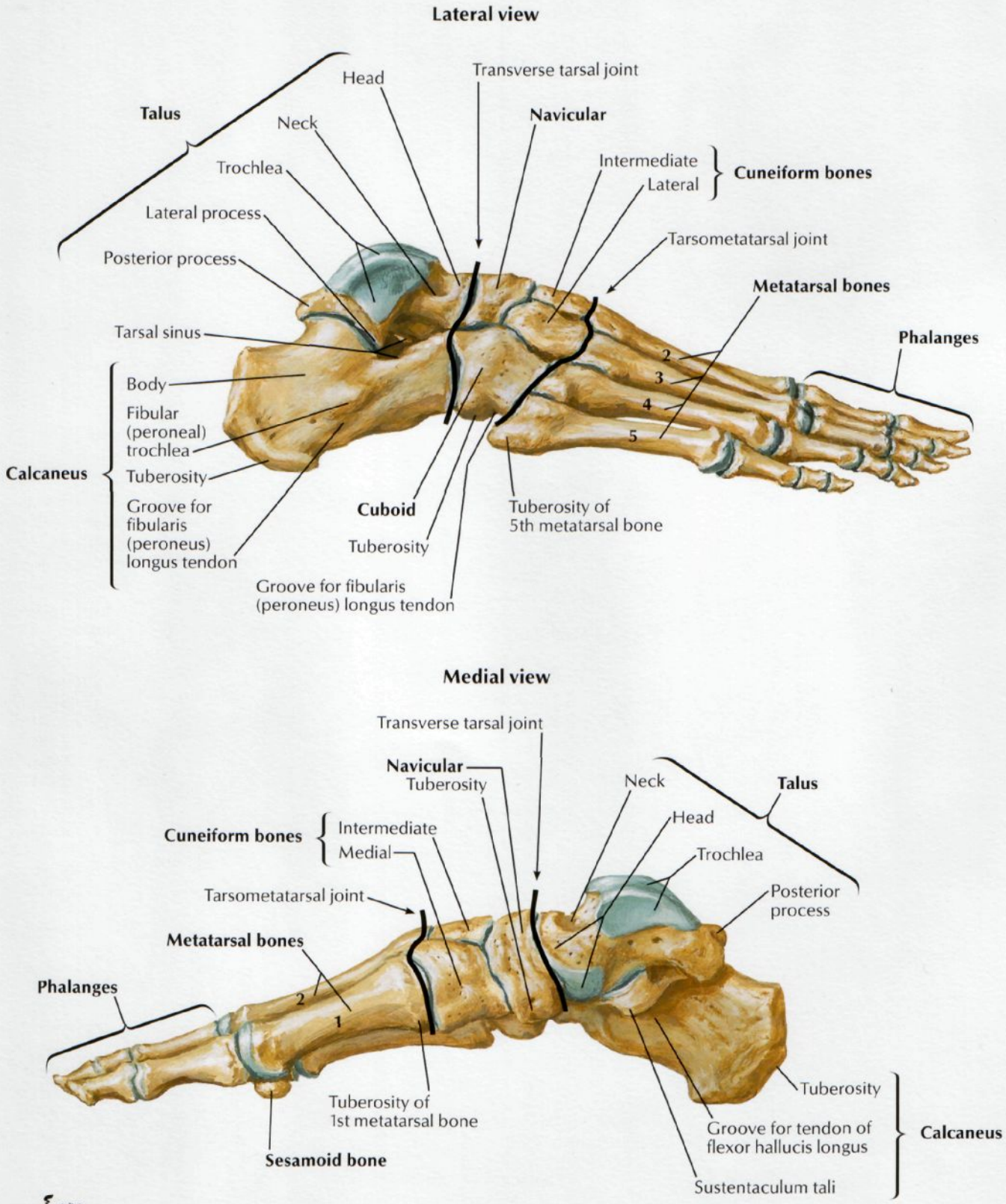
Lateral view
Talus
Head
Neck
Trochlea
Lateral process
Posterior process
Tarsal sinus
Transverse tarsal joint
Navicular
Intermediate
Lateral
Cuneiform bones
Tarsometatarsal joint
Metatarsal bones
Phalanges
2
3
4
5
Calcaneus
Body
Fibular (peroneal) trochlea
Tuberosity
Groove for fibularis (peroneus) longus tendon
Cuboid
Tuberosity
Groove for fibularis (peroneus) longus tendon
Tuberosity of 5th metatarsal bone
Medial view
Transverse tarsal joint
Navicular
Tuberosity
Cuneiform bones
Intermediate
Medial
Tarsometatarsal joint
Metatarsal bones
Phalanges
2
1
Tuberosity of 1st metatarsal bone
Sesamoid bone
Neck
Talus
Head
Trochlea
Posterior process
Tuberosity
Groove for tendon of flexor hallucis longus
Sustentaculum tali
Calcaneus

Right foot

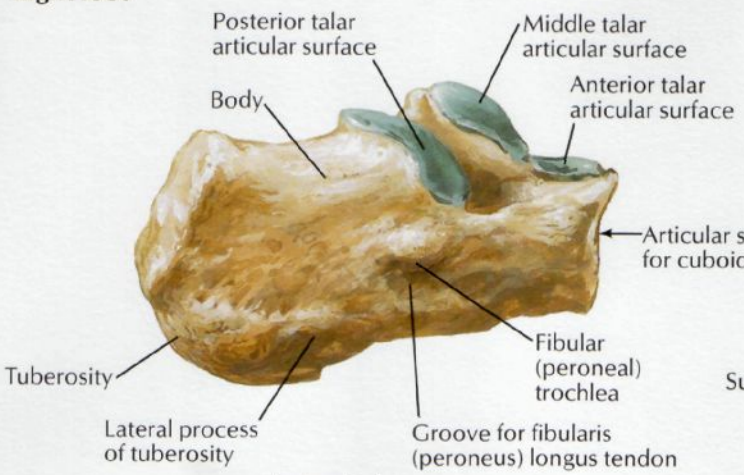

Lateral view

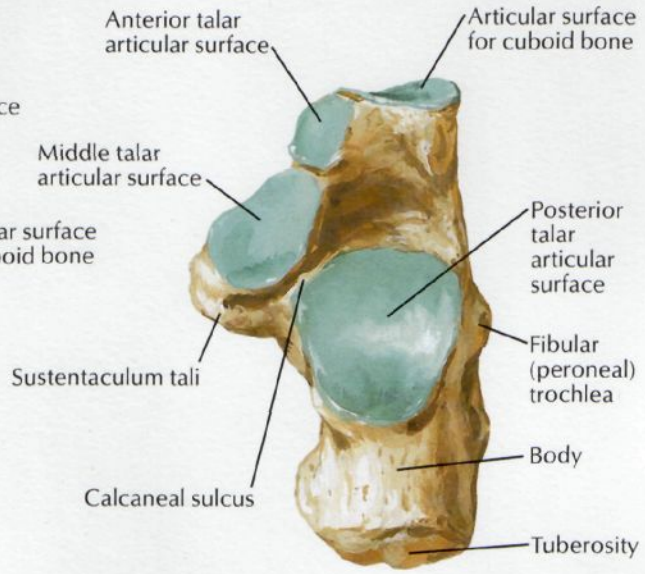

Superior view

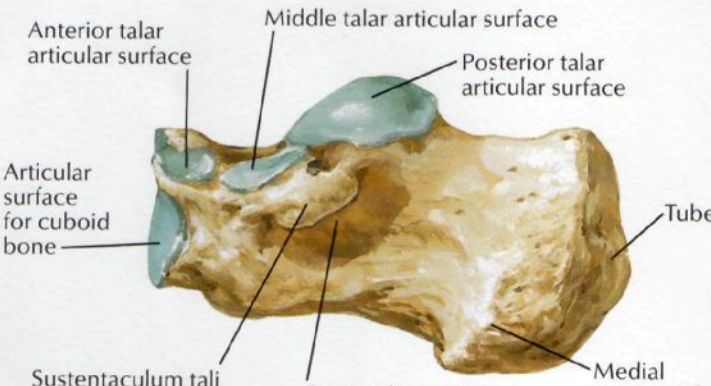

Medial view

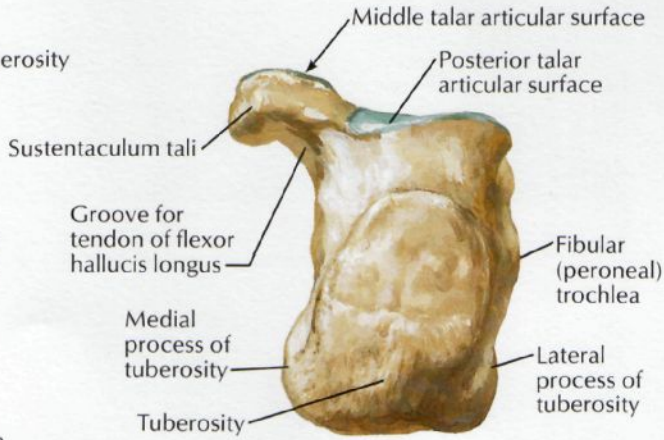

Posterior view

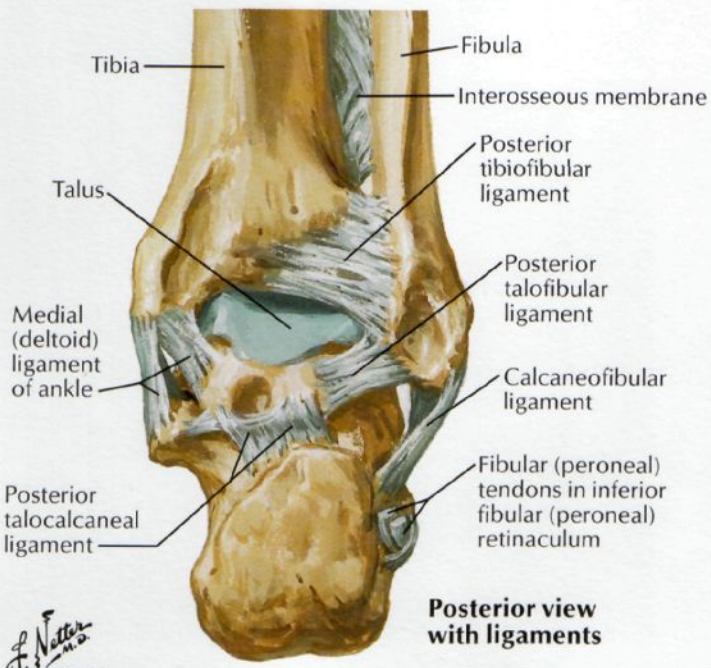

Posterior view with ligaments

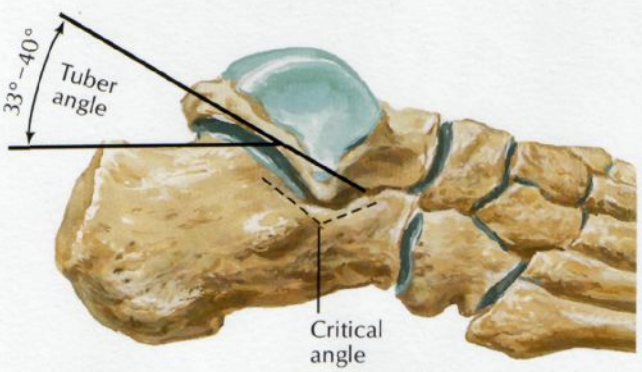

Functional relations of calcaneus

Ankle: Radiographs

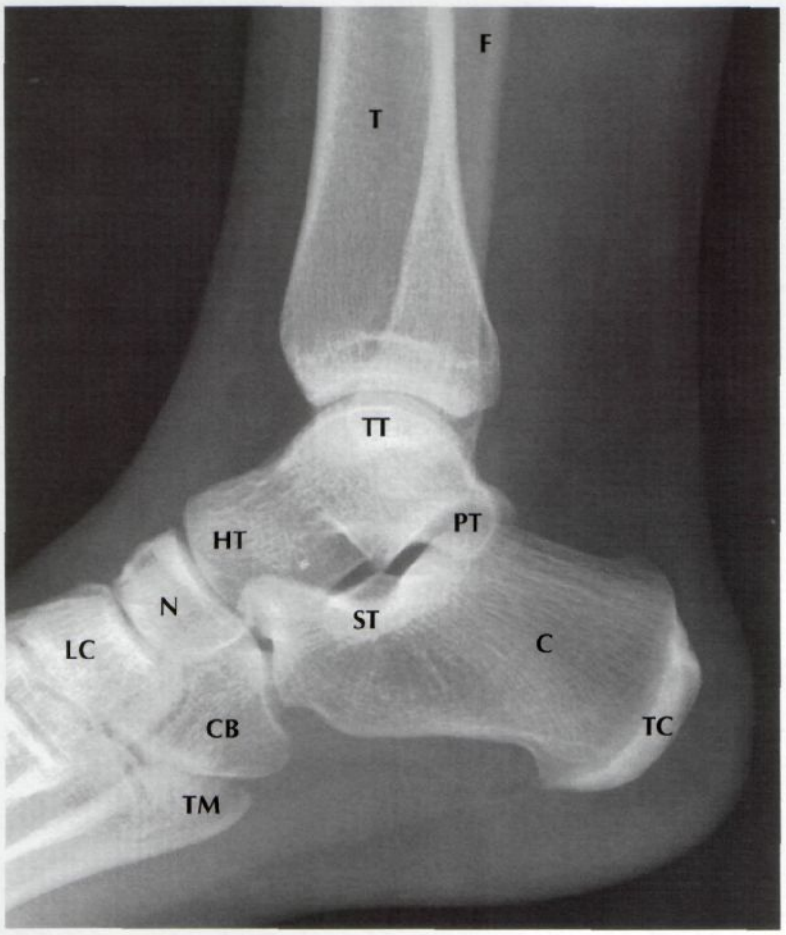

Lateral view

C	Calcaneus
CB	Cuboid
F	Fibula
HT	Head of talus
LC	Lateral cuneiform
N	Navicular
PT	Posterior process of talus
ST	Sustentaculum tali of calcaneus
T	Tibia
TC	Tuberosity of calcaneus
TM	Tuberosity of 5th metatarsal
TT	Trochlea of talus

Anterior view

F	Fibula
LM	Lateral malleolus
MM	Medial malleolus
T	Tibia
TA	Talus

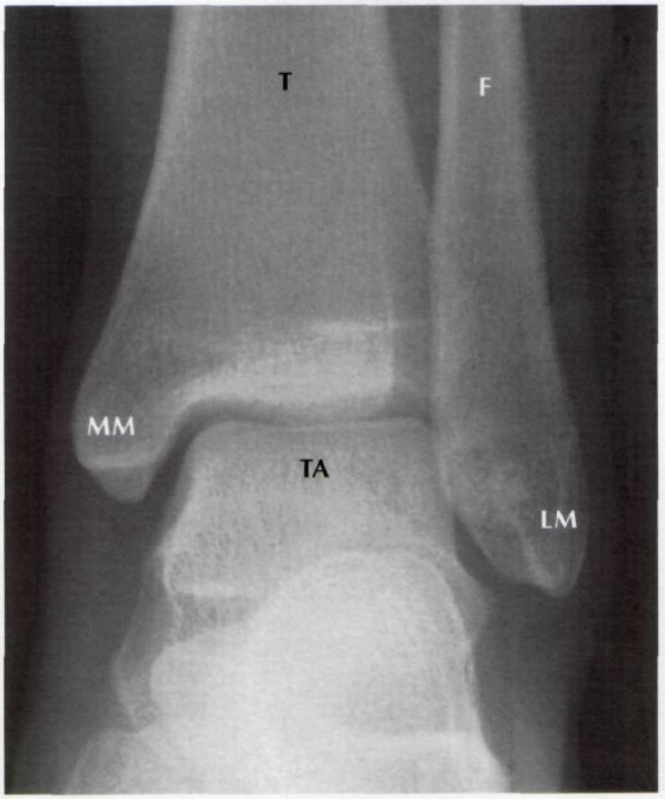

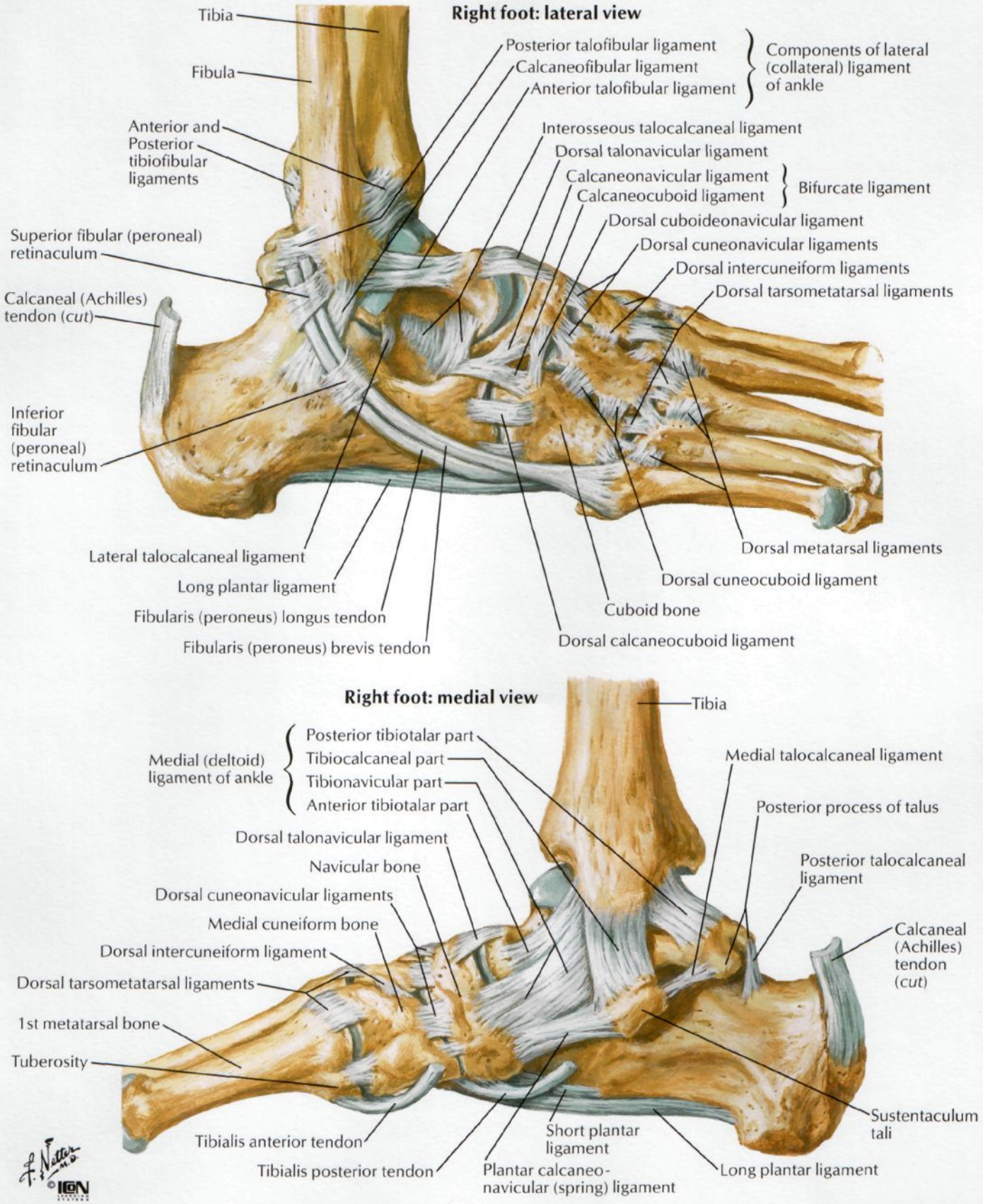
Right foot: lateral view
Tibia
Fibula
Anterior and Posterior tibiofibular ligaments
Superior fibular (peroneal) retinaculum
Calcaneal (Achilles) tendon (cut)
Inferior fibular (peroneal) retinaculum
Posterior talofibular ligament
Calcaneofibular ligament
Anterior talofibular ligament
Components of lateral (collateral) ligament of ankle
Interosseous talocalcaneal ligament
Dorsal talonavicular ligament
Calcaneonavicular ligament
Calcaneocuboid ligament
Bifurcate ligament
Dorsal cuboideonavicular ligament
Dorsal cuneonavicular ligaments
Dorsal intercuneiform ligaments
Dorsal tarsometatarsal ligaments
Lateral talocalcaneal ligament
Long plantar ligament
Fibularis (peroneus) longus tendon
Fibularis (peroneus) brevis tendon
Dorsal metatarsal ligaments
Dorsal cuneocuboid ligament
Cuboid bone
Dorsal calcaneocuboid ligament
Right foot: medial view
Tibia
Medial (deltoid) ligament of ankle
Posterior tibiotalar part
Tibiocalcaneal part
Tibionavicular part
Anterior tibiotalar part
Medial talocalcaneal ligament
Posterior process of talus
Dorsal talonavicular ligament
Navicular bone
Posterior talocalcaneal ligament
Dorsal cuneonavicular ligaments
Medial cuneiform bone
Calcaneal (Achilles) tendon (cut)
Dorsal intercuneiform ligament
Dorsal tarsometatarsal ligaments
1st metatarsal bone
Tuberosity
Sustentaculum tali
Tibialis anterior tendon
Short plantar ligament
Tibialis posterior tendon
Plantar calcaneo-navicular (spring) ligament
Long plantar ligament

Ligaments and Tendons of Foot: Plantar View

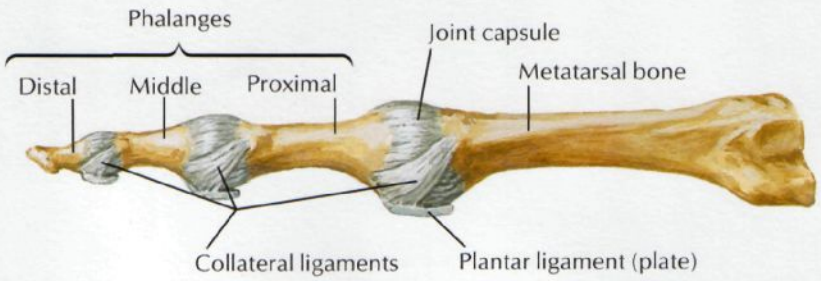

Capsules and ligaments of metatarsophalangeal and interphalangeal joints: lateral view

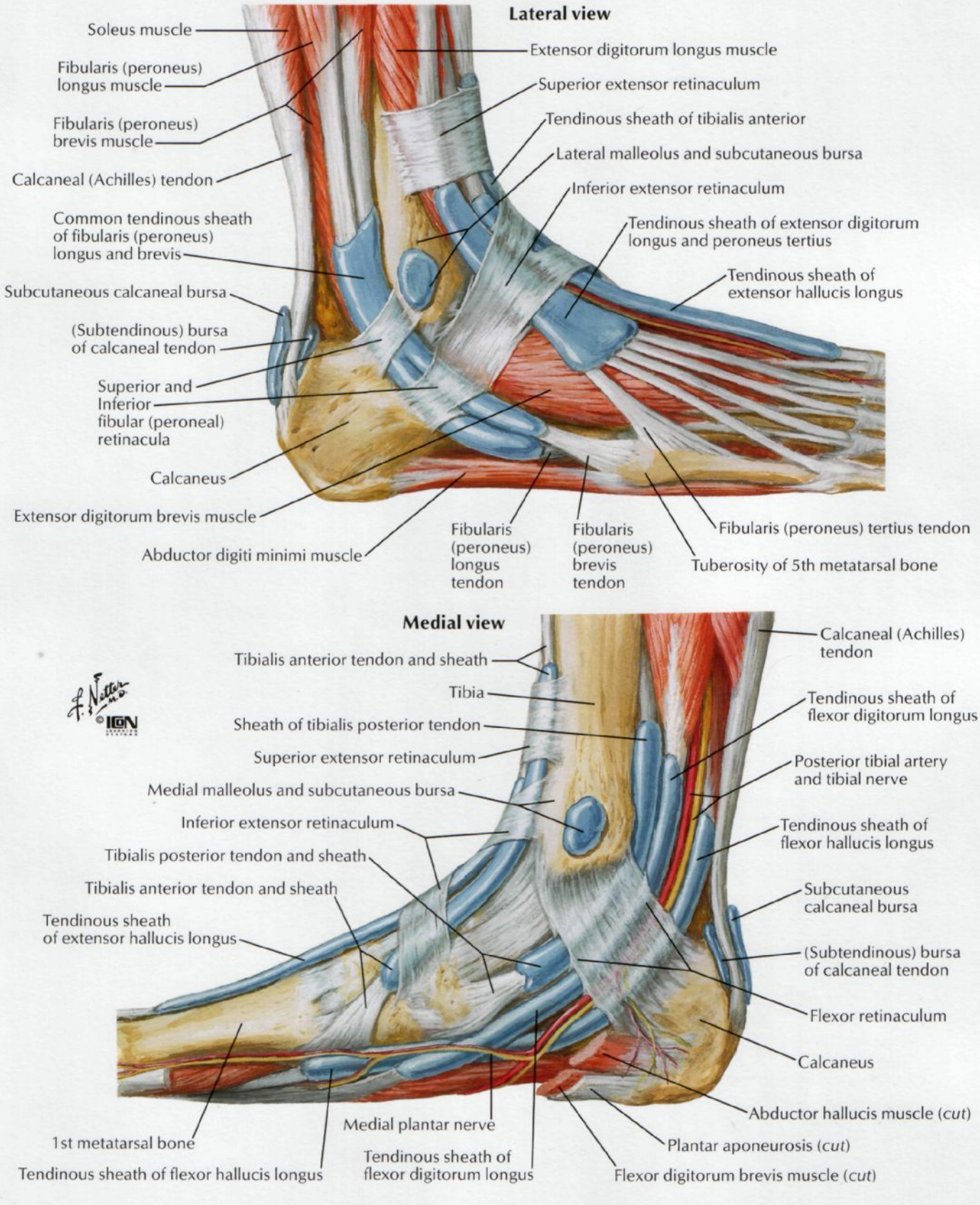
Lateral view
Soleus muscle
Fibularis (peroneus) longus muscle
Fibularis (peroneus) brevis muscle
Calcaneal (Achilles) tendon
Common tendinous sheath of fibularis (peroneus) longus and brevis
Subcutaneous calcaneal bursa
(Subtendinous) bursa of calcaneal tendon
Superior and Inferior fibular (peroneal) retinacula
Calcaneus
Extensor digitorum brevis muscle
Abductor digiti minimi muscle
Extensor digitorum longus muscle
Superior extensor retinaculum
Tendinous sheath of tibialis anterior
Lateral malleolus and subcutaneous bursa
Inferior extensor retinaculum
Tendinous sheath of extensor digitorum longus and peroneus tertius
Tendinous sheath of extensor hallucis longus
Fibularis (peroneus) longus tendon
Fibularis (peroneus) brevis tendon
Fibularis (peroneus) tertius tendon
Tuberosity of 5th metatarsal bone
Medial view
Tibialis anterior tendon and sheath
Tibia
Sheath of tibialis posterior tendon
Superior extensor retinaculum
Medial malleolus and subcutaneous bursa
Inferior extensor retinaculum
Tibialis posterior tendon and sheath
Tibialis anterior tendon and sheath
Tendinous sheath of extensor hallucis longus
1st metatarsal bone
Tendinous sheath of flexor hallucis longus
Medial plantar nerve
Tendinous sheath of flexor digitorum longus
Calcaneal (Achilles) tendon
Tendinous sheath of flexor digitorum longus
Posterior tibial artery and tibial nerve
Tendinous sheath of flexor hallucis longus
Subcutaneous calcaneal bursa
(Subtendinous) bursa of calcaneal tendon
Flexor retinaculum
Calcaneus
Abductor hallucis muscle (cut)
Plantar aponeurosis (cut)
Flexor digitorum brevis muscle (cut)

Muscles of Dorsum of Foot: Superficial Dissection

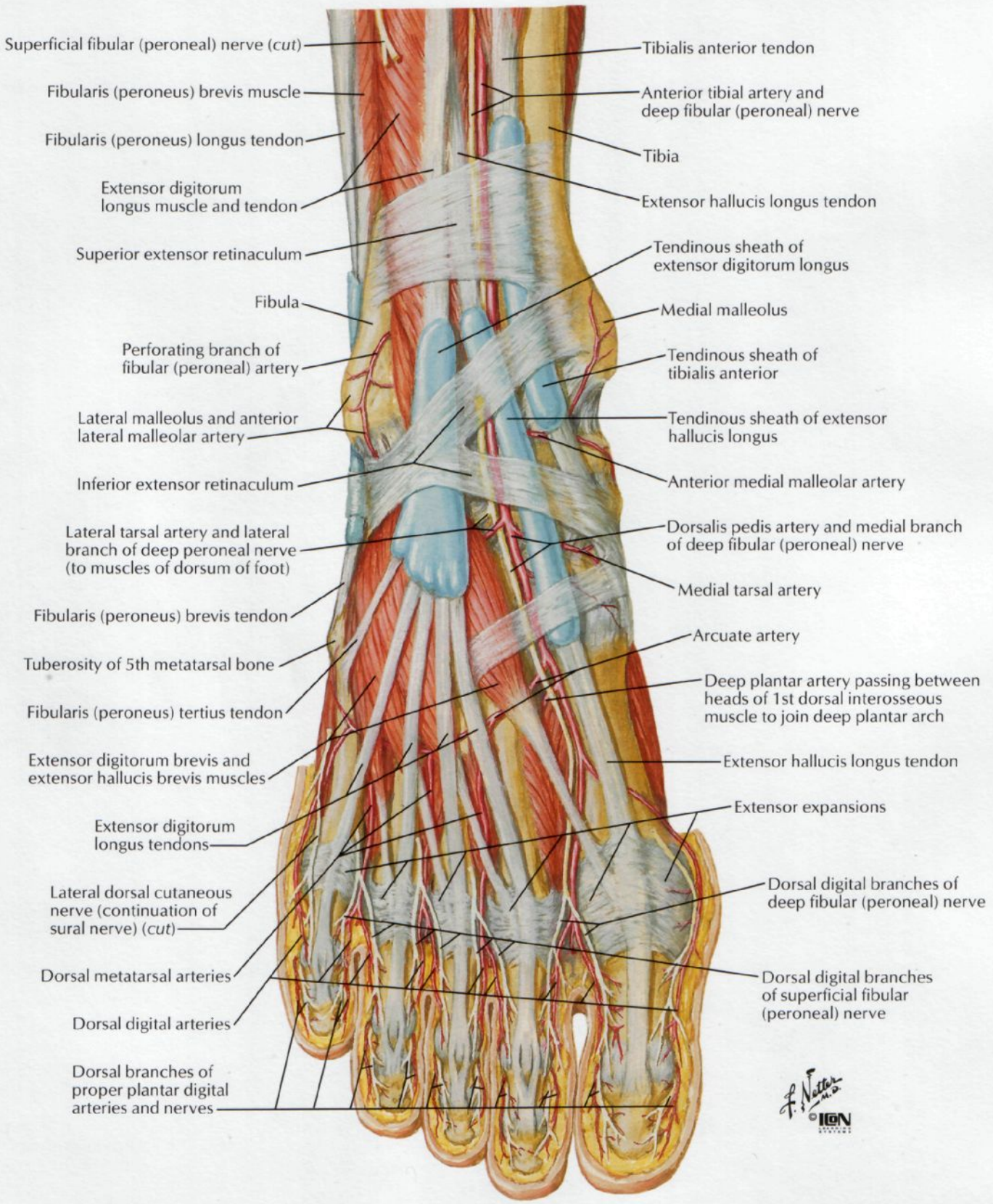

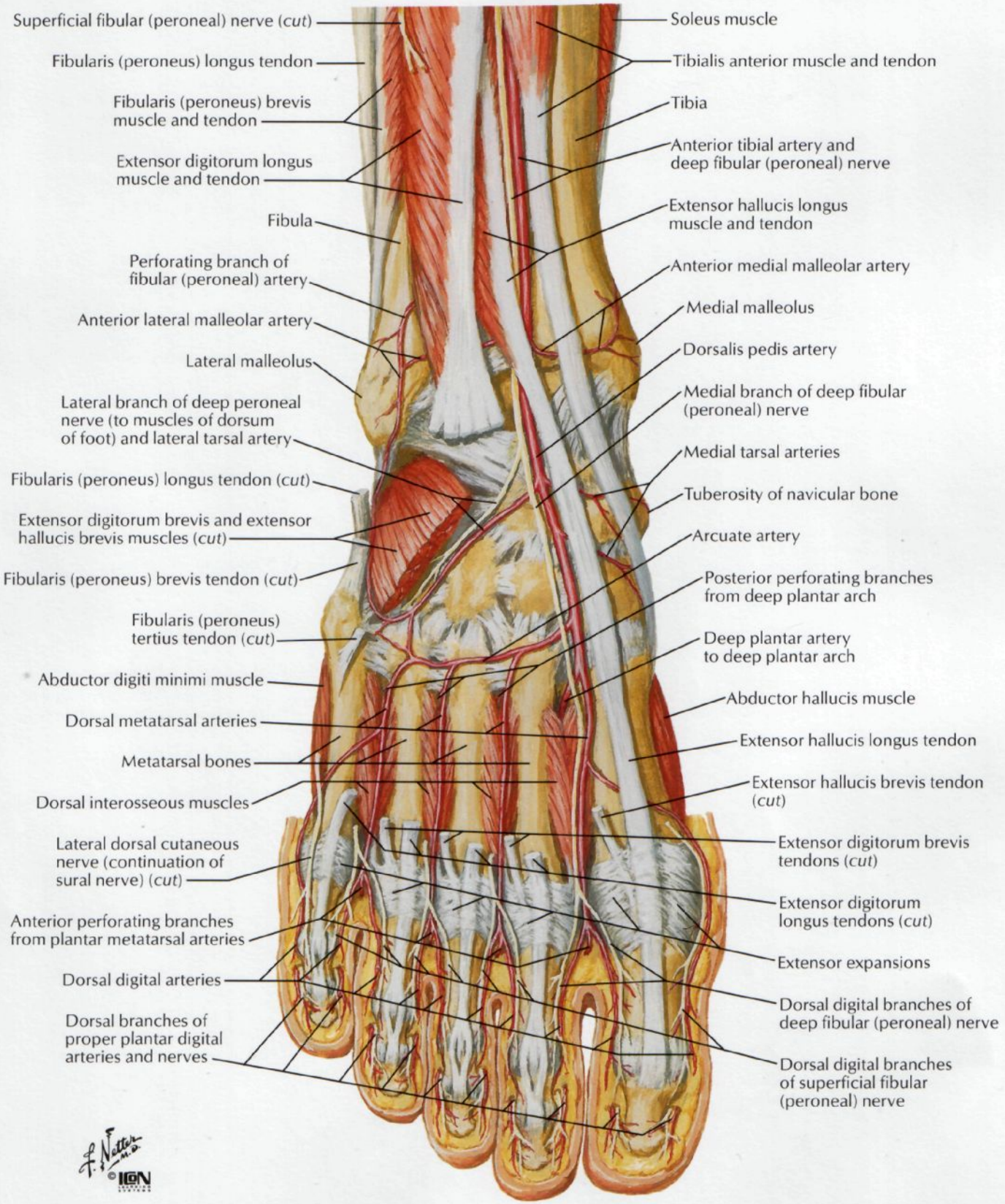
Superficial fibular (peroneal) nerve (cut)
Fibularis (peroneus) longus tendon
Fibularis (peroneus) brevis muscle and tendon
Extensor digitorum longus muscle and tendon
Fibula
Perforating branch of fibular (peroneal) artery
Anterior lateral malleolar artery
Lateral malleolus
Lateral branch of deep peroneal nerve (to muscles of dorsum of foot) and lateral tarsal artery
Fibularis (peroneus) longus tendon (cut)
Extensor digitorum brevis and extensor hallucis brevis muscles (cut)
Fibularis (peroneus) brevis tendon (cut)
Fibularis (peroneus) tertius tendon (cut)
Abductor digiti minimi muscle
Dorsal metatarsal arteries
Metatarsal bones
Dorsal interosseous muscles
Lateral dorsal cutaneous nerve (continuation of sural nerve) (cut)
Anterior perforating branches from plantar metatarsal arteries
Dorsal digital arteries
Dorsal branches of proper plantar digital arteries and nerves
Soleus muscle
Tibialis anterior muscle and tendon
Tibia
Anterior tibial artery and deep fibular (peroneal) nerve
Extensor hallucis longus muscle and tendon
Anterior medial malleolar artery
Medial malleolus
Dorsalis pedis artery
Medial branch of deep fibular (peroneal) nerve
Medial tarsal arteries
Tuberosity of navicular bone
Arcuate artery
Posterior perforating branches from deep plantar arch
Deep plantar artery to deep plantar arch
Abductor hallucis muscle
Extensor hallucis longus tendon
Extensor hallucis brevis tendon (cut)
Extensor digitorum brevis tendons (cut)
Extensor digitorum longus tendons (cut)
Extensor expansions
Dorsal digital branches of deep fibular (peroneal) nerve
Dorsal digital branches of superficial fibular (peroneal) nerve
F. Netter M.D.
©IGN

Sole of Foot: Superficial Dissection

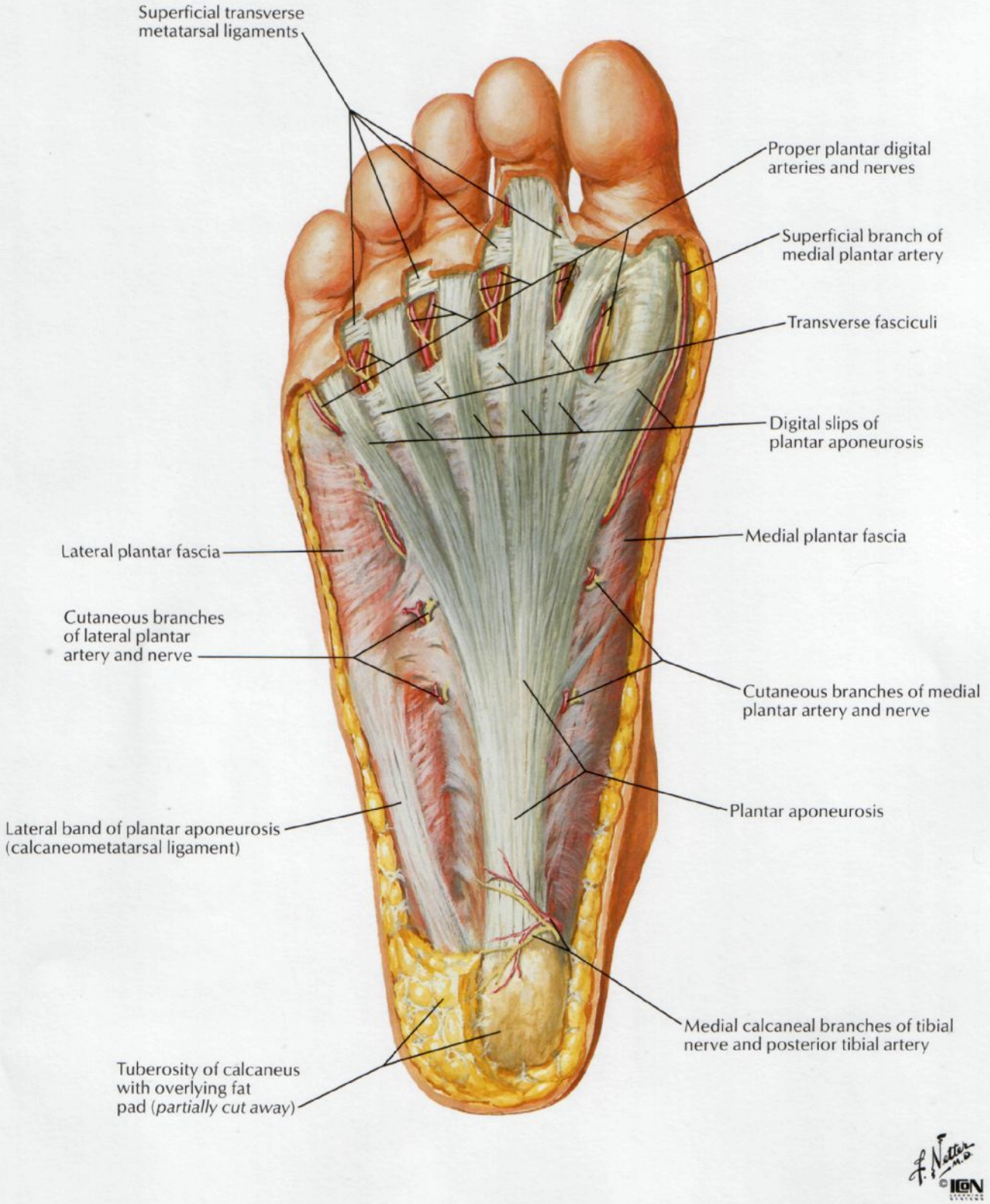

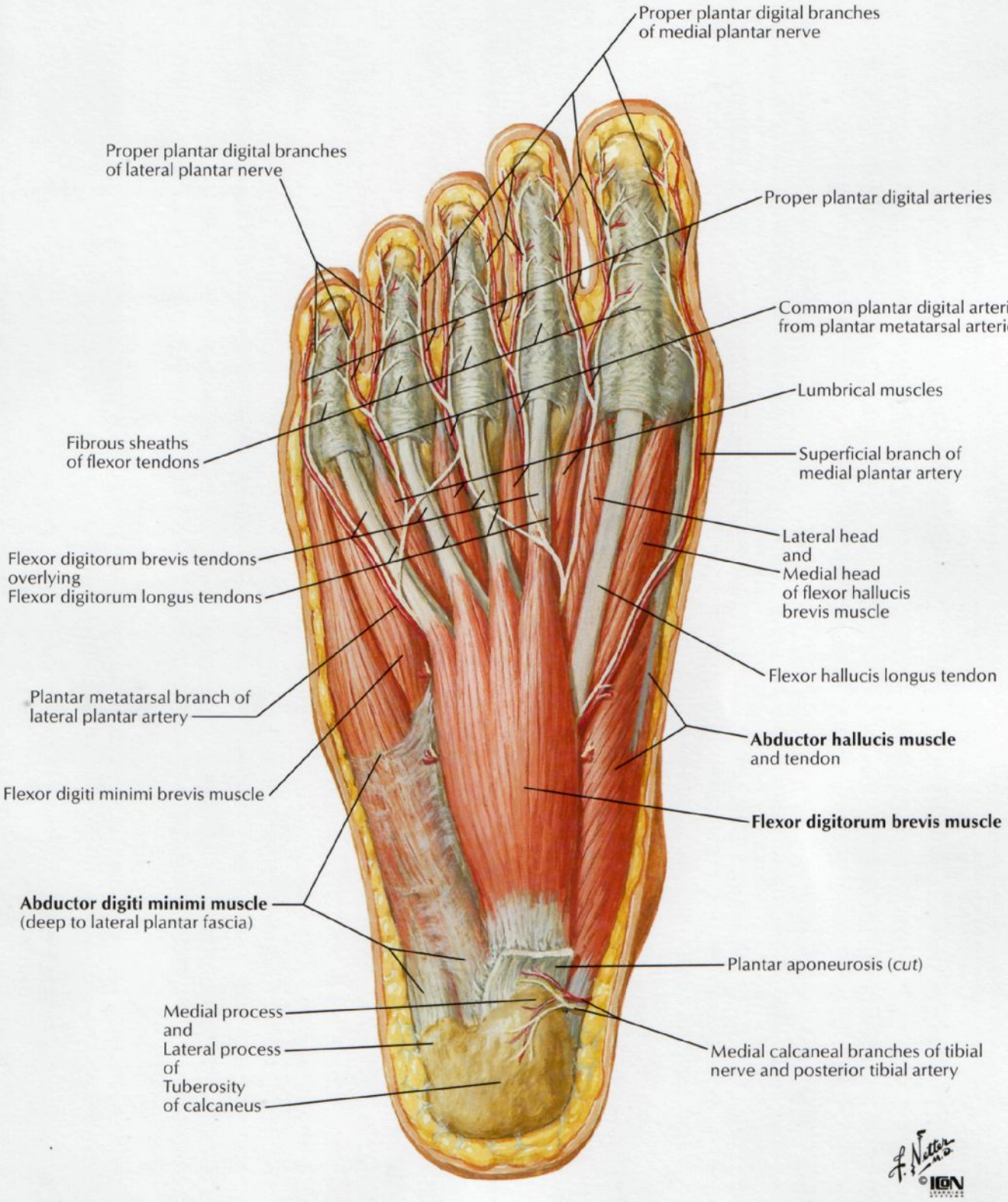
Proper plantar digital branches of medial plantar nerve
Proper plantar digital branches of lateral plantar nerve
Proper plantar digital arteries
Common plantar digital arteries from plantar metatarsal arteries
Lumbrical muscles
Fibrous sheaths of flexor tendons
Superficial branch of medial plantar artery
Lateral head and Medial head of flexor hallucis brevis muscle
Flexor digitorum brevis tendons overlying Flexor digitorum longus tendons
Flexor hallucis longus tendon
Plantar metatarsal branch of lateral plantar artery
Abductor hallucis muscle and tendon
Flexor digiti minimi brevis muscle
Flexor digitorum brevis muscle
Abductor digiti minimi muscle (deep to lateral plantar fascia)
Plantar aponeurosis (cut)
Medial process and Lateral process of Tuberosity of calcaneus
Medial calcaneal branches of tibial nerve and posterior tibial artery

Muscles of Sole of Foot: Second Layer

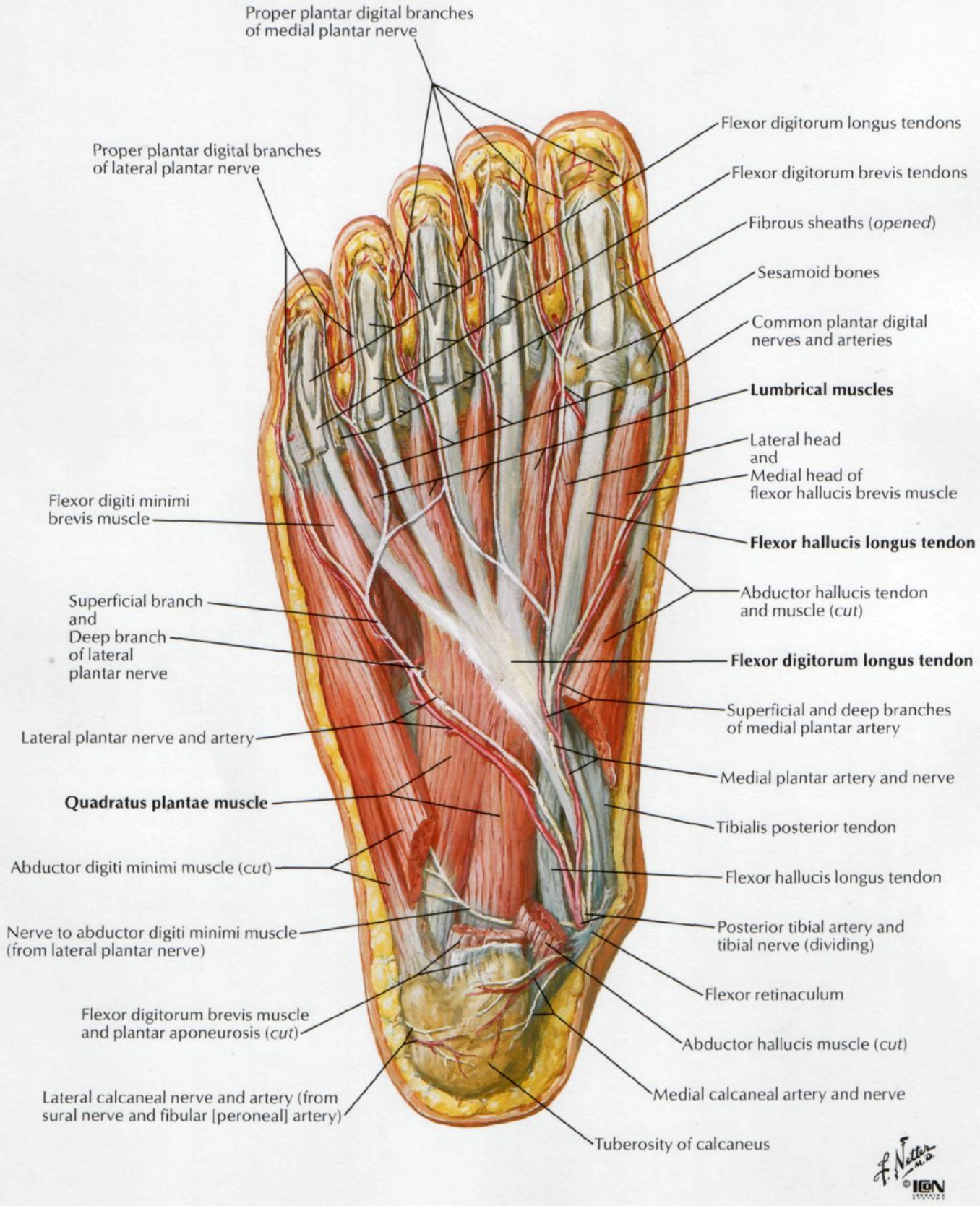

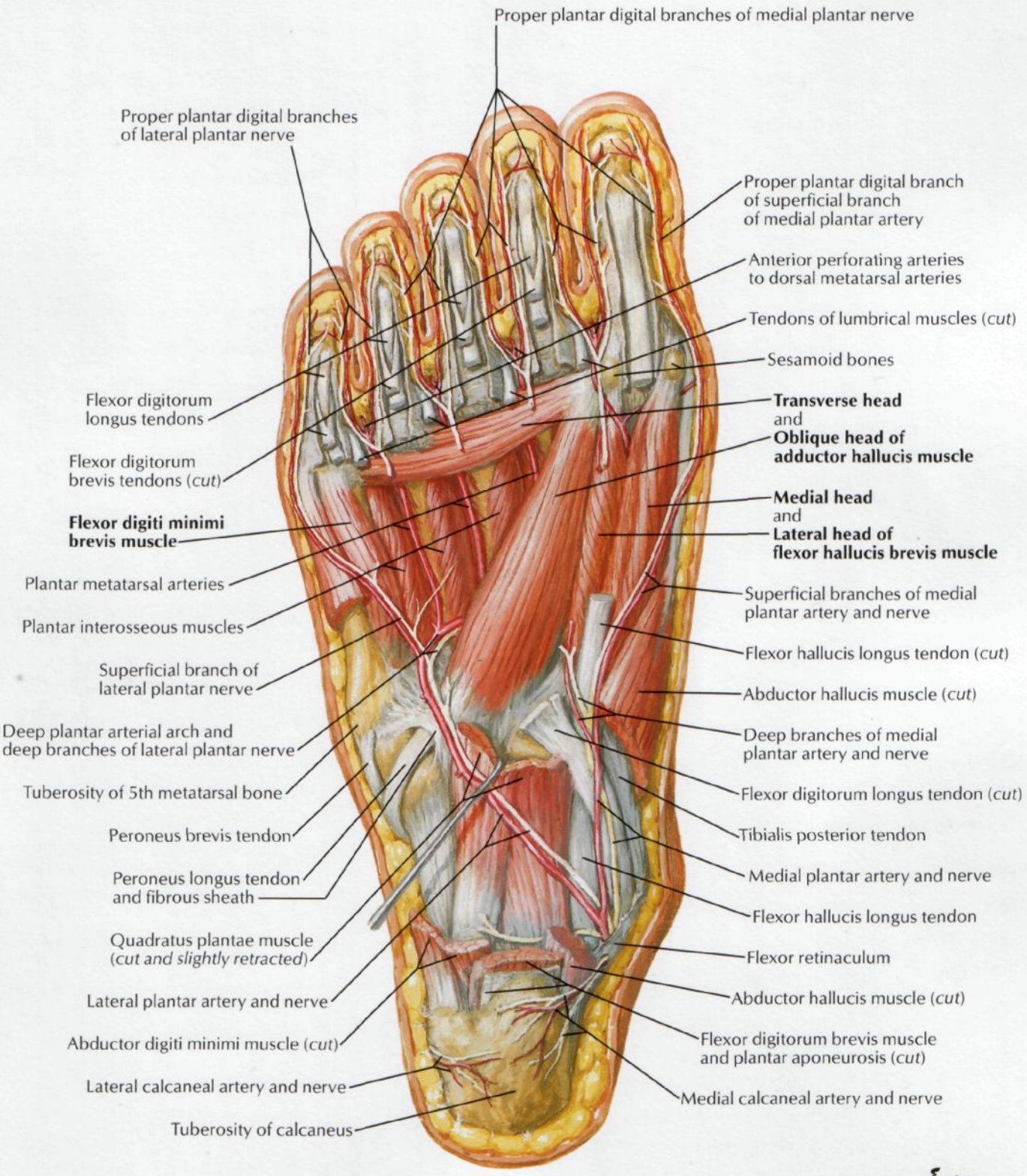
Proper plantar digital branches of medial plantar nerve
Proper plantar digital branches of lateral plantar nerve
Proper plantar digital branch of superficial branch of medial plantar artery
Anterior perforating arteries to dorsal metatarsal arteries
Tendons of lumbrical muscles (cut)
Sesamoid bones
Flexor digitorum longus tendons
Transverse head and Oblique head of adductor hallucis muscle
Flexor digitorum brevis tendons (cut)
Medial head and Lateral head of flexor hallucis brevis muscle
Flexor digiti minimi brevis muscle
Plantar metatarsal arteries
Superficial branches of medial plantar artery and nerve
Plantar interosseous muscles
Flexor hallucis longus tendon (cut)
Superficial branch of lateral plantar nerve
Abductor hallucis muscle (cut)
Deep plantar arterial arch and deep branches of lateral plantar nerve
Deep branches of medial plantar artery and nerve
Tuberosity of 5th metatarsal bone
Flexor digitorum longus tendon (cut)
Peroneus brevis tendon
Tibialis posterior tendon
Peroneus longus tendon and fibrous sheath
Medial plantar artery and nerve
Flexor hallucis longus tendon
Quadratus plantae muscle (cut and slightly retracted)
Flexor retinaculum
Lateral plantar artery and nerve
Abductor hallucis muscle (cut)
Abductor digiti minimi muscle (cut)
Flexor digitorum brevis muscle and plantar aponeurosis (cut)
Lateral calcaneal artery and nerve
Medial calcaneal artery and nerve
Tuberosity of calcaneus

Interosseous Muscles and Deep Arteries of Foot

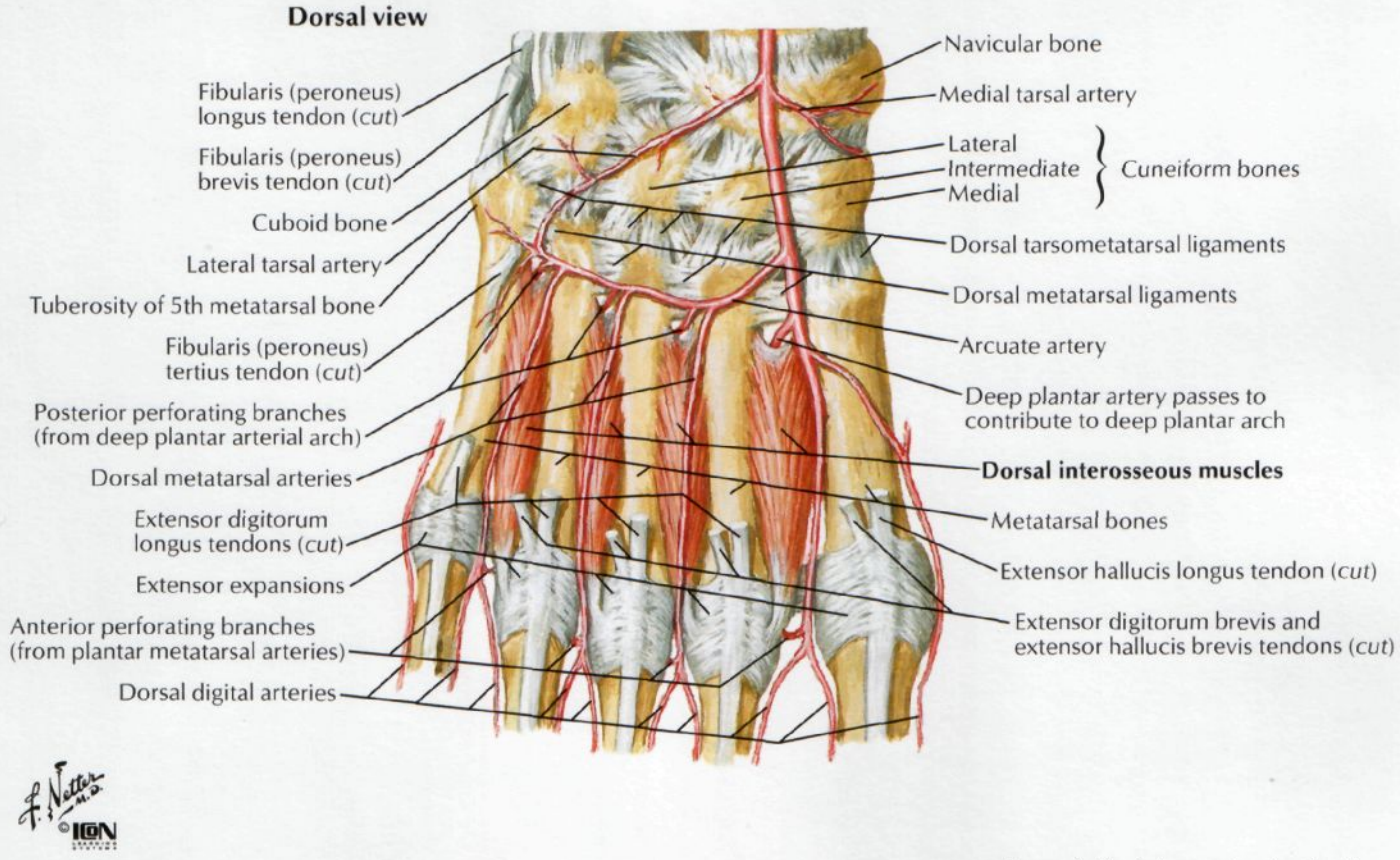

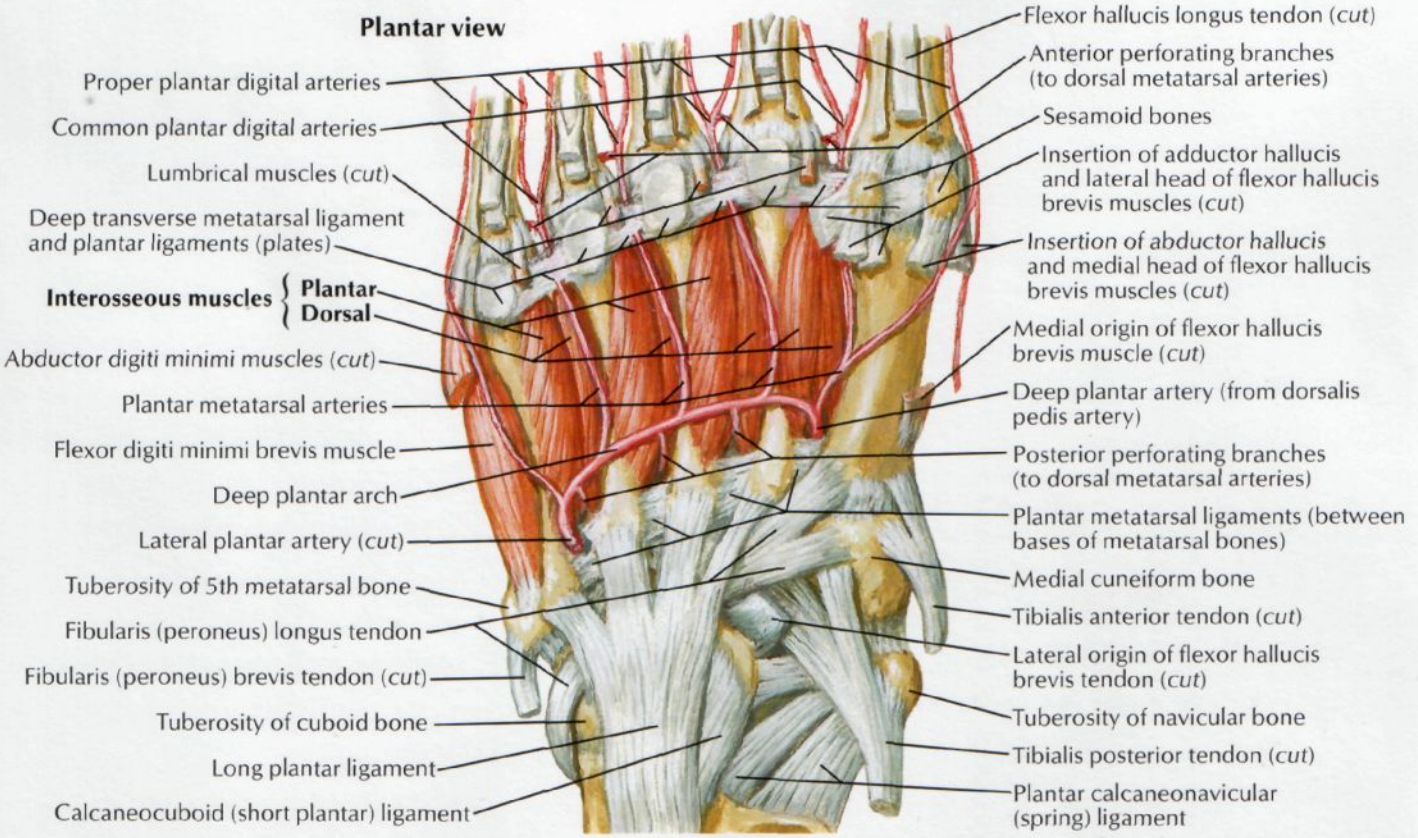

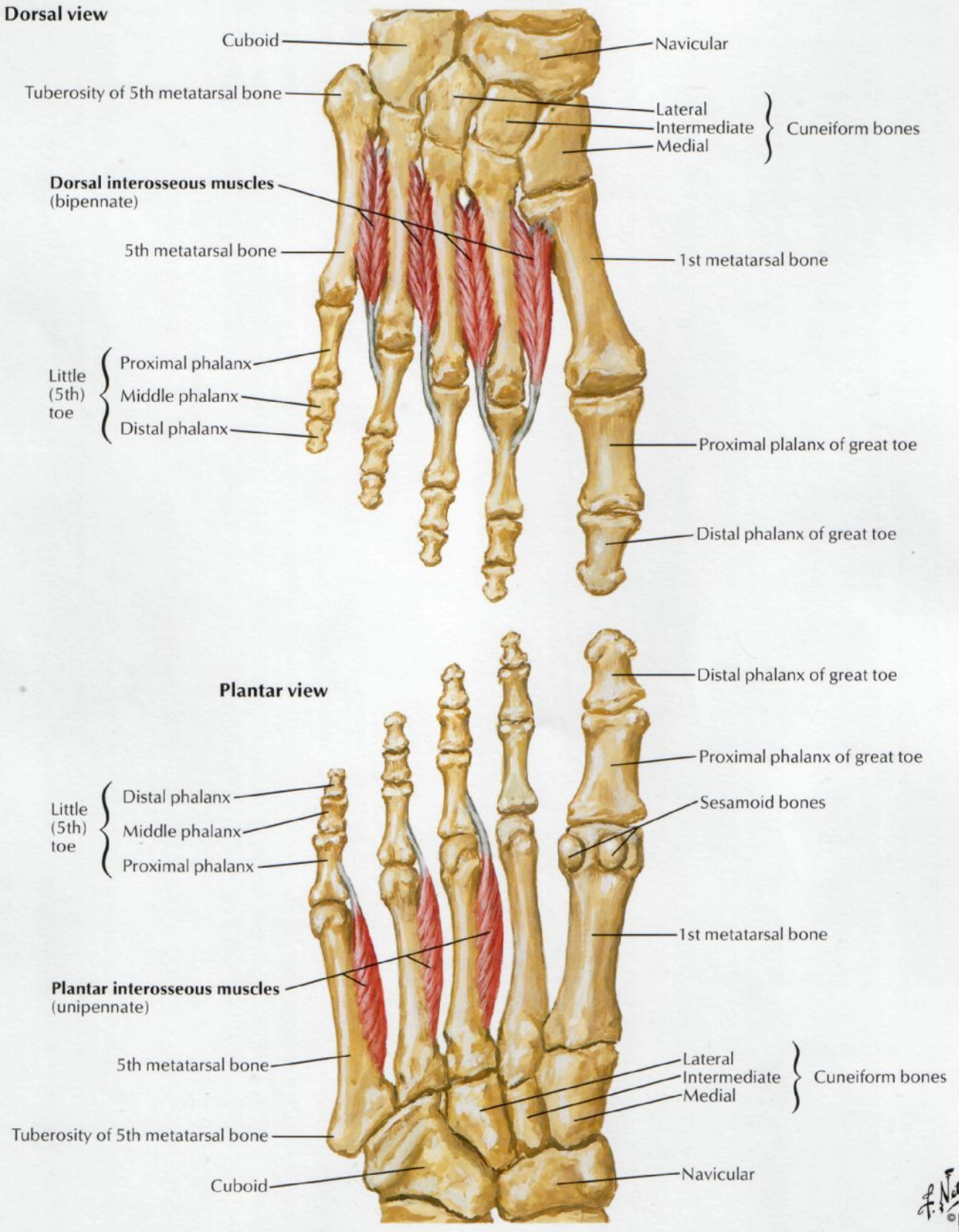
Dorsal view
Cuboid
Navicular
Tuberosity of 5th metatarsal bone
Lateral
Intermediate
Medial
Cuneiform bones
Dorsal interosseous muscles
(bipennate)
5th metatarsal bone
1st metatarsal bone
Little
(5th)
toe
Proximal phalanx
Middle phalanx
Distal phalanx
Proximal plalanx of great toe
Distal phalanx of great toe
Plantar view
Distal phalanx of great toe
Proximal phalanx of great toe
Little
(5th)
toe
Distal phalanx
Middle phalanx
Proximal phalanx
Sesamoid bones
1st metatarsal bone
Plantar interosseous muscles
(unipennate)
5th metatarsal bone
Lateral
Intermediate
Medial
Cuneiform bones
Tuberosity of 5th metatarsal bone
Cuboid
Navicular

Femoral Nerve and Lateral Cutaneous Nerve of Thigh

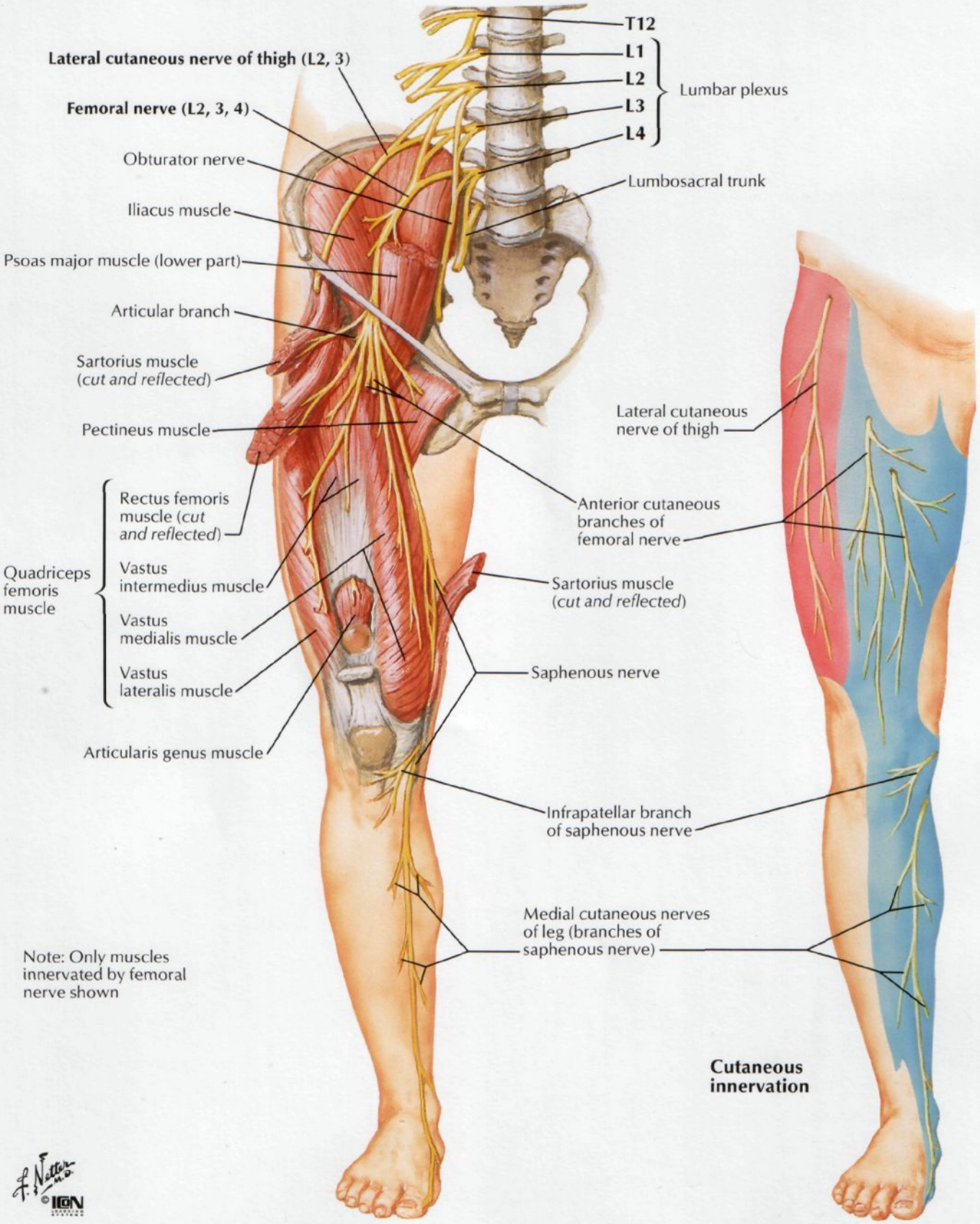

©IGN

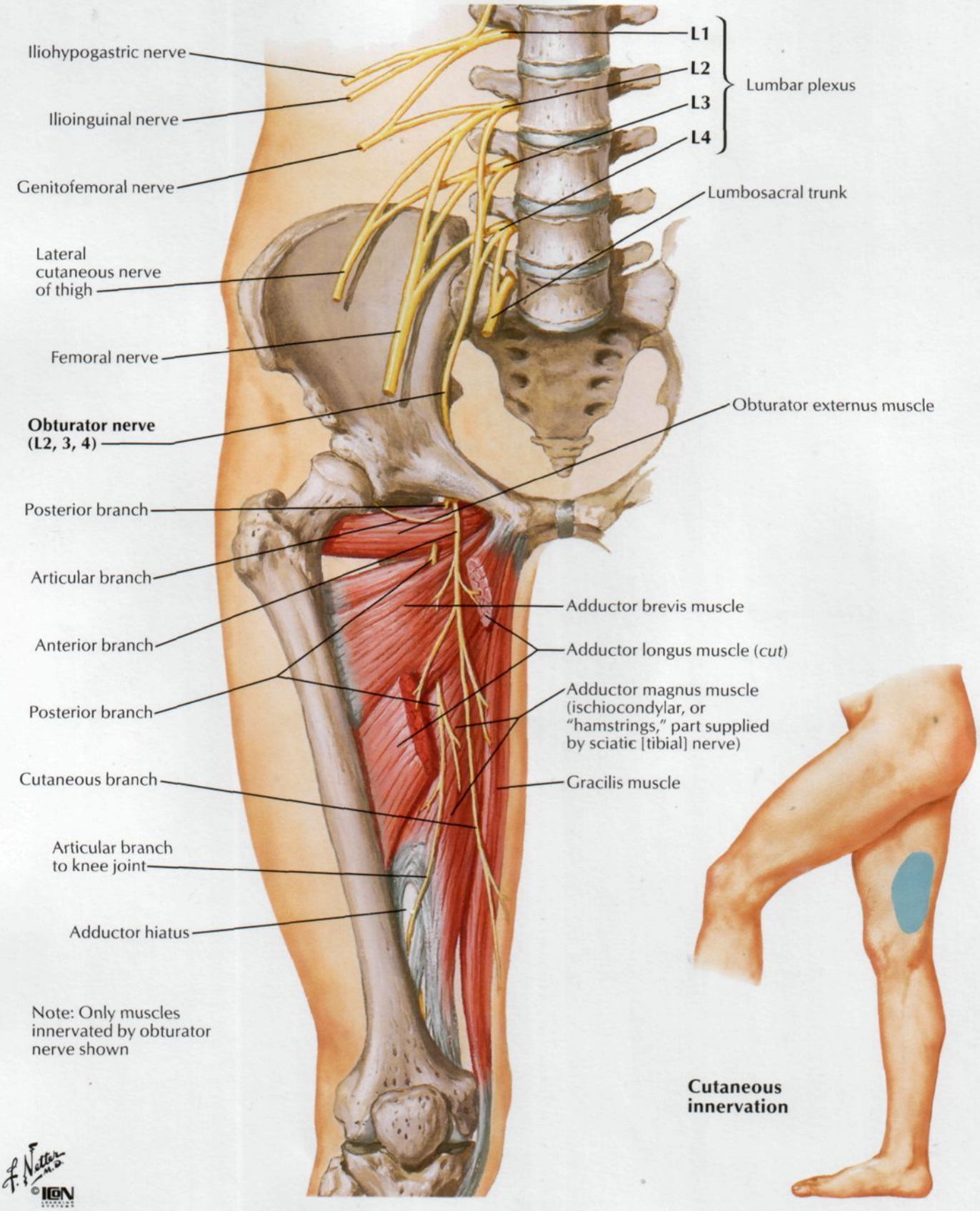

Note: Only muscles innervated by obturator nerve shown

F. Netter M.D.
©IGN

Sciatic Nerve and Posterior Cutaneous Nerve of Thigh

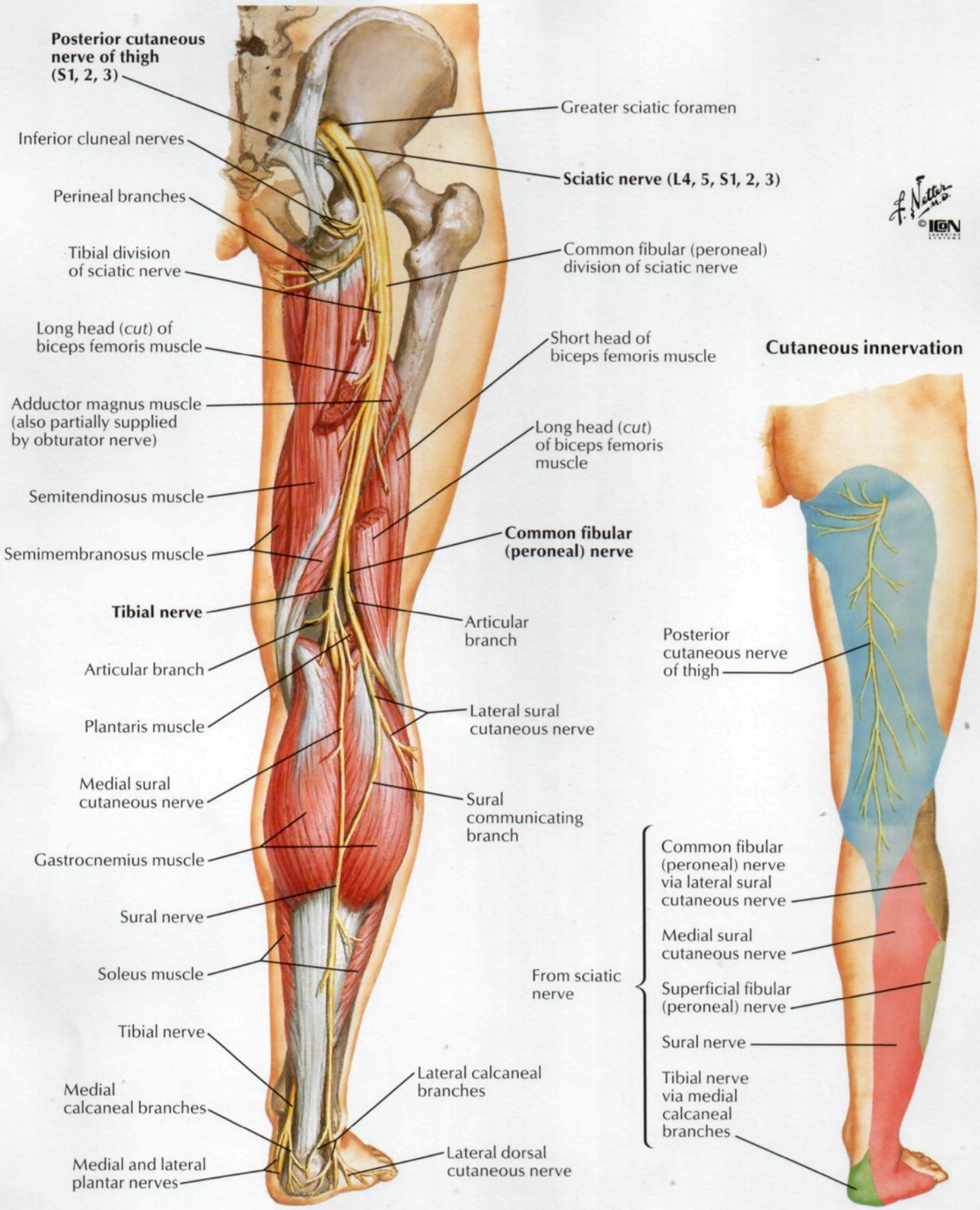

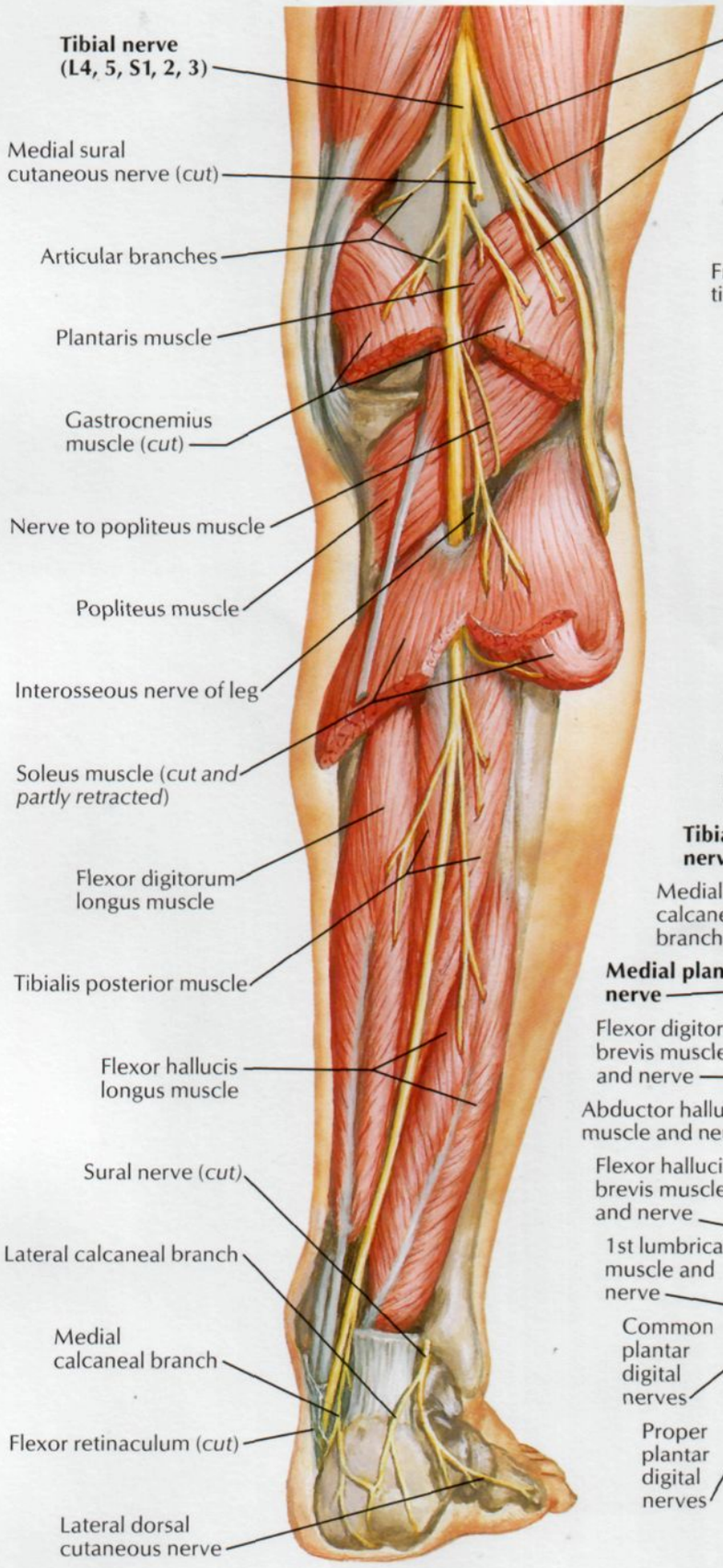

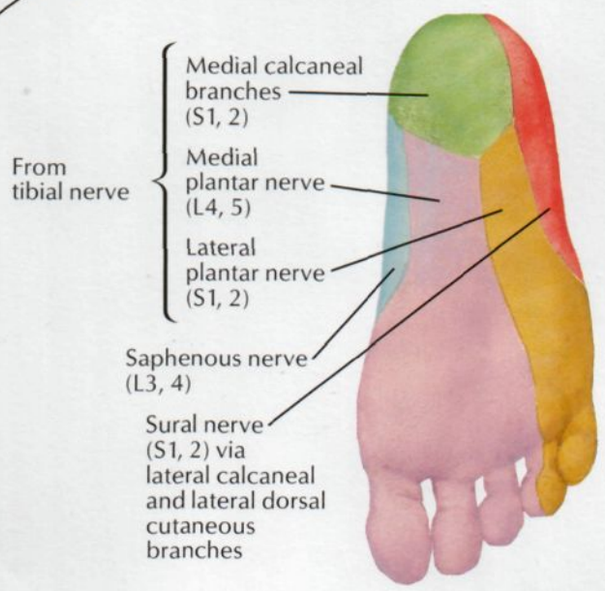

Cutaneous innervation of sole

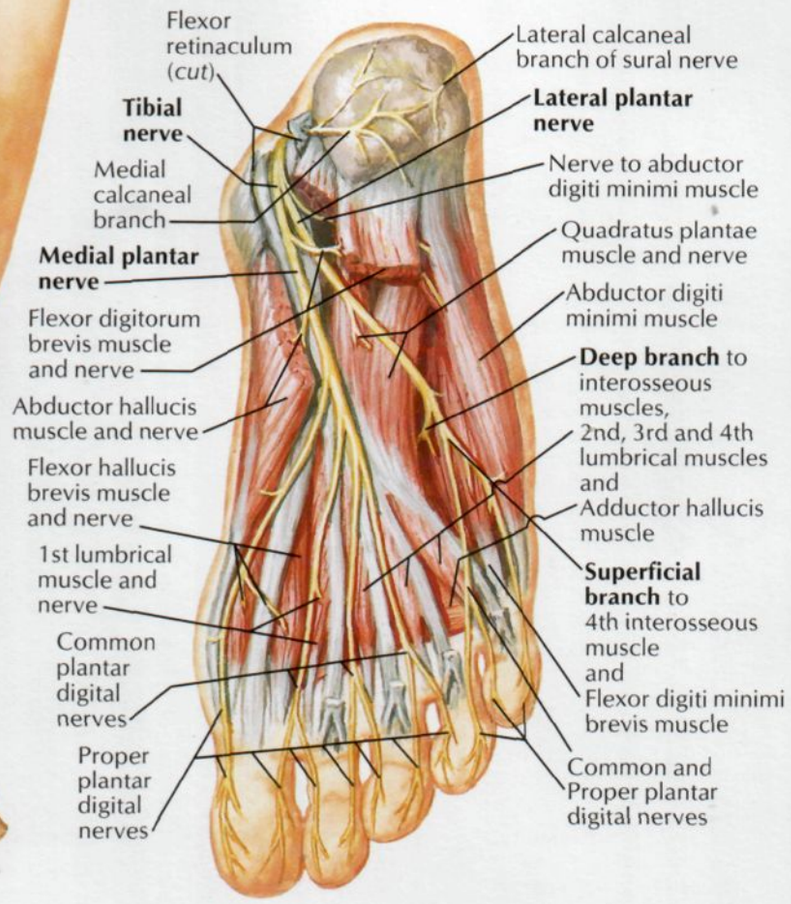

Note: Articular branches not shown

Common Fibular (Peroneal) Nerve

SEE ALSO PLATES 502, 503

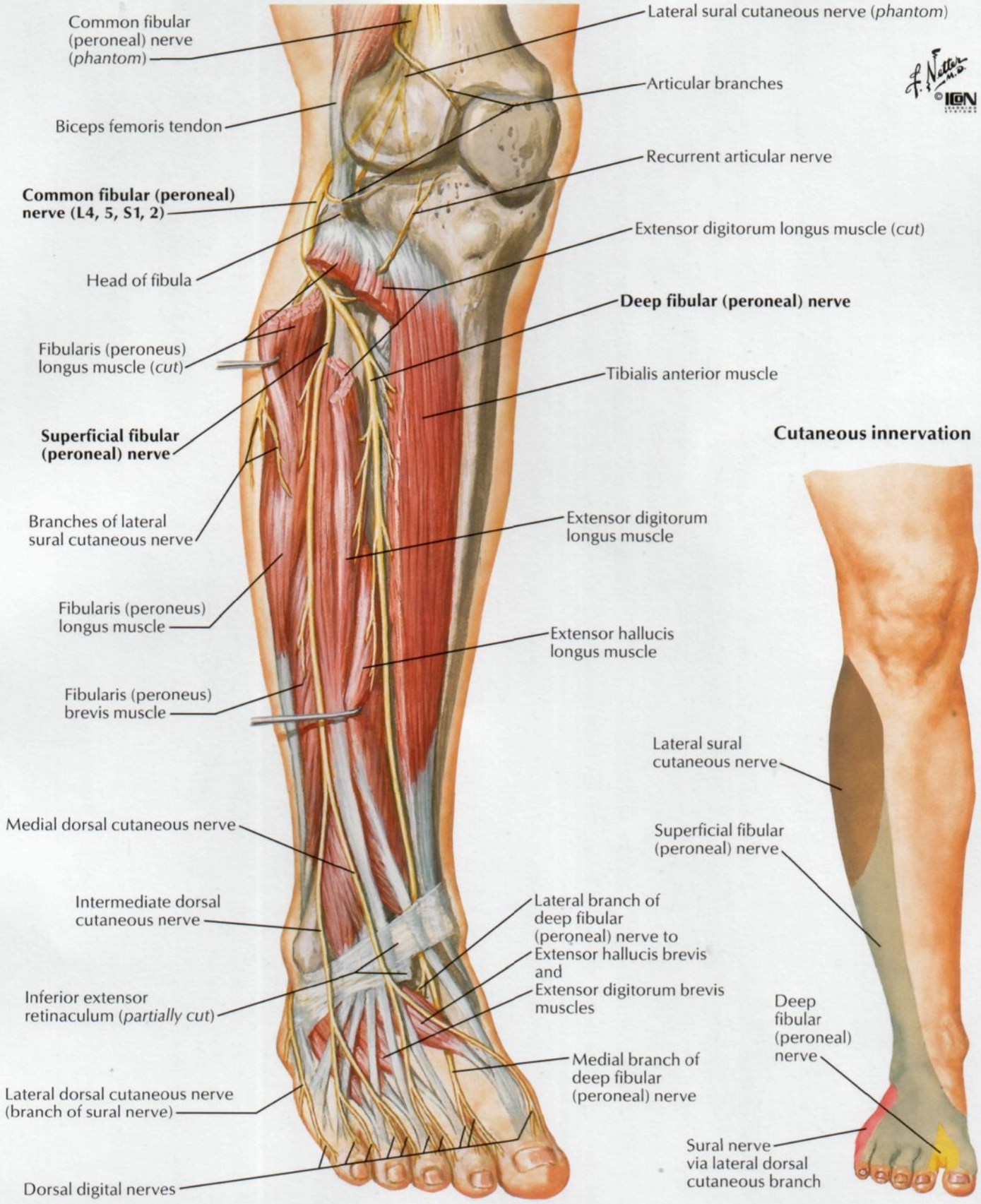

Schematic demarcation of dermatomes (according to Keegan and Garrett) shown as distinct segments. There is actually considerable overlap between any two adjacent dermatomes. An alternative dermatome map is that provided by Foerster (see References).

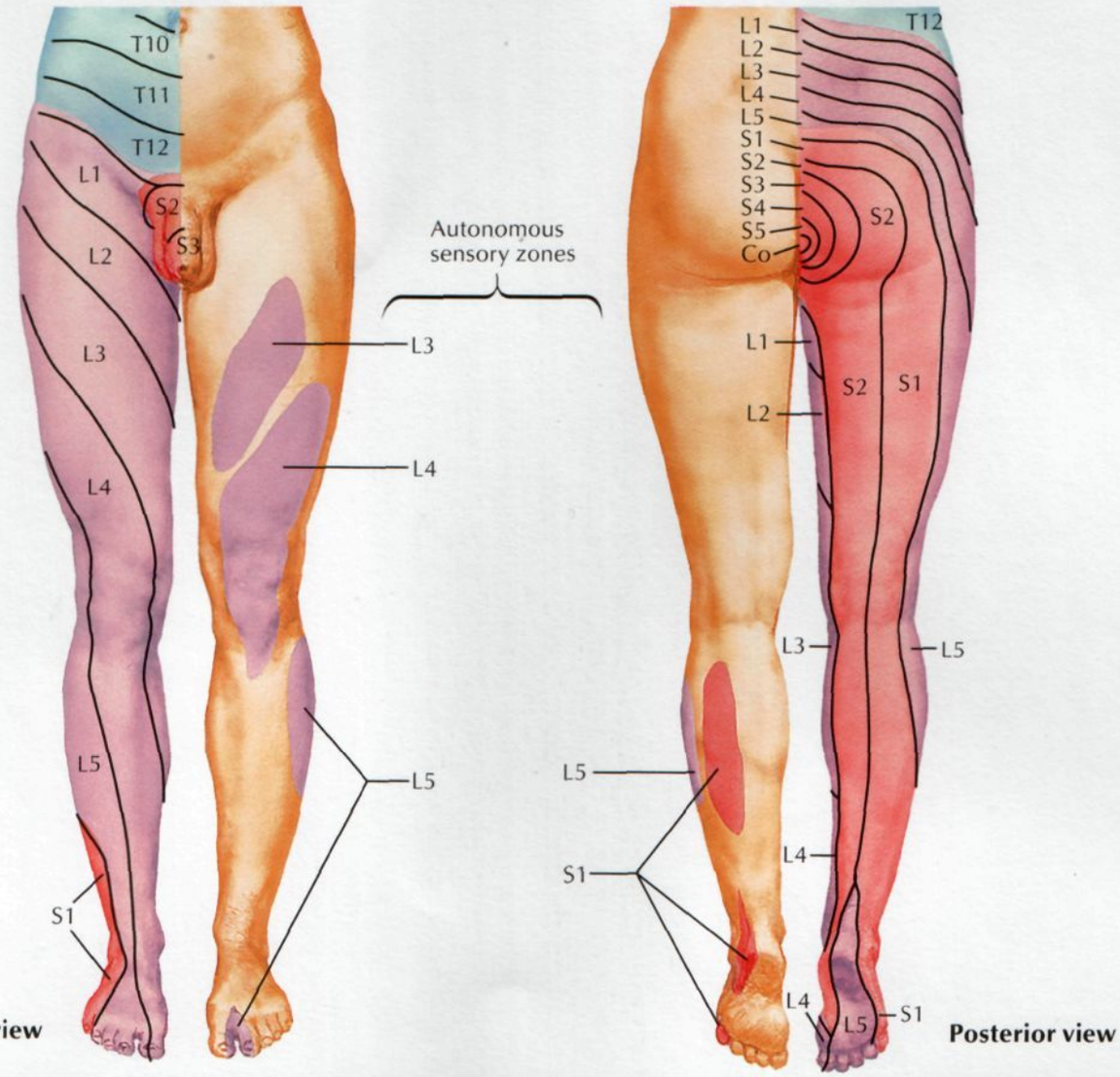

Segmental innervation of lower limb movements

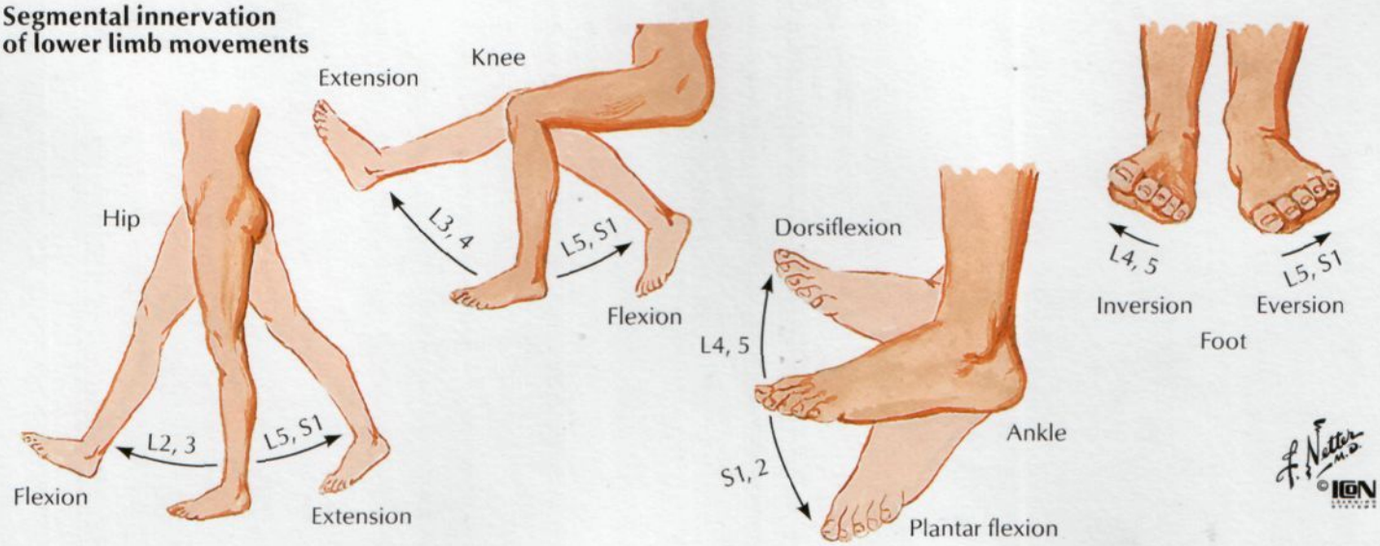

Superficial Nerves and Veins of Lower Limb: Anterior View

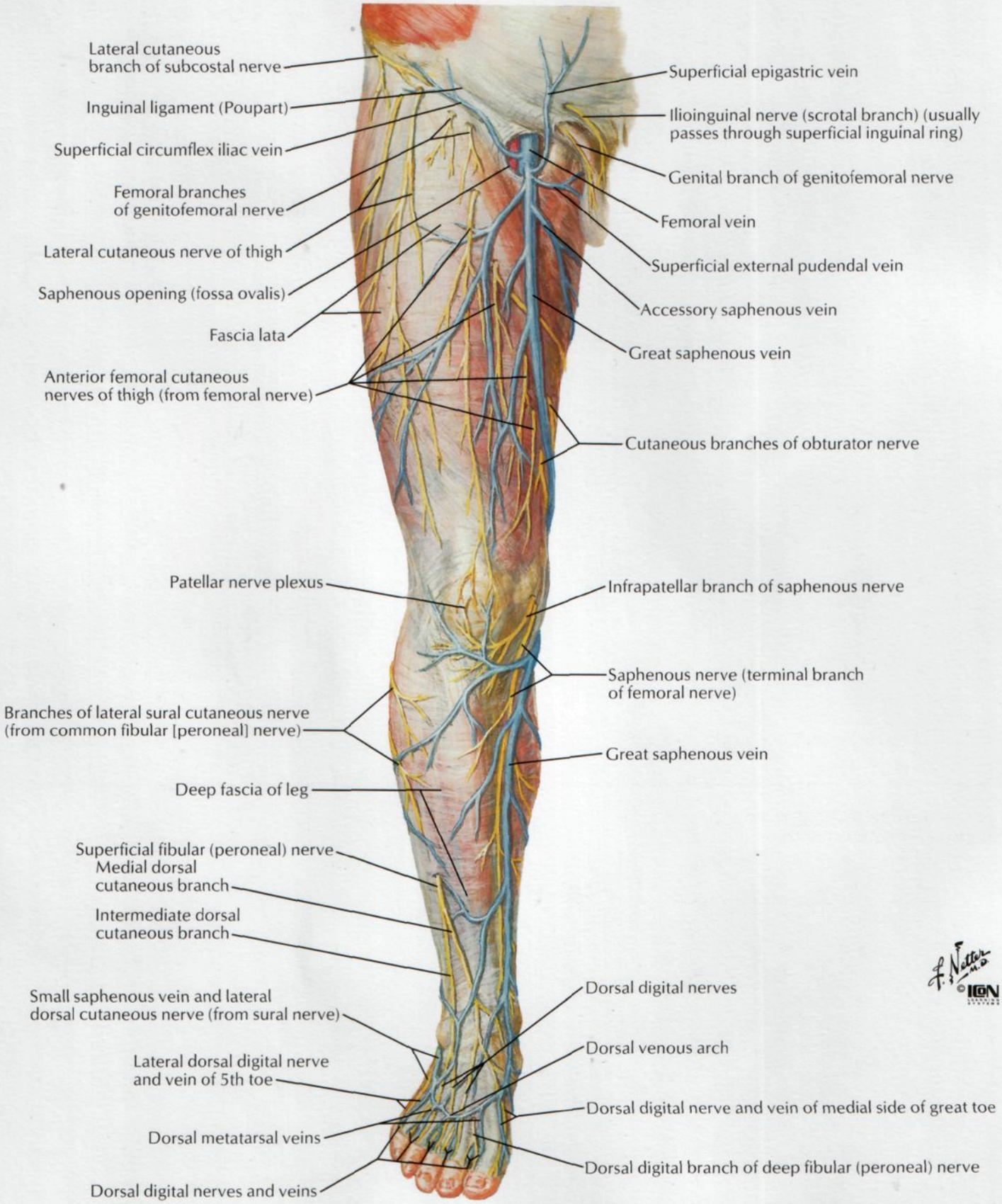

Superficial Nerves and Veins of Lower Limb: Posterior View

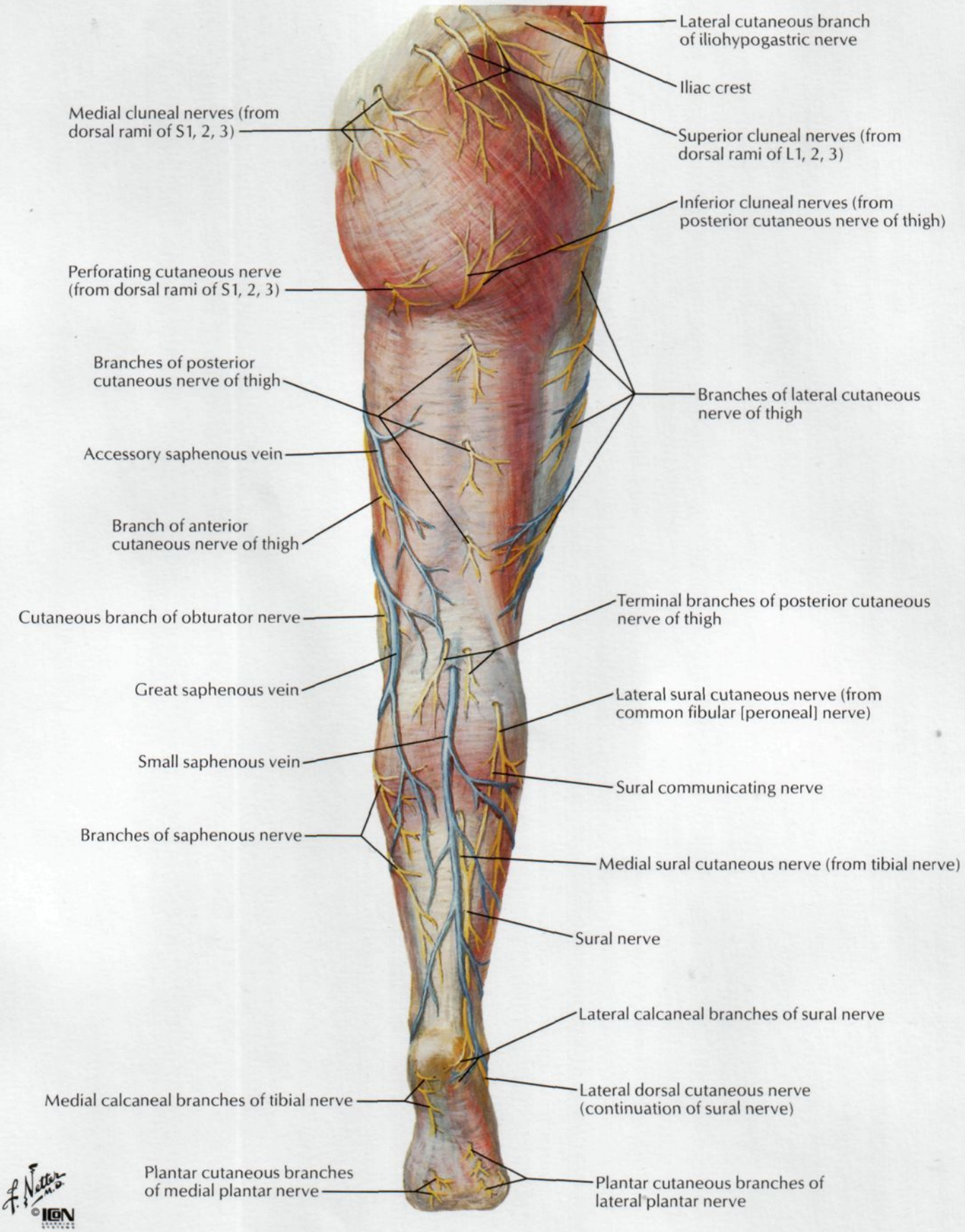

F. Netter M.D. © IGN

Lymph Vessels and Nodes of Lower Limb

SEE ALSO PLATES 387, 388

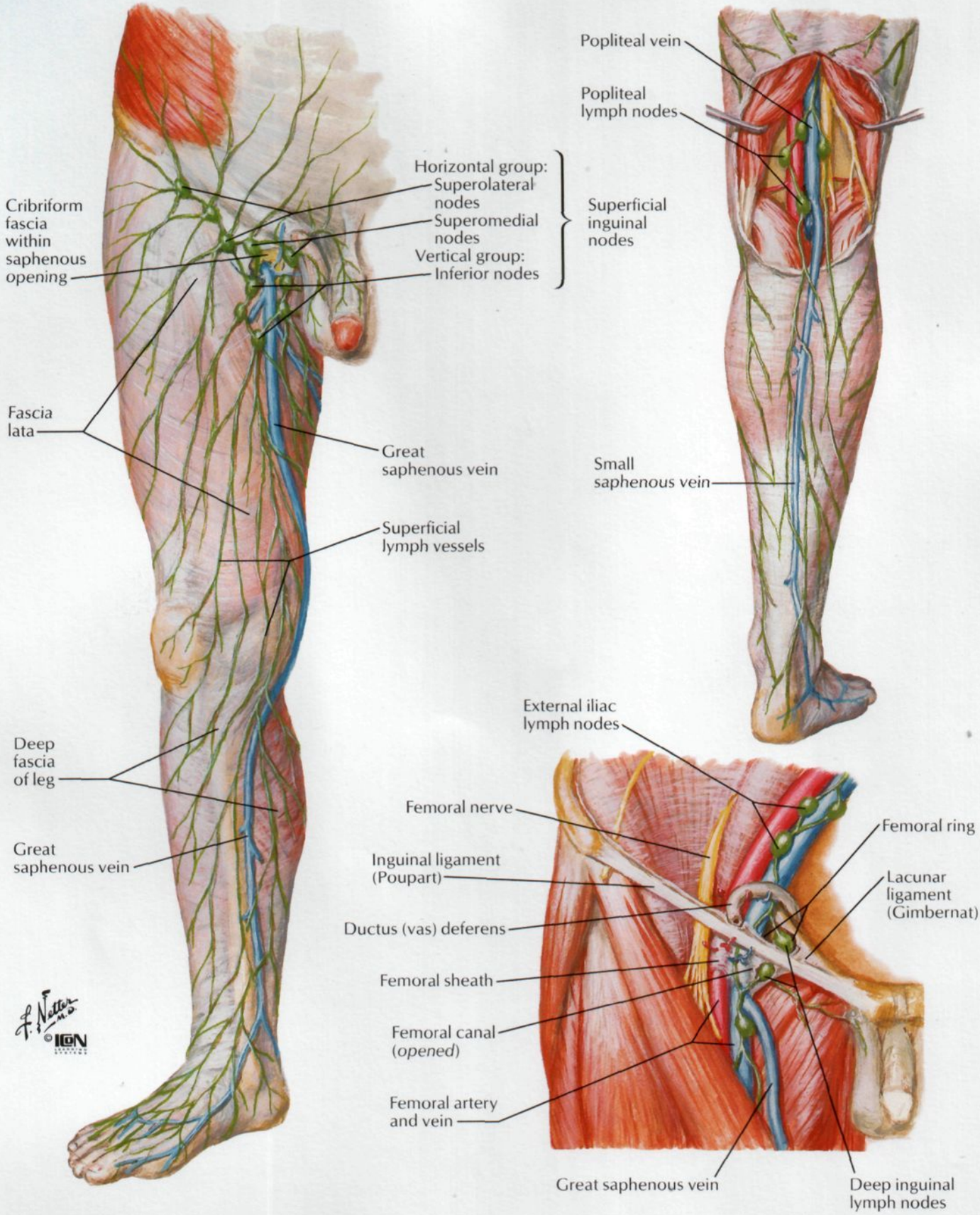

Section VIII

CROSS-SECTIONAL ANATOMY

CROSS-SECTION OVERVIEW
Plate 529
529. Key Figure for Cross Sections

THORAX
Plates 530–533
530. Thorax: Brachiocephalic Vessels
531. Thorax: Aortic and Azygos Arches
532. Thorax: Pulmonary Trunk
533. Thorax: Four Chambers of Heart

ABDOMEN
Plates 534–539
534. Abdomen: Esophagogastric Junction
535. Abdomen: Pylorus and Body of Pancreas
536. Abdomen: Origins of Celiac Artery and Portal Vein
537. Abdomen: Renal Hilum and Vessels
538. Abdomen: Ileocecal Junction
539. Abdomen: Sacral Promontory

MALE PELVIS
Plate 540
540. Male Pelvis: Bladder-Prostate Junction

THORAX
Plates 541–542
541. Thorax: Heart, Ascending Aorta
542. Thorax: Tracheal Bifurcation, Left Atrium

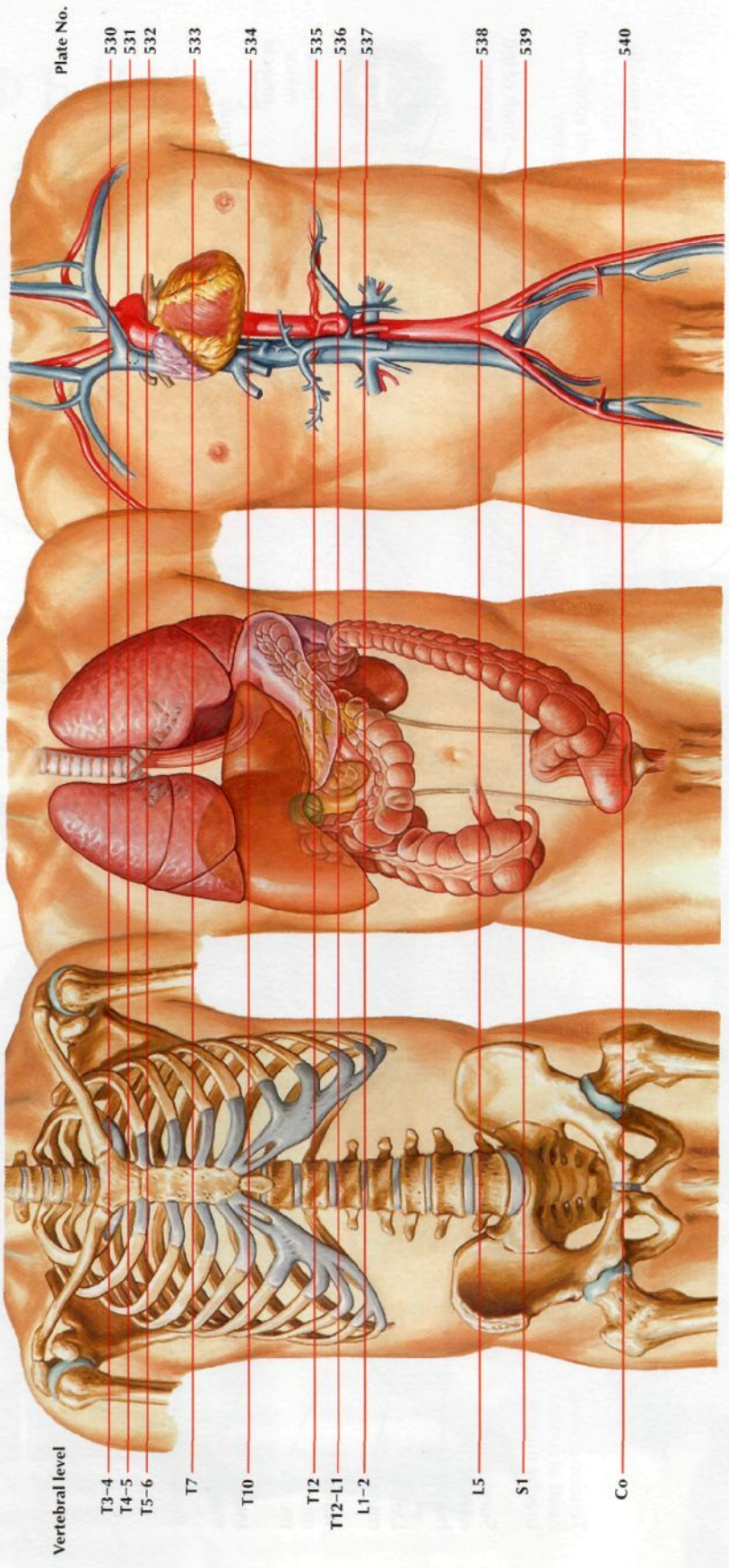
Plate No.
530
531
532
533
534
535
536
537
538
539
540
Vertebral level
T3–4
T4–5
T5–6
T7
T10
T12
T12–L1
L1–2
L5
S1
Co

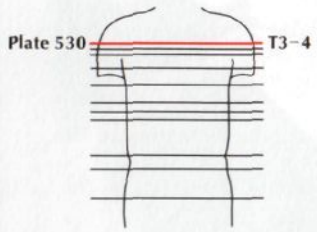

Transverse Section: Upper Level of T4, Sternoclavicular Joint

Mediastinal lymph node
Manubrium
Sternoclavicular joint (articular disc)
Brachiocephalic trunk
Clavicle
Trachea
Right brachiocephalic vein
Left brachiocephalic vein
Costal cartilage of 1st rib
Left common carotid artery
Pectoralis major muscle
Left vagus nerve (X)
Right lung
Pectoralis minor muscle
Axillary fossa
Left subclavian artery
Tendon of long head of biceps brachii muscle
Shaft of left humerus
Surgical neck of right humerus
Long head of triceps brachii muscle
Deltoid muscle
Teres minor muscle
Teres minor muscle
Intercostal muscles
Scapula
Subscapularis muscle
Left lung
Infraspinatus muscle
Phrenic nerve
Serratus anterior muscle
Right vagus nerve (X)
Left recurrent laryngeal nerve
Esophagus
Thoracic duct
Rhomboid major muscle
Erector spinae muscle
Costotransverse joint
Trapezius muscle
Rhomboid major muscle
Body of T4 vertebra
Spinal cord
Transversospinalis muscle

C. Machado, M.D.
© ICON

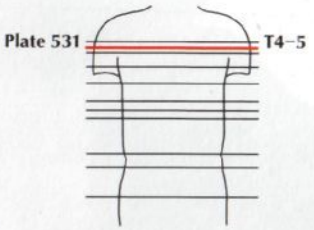

Transverse Section: T4–5 Intervertebral Disc, Manubrium

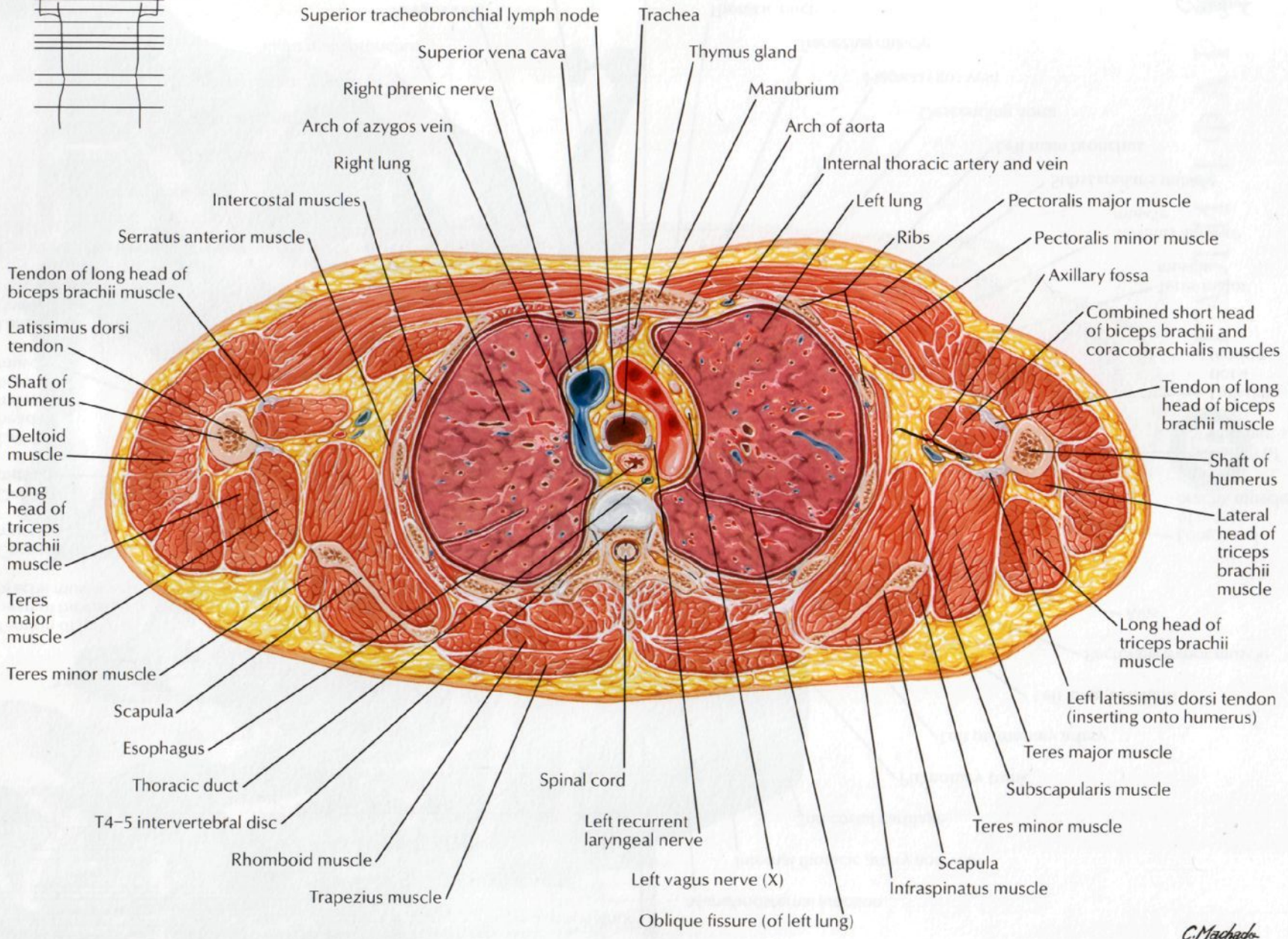

C. Machado M.D.
© ION

Transverse Section: T5–6 Intervertebral Disc, Sternal Angle

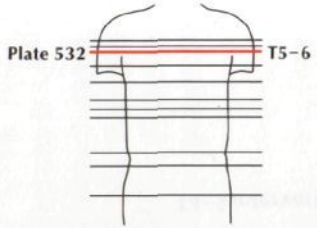

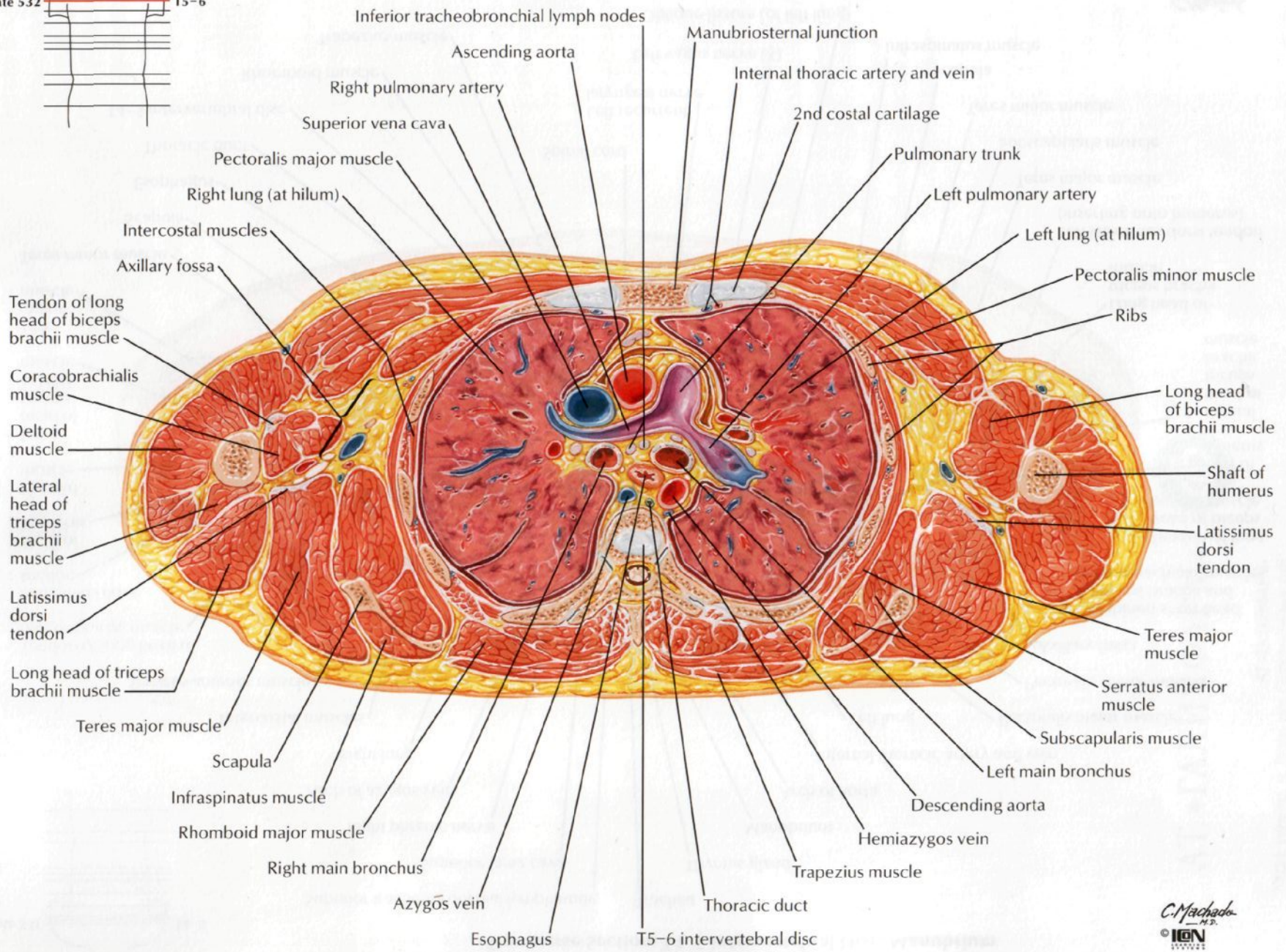

C. Machado M.D.
© ICN

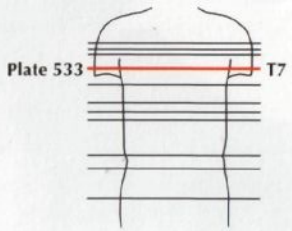

Transverse Section: Level of T7, 3rd Interchondral Space

Orifice of tricuspid valve
Groove for coronary artery
Sternum (body)
Internal thoracic artery and vein
Right ventricle
Left atrium
Anterior interventricular groove
Right atrium
Pectoralis major muscle
Interatrial septum
Apex of heart
Superior vena cava
Interventricular septum
Right inferior pulmonary vein
Papillary muscle
Esophagus
Left ventricle
Azygos vein
Leaflet of mitral valve
Serratus anterior muscle
Coronary groove
Latissimus dorsi muscle
Coronary sinus
Inferior angle of scapula
Oblique pericardial sinus
Descending aorta
Thoracic duct
Latissimus dorsi muscle
Triangle of auscultation
Triangle of auscultation
Neck of 7th rib
Head of 7th rib
Zygapophyseal (facet) joint
Body of T7 vertebra
Trapezius muscle

C. Machado M.D.
©IGN

Abdomen: Esophagogastric Junction

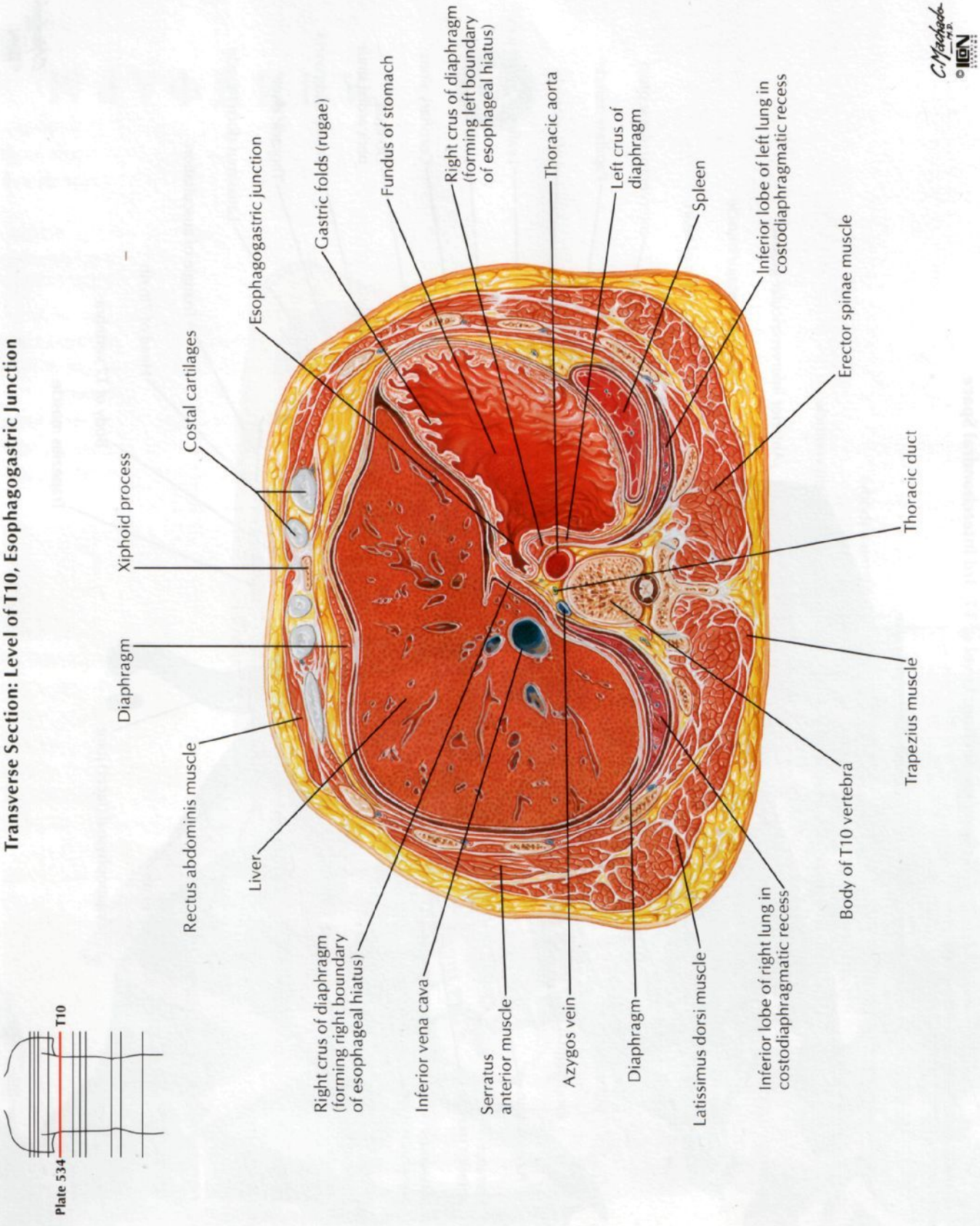

Abdomen: Origins of Celiac Artery and Portal Vein

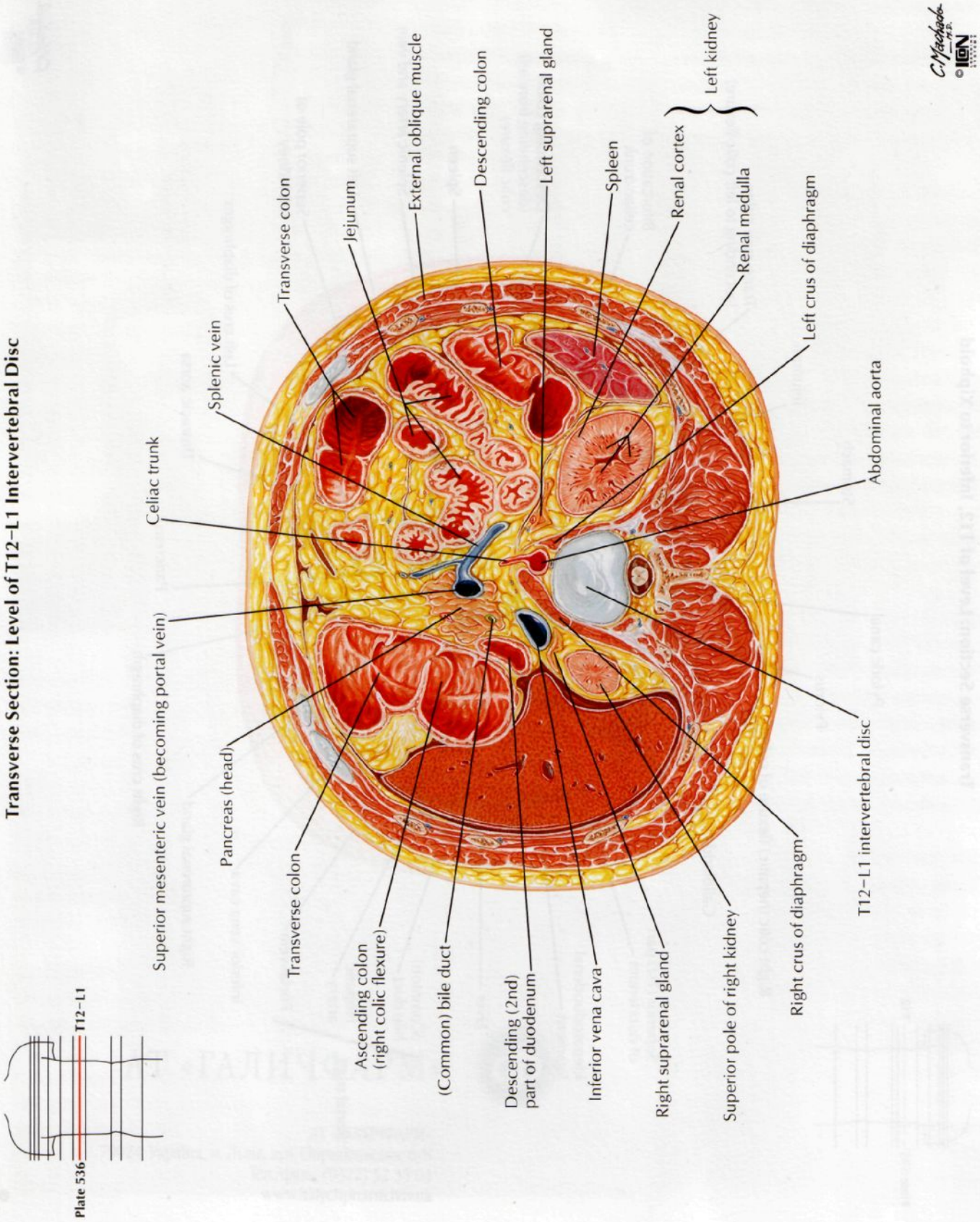

Transverse Section: Level of T12, Inferior to Xiphoid

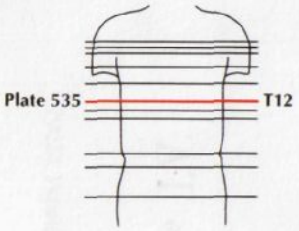

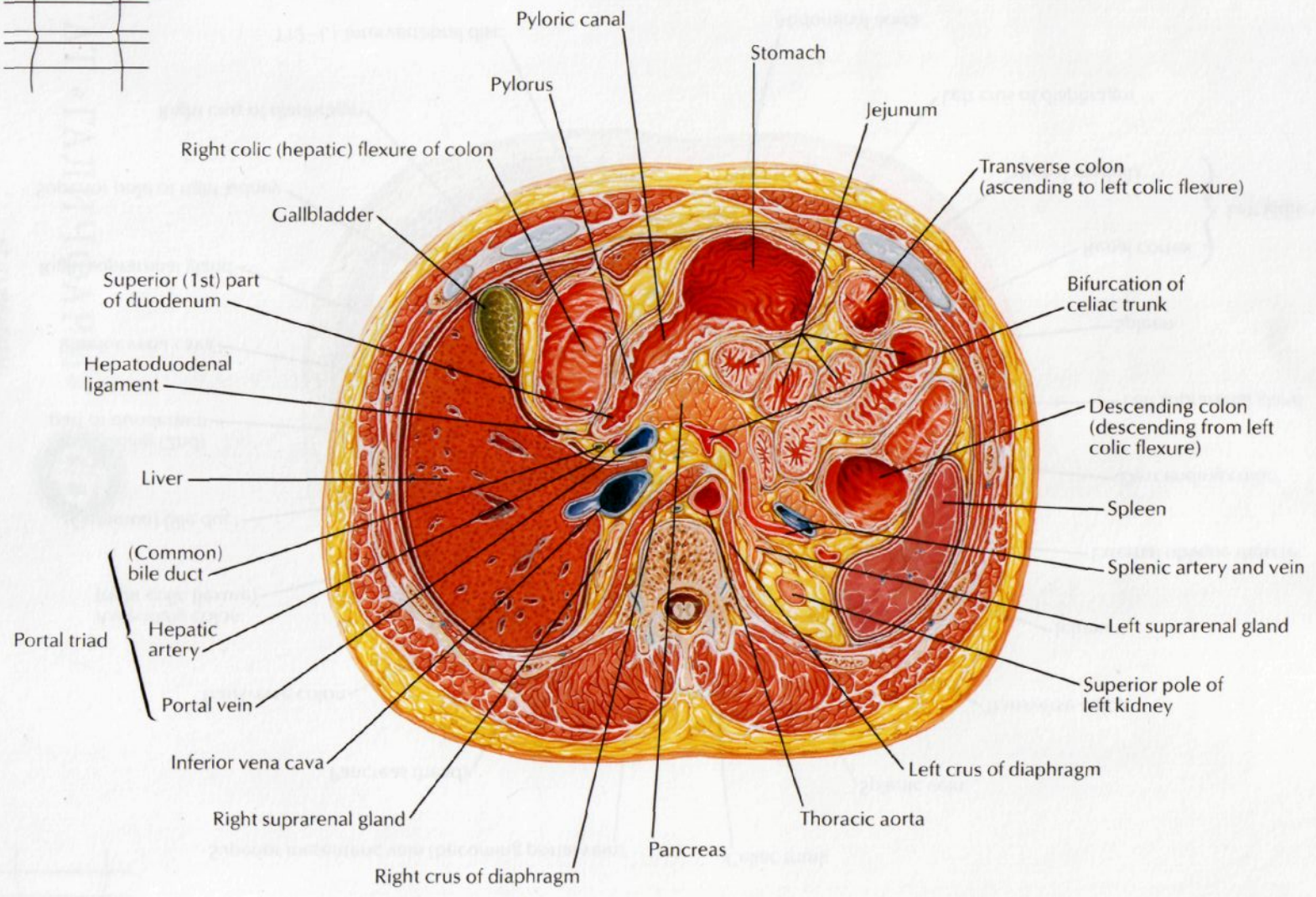

C. Machado M.D.
©IGN

Transverse Section: Level of L1–2 Intervertebral Disc

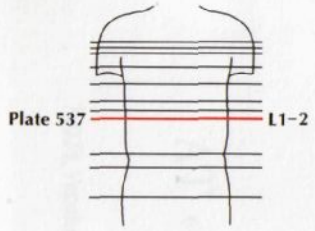

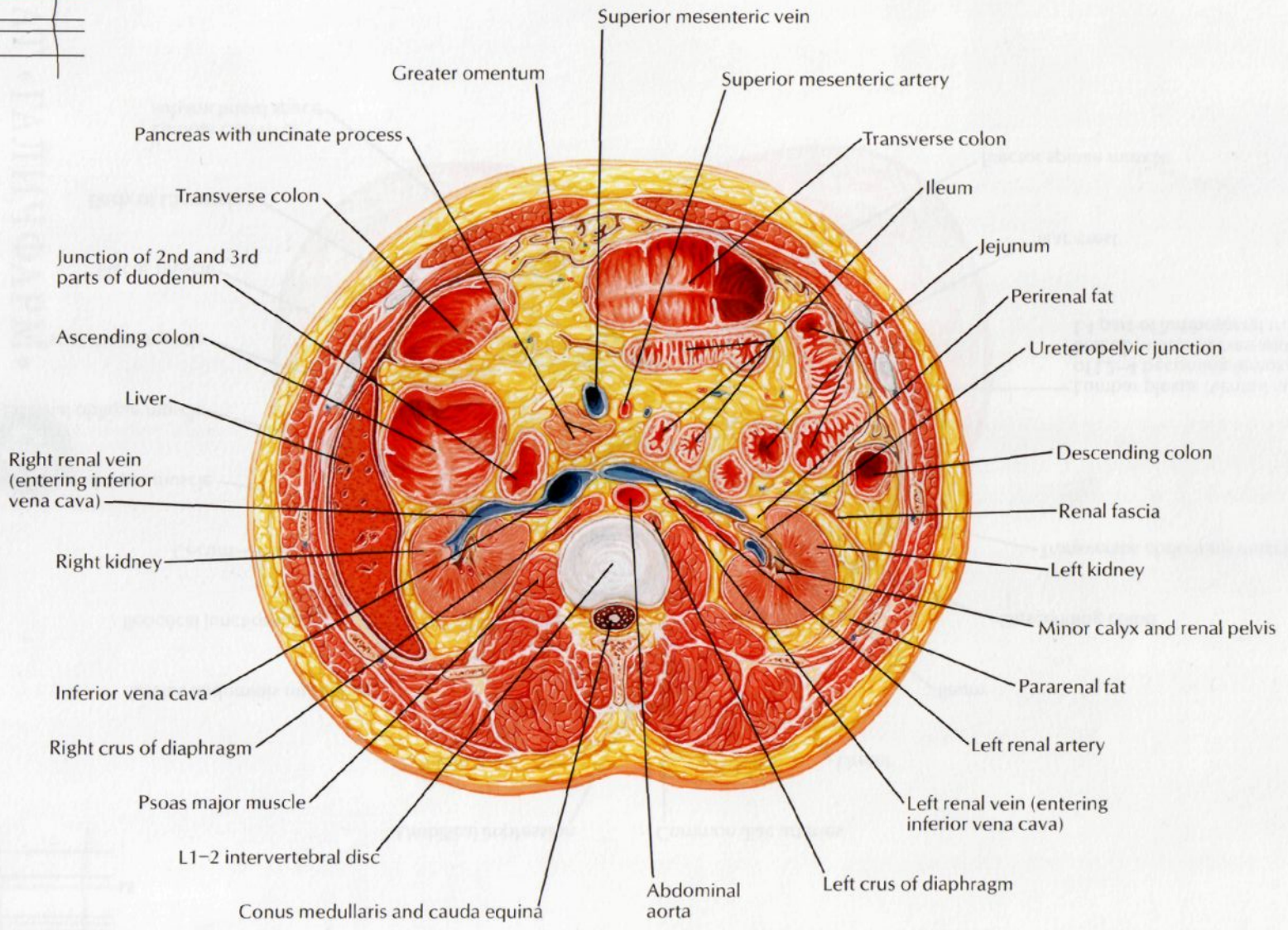

C. Machado M.D.

© ICN

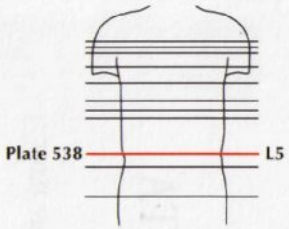

Transverse Section: Level of L5, Near Transtubercular Plane

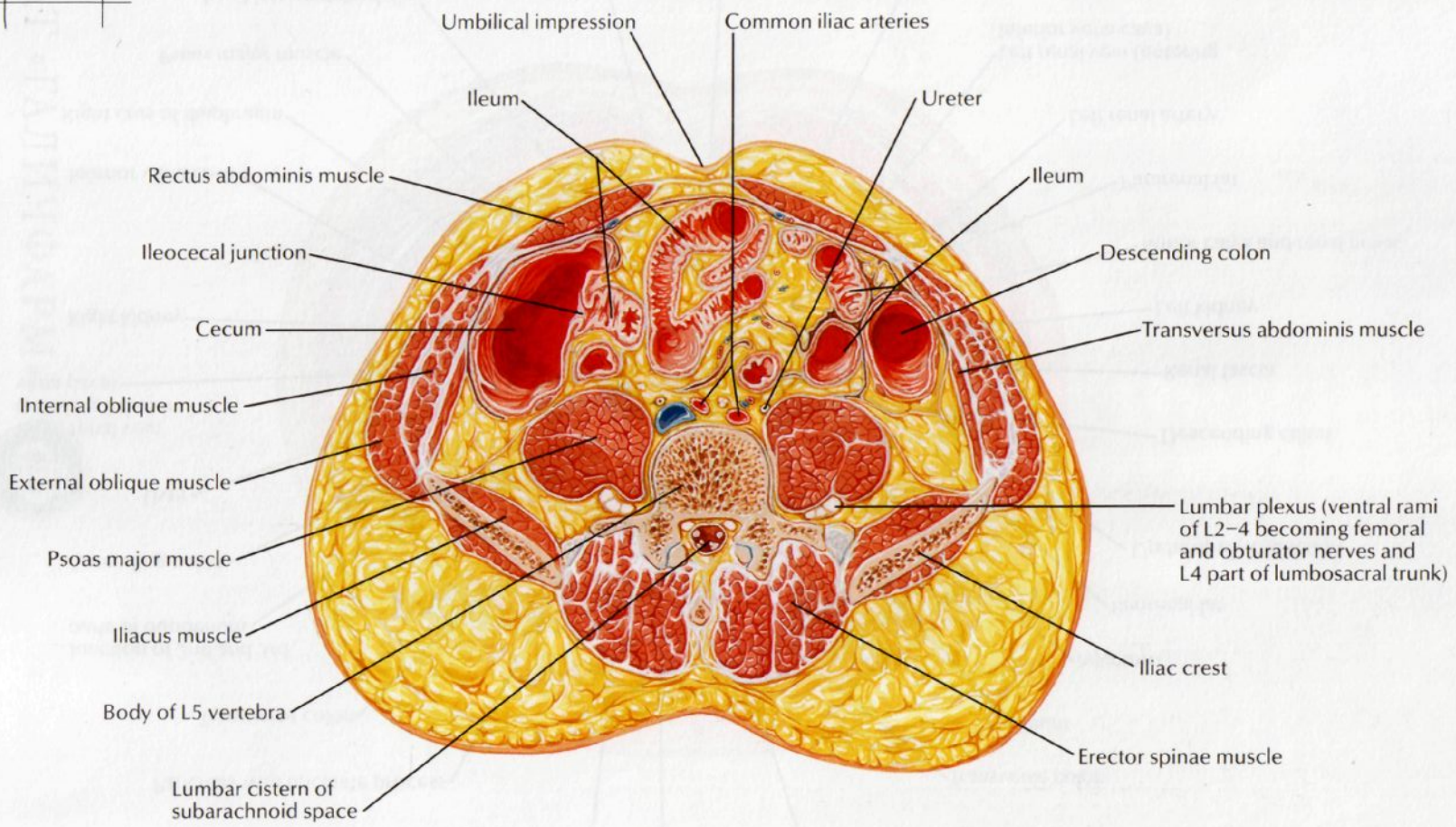

C. Machado M.D.

©IGN

Transverse Section: Level of S1, Anterior Superior Iliac Spines

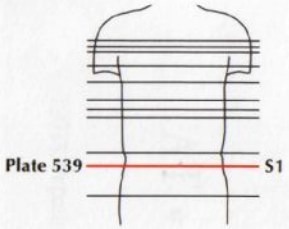

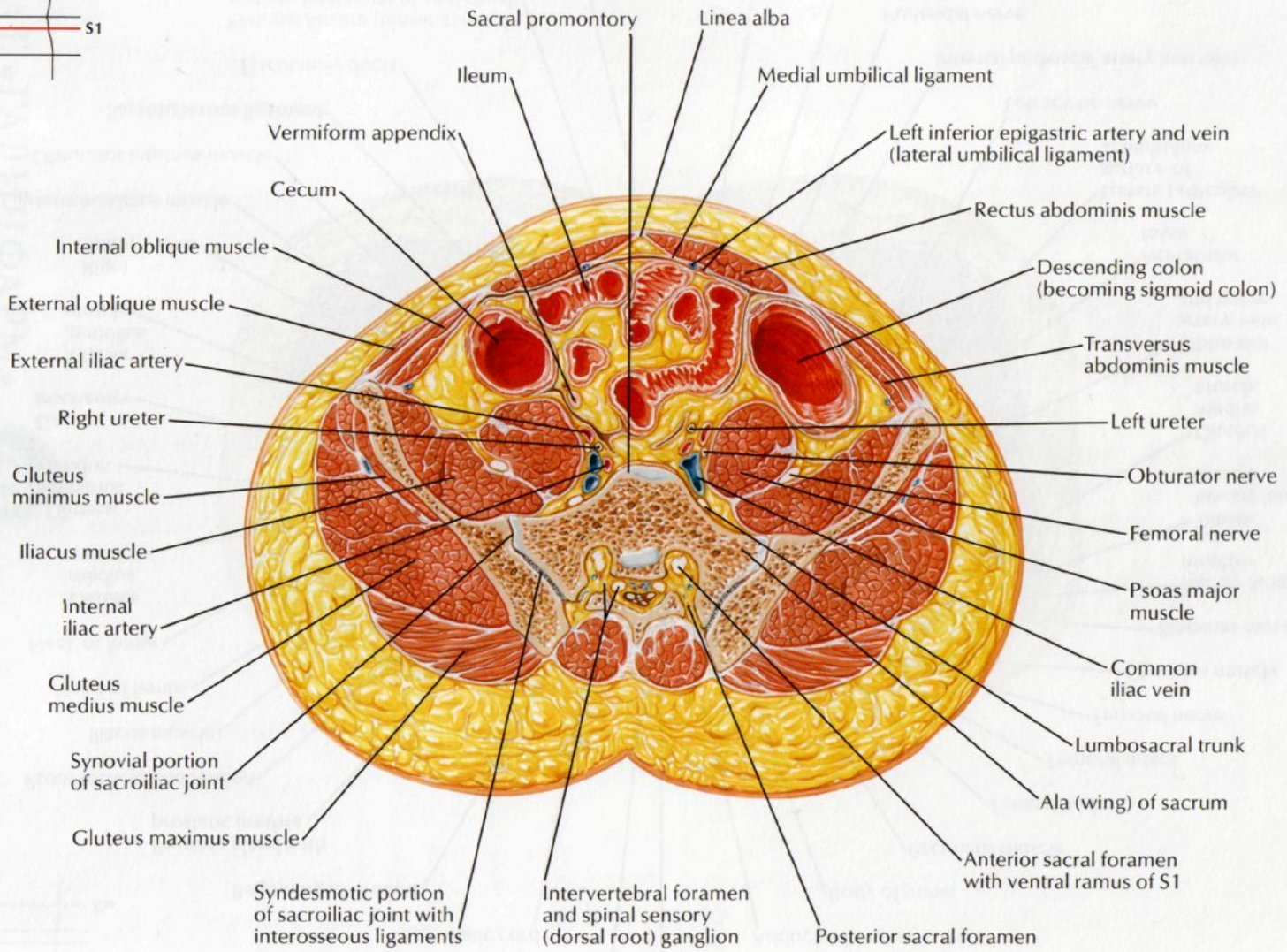

C. Machado, M.D.

© IGN

Transverse Section: Pubic Crest, Femoral Heads, Coccyx

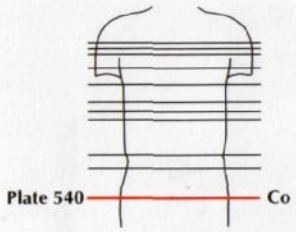

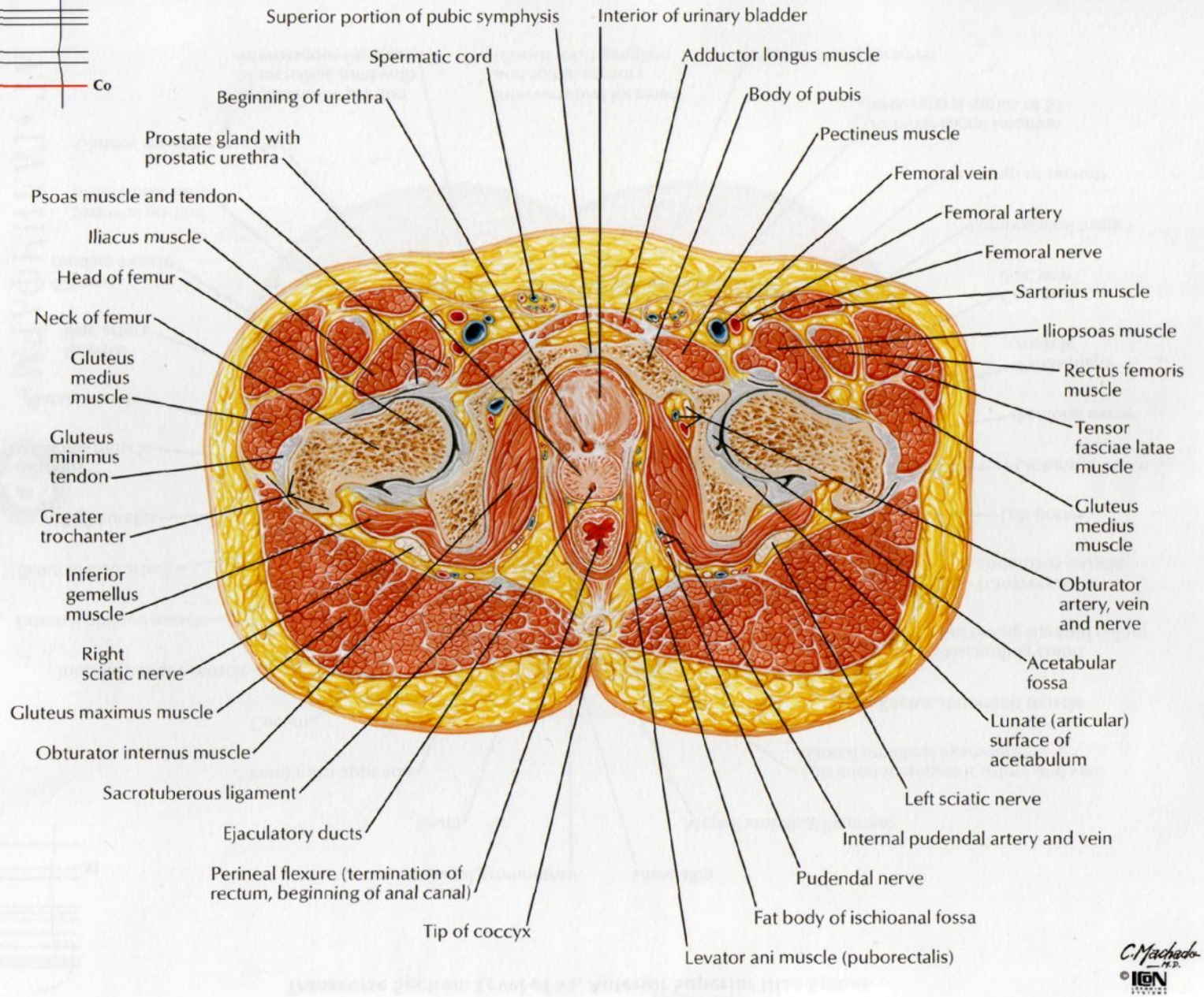

C. Machado, M.D.

© IGN

Coronal Section: Anterior Axillary Line

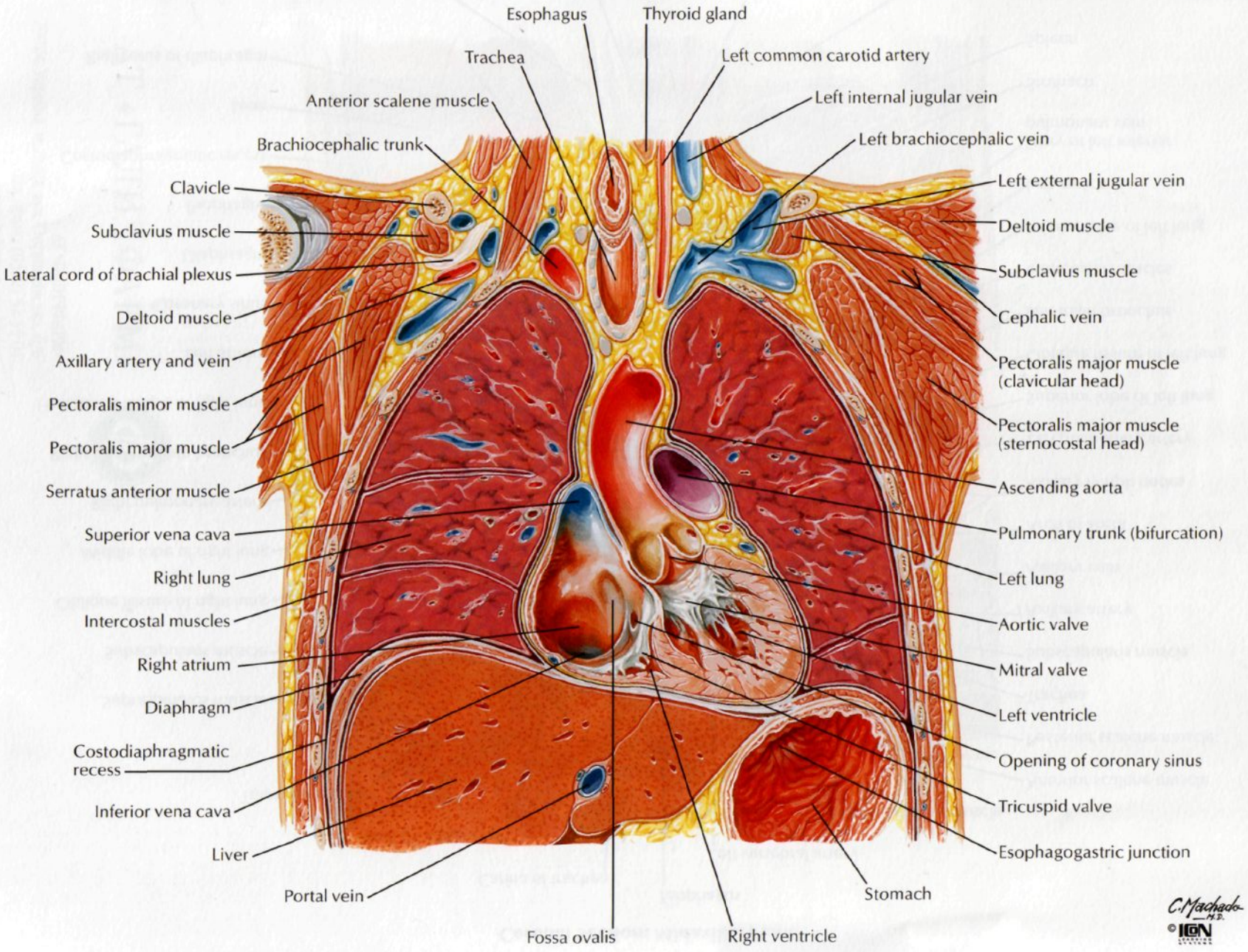

Thorax: Tracheal Bifurcation, Left Atrium

Coronal Section: Midaxillary Line

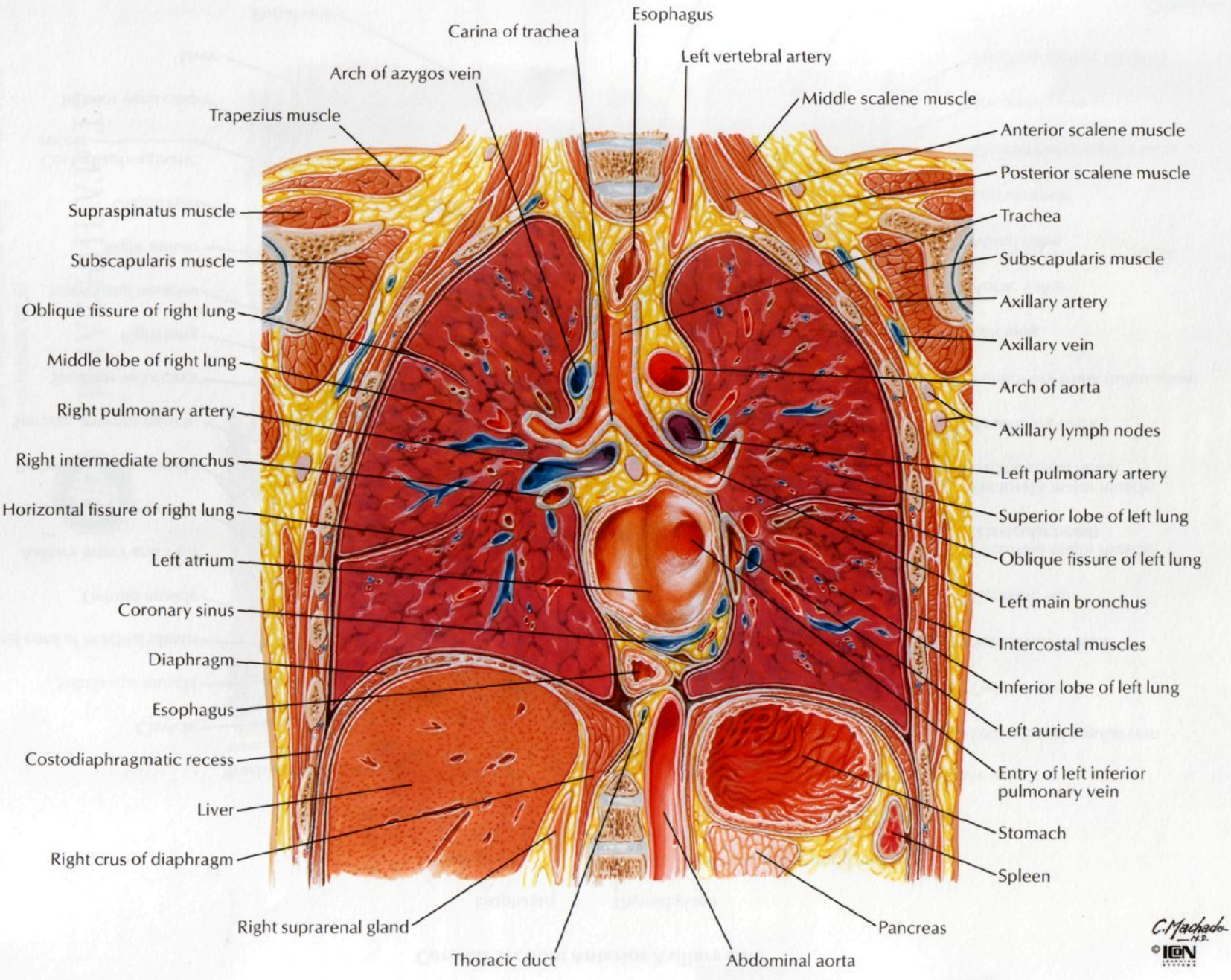

Frank H. Netter, M.D.

Frank H. Netter was born in 1906 in New York City. He studied art at the Art Student's League and the National Academy of Design before entering medical school at New York University, where he received his M.D. degree in 1931. During his student years, Dr. Netter's notebook sketches attracted the attention of the medical faculty and other physicians, allowing him to augment his income by illustrating articles and textbooks. He continued illustrating as a sideline after establishing a surgical practice in 1933, but he ultimately opted to give up his practice in favor of a full-time commitment to art. After service in the United States Army during World War II, Dr. Netter began his long collaboration with the CIBA Pharmaceutical Company (now Novartis Pharmaceuticals). This 45-year partnership resulted in the production of the extraordinary collection of medical art so familiar to physicians and other medical professionals worldwide.

Icon Learning Systems acquired the Netter Collection in July 2000 and continues to update Dr. Netter's original paintings and to add newly commissioned paintings by artists trained in the style of Dr. Netter.

Dr. Netter's works are among the finest examples of the use of illustration in the teaching of medical concepts. The 13-book Netter Collection of Medical Illustrations, which includes the greater part of the more than 20,000 paintings created by Dr. Netter, became and remains one of the most famous medical works ever published. The Netter Atlas of Human Anatomy, first published in 1989, presents the anatomical paintings from the Netter Collection. Now translated into 11 languages, it is the anatomy atlas of choice among medical and health professions students the world over.

The Netter illustrations are appreciated not only for their aesthetic qualities, but more importantly, for their intellectual content. As Dr. Netter wrote in 1949, ". . . clarification of a subject is the aim and goal of illustration. No matter how beautifully painted, how delicately and subtly rendered a subject may be, it is of little value as a medical illustration if it does not serve to make clear some medical point." Dr. Netter's planning, conception, point of view, and approach are what inform his paintings and what makes them so intellectually valuable.

Frank H. Netter, M.D., physician and artist, died in 1991.

REFERENCES

Plate 54

Braus H. Anatomie des Menschen. Berlin, Verlag von Julius Springer, 1924

Plate 85

Nishida S. The Structure of the Eye. New York, Elsevier North-Holland, 1982

Plates 110, 111, 121

Lachman N, Acland RD, Rosse C. Anatomical evidence for the absence of morphologically distinct cranial root of the accessory nerve in man. Clin Anat 2002;15:4

Plates 157, 465, 507, 525

Foerster O. The dermatomes in man. Brain 1933;56:1

Garrett FD. The segmental distribution of the cutaneous nerves in the limbs of man. Anat Rec 1948;102:409

Keegan JJ. J Neurosurg 1947;4:115

Plate 165

Turnbull IM. Blood supply of the spinal cord. In Vinken PJ, Bruyn GW (eds). Handbook of Clinical Neurology, XII. Amsterdam, North-Holland, 1972, pp 478-491

Plates 196, 197

Jackson CL, Huber JF. Correlated applied anatomy of the bronchial tree and lungs with a system of nomenclature. Dis Chest 1943;9:319

Plate 199

Ikeda S, Ono Y, Miyazawa S, et al. Flexible broncho-fiberscope. Otolaryngology (Tokyo) 1970;42:855

Plate 221

James TN. The internodal pathways of the human heart. Prog Cardiovas Dis 2001;43:495

Plates 245, 353, 355, 362, 366

Myers RP, King BF, Cahill DR. Deep perineal "space" as defined by magnetic resonance imaging. Presented at 14th Annual Scientific Session of the American Association of Clinical Anatomists, Honolulu, HI, 1997. (Abstract:Clin Anat 1998;11)

Plate 274

DiDio LJA. Anatomo-Fisiologia do Piloro ileo-ceco-colica no homen, Actas das Primeiras Jornadas Inter-universitarías Argentinas de Gastroenterologia, Rosario, 1954

———. Dados anatomicos sobre o "piloro" ileo-ceco-colico. (Com observacao direta in vivo de "papila" ileo-ceco-colica.) (English summary). Thesis, Fac Med, Univ de São Paulo, 1952

Plate 282

Healey JE Jr, Schroy. Anatomy of the biliary duct within the human liver; analysis of the prevailing pattern of branchings and the major variations of the biliary ducts. Arch Surg 1953;66:599

———, Sörensen. The intrahepatic distribution of the hepatic artery in man. J Int Coll Surg 1953;20:133

Plates 283, 284

Elias H. Liver morphology. Biol Rev 1955;30:263

———. Origin and early development of the liver in various vertebrates. Act Hepat 1955;3:1

———. Morphology of the liver. In "Liver Injury," Trans 11th Conference. New York, Macy Foundation, 1953

———. A re-examination of the structure of the mammalian liver; the hepatic lobule and its relation to the vascular and biliary system. Am J Anat 1949;85:379

———. A re-examination of the structure of the mammalian liver; parenchymal architecture. Am J Anat 1949;84:311

Plates 297, 298

Michels NA. Blood Supply and Anatomy of the Upper Abdominal Organs, With a Descriptive Atlas. Philadelphia, JB Lippincott, 1955

Plate 316

Thomas MD. In The Ciba Collection of Medical Illustrations, Vol 3, Part II. Summit NJ, CIBA, p 78

Plates 335, 348, 367, 377, 394

Stormont TJ, Cahill DR, King BF, Myers RP. Fascias of the male external genitalia and perineum. Clin Anat 1994;7:115

Plates 343, 347, 352, 355, 360, 361

Oelrich TM. The striated urogenital sphincter muscle in the female. Anat Rec 1983;205:223

Plates 346, 348

Myers RP, Goellner JR, Cahill DR. Prostate shape, external striated urethral sphincter and radical prostatectomy: the apical dissection. J Urol 1987;138:543

Plates 346, 348, 366, 367

Oelrich TM. The urethral sphincter muscle in the male. Am J Anat 1980;158:229

Plate 383

Flocks RH, Kerr HD, Elkins HB, et al. Treatment of carcinoma of the prostate by interstitial radiation with radio-active gold (Au198):A preliminary report. J Urol 1952;68(2):510

Plate 465

Keegan JJ, Garrett FD. The segmental distribution of the cutaneous nerves in the limbs of man. Anat Rec 1948;102:409

Plate 525

Keegan JJ. Neurological interpretation of dermatome hypalgesia with herniation of the lumbar intervertebral disc. J Bone Joint Surg 1944;26:238

Last RJ. Innervation of the limbs. J Bone Joint Surg 1949;31(B):452

INDEX

References are to plate numbers; numbers in bold refer to primary sources. In most cases, structures are listed under singular nouns.

A

Abdomen
arteries of 247, 256–see also arteries of individual organs
bony framework of 240
cross sections of 534–539
lymph vessels and nodes of 258, 304–306, 329–see also lymph nodes of individual organs
muscles of 241–246, 255
nerves of 249, 250, 259–see also nerves of individual organs
autonomic 308
planes of 260
quadrants of 260
regions of 260
veins of 248, 257–see also veins of individual organs
viscera of 261, 267–277–see also individual organs
Acetabulum 344, 468, 470
Achilles–see Tendon, Achilles; calcaneal
Acinus 200
Acromion 23, 178, 182, 186, 401, **403**–410, 412, 414, 415
Action of
extrinsic eye muscles 80
infrahyoid muscles 25
intrinsic laryngeal muscles 75
jaws 14
suprahyoid muscles 25
wrist 436
Adamkiewicz–see Artery, medullary, segmental, major anterior (Adamkiewicz)
Adam's apple–see Prominence, laryngeal
Adenohypophysis 133, 140
Adenoid–see Tonsil, pharyngeal
Adhesion, interthalamic 100, 102, 105, 109, 139
Aditus of larynx 59, 62, 231
Adnexa
of orbit–see Apparatus, lacrimal; Eyelids
of uterus 356
Adrenergic 161
synapsis–see Synapsis, adrenergic
terminal–see Terminal, adrenergic
Agger nasi 33, 34
Airway, intrapulmonary 200
Ala (wing)
of central cerebellar lobule–see Wing, of central (cerebellar) lobule
ilium 240, 340, 345, 468
of nose 1
sacrum 150, 539
vomer 8
Albini–see Nodule, fibrous, of mitral valve (Albini)
ALS–see System, anterolateral (ALS)
Alveolus of
lung 200, 201
pancreas 288
Alveus of hippocampus 106
Ampulla 271
of duodenum 271, 285
hepatopancreatic 287
of inner ear 87
labyrinthine 90, 118
of lactiferous duct 175
of semicircular duct 90, 118
of uterine tube 356
of Vater–see Ampulla, hepatopancreatic
of vestibule 91
Anastomosis
around
elbow 417
eye/orbit 81
knee 494
scapula 410
between
angular and dorsal nasal arteries 36, 81
carotid and vertebral arteries 131
cervical and occipital arteries 29
circumflex femoral arteries 486
external and internal carotid arteries 81, 131
inferior phrenic and left gastric arteries 297
intercostal and lumbar arteries 226, 247
lacrimal and middle meningeal arteries 95
median and ulnar nerves 458, 459, 478
pancreatic arteries 292–295
posterior septal branch of sphenopalatine artery and greater palatine artery 37
pubic branches of obturator and inferior epigastric arteries 251, 350, 351
right and left carotid arteries 131
right and left hepatic arteries 297
subclavian and carotid arteries 131
subclavian and vertebral arteries 131
superior and inferior mesenteric arteries (arc of Riolan) 298
paravertebral 165
portacaval 302
prevertebral 165
scapular 410
Anesthesia perineal 393
Angiogram, coronary–see Arteriogram of coronary arteries
Angle
anterior chamber of eye–see Angle, iridocorneal
iridocorneal 83, 84, 86
of jaw 1
of Louis–see Angle, sternal
of mandible 12, 13, 62
of mastoid 9
of rib 178, 179
Angle *cont.*
of scapula 403, 404, 533
sternal 178
subpubic 342
tuber 507
Ankle
bones of 505–507
ligaments of 509
lymph nodes of 528
tendinous sheaths of 511
tendons of 509
Anoderm 374
Anomaly of
cervical ribs 181
right inferior laryngeal nerve 76
right subclavian artery 76
Ansa
cervicalis 27, **28,** 30, 67, 70, 122, 123
subclavia 124, 205, 222, 223, 236
Anteflexion of uterus 358
Antihelix of external ear 1, 88
Antitragus of external ear 1, 88
Antrum
mastoid 89
pyloric 267, 271
tympanic 89
Anulus fibrosus
of heart–see Ring, fibrous, of heart
of intervertebral disc 148
Anus 347, 359, 363, 365, 376, 378, 398
Aorta 238, 338
abdominal 172, 189, 225, 228, 255, **256,** 262, 265, 266, 270, 288, 290, 292, 299, 314, 317, 319, 320, 322, 328, 332, 333, 335–337, 349, 350, 354, 378, 380–383, 392, 536, 537, 542
ureteric branches 328
arch of 31, 70, 71, 76, 131, 192, 202, 203, 206–211, 216, 217, 221, 225, 227, **228,** 229, 233, 531, 542
ascending 131, 211, 216, 219, 220, 532, 541
descending 131, 188, 203, 227, 228, 233, 237, 532, 533
thoracic 163, 165, 187, 225, 227, 229, **233,** 534, 535
esophageal branches 233
ureteric branch 328
Aperture–see also Opening
lateral, of 4th ventricle (Luschka) 102, 103, 139
median, of 4th ventricle (Magendie) 102, 103, 109, 139
Apex of
bladder 348
fibula 495, 496
heart 208–210, 533
lung 192, 193, 195
sacrum 150
tongue 54
Aponeurosis
bicipital 414, 416, 429, 456, 463
epicranial (galea aponeurotica) 19, 22, 96, 171

Aponeurosis *cont.*
external abdominal oblique 241–244, 249, 252, 336, 337
gluteal 320, 476, 477, 484
internal abdominal oblique 243, 244, 249, 337
oblique
external 254
internal 254
palatine 48, 61
palmar 425, 429, 430, 437, 442, 443, 445, 463
pharyngeal 61, 63, 231
plantar 511, 514–517
of scalp–see Aponeurosis, epicranial (galea aponeurotica)
transversus abdominis 168, 169, 172, 244, 246, 247, 320, 332, 335
Apparatus
lacrimal 78
Appendage, atrial–see Auricle, of left atrium; of right atrium
Appendix
epididymidis 370, 399
epiploic–see Appendix, omental
fibrous, of liver 279
omental (epiploic) 263, 276, 337
of testis 374, 406
vermiform 120, 263, 274, **275,** 276, 349, 350, 539
vesicular 356, 399
Aqueduct
cerebral 100, 102, 103, 109, 139
cochlear 91
of Sylvius (midbrain aqueduct) 100, 102, 103, 109
vestibular 90–92
Arachnoid
granulation 94–96, 103
mater 94, 96, 103, 162, 163
Arantius, nodules of–see Nodule, of semilunar valve
Arc
omental (epiploic) arterial 297
of Riolan–see Anastomosis, between superior and inferior mesenteric arteries
Arch
anterior, of atlas 15, 16, 59
aortic 209
lumbocostal, of diaphragm 189, 255–see also Ligament, arcuate, of diaphragm
of obturator fascia–see Arch, tendinous, of levator ani muscle
palatoglossal 47, 54, 56, 60
palatopharyngeal 47, 54, 56, 60, 62
of pelvic diaphragm–see Arch, tendinous, of levator ani muscle
of pelvic fascia–see Arch, tendinous, of pelvic fascia
pharyngopalatine–see Arch, palatopharyngeal
posterior, of atlas 15, 16, 171
Arch *cont.*
pubic 240, 342
of soleus muscle–see Arch, tendinous, of soleus muscle
superciliary 1
tendinous
of levator ani muscle 245, 255, 343–**346,** 351–353, 355, 361, 373
of pelvic fascia 47, 353
of soleus muscle 499, 500
zygomatic 4, 12, 50
Arch (arterial)
of aorta 70, 71, 76, 131, 202, 206–208, 210, 211, 217, 227, 228, 233, 531, 542
deep
palmar 448, 449
plantar 502, 513, 518
dorsal carpal 452
palmar carpal 448
palpebral 81
superficial palmar 443, 444, 449, 456
Arch (venous)
of azygos vein 531, 542
dorsal
of foot 526
of hand 455, 463
superficial palmar 443
Area
bare
of diaphragm 266, 279, 319
of liver 279, 319, 332, 335
of pericardium 192
cribriform, of kidney 329
intercondylar, of tibia 495, 496
of Laimer 71, 230, 231
of liver–see Segment, of liver
parolfactory 100, 113
pontine taste 129
of referred pain
biliary 317
pancreatic 318
septal (pellucidum) 113
subcallosal 100, 113
vestibular, of 4th ventricle 109
Arm
arteries of 416, 417, 456
bones of 403, 404
cross sections of 418
fascia/fascial compartments 418, 462
lymph nodes and vessels of 466
muscles of 414, 415
nerves of 456, 457, 460, 462
Arteria recta–see Artery, straight of small intestine
Arteriogram of coronary arteries 214, 215
Arteriole
of kidney
afferent 325, 326
aglomerular 326
cortical radiate 323, 326
efferent 325, 326
interlobular–see Arteriole, of kidney, cortical radiate
Arteriole *cont.*
of liver
intralobular 283
periportal 283
portal 283
macular (of retina) 86
nasal (of retina) 86
temporal (of retina) 86
Artery
of abdominal wall 247, 256
accessory
hepatic 297, 298
left gastric 297
meningeal 36, 95
middle colic 300
renal 324
acetabular–see Artery, obturator, acetabular branch
acoustic, internal–see Artery, labyrinthine
acromial–see Artery, thoracoacromial, acromial branch
of Adamkiewicz–see Artery, medullary, segmental, major anterior
alveolar
anterior superior 36
inferior 36, 49, 56, 65, 66
lingual branch 65
mental branch 36, 65
mylohyoid branch 36, 65
middle superior 36
posterior superior 36, 65
of anal canal 378
angular (of face) 19, 32, 36, 65, 81, 131–see also Artery, cerebral, middle, branch to angular gyrus
anomalous right subclavian 76
anterolateral central (lenticulostriate) 132–134, 136
anteromedial central (perforating) 133
aortic intercostal–see Artery, intercostal, posterior
appendicular 273, 295, 296, 302, 312
arcuate
of arm 416, 417, 456
of foot 502, 512, 513, 518
of kidney 323, 326
ascending
branch–see under Artery, iliac, circumflex, deep; femoral, circumflex, lateral; humeral, circumflex, posterior
cervical–see Artery, cervical, ascending
frontal–see Artery, prefrontal
palatine–see Artery, palatine, ascending
pharyngeal–see Artery, pharyngeal, ascending
atrial, anterior right–see under Artery, coronary, right
atrioventricular–see under Artery, coronary, left, circumflex branch of
of atrioventricular node–see Artery, coronary, right, atrioventricular (AV) nodal branch

Artery *cont.*
auricular
anterior–see Artery, temporal, superficial, anterior auricular branch
deep 36
posterior 19, 30, 36, 65, 95, 130, 131, 171
axillary 176, 183, 194, 247, **410**–412, 416, 541, 542
basal 143
basilar 130–134, 136, 164
brachial 176, 410, 412, 414, **416**–418, 429–431, 456
deep–see Artery, deep, of arm (deep brachial) muscular branches of 416
brachiocephalic–see Trunk (arterial), brachiocephalic
of brain 130–136, 141
bronchial 195, 201, **203,** 226, 227, 233
esophageal branches 233
variations in 203
buccal 36, 65
of bulb
of penis 385
of vestibule 355, 384
calcaneal 498, 499
lateral–see Artery, fibular (peroneal), (lateral) calcaneal branch
medial–see Artery, tibial, posterior, calcaneal branch
calcarine–see Artery, cerebral, posterior, calcarine branch
callosomarginal 134, 135
medial frontal branches 134, 135
candelabra–see Artery, prefrontal
capsular
of kidney 326
of liver 297
caroticotympanic 131
carotid 30
common 19, 26–**30,** 65–67, 70–72, 76, 119, 122, 124, 125, 127, 128, **130,** 131, 184, 190, 194, 202, 206, 207, 210, 228, 233, 530, 542
external 19, 24, 25, 27–**30,** 36, 37, 55–57, 65–67, 70–72, 95, 119, 124, 125, 127, 128, **130,** 131
internal 19, 28–**30,** 31, 40, 43, 56, 65, 67, 70–72, 81, 82, 89, 93, 95, 98, 115, 117, 119, 122, 124–128, **130,** 131–136
cavernous branch of 95
meningeal branch of 95
meningohypophyseal trunk of 95
tentorial branch of 95, 98
carpal–see carpal branches under Artery, radial; ulnar
of cauda equina 164
of cavernous sinus–see Artery, carotid, internal, cavernous branch of
cecal 273, 295, 296, 302, 313
celiac–see Trunk (arterial), celiac
central
anterolateral (lenticulostriate) 132, 134, 136
anteromedial (perforating) 133
Artery *cont.*
posteromedial (perforating) 133
of retina–see Artery, retinal, central
sulcal (Rolandic), of brain–see Artery, sulcal, central (Rolandic)
cerebellar
anterior inferior 130–134, 136, 164
posterior inferior 130–132, 134, 136, 164
cerebellar tonsillar branch 136
choroidal branch to 4th ventricle 136
superior 130–134, 136, 164
superior vermian branch 136
cerebral
anterior 130–136
terminal branches 135
middle 130, 132–136
branch to angular gyrus 134, 135
temporal branches 135
terminal branches (trunks) 135
posterior 130–136
calcarine branch 135, 136
dorsal branch to corpus callosum 135, 136
parietooccipital branch 135, 136
temporal branches 135
terminal branches 135
cervical
ascending 29, 65, 67, 70–72, 130, 131, 164
deep 29, 130, 131, 164
transverse 28, 29, 65, 70–72, 131, 170, 410, 412
choroidal
anterior 132–134, 136
posterior
lateral 132, 136
medial 132, 136
to 4th ventricle–see Artery, cerebellar, posterior inferior, choroidal branch to 4th ventricle
ciliary
anterior 86
posterior 81, 86
cingular 135
of Circle of Willis 133
circumflex
coronary–see Artery, coronary, left, circumflex branch of
femoral–see Artery, femoral, circumflex
fibular–see Artery, tibial, posterior, circumflex fibular branch
humeral–see Artery, humeral, circumflex
iliac–see Artery, iliac, circumflex
scapular–see Artery, scapular, circumflex
clavicular–see Artery, thoracoacromial, clavicular branch
of clitoris
deep 384
dorsal 384
colic 298
branch of ileocolic–see Artery, ileocolic, colic branch
Artery *cont.*
left 256, 296, 298, 308, 313, 314, 327, 378
large branch replacing middle colic 298
middle 288, 291, 292, 295, 296, 298, 312, 313, 335
common trunk with right colic 298
right 295, 296, 298, 312, 313, 327, 337
common trunk
with ileocolic 298
with middle colic 298
variations in 298
collateral
of gallbladder 297
of liver 297
medial 415, 417, 428
radial 415, 417, 418
ulnar
inferior 416, 417, 428
superior 416–418, 428
communicating
anterior 130–135
posterior 98, 130–136
of conjunctiva 86
of conus arteriosus–see Artery, coronary (in general), right, conus branch
coronary (in general) 212, 213
left 212, 213, 215
anterior descending (LAD)–see Artery, coronary (in general), left, anterior interventricular branch of
anterior interventricular branch of 208, 212, 213, 215
interventricular septal branch 212
circumflex branch of 212, 213, 215
atrioventricular branch of 215
lateral branch of 215
posterolateral branch of 215
marginal–see Artery, coronary (in general), right, right marginal branch
posterior descending–see Artery, coronary (in general), right, posterior interventricular branch
right 208, 210, 212–214
anterior right atrial branch 212
conus branch 214
posterior interventricular branch 210, 212, 214
atrioventricular (AV) nodal branch 214, 218
interventricular septal branch 212
right marginal branch 212, 214
sinuatrial (SA) nodal branch 212, 214
right marginal–see Artery, coronary (in general), right, right marginal branch
cortical radiate (interlobular) of kidney 323, 326
costocervical–see Trunk (arterial), costocervical
of cranial fossa, posterior 136
cremasteric 243, 245, 247, 252, 253, 256, 381

Artery *cont.*
cricothyroid–see Artery, thryoid, superior, cricothyroid branch
cystic 285, 290, 292, 297
deep
of arm (deep brachial) 409, 412, 415, 418
of clitoris 384
of penis 364, 366, 368, 385
of thigh (deep femoral) 482–484, 486, 487, 494
muscular branches 494
perforating branches 484, 494
deferential–see Artery, to ductus deferens
deltoid–see Artery, thoracoacromial, deltoid branch
descending
branch of
lateral femoral circumflex–see Artery, femoral, circumflex, lateral
posterior humeral circumflex–see Artery, humeral, circumflex, posterior
coronary–see Artery, coronary, left, anterior interventricular branch; right, posterior interventricular branch
genicular–see Artery, genicular, descending
palatine–see Artery, palatine, descending
digital (foot)
common plantar 515, 516, 518
dorsal 502, 512, 513, 518
proper plantar 502, 512–515, 518
digital (hand)
common palmar 442, 443, 445, 448, 449
dorsal 452, 454
proper palmar 442, 443, 445, 449, 454
dorsal
branch to corpus callosum–see Artery, cerebral, posterior, dorsal branch to corpus callosum
of clitoris 384
of foot 502, 512, 513, 518
of penis 247, 364, 366, 381, 383
scapular–see Artery, scapular, dorsal
dorsalis pedis–see Artery, dorsal, of foot
of Drummond–see Artery, marginal (juxtacolic, of Drummond)
to ductus deferens 247, 256, 327, 370, 378, 381, 383
branch from inferior vesicle artery 256, 327, 378, 381
of duodenum 288, 289
of elbow 417, 456
epigastric
inferior 243, 245, 247, 251, **252,** 256, 266, 328, 337, 349–351, 378, 380, 381, 383, 494
cremasteric branch–see Artery, cremasteric
pubic branch 243, 245, 252, 256, 350, 351
superficial 241, 243, 247, 256, 482, 494
superior 182–184, 187, 207, 243, 247, 336
episcleral 86

Artery *cont.*
esophageal branch from
aorta–see Aorta, thoracic, esophageal branch
bronchial–see Artery, bronchial, esophageal branch
inferior phrenic–see Artery, phrenic, inferior, esophageal branch
inferior thyroid–see Artery, thyroid, inferior, esophageal branch
left gastric–see Artery, gastric, left, esophageal branches
ethmoidal
anterior 37, 81, 95
anterior meningeal branch 81, 95
anterior septal branch 37
nasal (external and anterior lateral) branch 37
posterior 81, 95
lateral nasal branch 37
septal branch 37
of eye 86–see also Artery, ophthalmic
of eyelids 81
facial **19,** 27, 28, 30, 32, 36, 43, 56, 57, 65, 66, 71, 81, 125, 127, 130, 131
inferior labial branch 65
lateral nasal branch 37
alar branch 37
superior labial branch 65
nasal septal branch 37
tonsillar branch (tonsillar artery) 36, 60, 65
transverse 19, 30, 32, 57, 65, 81
femoral 243, 247, 252, 253, 256, 363, 381, 387, 475, 482, 483, 486, 487, **494,** 528, 540
circumflex
lateral 482, 483, 486, 494
ascending branch 486, 494
descending branch 486, 494
tranverse branch 486, 494
medial 483, 484, 486, 494
deep–see Artery, deep, of thigh (deep femoral)
muscular branch 494
of proximal femur 486
fibular (peroneal) 494, 498–500, 504, 512
communicating branch 500
(lateral) calcaneal branch 498–500, 516, 517
perforating branch 500, 501
posterior lateral malleolar branch 500
of foot 513, 515–518
of forearm 456
foveolar–see Artery, obturator, acetabular branch to ligament of femoral head
frontal
ascending (middle cerebral)–see Artery, prefrontal
branch of middle meningeal–see Artery, meningeal, middle, frontal branch
branch of superficial temporal–see Artery, temporal, superficial, frontal branch
medial frontal branch–see Artery, callosomarginal, medial frontal branches
polar (frontopolar) 134, 135
frontobasal (orbitofrontal) 132, 134, 135
frontopolar–see Artery, frontal, polar (frontopolar)
gastric
accessory left 297
left 233, 256, 264, 266, 290, **291**–293, 295, 297, 308–313, 335, 336, 390
esophageal branch 233, 236, 290, 291
right 271, 285, 290–293, 295, 297, 309–312
short 266, 289–292, 295, 297, 336
gastroduodenal 271, 285, 291–295, 297, 299, 310–312, 317
gastroepiploic–see Artery, gastro-omental (gastroepiploic)
gastro-omental (gastroepiploic)
left 264, 288–292, 295, 309–311
right 264, 266, 290–292, 295, 297, 309–311
genicular
descending 482, 483, 487, 494
articular branch 482, 483, 494
saphenous branch 482, 483, 494
lateral
inferior 494, 498–503
superior 484, 494, 498–503
medial
inferior 482, 483, 494, 499–502
superior 482–484, 498–502
middle 494
gluteal
inferior 256, 328, 378, 382, 383, 481, 484
superior 256, 328, 378, 382, 383, 481, 484
of hand 449, 452, 456
of head of femur 486
of heart 212–215
hemorrhoidal–see Artery, rectal
hepatic
accessory 297
common 256, 264, 271, 285, **290**–297, 308, 311, 317, 336, 535
intermediate 292
left 285, 292, 297
accessory/replaced 297
proper 266, 270, 271, 279–282, 285, 288, 290–**292,** 293, 294, 297, 307, 311, 335, 336
replaced 297
right 285, 292, 297
accessory/replaced 297
of Heubner–see Artery, striate, distal medial (recurrent artery of Heubner)
of hip 486, 494
humeral
circumflex
anterior 410, 412, 414, 416, 417
posterior 410, 412, 415–417
ascending and descending branches 410
hypogastric–see Artery, iliac, internal
hypophyseal 133, 141

Artery *cont.*
hypothalamic 133, 141
ileal 273, 295, 296, 300
branch from ileocolic–see under Artery, ileocolic
ileocolic **273,** 295, 296, 298, 312, 313, 327
colic branch 273, 295, 296
ileal branch 273, 295, 296
of ileum 295
iliac
circumflex
ascending branch–see under Artery, iliac, circumflex, deep
deep 245, 247, 252, 256, 351, 383, 483, 494
ascending branch 247, 256
superficial 241, 243, 247, 256, 482, 494
common 256, 263, 266, 308, 319, 327, 328, 338, **378,** 380–383, 392, 538
ureteric branch 328
external 245, 251–**253,** 256, 263, 266, 273, 301, 308, 319, 327, 347–351, 354, 373, 378, 380–383, 392, 483, 494, 539
internal 256, 296, 308, 313, 319, 327, 329, 351, 355, 378, 380–**382, 383,** 392, 539
iliolumbar 256, 382, 383
infraorbital 19, 32, 36, 65, 77, 81
of infratemporal fossa 36
innominate–see Trunk (arterial), brachiocephalic
intercostal 165, 182, 183, 185, 187, 203, 226, 233, 247, 297, 341
anterior 184, 187, 247
highest–see Artery, intercostal, supreme
lateral cutaneous branch of 182, 183, 185, 203
posterior 164, 165, 176, 182, 183, 185, 187, 203, 226, 227, 233, 247
dorsal branch of 165, 187
supreme 29, 130, 131
interlobar, of kidney 323, 326
interlobular, of kidney–see Artery of kidney, cortical radiate
internal acoustic–see Artery, labyrinthine (internal acoustic)
internal mammary–see Artery, thoracic, internal
internal spermatic–see Artery, testicular
interosseous (forearm)
anterior 417, 428, 430–432
common 417, 430–432
posterior 417, 428, 431, 432
recurrent 417, 428
interventricular–see Artery, coronary (in general), left, anterior interventricular branch of ; right, posterior interventricular branch
intestinal–see Artery, ileal; jejunal; of small intestine

Artery *cont.*
intrahepatic 283, 284
intrapulmonary 201
intrarenal–see cortical radiate; interlobar Artery, of kidney
of iris 84, 86
greater arterial circle 84, 86
lesser arterial circle 84, 86
jejunal 295–297, 300, 309
juxtacolic–see Artery, marginal (juxtacolic, of Drummond)
of kidney 323, 326–see also Artery, renal
arcuate 323, 326
cortical radiate 323, 326
interlobar 323, 326
interlobular–see Artery, of kidney, cortical radiate
segmental 323
of knee 494
labial branches–see labial branches under *Artery, facial, perineal*
labyrinthine (internal acoustic) 130, 132–134, 136
lacrimal 81, 131
anastomotic branch with middle meningeal 95
zygomatic branches 81
laryngeal, superior 30, 65, 70–72, 130, 231
of larynx 70, 72
of leg 498–502
lenticulostriate–see Artery, anterolateral central (lenticulostriate)
of ligament of femoral head–see Artery, obturator, acetabular branch (to ligament of femoral head)
lingual 19, 28, 30, 36, 55, 56, 65, 71, 127, 130, 131
deep 47, 55
dorsal 55
tonsillar branch 60
suprahyoid branch 55, 65
of liver 290–292–see also Artery, hepatic
lumbar 164, 247, 256
of lung 202–see also Artery, pulmonary
macular–see Arteriole, macular (of retina)
malleolar–see also malleolar branch under Artery, fibular; tibial, posterior
anterior
lateral 502, 512, 513
medial 502, 512, 513
mammary 176–see mammary branch under Artery, thoracic, internal; lateral
internal–see Artery, thoracic, internal
of mammary gland 176
marginal
branch of right coronary–see Artery, coronary (in general), right, right marginal branch
(juxtacolic, of Drummond) 296, 301, 313
masseteric 36, 50, 51, 65
mastoid–see Artery, occipital, mastoid branch

Artery *cont.*
maxillary 14, 30, **36,** 37, 42, 50, 51, 65, 67, 95, 125, 127, 128, 130, 131
pterygoid branch 36
medullary
segmental 131, 164, 165, 187
major anterior (Adamkiewicz) 164
meningeal
accessory 36, 95
branch–see under Artery, carotid, internal: ethmoidal, anterior; occipital; pharyngeal, ascending; vertebral
branch of lacrimal–see Artery, lacrimal, anastomotic branch with middle meningeal
middle 14, 36, 42, 51, 65, 67, 94–96, 98, 125, 130, 131
frontal branch 95
parietal branch 95
mental–see Artery, alveolar, inferior, mental branch
mesenteric
inferior 159, 256, 262, 270, 271, 296, 298, 308, 313, 314, 319, 322, 327, 328, 335, 337, 378, 380, 381, 390
superior 159, 172, 225, 256, 262, 266, 270, 271, 273, 288, 291, 292, 294–298, 300, 307, 309, 311, 312, 314, 318, 319, 322, 327, 328, 332, 335, 337, 390, 537
ileal branch 295, 296, 300
jejunal branch 295, 296, 300
metacarpal
dorsal 452
palmar 448, 449
metatarsal
dorsal 502, 512, 513, 518
plantar 515, 517, 518
anterior perforating branches of, to dorsal metatarsal arteries 513, 517, 518
of mouth 65
musculophrenic 183, 184, 194, 207, 247
mylohyoid–see Artery, alveolar, inferior, *mylohyoid branch*
nasal
dorsal 19, 32, 36, 65, 77, 81, 131
external–see Artery, ethmoidal, anterior, nasal (external and anterior lateral) branch
lateral–see lateral nasal branch under Artery, ethmoidal, posterior; facial, sphenopalatine
septal–see nasal septal branch under Artery, ethmoidal (anterior and posterior); facial, superior labial branch
of nasal cavity 36, 37
of neck 29, 30, 65
of femur 486
obliterated umbilical–see Artery, umbilical, occluded part
obturator 245, 251, 256, 296, 327, 328, 351, 354, 378, 380, **382,** 383, 390, 469, 486, 494, 540

Artery *cont.*
ulnar
anterior 417, 430, 431
posterior 416, 427, 428, 431
renal 256, 308, 311, 313, 319, 321, **322**–324, 328, 331–333, 335, 380, 381, 390, 397, 537
accessory 324
pelvic branch 323
ureteric branch 322, 323, 328
variations 324
retinacular (to femoral neck/head) 486
retinal
central 81, 83, 86
macular–see Arteriole, macular
nasal–see Arteriole, nasal
temporal–see Arteriole, temporal (of retina)
retroesophageal right subclavian 76
Rolandic–see Artery, sulcal, central (Rolandic)
of round ligament
of femur–see Artery, obturator, acetabular branch (to ligament of femoral head)
of uterus–see Artery, uterine, branch to round ligament
sacral
lateral 164, 256, 378, 382, 383
middle 164, 256, 296, 351, 354, 378, 380, 382, 383
saphenous–see Artery, genicular, descending, saphenous branch
scapular
circumflex 409, 410, 412, 414, 417
dorsal 28, 29, 410, 412
scrotal, posterior–see Artery, perineal, posterior scrotal branch
segmental
medullary–see Artery, medullary, segmental
septal, nasal–see septal branch under Artery, ethmoidal (anterior and posterior); facial, superior labial branch; sphenopalatine
of shoulder 29
sigmoid 256, 266, 296, 313, 327, 337, 378
sinuatrial–see Artery, coronary, right, sinuatrial (SA) nodal branch
of small intestine 295
sphenopalatine 36, 37, 65
posterior lateral nasal branch 36, 37
posterior septal branch 36, 37
spermatic, internal–see Artery, testicular
spinal
anterior 131, 132, 134, 136, 164, 165
posterior 132, 134, 136, 164, 165
splenic 233, 256, 266, 270, 288–290, **291**–295, 297, 308–311, 317, 318, 335, 336, 535
splenic branch 290
sternocleidomastoid–see Artery, occipital, sternocleidomastoid branch
of stomach 290, 291
straight (arteria recta) of small intestine 272, 295, 296, 316

Artery *cont.*
striate, distal medial (recurrent artery of Heubner) 132–135
subclavian 26, 28, **29,** 65–67, 70–72, 76, 120, 124, 130, 131, 164, 176, 181, 183–185, 190, 194, 202, 207, 208, 210, 226–228, 233, 247, 410, 412, 530
retroesophageal right 76
subcostal 247, 256
sublingual 55, 57
submental 36, 65
subscapular 247, 409, 410, 412, 417
sulcal
central (Rolandic) 134, 135
postcentral 135
precentral (pre-Rolandic) 134, 135
of spinal cord 165
superior vena cava–see Artery, coronary, right, sinuatrial (SA) nodal branch
supraduodenal 290–295
suprahyoid–see Artery, lingual, suprahyoid branch
supraorbital 19, 32, 36, 65, 77, 81, 131
suprarenal
inferior 256, 322, 323, 328, 333
middle 256, 322, 333
superior 189, 256, 322, 333
suprascapular 28, 29, 65, 70–72, 131, 409, 410, 412
infraspinous branch 410
supratrochlear 19, 32, 36, 65, 77, 81, 131
of tail of pancreas–see Artery, pancreatic, caudal
tarsal
lateral 502, 512, 513, 518
medial 502, 512, 513, 518
of teeth 36
temporal
branch of
middle cerebral–see Artery, cerebral, middle, temporal branches
posterior cerebral–see Artery, cerebral, posterior, temporal branches
deep 36, 65, 94
superficial 19, 30, 36, 43, 57, 65–67, 81, 94, 95, 128, 130, 131
anterior auricular branch 19
frontal branch 19, 81, 94
parietal branch 19, 94
tentorial–see Artery, carotid, internal, tentorial branch; Trunk (arterial), meningohypophyseal
terminal–see Terminal branches under Artery, cerebral, anterior; middle; posterior
testicular 247, 251–253, 256, 266, 301, 308, 319, 322, 327, 328, 330, 337, 350, 370, **381,** 383, 389, 396
thalamogeniculate 136
thalamoperforating 133, 136
thalamotuberal 133
of thigh 486–488, 498
thoracic

Artery *cont.*
internal 29, 71, 130, 131, **176,** 182–**184,** 187, 188, 190, 194, 202, 207, 208, 226–228, 233, 237, 247, 297, 531–533
medial mammary branch 176
perforating branch 176, 184, 185, 187
lateral 176, 182, 183, 185, 247, 410, 412, 417
lateral mammary branch 176
superior 183, 185, 410, 412, 417
thoracoacromial 182, 183, 410–412, 417
acromial branch 410, 412, 417
clavicular branch 410, 412, 417
deltoid branch 407, 410, 412, 417
pectoral branch 410, 412, 417
thoracodorsal 247, 409, 410, 412, 417
thyrocervical–see Trunk (arterial), thyrocervical
thyroid
inferior 28, 29, 65, 70–72, 130, 131, 184, 222, 233, 410
esophageal branch 233
superior 27, 28, 30, 65, 70–72, 130, 131
cricothyroid branch 65
of thyroid gland 70, 72
tibial
anterior 494, 500, 502, 504, 512, 513
posterior 494, 498–500, 504, 511, 515–517
calcaneal branch 498–500, 514–517
circumflex fibular branch 494
medial malleolar branch 500
of tongue 55–see also Artery, lingual
tonsillar–see tonsillar branch under Artery, facial; lingual, dorsal; palatine, (ascending and lesser); pharyngeal, ascending–see also Artery, cerebellar, posterior, inferior, cerebellar tonsillar
tubal–see tubal branch under Artery, ovarian; uterine
tympanic, anterior 36, 131
ulnar 416, 417, 427–**431,** 432, 437, 442–444, 448, 449, 456
deep palmar branch of 430, 431, 437, 442, 443, 448, 449, 456
dorsal carpal branch of 452
palmar carpal branch 431, 438, 448
umbilical 225
occluded part 243, 245, 252, 253, 266, 327, 349–351, 380, 382, 383
patent part 245, 256, 378, 380, 382, 383
ureteric–see ureteric branch under Aorta, abdominal; and under Artery, iliac, common; ovarian; renal; vesical (inferior and superior)
urethral 366, 383, 385
of urinary bladder 328
uterine 327, 328, 351, 354–356, 380, 382, **384**
branch to round ligament 384
ovarian branch 384
tubal branch 384
vaginal branch 384

Artery *cont.*
vaginal 327, 328, 351, 352, 355, 380, 382, 384
vermian–see Artery, cerebellar, superior, superior vermian branch
vertebral 17, 28, 29, 65, 67, 71, 72, 95, 124, **130**–134, 136, 164, 171, 184, 222, 233, 542
groove for 15
meningeal branch 95, 130, 136
vesical
inferior 256, 296, 327, 328, 351, 352, 378, 380, 382, 383
ureteric branch 328
superior 245, 256, 296, 327, 328, 351, 378, 380, 382, 383
ureteric branch 332
of wrist 456
zygomatic branch from lacrimal–see Artery, lacrimal, zygomatic branches
zygomaticofacial 19, 81
zygomaticoorbital 19
zygomaticotemporal 19
Articular facet–see Atlas; Dens
Articulation–see Joint
Arytenoid–see Cartilage, arytenoid
Atlas (C1) 12, **15,** 17, 18, 33, 59, 146
anterior arch–see Arch, anterior, of Atlas
anterior articular facet 15
C1 vertebra 5
inferior view 15
lateral masses 15
posterior arch–see Arch, posterior, of Atlas
superior articular facet 15
superior view 15
transverse ligament
posterior articular facet 15
transverse ligament, tubercle 15
Atrium
left 210, 211, 216, **217,** 219, 220, 237, 533, 542
right 208–211, **216,** 219, 220, 226, 237, 533, 541
Attachment of
ascending colon 266
cecum 273
descending colon 266
greater omentum 266
lesser omentum 266
muscles–see origins and insertions of individual muscles
sigmoid mesocolon 266
transverse mesocolon 266, 288
Auerbach–see Plexus (nerve), myenteric (Auerbach's)
Auricle
of ear 87, 88
of left atrium 208, 210, 211, 217, 220, 221, 542
of right atrium 208, 210, 216, 220
Autonomic nervous system–see System, nervous, autonomic (ANS)
Axilla 174, 414–417–see also Fossa, axillary
Axilla *cont.*
cross sections of 411, 530–**532,** 541, 542
fold
anterior axillary 174
posterior axillary 174
Axis (C2) 12, **15,** 18, 56
anterior view 15
body 15
C2 vertebra–see Dens, of axis (C2 vertebra)
celiac–see Trunk (arterial), celiac
lateral mass
inferior articular surface 15
of lens 85
posterosuperior view 15

B

Back
bones of 146–150
cross section (of lumbar region) 172
joints of 151, 152
ligaments of 151, 152
muscles of 167–169, 171
nerves of 170
Band–see also Fiber
central, of extensor (digitorum) tendon 434, 447
lateral
of extensor (digitorum) tendon 434, 447
of plantar aponeurosis 518
longitudinal, of cruciate ligament 18
moderator 216, 220, 221
parietal, of supraventricular crest–see Limb, of supraventricular crest
septal 216, 219, 220
Bartholin–see Duct, sublingual; Gland, vestibular, greater
Base
cranial 8–10
bones of 9
foramina of 10
of (5th) metacarpal bones 440
of heart 210
of metacarpal bones 439
of metatarsal bones 505
of phalanges (foot) 505
of phalanges (hand) 439
of phalanx (4th proximal) 440
of renal pyramid 321
of sacrum 150
of skull–see Base, cranial
Basiocciput–see Part, basilar, of occipital bone
Bed
of liver 279
of nail 453
of parotid gland 30, 56
of sublingual gland 56
of submandibular gland 56
Bertin–see Column, renal
Biceps–see Muscle, biceps
Bigelow–see Ligament, iliofemoral
Bladder, urinary 161, 245, 253, 261, 313, 319, 327, 335, 347–**353,** 354, 360, 362, 366, 367, 369, 372, 380, 397, 400, 540
Blood supply–see Artery; Vein
Blood vessels, innervation of 224
Body
adipose–see Fat, pararenal
amygdaloid 104, 106, 113
anococcygeal 360, 361
of Arantius–see Nodule, of semilunar valve (Arantius)
of axis 15
of bladder 348, 353
carotid 30, 67, 119, 124, 130, 206
of caudate nucleus 102, 104
cell, of presynaptic sympathetic neurons 126–128
ciliary 83–86
of clitoris 347, 398
of epididymis 371
fat
infrapatellar 493
of ischioanal fossa 360, 363, 373, 540
of orbit 44, 79
of femur 471, 478
of fibula 495, 496
of fornix 100, 102, 106
of gallbladder 285
gastric–see Body, of stomach
geniculate
lateral 101, 104, 105, **108**–110, 114, 126, 132, 136–138
medial 105, 108, 109, 132, 136–138
of hyoid bone 12, 49
of ilium 344, 468
of ischium 468
of L3 vertebra 149
mammillary 100, 101, 106, 108, 140
of mandible 2, 4, 12, 13, 23
of metacarpal bones 439
of metatarsal bones 505
of pancreas 288
of penis 339, 404
perineal 348, 352, 359–361, 365–367, 372, 376, 385
of phalanges
foot 505
hand 439
pineal 100, 104, 105, 108, 109
of pubis 540
of rib 178
of scapula 411
of sphenoid bone 6, 35, 37, 46
of sternum 174, 178, 182, 184, 239, 240, 533
of stomach 267, 268, 271
of tibia 495, 496
of tongue 44, 54
of uterus 347, 354, 356
of vertebra 338
vertebral 16, 147, 148, 151, 152, 163, 172, 238, 530, 533, 534, 538
C4 vertebra 16
C7 vertebra 16
L3 vertebra 149
vitreous, of eye 83

Bone
of abdomen 240
of ankle 495, 496, 505–507
of arm 403, 404
auditory–see Ossicle, auditory
of back 146–148, 150
breast–see Sternum
calcaneal–see Calcaneous
capitate–see Capitate
carpal 435–439
clavicle–see Clavicle
conchal–see Concha, nasal
coxal–see Bone, hip (coxal)
of cranial base 9
cuboid–see Cuboid
cuneiform–see Cuneiform
of ear–see Ossicle, auditory
of elbow 424
ethmoid 2, 4, 6, 9–11, 33–35, 39, 46
femur–see Femur
fibula–see Fibula
of foot 505–507
of forearm 422
frontal 1, 2, 4, 6–9, 11, 32, 34, 35, 77, 78
"funny"–see Nerve, ulnar
hamate–see Hamate
of hand 444
hip (coxal) 340–342, 468, 469, 471–473
hyoid **12,** 23–25, 27, 30, 49, 55–57, 59, 61, 63, 64, 70, 72, 73
ilial–see Ilium
ischial–see Ischium
lacrimal 2, 4, 6, 11, 34, 46
of leg 495, 496
lunate–see Lunate
mandibular–see Mandible
maxillary 43–see also Maxilla
metacarpal 421–441, 444, 447, 450
(index finger) 440
shaft 440
metatarsal 500, 503, 505, 506, 509–511, 513, 518, 519
nasal 1, 2, 4, 6, 11, 32, 34, 35, 46
of nasal cavity 34, 46
navicular–see Navicular
of neck 12–16
occipital 4–9, 11, 17, 26, 33–35, 59–63
basilar part–see Part, basilar, of occipital bone
palatine 2, 6, 8, 11, 12, 34, 43, 46
parietal 2–9, 11
of pelvis 340, 341–see also Pelvis, bony
phalanx
distal
(ring finger) 440
(thumb) 440
middle (middle finger) 440
proximal
(index finger) 440
(thumb) 440
pisiform–see Pisiform
pubic–see Pubis
scaphoid–see Scaphoid
sesamoid 439, 505, 506, 512, 516–519

Bone *cont.*
of shoulder 402–404
sphenoid 2–6, 8, 9, 11, 12, 34, 35, 43
greater wing 3, 5
lesser wing 3
sternum–see Sternum
talus–see Talus
tarsal–see Bone, of foot
temporal 2–6, 8, 9, 11, 12
of thigh 469, 487
of thorax 178, 179
tibia–see Tibia
trapezium–see Trapezium
trapezoid–see Trapezoid
triquetrum–see Triquetrum
vertebra–see Vertebra
vomer–see Vomer
of wrist 435, 436, 439
zygomatic 1, 2, 4, 8, 11, 77
Bony framework–see Framework, bony
Border
anterior
of fibula 495, 496
of radius 422
of tibia 495, 496
of ulna 422
of fibula–see Border, anterior; interosseous; posterior; of fibula
of heart–see Border, inferior; left; right; of heart
inferior
of heart 208
of liver 278, 279
of lung 192, 193
interosseous
of fibula 495, 496
of radius 422
of tibia 495, 496
of ulna 422
lateral, of scapula 403, 404
left, of heart 192, 208
of liver–see Border, inferior, of liver
of lung–see Border, inferior, of lung
medial, of scapula 404, 406
posterior
of fibula 495, 496
of radius 422
of ulna 422
of radius–see Border, anterior; interosseous; posterior; of radius
right, of heart 192
of scapula–see Border, lateral; medial; superior; of scapula
superior, of scapula 404, 406
of tibia–see Border, anterior; interosseous; of tibia
of ulna–see Border, anterior; interosseous; posterior; of ulna
Bowel–see Colon; Intestine, large; small
Bowman–see Capsule, glomerular
Boyden–see Sphincter, of (common) bile duct

Brachium–see also Arm
of inferior colliculus 105, 108
of superior colliculus 105, 108
Brain 96, 99–109
arteries of 130–135
schema 131
meninges of 94–96
veins of
deep 138
subependymal 139
superficial 96
venous sinuses 97, 98
Brainstem 108, 110, 111
Branch
bundle, of conducting system of heart–see Bundle, left; right; of conductive fibers of heart
subendocardial, of conductive system of heart 221
Branch (of artery)–see under parent artery
acetabular–see under Artery, obturator, acetabular branch
acromial–see under Artery, suprascapular; thoracoacromial
alar–see under Artery, facial, lateral nasal branch
anastomotic, of lacrimal with middle meningeal artery 95
angular–see Artery, cerebral, middle, branch to angular gyrus
to angular gyrus–see under Artery, cerebral, middle, branch to angular gyrus
articular–see under Artery, genicular, descending, articular branch
ascending–see ascending branch under Artery, iliac, circumflex, deep; femoral, circumflex, lateral
atrial–see under Artery, coronary, right
atrioventricular–see under Artery, coronary, left, circumflex branch of, atrioventricular branch of
atrioventricular (AV) nodal–see under Artery, coronary, right, posterior interventricular branch
auricular–see Artery, temporal, superficial, anterior auricular branch
calcaneal
lateral–see under Artery, fibular (peroneal)
medial–see under Artery, tibial, posterior
calcarine–see under Artery, cerebral, posterior
carpal–see under Artery, radial; ulnar
cavernous–see under Artery, carotid, internal
cerebellar tonsillar–see under Artery, cerebellar, posterior inferior
choroidal–see under Artery, cerebellar, posterior inferior
circumflex–see under Artery, coronary, left; femoral; tibial, posterior
clavicular–see under Artery, thoracoacromial
colic–see under Artery, ileocolic
communicating–see under Artery, fibular (peroneal)

Branch (of artery) *cont.*
conus–see under Artery, coronary, right
to corpus callosum (dorsal)–see under Artery, cerebral, posterior
cremasteric–see Artery, cremasteric
cricothyroid–see under Artery, thyroid, superior
deferential–see under Artery, to ductus deferens
deltoid–see under Artery, thoracoacromial
descending–see under Artery, coronary, left; Artery, femoral, circumflex, lateral; occipital
esophageal–see under Aorta, thoracic; Artery, bronchial; gastric, left; phrenic, inferior; thyroid, inferior
frontal–see under Artery, meningeal, middle; temporal, superficial
medial–see under Artery, callosomarginal
genicular–see Artery, genicular
ileal–see under Artery, ileocolic
infraspinous–see under Artery, suprascapular
interventricular, posterior–see under Artery, coronary, right
labial
inferior and superior–see under Artery, facial
posterior–see under Artery, perineal
lateral–see under Artery, coronary, left, circumflex branch of
malleolar–see under Artery, fibular (peroneal); tibial, posterior–see also Artery, malleolar, anterior
mammary–see under Artery, thoracic, internal; lateral
marginal–see under Artery, coronary, right
mastoid–see under Artery, occipital
meningeal–see under Artery, carotid, internal; ethmoidal, anterior; posterior; occipital; pharyngeal, ascending; vertebral
mental–see under Artery, alveolar, inferior
muscular–see under Artery, brachial; femoral
mylohyoid–see under Artery, alveolar, inferior
nasal, lateral–see under Artery, ethmoidal (anterior and posterior); facial; sphenopalatine
nodal–see Artery, coronary, right , posterior interventricular branch, atrioventricular (AV) nodal branch; sinuatrial (SA) nodal branch
palmar, deep–see under Artery, ulnar
parietal–see under Artery, meningeal, middle; temporal, superficial
parietooccipital–see under Artery, cerebral, posterior
pectoral–see under Artery, thoracoacromial
pelvic–see under Artery, renal
perforating–see under Artery, deep, of thigh; fibular (peroneal); metatarsal, plantar; thoracic, internal

Branch (of artery) *cont.*
posterolateral–see under Artery, coronary, left, circumflex branch of
pterygoid–see under Artery, maxillary
pubic–see under Artery, epigastric, inferior; obturator
to round ligament–see under Artery, uterine
saphenous–see under Artery, genicular, descending
scrotal, posterior–see under Artery, perineal
septal
interventricular–see under Artery, coronary, left, anterior interventricular branch; coronary, right, posterior interventricular branch
nasal–see under Artery, ethmoidal (anterior and posterior); facial, superior labial branch; sphenopalatine
sinuatrial (SA) nodal–see under Artery, coronary, right
splenic–see under Artery, splenic
sternocleidomastoid–see under Artery, occipital
suprahyoid–see under Artery, lingual
sural (muscular)–see under Artery, popliteal
temporal–see under Artery, cerebral, middle; posterior
tentorial–see under Artery, carotid, internal
terminal–see under Artery, cerebral, anterior; middle; posterior
tonsillar–see under Artery, facial; lingual, dorsal; palatine (ascending and lesser); pharyngeal, ascending–see also Artery, tonsillar under Artery, cerebellar, posterior inferior, cerebellar tonsillar branch
transverse–see under Artery, femoral, circumflex, lateral
tubal–see under Artery, ovarian
ureteric–see under Aorta, abdominal; and Artery, iliac, common; ovarian; renal; vesical (inferior and superior)
vermian–see under Artery, cerebellar, superior
zygomatic–see under Artery, lacrimal,

Branch (of nerve)–see under parent nerve
anterior–see under Nerve, obturator
anterior cutaneous–see under Nerve, femoral
articular–see under Nerve, auriculotemporal; fibular (peroneal), common; median; obturator; tibial; ulnar
auricular–see under Nerve, vagus
buccal–see under Nerve, facial–see also Nerve, buccal (of mandibular nerve)
calcaneal–see under Nerve, sural; tibial
carotid (to carotid sinus and body)–see under Nerve, glossopharyngeal

Branch (of nerve) *cont.*
celiac–see under Nerve, vagus
cervical–see under Nerve, facial
communicating
of cervical plexus
to brachial plexus 123
to vagus 28
of glossopharyngeal nerve
with auricular branch of vagus 119
with chorda tympani of facial 119
of intercostal with intercostal 250
of median nerve with ulnar nerve 458
between nasopalatine and greater palatine 38
of vagus with glossopharyngeal nerve 120
of zygomatic to lacrimal 41, 116, 127
cutaneous–see under Nerve, femoral; iliohypogastric; intercostal; plantar (lateral and medial); subcostal
deep–see under Nerve, plantar, lateral; radial; ulnar
dental–see under Nerve, maxillary
dorsal–see under Nerve, digital, proper (palmar and plantar); radial; ulnar
external–see under Nerve, accessory; laryngeal, superior
femoral–see under Nerve, genitofemoral
ganglionic–see Nerve, maxillary, branches to pterygopalatine ganglion
gastric–see under Nerve, vagus
genital–see under Nerve, genitofemoral
gingival–see under Nerve, maxillary
hepatic–see under Nerve, vagus
infrapatellar–see under Nerve, saphenous
internal–see under Nerve, accessory; laryngeal, superior
intestinal–see under Nerve, vagus
labial–see under Nerve, ilioinguinal; perineal
laryngopharyngeal–see under Ganglion, cervical sympathetic, superior
lingual–see under Nerve, glossopharyngeal
marginal mandibular–see under Nerve, facial
meningeal–see under Nerve, hypoglossal; mandibular; spinal; vagus–see also Nerve, ophthalmic, tentorial (meningeal) branch
motor, to thenar muscles–see under Nerve, median
nasal–see under Ganglion, pterygopalatine; and under Nerve, alveolar, superior; ethmoidal, anterior; infraorbital; maxillary; palatine, greater
occipital–see under Nerve, auricular, posterior
palmar–see under Nerve, median; ulnar
palpebral–see under Nerve, lacrimal
parotid–see under Nerve, auriculotemporal
pericardial–see under Nerve, phrenic
perineal–see under Nerve, cutaneous,

Branch (of nerve) *cont.*
of thigh posterior; spinal, sacral
pharyngeal–see under Ganglion, pterygopalatine; and under Nerve, glossopharyngeal; vagus
posterior–see under Nerve, obturator
pterygopalatine–see Nerve, maxillary, ganglionic branch to pterygopalatine ganglion
pyloric–see under Nerve, vagus, hepatic branch
recurrent–see Nerve, spinal, (recurrent) meningeal branch
scrotal
anterior–see under Nerve, ilioinguinal
posterior–see under Nerve, perineal
stylohyoid–see under Nerve, facial
stylopharyngeal–see under Nerve, glossopharyngeal
superficial–see under Nerve, plantar, lateral; radial; ulnar
temporal–see under Nerve, facial
tentorial–see under Nerve, ophthalmic
tonsillar–see under Nerve, glossopharyngeal
zygomatic–see under Nerve, facial–see also Nerve, zygomatic
zygomaticofacial–see under Nerve, zygomatic
zygomaticotemporal–see under Nerve, zygomatic
Breast 175–177
artery of 176
cross section of 175
mammary gland 175
lymph vessels and nodes 177
Bregma 7
Brim, pelvic 150, 355–see also Linea, terminalis (of pelvis)
Bronchiole 200, 201
Bronchus
arteries of 203
cardiac (left lung) 199
eparterial 195, 198, 199, 202, 228
extrapulmonary 198
innervation of 206
intermediate 199, 202
intrapulmonary 198, 200
left 238
lingular 198, 199
lobar
inferior 195, 198, 199
lower–see Bronchus, lobar, inferior
middle 198, 199
superior
left 198, 199
right (eparterial) 195, 198, 199, 202
upper–see Bronchus, lobar superior
main 195, **198,** 199, 202, 203, 205, 226–230, 237, 532, 542
nomenclature of 199
Bronchus *cont.*
2nd order–see Bronchus, lobar
3rd order–see Bronchus, segmental
4th order–see Bronchus, subsegmental
primary–see Bronchus, main
right 238
segmental 199, 200
subsegmental 199, 200
superior division 198, 199
veins of 203
Brunner–see Gland, duodenal
Buck–see Fascia, deep, (Buck's) of penis
Bulb–see also Eyeball
of corpus spongiosum 365
duodenal 268, 271
olfactory 39, 101, 113
of penis 365, 366
urethral–see Urethra, male, spongy, bulbous portion
of vestibule 353, 355, 360–362, 384
Bulla, ethmoidal 33, 34
Bundle
atrioventricular (His) 221
of His–see Bundle, atrioventricular
left, of conductive fibers of heart 221
oval–see Fasciculus, septomarginal
right, of conductive fibers of heart 221
Burns–see Space, suprasternal (Burns)
Bursa
anserine 488, 489
of biceps femoris tendon–see Bursa, subtendinous, inferior, of biceps femoris
of fibular collateral ligament 488–490, 493
of gastrocnemius muscle–see Bursa, subtendinous, of gastrocnemius muscle
iliopectineal 469, 478
of iliotibial tract 488–490
olecranon–see Bursa, subcutaneous, olecranon
omental 264, 265, 335, 336
cross section of 265
inferior recess of 335
superior recess of 264, 266, 279, 335
radial–see Sheath, synovial, of flexor pollicis longus
semimembranosus 488, 493
subcutaneous
calcaneal 511
infrapatellar 493
lateral malleolar 511
medial malleolar 511
olecranon 421
prepatellar 493
subdeltoid 410, 414
subscapular–see Bursa, subtendinous, of subscapularis
subtendinous
calcaneal 503, 511
of gastrocnemius muscle 493
inferior, of biceps femoris 488, 489, 493
Bursa *cont.*
infrapatellar 493
of subscapularis 406
suprapatellar 489, 490, 493
ulnar–see Sheath, flexor, common
Buttock, nerves of 484, 485, 527

C

Calcaneus 505–**507,** 508, 510, 511–see also Sustentaculum tali; Tuberosity
Calcar avis 105, 106
Calot–see Lymph node, cystic; Triangle of Calot
Calvaria 7, 96
Calyx of kidney 321, 537
Camera–see Chamber of eye
Camper–see Tissue, subcutaneous, fatty layer, of abdomen
Canal
adductor 482, 483, 487
Alcock's–see Canal, pudendal
anal 347, 373, 374, 400–see also Rectum/anal canal
carotid 8, 93
central, of spinal cord 102, 103, 109
cervical, of uterus 356
condylar 8, 10
dental root 53
facial 118
femoral 252, 528
gastric 268
of Hering–see Ductule, bile
Hunter–see Canal, adductor
hyaloid, of eye 83
hypoglossal 6, 8, 10, 122
incisive 6, 33–38, 39
infraorbital 41
inguinal 252
mandibular 56
nasofrontal 34
nasolacrimal 34
obturator 245, 340, 343, 345, 351, 352, 354, 382
optic 2, 6, 10, 79
pudendal 296, 305, 373, 378, 379, 382, 384, 385, 391, 393
pyloric 267
sacral 150, 345
Schlemm's–see Sinus, venous, scleral
semicircular 90–92, 143
spinal–see Canal, vertebral
vertebral 16, 147, 148
Canaliculus
bile 284
lacrimal 78
mastoid 8
tympanic 8
Cap of duodenum 268, 271
Capillary
intrapulmonary 201
subpleural 201

Capitate 435, 439, 440
Capitulum of humerus 403, 419, 420
Capsule–see also Ligament; Joint
atlantoaxial–see Capsule, joint, atlantoaxial
atlantooccipital–see Capsule, joint, atlantooccipital
of basal nuclei
external 104
internal 102, 104, 134
Bowman's–see Capsule, glomerular
fat, perirenal–see Fat, perirenal
fibrous, of thyroid gland 72
glomerular 325
joint
atlantoaxial 17, 18
atlantooccipital 17, 18
temporomandibular 14
zygapophyseal 17, 18, 151
of kidney 321, 325, 326, 332
lens 83–85
of liver 282
of suprarenal gland 333
temporomandibular–see Capsule, joint, temporomandibular
Tenon's–see Sheath, fascial, of eyeball
of vertebral joint, lateral–see Capsule, joint, zygapophyseal
zygapophyseal–see Capsule, joint, zygapophyseal
Caput of mandible–see Head, of mandible
Carina, of trachea 542
Carpal–see Bone, carpal
Cartilage
alar 32, 34, 35
alar (major) 43
arytenoid 61, 73, 74
of auditory tube 43, 48, 51, 61, 63, 93
auricular 43
corniculate 61, 73
costal 178, 179, 188, 192, 240, 250, 530, 531, 534
cricoid 12, 24, 25, 59, 61, 64, 70, 73, 74, 192, 198, 202, 229–231
laryngeal 73
nasal
lateral 32, 34, 35
septal 32, 35, 43
thyroid 1, 12, 24, 25, 27, 59, 61, 64, 70, 73, 74, 192, 198, 202, 229–231
tracheal 198
Caruncle
hymenal 355, 359
lacrimal 77, 78
sublingual 47, 57
Cauda equina 153, 154, 163, 172, 537
Cavity
of concha 88
glenoid, of scapula 178, 403, 406
nasal 33–46, 78, 79
arteries of 37
autonomic innervation of 40
nerves of 38–39
paranasal sinuses 44–46
oral 44, 47, 144–see also Mouth
Cavity *cont.*
inspection of 47
pericardial 237
peritoneal 260–266
pleural 237
tympanic 40, 42, 87, **89,** 91, 118, 119
Cavum conchae–see Cavity, of concha
Cecum 120, 261, 263, 276, 349, 350, 538–539
Cell
amacrine, of retina 114
bipolar, of retina 114
body–see Body, cell, of presynaptic sympathetic neurons
epithelial, of stomach 268
ethmoidal (air) 44–46, 79
ganglion, of retina 114
granule, of olfactory bulb 113
hair, of spiral organ 91
horizontal, of retina 114
mastoid (air) 5, 43, 89, 143
mitral, of olfactory bulb 113
mucous, of stomach 268
neuroendocrine G, 268
olfactory 113
parietal, of stomach 268
periglomerular, of olfactory bulb 113
pigment, of retina 114
pillar, of spiral organ 91
of retina 114
rod, of spiral organ 91
of spiral organ 91
of stomach 268
of taste bud, sustentacular 54
tufted, of olfactory bulb 113
tympanic (air) 89
zymogenic, of stomach 268
Cementum 53
Cerebellum 92, 100, 105, **107, 109,** 137, 139, 142, 143–see also Tentorium cerebelli
Cerebrospinal fluid (CSF) 103
Cerebrum 96, 99–104
Cervix of uterus 347, 351, 354–356, 395
os, external, 400
Chamber of eye
anterior 77, 83–86
posterior 77, 83–86
vitreous 86
Chiasm, optic 98, 100, 101, 108, 114, 133, 134, 138–140
Choana 8, 12, 35, 48, 51, 62, 63, 93
Cholangiole 283, 284
Cholinergic
synapses 161
terminals 206
Chorda tympani–see Nerve, chorda tympani
Chordae tendineae 216, 217, 219
Choroid 83, 85, 86, 114
Cilia of eyelid–see Eyelash
Circle, arterial
cerebral (Willis) 132, 133
major, of iris 84
minor, of iris 84
of Willis–see Circle, arterial, cerebral (Willis)
Circulation
of cerebrospinal fluid (CSF) 103
intrapulmonary (schema) 201
postnatal 225
prenatal 225
Cistern
cerebellomedullary (posterior) 103
chiasmatic 103
chyle–see Cisterna, chyli
of corpus callosum 103
of great cerebral vein–see Cistern, quadrigeminal
interpeduncular 103
lumbar 538
prepontine 103
quadrigeminal 103
Cisterna
chyli 258, 305, 308
magna–see Cistern, cerebellomedullary (posterior)
Claustrum 104
Clavicle 1, 23–25, 27, 174, 178, 179, 182–184, 192–194, 209, 226, 227, 401, **402**–408, 410–412, 530, 541
Cleft
intergluteal (natal) 145
Clitoris 357, 359, 361, 376, 398
Clivus 9, 18
Cloquet–see Lymph node, deep, inguinal, highest
Coccyx 146, 150, 152–154, 240, 340–346, 361, 363, 365, 372, 376, 540
Cochlea 87, 89–92
Collar of Helvetius 232, 269
Colles–see Fascia, perineal, superficial
Colliculus
facial, of 4th ventricle 109
inferior 100, 105, 108, 109, 137
seminal 353, 367
superior 100, 101, 105, 108–110, 126, 136, 137
Colon–see also Intestine, large
ascending 120, 261, **263,** 270, 276, 320, 337, 338, 349, 350, 536, 537
descending 261, **263,** 270, 276, 332, 337, 338, 349, 350, 535–538
flexure of–see Flexure, colic
sigmoid 261, 263, 276, **277,** 349, 350, 354, 372–375, 392, 537
transverse 261–**263,** 265, 270, 276, 279, 285, 288, 289, 304, 335, 337, 338, 535–537
Column
anal 374
of Bertin–see Column, renal
of fornix 100, 104–106, 138
of Morgagni–see Column, anal
rectal–see Column, anal
renal 321, 326
spinal–see Column, vertebral
vertebral 146
arteries of 165
relationship to spinal cord/nerves 153, 154
veins of 166

Commissure
cerebral
anterior 100, 109, 113, 139, 140
posterior 100, 105, 109
of fornix 106
of gray matter 158
habenular 100, 105, 109
labial 359
of lips 1
white, of spinal cord 158
Compartment
of extensor tendons at wrist 427, 428, 453
fascial, of
arm 418
forearm 432
leg 504
thigh 487
perineal, superficial–see Space, perineal (superficial)
Compressor urethrae 343, 355, 361, 384
Concha
of external ear 88
nasal 143
inferior 2, 6, 33, 34, 44–46, 78, 144
middle 2, 6, 33, 34, 44–46, 78
superior 6, 33, 34, 46
sphenoidal 46
Conduction fiber–see Bundle, atrioventricular; left; right
Conducting system, see System, conducting
Condyle
of femur 471, 489–491
lateral 492
medial 492
of humerus 403, 419
occipital 6, 8, 9, 26, 93, 122
of tibia 476, 489, 491, 495, 496, 503
lateral 492
medial 492
Cone
of light 88
medullary–see Conus, medullaris
of retina 114
Confluence of sinuses 97, 98, 137, 138
Conjunctiva 77, 79, 83, 84, 86
Constrictions of esophagus 229
Constrictor of pupil–see Muscle, sphincter, of pupil
Conus
arteriosus 208, 216–218, 220
elasticus 74
medullaris 153, 154, 163, 537
Cooper–see Ligament, pectineal; suspensory, of breast
Cord
of brachial plexus 413, 457, 458, 541
genital 399
oblique, of radioulnar syndesmosis 421, 422
spermatic 241, 245, 247, 249, 251–254, 381, 385, 540
spinal 40, 126–128, 142, **153,** 158, 161, 163, 206, 238, 314, 315, 317, 318, 331, 334,
Cord *cont.*
397, 530–537
arteries of 164, 165
cross sections of 158
fiber tracts of 158
in situ 153, 163
relationship to vertebrae 154
veins of 166
tendinous–see Chordae tendineae
vocal–see Ligament, vocal
Cornea 77, 79, 83, 84, 86
Cornu–see also Horn
coccygeal 150
sacral 150
Corona
of glans 365
Corpus–see also Body
adiposum–see Body, fat
albicans 359, 362
Arantii–see Nodule, of semilunar valve (Arantius)
callosum **100**–102, 104–106, 134, 136, 138, 139, 142
cavernosum 348, 364–366, 368, 400
clitoris–see Body, of clitoris
of gallbladder–see Body, of gallbladder
luteum 356
of penis–see Body, of penis
spongiosum 348, 364–366, 368, 400
of stomach–see Body, of stomach
striatum 104, 134
of uterus–see Body, of uterus
Corpuscle
cortical renal 325
juxtamedullary renal 325
Malpighian–see Corpuscle, renal
renal 325
Cortex
of kidney 321, 325, 326, 536
of lens 85
of suprarenal gland 333, 334
Corti–see Organ, spiral, of Corti
Cough receptors 206
Cowper–see Gland, bulbourethral (Cowper's)
Coxa–see Bone, hip (coxal)
Cranium 2, 4, 6–12–see also Base, cranial
neonatal 11
view
anterior 2
inferior 8
lateral 4
median section 6
superior 7
Crease
digital
distal 401
middle 401
proximal 401
longitudinal, radial 401
palmar, proximal 401
Crest
frontal 7, 9
of humeral tubercle 403
Crest *cont.*
iliac 145, 152, 167–170, 186, 239, 240, 246, 319, 320, 332, 339–341, 467, **468,** 476–478, 484, 485, 527, 538
infratemporal 4
intertrochanteric 469–471, 485
nasal
of maxilla 35
of palatine bone 35
obturator 340, 469
occipital
external 8
internal 9
pubic 251, 345
sacral 150, 340, 344
of sphenoid bone 35
supracondylar 403, 404, 419
supraventricular 216, 220
urethral 367, 368
Cricoid–see Cartilage, cricoid
Crista
galli 3, 6, 9, 35, 144
terminalis 216, 221
Cross section
abdomen
abdominal wall, anterior (transverse) 244
abdominal wall, lateral (coronal) 245
abdominal wall and viscera (median) 335
abdominal wall and viscera at L1–2 (transverse) 537
abdominal wall and viscera at L2–3 (transverse) 337
abdominal wall and viscera at L5 (transverse) 538
abdominal wall and viscera at S1 (transverse) 539
abdominal wall and viscera at T10 (transverse) 534
abdominal wall and viscera at T12 (transverse) 336, 535
abdominal wall and viscera at T12–L1 (transverse) 536
appendix (transverse) 275
duodenum (coronal) 271
esophagogastric junction (coronal) 232
gallbladder/biliary tract (sagittal) 285
kidney (multisectional) 325
kidney with arteries (coronal) 323
omental bursa (transverse) 265
pylorus (coronal) 269
retroperitoneum, kidney, suprarenal gland (sagittal) 332
retroperitoneum at level of renal hilum (transverse) 332
stomach (coronal) 268
back
lumbar region of back (transverse) 172
lumbar vertebra/spinal cord (transverse) 163
spinal cord with arteries (transverse and median) 165

Cross section *cont.*
spinal cord with veins (transverse) 166
thoracic vertebra/spinal cord (transverse) 163
thoracic vertebra/spinal cord with arteries (transverse) 165
head and neck
brain/cranial cavity
brain with arteries (coronal) 134
brain with arteries (median) 135
brain with basal nuclei (transverse) 104
cavernous/sphenoidal sinuses (coronal) 98
cerebellum (in plane of cerebellar peduncle) 107
cerebellum/brainstem (median) 109
hemisected brain/brainstem/spinal cord with subarachnoid space 103
hemisected brain minus brainstem 100
hemisected cranium and brain 100
hemisected cranium with meninges/dural sinuses 97
thalamus (schema) 105
ventricles of brain (coronal) 102
ear
cochlea, section through turn 91
external, middle, internal (schema) 87
labyrinth (bony, membranous) 91
pharyngotympanic (auditory) tube 93
hemisections (median sections)
hemisected cranium 6
hemisected cranium with meningeal arteries 95
hemisected head and neck 59
mouth
oral cavity/oropharynx/parotid region (transverse) 56
tongue and floor of mouth (coronal) 56
nasal cavity
arteries (hinged bony specimen) 37
lateral wall (bony, median) 6, 34
lateral wall (median) 33
nerves (hinged bony specimen) 38
paranasal sinuses (coronal) 44
paranasal sinuses (transverse) 44
paranasal sinuses (sagittal) 45
septum (bony, median) 35
septum (median) 35
neck
fascial layers (schematic, median) 31
fascial layers (schematic, transverse) 31
orbits
anterior orbit (sagittal) 77
eyeball, whole (transverse) 83
anterior/posterior chambers 84
blood vessels (schema) 86
left orbit/maxillary sinus (sagittal) 45
left and right orbits (coronal) 44
left and right orbits (transverse) 44
middle of orbit (coronal) 79
right orbit (sagittal) with veins 81
Cross section *cont.*
right orbit (transverse) 79
parotid region
(transverse) 21, 56
pharynx
mucosa (median) 59
muscles (median) 61
tongue
(coronal) 56
(sagittal) 59
tooth 53
lower limb
hip joint with arteries (coronal) 486
knee (sagittal lateral to midline) 385
leg (above middle) (transverse) 504
thigh (serial transverse) 487
pelvis and perineum
ischioanal fossae (coronal) 373
pelvic viscera and perineum: female (median) 347, 356
pelvic viscera and perineum: male (median) 348
pelvic wall and floor (coronal) 245
pelvic wall and viscera at level of femoral heads, tip of coccyx 540
perineopelvic spaces (median) 377
perineum and urethra: male (coronal) 366
prostate (transverse) 367
prostate with arteries (coronal) 383
prostatic, seminal vesicles and penile urethra (median) 367
prostatic and bulbous urethra (coronal) 367
rectum (coronal) 374
scrotum and testis (coronal) 371
testis (coronal) 371
urethra: female (coronal) 362
urethra: male (coronal) 368
urinary bladder and urethra: female (coronal) 353
urinary bladder and urethra: male (coronal) 353
uterus: age changes (coronal) 357
uterus and adnexa (coronal) 356
vagina and endopelvic fascia (coronal) 253
wall of anal canal (coronal) 375
thorax
breast (sagittal) 175
heart: atria, ventricles and interventricular septum (oblique) 220
mediastinum (transverse) 237
ribs and sternocostal joints (coronal) 179
thoracic wall/spinal nerve (transverse) 166 (schema), 250
thoracic wall and viscera, T4 level (transverse) 530
thoracic wall and viscera, T4–5 level (transverse) 531
thoracic wall and viscera, T5–6 level (transverse) 532
Cross section *cont.*
thoracic wall and viscera, T7 level (transverse) 533
thoracic wall and viscera at anterior axillary line (coronal) 541
thoracic wall and viscera at midaxillary line (coronal) 542
trachea (transverse) 198
upper limb
arm (serial transverse) 418
axilla (sagittal) 411
finger, distal (sagittal) 454
finger, distal (transverse) 454
forearm (serial transverse) 432
hand at midpalm (transverse) 445
shoulder (coronal) 406
sternoclavicular joint (coronal) 402
wrist/carpal tunnel (transverse) 444
wrist joints (coronal) 438
Crown of tooth 53
Crus–see also Limb
of antihelix 88
cerebral 100, 101, 107, 109, 132, 138
of clitoris 347, 353, 355, 361
of diaphragm–see under Diaphragm, thoracic, crura
of fornix 100, 104, 106, 136
of helix 88
of incus 88, 89
of penis 353, 365, 366, 368
of stapes 87–89
of superficial inguinal ring 251
Crypt
anal 378
of intestinal glands (Lieberkühn) 275
of Lieberkühn–see Crypt, of intestinal glands
of lingual tonsil 54
Cuboid 505, 506, 508–510, 518, 519
Cuff
musculotendinous–see Cuff, rotator
rotator 410, 413, 412
Cul-de-sac of Douglas 347, 349, 351, 354, 356, 372
Culmen
of cerebellum 107, 109, 137
of left lung 196, 197
Cuneiform 505, 506, 508–510, 518, 519
Cuneus 100, 101
Cupula of
cochlea 90
pleura 70, 192, 193, 226, 227
Curvature
cervical 16
lumbar 146
sacral 146
of stomach 267
thoracic 146
of vertebral column 146
Cusp
anterior
of mitral valve 217–220, 237

Cusp cont.
of pulmonary valve–see Cusp, semilunar, anterior, of pulmonary valve
of tricuspid valve 218–220, 237
of aortic valve–see Cusp, semilunar, left; posterior; right; of aortic valve
commissural, of mitral valve 218, 219
coronary–see Cusp, semilunar, left; right; of aortic valve
mitral valve–see Cusp, anterior; commissural; posterior; of mitral valve
noncoronary–see Cusp, semilunar, posterior, of aortic valve
posterior
of aortic valve–see Cusp, semilunar, posterior, of aortic valve
of mitral valve 217–220, 237
of tricuspid valve 216, 218–220, 237
of pulmonary valve–see Cusp, semilunar, anterior; left; right; of pulmonary valve
semilunar
anterior, of pulmonary valve 216, 218
left
of aortic valve 217–221
of pulmonary valve 216, 221
posterior (noncoronary), of aortic valve 217–221
right
of aortic valve 217–221
of pulmonary valve 216, 221
septal, of tricuspid valve 216, 218–220, 237
of tricuspid valve–see Cusp, anterior; posterior; septal; of tricuspid valve
Cymba conchae of external ear 88

D

Dartos–see Fascia, superficial (dartos), of penis; of scrotum
Darwin–see Tubercle, auricular
Declive of cerebellum 107, 109, 137
Decussation
of pyramids 108, 109
of superior cerebellar peduncles 107
Deltoid–see Muscle, deltoid
Denonvilliers'–see Fascia, rectovesical/rectoprostatic (Denonvilliers')
Dens 5, 15, 16
articular facet, 15
of axis (C2 vertebra) 5, **15**, 16, 18, 33, 59
Dentin 53
Depression for trigeminal ganglion–see Impression, trigeminal
Depressor–see Muscle, depressor
Dermatomes–see also Plate 20 for zones of head and neck
of lower limb 157, 525
of neck 465
of trunk 157
of upper limb 157, 465
Descemet–see Lamina, posterior limiting (of cornea)
Descendens
cervicalis–see Root, of ansa cervicalis, inferior
hypoglossi–see Root, of ansa cervicalis, superior
Descent of testis 369
Diameters of pelvic inlet 342
Diaphragm 155–see also Dome
pelvic **343**–348, 372, 373, 375–see also Muscle, levator ani
female 343, 344
male 345, 346
thoracic 184, **188, 189, 191,** 192, 194, 202, 205, 207, 226–229, 232–234, 245, 247, 250, 255, 257, 264, 265, 267, 278, 279, 289, 317, 319, 320, 332, 335, 336, 390, 480
arteries 189, 256
central tendon 188, 189, 255
crura 172, 189, 255, 262, 332, 336, 534–537, 542
function 191
innervation (schema) 190
nerves 189, 190
surface
abdominal 189
projection 192
thoracic 188
veins 257, 326
Diastole 218
Dilator of pupil–see Muscle, dilator, of pupil
DIP–see Joint
Diploë 7
Disc
articular
of sternoclavicular joint 179, 402, 530
of temporomandibular joint 14, 51
of wrist 436–438
intervertebral 17, **148,** 151, 152, 188, 531, 532, 536, 537
lumbar, herniation 156
optic 86
space, intervertebral 149
Disse–see Space, perisinusoidal (Disse)
Division
of brachial plexus 413
of left lung–see Culmen, of left lung; Lingula, of left lung
of mandibular nerve 42
of oculomotor nerve 79, 82, 115
of vestibular nerve 90, 118
Dome
of diaphragm 192, 193, 209
of pleura–see Cupula of, pleura
Dorsum
of foot 501, 502, 512, 513
of hand 445, 451–453, 455, 464
sellae 9
of tongue 54
Douglas–see Line, arcuate, of rectus sheath; Pouch, rectouterine
Drummond–see Artery, marginal (juxtacolic, of Drummond)
Duct–see also Opening
alveolar 200
Bartholin–see Duct, sublingual
bile
(common) 265, 266, 270, 271, 280, 285, 287, 288, 290, 292, 294, 299, 307, 535, 536
intrahepatic 283, 284
bulbourethral 370
cochlear 87, 90–92
cystic 279, 285, 286, 290, 292, 336
parts of 285
variations of 286
ejaculatory 367, 399, 540
endolymphatic 91, 92
epididymal 371
Gartner's–see Duct, longitudinal, of epoöphoron (Gartner)
hepatic
accessory 286
common, 279, 281, 282, 285, 286, 292, 298, 299, 336
of labyrinth 90–92, 118
of lacrimal gland 78
lactiferous 175
longitudinal, of epoöphoron (Gartner) 399
lymph–see also Duct, thoracic; Trunk (lymphatic)
right 204
mesonephric (wolffian) 369, 399
müllerian–see Duct, paramesonephric (müllerian)
nasofrontal–see Canal, nasofrontal
nasolacrimal 33, 46, 78–see also Canal, nasolacrimal
pancreatic 285, 287
accessory 271, 288
interlobular 288
principal 271, 288
paramesonephric (müllerian) 369, 399
paraurethral 362
parotid 21, 50, 51, 57, 65
of Santorini–see Duct, pancreatic, accessory
semicircular, of labyrinth 90–92, 118
Skene's–see Duct, paraurethral
Stenson's–see Duct, parotid
sublingual 57
submandibular 47, 49, 55–57
thoracic 68, 183, 188, 194, 202, 204, 205, 207, 227, 228, 234, **235,** 237, 255, 258, 305, 308, 336, 530–534, 542
Wharton's–see Duct, submandibular
of Wirsung–see Duct, pancreatic, principal
wolffian–see Duct, mesonephric (wolffian)
Ductule
bile 283, 284
of testis 371, 399

Ductus
arteriosus 225
choledochus–see Duct, bile (common)
deferens 245, 251–254, 256, 327, 348, 350, 353, 367, 369–**371,** 372, 383, 389, 390, 396, 399, 528
reuniens 91
venosus 225
Duodenojejunal flexure–see Flexure, duodenojejunal
Duodenum 120, 265, 266, **270, 271,** 288, 294, 319, 327
ampulla 268, 271
arteries of 291–294
ascending (4th) part 262
cap of 268, 271
cross sections 332, 335, 535, 536
descending (2nd) part 172, 264, 267, 285, 287, 332, 536, 537
flexures of 271
inferior (horizontal–3rd) part 262, 335, 537
innervation of (schema) 311
in situ 270
mucosa of 271
musculature of 271
nerves of 309–311
superior (1st) part 265, 267, 268, 279, 285, 535
veins of 299
Dura 156
Dura mater 35, 93–97, 103, 153, 154, 162, 163, 172

E

Ear 87–89
drum–see Membrane, tympanic
external 88
inner 87
lobe–see Lobule, of auricle
middle 87, 88–see also Cavity, tympanic
Ebner–see Gland, serous (Ebner)
Edinger-Westphal–see Nucleus, oculomotor, accessory
Elbow
arteries of 460
bones of 419
collateral circulation at–see Anastomosis, around elbow
joint–see Joint, elbow
ligaments of 421
Eminence
collateral 105
hypothenar 401
iliopectineal–see Eminence, iliopubic
iliopubic 240, 340–342, 345, 468, 469
intercondylar, of tibia 490, 492, 495, 496
medial, of 4th ventricle 109
Eminence *cont.*
median, of tuber cinereum 140
pyramidal, in tympanic cavity 89
thenar 401
Enamel of tooth 53
Endometrium 356
Endothelium
of anterior chamber (cornea) 84
Ependyma 102
Epicondyle
of femur
lateral 420, 471, 475, 492
medial 420, 471, 475, 483, 484, 488, 491, 492
of humerus
lateral 403, 404, 414, 415, 419, 421, 423–426, 428, 431, 461
medial 403, 404, 414–416, 419, 421, 423–431, 459, 460
Epididymis 369–371, 396, 399
Epiglottis 54, 59, 60, 62, 63, 72–74, 129, 229, 231
Epithelium
gingival 53
pigment 84
of tongue 54
Epoöphoron 356, 399
Equator of lens 85
Eruption of teeth 52
Esophagus 31, 59, 61–64, 71, 72, 120, 188, 202, 203, 226–**230,** 231–234, 236, 237, 255, 257, 262, 266, 267, 269, 313, 319, 322, 335
arteries of 233
constrictions 229
cross section 237, 530–534, 541, 542
in situ 228
junctions
esophagogastric 232, **534**
pharyngoesophageal 231
lymph vessels and nodes 235
mucosa/submucosa 231, 232
musculature **230,** 231, 269
nerves 236
Ethmoid–see Bone, ethmoid
Eustachian–see Tube, pharyngotympanic (auditory); Valve, of inferior vena cava
Expiration 191
Eye 44, 77, 80, 83–86, 115, 143, 160–see also Orbit
muscle–see Muscle, of eye
vitreous chamber 144
Eyeball 44, **83**–86
arteries of 86
chambers of 84
extrinsic muscles of 80
lens and supporting structures of 85
veins of 86
Eyelashes 77
Eyelids 77

Face
arteries of 19, 36, 65
lymph nodes of 68, 69
muscles of 22, 50
nerves of 20, 21, 67
veins of 19, 66
zones of sensory innervation 20
Facet
articular–see also Atlas; Dens; Surface, lumbosacral articular; of tibia, articular
anterior (of dens for atlas) 15
for dens 15
of axis
for atlas–see Facet, articular, anterior (of dens for atlas);
for C3 vertebra–see Facet, articular, inferior (of axis) for C3
for transverse ligament–see Facet, articular, posterior (of dens for transverse ligament)
costal
(1st rib) 16
superior (for head of rib) 16, 147, 180
transverse (for tubercle of rib) 16, 147, 180
of cricoid cartilage for thyroid cartilage 76
of dens for transverse ligament–see Facet, articular, posterior (of dens for transverse ligament)
inferior (of axis) for C3 15
inferior articular–see under Vertebra, C3 vertebra
posterior (of dens for transverse ligament) 15, 18
posterior articular–see under Atlas, transverse ligament
(of rib)
for transverse process 179
for vertebral body 179
(of sacrum) for vertebra 150
superior articular 16
(of transverse process) for rib 147, 180
(of vertebra)
for rib–see Facet, articular, costal superior, (for head of rib); transverse (for tubercle of rib)
for sacrum 148
tropism 152
Fallopius–see Tube, uterine
False
pelvis–see Pelvis, false
Falx
cerebelli 97, 137
cerebri 35, 96–98, 134, 137
inguinal (conjoint tendon) 242, 243, 245, 251

Fascia
alar 31, 32, 34
antebrachial 432, 463
of arm–see Fascia, brachial
axillary 411, 462
brachial 418, 462
buccopharyngeal 31, 56, 59, 61
Buck's–see Fascia, deep, (Buck's), of penis
Camper's–see Tissue, subcutaneous, fatty layer, of abdomen
cervical 22, 24, **31,** 59, 182, 407
investing layer 22, 24, 27, 31, 59
pretracheal layer 24, 31, 59
prevertebral layer 31, 56, 59, 61
superficial layer (of deep)–see Fascia, cervical, investing layer
clavipectoral 182, 411
Colles'–see Fascia, perineal, superficial (Colles')
cremasteric 242, 243, 253, 254, 370, 371
cribriform 241, 528
crural–see Fascia, deep, of leg
dartos–see Fascia, superficial, (dartos), of penis; of scrotum
deep
of arm–see Fascia, brachial
(Buck's), of penis 241–243, 247, 248, 335, 348, 363–366, 368, 370, 376, 377, 381, 383, 385
of deep perineal muscles 343
of forearm–see Fascia, antebrachial
of hand–see Aponeurosis, palmar; Fascia, dorsal, of hand
of leg 504, 526–528
deltoid 22
Denonvilliers'–see Fascia, rectovesical/rectoprostatic (Denonvilliers')
dorsal, of hand 445, 451
diaphragmatic 232, 245, 332, 335, 336
endopelvic 351
paravesical 353
extraperitoneal 172, 243, 244, 252, 253, 392–see also Fascia, endopelvic
of eyeball–see Sheath, fascial, of eyeball
Gallaudet's–see Fascia, perineal, deep (investing–Gallaudet's)
geniohyoid 31
gluteus medius–see Aponeurosis, gluteal
iliac 245, 251–253, 351, 373
infradiaphragmatic 232
infraspinatus 167, 170, 186, 246, 407
intercavernous, of deep fascia of penis (Buck's) 365
investing–see also under names of individual muscles or regions

Fascia *cont.*
cervical–see Fascia, cervical, investing layer
of perineum (Gallaudet's)–see Fascia, perineal, deep (investing–Gallaudet's)
lata **241**–243, 355, 359, 363, 364, 387, **482,** 487, 526, 528
levator ani, superior–see Fascia, of pelvic diaphragm, superior
lumbodorsal–see Fascia, thoracolumbar
masseteric 22
nasal fibrofatty 32, 34
of neck–see Fascia, cervical
obturator 343, 345, 351, 352, 354, 355, 361, 373, 382, 391
of orbit 79
paravesical–see under Fascia, endopelvic
parotid 22
pectineal 243, 252
pectoral 22, 175, 415
pelvic–see Fascia, endopelvic
tendinous arch of–see Arch, tendinous, of pelvic fascia
of pelvic diaphragm
deep–see Fascia, of pelvic diaphragm, superior
inferior 355, 360, 361, 373, 375, 377, 385
superficial–see Fascia, of pelvic diaphragm, inferior
superior 351, 352, 354, 355, 360, 373, 375, 377
of penis
deep (Buck's)–see Fascia, deep, (Buck's), of penis
superficial (dartos)–see Fascia, superficial, (dartos), of penis
perineal
deep (investing–Gallaudet's) 348, 353, 355, 360, **361,** 362, **364**–366, 372, 377
superficial (Colles') 335, 348, 353, 355, 360–**362, 363**–366, 372, 376, 377, 384, 385, 391
pharyngobasilar 33, 48, 55, 59–61, 63, 64, 69
plantar 518
presacral 335, 351, 377
pretracheal–see Fascia, cervical, pretracheal layer
prevertebral–see Fascia, cervical, prevertebral layer
prostatic 348, 353, 367
psoas 172, 332
rectal 335, 351, 354, 360, 367, 372–375, 377
rectovesical/rectoprostatic (Denonvilliers') 335, 346, 348, 367, 372, 377
renal 172, **332,** 333, 537
Scarpa's–see Tissue, subcutaneous, membranous layer, of abdomen

Fascia *cont.*
of scrotum–see Fascia, superficial, (dartos), of scrotum
Sibson's–see Membrane, suprapleural
spermatic 254
external 241–243, 251, 253, 254, 348, 363–365, **370,** 371, 376
internal 243, 252–254, 370, 371
subcutaneous–see Tissue, subcutaneous
of abdomen 241, 244, 335, 348, 360, 363, 364
subserous 172, 243, 244, 252, 253, 392
superficial
of abdomen–see Tissue, subcutaneous, fatty layer; membranous layer; of abdomen
cervical (investing)–see Fascia, cervical, investing layer
(dartos), of penis 241–243, 335, 348, 363–365, 370
(dartos), of scrotum 241–243, 335, 348, 363, 370, 371, 376, 385
of penis–see Fascia, superficial; (dartos), of penis; deep, (Buck's), of penis
supradiaphragmatic 232
temporalis 22, 42, 50
of thigh–see Fascia lata
thoracolumbar 145, **167**–170, 172, 185, 186, 246, 320, 337
transversalis 172, 232, 243–**245,** 251–254, 256, 266, 332, 335–337, 348–352, 360
trapezius 22
umbilical prevesical 243–245, 252, 253, 335, 348, 351, 352
of urogenital diaphragm
inferior–see Membrane, perineal
uterine 351
uterovaginal 354, 355, 360
vaginal 354, 372
vesical 335, 348, 351, 353, 354, 360, 372, 377
Fascicle–see Fiber
Fasciculus–see also Fiber
cuneate 108, 109, 158
dorsal longitudinal 140
dorsolateral 158
gracile 108, 109, 158
interfascicular 158
mammillothalamic 100
medial longitudinal 107, 109, 158
proprii 158
semilunar–see Fasciculus, interfascicular
septomarginal 158
sulcomarginal–see Fasciculus, medial longitudinal
transverse, of
palmar aponeurosis 442
plantar aponeurosis 514
Fat–see also Body, fat
of anterior abdominal wall–see Tissue, subcutaneous, fatty layer, of abdomen
of breast 175
in epidural space 163

Fat *cont.*
extraperitoneal 392
hilar 330
in ischioanal fossa–see also Body, fat, of ischioanal fossa
orbital 143–see Body, fat, of orbit
pararenal 172, 332, 537
pericardial 226, 227
perirenal 172, 325, 332, 537
in prevesical space 243
subcutaneous–see Tissue, subcutaneous
of subhiatal ring 232
Fauces 60
Femur 240, 470, **471,** 486, 487, 489, 492, 493–see also Condyle; Head; of femur
Fenestra
cochleae–see Window, round
vestibuli–see Window, oval
Fiber–see also Fasciculus
of ciliary zonule 83–86
of His–see Bundle, atrioventricular
intercrural inguinal 241, 253
of Luschka–see Muscle, levator ani, prerectal fibers
nerve
afferent (sensory) 110–113, 115–120, 122, 123, 126, 206, 314, 315, 317, 318, 331, 395–397
vagal 223, 311
antidromic conduction 160, 161, 315
efferent (motor) 110–112, 115–117, 119–123, 314–see also Fiber, nerve, somatic efferent
mixed 110, 111
motor–see Fiber, nerve, efferent
olfactory 113
parasympathetic 40, 115–117, 119, 120, 159, 206, 314
presynaptic/postsynaptic 126–128, 160, 161, 311, 315, 317, 318
proprioceptive 116, 121, 123
sensory–see Fiber, nerve, afferent
somatic efferent 161, 314, 397
spinoreticular 158
sympathetic 115–117, 159, 206, 314
presynaptic/postsynaptic 126–128, 160, 161, 223, 224, 311, 315, 317, 318, 331, 334, 395, 397
to olfactory bulb 113
Purkinje–see Branch, subendocardial, of conducting system of heart
transverse, of antebrachial fascia (palmar carpal ligament) 429, 430, 437, 442–444, 449, 463
vaginorectal fascial 351
vesicocervical fascial 351
zonular 85, 86–see also Fiber, of ciliary zonule
Fibula 492, **495,** 496, 501, 503, 504, 507–509, 512, 513–see also Head, of fibula
Filum terminale (dural and pial) 153, 154
Fimbria
of hippocampus 100, 102, 104–106, 113
of uterine tube 356
Finger 447, 454
Fissure–see also Sulcus
of cerebellum 107
cerebral
lateral–see Sulcus, cerebral; lateral
longitudinal 101, 136, 138
Sylvian–see Sulcus, cerebral; lateral
for round ligament of liver 279
for ligamentum venosum 279
of lung 192–195, 531, 542
orbital
inferior 2, 4, 79
superior 2, 10, 79
petrosquamous 11
petrotympanic 8
pterygomaxillary 4
ventral median, of spinal cord 158
Flexure
colic
hepatic–see Flexure, colic, right
left (splenic) 261–264, 267, 270, 276, 280, 288, 329
right (hepatic) 261, 263, 264, 267, 270, 276, 280, 288, 332
splenic–see Flexure, colic, left
duodenojejunal 172, 247, 262, 270, 271, 288, 333
of duodenum 271
inferior 271
superior 271
hepatic–see Flexure, colic, right
perineal (of rectum and anal canal) 540
splenic–see Flexure, colic, left
Flocculus of cerebellum 107, 108
Floor
of mouth 49
of nasal cavity 33
of urethra 372
Fluid, cerebrospinal 103
Foerster 465, 525
Fold–see also Ligament; Plica
alar, of knee 494
aryepiglottic 62, 63, 74
axillary
anterior 174
posterior 174
bloodless, of Treves–see Fold, ileocecal
cecal 273, 349, 350
circular 271
of duodenum 271, 287
ileum 272
jejunum 272
duodenal 262, 270
duodenojejunal–see Fold, duodenal
fimbriated, of tongue 47
gastric 232, 268, 534
gastropancreatic 264
glossoepiglottic 54
gluteal 145, 467
ileocecal 273
infrapatellar 494
inguinal 399
interureteric 353
Fold *cont.*
of iris 84
of Kerckring–see Fold, circular, of duodenum; ileum; jejunum
of left vena cava 211, 217
longitudinal 271
mallear 88, 89
palatine, transverse 48
palmate, of cervical canal 356
pharyngoepiglottic 61, 63, 231
pubovesical 245
rectal–see Fold, transverse, of rectum
rectosacral–see Fold, sacrogenital; uterosacral
sacrogenital 266, 350, 373–see also Fold, uterosacral
salpingopharyngeal 60, 62
semilunar
of conjunctiva 77, 78
of fauces 60
of large intestine 276
sublingual 47, 57
transverse, of rectum 374
triangular, of fauces 60
umbilical
lateral 245, 266, 349, 350, 539
medial 244, 245, 266, 349, 350, 380
median 244, 245, 266, 349, 351, 354
ureteric 349, 350, 354
urethral 398
urogenital 398
of uterine tube 356
uterosacral 327, 349, 354, 373–see also Fold, sacrogenital
vascular cecal 273
vesical, transverse 245, 349, 350
vesicosacral 350
vocal 59
Folium of cerebellum 107, 109, 137
Follicle
Graffian–see Follicle, vesicular ovarian
hair 160, 161
lingual–see Tonsil, lingual
lymph
of appendix–see Lymph nodule, of appendix
of small intestine–see Lymph nodule, aggregate of small intestine
of stomach–see Lymph nodule, of stomach
ovarian–see Follicle, vesicular ovarian
vesicular ovarian 356
Fontana–see Space, of iridocorneal angle
Fontanelle 11
Foot
arteries of 518
bones of 505–507
ligaments of 509, 510
lymph nodes of 528
muscles of 512–519
nerves of 522, 523

Foot *cont.*
plantar surface 467
sole of 514–517
tendons of 510
Footplate of stapes, 87, 89
Foramen–see also Aperture; Opening
alveolar, of maxilla 4
apical dental 53
cecum of
frontal bone 9, 10
tongue 54, 59
of cranial base 10
cribriform 10
of emissary veins 7–see also Canal, condylar; Foramen, mastoid; parietal; sphenoidal emissary
epiploic–see Foramen, omental
ethmoidal
anterior 2, 10, 11
posterior 2, 10
infraorbital 2, 4, 11, 32
interventricular (Monro) 100, 102, 103, 105, 109, 138, 139
intervertebral 16, 148–152, 173, 539
for spinal nerves–see Nerve, spinal
ischiatic–see Foramen, sciatic
jugular 6, 8, 9, 97, 98, 119–121
lacerum 8, 10, 93
of Luschka–see Aperture, lateral, of 4th ventricle
of Magendie–see Aperture, median, of 4th ventricle
magnum 6, 8, 10, 93, 121
mandibular 13, 42
mastoid 8, 10
mental 2, 4, 13
of Monro–see Foramen, interventricular (Monro)
nasolacrimal 46
nutrient, of femur 471, 495
obturator 240, 341, 468, 470, 483
omental (epiploic) 264–267, 280, 335, 336
optic 2
ovale of
cranium 4, 8, 10, 12, 41, 42, 93
heart 217, 225
palatine
greater 8, 34, 35, 37, 48, 52
lesser 8, 34, 35, 37, 48, 52
parietal 7
rotundum 10, 40, 41
sacral 149
anterior (ventral) 150, 341, 345, 539
posterior 150, 341, 344, 539
sciatic
greater 152, 340, 341, 344, 522
lesser 152, 340, 341
sphenoidal emissary 10
sphenopalatine 4, 6, 12, 34, 36, 37
spinosum 8, 10, 12, 42, 93
stylomastoid 8, 21, 89, 117, 119
Foramen *cont.*
supraorbital 2, 4, 11
of transverse process 15, 16
vena caval–see Opening, caval
vertebral 15, 16, 147, 148
of Vesalius–see Foramen, sphenoidal emissary
of Winslow–see Foramen, omental (epiploic)
zygomaticofacial 2, 4, 11
Forearm
arteries of 456
bones of 422
cross sections of 432
fascia/fascial compartments of 432, 463
lymph nodes of 466
muscles of 427–431
nerves of 458, 461
cutaneous 463
superficial veins of 462
Foreskin–see Prepuce
Fornix
cerebral 100, 105, **106,** 138, 140
body of 102, 106, 109
column of 104, 106, 138
commissure of 106
crus 104, 106, 136
conjunctival 77
vaginal 347, 356
Fossa–see also Olecranon
acetabular 340, 468, 469, 540
axillary 530–532–see also Axilla
of cochlear window–see Fossa, of round window
condylar, of occipital bone 8
coronoid, of humerus 403, 424
cranial 9
cubital **401**
digastric, of mandible 13
duodenal 262, 270
glenoid–see Cavity, glenoid, of scapula
hypophyseal of sphenoid bone 5, 9, 46
ileocecal 273
ileocolic–see Recess, ileocecal
iliac 340, 341, 349, 350, 468
incisive 8, 48, 52
infraspinous 178, 404
infratemporal 4, 12
intercondylar, of femur 471
interpeduncular 101
intersigmoid 263
ischioanal 355, 360, 361, 363–365, **373,** 375, 377, 385
anterior recess of 245, 353, 355
jugular 8, 89
for lacrimal sac 2, 4
mandibular 4, 8, 11, 14
mesentericoparietal 262
navicular, of urethra 348, 368
olecranon, of humerus 404, 419
of oval window 89
ovalis
of fascia lata–see Opening, saphenous
heart 216, 225, 541
Fossa *cont.*
paraduodenal–see Recess, paraduodenal
pararectal 350
parotid–see Bed, of parotid gland
piriform 62, 229
popliteal **467**
pterygoid
of mandible–see Fovea, pterygoid, of mandible
of sphenoid bone 8
pterygopalatine 4, 12, 36, 40
radial, of humerus 403, 419
retrocecal–see Recess, retrocecal
rhomboid, of 4th ventricle 108
of round window 88, 89
scaphoid
of external ear 88
of sphenoid bone 8, 93
sublingual 13
submandibular 13
subscapular 178, 403
supraspinous 178, 404
supratonsillar 60
supravesical 245
temporal 4, 12
triangular, of ear 88
trochanteric, of femur 471
of vestibular window–see Fossa, of oval window
Fourchette–see Commissure, labial
Fovea
caudal–see Fovea, inferior, of 4th ventricle
centralis, in macula (lutea) 83, 86
of head of femur 471
inferior, of 4th ventricle 109
pterygoid, of mandible 13
superior, of 4th ventricle 109
Foveola, granular 7, 94, 96
Framework, bony
of abdomen 240
of head and neck 12
of thorax 178
Frenulum
of clitoris 359
of ileal orifice 274
of lip 47
of penis 365
of tongue 47, 57
Fundus
of gallbladder 279, 285
of stomach 229, 232, 267, 268, 534
of urinary bladder 348, 353
of uterus 347, 349, 354, 356
Funiculus, lateral 109

G

Galea aponeurotica–see Aponeurosis, epicranial
Galen–see Vein, cerebral, great (Galen)
Gallaudet–see Fascia, perineal, deep
Gallbladder 120, 160, 192, 261, 264, 267,

Gallbladder *cont.*
278–280, **285,** 286, 292, 336, 535
artery (cystic) of 290, 292
innervation (schema) 321
parts 285
referred pain from 321
surface projection of 278
Ganglion
aorticorenal 159, 160, 259, **308,** 310–316, 330, **331,** 334, 389, 390, 394–397
basal–see Nucleus, basal
celiac 120, 159–161, 236, 259, **308,** 309–**314,** 315, 317, 318, 330, 334, 336, 389, 390, 394–397
cervical sympathetic
inferior–see Ganglion, cervicothoracic (stellate)
middle 67, 124, 159, 161, 222, 223, 236
superior 29, 40, 56, 119, 122, **124,** **125**–128, 159, 161, 206, 222, 223, 236
laryngopharyngeal branch 129
cervicothoracic (stellate) 124, 159, 205, 222, 223, 236
ciliary 41, 82, 115, 116, 125, **126,** 159, 160
cochlea (spiral) 91, 118
dorsal root–see Ganglion, spinal sensory
geniculate 40, 42, 110, 117–119, 125, 129
of glossopharyngeal nerve
inferior 119, 128, 129
superior 119
inferior
of glossopharyngeal nerve 119, 128, 129
of vagus nerve 120–122, 129, 236
jugular–see Ganglion, superior, of glossopharyngeal nerve; of vagus nerve
lumbar sympathetic 163, 224, 308, 330, 331, **389, 390,** 392, 394–396
mesenteric
inferior 159–161, 308, **313,** 314, 330, 389, 390, 394–397
superior 120, 159–161, 259, 308, 310–**312, 313**–315, 318, 330, 331, 334, 389, 390, 394–397
nodose–see Ganglion, inferior, of vagus nerve
otic 14, 42, 51, 116, 117, 119, 125, 127, **128,** 129, 159, 160
petrosal–see Ganglion, inferior, of glossopharyngeal nerve
phrenic 310, 317
pterygopalatine 38–41, 58, 67, 115–117, 119, 125, **127,** 129, 159, 160
nasal branches 38–40, 125, 127
pharyngeal branch 39, 58, 116, 127
renal 330, 331, 334, 396, 397
sacral sympathetic 161, 308
semilunar–see Ganglion, trigeminal
spinal sensory (dorsal root) **162,** 163, 173, 187, 250, 311, 314, 315, 317, 318, 331, 397
spiral–see Ganglion, cochlear (spiral)
stellate–see Ganglion, cervicothoracic (stellate)
Ganglion *cont.*
submandibular 42, 55, 57, 67, 116, 117, 125, **127,** 159, 160
superior
of glossopharyngeal nerve 119
of vagus nerve 120, 121, 236
of sympathetic trunk
cervical
inferior–see Ganglion, cervicothoracic (stellate)
middle 67, 124, 159, 161, 222, 223, 236
superior 29, 40, 56, 119, 122, **124,** **125**–128, 159, 161, 206, 222, 223, 236
lumbar 163, 224, 308, 330, 331, **389, 390,** 392, 394–397
sacral 161, 308
thoracic 126, 159, 163, 187, 205, 222, 223, **236,** 237, 311, 315, 395, 396
vertebral 124, 159, 222, 223, 236
thoracic sympathetic 126, 159, 163, 187, 205, 222, 223, **236,** 237, 311, 315, 395, 396
trigeminal **41,** 42, 82, 93, 98, 110, 111, 116, 125–129
of vagus nerve–see Ganglion, inferior; superior; of vagus nerve
vertebral sympathetic 124, 159, 222, 223, 236
vestibular 90, 118
Gartner–see Duct, longitudinal, of epoöphoron (Gartner)
Gasserian ganglion–see Ganglion, trigeminal
Geniculum of facial nerve 89, 92, 111, 118
Genitalia
female 359, 398
homologues of 398, 399
male 363–365, 370, 398
Genu
of corpus callosum 100, 101, 104, 106, 139
of facial nerve
external–see Ganglion, geniculate
internal–see Geniculum of facial nerve
of internal capsule 104
Gerdy–see Tubercle, Gerdy's
Gimbernat–see Ligament, lacunar
Gingiva (gum) 53
Glabella 1, 2, 4
Gland
adrenal–see Gland, suprarenal
anal 374
areolar 175
Bartholin's–see Gland, vestibular, greater
Brunner's 271–see also Gland, duodenal
bulbourethral (Cowper's) 245, 335, 348, 353, 366–368, 399
Cowper's–see Gland, bulbourethral
duodenal 271
gastric 268
intestinal 316
lacrimal 41, 78, 79, 81, 82, 127, 160
Gland *cont.*
lingual 47, 54
of Littré–see Gland, urethral, male
mammary 175–see also Breast
meibomian–see Gland, tarsal
mucous, of tongue 54
palatine 48, 59, 60
parathyroid 71, 72
parotid **21,** 23, 24, 27, 43, 56, 57, 62, 68, 119, 128, 160, 161
accessory 57
pineal–see Body, pineal
pituitary 142–see also Hypophysis (pituitary gland)
preputial 365
prostate–see Prostate
pyloric 268
retromolar 48
salivary 56, 57–see also Gland, parotid; sublingual; submandibular
sebaceous 77
serous (Ebner) 54
Skene's–see Gland, urethral, female
Stenson's–see Gland, parotid
sublingual 42, 47, 49, 56, 57, 117, 127, 160
submandibular 1, 23, 24, 27, 28, **42,** 49, 56, **57,** 62, 65, 66, 117, 127, 160
suprarenal 160, 161, 193, 264, 266, 270, 279, 288, 289, 319, 321, 332, **333**–336, 369
arteries of 322, 333
cross section of 333, 535, 536, 542
of infant 321
innervation of (schema) 334
nerves of 334
veins of 333
sweat 160, 161, 374
tarsal (meibomian) 77
thymus 207, 226, 227, 531
thyroid 24, 25, 27, 29, 31, 59, 66, **70,** 71, **72,** 192, 194, 202, 541
arteries of 65, 70
veins of 66, 70
Tyson's–see Gland, preputial
urethral
female 362, 399
male 368, 399
vestibular, greater 361, 384, 399
Wharton's–see Gland, submandibular
Glans of
clitoris 359, 398
penis 339, 348, 363, 368, 398, 400
Glisson–see Capsule, of liver
Globe–see Eyeball
Globus pallidus 102, 104
Glomerulus of
kidney 325, 326
olfactory nerves 113

Gonad 369, 399–see also Ovary; Testis
Graffian follicle–see Follicle, vesicular ovarian
Granulation, arachnoid 94–96, 103
Groove–see also Sulcus
for anterior meningeal vessels 9
atrioventricular–see Sulcus, coronary
of auditory tube–see Sulcus, of pharyngotympanic (auditory) tube
chiasmatic–see Sulcus, prechiasmatic
for circumflex scapular vessels 404
coronary (for coronary artery) 533
costal 179
for digastric muscle–see Notch, mastoid
gingival 53
for greater petrosal nerve 9, 92
for inferior petrosal sinus 6, 9
for inferior vena cava, on bare area of liver 279
infraorbital 2
intermuscular anal–see Groove, intersphincteric
for internal carotid artery–see Sulcus, carotid
intersphincteric 373–375
intertubercular, of humerus–see Sulcus, intertubercular, of humerus
interventricular 533
for lesser petrosal nerve 9
mastoid–see Notch, mastoid
for middle meningeal vessels 6, 7, 9
for middle temporal artery 4, 7
mylohyoid 13
for nasopalatine nerve and vessels–see Groove, vomerine
obturator 473
occipital 8
for occipital artery–see Groove, occipital
for occipital sinus 9
for posterior meningeal vessels 9
for radial nerve 404
for sigmoid sinus 6, 9
for spinal nerve 16
for subclavian artery 179
for subclavian vein 179
for superior petrosal sinus 6, 9
for superior sagittal sinus 7, 9
for transverse sinus 6, 9
for ulnar nerve 404, 419
urogenital 398
for vertebral artery 15
vomerine (for nasopalatine nerve and vessels) 35
Gubernaculum 369, 399
Gum–see Gingiva (gum)
Gutter, paracolic 263, 273, 337, 349, 350
Gyrus
angular 99
cingulate 100, 101
dentate 100, 102, 105, 106, 113
frontal 99, 100
of insula 99
lingual 100, 101
marginal 100
Gyrus *cont.*
occipitotemporal 100, 101
orbital 101
parahippocampal 100–102, 113
paraterminal–see Gyrus, subcallosal
postcentral 99
precentral 99
straight 101
subcallosal 100
supramarginal 99
temporal 99, 101

H

Habenula 104
Hair
follicle 160, 161
Hamate 435, 436, 438–440–see also Hook of Hamate
Hamulus
of cochlea–see Hamulus, of spiral lamina (of cochlea)
of hamate–see Hook of hamate
pterygoid 4, **6,** 8, 11, 12, 34, 42, 46, 48, 51, 60, 61, 64, 93
of spiral lamina (of cochlea) 90
Hand
arteries of 449, 452, 456
bones of 439
ligaments of 441
lymph nodes of 466
muscles (intrinsic) of 442–448, 453
nerves of 449–453, 455, 456, 458, 459, 461
veins of 451, 463
Handle, of malleus 88
Hartmann–see Infundibulum, of gallbladder
Haustra of large intestine 276
Head–see also individual regions; Muscle
of caudate nucleus 104–106, 136, 138
of epididymis 371
of femur 469–471, 540
of fibula 474–476, 488, 489, 491–493, 495, **496,** 499–503, 524
of humerus 403, 405, 406
of malleus 89, 118
of mandible 4, 13
of metacarpal bones (5th) 439, 440
of metatarsal bones 505
of pancreas 271, 288, 536
of phalanges (foot) 501
of phalanges (hand) 439
of phalanx (proximal) 440
of radius 414, 419, 420, 422
of rib 178, 179, 533
of talus 506, 508
Heart 120, 160, 161, 207, 208, 210, 212, 213, 217–219, **220**–223, 533, 541
arteries of 212–215
chambers of 216, 217, 220
Heart *cont.*
conducting system of 221
cross section of 220, 237, 533, 541, 542
exterior features 208, 210
in situ 207
innervation of (schema) 223
internal features 216–220
nerves of 222
pericardial sac for 207, 211
surfaces of 208, 210
valves of 218, 210
veins of 212
Helicotrema of cochlea 87, 90, 91
Helix 1–see also Antihelix
of external ear 88
Helvetius–see Collar, of Helvetius
Hematoma
site of epidural–see Interface, dura-skull
site of subdural–see Interface, arachnoid-dura
Hemisphere, cerebral 96, 99–101, 104, 143
Henle–see Loop, nephronic (Henle's)
Hering–see Ductule, bile
Hering-Breuer–see Reflex, Hering-Breuer
Hernia sac–see Neck, of hernia sac
Hesselbach–see Triangle, inguinal
Hiatus–see also Opening
adductor 475, 483, 484, 494, 521
anorectal 345
of deep dorsal vein of penis 345
esophageal 189
for greater petrosal nerve 10
for lesser petrosal nerve 10
sacral 150
saphenous–see Opening, saphenous
semilunar, of ethmoid bone 33, 34, 45, 46
for urethra 345
Hilton–see Groove, intersphincteric
Hilum
of kidney 321, 537
of lung 195, 532
Hip
arteries of 486
bone–see Bone, hip (coxal)
joint 469
ligaments of 469, 471
muscles of 476–478
nerves of 485
Hippocampus 102, 104–106
His–see Bundle, atrioventricular (His)
Homologues
external genitalia 398
internal genitalia 399
Hook of Hamate 425, 431, 435, 437, 439, 440
Horn–see also Cornu
anterior, of lateral ventricle–see Horn, frontal, of lateral ventricle
coccygeal–see Cornu, coccygeal
frontal (anterior), of lateral ventricle 102
of gray matter 158
of hyoid bone
greater 12, 64

Horn *cont.*
lesser 12
inferior, of lateral ventricle–see Horn, temporal, of lateral ventricle
lateral, of gray matter 158, 163–see also Nucleus, intermediolateral (IML)
of lateral ventricle–see Horn, frontal; occipital; temporal; of lateral ventricle
occipital, of lateral ventricle 102, 104–106, 136, 139
posterior, of lateral ventricle–see Horn, occipital, of lateral ventricle
sacral–see Cornu, sacral
temporal, of lateral ventricle 102, 105, 106, 139
of thyroid cartilage 64, 73, 231
Houston–see Fold, transverse, of rectum
Huebner–see Artery, striate, distal medial
Humerus 403, 404, 405, 416, 418–421, 433, 434–see also Head; Neck; Trochlea; of humerus
Hunter–see Canal, adductor
Hydatid of Morgagni–see Appendix, vesicular
Hymen of vagina 355, 359
Hyoid–see Bone, hyoid
Hypopharynx 62–see also Laryngopharynx
Hypophysis (pituitary gland) 33, 98, 100, 101, 140
arteries and veins of 141
Hypothalamus 102, 129, 140, 141, 314

I

Ileum 261, 263, 272–274, 276, 337, 338, 349, 350, 470, 537–539
Ilium 240, 340–342, 345, 468–see also individual landmarks
Impression
of liver 279
of lung 195
trigeminal 9
umbilical 538
Incisure–see Notch
angular, of stomach–see Notch, angular, of stomach
cardiac–see Notch, cardiac, of stomach
Incus 87, 88, 91, 118
Infundibuliform–see Fascia, spermatic, internal
Infundibulum
of ethmoid bone–see Infundibulum, ethmoidal
ethmoidal 34
of gallbladder 285
of neurohypophysis (pituitary stalk) 108, 133, 140
Innervation
of abdominal viscera 312–322
afferent, of mouth and pharynx 58
autonomic
of blood vessels 224
of nasal cavity 40
of biliary tract 317
of blood vessels 224
cutaneous
Innervation *cont.*
of abdomen 249, 250
of back 170, 186, 187
of back of neck and scalp 170, 171
of head and neck 20
of lower limb 520–527
of thorax 173, 182, 187, 249, 250
of upper limb 455, 457–459, 461–465
of duodenum 309, 311
of extrinsic eye muscles 80
of heart 223
of intestines 314
of kidneys 331
of liver 317
of pancreas 318
of reproductive organs
female 395
male 396
segmental, of lower limb movements 525
segmental, of skin–see Dermatomes
of stomach 315
of tracheobronchial tree 206
of ureters 331, 397
of urinary bladder 397
Inscriptions, tendinous, of rectus abdominis muscle 242
Insertion of
arm muscles 403, 404
forearm muscles 433, 434
hip muscles 472, 473
leg muscles 497
scalene muscles 26, 179
shoulder muscles 402–404
thigh muscles 472, 473
Inspection of
mouth 47
Inspiration 191
Insula 99, 104, 134
Interface
arachnoid-dura 96
dura-skull 96
Intersection, tendinous–see Tendon, intersection, tendinous
Intestine
innervation of (schema) 314
intrinsic autonomic plexuses of 316
large 261, 263, 276–see also Colon
arteries of **296,** 297
lymph vessels/nodes of 306
mesenteric relations of 263
mucosa of 276
musculature 276
nerves of 313
veins of 301
small 120, 261, 272, 335, 337–see also Duodenum; Ileum; Jejunum
arteries of 295
lymph vessels/nodes of 305
mesenteric relations of 262
mucosa of 272
musculature of 272
nerves of 312
autonomic (schema) 316
veins of 300, 301
Iris 77, 83, 85, 86
Ischium 468, 470–see also individual landmarks
Island
of Langerhans–see Islet, pancreatic
of Reil–see Insula
Islet, pancreatic (island of Langerhans) 288
Isthmus of
cingulate gyrus 100, 101
prostate 367
thyroid gland 70

J

Jacobson–see Nerve, tympanic
Jaws 14–see also Mandible
angle of–see Angle of jaw
Jejunum 261–263, 270–272, 337–see also Intestine, small
proximal 271
Joint
acromioclavicular 408
atlantoaxial 15, 17, 18
atlantooccipital 17, 18
of back 151, 152
carpometacarpal 436, 438
costotransverse 180, 530
costovertebral 180
craniovertebral–see Joint, atlantoaxial; atlantooccipital
elbow 419, 421, 456
facet–see Joint, zygapophyseal
glenohumeral 406, 409, 415–see Joint, shoulder
hip 469, 474, 475, 478, 486
intercarpal 436, 438
intermetacarpal 438
interphalangeal
distal (DIP) 401
proximal (PIP) 401
interphalangeal (finger) 441, 447, 454
interphalangeal (toe) 510
intervertebral (symphysis) 16
knee 488–493
manubriosternal 179
metacarpophalangeal 441, 510
midcarpal 436, 438
radiocarpal–see Joint, wrist
radioulnar
distal 435–438
proximal 419, 421, 422
sacroiliac 342, 345, 539
shoulder (glenohumeral) 406, 409, 415
sternoclavicular 179, 192, 402, 530
sternocostal **179,** 402
sternomanubrial–see Joint, manubriosternal
tarsometatarsal 505, 506
temporomandibular 14, 36, 50, 51
of thorax 179, 180
transverse tarsal 505, 506

Joint *cont.*
vertebral body 16
wrist (radiocarpal) 435–438
zygapophyseal (facet) 16–18, 151, 533–see also Facet, articular, costal, superior (for head of rib)
Jugum of sphenoid bone 9
Junction
anorectal 346–see also Line, anorectal; pectinate of
atlantooccipital 16–see Joint, atlantooccipital
of bile duct with duodenum–see Junction, choledochoduodenal
choledochoduodenal 287
duodenojejunal 172–see also Flexure, duodenojejunal
esophagogastric 232, 268, 534, 541
ileocecal 273, 274, 538
manubriosternal 179, 532
pharyngoesophageal 231
rectosigmoid 276, 372, 374, 375
ureteropelvic 537

K

Kerckring–see Fold, circular, of duodenum; ileum; jejunum; Valve of Kerckring
Kidney 172, 193, 225, 264–267, 270, 279, 280, 289, **319–321,** 327, 332, 333, 336, 369, 380, 535–537
arteries 326
internal (intrarenal) 323
variations 324
cross sections 321, 331
in situ 319, 320
innervation (schema) 331
lymph vessels anal nodes 329
microvasculature 326
nerves 330
relations 319, 320, 332
segments 323
structure
gross 321
internal 325, 326
vasculature 322–see also Kidney, microvasculature
Knee
arteries of 494
collateral circulation at–see Anastomosis, around knee
cross section of 493
joint–see Joint, knee
lymph nodes of 528
lymph vessels/nodes at–see Lymph node, popliteal

L

L3 vertebra–see Body, of L3 vertebra; Pedicle, vertebra; Process, spinous , of vertebra
Labbé–see Vein, anastomotic, inferior
Labium–see also Lip
majus 347, 352, 355, 359, 362, 398
minus 347, 352, 355, 359, 362, 398
Labrum
of acetabulum 340, 469, 486
glenoid, of scapula 410
Labyrinth
bony 90–92
membranous 90–92
osseous–see Labyrinth, bony
Lacertus fibrosus–see Aponeurosis, bicipital
Lacuna
lateral (venous), of superior sagittal sinus 94, 95
of Morgagni–see Lacuna/urethral
of urethral gland–see Lacuna/urethral
urethral 362, 368
Laimer–see Area, of Laimer
Lake, lacrimal 77, 78
Lambda 7
Lamina 16–see also Layer; Plate
affixa 105
cribrosa, of sclera 83
of L4 vertebra 149
medullary, of thalamus 105
osseous spiral, of cochlea 91
posterior limiting, of cornea (Descemet's membrane) 84
propria, of gingiva 53
quadrigeminal–see Plate, tectal
tectal–see Plate, tectal
terminalis 100, 101, 109, 140
of thyroid cartilage 63, 73
of vertebra 16, 147, 148, 151, 152
Langerhans–see Islet, pancreatic (of Langerhans)
Laryngopharynx 58, 59, 62
Larynx 129, 161, 206
arteries of 72
cartilages (skeleton) of 73
muscles of 74, 75
extrinsic (infrahyoid and suprahyoid muscles) 25
intrinsic 74
action of 75
nerves of 70, 72, **76**
Layer–see also Lamina
nuclear, of medulla oblongata 107
odontoblast 53
of rectus sheath 244
Leg
arteries of 498–502
bones of 495, 496
cross sections of 504
deep fascia of 504, 526–528
lymph nodes of 528
muscles of 498–503
Leg *cont.*
nerves of 498–502, 522–524
veins of 498–502
Lens 77, 83–86, 143
Leptomeninges 163
Ligament–see also Fold; Raphe
acetabular, transverse 340, 469
alar 18
of ankle 496, 509, 511
anococcygeal 344, 360, 361, 396, 397
anterior, of head of fibula 496
anular
of fibrous digital sheath–see Part, anular, of fibrous digital tendon sheath of fingers
of radius 421
of trachea 198
apical, of dens 18, 59, 61
arcuate
of diaphragm 189, 255
popliteal 490, 493
pubic–see Ligament, pubic, inferior (arcuate)
of atlas 18
bifurcate (of transverse tarsal joint) 509
broad 327, 347, 349, 354–356, 399
calcaneocuboid 509, 518
dorsal 509
plantar 510
calcaneofibular 496, 507, 509
calcaneometatarsal–see Band, lateral, of plantar aponeurosis
calcaneonavicular, plantar (spring) 509, 510, 518
capitotriquetral 437
cardinal (transverse cervical or Mackenrodt's) 351, 354–357
carpal 429, 430, 437, 441–444, 449, 463
palmar–see Fiber, transverse, of antebrachial fascia
transverse (flexor retinaculum) 430, 437, 443–445, 448, 449, 456
carpometacarpal 437, 438, 441
cervical
lateral–see Ligament, cardinal
transverse–see Ligament, cardinal
check, of rectus muscles 79
collateral
of ankle 509
of elbow 421
fibular (of knee) 475, 476, 488–493, 496, 499, 500, 502, 503
of finger–see Ligament, collateral, of interphalangeal joint, of hand
of interphalangeal joint
of foot 510
of hand 441, 447
of knee 475, 476, 488–491, 493, 496, 499–503
of metacarpophalangeal joint 441
of metatarsophalangeal joint 510
radial
of elbow joint 421

Ligament *cont.*
of wrist joint 437, 438
tibial (of knee) 475, 488–493, 499–502
of toe–see Ligament, collateral, of interphalangeal joint, of foot
ulnar
of elbow 421
of wrist joint 437, 438
of wrist 437, 438
conoid 406, 408
Cooper's–see Ligament, pectineal; suspensory, of breast
coracoacromial 406, 408, 409, 414
coracoclavicular 406, 408
coracohumeral 406
coronary, of liver 266, 279, 335
costoclavicular 179, 402, 411
costocoracoid 182, 411
costotransverse 180, 187, 250
costovertebral 180
costoxiphoid 179
craniocervical 17, 18
cricothyroid, median 25, 61, 64, 70, 73, 198
cruciate
of atlas 18
of fibrous digital sheath–see Part, cruciate, of fibrous digital tendon sheath of fingers
of knee 489–491, 496
cuboideonavicular
dorsal 509
plantar 510
cuneocuboid, dorsal 509
cuneonavicular
dorsal 509
plantar 510
deep
posterior sacrococcygeal 341
transverse metacarpal 441, 448
transverse metatarsal 510, 518
deltoid–see Ligament, medial (collateral), of ankle
denticulate 162
diaphragmatic (of gonad)–see Ligament, suspensory, of gonad
of elbow 421
falciform 244, 245, 261, 266, 267, 279, 297, 302, 336
fibular collateral–see Ligament, collateral, fibular
of foot 509, 510
fundiform, of penis 241, 251, 335, 348
gastrolienal–see Ligament, gastrosplenic
gastrophrenic 264, 266, 319
gastrosplenic 264–266, 289, 319, 336
Gimbernat's–see Ligament, lacunar
glenohumeral 406
of hand 441
of head of femur 469
of head of fibula 493, 496
hepatoduodenal 264, 267, 270, 271, 280, 535
hepatogastric 267, 280
of hip 469, 474, 475, 486

Ligament *cont.*
humeral, transverse 406
hyoepiglottic 59, 73
iliofemoral 469, 478, 486
iliolumbar 152, 320, 341
of incus 89
infundibulopelvic–see Ligament, suspensory, of ovary
inguinal (Poupart's) 239, 241–243, 251, 252, **253,** 255, 339, 343, 349–351, 360, 363, 364, 387, 467, 474, 480, 482, 483, 526, 528
intercarpal, interosseous 438
intercartilaginous, of trachea 198
interclavicular 179, 402
intercuneiform, dorsal 509
interfoveolar 245
interosseous–see under Ligament, intercarpal; sacroiliac; talocalcaneal –see also Membrane, interosseous of
interphalangeal
of foot 510
of hand 441, 447
interspinous 151, 152
intertransverse 180
ischiofemoral 469, 486
of knee 474–476, 488–494, 496, 499, 500, 503
lacunar (Gimbernat's) 242, 243, 245, 251, 252, 255, 528
lateral
(collateral) of ankle 509
of temporomandibular joint 14, 36
lienorenal–see Ligament, splenorenal
longitudinal
anterior 17, 59, 61, 151, 152, 172, 180, 255, 335–337, 341, 349, 350
posterior 18, 151, 152
lumbocostal 320
Mackenrodt's–see Ligament, cardinal
of malleus 89
of Marshall–see Fold, of left vena cava
medial (collateral), of ankle 496, 507, 509
meniscofemoral, posterior 490, 491
metacarpal
dorsal 438
palmar 437, 441
transverse
deep 441, 448
superficial 442, 463
metacarpophalangeal 441, 447
metatarsal
dorsal 509, 518
plantar 510, 514, 518
transverse
deep 510, 518
superficial 514
nuchal–see Ligamentum, nuchae
oblique popliteal 490, 493
of ovary 347, 349, 354–357, 399
palmar
carpal 429, 430, 437, 442–444, 449, 463

Ligament *cont.*
carpometacarpal 437, 441
digital 441, 447, 454
metacarpal 437, 441
radiocarpal 437
radioulnar 437
ulnocarpal 437
palpebral 77, 79
patellar 439, 467, 474–476, 483, 490, 493, 496, 501–503
pectineal (Cooper's) 242, 243, 245, 251, 252, 255
of pelvis 340, 341
perineal, transverse 343, 345, 348, 352, 360, 366, 385
phrenicocolic 264, 266
phrenoesophageal 232
pisohamate 437
pisometacarpal 437
plantar
calcaneocuboid 510
calcaneonavicular 509, 510, 518
cuboideonavicular 510
cuneonavicular 510
long 509, 510, 518
metatarsal 510, 518
short 492 518
tarsometatarsal 510
popliteal
arcuate 490, 493
oblique 490, 493
Poupart's–see Ligament, inguinal
proper ovarian–see Ligament, of ovary
pubic, inferior (arcuate) 240, 347, 348, 351, 352, 360, 366
pubofemoral 469
puboprostatic 352, 353
pubovesical 351–353
pulmonary 195, 204, 226, 227
radial collateral–see Ligament, collateral, radial, of elbow joint; of wrist joint
radiate
carpal 437
of head of rib 180
sternocostal 402
radiocarpal 438
radioulnar 438
rectosacral–see Ligament, uterosacral
reflected inguinal 242, 243, 251
round
of femur–see Ligament, of head of femur
of liver 225, 245, 267, 279, 280, 297, 302, 337
of uterus 347, 349, 353–**355,** 357, 360, 362, 380, 399
sacrococcygeal
anterior 255, 341, 343, 345, 351
lateral 152, 340, 341
posterior 152, 340, 341
sacrogenital–see Ligament, uterosacral; Fold, sacrogenital

Ligament *cont.*
sacroiliac
anterior 341
dorsal–see Ligament, sacroiliac, posterior
interosseous 539
posterior 152, 340, 341
sacrospinous 152, 340, 341, 344, 346, 390, 477, 485
sacrotuberous 152, 340, **341,** 344, 346, 361, 376, 377, 382, 390, 391, 393, 477, 484, 485, 540
of scapula 406, 408–410
scapular, transverse
inferior 409
superior 406, 408, 409, 410
sphenomandibular 14, 36, 51
spiral, of cochlea 91
splenorenal 264, 266, 289, 319, 336
spring–see Ligament, calcaneonavicular, plantar (spring)
sternoclavicular 402
sternocostal 179, 402
stylohyoid 12, 55, 60, 61, 64
stylomandibular 12, 14
supraspinous 151, 152, 172, 337, 340, 341
suspensory
of axilla 411
of breast 175
of clitoris 360, 361
of gonad 369, 399
of lens–see Zonule, ciliary; see also Fiber, zonular
of ovary 347, 349, 351, 354–356, 380, 399
of penis 242, 335, 348
talocalcaneal 507, 509
talocrural
lateral–see Ligament, collateral, of ankle
medial–see Ligament, medial (collateral), of ankle
talofibular 496, 507, 509
talonavicular 509
tarsometatarsal
dorsal 509, 518
plantar 510
temporomandibular–see Ligament, lateral, of temporomandibular joint
thyroepiglottic 73
tibial collateral–see Ligament, collateral, tibial, (of knee)
tibiocalcaneal–see Part, of medial (collateral) ligament of ankle
tibiofibular 496, 507, 509
tibionavicular–see Part, of medial (collateral) ligament of ankle
tibiotalar–see Part, of medial (collateral) ligament of ankle
transverse–see also Atlas (C1)
acetabular–see Ligament, acetabular, transverse
of atlas 18
cervical–see Ligament, cardinal
Ligament *cont.*
humeral–see Ligament, humeral, transverse
of knee 491
metacarpal–see Ligament, metacarpal, transverse, deep; superficial
metatarsal–see Ligament, metatarsal, transverse, deep; superficial
perineal 343, 345, 348, 351, 352, 360, 366, 385
posterior articular facet–see under Atlas (C1), transverse ligament
scapular–see Ligament, scapular, transverse
trapezoid 406, 408
of Treitz–see Muscle, suspensory, of duodenum
triangular, of liver 266, 279
ulnar collateral–see Ligament, collateral, ulnar, of elbow; of wrist joint
ulnocarpal 438
umbilical–see also Fold, umbilical
medial 225, 243–**245,** 252, 253, 256, 327, 349–351, 380, 382, 383, 539
median 245, 252, 253, 335, 351, 352, 380, 383
uterine, lateral–see Ligament, broad
uterosacral 347, 351, 354, 356, 357
of vertebral column 151, 152
vocal 73, 74
of wrist 437, 438
Y, of Bigelow–see Ligament, iliofemoral
Ligamentum
arteriosum 202, 208, 217, 225, 227
capitis femoris–see Ligament, of head of femur
flavum 17, 151, 152, 337
nuchae 17, 145
teres–see Ligament, round, of liver; of uterus
venosum 225
Limb
of incus 88, 89
lower 468–528
of stapes 87, 88
of supraventricular crest (parietal and septal) 216
upper 402–466
Limbus
of acetabulum–see Margin, acetabular
of cornea 77
of fossa ovalis 216
Limen
of insula 99, 134
nasal 33
Line–see also Plane
anocutaneous–see Groove, intersphincteric
anorectal 374
arcuate
of ilium 240, 340, 341, 343, 345, 468
of rectus sheath 243, 245, 247, 251, 335
dentate, of anal canal–see Line, pectinate, of anal canal
gluteal 340, 468
Line *cont.*
Hilton's white–see Groove, intersphincteric
iliopectineal 341, 345, 373
intermediate, of iliac crest 240, 340, 341, 468
intersphincteric anal–see Groove, intersphincteric
intertrochanteric, of femur 469, 471
mylohyoid 13
nuchal
inferior 8
superior 8, 167–169
oblique, of
mandible 4, 13, 64
thyroid cartilage 25, 73
tibia 489, 495
pectinate, of
anal canal 374
femur 475
pubis 240, 255, 340, 341, 345, 468
pectineal
of femur 471
of pubis–see Pecten, pubis
Schwalbe's 84
semilunar, of abdomen 239, 260, 339
soleal, of tibia 495
temporal 4
transverse sacral–see Ridge, transverse, of sacrum
white, of Hilton–see Groove, intersphincteric
zigzag (Z), of stomach 232, 268
Linea
alba 174, 182, 239, **241**–244, 250, 251, 336–339, 349, 350, 539
aspera of femur 471
semicircularis–see Line, arcuate, of rectus sheath
semilunaris–see Line, semilunar, of abdomen
terminalis (of pelvis) 150, 341, 349–351, 355
Lingula
of cerebellum 107, 109, 137
of left lung 194–197
of mandible 13
of pancreas–see Process, uncinate, of pancreas
Lip 47–see also Labium
of bicipital groove–see Crest, of humeral tubercle
of iliac crest 240, 340, 341
superior
tubercle–see Tubercle, of superior lip
Lips–see Commissure
Lissauer–see Fasciculus, dorsolateral
Littré–see Gland, urethral (male)
Liver 120, 192, 193, 225, 234, 238, 261, 264, 267, 270, 278, **279**–281, 283, 285, 332, 333, 335, 336
arteries of 290, 292, 297
bed of 279
collateral supply of 297
cross sections of 534–537, 541, 542
histology of 282–284

Liver *cont.*
in situ 280
innervation of (schema) 317
intrahepatic vascular and duct systems 281, 282
lobes 338
segments and lobes 281
structure (schema) 283
surfaces 279
topography 278
variations in form 280
Lobe
cerebellar 107
cerebral 99
ear–see Lobule, of auricle
eparterial–see Bronchus, eparterial
frontal 99
of liver 267, 281
of lung–see Lobe, pulmonary
occipital 99, 114
parietal 99
piriform 113
of pituitary gland 133, 140
of prostate 367, 383
pulmonary 194–197, 237, 534, 542
temporal 99, 134, 143
of thyroid gland 70, 72
Lobule 1
of auricle 88
cerebellar 107, 109, 137
of external ear–see Lobule, of auricle
of mammary gland 175
paracentral, of cerebrum 100
parietal, of cerebrum
inferior 99
superior 99
of testis 371
Locus ceruleus 109
Loop, nephronic (Henle's) 325, 326
Lunate 435–439, 440
of acetabulum–see Surface, lunate
Lung 161, 192–**195,** 196, 197, 204, 207, 208, 237, 278, 332
bronchopulmonary segments 196, 197
cross sections 237, 530–534, 541, 542
external features 192–195
in situ 194
intrapulmonary circulation (schema) 201
lobe
left superior 238
right superior 238
lymph vessels and nodes 204
topography 192, 193
Lunula
of fingernail 454
of semilunar cusp 219
Luschka–see Aperture, lateral, of 4th ventricle; Muscle, of levator ani, prerectal fibers of
Lymph follicle–see Lymph nodule
Lymph node–see also Lymph vessel
of abdominal cavity 258
aortic

Lymph node *cont.*
arch 204
lateral 253, 325, 382
apical axillary–see Lymph node, axillary, apical
appendicular 306
axillary 68, 177, 411, 542
anterior–see Lymph node, axillary, pectoral
apical 68, 177
brachial 177
central 177, 411
lateral–see Lymph node, axillary, brachial
pectoral 177, 411
posterior–see Lymph node, axillary, subscapular
subscapular 177
of bladder 329
brachial (lateral) axillary–see Lymph node, axillary, brachial
of breast 177
bronchopulmonary 195, 204, 226, 227
buccinator 68
of Calot–see Lymph node, cystic
cardiac (of stomach)–see Lymph node, gastric, left
carinal–see Lymph node, tracheobronchial
cecal 306
celiac 235, 258, 304, 305, 307
central axillary–see Lymph node, axillary, central
cervical 68, 69, 204, 235
Cloquet's–see Lymph node, inguinal, deep, highest
colic 306
cubital 466
cystic 307
deltopectoral 466
diaphragmatic 235
epicolic 306
epigastric
inferior 258
superficial 258, 387
of esophagus 235
facial 68'
gastric, left 235, 304, 307
gastroepiploic–see Lymph node, gastro-omental
gastro-omental 304
of genitalia 388
hepatic 300, 307
hilar–see Lymph node, bronchopulmonary
hypogastric–see Lymph node, iliac, internal
ileocolic 306
iliac
common 258, 306, 329, 386, 388
external 258, 306, 329, 386, 388, 528
internal 258, 306, 329, 386, 388
infracardiac 235
infrapyloric–see Lymph node, subpyloric
inguinal

Lymph node *cont.*
deep 258, 386–388, 5140
highest 258, 386–388
superficial 258, 306, 386–388, 528
intercalated 68, 69
intercostal 235, 258
internal thoracic–see Lymph node, parasternal
interpectoral 177
intestinal–see Lymph node, mesenteries, superior
intrapulmonary–see Lymph node, pulmonary
jugular
anterior–see Lymph node, cervical
external–see Lymph node, cervical
internal–see Lymph node, cervical
jugulodigastric 68, 69
juguloomohyoid 68, 69
of kidney 329
of large intestine 306
of limb
lower 528
upper 466
of liver–see Lymph node, hepatic
lumbar 258, 329, 386
of lung 204
mandibular 68
mastoid 68
mediastinal 235, 258, 530
mesenteric
inferior 258, 306, 307
superior 258, 304–307
of mouth 68, 69
nasolabial 68
of neck 68, 69
obturator 386
occipital 68
of oral region 68, 69
pancreatic 304, 307
pancreaticoduodenal 307
paracolic 306
parasternal 177
paratracheal 204, 235
paravesical 329
parotid 68
pectoral (anterior) axillary–see Lymph node, axillary, pectoral
of pelvis 386, 388
of perineum 386–388
of pharynx 68, 69
phrenic, inferior 177, 258
popliteal 528
preaortic 258, 306, 388
presacral–see Lymph node, sacral, middle
pretracheal 68, 70
promontorial 329, 386, 388
pulmonary 204

Lymph node *cont.*
pyloric 307
rectal 306
retrocardiac 235
retropharyngeal 69
retropyloric 304
of Rosenmüller–see Lymph node, inguinal, deep, highest
Rotter's–see Lymph node, interpectoral
sacral
lateral 258, 386, 388
middle 258, 329, 386, 388
scalene–see Lymph node, cervical
sigmoid 306
of small intestine 305
spinal accessory–see Lymph node, cervical
splenic 304, 307
sternocleidomastoid 68
of stomach 304
nodes around cardia 235, 304
subclavian–see Lymph node, axillary apical
subinguinal–see Lymph node, inguinal
submandibular 56, 68, 69
submental 68, 69
subparotid 68
subpyloric 304
subscapular (posterior) axillary–see Lymph node, axillary, subscapular
supraclavicular 68
suprahyoid 68
suprapyloric 304
thoracic, internal–see Lymph node, parasternal
thyroid 68
of tongue 69
tracheal–see Lymph node, paratracheal
tracheobronchial 204, 226, 227, 235, 258, 531, 532
transverse cervical 68
of urinary bladder 329, 388
vesical 329, 388
Lymph nodule
aggregate of small intestine 272
of appendix 275
of stomach 268
Lymph trunk
bronchomediastinal 204, 258
intestinal 258, 305
jugular 68, 204, 258
lumbar 258, 305, 329
subclavian 68, 204, 258
Lymph vessel–see also Lymph node; Lymph nodule
anal 306
of breast 177
of esophagus 235
of genitalia
female 386
male 388
of hand 466
of intestine
large 306
small 305
Lymph vessel *cont.*
of kidneys 329
of liver 283
of lower limbs 528
of lung 204
of mammary gland 177
of oral region 68
of pancreas 307
perianal 306
of pelvis
female 386
male 388
of perineum (female) 387
of pharynx
of posterior abdominal wall 258
prostatic 388
of stomach 304
testicular 388
of trachea 198
of upper limb 466
of urinary bladder 329
Lymphatic duct–see also Cisterna, chyli; Duct, thoracic; Trunk (lymphatic);
right 204, 305
Lymphoid nodule
aggregated
of vermiform appendix 275
of ileum (Peyer's patches) 272
solitary
of ileum 272
of stomach 268

M

Mackenrodt–see Ligament, cardinal
Macula lutea 83, 86, 114
Magenstrasse–see Canal, gastric
Mall–see Space, periportal (Mall)
Malleolus 495, 496, 498–503, 511–513
lateral 467, 508
medial 467, 508
Malleus 87–89, 91, 118
Malpighian–see Corpuscle, renal
Mandible 1, 2, 4, 12, **13,** 14, 23, 31, 49, 56, 59, 62, 64–see also Neck
angle 3
condyle 5
coronoid process–see Process
ramus 3
Manubrium–see also Handle
malleus–see Handle, of malleus
sternum 23, 24, 31, 59, 178, 179, 184, 194, 402, 530, 531
Margin–see also Border
acetabular 341, 468
of heart–see also Border, inferior; left; right; of heart
acute 208
obtuse 208
infraorbital 1
of pharyngeal constrictor muscles 61
Marshall's ligament–see Vein, oblique, of left atrium
Mass
lateral 15
C1 vertebra–see under Atlas (C1), anterior arch
inferior articular surface–see under Axis (C2) lateral mass
superior articular surface–see Condyle
Mater
arachnoid 94, 96, 103, 162, 163
dura 35, 91, 93–97, 103, 153, 154, 162, 163, 172
pia 94, 96, 154, 162, 163
Matter
gray 158, 162
white 158, 162
Maxilla 2, 4, 6, 8, 11, 12, 32–35, 44, 46, 48, 52, 77, 93
palatine process 5
McBurney–see Point, McBurney's
Measurement of pelvis 342
Meatus 339
acoustic
external 4, 8, 12, 87, 88, 91, 143
internal 6, 10, 87, 92, 117, 118
urethral, external–see Orifice, urethral, external
nasal
inferior 33, 44, 78
middle 33, 44, 46
superior 33, 46
Medial–see Radius
Mediastinum 226, 237
cross section of 237
lateral views 226, 227
testis 371
Medulla
of kidney 321, 325, 326, 536
oblongata 40, 43, 100, 109, 118, 128, 129, 142, 143, 160, 161, 223, 314, 331
spinal–see Cord, spinal
of suprarenal gland 333, 334
Meibomian–see Gland, tarsal
Meissner–see Plexus (nerve), myenteric
Membrane
atlantooccipital
anterior 17, 59, 61
posterior 17
basilar, of cochlea 91
costocoracoid 411
cricothyroid–see Ligament, cricothyroid, median
Descemet's–see Lamina, posterior limiting, of cornea
intercostal
external 173, 182, 183, 185, 187, 250
internal 173, 187, 226, 227, 250
interosseous, of
forearm 422, 424, 426, 432, 437, 438
leg 493, 494, 496, 500, 502, 504, 507
obturator 255, 340, 355, 469
perineal 335, 343, 346, 353, 355, 360–362, 364–366, 372, 375, 377, 383–385
pharyngobasilar–see Fascia,

Membrane *cont.*
pharyngobasilar
Reissner's–see Membrane, vestibular
suprapleural 226, 227
tectorial, of
atlantoaxial joint 18
cochlea 91
thyrohyoid 25, 59, 61, 63, 64, 70, 72, 73, 231
tympanic 87–89, 91
secondary 91
vestibular (Reissner's) 91
Meninges 94–96, 103, 162, 163
arteries 95
veins 94–96
Meniscus of knee 489–493
Mesentery 172, **261–266,** 270, 272, 300, 316, 337, 335, 349, 350
relation to intestines 262, 263
Meshwork, trabecular, of iridocorneal angle 84
Mesoappendix 273, 275, 312
Mesocolon
sigmoid 263, 276, 296, 319, 327, 372
transverse 261–265, 270, 276, 296, 300, 319, 335
Mesometrium (of broad ligament) 356
Mesosalpinx (of broad ligament) 354, 356
Mesovarium (of broad ligament) 354–356
Metacarpal–see Base, of metacarpal bones; Bone, metacarpal
Metatarsal–see Bone, metatarsal; Tuberosity if metatarsal bone
Midbrain 142, 143
Modiolus, *cochlear* 91
Monro–see Foramen, interventricular (Monro)
Mons pubis 359
Morgagni–see Appendix, vesicular; Column, anal; Lacuna, urethral
Mouth
floor of 49
glands of 57
inspection of 47
lymph nodes of 68, 69
muscles of 49, 56
nerves of 58, 67
roof of 48
veins of 66
Movement–see Action of
Mucosa
of colon 276
of duodenum 271, 287
of esophagus 231, 232
of ileum 272, 316
of intestine
large 276, 316
small 272, 316
of jejunum 272, 316
olfactory 39, 113
pharyngeal 60
of stomach 232, 268
of tongue 54
of trachea 198
Müller–see Muscle, tarsal, superior (Müller)
Müllerian duct–see Duct, paramesonephric (müllerian)
Muscle
abdominal oblique–see Muscle, oblique, external; internal
of abdominal wall 241–246, 255
abductor
digiti minimi (foot) 510, 511, 513, 515–518, 523
digiti minimi (hand) 444, 448, 453, 459
hallucis 510, 511, 513, 515–518, 523
pollicis brevis 444, 448, 449, 458
pollicis longus 424, 427, 428, 432, 450, 452, 453, 461
adductor
brevis 155, 475, 483, 487, 521
hallucis 510, 517, 519, 523
longus 155, 474, 475, 482, 483, 487, 521, 540
magnus 467, **475,** 477, 482–484, 487, 488, 493, 499, 521, 522
hamstrings (ischiocondylar) part of 521
minimus 475, 477, 484
pollicis 443–445, 448, 449, 459
anal sphincter–see Sphincter, anal
anconeus 415, 427, 428, 432, 460, 461
of arm 414, 415
articularis, genus 487, 489, 493, 520
aryepiglottic 74, 76
arytenoid
oblique 63, 74, 76, 231
transverse 59, 63, 74–76, 231
auricularis 22
of back 167–169, 171
deep 338
biceps
brachii 155, 174, 401, 406–409, 411, 413, **414,** 416, 418, 421, 429–431, 456, 457, 530–532
femoris 467, 476, **477,** 484, 485, 488, 489, 493, 496, 498–503, 522, 524
long head 467
short head 467
brachialis 155, 412, **414,** 416, 418, 429–431, 456, 457, 460
brachioradialis 401, **414**–416, 418, 427, 428, **429**–432, 456, 460, 461
buccinator 22, 42, 44, 48, 50, **51,** 56, 57, 61, 64, 65, 117
bulbocavernosus–see Muscle, bulbospongiosus
bulbospongiosus 335, 348, 353, 355, 360–362, **364,** 366, 376, 377, 384, 385, 397
ciliary 83, 84, 115, 126
circular
of duodenum 271
esophageal 61, 63–71, 230–232
intestinal 316
of rectum 346, 374, 375
of stomach 232
coccygeus–see Muscle, (ischio-)coccygeus
Muscle *cont.*
compressor–see under Compressor urethrae
constrictor
pharyngeal
inferior 23, 61, 63, **64,** 71, 72, 76, 120, 229–231
cricopharyngeal part–see Muscle, cricopharyngeus
middle 23, 55, 60, 61, **63,** 64, 71, 120, 231
superior 36, 48, 51, 55, 56, 60, **61,** 63–65, 71, 120, 231
glossopharyngeal part 55, 61
of pupil–see Muscle, sphincter, of pupil
coracobrachialis 409, 413, 414, 416, 418, 456, 457, 531, 532
corrugator
cutis ani 374, 375
supercilii 22, 32, 117
cremaster 242, 243, 251, 253, 370, 371
cricoarytenoid
lateral 74–76
posterior 63, 74–76, 231
cricopharyngeus 61, 63, 64, 71, 72, 76, 229–231
cricothyroid 25, 64, 70, 74–76, 120
deltoid 23, 24, 145, 155, 167, 170, 174, 182, 183, 186, 239, 339, 401, 406, **407,** 409, 411, 413–416, 418, 456, 460, 530, 532, 541
deltopectoral triangle 239
depressor
anguli oris 22, 50, 117
labii inferioris 22, 50, 117
septi nasi 22, 32, 117
detrusor–see Muscle, of urinary bladder, intrinsic
digastric
anterior belly 23–25, 27, 28, 30, 42, **49,** 57, 64
posterior belly 23–25, 28, 30, 36, 42, **49,** 55–57, 63, 64, 69, 117
dilator, of pupil 84, 115, 126
of duodenum–see Muscle, suspensory, of duodenum
epicranius–see Muscle, occipitofrontalis
erector spinae 167, **168,** 169, 172, 173, 185–187, 250, 320, 332, 336, 337, 530–539
of esophagus
circular 61, 63, 71, 230–232
longitudinal 61, 63, 71, 230–232
of expiration 191
extensor
carpi radialis brevis 155, 401, 415, **424,** 427–429, 432, 450, 452, 453, 460, 461
carpi radialis longus 155, 401, 415, 418, **424,** 427–429, 432, 450, 452, 453, 460, 461
carpi ulnaris 401, 415, **424,** 427, 428, 432, 452, 453, 460, 461

Muscle *cont.*
digiti minimi **424,** 427, 428, 432, 452, 453, 461
digitorum 415, **424,** 427, 432, 445, 447, 452–454, 460, 461
digitorum brevis 501–503, 511, **512,** 513, 518, 524
digitorum longus 476, 489, **501**–504, 511–513, 518, 524
hallucis brevis 501, 502, 512, 513, 518, 524
hallucis longus 155, 501–504, 511–513, 518, 524
indicis 424, 428, 432, 452, 453, 461
pollicis brevis **424,** 427, 428, 431, 432, 450, 452, 453, 461
pollicis longus **424,** 427, 428, 432, 445, 450, 452, 453, 461
extraocular 142
extrinsic
oblique
inferior 79, 80, 115
superior 79, 80, 82, 115
rectus
inferior 79, 80, 115
lateral 79, 80, 82, 83, 115
medial 79, 80, 82, 83, 115
superior 79, 80, 82, 115
intrinsic
ciliary 88, 84, 115, 126
dilator, of pupil 84, 115, 126
sphincter, of pupil 84, 115, 126
of eye 80, 115
of facial expression 22, 50, 117
fibularis (peroneus)
brevis 498–504, 507–513, 517, 518, 524
longus 467, 476, 488, 489, 498–503, 504, 507–513, 517, 518, 524
tertius 501, 503, 504, 509, 511–513, 518
flexor
carpi radialis 414, 416, **425,** 429–432, 437, 443–445, 456, 458
carpi ulnaris 401, 415, **425,** 427–432, 437, 443, 444, 448, 456, 459
digiti minimi brevis (hand) 445, 448, 459
digiti minimi brevis (foot) 510, 515–518, 523
digitorum brevis 510, 511, 515–517, 523
digitorum longus 498–500, 504, 511, 523
digitorum profundus 155, **426,** 431, 432, 437, 441, 443–447, 454, 456, 458, 459
digitorum superficialis 155, **426,** 429–432, 437, 441, 443–447, 454, 456, 458
hallucis brevis 504, 515–518, 523
hallucis longus 500, 504, 523
pollicis brevis 431, 444, 448, 449, 458, 459
pollicis longus **426,** 429–432, 437, 443–445, 456, 458
of floor of mouth 49
of foot 512–519

Muscle *cont.*
of forearm 423–431
frontalis–see also Muscle, occipitofrontalis, frontal belly
gastrocnemius 155, 467, 476, 477, 484, 488, 489, 493, **498**–504, 522, 523
lateral head 467
medial head 467
gemellus
inferior 477, 484, 485, 540
superior 477, 484, 485
genioglossus 55, 56, 59, 122
geniohyoid 25, 31, 49, 55, 59, 61, 122, 123
glossopharyngeus–see Muscle, constrictor, pharyngeal, superior, glossopharyngeal part
gluteus
maximus 145, 167, 170, 246, 320, 346, 356, 361, 364, 376, 377, 390, 391, 393, 467, 476, **477,** 484, 485, 487, 539, 540
medius 145, 167, 246, 320, 467, 474, 476, **477,** 478, 482–485, 539, 540
minimus 477, 478, 482–485, 539, 540
gracilis 474, 475, 477–482, 487–489, 498, 521
of hand 442–448, 453–see also individual muscles
of hip 476–478
hyoglossus 23, 25, 30, 49, 55, 56, 60, 61, 64, 122
hypothenar 442–445, 448, 459
iliacus 245, 255, 319, 351, 373, 474, **478,** 480, 481, 520, 538–540
iliococcygeus 343–346, 355, 376
iliocostalis 168, 341
iliopsoas 245, 251, 474, 475, **478,** 482, 483, 486, 487, 540
infrahyoid 25–see also individual muscles
infraspinatus 145, 167, 173, 186, 187, 406–411, 415, 460, 530–532
of inspiration 191
intercostal 530–537, 541, 542
external 169, 173, 182, 183, **185,** 187, 191, 194, 226, 227, 242, 247, 250
innermost 173, 184, 187, 247, 250
internal 119, 173, 183, 184, 187, 191, 194, 196, 226, 247, 250
interossei 155
interosseous
dorsal (of foot) 510, 512, 513, 518, 519, 523
dorsal (of hand) 428, 443, 445, 447, 448, 450, 453, 459
palmar 445, 447, 448, 459
plantar 510, 517–519, 523
interspinalis
cervicis 169
lumborum 169
intertransversarius, lateral 169
ischiocavernosus 347, 348, 353, 355, 360, 361, 364–366, 372, 376, 384, 385

Muscle *cont.*
(ischio-)coccygeus 255, 343–346, 378, 382, 390–392, 481
of larynx 74
latissimus dorsi 145, **167,** 170, 172–174, 182, 186, 241, 242, 246, 247, 249, 250, 320, 332, 336, 337, 407, 409, 411, 412, 414, 416, 418, 531–534
layer
inner circular 271
outer longitudinal 271
of leg 498–503
levator
anguli oris 22, 50, 117
ani 255, 276, 302, 314, 335, **343**–348, 353, 355, 360–362, 364–366, 372–378, 382, 384, 390, 391, 481, 540
prerectal fibers of 346
costorum 169, 185
labii superioris 22, 50, 62, 117
alaeque nasi 22, 50, 117
palpebrae superioris 77, 79, 80, 82, 115
scapulae 23, 28, 31, 167, 170, 183, 185, **186,** 407, 410, 460
veli palatini 43, 48, 51, 60, 61, 63, 64, 88, 89, 93, 120
longissimus 168, 341
capitis 168, 171
cervicis 168
thoracis 168
longitudinal
of duodenum 271
esophageal 61, 71
intestinal 320
pharyngeal 61, 231
of rectum 346, 373–375
of stomach 232
longus
capitis 23, 26, 43, 56
colli 26, 31, 228
lumbrical
(of foot) 510, 515–518, 523
(of hand) 443–448, 458, 459
of Luschka
masseter 21, 23, 24, 43, 50, 57, 56, 143
of mastication 50, 51
mentalis 22, 50, 117
of mouth 49–51
Müller's–see Muscle, tarsal, superior (Müller)
multifidus 169
mylohyoid 22–24, 27, 28, 30, 42, **49,** 55–57, 61, 64
nasalis 22, 32, 117
of neck 24–26
oblique
external 167, 168, 170, 172, 174, 175, 182–187, 191, 239, 241–247, 249–251, 253, 255, 320, 332, 336, 337, 339, 349, 350, 363, 364, 407, 476

Muscle *cont.*
inferior 79, 80, 115
internal 167, 168, 172, 182, 183, 185, 186, 191, 242–247, 249, 251, 255, 320, 332, 337, 349, 350
superior 79, 80, 82, 115
obliquus capitis
inferior 168, 169, 171
superior 168, 169, 171
obturator
externus 475, 483, 521
internus 245, 255, 343–346, 353, 355, 373, 378, 382, 391, 477, 481, 484, 485, 540
occipitalis–see Muscle, occipitofrontalis, occipital belly
occipitofrontalis
frontal belly 22, 32, 117
occipital belly 22, 117, 171
omohyoid
inferior belly 1, 23–**25,** 27, 28, 122, 123, 182, 183, 407, 410–412
superior belly 23–**25,** 27, 28, 31, 49, 122, 123, 182, 183, 194
opponens
digiti minimi 444, 448, 459
pollicis 444, 448, 449, 458
orbicularis
oculi 22, 77, 117
oris 22, 32, 50, 56, 117
palatoglossus 48, 54–56, 60, 120
palatopharyngeus 48, 54–56, 60, 61, 63, 120, 231, 249
palmaris
brevis 442, 459
longus 425, 431, 432, 437, 442–444, 458
papillary 237, 533
anterior 216, 217, 219–221, 237
conal–see Muscle, papillary, septal
medial 216, 219, 220
posterior 216, 217, 219–221, 237
septal 216, 219, 220
pectinate 216
pectineus 474, 475, 482, 483, 486, 487, 520, 540
pectoralis
major 23, 24, 27, 174, 175, **182,** 183, 187, 194, 237, 239, 241, 242, 339, 401, 407, 411, 412, 414, 416, 418, 530–533, 541
clavicular head 174
sternal head 174
minor **182,** 183, 194, 409, 411, 412, 414, 416, 530–532, 541
perineal–see also individual muscles of perineum
transverse
deep 335, 343, 347, 352, 355, 361, 366, 372, 384
superficial 343, 344, 360, 361, 364–366, 372, 376, 377, 384, 385
peroneus 467–see also Muscle, fibularis (peroneus)

Muscle *cont.*
pharyngeal constrictor–see Muscle, constrictor, pharyngeal
of pharynx 60, 61, 63, 64, 70, 231
piriformis 255, **343**–345, 382, 390–392, 477, 481, 484, 485
plantaris 476, 477, 484, 488, 493, 498, **499,** 500, 504, 522, 523
platysma 22, 24, 27, 31, 117
popliteus 477, 489–491, **493,** 499, 500, 504, 523
prevertebral 26
procerus 22, 32, 117
pronator
quadratus **423,** 431, 432, 444, 445, 448, 458
teres 414, 416, **423,** 428–432, 456, 458
psoas 338
major 172, 189, 245, 255–257, 259, 270, 319, 320, 328, 332, 337, 349–351, 380, 474, **478,** 480, 481, 520, 537–540
minor 255, 337, 349, 350, 478
pterygoid
external–see Muscle, pterygoid, lateral
internal–see Muscle, pterygoid, medial
lateral 36, 42, 43, 50, 51, 143
medial 21, 36, 42, 43, 48, 51, 56, 63, 67
pubococcygeus 343–346, 355, 376
puborectalis 335, 343–346, 372, 376, 378, 540
pyramidalis 242, 253
quadratus
femoris 475, 477, 483–485
lumborum 169, 172, **189,** 255–257, 259, 319, 320, 332, 337, 349, 350, 478, 480
plantae 516, 517, 520, 523
quadriceps femoris 474, 520–see also Muscle, rectus femoris; vastus intermedius; vastus lateralis; vastus medialis
rectococcygeus 255
rectourethralis 255, 346
of rectum 346, 373–375
rectus
abdominis 174, 182, 183, 187, 191, 239, **242**–245, 247, 249, 250, 251, 253, 335–400, 534–539
capitis
anterior 26, 43, 69
lateralis 26
posterior (major and minor) 168, 169, 171
of eye
inferior 79, 80, 115, 144
lateral 79, 80, 82, 83, 115, 143, 144
medial 79, 80, 82, 83, 115, 143, 144
superior 79, 80, 82, 115, 144
femoris 467, 474–476, 482, 483, 487, 520, 540
of respiration 191
rhomboid
major 167, 170, 173, 186, 187, 246, **407,** 460, 530–532

Muscle *cont.*
minor 167, 170, 186, 411, 464
risorius 22, 117
sacrospinalis–see Muscle, erector spinae
salpingopharyngeus 60, 61, 63, 93, 120
sartorius 243, 467, **474**–477, 482, 483, 487–489, 498, 501, 502, 520, 540
scalene
anterior 23–25, **26,** 28, 29, 31, 65–67, 70, 181, 183–185, 190, 191, 194, 202, 207, 226–228, 410, 412, 541, 542
middle (medius) 23–**26,** 28, 31, 65–67, 181, 183, 185, 191, 228, 542
posterior 23–**26,** 31, 183, 185, 191, 542
semimembranosus 476, **477,** 484, 487, 488, 490, 493, 498–500, 522
semispinalis
capitis 167–169, 171, 407
cervicis 171
thoracis 169
semitendinosus 467, 474, 475, **477,** 484, 485, 487–489, 498, 522
serratus
anterior 167, 173–175, 182, 183, **185**–187, 239, 241–243, 246, 247, 249, 250, 336, 339, 401, 407, 411, 412, 530–534, 541
posterior inferior 167, 168, 172, 185, 186, 246, 320
posterior superior 167, 168, 185
of shoulder 407–409–see also individual muscles
of soft palate 61
soleus 155, 477, 488, 498–504, 511, 513, 522, 523
sphincter
anal–see Sphincter, anal
ani externus 155
of pupil 84, 115, 126
urethrae 245, 343, 346, 348, 352, 353, 360–362, 366–368, 383, 384, 397
spinalis 168, 341
splenius
capitis 23, 167, 168, 171, 185, 186, 407
cervicis 167, 168, 171, 185
stapedius 88, 89
sternalis 182
sternocleidomastoid 1, **23,** 24, 27, 28, 30, 31, 56, 57, 69, 121, 123, 167, 171, 174, 182, 186, 191, 194, 239, 339, 407, 412
clavicular head 1, 174, 239
sternal head 1, 174, 239
sternohyoid 23–**25,** 27, 28, 31, 49, 122, 123, 182–184, 194
sternothyroid 23–**25,** 27, 28, 31, 122, 123, 182–184, 194
of stomach 232, 269
styloglossus 23, 36, 43, 55, 56, 61, 64, 122
stylohyoid 23–25, 28, 30, 36, 42, 43, 49, 55–57, 63, 64, 117
stylopharyngeus 55, 56, 60, 61, 63, 64, 119, 120, 231

Muscle *cont.*
subclavius 182, 183, 226, 227, 407, 411, 412, 541
subcostal 250
submucosae ani 374, 375
subscapularis 173, 185, 187, 406, 408, 409, 411, 414, 416, 530–532, 542
supinator 423, 428, 430–432, 456, 461
suprahyoid 25–see also individual muscles
supraspinatus 167, 170, 186, 406–408, 409–411, 415, 460, 542
suspensory, of duodenum 262, 269, 271, 287
tarsal, superior (Müller) 77
temporalis 42, 50, 143
tensor
fasciae latae 246, 467, 474, **476,** 482–485, 487, 540
tympani 42, 88, 89
veli palatini 42, 48, 51, 60, 61, 64, 93
teres
major 145, 167, 170, 173, 185, 186, 246, 407, 409–412, 414–416, 418, 460, 531, 532
minor 167, 170, 186, 406–408, 409–411, 415, 460, 530, 531
thenar 429, 442, 443, 448, 449, 458
of thigh 474–478
of thoracic wall 182–186, 191
thyroarytenoid 74–76
thyroepiglottic 74, 76
thyrohyoid 23–25, 27, 28, 49, 122, 123
tibialis
anterior 155, 467, 476, 488, 489, **501**–504, 509, **510**–513, 518, 524
posterior 498–**500,** 504, 509, **510,** 511, 516–518, 523
of tongue 54–56, 122
trachealis 198
transverse perineal–see Muscle, perineal, transverse
transversospinalis 185, 530–see also Muscle, longissimus; multifidus; semispinalis
transversus
abdominis 168, 169, 172, 183–185, 189, 191, **243**–247, 249–251, 253–255, 259, 319, 320, 336, 337, 349, 350, 478, 480, 538, 539
thoracis 173, 183, 184, 187, 188, 237, 247
trapezius 1, 23–25, 27, 31, 121, 123, 145, **167,** 170, 171, 173, 182, 183, 186, 187, 239, 246, 250, 339, 401, 407, 411, 412, 530–534, 542
triceps brachii 145, 149, 174, 401, 407, 409, 410, 412, **415,** 416, 418, 421, 427, 429, 460, 530–532
lateral head 145, 401
long head 145, 401
of urinary bladder, intrinsic 352–354, 362, 367, 368
of urogenital diaphragm 361, 367
uvular 48
vastus
Muscle *cont.*
intermedius **474,** 475, 483, 487, 489, 520
lateralis 467, 474–**476,** 482–484, 487–489, 501, 503, 520
medialis 467, **474,** 475, 482, 483, 487–489, 501, 520
vocalis 74–76
zygomaticus
major 22, 50, 117
minor 22, 50, 117
Muscle layer
of appendix 275
of colon 274
of duodenum 269, 271, 287
of esophagus 63, 71, 269
of ileum 272, 274
of jejunum 272
of large intestine 276
of stomach 269
Muscularis mucosae
of intestine 316
of rectum 374, 375
of stomach 268
Musculus
uvulae–see Muscle, uvular
Myometrium 356

N

Nares (nostrils), anterior 1
Naris, posterior–see Choana
Nasopharynx 33, 58, 59, 62, 87, 93, 98, 142
Navicular 505, 506, 508, 509, 518, 519
Navicular bone–see Navicular
Neck
arteries of 29, 30, 65
of bladder 348, 353, 362
bones of 12, 15, 16
cutaneous nerves of 27
fascial layers of 31
of femur 469, 471, 540
of fibula 495
of gallbladder 285
of hernia sac 254
of humerus 403, 404, 530
anatomical 405
surgical 405
ligaments of 17, 18
lymph nodes of 68, 69
of mandible 13, 43
muscles of 22–26
nerves of 20, 27, 28, 67, 123, 124
of pancreas 288
of radius 419, 420, 422
of rib 178, 179, 188, 533
of scapula 178, 403, 404
surgical–see Neck, of humerus
of tooth 53
veins of
superficial 27
deep 66
Nephron of kidney 325, 326
Nerve
of abdominal wall 249, 250, 259
abducent 79, 82, 98, 108, 111, 112, **115**
accessory 28, 30, 43, 67, 98, 108, 110–112, 120, **121,** 123, 170, 185, 186
external branch 121
internal branch 121
obturator 259, 479, 480
alveolar
inferior 36, 42, 49, 51, 56, 58, 67, 116, 125, 128, 751
superior 40, 41, 58, 67, 116
nasal branch 38
anal (rectal), inferior 314, 390, 391, 393, 394, 479, 485
anococcygeal 391, 393, 479, 481
antebrachial cutaneous–see Nerve, cutaneous, of forearm
anterior cutaneous branch of femoral–see Nerve, femoral, anterior cutaneous branch
anterior division of
mandibular 42
obturator–see Nerve, obturator, anterior branch
of arm 456, 457, 460–462
of arteries 224
articular–see articular branch under Nerve, auriculotemporal; fibular (peroneal); median; obturator; tibial; ulnar
auricular
anterior 116
great 20, 27, 28, 123, 170, 171
posterior 21, 42, 117
occipital branch 117
to auricular muscles 117
auriculotemporal 14, 20, 36, **42,** 51, 57, 67, 116, 119, 128
articular branch 116
parotid branch 116
autonomic 40, 110–112, 115–117, 119, 120, **124**–128, 159–161, **205,** 206, 223, 224, 236, **308**–318, 330, 331, 334, 389, 390, 392, 394–397
in abdomen 312
in head 125
in neck 124
in thorax 205
axillary 408, 409, 412, 413, 415, 457, 458, **460,** 464
of back 170
of bile ducts 160, 321
of blood vessels 224
brachial cutaneous–see Nerve, cutaneous, of arm
of bronchus 160, 206
buccal (of mandibular nerve) 20, 36, 42, 58, 67, 116
branch of facial–see Nerve, facial, buccal branch
branch of mandibular nerve–see Nerve,

Nerve *cont.*
buccal (of mandibular nerve)
calcaneal
lateral–see Nerve, sural, calcaneal branch (lateral)
medial–see Nerve, tibial, calcaneal branch (medial)
cardiac (sympathetic)
cervical 65, 124, 125, 159, 205, 222–224, 236
thoracic 124, 159, 190, 205, 222–224, 236
cardiac (vagal)
cervical 65, 67, 120, 124, 125, 159, 205, 222, 223, 236
thoracic 120, 124, 159, 190, 205, 222, 223, 236
caroticotympanic 117, 119
carotid
internal 40, 124, 125, 127, 159, 161, 224
sinus branch–see Nerve, glossopharyngeal, carotid branch
cavernous 390, 396
celiac–see Nerve, vagus, celiac branch
cervical
branch of facial–see Nerve, facial, cervical branch
transverse 20, 27, 28, 123
chorda tympani 42, 58, 67, 88, 89, 116–118, **125,** 127–129, 159
ciliary
long 41, 82, 115, 116, 125, 126
short 41, 82, 115, 116, 125, 126
of clitoris 259, 393, 394, 479, 485
cluneal
inferior 170, 391, 397, 484, 485, 522, 527
medial 170, 484, 527
superior 170, 246, 484, 527
coccygeal 153, 154, 481
to coccygeus muscle 259, 479, 481
cochlear 87, 90–92, **118**
communicating–see Artery, fibular (peroneal), communicating branch
cranial 110–122, 125–129–see also individual nerves
crural, medial cutaneous 524
cutaneous see also individual nerves
antebrachial–see under Nerve, cutaneous, of forearm
of anterior abdominal wall 249, 250
of arm 461, 462, 464
lateral
inferior 415, 460–462, 464
superior 170, 409, 415, 460–462, 464
medial 249, 412, 413, 416, 418, 456–458, 462, 464
posterior 415, 460, 461, 464
brachial–see under Nerve, cutaneous, of arm

Nerve *cont.*
branch–see under Nerve, femoral; iliohypogastric; intercostal; spinal; subcostal
dorsal
intermediate (superficial fibular) 524, 526
lateral (sural) 512, 513, 522–524, 526, 527
medial (superficial fibular) 524, 526
of face 20
femoral–see under Nerve, cutaneous, of thigh
of foot 523, 524, 526, 527
of forearm 457, 461, 463, 464
lateral 414, 418, 429–432, 452, 455–457, 462–464
medial 412, 413, 416, 418, 429, 432, 452, 455–458, 462–464
posterior 415, 418, 432, 451, 452, 455, 460–464
of hand 455, 458, 459, 462, 464
of head 20
of leg 520, 524, 526, 527
of lower limb 526, 527
of neck 20, 27
perforating 391, 393, 479, 481, 485, 527
of shoulder 462, 464
sural
lateral 498, 499, 522–524
median 498, 499, 522, 523
of thigh 520–522, 526, 527
lateral 249, 252, 259, 319, 389, 478–480, 482, 483, 487, 520, 521, 526, 527
posterior 153, 393, 479, 481, 484, 485, 487, 522, 527
pudendal branch 393, 485, 522
deep–see under Nerve, fibular (peroneal); petrosal; temporal–see also Deep branch under Nerve, plantar, lateral; radial; ulnar
dental branch–see under Nerve, maxillary
to descending colon 160
of diaphragm 190
digastric–see digastric branch under Nerve, facial
digital
dorsal (finger) 450–452, 454, 455, 461, 463, 464
dorsal (toe) 501, 502, 512, 513, 524, 526
palmar
common 442, 443, 445, 449, 455, 456, 458, 459
proper 442, 443, 449, 454–456, 458, 459, 463, 464
dorsal branch to dorsum of middle and distal phalanges 458, 459
proper (thumb) 443, 449

Nerve *cont.*
plantar
common 516, 523
proper 502, 512–517, 523
dorsal branch to dorsum of middle and distal phalanges 502, 512
to dilator of pupil 115, 160
dorsal
branch of–see under Nerve, radial; ulnar
of clitoris 259, 393, 394, 479, 490
of penis 259, 364, 366, 385, 389–391, 396, 479, 485
scapular–see Nerve, scapular, dorsal
of duodenum 308–311
of esophagus 236
ethmoidal
anterior 20, 38, 39, 41, 82, 115, 116
nasal branch 14, 32, 28, 39, 41, 116
posterior 41, 82, 115, 116
external branch–see under Nerve, accessory; laryngeal, superior
to eye muscles 79, 82, 112, 115, 126
facial **21,** 27, 30, 36, 40, 42, 43, 56, 57, 67, 87, 89, 92, 98, 108, 110–112, **117**–119, 125, 127–129, 159, 160
buccal branch 21, 117
cervical branch 21, 117
digastric branch (to posterior belly of digastric muscle) 21
marginal mandibular branch 21, 27, 117
stylohyoid branch 21
temporal branch 21, 117
zygomatic branch 21, 117
femoral 245, 252, 259, 351, 387, 389, 478–480, 482, 483, 487, **520,** 521, 528, 538–540
anterior cutaneous branch 259, 389, 520, 526, 527
branch–see under Nerve, genitofemoral
lateral, cutaneous–see Nerve, cutaneous, of thigh, lateral
posterior, cutaneous–see Nerve, cutaneous, of thigh, posterior
fibular (peroneal)
common 477, 479, 481, 484, 487–489, 498–503, 522–**524**
articular branch 522
deep 501, 502, 504, 512, 513, 524
dorsal digital branch 512
lateral and medial branch 502, 512, 522
superficial 501–504, 512, 513, 522, 524, 526
dorsal digital branch 512
of foot 512–517, 522, 523
of forearm 456, 458, 459, 461
frontal 41, 79, 82, 115, 116, 125
of gallbladder 160
ganglionic–see Nerve, maxillary, ganglionic branch to pterygopalatine ganglion
gastric branch–see Nerve, vagus, gastric branch

Nerve *cont.*
to geniohyoid muscle 28
genital–see Nerve, genitofemoral, genital branch
of genitalia 160, 389, 393, 395, 396
genitofemoral 249, 252, 259, 319, 327, 337, 389, 478–480, 521, 526
femoral branch **249,** 252, 259, 389, 479, 480, 526
genital branch 249, 251–254, **259,** 370, 389, 479, 480, 526
gingival–see Nerve, maxillary, gingival branch
glossopharyngeal 30, 43, 58, 60, 65, 67, 98, 108, 110–112, 117, **119,** 120, 124, 125, 127–129, 159–161, 206
branch to stylopharyngeus 119
carotid branch 119, 124, 125
lingual branch 58, 119
pharyngeal branch 119
tonsillar branch 58, 60, 67, 119
gluteal (inferior and superior) 153, 479, 481, 484, 485
of hair follicle 160
of hand 449–452, 454–456, 458, 459, 461, 463
of heart 160, 222, 223
hepatic–see Nerve, vagus, hepatic branch
of hip 485
hypogastric 159, 160, 308, 313, 314, 330, 331, **389,** 390, **392,** 394, 395–397
hypoglossal 28, 30, 42, 43, 55, 56, 66, 67, 98, 108, 111, 112, **122,** 123
meningeal branch 122
to iliacus muscle 479, 480
iliohypogastric 153, 170, 246, 249, 259, 319, 320, 337, 389, 394, 478–**480,** 521, 527
cutaneous branch 246, 249, 393
ilioinguinal 153, 249, 253, 259, 319, 320, 337, 389, 393, 394, 478–**480,** 521, 526
anterior labial branch of 259, 393
anterior scrotal branch of 249, 259, 389, 526
to inferior gemellus muscle 479, 481, 485
infraorbital 20, 32, 38, 40, 41, 67, 77, 79, 115, 116
nasal branch 38, 40, 41
infrapatellar–see Nerve, saphenous; infrapatellar branch
infratrochlear 20, 32, 41, 82, 116
intercostal 153, 159, 163, 173, 182–185, 187, 190, 205, 223, 224, 226, 227, 236, 249, **250,** 311, 331, 336, 413, 479–see also Nerve, spinal, thoracic
cutaneous branch 182–185, 187, 249, 250
intercostobrachial 183, 185, 249, 412, 456, 462, 464
intermediate 58, 98, 108, 117, 118, 129
intermesenteric–see Plexus (nerve), intermesenteric
internal branch–see under Nerve, accessory; laryngeal superior

Nerve *cont.*
internal carotid 40, 124, 125, 127, 159, 161, 224
interosseous
anterior (median) 431, 432, 458
of leg (tibial) 523
posterior (radial) 428, 432, 451, 461
intestinal–see Intestinal branch under Nerve, vagus
of intestine 320
large 120, 160, 161, 313, 314, 316
small 120, 160, 161, 312, 314, 316
ischiatic–see Nerve, sciatic
of Jacobson–see Nerve, tympanic
of kidney 160, 334, 336
labial–see under Nerve, genitofemoral, genital branch; ilioinguinal; perineal
lacrimal 20, 41, 79, 82, 115, 116, 125
palpebral branch 20
of lacrimal gland 160
laryngeal
inferior, right (anomalous) 76
recurrent 29, 31, 67, 70–72, 76, 120, 124, 159, 190, 202, 205, 207, 208, 222, 227, 228, 231, 236
superior 58, 61, 63, 67, 70–72, 76, 120, 124, 125, 129, 159, 206, 231, 236
external branch 67, 70, 72, 76, 120
internal branch 61, 67, 70, 72, 76, 120, 231
laryngopharyngeal branch of superior cervical ganglion–see under Ganglion, cervical sympathetic, superior
of larynx 70, 72, 76, 160
to lateral pterygoid muscle 42, 67
of leg 498–502, 520–524
to levator ani muscle 259, 479, 481
to levator scapulae muscle 28, 123
lingual 14, 36, 42, 47, 49, 51, 55–58, 67, 116, 117, 125, 127–129, 159
branch–see under Nerve, glossopharyngeal
of liver 160, 317
long thoracic 182, 183, 185, 249, 412, 413, 450
to longus capitis muscle 28, 123
to longus colli muscle 28, 123, 413
lumbar splanchnic 159, 160, 308, 313, 314, 330, 331, 334, 389, 390, 392, 394–397
of lung 160, 205, 206
mandibular 14, 20, 41, **42,** 58, 67, 82, 98, 112, 115, 116, 119, 125, 127–129
meningeal branch 42, 82
marginal mandibular branch–see under Nerve, facial
masseteric 36, 42, 50, 51, 67, 116
maxillary 20, 39–**41,** 42, 58, 67, 82, 98, 112, 115, 116, 125, 127–129
dental branch 41

Nerve *cont.*
ganglionic branch to pterygopalatine ganglion 41
gingival branch 41
mandibular branch 41, 82, 116
nasal branch 116
to medial pterygoid muscle 42, 67, 116
median 412–414, 416, 418, 429–432, 437, 442–444, 448, 449, 455–**458,** 463, 464
articular branch 458
motor branch to thenar muscle 438, 448, 456, 495
palmar branch 429, 430, 442, 443, 449, 450, 455, 458, 463,
meningeal branch–see under Nerve, hypoglossal; mandibular; maxillary; spinal; vagus–see Nerve, ophthalmic
mental 20, 42, 67, 116
motor
branch–see under Nerve, median, motor branch to thenar muscle
root of trigeminal–see Nerve, trigeminal, motor and sensory roots
of mouth 58, 67
musculocutaneous 412–414, 416, 418, 431, 455–**457,** 458
to mylohyoid 14, 36, 42, 49, 51, 56, 67, 116
nasal–see nasal branch under Nerve, alveolar, superior; ethmoidal, anterior; infraorbital; maxillary; palatine, greater; also under ganglion, pterygopalatine
of nasal cavity 38–40
nasociliary 41, 79, 82, 115, 116, 125, 126
nasopalatine 38–40, 116
of neck 24, 27, 28, 67, 123, 124
obturator 245, 259, 327, 380, 390, 479–481, 483, 487, 520, **521,** 526, 527, 538–540
accessory 259, 479, 480
anterior branch 483, 521
articular branch 521
posterior branch 483, 521
to obturator internus muscle 479, 481, 484, 485
occipital
branch–see under Nerve, auricular, posterior
greater 20, 123, 170, 171
lesser 20, 28, 123, 170, 171
third 20, 170, 171
oculomotor 79, 80, 82, 98, 108, 110–112, **115,** 125, 159, 160
olfactory 38, 39, 112, 113
to omohyoid muscle 28–see also Ansa cervicalis
ophthalmic 20, **41,** 42, 82, 98, 112, 115, 116, 125–129
meningeal branch–see Nerve, ophthalmic, tentorial (meningeal) branch
tentorial (meningeal) branch 41, 82, 116

Nerve *cont.*
optic 44, 79, 80, 82, 83, 86, 98, 101, 112, **114,** 126, 136, 137, 142, 144
of orbit 41, 82
palatine
descending 127
greater 38–41, 48, 58, 67, 116, 125,127
nasal branch 38, 39, 125, 127
lesser 38–41, 48, 58, 67, 116, 125, 127
palmar–see palmar branch under Nerve, median; ulnar
palpebral–see Nerve, lacrimal, palpebral branch
of pancreas 160, 321, 322
parasympathetic–see Fiber nerve, parasympathetic
parotid–see Nerve, auriculotemporal, parotid branch
of parotid gland 128
pectoral
lateral 182, 411–413
medial 182, 411–413
pelvic splanchnic–see Nerve, splanchnic, pelvic
of pelvic viscera 390, 392, 395, 396
of penis 259, 364, 366, 385, 389–391, 396, 479, 485
perforating cutaneous–see Nerve, cutaneous, perforating
pericardial–see Nerve, phrenic, pericardial branch
perineal
branch–see under Branch, perineal, sacral
posterior labial branch of 393, 479, 485
posterior scrotal branch of 390, 391, 479, 485
of perineum 391, 393, 395, 396
of peripheral blood vessels 160
peroneal–see Nerve, fibular (peroneal)
petrosal
deep 39, 40, 117, 119, **125,** 127
greater 39, 40, 58, 82, 89, 117–119, 125, 127, 129
lesser 42, 82, 116, 117, 119, 128
pharyngeal–see pharyngeal branch under Nerve, glossopharyngeal; vagus; also under ganglion, pterygopalatine
of pharynx 58, 67
phrenic
abdominal portion 189, 308, 310, 317, 334
cervical portion 26, 28, 29, 31, 65, 67, 70, 123, 124, 183, 185, 190, 194, 202, 207, 208, 222, 228
pericardial branch 190
thoracic portion 184, 188, 190, 207, 208, 211, 226, 227, 237, 247, 416, 530, 531
to piriformis muscle 479, 481
plantar
lateral 500, 514, 516, 517, 522, 523, 527
cutaneous branch 514
Nerve *cont.*
deep branch 516, 517, 523
superficial branch 516, 517, 523
digital branch (common and proper) 515–517
medial 500, 511, 514–517, 522, 523, 527
cutaneous branch 514
digital branch (common and proper) 515–517
posterior
division of
mandibular 42
obturator–see Nerve, obturator, posterior branch
presacral–see Plexus (nerve), hypogastric, superior
of prostate 160
to psoas muscle 479, 480
of pterygoid canal (Vidian) 38–41, 116, 117, 119, 125, 127, 129
to pterygoid muscle 42, 67, 116
pudendal 153, 259, 314, 330, 390–397, 479, 481, 484, 485, 540
block (anesthesia) of 393
perineal branch–see Branch, perineal
of pupil
dilator 115, 160
sphincter 115, 160
pyloric–see pyloric branch under Nerve, vagus, hepatic branch
to quadratus femoris muscle 479, 481, 485
quadratus plantae 523
radial 409, 412, 413, 415, 418, 427, 428, 430–432, 442, 450–452, 455–458, **460, 461,** 464
deep branch 428, 430–432, 456, 459
dorsal branch 432, 461
superficial branch 427, 430, 432, 442, 450–452, 455, 456, 461, 463, 464
rectal
inferior–see Nerve, anal (rectal), inferior
superior 314
to rectus capitis muscle 28, 123
of rectum 160
recurrent
branch–see also Nerve, spinal (recurrent) meningeal branch
laryngeal–see Nerve, laryngeal, recurrent
root–see Root
sacral splanchnic–see under Nerve, splanchnic
saphenous 482, 483, 487, 501, 502, 504, 520, 523, 526, 527
infrapatellar branch 482, 483, 520
medial cutaneous branch 520
to scalene muscle 28, 123, 413
scapular, dorsal 412, 413, 460
sciatic 153, 159, 477, 479, 481, 484, 485, 487, **522,** 540
Nerve *cont.*
muscular branch 484
scrotal–see Nerve, genitofemoral, genital branch; ilioinguinal, anterior scrotal branch; perineal posterior scrotal branch
to sebaceous gland 160
sensory
root of trigeminal–see Nerve, trigeminal, motor and sensory roots
of shoulder 460–462
of sigmoid colon 160
of small intestine 160, 312, 314, 316
to sphincter of pupil 115, 160
spinal
cervical 20, 28, 31, 67, 108, 121, 153, 154, 159, 170, 171, 173, 190, 223, 224
cutaneous branch 170, 171, 173, 246, 250
groove 16
intervertebral foramina 16
lumbar 152–154, 159, 163, 170, 172, 173, 223, 224, 246, 250, 390, 395, 397
(recurrent) meningeal branch 163, 250, 315
sacral 153, 154, 159, 170, 173, 394
perineal branch of 56, 483, 485
thoracic 126–128, 153, 154, 159, 162, 163, 170, **173,** 186, 187, 223, 224, 246, **250,** 315–see also Nerve, intercostal
spinosus–see Nerve, mandibular, meningeal branch
splanchnic
greater 159, 160, 188, 189, **205,** 224, 226, 227, 236, 237, 250, 255, 259, 308–315, 317, 318, 330, 334, 389, 390, 394–396
least 159, 160, 189, 205, 224, 255, 259, 308–315, 330, 331, 334, 336, 389, 390, 394–396
lesser 159, 160, 189, **205,** 224, 250, 255, 259, 308–315, 330, 331, 334, 336, 389, 390, 394–396
lumbar 159, 160, 308, 313, 314, 330, 331, 334, 389, 390, 392, 394–397
pelvic 159–161, 259, 308, 313, 330, 331, 390, 392, 394–397, 479, 481
sacral 159, 160, 313, 314, 330, 390, 392, 397, 481
thoracic–see Nerve, cardiac (sympathetic), thoracic; splanchnic, greater; least; lesser
to stapedius muscle 117
to sternohyoid muscle 28–see also Ansa cervicalis
to sternothyroid muscle 28–see also Ansa cervicalis
of stomach 160, 308–311
to stylohyoid muscle–see Nerve, facial, stylohyoid branch
to stylopharyngeus muscle–see Nerve, glossopharyngeal, branch to stylopharyngeus

Nerve *cont.*
to subclavius muscle 417
subcostal 153, 246, 249, 259, 319, 320, 389, 394, 479, 480, 526
cutaneous branch 246, 249, 259
sublingual 42
of sublingual gland 160
of submandibular gland 160
suboccipital 17, 171
subscapular
lower 409, 412, 413, 460
upper 412, 413
superficial branch–see under Nerve, plantar, lateral; radial; ulnar
to superior gemellus muscle 479, 481, 484, 485
supraclavicular 20, 27, 28, 123, 249, 462, 464
supraorbital 20, 32, 41, 77, 82, 116
of suprarenal gland 160, 334
suprascapular 409, 412, 413, 460
supratrochlear 20, 32, 41, 77, 82, 116
sural 522, 523, 527
calcaneal branch (lateral) 500
communicating branch 518
cutaneous branch
lateral 484, 498, 499, 504, 522–527
lateral dorsal 512, 513, 522–524, 526, 527
medial 484, 498, 499, 504, 522, 523, 527
of sweat gland 160
sympathetic–see Fiber, nerve, sympathetic
of teeth 41, 42
temporal
branch of facial–see Nerve, facial, temporal branch
deep 36, 42, 67, 116
to tensor tympani muscle 42, 116
to tensor veli palatini muscle 42, 67, 116
tentorial–see Nerve, ophthalmic, tentorial (meningeal) branch
of thigh 482–484, 520–522
thoracic, long 182, 183, 185, 249, 412, 413
of thoracic wall 187
thoracoabdominal 250
thoracodorsal 409, 412, 413
to thyrohyoid muscle 28, 30–see also Ansa cervicalis
of thyroid gland 70
tibial 477, 479, 481, 484, 487, 498–500, 504, 511, 516, 522, 523
articular branch 522
calcaneal branch (medial) 514–517, 522
of tongue 55, 58
tonsillar–see Nerve, glossopharyngeal, tonsillar branch
of trachea 160, 206
of tracheobronchial tree 206
transverse cervical–see Nerve, cervical, transverse
Nerve *cont.*
trigeminal 20, 41, 42, 58, 92, 108, 110–112, **116,** 125, 127–129, 137
motor and sensory roots 42, 125
trochlear 79, 82, 98, 108–112, **115**
tubal, of tympanic plexus 119
tympanic (Jacobson) 89, 117, 119, 128
ulnar 412, 413, 415, 416, 418, 427–432, 437, 443, 444, 448, 449, 451, 455–**459,** 464
articular branch 459
deep branch 430, 431, 437, 442, 443, 448, 449, 456, 459
dorsal branch 427, 429–431, 451, 452, 455, 459, 463
palmar branch 430, 442, 443, 449, 455, 463, 464
superficial branch 430, 442, 443, 453, 456, 459
of ureter 330, 331, 397
of urinary bladder 160, 330, 397
vagus 28–31, 43, 58, 65–67, 70–72, 76, 98, 108, 110–112, 119, **120,** 121, 124, 125, 129, 159–161, 190, 202, 205–208, 222, 223, 226–228, 236, 308–315, 331, 530, 531–see also Nerve, laryngeal
anterior vagal trunk 120, 228, 308–313
auricular branch 20, 120
cardiac branch
cervical 120, 124, 125, 205, 222, 223, 228
thoracic 120, 205, 222, 223, 228
celiac branch 120, 228, 312, 313
esophageal branch
gastric branch 120, 308–313
hepatic branch 120, 308, 309
pyloric branch 120, 309
intestinal branch 120
meningeal branch 120
pharyngeal branch 119, 120, 124, 159, 236
posterior vagal trunk 228, 308–313
pulmonary branch 206
vestibular 87, 90, 92, 118
vestibulocochlear 87, 90, 92, 98, 108, 110–112, **118,** 125
Vidian–see Nerve, of pterygoid canal (Vidian)
of wrist 455
zygomatic 41, 115, 116
branch of facial nerve–see under Nerve, facial, zygomatic branch
branch of maxillary nerve–see Nerve, zygomatic
zygomaticofacial branch 20, 41, 67, 116
zygomaticotemporal branch 20, 41, 67, 116
Nervi erigentes–see Nerve, splanchnic, pelvic
Nervous system–see System, nervous
Nervus
intermedius–see Nerve, intermediate
spinosus–see Nerve, mandibular, meningeal branch
Neurohypophysis 133, 140
infundibulum of–see Infundibulum, of neurohypophysis
Newborn (neonate)
circulation of–see Circulation, postnatal
cranium of 11
Nipple of breast 174, 175, 192, 339
Node
atrioventricular (AV) 221
lymph–see Lymph node
sinuatrial (SA) 212, 221
Nodule
Albini's–see Nodule, fibrous, of mitral valve
Arantii–see Nodule, of semilunar valve
of cerebellum 107, 137
fibrous, of mitral valve (Albini) 219
lymph–see Lymph nodule
of semilunar valve (Arantius) 219
Nodulus of cerebellum 109
Nose–see Nares
cartilage of 32
concha of 33–35
external 32
lateral wall of 33, 34
medial wall of 35
septum of 35
Nostrils–see Nares
Notch
acetabular 340, 468
angular, of stomach 267
cardiac, of
of left lung 192, 194, 195
of stomach 232, 267
cerebellar (anterior and posterior) 107
fibular, of tibia 495
inferior–see under Notch, vertebral
interarytenoid 62
intertragic 88
ischiatic–see Notch, sciatic
jugular 1, 24, 174, 178, 192
mandibular 4, 12, 13
mastoid 8
pancreatic 288
preoccipital 99
radial, of ulna 419, 422
scapular–see Notch, suprascapular
sciatic (greater and lesser) 240, 468
of stomach–see Notch, angular; cardiac; of stomach
superior–see under Notch, vertebral
supraorbital 1, 2, 4, 11
suprascapular 178, 403, 406, 408–410
suprasternal 192–see also Notch, jugular
of thyroid cartilage 73
trochlear, of ulna 419, 420, 422
of ulna–see Notch, radial; of ulna; trochlear, of ulna
ulnar, of radius 422
vertebral (inferior and superior) 147, 148
inferior, of L4 vertebra 149
superior, of L5 vertebra 149
Nucleus
abducent 110, 111, 115
accessory oculomotor–see Nucleus oculomotor, accessory
ambiguus 110, 111, 119–121
basal (basal ganglia) 104

Nucleus *cont.*
caudate 102, 104–106, 134, 138
cerebellar (dentate, emboliform, fastigial, globose) 107
cochlear (anterior and posterior) 110, 111, 118
of cranial nerve **110, 111,** 115–122
dentate, of cerebellum 107, 109
dorsal
cochlear 110, 111, 118
vagal–see Nucleus, posterior (dorsal), of vagus nerve
dorsomedial, of hypothalamus 140
Edinger-Westphal–see Nucleus, oculomotor accessory
emboliform, of cerebellum 107
facial 110, 111
fastigial, of cerebellum 107
geniculate, lateral 114
globose, of cerebellum 107
hypoglossal 110, 111, 122
hypothalamic (dorsomedial; mammillary; paraventricular; posterior; supraoptic; tuberal; ventromedial) 140
intermediolateral (IML) 126–128–see also Horn, lateral, of gray matter
intralaminar, of thalamus 105
of lens 84, 85
lentiform 102, 104, 134
mammillary, of hypothalamus 140
mesencephalic, of trigeminal nerve 110, 111, 116, 129
motor
of facial nerve 117
of trigeminal nerve 110, 111, 116, 129
oculomotor 115
accessory 110, 111, 115, 126
olfactory 113
paraventricular, of hypothalamus 140
pontine, of trigeminal nerve–see Nucleus, principal sensory, of trigeminal nerve
posterior (dorsal)
of hypothalamus 140
of vagus nerve 110, 111, 120, 223, 314, 331
principal sensory, of trigeminal nerve 110, 111, 116
pulposus 148, 156
red 101, 110, 111
reticular 105
ruber–see Nucleus, red
salivatory
inferior 110, 111, 119, 128
superior 40, 110, 111, 117, 127
sensory, principal, of trigeminal nerve 110, 111, 116
septal (pellucidum) 113
of solitary tract 110, 111, 117, 119, 120, 129, 223, 336
spinal
of accessory nerve 110, 111
of trigeminal nerve 110, 111, 116, 119, 120
Nucleus *cont.*
supraoptic, of hypothalamus 140
thalamic 105
trigeminal–see Nucleus, motor; sensory, principal; spinal; of trigeminal nerve
trochlear 110, 111, 115
tuberal, of hypothalamus 140
vagal, dorsal–see Nucleus, posterior (dorsal), of vagus nerve
of vagus nerve, posterior (dorsal)–see Nucleus, posterior (dorsal), of vagus nerve
ventromedial, of hypothalamus 140
vestibular 110, 111, 118
inferior, lateral, medial and superior 118

O

Oddi–see Sphincter, of hepatopancreatic ampulla
Olecranon of ulna 401, 415, 419, 420, 422, 424, 427, 428, 460
fossa 420
Omentum
greater 261, 264, 265, 267, 280, 335, 337
lesser 267, 280, 288, 309, 310, 335, 336, 537
right free margin 271
Opening–see also Hiatus
of alveolar duct 200
of auditory tube–see Opening, pharyngeal, of pharyngotympanic (auditory) tube
of Bartholin's gland 359
of bladder 352
of bulbourethral duct 367, 368
of coronary arteries 219, 220
of coronary sinus 216
of ejaculatory duct 367, 368, 399
of ethmoidal cells 33, 34, 46
of greater vestibular gland 359
ileocecal–see Orifice, ileal
internal acoustic 92
of maxillary sinus 33, 34, 44–46
of nasolacrimal duct 33, 34, 45, 78
of paraurethral duct 359, 362
of parotid duct 47
pharyngeal, of pharyngotympanic (auditory) tube 33, 59, 60, 62, 63, 119
of preputial gland 365
of prostatic duct 367, 368
of pylorus–see Orifice, pyloric
saphenous 241, 242, 248, 252, 360, 363, 526, 528
of Skene's ducts 359, 362
of sphenoidal sinus 33, 34, 45
of stomach
cardiac–see Orifice, cardiac, of stomach
pyloric–see Orifice, pyloric
of sublingual duct 47, 57
of submandibular duct 47, 57
of superior cerebral vein 95
of Tyson's glands 369
Opening *cont.*
of ureter–see Orifice, ureteric
of urethra–see Orifice, urethral, external
of urethral gland 366
of uterine tube 359
of uterus–see under Os
of vagina–see Orifice, vaginal
of vermiform appendix–see Orifice, of (vermiform) appendix
of vestibular canaliculus 90
Ora serrata 83, 85, 86
Orbit 2, 4, 11, 44, 46, 77–82
anterior adnexa of 77, 78
arteries of 81
fascia of 79
muscles of 80
nerves of 41, 82
veins of 81
Organ
reproductive
female, innervation of 395
male, innervation of 396
spiral, of Corti 91
Orifice–see also Opening
cardiac, of stomach 268
pyloric 271
of tricuspid valve 533
ureteric 353, 362, 367
urethral, external 339, 347, 348, 359, 362, 365, 368, 372, 398
vaginal 347, 359
of (vermiform) appendix 274
Origin of
arm muscles 403, 404
cremaster muscle 242
diaphragm 189
forearm muscles 433, 434
genioglossus muscle 49
hip muscles 472, 473
leg muscles 497
scalene muscles 26
serratus anterior muscle 179
shoulder muscles 179
subclavius muscle 179
thigh muscles 472, 473
Oropharynx 31, 47, 58–60, 62, 63
Os–see also Bone
of uterus (external, internal) 359
Ossicle, auditory 88
Ostium–see Opening
Ovary 351, 353, 358, 359, **362,** 384, 396, 399, 406
Ovum 362

P

Pain, referred, in
biliary disease 321
pancreatic disease 322
Palate 35, 44, 46
Palatine bone–see Bone, palatine
Palatine process–see under Maxilla

Palpebrae 77
levator superioris 144
Pancreas 102, 172, 264–266, 270, 271, 285, 287, **288,** 294, 318, 335, 343, 535–537–see Head
arteries of 291–294
cross sections of 265, 535–537
duct of 285, 287
histology of 288
in situ 288
innervation of (schema) 160, 322
intrinsic nerve supply 318
lymph vessels and nodes of 311
notch of 288
veins of 303
Papilla
circumvallate–see Papilla, vallate
duodenal
major 271, 285, 287
minor 271, 287
filiform 54
foliate 54, 129
fungiform 54, 129
gingival 53
incisive 48
lacrimal 77, 78
of parotid duct 47
renal 325
vallate 54, 129
of Vater–see Papilla, duodenal, major
Paradidymis 399
Parietal bone–see Bone, parietal
Paroöphoron 399
Pars
distalis, of adenohypophysis 140
flaccida, of tympanic membrane 88
infundibularis, of adenohypophysis 140
intermedia, of adenohypophysis 140
nervosa–see Part, optic (visual), of retina
plana, of ciliary body 85
tensa, of tympanic membrane 88
tuberalis, of adenohypophysis 140
Part
anular, of fibrous digital tendon sheath of fingers 438, 441, **442,** 445
atrioventricular, of membranous septum 217–221
basilar, of occipital bone 6, 8, 9, 17, 18, 26, 33–35, 48, 61–63
cardiac, of stomach 232
cavernous, of internal carotid nerve plexus–see under Plexus (nerve), of carotid artery, internal
central, of lateral ventricle 102
ciliary, of retina 83, 85
cricopharyngeal, of inferior pharyngeal constrictor–see Muscle, cricopharyngeus
cruciate, of fibrous digital tendon sheaths of fingers 438, 441, **442,** 445
of duodenum 262, 270, 335
ascending (4th) 271
descending (2nd) 271
Part *cont.*
horizontal (3rd) 271
superior (1st) 271
glossopharyngeal, of superior pharyngeal constrictor–see under Muscle, constrictor, pharyngeal, superior
hamstrings, of adductor magnus muscle 521
of hypothalamus 314
inferior 271
of inferior frontal gyrus 99
interarticular, of cervical vertebrae 15, 16
articular pillar 16
interchondral, of internal intercostal muscle 191
of interventricular septum 217–221, 237
ischiocondylar–see Part, hamstrings, of adductor magnus muscle
of lacrimal gland 78
of medial (collateral) ligament of ankle
tibiocalcaneal 509
tibionavicular 509
tibiotalar (anterior and posterior) 509
membranous, of interventricular septum 217–221, 237
muscular, of interventricular system 216, 217, 219–221
optic (visual), of retina 83
of temporal bone
petrous 6, 8, 92
squamous 4, 6
Passavant–see Ridge, Passavant's
Patella 467, 474–476, 483, 488, 489, 492, 493, 501, 503
Pathway
ascending, of spinal cord 158
autonomic reflex 319
descending, of spinal cord 126, 158
lymphatic
to anterior mediastinal nodes 177
to inferior phrenic nodes and liver 177
to opposite breast 177
of sound reception 87
taste 129
visual 114, 126, 126
Pecten
anal 374
pubis 240, 255, 340, 341, 345, 468
Pedicle of
axis 15, 16
vertebra 15, 147–149, 151, 152
Peduncle
cerebellar
inferior 107–109, 118, 137
middle 107–109, 137
superior 107–109, 137
cerebral 100, 101, 109, 132, 138
Pelvis
arteries of 378, 380–385
female 380, 382, 384
male 383
bony 240, 340–342, 468
diameters of 342
Pelvis *cont.*
diaphragm of 344–346
false 340, 349, 350
gender differences of 342
of kidney–see Pelvis, renal
ligaments of 340, 341
lymph vessels and nodes of 333, 386–388
female 386
male 388
measurements of 342
muscles of–see Diaphragm, pelvic
nerves of 390, 395, 396
female 392, 394
male 396
renal 321, 537
true 340
veins of 380, 382–385
viscera of
female 347, 349, 353–358
male 348, 350, 353, 367
Penis 363–365, 368, 370, 398–see Body; Glans; Vein; of penis
Pericardium 31, 188, 194, 202, 207, 208, 211, 226–229
Pericranium 96
Perineum 347, 348, 359–361, 363, 364, 366, 385, 387, 391, 393
(female)
arteries of 384
external genitalia (vulva) 359
deep dissection of 361
lymph vessels and nodes 386, 387
nerves of 393
superficial dissection of 360
urethra 362
veins of 384
(male)
arteries of 381, 385
external genitalia 363
deep dissection of 366
lymph vessels and nodes 388
nerves of 389, 391
scrotum and contents 370
superficial dissection of 364, 365
testis, epididymis 371
urethra 368
veins of 381, 385
Periodontium 53
Periorbita 79
Peritoneum 172, 232, 243–245, 253, 254, 276, 312, 319, 332, 333, 347–350, 352, 353, 355, 360, 372, 373, 377, 380, 392–see also Cavity, peritoneal
parietal 252, 263, 265, 266, 335–337, 350
of posterior aspect of anterior abdominal wall 266
visceral 265, 272, 275, 316
Pes
anserinus 474, 488, 489
hippocampi 105, 106
Petit–see Triangle, lumbar
Peyer's–see Lymph nodule, aggregate of small intestine

Phalanges 433, 434, 439, 441, 447, 454, 505, 506, 510, 519
Phalanx–see under Base; Bone
Pharynx/pharyngeal region 31, 33, 47, 58–60, 62, 63, 87, 93, 98
arteries of 65
lymph vessels and nodes of 68, 69
mucosa of 62
muscles of 60, 61, **63, 64,** 70
nerves of 58, 67
veins of 66
Philtrum 1, 47
Pia mater 94, 96, 102, 162, 163
PIP–see Joint
Pisiform 429–431, 435–444, 448, 449
Pit, anal 398
Plane
of abdomen 260
interspinous 260
intertubercular 260
lateral rectus 260, 278
midclavicular 260
midinguinal–see Plane, lateral rectus
semilunar–see Plane, lateral rectus
subcostal 260
transpyloric 260, 278
Plate–see also Lamina; Surface
cribriform, of ethmoid bone 6, 9, 10, 34, 35, 39, 113
horizontal, of palatine bone 6, 8, 34, 35, 93
lateral pterygoid of sphenoid bone 4, 6, 8, 11, 12, 34, 35, 51, 64, 93
levator 347, 348
limiting, of portal space 283, 284
medial pterygoid of sphenoid bone 6, 8, 34, 35, 43, 46, 48, 51, 60, 61
orbital, of ethmoid bone 2, 4, 11
palmar digital 445, 451, 454
perpendicular, of
ethmoid bone 2, 6, 35
palatine bone 6, 34, 35
plantar digital 510, 518
quadrigeminal–see Plate, tectal
tectal 100, 109
Pleura
cervical 192, 193
costal 188, 192–194, 202, 207, 226–228, 245, 278, 324, 336
cupula 192, 193
diaphragmatic 188, 190, 194, 202, 207, 226–228, 245, 278, 336
dome 192, 193
mediastinal 188, 190, 194, 202, 207, 208, 211, 226–228, 237
parietal–see Pleura, cervical; costal; diaphragmatic; mediastinal
pericardial–see Pleura, mediastinal
visceral 201
Plexus (arterial)
malleolar 502
patellar 482, 483, 494
pial 164, 165
Plexus (capillary), of kidney 326
Plexus (choroid) of
lateral ventricle 94, 102, 104–106, 132, 136, 138
3rd ventricle 100, 102, 103, 136
4th ventricle 103, 108, 109
Plexus (lymph), subpleural 204
Plexus (nerve)
alveolar, superior–see Plexus nerve, dental, superior
aortic 159, 205, 259, 308, 311, 330, 390, 392–397–see also Plexus (nerve), intermesenteric
of appendicular artery 304. 313
Auerbach's–see Plexus (nerve), myenteric
autonomic, intrinsic, of intestines (schema) 316
brachial 1, 23, 26–28, 67, 153, 176, 181, 183, 185, 190, 194, 202, 207, 224, 226–228, 411–**413,** 416
cardiac 120, 159, 160, 205, 222, 223, 236
of carotid artery
common 124, 125
external 124, 125, 127
cavernous part 115
internal 82, 115, 117, 119, 125, 126, 159
cavernous–see under Plexus (nerve), of carotid artery, internal
of cecal arteries 317
celiac 120, 159, 236, **308–311,** 312, 313, 330, 331, 334, 390, 395
cervical 20, **28,** 122, 123, 153–see also Ansa cervicalis
coccygeal 479, 481
of colic arteries
left 312–314
middle 312, 313
right 312, 313
dental
inferior 116
superior 41
of ductus deferens 389, 390, 396
enteric 315, 316
esophageal 120, 159, 202, 205, 226–228, 236, 237, 311
of facial artery 125
of gastric arteries
left 308–313, 390
right 309–312
of gastroduodenal artery 310, 312, 317
of gastro-omental artery 309, 310
of hepatic artery 120, 308–310, 312, 317, 336
hypogastric
inferior 159, 160, 300, 313, 314, 330, 331, 389, 390, 392, 394–397
superior 159, 160, 308, 313, 314, 330, 331, 349, 350, 389, 390, 392, 394–397
of ileocolic artery 312, 313
of iliac arteries
common 308, 392
external 308, 392
internal 305, 308, 392
Plexus (nerve) *cont.*
intermesenteric 159, 160, 259, 308, 312–314, 330, 331, 337, 389, 390, 392, 394–397
intrinsic, of intestines (schema) 316
jejunal 309
lumbar 153, 224, 259, 337, **478, 479,** 480, 520, 521, 538
lumbosacral 479
of marginal artery 313
of maxillary artery 125
Meissner's–see Plexus (nerve), submucous
mesenteric
inferior 159, 308, 313, 314, 390
superior 159, 308–310, **312,** 314, 318, 390
of middle meningeal artery 125
myenteric (Auerbach's) 316
ovarian 308, 330, 392, 395
of pancreaticoduodenal arteries
anterior inferior 309, 310
anterior superior 309, 310
inferior 309, 312, 313
posterior inferior 310
posterior superior 310
parotid, of facial nerve 21
patellar 526
pelvic 159, 308, 313, 314, 328, 331, 389, 390, 392, 394–397
periglandular 316
perivascular 315–see also name of specific artery under Plexus (nerve)
pharyngeal 58, 67, 119, 120, 124, 125
phrenic, inferior 308–310, 312, 313, 334, 390
prostatic 159, 330, 390, 396, 397
pulmonary 120, 159, 160, 205, 206, 236
pyloric 309
rectal 159, 313, 314, 330, 390, 392
of rectal arteries
middle 313
superior 308, 313, 390
of rectosigmoid artery 313
renal 308, 313, 330, 331, 334, 390, 397
sacral 153, 224, 259, 308, 313, 330, 331, 390, 395–397, **479, 481**
of sigmoid arteries 313
of splenic artery 308–310
submucous (Meissner's) 316
subserous 316
suprarenal 308, 313
testicular 308, 330, 389, 396
tympanic 89, 117, 119, 126, 128
ureteric 308, 330, 390
uterine 392, 394, 395
uterovaginal 392, 394, 395
vaginal 392, 394, 395
of vertebral artery 124
vesical 159, 313, 330, 390, 392, 394, 396, 397
Plexus (venous)
anal 373
areolar 248

Plexus (venous) *cont.*
basilar 97, 98
epidural–see Plexus (venous), vertebral, internal
esophageal 234
pampiniform 248, 370, 381, 383
paravesical 353
pial 166
prevesical 352, 383
prostatic 383
pterygoid 66, 81
pudendal 257
rectal
external 305, 374, 375, 379
internal 374, 375, 379
perimuscular 257, 305, 379
retropubic 352, 383
submucous 234
urethral 362
vertebral
external 166
internal (epidural) 163, 166
vesical 348
vesicourethral 257
Plica–see also Fold
semilunaris, of conjunctiva 77, 78
Point
anthropometry 2, 4, 7
central, of perineum–see Body, perineal
McBurney's 275
Poirier–see Space, of Poirier
Pole of cerebrum 99, 101
frontal 142
of kidney 321, 535, 536
occipital 142
Pons 100, 108, 109, 128, 129, 142, 143
Pore
interalveolar (Kohn) 200
Porta hepatis 279, 282
Position of
appendix 275
stomach 267
uterus 358
Postnatal circulation 225
Pouch
of Douglas–see Pouch, rectouterine
Rathke's 46
rectouterine 347, 349, 351, 354, 356, 372
superficial perineal–see Space, perineal (superficial)
vesicouterine 351, 355, 356, 376
Poupart–see Ligament, inguinal (Poupart's)
Precuneus 100
Prenatal circulation 225
Prepuce of
clitoris 360, 398
penis 348, 398
Pre-Rolandic–see Artery, sulcal, precentral
Process
accessory, of lumbar vertebra 148
alveolar, of maxilla 2, 4, 6, 12, 34, 44
Process *cont.*
articular, of
articular pillar 16
inferior, of L1 vertebra 149
sacrum, superior 150
vertebra
inferior 15, 16, 147, 148, 151, 152
superior 147, 148, 151, 152
caudate, of liver 279, 281
ciliary 83, 84, 85
clinoid
anterior 6, 9, 144
posterior 9
condylar, of mandible 4, 12, 13
coracoid, of scapula 178, 182, 183, 209, 403–406, 408–412, 414, 416
coronoid, of
mandible 4, 5, 12, 13, 43
ulna 419, 420, 422, 426
ethmoidal, of inferior nasal concha 34
frontal, of
maxilla 2, 4, 32, 34, 77
zygomatic bone 2
inferior articular 15, 16
infundibular, of neurohypophysis 140
jugular, of occipital bone 26
lenticular, of incus 89
of malleus anterior 89
mammillary, of lumbar vertebra 148
mastoid, of temporal bone 4, 8, 12, 21, 23–26, 30, 49, 55, 93, 169
muscular, of arytenoid cartilage 73, 74
odontoid–see Dens, of axis
orbital, of palatine bone 2, 34
palatine, of maxilla 6, 8, 33–35, 48, 93
papillary, of liver 279
pterygoid, of sphenoid bone 4, 6, 8, 11, 12, 34, 35
pyramidal, of palatine bone 8, 11, 12
sphenoid, of palatine bone 34
spinous, of 15, 16
axis 169
sphenoid bone–see Spine, of sphenoid bone
vertebra 15–17, 147, 148, 151, 152, 167, 169, 170, 172, 185, 193, 238
C7 vertebra 16, 145
L3 vertebra 149
L4 vertebra 149
T12 vertebra 145
styloid, of 43
radius 426, 439, 440
temporal bone 4, 8, 11, 12, 14, 23, 25, 26, 30, 49, 55, 63, 64
ulna 422, 435, 440
of talus, posterior 508–510
temporal, of zygomatic bone 2, 4
transverse of 15, 16
atlas 15, 26, 169
Process *cont.*
axis 15, 26
cervical vertebra 15, 16, 26, 130
coccyx 150
lumbar vertebrae 148, 149, 151, 152, 172, 189, 240
thoracic vertebrae 147, 180
uncinate, of
cervical vertebrae 16
ethmoid bone 33, 34, 45, 46
pancreas 288, 537
vocal, of arytenoid cartilage 73, 74
xiphoid 178, 179, 182, 184, 192, 194, 240, 241, 534
of sternum 174, 239
zygomatic, of
maxilla 2, 8
temporal bone 4, 8, 11
Prominence
of facial canal 89
laryngeal 73
of lateral semicircular canal 87, 89
Promontory
sacral 150, 240, 340–343, 347, 349, 350, 354, 392, 539
of tympanic cavity 87–89
Prostate 161, 245, 335, 346, 353, 366, **367**, 368, 372, 391, 399, 400, 540
Protuberance
mental 1, 2, 13
occipital
external 4, 6, 8, 145, 186
internal 9
Pterion 4
Pubis–see Ramus, pubic
Pulley–see Part, anular; cruciate; of fibrous digital tendon sheaths of fingers
Pulp, dental 53
Pulposus–see also Nucleus, pulposus
herniated lumbar nucleus, clinical features 156
Pulvinar 101, 104, 105, 108, 109, 132, 136–138
Puncta, lacrimal 77, 78
Pupil 77
Purkinje–see Branch, subendocardial, of conductin system of heart
Putamen 102, 104
Pylorus 267–271, 307, 309, 535
Pyramid of
cerebellum 107, 109, 137
kidney 321, 325, 326
medulla 108

Q

Quadrants of abdomen 260
Quadriceps 155

R

Radiograph of
appendix 275
ileum 272
jejunum 272
Radius 419–**422,** 423–426, 428, 431–438, 440, 444, 448, 453–see also Head; Neck; of radius
medial of 420
Ramus
communicans
gray 28, 124, 126–128, 159–163, 173, 187, 205, 223, **224,** 226, 227, 236, 250, 259, 308, 311, **314,** 315, 330, 331, 390, 392, 394–397, 479–481
white 126–128, 159–**161,** 162, 163, 173, 187, 205, 223, **224,** 226, 227, 236, 250, 259, 308, 311, **314,** 315, 331, 390, 392, 394–397, 479, 480
ischiopubic 346, 348, 360, 361, 363–367
of ischium 468
of lateral sulcus 99
of mandible 2, 4, 12, 13, 21, 23, 56
pubic
inferior 240, 340, 341, 344, 347, 353, 355, 468
superior 240, 251, 340, 341, 345, 347, 348, 365, 366, 468–470, 475, 478, 481
of spinal nerve
dorsal 20, 162, 163, 171, 173, 187, 250
ventral 162, 163, 173, 187, 250, 331–see also Nerve, intercostal; Plexus (nerve), brachial; cervical; lumbar; sacral
Raphe–see also Ligament
iliococcygeal 343, 344
median, of
levator ani muscle 343, 344
mylohyoid muscle 49
of palate 48
penoscrotal 398
perineal 359, 398
pharyngeal 63, 71, 230
pterygomandibular 12, 36, 48, 51, 56, 60, 61, 64
urethral 398
Rathke–see Pouch, Rathke's
Ray, medullary, of kidney 325
Recess–see also Fossa; Pouch; Space
anterior, of ischioanal fossa–see Fossa, ischioanal, anterior recess of
cochlear, of vestibule 90
costodiaphragmatic 188, 192, 193, 202, 226, 227, 320, 332, 336, 534, 541, 542
costomediastinal 188
duodenal 262
elliptical, of vestibule 90
epitympanic 87–89
ileocecal 273
ileocolic–see Recess, ileocecal
infundibular, of 3rd ventricle 102
intersigmoid 263, 327
Recess *cont.*
lateral, of 4th ventricle 102, 109
of lesser sac–see Recess, of omental bursa
of maxillary sinus 44
mesentericoparietal 262
of omental bursa (superior) 264, 266, 279, 335
optic, of 3rd ventricle–see Recess, supraoptic, of 3rd ventricle
paraduodenal 262
pharyngeal 33, 43, 60, 62
pineal, of 3rd ventricle 102
piriform–see Fossa, piriform
retrocecal 259, 269
sphenoethmoidal 33, 34
spherical, of vestibule 90
subpopliteal 489, 490
supraoptic, of 3rd ventricle 100, 102
suprapineal, of 3rd ventricle 102
of 3rd ventricle 100, 102
of 4th ventricle, lateral 102, 109
vesicouterine–see Pouch, vesicouterine
of vestibule 90
Rectum/anal canal 160, 255, 263, 266, 276, 319, 335, 343, 344, 346–352, 360, 367, **372–377,** 378–380, 392, 400
arteries 378
external sphincter (female and male) 376
in situ (female and male) 372
veins of 379
Reflex
autonomic 315
cough 206
Hering-Breuer 206
sneeze 206
Region
of abdomen 260
epigastric 260
femoral 252
flank 260
groin 260
hypochondriac 260
hypogastric–see Region, pubic
iliac–see Region, groin
iliocecal 273, 274
inguinal 251–253–see also Region, groin
lateral, of abdomen–see Region, flank
lumbar, of back 260
oral/pharyngeal
arteries of 65
lymph vessels and nodes of 68, 69
muscles of 63, 64
nerves of 67
veins of 66
pubic 260
umbilical 260
Reil–see Insula
Reissner–see Membrane vestibular (Reissner's)
Relations of spinal nerve roots to vertebrae 154
Respiration 191
Rete–see Plexus
Rete testis 371
Retina 83, 84, 86, 114
Retinaculum
extensor
inferior 501, 503, 511, 512, 524
superior 501, 503, 511, 512
of wrist 427, 428, 450–453
fibular
inferior 500, 503, 507, 509, 511
superior 498–500, 503, 509, 511
flexor, of
ankle 498–500, 511, 516, 517, 523
wrist–see Ligament, carpal, transverse
patellar
lateral 474–476, 488–490, 501–503
medial 474, 475, 483, 488–490, 501, 502
peroneal–see Retinaculum, fibular
Retrocession of uterus 358
Retroversion of uterus 358
Retzius–see Space, of retropubic
Rib 178, 179, 181, 188, 192, 193, 238, 240, 338, 530–537, 541, 542
cervical 181
Ridge–see also Crest; Fold
Passavant's 61
transverse, of sacrum 150
Ring
common tendinous 79, 80, 82, 115
femoral 245, 251, 252, 349–351, 528
fibrous, of heart 218
inguinal
deep 243, 245, 251, 254, 349–351, 354, 369
superficial 241, 251, 253, 254, 360, 364, 369, 370
Riolan–see Arc of Riolan
Rod of retina 114
Rolandic artery–see Artery, sulcal, central
Roof of mouth 48
Root
of accessory nerve
cranial 120, 121
spinal 121
of ansa cervicalis
cervical–see Root, of ansa cervicalis, inferior
hypoglossal–see Root, of ansa cervicalis, superior
inferior 28, 30, 67, 70, 122, 123
superior 28, 30, 67, 70, 122, 123
of brachial plexus 413
of ciliary ganglion
nasociliary–see Root, of ciliary ganglion, sensory
oculomotor–see Root, of ciliary ganglion, parasympathetic
parasympathetic 82, 115
sensory 82, 115, 116, 125, 126
sympathetic 82, 115, 125, 126
of lung 190, 208
of mesentery 262, 266, 270, 288, 300, 327
of pterygopalatine ganglion–see Nerve, maxillary, ganglionic branch to pterygopalatine ganglion
of spinal nerve 156

Root *cont.*
arteries of 164, 165
compression 156
dorsal 108, 127, 128, 154, 162, 163, 173, 250, 315, 397
relation of, to meninges 162, 163
relation of, to vertebrae 154, 163
veins of 166
ventral 108, 127, 128, 154, 162, 163, 173, 187, 250, 311, 315, 397
of tongue 54, 59, 62, 231
of tooth 53
of trigeminal nerve
motor 42, 125
sensory 42, 125
Rosenmüller–see Lymph node, inguinal, deep, highest
Rosenthal–see Vein, of basal
Rostrum of corpus callosum 100, 134, 138
Rotter–see Lymph node, interpectoral
Ruga–see also Fold
gastric 232, 268, 534
vaginal 355

S

Sac–see Neck
alveolar 200
endolymphatic 91
hernial 254
lacrimal 77, 78
lesser peritoneal–see Bursa, omental
scrotal 373
thecal 400
Saccule of internal ear 87, 90, 91, 118
Sacrum 145, 146, 149, **150,** 152, 154, 240, 340, 344, 345, 400
Santorini–see Duct, pancreatic, accessory
Scala
tympani of cochlea 87, 90, 91
vestibuli of cochlea 87, 90, 91
Scapha of external ear 88
Scaphoid 435–439, 440, 450
Scapula 25, 29, 173, 178, 185, 187, **403, 404,** 411, 530–533, 542–see also Spine
inferior angle 145
(lateral border) 405
medial border 145
Scarpa–see Tissue, subcutaneous, membranous layer, of abdomen (Scarpa's)
Schlemm–see Sinus, venous, scleral
Schwalbe–see Line, Schwalbe's
Sclera 77, 79, 83–86
Scrotum 339, 348, 369–371, 376, 385, 398
Segment
bronchopulmonary 196, 197
of kidney–see Segment, renal
of liver 281
of lung–see Segment, bronchopulmonary
renal 327
Segmentation, dermal–see Dermatomes
Sella turcica 6, 9, 33, 35, 59
Septum
atrioventricular 218, 221, 237
Denonvilliers'–see Fascia, rectovesical/rectoprostatic
interalveolar 13
interatrial 216, 533
intercavernous, of Buck's fascia 364
interlobular, of pancreas 288
intermuscular
anterior, of leg 504
lateral
of arm 414, 415, 418, 428, 431, 460
of thigh 487
medial
of arm 414–416, 418, 428–431
of thigh 487
posterior, of leg 504
transverse, of leg 504
interventricular 216–221, 533
of lung 201
nasal 33, **35,** 38, 39, 44, 46, 59, 62, 143, 144
orbital 77
pellucidum 100, 102, 104–106, 134, 136, 138, 140
of penis 368
rectovesical–see Fascia, rectovesical/rectoprostatic
of scrotum 348, 370, 371, 376, 385
transverse fibrous, of ischioanal fossa 373–376
Serosa 316–see also Peritoneum, visceral
of appendix 275
of small intestine 272
Sesamoid–see Bone, sesamoid
Shaft
of clitoris–see Body, of clitoris
of femur 471, 478
of humerus 530–532
of penis–see Body, of penis
Sheath
bulbar–see Sheath, fascial, of eyeball
carotid 24, 31, 56
fascial, of eyeball 79, 83
femoral 242, 243, 245, 252, 482, 528
flexor–see also Sheath, tendon, fibrous digital; synovial
common (ulnar bursa) 443–446
of optic nerve 79, 83
rectus 183, 241–244, 251, 335–337
anterior layer of 182, 249, 348, 360, 407
posterior layer of 247, 249
tendon
of ankle 511
fibrous digital
of foot 515, 516
of hand 441, 443–446, 449, 454
anular and cruciform parts of 443, 445, 446
synovial
(extensor) of wrist/dorsum of hand 453
of flexor carpi radialis 444
(flexor) of fingers 441, 443, 445, 446, 449, 454
Sheath *cont.*
of flexor pollicis longus (radial bursa) 443–445
of foot 504, 516,
of thyroid gland–see Capsule, fibrous of thyroid gland
Shoulder
arteries of 29, 410
bones of 402–404
cross sections of 406, 530–532
fasciae of 411
joints of 402, 406
lymph vessels and nodes of 466
muscles of 407–409
nerves of 460
Sibson–see Membrane, subpleural
Sinus–see also Recess
anal 374
aortic 219, 220
carotid 119, 124, 125, 130, 206
cavernous 81, 98, 130, 133
confluence of 97, 98, 137, 138, 143
coronary 210–212, 217, 219, 237, 533, 541, 542
dural 97, 98, 137, 138
of epididymis 371
ethmoid 3, 143, 144–see Cell, ethmoidal
frontal 3, 5, 6, 33–35, 44–46, 59
intercavernous (anterior and posterior) 97
maxillary 3, 5, 40, 41, 43–46, 142–144
occipital 97, 137
paranasal 44–46–see also individual paranasal sinuses
changes with age 46
pericardial
oblique 211, 237, 533
transverse 208, 211, 216, 217
petrosal
inferior 97, 98
superior 92, 97, 98
prostatic 367, 368
pyloric 267
rectal–see Sinus, anal
renal 321
sagittal
inferior 94, 97, 98, 137–139
superior 94–98, 100, 103, 137, 138, 143
sigmoid 92, 97, 98
sphenoidal 5, 6, 33–35, 44–46, 59, 60, 79, 98, 142–144
sphenoparietal 97, 98
straight 97, 98, 100, 137–139
tarsal 505, 506
transverse, of dura 97, 98, 137, 138
urethral–see Sinus, prostatic
urogenital 399
of Valsalva–see Sinus, aortic
venosus sclera–see Sinus, venous, scleral
venous 97, 98–see also individual venous sinuses
dural 97, 98
scleral 84

Sinusoid of liver 282–284
Skeleton–see Bone
Skene–see Duct, paraurethral; Gland, urethral, female
Skin 244
of penis 364, 365, 370
of scrotum 370
Skull–see Cranium
Slit, nasal 10
Sneeze 206
Snuffbox, anatomical 427, 450, 452, 453
Space–see also Pouch; Fossa; Recess
of Burns–see Space, suprasternal
of Disse–see Space, perisinusoidal
endopelvic 351
epidural 94, 96, 163
cranial–see Interface, dura-skull
vertebral 163
episcleral 79, 83
of Fontana–see Space, of iridocorneal angle
interglobular 53
interproximal, between teeth 53
intervaginal, of optic nerve 83
of iridocorneal angle (Fontana) 84
lumbar
inferior–see Triangle, lumbar
superior–see Triangle, auscultatory
of Mall–see Space, periportal (Mall)
midpalmar 443, 445, 446
paravesical 353
perianal 373, 374, 377
perichoroidal 83, 84
perineal (superficial) 348, 352, 355, 360, 364–366, 377, 384, 385, 391
perineopelvic 377
periportal (Mall) 283
perisinusoidal (Disse) 283
of Poirier 437
postanal 377
prerectal 377
presacral (potential) 351, 377
prevesical 243, 335, 346, 348, 351, 352, 377
quadrangular 409, 410
rectovaginal (potential) 351
rectovesical 348, 377
retropharyngeal 31, 56, 59, 61
retroprostatic 377
retropubic 335, 346, 348, 351, 352, 377
of Retzius–see Space, retropubic
subarachnoid 94, 96, 103, 162, 163
subdural 94, 96
submucous 373, 377
suprachoroidal 83, 84
suprasternal (Burns) 24, 31, 59
thenar 443, 445, 446
triangular 409, 410
vesicocervical (potential) 351, 354
vesicovaginal (potential) 351, 354
Sphenoid–see Bone, sphenoid
Sphincter
anal
external 276, 314, 335, 343, 347, 348, 352, 360, 361, 364–366, 372–378, 384, 398
internal 373–375
of Boyden–see Sphincter, of (common) bile duct
of (common) bile duct 287
esophageal
inferior 229
external anal–see Sphincter, anal, external
of hepatopancreatic ampulla 287, 317
ileocecal 274
of Oddi–see Sphincter, of hepatopancreatic ampulla
palatopharyngeal 61
of pancreatic duct 287
of pupillae–see Muscle, sphincter, of pupil
pyloric–see Pylorus
urethrae–see Muscle, sphincter urethrae 383
urethral
external–see Muscle, sphincter urethrae
internal 353, 367, 368
urethrovaginalis 343, 352, 355, 360, 361
Spine–see also Column, vertebral
iliac
anterior
inferior 240, 255, 340, 341, 345, 468, 469, 474, 475
superior 239, **240**–243, 251, 253, 255, 339, **340,** 341, 361, 363, 467, **468,** 469, 474–476, 478, 482
posterior
inferior 152, 340, 468
superior 145, 152, 340, 341, 468
ischial 152, 240, 255, 340–345, 378, 391, 393, **468,** 469, 485
mental 13, 49
nasal
anterior, of maxilla 2, 4, 6, 32, 34, 35
of frontal bone 34, 35
posterior, of palatine bone 8, 34, 35
of scapula 145, 167, 170, 178, 186, 193, 209, 404, 405, 407–411
of sphenoid bone 8, 12, 93
Spleen 192, 193, 264, 265, 267, 280, 288, **289,** 333, 336, 338, 534–536, 542
arteries of 290–292
cross sections 289, 534–536, 542
in situ 289
surfaces 289
veins of 299, 302
Splenium of corpus callosum 100, 101, 104, 106, 109, 136–139
Spur, scleral 83
Stage of development
of paranasal sinuses 46
Stalk, pituitary–see Infundibulum, of neurohypophysis
Stapes 87–89, 91
Stem, infundibular, of neurohypophysis 140
Stensen–see Duct, parotid
Sternum 25, 59, 173, 178, 182, 184, 187, 188, 229, 237, 238, 335, 407, 534, 535, 541, 542–see also Body, of sternum; Process
Stomach 192, 228, 229, 232, 233, 261, 264, 265, **267**–269, 279, 280, 285, 288, 289, 336, 338–see also Body, of stomach
arteries of 290, 291
bed of 266, 270
cross sections of 265, 268, 534, 535, 541, 542
innervation of (schema) 311
in situ 267
mucosa of 268
musculature of 269
nerves of 309, 310
variations in form of 267
veins of 303
Stria
medullaris of thalamus 100, 105, 109
olfactory 113
terminalis 102, 105, 106
Striatum 104
Submucosa 271
of esophagus 231, 232
of ileum 272
intestinal 316
of jejunum 272
of stomach 268
Substance
gelatinous 158
interpeduncular–see Substance, perforated, posterior
perforated
anterior 101, 113
posterior 108
Substantia
adamantina 53
eburnea 53
gelatinosa–see Substance, gelatinous
nigra 101
ossea 53
Sulcus–see also Groove
calcaneal 525
calcarine (cerebral) 99–101, 105, 114
carotid 9
central (cerebral) 99, 100
cerebral 99, 101, 134
cingulate (cerebral) 100
collateral (cerebral) 100, 101
coronal, of glans, penis 398
coronary 208, 210
of corpus callosum 100
frontal (cerebral) 99
hippocampal 106
hypothalamic 100, 109, 140
for inferior vena cava on liver–see Groove, for inferior vena cava, on bare area of liver
of insula 99

Sulcus *cont.*
interparietal (cerebral) 99
intertubercular, of humerus 403
interventricular, of heart
anterior 208
posterior 210, 211
lateral (cerebral) 99, 101, 134
limitans of 4th ventricle 109
lunate, of cerebrum 99
4th ventricle 109
nasolabial 1
occipital, transverse (cerebral) 99
occipitotemporal (cerebral) 100, 101
olfactory (cerebral) 101
orbital (cerebral) 101
paracentral (cerebral) 100
paracolic–see Gutter, paracolic
parieto-occipital (cerebral) 99, 100
of pharyngotympanic (auditory) tube 8
postcentral (cerebral) 99
precentral (cerebral) 99, 100
prechiasmatic 9
rhinal (cerebral) 100, 101
of Rolando–see Sulcus, central (cerebral)
of spinal cord
dorsal
intermediate 158
lateral 158
median 109, 158, 162
ventral lateral 158
Sylvian–see Sulcus, lateral (cerebral)
temporal 99, 101
terminalis 54, 210
transverse occipital 99
of 4th ventricle 109
Surface–see also Plate
of heart 208, 210
of liver 279
diaphragmatic 279, 281
parietal–see Surface, of liver, diaphragmatic
visceral 279, 281
lumbosacral articular 150
lunate, of acetabulum 469
of lung 195
costal 192–194
diaphragmatic 195
mediastinal 195
nasal, of maxilla 6
orbital, of frontal bone 9
patellar, of femur 471
of sacrum
auricular 150, 152
dorsal 150
pelvic 150
of tibia, articular 490, 495, 496
Sustentaculum tali 506–510
Suture
coronal 2, 4–7, 11
frontoparietal–see Suture, coronal
Suture *cont.*
intermaxillary 32
interparietal–see Suture, sagittal
lambdoid 4–7, 11
median palatine 8
parietooccipital–see Suture, lambdoid
sagittal 7, 11
sphenooccipital–see Synchondrosis, sphenooccipital
squamous 11
transverse palatine 8
Swelling, labioscrotal 398
Sylvian sulcus–see Sulcus, lateral (cerebral)
Symphysis, pubic 16, 239, **240,** 251, 253, 255, 339, 340–346, 348, 351, 352, 360, 363, 366, 382, 400, 540
Synapsis–see also Terminal, nerve
adrenergic 161
cholinergic 161
Synchondrosis
of first rib 402
manubriosternal 179, 402
sphenooccipital 59
xiphisternal 179
System
anterolateral (ALS) 158
biliary, intrahepatic (schema) 284
conducting, of heart 221
dorsal column 158
nervous, autonomic (ANS) 40, 115–117, 119, 120, **124**–128, 159–161, **205,** 206, 223, 224, 236, **308**–318, 330, 331, 334, 389, 390, 392, 394–397
schema 160
synapses of 161
topography of 159
nervous, parasympathetic 40, 115–117, 119, 120, 126–128, 159–161, 206, 223, 311, 314, 315, 317, 318, 331, 394–397
nervous, sympathetic 40, 115–117, 126–128, 159–161, 206, 223, 224, 311, 314, 315, 317, 318, 331, 334, 394–397
reproductive–see Organ, reproductive
Systole 218

T

T12 vertebra–see Process, spinous, vertebra, T12 vertebra
Taenia
of colon
free 263, 273, 274, 276, 372, 375
libera–see Taenia, of colon, free
mesocolic 273, 274, 276
omental 273, 276
of 4th ventricle 109
Tag, epithelial, of glans 398
Tail of
caudate nucleus 102, 104, 106
pancreas 288, 289, 319
Talus 505–508–see also Head; Process; Trochlea; of talus
Tarsal bone–see Bone, of foot
Tarsus–see Bone, of foot
of eyelid 77, 79, 80
Taste 54, 58, 117, 119, 129
Tectum–see Plate, tectal
Teeth 46, 52, 53, 229
Tegmen tympani 87
Tela choroidea of 3rd ventricle 102, 105, 138
Tendon 145, 401–see also individual muscles
Achilles 467, 498–500, 503, 509, 511
of ankle 509, 511–513
anular, common–see Ring, common tendinous
calcaneal 467, 498–500, 503, 509, 511
central, of
diaphragm 188, 189, 255
perineum–see Body, perineal
common
anular–see Ring, common tendinous
extensor 424, 427, 428
flexor 425, 426, 429
conjoined–see Falx, inguinal
digastric–see Tendon, intermediate, of digastric muscle
extensor, common 424, 426, 428
digitorum 401
longus 467
hallucis longus 467
indicis 401
pollicis longus 401
flexor, common 425, 426, 429
carpi radialis 401
carpi ulnaris 401
digitorum, superficialis 401
gracilis 467
intermediate, of digastric muscle 24, 25, 49, 55, 56
intersection, tendinous 174, **239,** 339
palmaris longus 401
patellar–see Ligament, patellar
plantaris 477, 498, 499, 504
popliteal 489–491
quadriceps femoris 467, 483, 487–489, 493, 501–503
rectus femoris 467
Tenon–see Sheath, fascial, of eyeball
Tentorium cerebelli 82, 97, 98, 100, 137, 138, 142
Terminal, nerve–see also Synapsis
adrenergic 206
cholinergic 206
Testis 335, 348, 369–371, 385, 396, 399, 400
Thalamus 100, 102, 104, **105,** 106, 108, 109, 137, 138, 140, 142, 314
Thebesian–see Valve, of coronary sinus;
Thigh
arteries of 482–484, 494
bones of 471–473
cross section of 487
lymph nodes of 528
muscles of 474–478
nerves of 482–484, 520–522
Thorax
arteries of 184, 187, 233–see also arteries of individual organs

Thorax *cont.*
bones of 178, 179
cross sections of 237, 530–533, 541, 542
joints of 179, 180
lymph vessels and nodes of 177, 204, 235
muscles of 182–186, 191
nerves of 182, 186, 187, 205–see also nerves of individual organs
veins of 184, 234–see also veins of individual organs
viscera of–see individual organs
Tibia 490, 492, 493, **495, 496,** 501, 475, 504, 507–509, 511–513–see also Condyle, of tibia
anterior 467
Tissue
adipose 31, 241–see also Tissue, subcutaneous
alar fibrofatty 32, 34
areolar
extraperitoneal 254
fatty, of anterior mediastinum 195
subcutaneous
fatty (Camper's) layer, of abdomen 241, 244, 335, 348, 360, 363
membranous layer
of abdomen (Scarpa's) 241, 244, 360
of perineum (Colles')–see Fascia, perineal, superficial (Colles')
Tongue 33, 35, 44, **54–57,** 59, 60, 62, 69, 119, 122, 129, 142
arteries of 55
cross sections of 56, 59
dorsum of 54
histology of 54
lymph vessels and nodes of 69
muscles of 55
veins of 55
Tonsil
of cerebellum 107, 109, 137
lingual 54, 59, 60
palatine 47, 48, 54, 56, 59, **60,** 62
pharyngeal 33, 59, 60, 62, 63
Topography of
abdominal viscera 260
autonomic nervous system 159
esophagus 229
gallbladder 278
kidney 320
liver 278
lung 192, 193
perineum 363
spinal nerve 153, 173
thyroid gland 70
Torus tubarius 33, 60, 62
Trabecula
carneae 216
fibrous, of adenohypophysis 140
of iridocorneal–see Meshwork, trabecular, of iridocorneal angle
septomarginal 216, 219, 220
Trachea 12, 24, 25, 31, 59, 61, 64, 70–73, 120, 161, 192, 194, **198,** 199, 203, 207, 209,
Trachea *cont.*
226, 228–230, 233, 530, 531, 541, 542
(bifurcation) 238
Tract
biliary 285–287
innervation (schema) 317
comma 158
corticospinal 158
dorsolateral 158
fiber, principle, of spinal cord 158
gastrointestinal 161
hypothalamohypophyseal 140
iliopubic 251, 351
iliotibial 467, 474, **476,** 477, 484, 487–490, 496, 498, 501–503
of Lissauer–see Fasciculus, dorsolateral
mammillothalamic 140
olfactory 39, 100, 101, 108, 113
optic 101, 102, 106, 108, 114, 132, 137
pontoreticulospinal 158
pyramidal 158
reticulospinal 158
rubrospinal 158
spinal, of trigeminal nerve 110, 111, 116, 119, 120
of spinal cord 158
spinocerebellar 158
spinohypothalamic 158
spinomesencephalic 158
spinoolivary 158
spinoreticular 158
spinotectal 158
spinothalamic 158
supraopticohypophyseal 140
tectospinal 126, 158
tuberohypophyseal 140
vestibulospinal 158
Tragus 1–see also Antitragus of external ear 88
Trapezium 435, 436, 439–441, 444, 450
Trapezoid 435, 436, 438–440
Treves–see Fold, ileocecal
Triad, portal 282, 535
Triangle
anal 363
auscultatory 246, 395, 533
of Calot 292–see Triangle, cystohepatic
cervical 22, 31, 167, 171, 182, 186
cystohepatic 292, 299
deltopectoral 239, 407
Hesselbach's–see Triangle, inguinal
inguinal 245, 251
lumbar 167, 186, 246
lumbocostal–see Triangle, lumbar
perineal–see Triangle, urogenital
of Petit–see Triangle, lumbar
sternocostal 189
suboccipital 171
urogenital 363
Trigone–see also Triangle
collateral 105
fibrous, of heart 218
Trigone *cont.*
habenular 105, 109
hypoglossal 109
lumbocostal 189
olfactory 113
of urinary bladder 348, 352, 353, 362, 367, 368
vagal 109
vertebrocostal 189
Triquetrum 435–440
Trochanter of femur
greater 145, 240, 467, 469–471, 474, 475, 477, 478, 484, 485, 540
lesser 240, 255, 470, 474, 471, 478
Trochlea
fibular 505–507
of humerus 403, 404, 419, 420
peroneal–see Trochlea, fibular
of superior oblique muscle 80
of talus 505, 506, 508
Trolard–see Vein, of Trolard
Tropism–see Facet, tropism
Trunk (arterial)
brachiocephalic 29, 70–72, 130, 131, 184, **190,** 202, 207–210, 228, 233
celiac 159, 189, 225, 228, 233, 256, 262, 266, 270, 288, **290**–295, 297–299, 301, 311, 314, 318, 319, 322, 335, 390, 535, 536
celiacomesenteric 297
of corpus callosum 100, 134
costocervical 28, 29, 65, 130, 131
gastrophrenic 297
hepatogastric 297
hepatolienomesenteric 297
hepatomesenteric 297
lienogastric 297
lienomesenteric 297
meningohypophyseal 95
pulmonary 202, 208, 211, 216, 220, 221, 225, 532, 542
thyrocervical 28–30, 65, 67, 70–72, 130, 131, 228, 233, 410
Trunk (lymphatic)–see also Duct, thoracic
bronchomediastinal 204, 258
intestinal 258, 305
jugular 68, 204, 258
lumbar 258, 305, 308, 333
subclavian 68, 204, 258
Trunk (nerve)
of brachial plexus 413
lumbosacral 259, 390, 478–481, 520, 521, 538, 539
sympathetic 43
cervical 31, 40, 65, 67, 119, **124**–128, 159, 224, 236
lumbar 159, 189, 224, 255, **259,** 308, 313, 314, 330, 334–337, 349, 350, 389, 390, 392, 394–396, 479–481
sacral 159, 334, 479, 481
thoracic 40, 126–128, 159, 187, 188, **205,** 224, 226, 227, 236, 237, 250, 308, 311, 314, 315, 317, 318, 394–396

Trunk (nerve) *cont.*
vagal
anterior 120, 159, 205, 228, **236,** 255, 308–313, 317, 318, 330, 334, 390
posterior 120, 159, **236,** 255, 308–313, 317, 318, 330, 334, 390
Tube
auditory–see Tube, pharyngotympanic; Cartilage, of auditory tube
Eustachian–see Tube, pharyngotympanic
Fallopian–see Tube, uterine
pharyngotympanic (auditory) 8, 33, 48, 51, 59–63, 87–89, 91, **93,** 120, 206
uterine 347, 349, 354–357, 380, 392, 395, 399
Tuber
of cerebellum 107, 109, 137
cinereum 100, 101, 108, 140
parietal 11
Tubercle
adductor 471, 475, 483, 484, 488, 491
anal 398
anterior 15, 16
of atlas 15, 18, 33
of C6–see Tubercle, carotid
thalamic 105
of transverse process of cervical vertebra 16
articular, of temporal bone 4, 8, 14, 51
of atlas, for transverse ligament 15
auricular 88
carotid 17
conoid, of clavicle 402
corniculate 62, 63, 74
cuneate 108, 109
cuneiform 62, 63, 74
dorsal, of radius 435
of external ear–see Tubercle, auricular
genital 398
Gerdy's 476, 489, 491, 495
gracile 108, 109
of humerus
greater 403–406, 409, 414, 415
lesser 403, 404, 414
of iliac crest–see Tuberculum, of iliac crest
infraglenoid of scapula 403, 404
intercondylar, of tibia 495, 496
mental, of mandible 2, 13
olfactory 113
pharyngeal, of basilar part of temporal bone 8, 17, 35, 59–61, 63
posterior 15, 16
of atlas 168, 169
of transverse process of cervical vertebra 16
pubic 239, **240,** 242, 243, 253, 255, 339–341, 345, 346, 360, 365, 468, 474, 475
of radius–see Tubercle, dorsal, of radius
of rib 178, 179
of scaphoid 435, 437, 439
of superior lip 1
Tubercle *cont.*
supraglenoid, of scapula 403
of talus 505
transverse ligament–see Atlas (C1), transverse ligament, tubercle
of trapezium bone 435, 437, 439
trigeminal 109
of Vater–see Papilla, duodenal, major
Tuberculum sellae 9
of iliac crest 240, 468
Tuberosity
calcaneal 467, 498, 499, 506, 507, 510, 514–517
of calcaneus 508
of cuboid bone 506, 510, 518
deltoid 403, 404
gluteal, of femur 471
iliac 240, 468
ischial 152, 240, **340**–342, 344, 346, 360, 361, 363–366, 373, 376, 378, 393, **468,** 469, 470, 477, 484, 485
maxillary 4, 12
of metatarsal bone
1st 506, 510–512
5th 505, 506, 508, 517–519
navicular 505, 506, 510, 513, 518
parietal–see Tuber, parietal
radial 414, 419, 420, 422
sacral 150
tibial 467, 474, 475, 488–491, 493, 495, 496, 501, 503
of ulna 414, 419, 422
Tubule
collecting, of kidney 325, 326
dentinal 53
mesonephric 399
seminiferous 371
Tunic dartos–see Fascia, superficial, (dartos); of penis; of scrotum
Tunica
albuginea
of corpora cavernosa penis 364, 368
of corpus spongiosum penis 364, 368
of penis–see Tunica, albuginea, of corpora cavernosa penis; of corpus spongiosum penis
testis 371
vaginalis, of testis 335, 370, 371
Tunnel, carpal 437
Turbinate–see Concha, nasal
Tyson–see Gland, preputial

U

Ulna 419–**422,** 423–428, 432–438, 440, 444, 448, 453–see also Olecranon (of ulna)
Umbilicus 239, 245, 297, 339
Umbo of tympanic membrane 88
Uncus
of brain 100, 101, 106, 113
of cervical vertebrae 16
Urachus 244, **245,** 252, 253, 266, 335, 348–352, 354, 360, 380, 383
Ureter 245, 252, 257, 263, 266, 308, 319, 321, **327,** 329, 337, 347–352, 354–356, 367, 372, 373, 380–384, 390, 392, 397, 537–539
Urethra 161, 255, 343, 344, 346, 352, 353, 360–**362,** 364, 366–**368,** 399, 540
female 352, 353, 360, 361, **362**
male
bulbous portion–see under Urethra, spongy
cavernous part–see Urethra, spongy
intermediate part 368
membranous part–see Urethra, intermediate part
pendulous (penile) portion–see under Urethra, spongy
prostatic 353, 368, 540
spongy 367, 368
bulbous portion 353, 367, 368
pendulous (penile) portion 367, 368
Urinary bladder–see Bladder, urinary
Uterus 347, 349, 352, 354–**356,** 357, 358, 360, 372, 380, 392, 394, 395, 399, 400
Utricle
prostatic 367, 368, 399
of vestibular labyrinth 87, 90, 91, 118
Uvula 47, 60, 62, 63
of bladder 353, 367, 368
of cerebellum 107, 109, 137

V

Vagina 343, 344, 347, 352, 353, **355**–357, 360–362, 372, 376, 380, 395, 398–400
Vallecula, epiglottic 54, 60
Valsalva–see Sinus, aortic
Valve
anal 374
aortic 217–221, 541
atrioventricular 219
of coronary sinus 216
eustachian–see Valve, of inferior vena cava
of foramen ovale 217
of heart 218, 219
Houston's–see Fold, transverse, of rectum
of inferior vena cava 216
of Kerckring 271
mitral 217–221, 237, 533, 541
pulmonary 216, 218, 221
rectal–see Fold, transverse, of rectum
thebesian–see Valve, of coronary sinus
tricuspid 216, 218–220, 237, 533, 541
Variation in
arteries
bronchial 203
cardiac–see Variation in, arteries, coronary
celiac–see Variation in, trunk, celiac
colic 298
coronary 213
esophageal 233
hepatic 297
renal 324
blood supply of heart 213

Variation in *cont.*
colon, sigmoid 277
ducts
bile 287
cystic 286
hepatic 286
pancreatic 287
liver, form of 280
sigmoid colon, position of 277
stomach, form of 267
trunk, celiac 297
uterus, position of 358
veins
cardiac 213
portal 303
renal 324
Vas deferens–see Ductus, deferens
Vasa rectae
of kidney 326
of small intestine–see Artery, straight (arteria recta)
Vasculature, visceral 290–311
Vater–see Papilla, duodenal, major
Vein–see also Sinus, venous
of abdominal wall 244, 252
accessory
cephalic 462, 511
hemiazygos 203, 227, 234
saphenous 526, 527
alveolar
inferior 56, 66
posterior superior 66
of anal canal 379
anastomotic
inferior (Labbé) 96, 138
superior (Trolard) 96
angular 19, 66, 81
antebrachial, intermediate (median) 401, 432, 462, 463
appendicular 305, 306
arcuate, of kidney 326
ascending lumbar 257, 322
atrial 139
auricular, posterior 19, 66
axillary 183, 194, 248, 411, 466, 541, 542
azygos 188, 189, 202, 203, 205, 226, 228, **234,** 237, 238, 255, 336, 531–534
basal (Rosenthal) 137–139
basilic 401, 412, 418, 432, 451, 462, 463, 466
basivertebral 166
brachial 412, 418
lateral 137
brachiocephalic 66, 70, 71, 184, 202, 204, 207, 208, 226–228, 234, 530, 541
of brain 137–139, 141
bronchial 203
capsular, of kidney 326
cardiac 212, 213
caudate 138, 139
cecal 301, 302

Vein *cont.*
central
of liver 282, 283
retinal 83, 86
of spinal cord 166
cephalic 174, 182, 183, 248, 401, 407, 411, 412, 418, 432, 451, **462,** 463, 466, 541
cerebellar 137
cerebral
anterior 137–139
deep 94, 96, 98, 137–139
direct lateral 138, 139
great (Galen) 97, 98, 100, 109, 137–139
internal 94, 102, 105, 137–139
superficial 94–**96,** 98, 138
cervical, transverse 66, 170
choroidal, superior 94, 138, 139
ciliary, anterior 84, 86
of ciliary body 86
circumflex humeral 462
of clitoris, deep dorsal–see Vein, dorsal, deep, of clitoris
colic
left 301–303
middle 288, 299–303
right 300–303, 337
of colon 301
communicating, between
anterior and internal jugular veins 27, 66
lumbar and hemiazygos veins 322
of conjunctiva 86
coronary 234–see also Vein, gastric, left
of cranial fossa, posterior 137
cremasteric 253, 381
cubital, median 401, 462, 466
cystic 303
deep, of thigh 487
deferential 301
digital
dorsal (foot) 526
dorsal (hand) 451, 463
palmar 463
diploic **94,** 96
dorsal
deep
of clitoris 257, 343, 344, 347, 351, 352
of penis 348, 364, 366, 381, 383, 385
superficial, of penis 339, 364
of duodenum 299
emissary 94, 96
mastoid 19, 94
occipital 94
parietal 19, 94
of Vesalius 66
epigastric
inferior 243, 245, **248,** 251–253, 257, 266, 337, 349, 350, 380, 381, 383
superficial 239, 241, 248, 257, 339, 482, 526
superior 183, 184, 243, 248, 336
episcleral 86

Vein *cont.*
esophageal 234, 299, 302, 303
of eye 86
of eyelids 81
facial 19, 27, 28, 43, 55–57, 66, 81
deep 19, 66
transverse 19, 66
femoral 242, 243, 248, 252, 253, 257, 363, 381, 387, 475, **482,** 483, 487, 526, 528, 540
deep–see Vein, deep, of thigh
fibular (peroneal) 498, 504
of Galen–see Vein, cerebral, great (Galen)
gastric
left 234, **299**–303, 336
right 234, 299–303
short 234, 266, 289, 299, 301–303, 336
gastroepiploic–see Vein, gastro-omental
gastro-omental 234, 289, 299, 301–303
gluteal 257, 301
of hand 451, 463
of head, superficial 19
of heart, 212, 213
hemiazygos 188, 189, 234, 237, 532
accessory 203, 227, 234
hemorrhoidal–see Vein, of anal canal; rectal
hepatic 225, 228, 234, 257, 266, 279, 282, 299
portal–see Vein, portal (hepatic)
hippocampal 139
hypophyseal 133, 141
hypothalamic 141
ileal 300, 301, 303
ileocolic 300–303
iliac
common 257, 263, 379, 381, 383, 392, 539
deep circumflex 245, 252, 257, 351, 383
external 245, 251–253, 257, 263, 273, 301, 347–**351,** 354, 373, 379, 381, 383, 483
internal 257, 301, 351, 355, 379, 381, 383
superficial circumflex 239, 241, 248, 257, 339, 482, 526
iliolumbar 257
infraorbital 19, 66
innervation of 224
innominate–see Vein, brachiocephalic
intercalated, of liver–see Vein, of liver, sublobular
intercapitular 451, 463
intercostal
anterior 184, 248
highest–see Vein, intercostal, superior
posterior 226, 227, 234, 248, 336
superior 226, 227, 234
interlobar, of kidney 326
interlobular, of kidney 326
intervertebral 166
intestinal 300, 301, 303
large 301
small 300
intraculminate 137

Vein cont.
intrapulmonary 201
jejunal 300, 301, 303
jugular 43
anterior 27, 66, 70, 248
external 1, 19, 27, 57, 66, 70, 194, 202, 207, 234, 248, 541
internal 19, 24–31, 55–57, **66,** 69–72, 122, 183, 184, 194, 202, 204, 207, 208, 228, 234, 248, 541
of kidney 321, 322, 326–see also Vein, renal
of Labbé–see Vein, anastomotic, inferior
labial 66
laryngeal, superior 66, 231
of left ventricle, posterior 212
of leg 498–502
lingual 19, 55–57, 66–see also Vena comitans, of hypoglossal nerve
deep 47, 55, 66
of liver
central 282, 283
intercalated–see Vein, of liver, sublobular
sublobular 282, 283
of lower limb, superficial 526, 527
lumbar 257, 322
ascending 257, 322
of lung 202
macular–see Venule, macular
Marshall–see Vein, oblique, of left atrium
maxillary 66
medullary, anterior 137
meningeal, middle 94, 96
mental 66
mesencephalic 137, 139
mesenteric
inferior 234, 262, 288, 299, **301**–303, 307, 337, 379
superior 172, 234, 266, 270, 271, 288, 295, 299, **300**–303, 307, 332, 337, 536, 537
metacarpal, dorsal 451, 463
metatarsal, dorsal 526
of mouth 66
musculophrenic 183, 184, 248
nasal
dorsal 19
external 66
of retina–see Venule, retinal, nasal
nasofrontal 19, 66, 81
of neck 27, 66
oblique, of left atrium 210–212, 217
obturator 234, 245, 257, 379, 383
occipital 19, 66
internal 139
ophthalmic
inferior 81
superior 66, 79, 81, 98
of orbit 81
ovarian 257, 301, 319, 322, 327, 337, 349, 351, 354, 356, 380, **384**

Vein cont.
tubal branch of 383
palatine, external 66
pancreatic 299, 301, 303
pancreaticoduodenal 299, 301–303
paraumbilical 245, 248, 302
of pelvic viscera 380, 382–385
of penis
dorsal
deep 241, 248, 257, 346, 348, 364, 366, 381, 383, 385
superficial 241, 248, 364, 383
lateral superficial 364
pericallosal 137, 139
pericardiacophrenic 184, 188, 202, 207, 208, 211, 226, 227, 237
perineal 385
peroneal–see Vein, fibular
petrosal 98, 137
of pharynx 66
phrenic, inferior 234, 257, 266, 322
pontine, transverse 137
pontomesencephalic, anterior 137
popliteal 477, 484, 487, 498, 499, 528
portal (hepatic) 225, 234, 265, 270, 271, 279–282, 285, 288, 290, 292, 299–**302, 303,** 307, 335, 336, 535, 536
anastomoses (portacaval) 302
branch of 283, 284
variations and anomalies of 303
of posterior cranial fossa 137
precentral 137
preculminate 137
prepyloric 299, 301
profunda femoris–see Vein, deep, of thigh
prostatic–see Plexus (venous), prostatic
pubic 252, 257
pudendal
external 248, 257
deep 381, 482
superficial 241, 381, 387, 493, 526
internal 257, 301, 373, 379, 385, 540
pulmonary 195, 201, 202, 208, 210, 211, 216, 217, 220, 221, 225–227, 237, 303, 533, 542
radicular 166
rectal 379
inferior 301, 302, 379
middle 257, 301, 302, 379
superior 266, 301, 302, 379
rectosigmoid 301, 302, 379
renal 234, 257, 289, 319, 321, **322,** 324, 328, 332, 333, 335, 380, 381, 537
of retina–see Venule, retinal
retromandibular 19, 27, 43, 55–57, 66, 81
retrotonsillar 137
of Rosenthal–see Vein, basal (Rosenthal)
sacral
lateral 257
median 257, 301, 354, 379, 380, 383
saphenous
accessory 526, 527

Vein cont.
great 241, 242, 248, 257, 363, 387, 467, 487, 504, 526–528
small 467, 484, 498, 504, 526–528
of scalp 19
scrotal, anterior 248
septal 138, 139
sigmoid 266, 301, 302, 337, 379
of skull 94
spermatic
external–see Vein, cremasteric
internal–see Vein, testicular
spinal 137, 166
splenic 234, 265, 266, 289, 295, **299**–303, 307, 333, 335, 336, 535, 536
stellate, of kidney 321, 326
of stomach 299
straight 300
subclavian 26, 28, 29, 66, 70, 71, 183–185, 194, 202, 204, 207, 208, 226–228, **234,** 248, 412
subcostal 257
subependymal 139
sublingual 55, 57
sublobular, of liver 282, 283
submental 66
sulcal (anterior and posterior) 166
superficial
of arm 462
cerebral 96
of head 19
of lower limb 526, 527
of neck 27
of shoulder 474
of trunk 248
supraorbital 19, 66, 81
suprarenal 234, 257, 322, 333
suprascapular 66
supratrochlear 19, 66, 81
temporal
deep 94
middle 19, 94
of retina–see Venule, retinal, temporal
superficial 19, 57, 66, 94, 96
terminal–see Vein, thalamostriate, superior
testicular 251–253, 257, 266, 301, 319, 322, 327, 337, 350, **381**
thalamic, superior 139
thalamostriate 94, 139
caudate 139
inferior 137, 139
superior 102, 105, 138, 139
of thigh 526, 527
deep 487
thoracic
internal 71, 183, 184, 188, 194, 208, 237, 248, 531–533
lateral 248
thoracoacromial 462
thoracoepigastric 241, 248
thyroid
inferior 66, 70, 71, 194, 207, 234

Vein *cont.*
middle 66, 70
superior 27, 66, 70
tibial
anterior 504
posterior 498, 499, 504
of Trolard 96
of trunk, superficial 248
tubal branch of ovarian–see Vein, ovarian, tubal branch
umbilical 225
uncal 138
uterine 257, 301, 354–356, 379, 384
vaginal 305, 383
vermian 137, 139
of vertebrae 166
vertebral 234
vesalian–see Vein, emissary, of Vesalius
vesical 257, 301, 379
vorticose 81, 86
zygomaticofacial 19
zygomaticotemporal 19
Velum
medullary, of cerebellum
inferior 100, 107
superior 100, 107–109
of palate 47, 62
Vena cava
inferior 172, 188, 202, 205, 209–211, 216, 217, 219, 221, 225, 226, 228, 234, 237, 238, **257,** 264–266, 270, 279, 281, 288, 299, 303, 319, 320, 322, 324, 332, 333, 336–338, 349, 350, 378–383, 392, 534–538, 541
superior 70, 71, 190, 202, 207–211, 216, 220, 221, 225, 226, 234, 531–533, 541
Vena comitans
of hypoglossal nerve 55, 56, 66
of radial artery 443
of ulnar artery 443
of vagus nerve 234
Vena recta–see Vein, straight
Vena terminalis–see Vein, thalamostriate, superior
Ventricle
of brain 102
lateral 94, **102,** 104, 106, 132, 136, 139, 142
3rd **102,** 105, 109, 139
4th 100, 102, 107, **109,** 136, 137, 139, 143
of heart
left 208–211, **217,** 220, 237, 238, 533, 542
right 208, 210, 211, **216,** 220, 237, 238, 533, 542
Venule
macular 86
rectae, of renal parenchyma 330
retinal 83
nasal 86
temporal 86
Vermis of cerebellum 107, 109
Vertebra–see Body, vertebral, C4 vertebra; C7 vertebra
C1–see Atlas (C1)
C1 vertebra–see under Atlas (C1)
C2–see Dens
C2 vertebra–see Dens
C3 vertebra 15
inferior articular facet 15
C4 vertebra 15, 16
C7 vertebra 16–see also Process, vertebra, C7 vertebra
cervical 12, 15–17, 26, 31, 146, 153, 154, 193, 229
coccygeal–see Coccyx
inferior articular facet–see Vertebra, C3 vertebra
lumbar 146, 148, 151–154, 163, 229
notch, of L4 vertebra
inferior vertebral 149
prominens 16, 17
sacral–see Sacrum
thoracic 12, 146, 147, 153, 154, 163, 229
Verumontanum–see Colliculus, seminal
Vesalius, vein of–see Vein, emissary (Vesalius)
Vesicle, seminal 348, 350, 367, 399
Vessel–see Cord
blood–see Artery; Vein
epigrastric
inferior 254
lymph–see Lymph vessel
testicular 254
Vestibule
of bony labyrinth 87, 90, 91
nasal 33, 35, 43
of vagina 355, 359, 399
Vidian–see Nerve, of pterygoid canal
Vinculum 447
Viscera 267–277–see also individual organs
Vision 114
Vomer 2, 6, 8, 35, 43

W

Wall
abdominal 240–259
anterior 241–245, 247–249
arteries of 247
dissection of 241–243
deep 243
intermediate 242
superficial 241
internal view 245
nerves of 249
peritoneum of 245
veins of 248
posterior 255–259
arteries of 256
internal view 255
lymph vessels and nodes of 258
nerves of 259
peritoneum of 266
veins of 257
posterolateral 246
Wall *cont.*
nasal
lateral 33, 34
medial 35–see also Septum, nasal
thoracic 182–187
anterior 182–184
cross sections of 187, 530–534
cutaneous nerves of 182
muscles of 182–187
posterior 186
Wharton–see Duct, submandibular; Gland, submandibular
Window
cochlear–see Window, round
oval 11, 87–91
round 11, 87–91
vestibular–see Window, oval
Wing of
central (cerebellar) lobule 107
ilium 240, 340, 345, 468
sacrum 150
sphenoid bone
greater 2–6, 8, 9, 11
lesser 2, 6, 9
Winslow–see Foramen, omental (epiploic)
Wirsung–see Duct, pancreatic, principal
Wolffian duct–see Duct, mesonephric (Wolffian)
Wrist
arteries of, 444, 456
bones of 435, 439
dissection of
superficial 442, 450–452
deep 443
ligaments of 437, 438
movements of 436
nerves of 444, 455
tendons of 444, 453

X

X-ray–see Arteriogram of coronary arteries; Radiograph
Xiphoid–see Process, xiphoid

Y

Y ligament–see Ligament, iliofemoral

Z

Zinn–see Ring, common tendinous; Zonule, ciliary (of Zinn)
Zona
orbicularis, of hip joint 469
Zone–see also Area; Region
of cutaneous innervation of face 20
of stomach 268
subcapsular, of kidney 325, 326
Zonule, ciliary (of Zinn) 83–86